Received: 6 May 2026 | Revised: 19 June 2026 | Accepted: 22 July 2026

DOI: 10.1002/vrc2.70547

Vet Record CaseReports

CASE REPORT

Companion or pet animals

Extragonadal mature cystic teratoma in a cat

Sinem Yaren Guzelbakan[1] | **Esra Acar**[2] | **Ozge Erdogan Bamac**[1] | **Murat Karabagli**[3]

[1]Faculty of Veterinary Medicine, Department of Pathology, Istanbul University-Cerrahpasa, Istanbul, Turkey

[2]Institute of Graduate Studies, Faculty of Veterinary Medicine, Istanbul University-Cerrahpasa, Istanbul, Turkey

[3]Faculty of Veterinary Medicine, Department of Surgery, Istanbul University-Cerrahpasa, Istanbul, Turkey

Correspondence
Sinem Yaren Guzelbakan, Faculty of Veterinary Medicine, Department of Pathology, Istanbul University-Cerrahpasa, Istanbul, Turkey.
Email: sinem.guzelbakan@iuc.edu.tr

Abstract

An 8-month-old, entire, female Scottish Fold cat was presented with decreased appetite, constipation and abdominal distension. Radiography and computed tomography revealed a well-defined pelvic mass containing mineralised and fat-density components. The mass was surgically excised and was anatomically separate from both ovaries. Histopathological examination identified mature epithelial and mesenchymal elements, including keratinising stratified squamous epithelium, glandular structures, hyaline cartilage and bone, supporting a diagnosis of extragonadal mature cystic teratoma. Postoperative recovery was uneventful, and no clinical signs suggestive of recurrence were reported during follow-up. This case highlights the importance of considering extragonadal teratoma as a differential diagnosis for pelvic masses in young cats. It demonstrates the value of combined cross-sectional imaging, surgical exploration and histopathology for diagnosis.

KEYWORDS
cat, mature, teratoma

BACKGROUND

Teratomas are germ cell neoplasms composed of differentiated tissues derived from at least two embryonic germ layers, most commonly arising in the gonads. In cats, teratomas are uncommon and predominantly gonadal; extragonadal forms are exceptional, with only sporadic cases documented in the veterinary literature.[1–6] Diagnosis is based on the histopathological identification of mature or immature tissue components representing more than one germ layer, and biological behaviour ranges from benign, following complete excision of mature lesions, to potentially malignant in immature variants containing embryonal tissue.[7] This report describes an extragonadal mature cystic teratoma located in the pelvic cavity of a young cat, a previously unreported anatomical location in this species, and discusses its clinical presentation, advanced imaging findings, surgical management and histopathological features.

CASE PRESENTATION

An 8-month-old, entire, female Scottish Fold cat was presented to the Istanbul University-Cerrahpaşa Veterinary Teaching Hospital with a history of constipation, decreased appetite and abdominal distension. On physical examination, abdominal palpation revealed a firm, irregular mass-like structure in the caudal abdomen. The cat was alert, and the vital parameters were within acceptable clinical limits. Radiographic and computed tomographic examinations were performed to further characterise the lesion, determine its anatomical relationships and guide surgical planning.

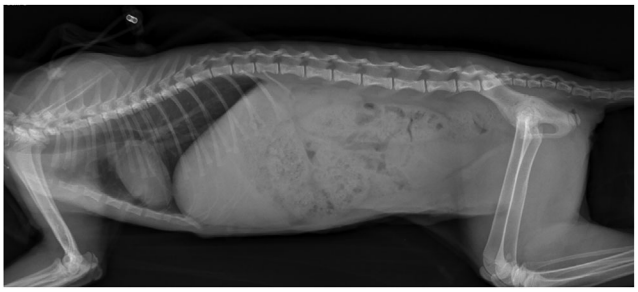

FIGURE 1 On the lateral abdominal radiograph, the colon appears markedly distended with faecal material. In the caudoventral abdomen, a prominently distended urinary bladder with smooth margins and soft tissue/fluid opacity is also evident.

INVESTIGATIONS

No obvious abnormality was identified on the available latero-lateral survey abdominal radiograph (Figure 1); ventrodorsal or dorsoventral projections were not available for evaluation. However, marked accumulation of faecal material within the

All rights reserved, including rights for text and data mining and training of artificial intelligence technologies or similar technologies.
© 2026 British Veterinary Association.

colon, together with palpation of a firm structure at the level of the pelvic inlet, prompted further diagnostic evaluation.

Computed tomography (CT) examination revealed a well-defined but irregularly contoured soft tissue mass located within the pelvic region, ventral to the sacral and caudal lumbar vertebrae (Figure 2). The mass measured approximately 4.5 × 2.5 × 2.5 cm and exhibited mixed attenuation characteristics, including coarse mineralised components and focal fat-density areas. The lesion displaced the rectum ventrally and caused compression of adjacent colonic loops, resulting in gas and faecal distension. On contrast-enhanced images, a marked mass effect was observed at the level of the abdominal aortic bifurcation and the bilateral iliac vessels; however, no appreciable internal contrast enhancement or vascularisation was identified within the mass. No evidence of invasion into adjacent osseous structures was detected. Although the margins between the lesion and the left psoas muscle were partially indistinct, definitive muscular invasion could not be confirmed. In addition, heterogeneous splenic enhancement and mildly enlarged mesenteric lymph nodes with a reactive appearance were observed. Overall, the CT findings were considered most consistent with a teratomatous lesion.

Following diagnostic imaging, exploratory laparotomy was performed. A well-encapsulated mass was identified in the pelvic cavity and was completely excised (Figure 3). Both ovaries were visualised intraoperatively and appeared grossly normal. The mass was neither part of nor continuous with either ovary. This finding supported an extragonadal origin. No intraoperative complications occurred, and the cat recovered uneventfully from anaesthesia. The excised specimen was submitted for histopathological examination.

Grossly, the excised mass was ovoid, with a smooth and focally multilobulated external surface, and measured approximately 4.5 × 2.5 × 2.5 cm (Figure 4).

LEARNING POINTS/TAKE-HOME MESSAGES

- Extragonadal teratoma should be considered as a differential diagnosis for pelvic or caudal abdominal masses in young cats.
- Computed tomography identification of fat density and mineralised components can strongly support a preoperative suspicion of teratoma.
- Intraoperative confirmation of anatomical separation from the ovaries is important when diagnosing an extragonadal lesion in female cats.
- Histopathology is required for definitive diagnosis and for distinguishing mature teratomas from immature or malignant forms.

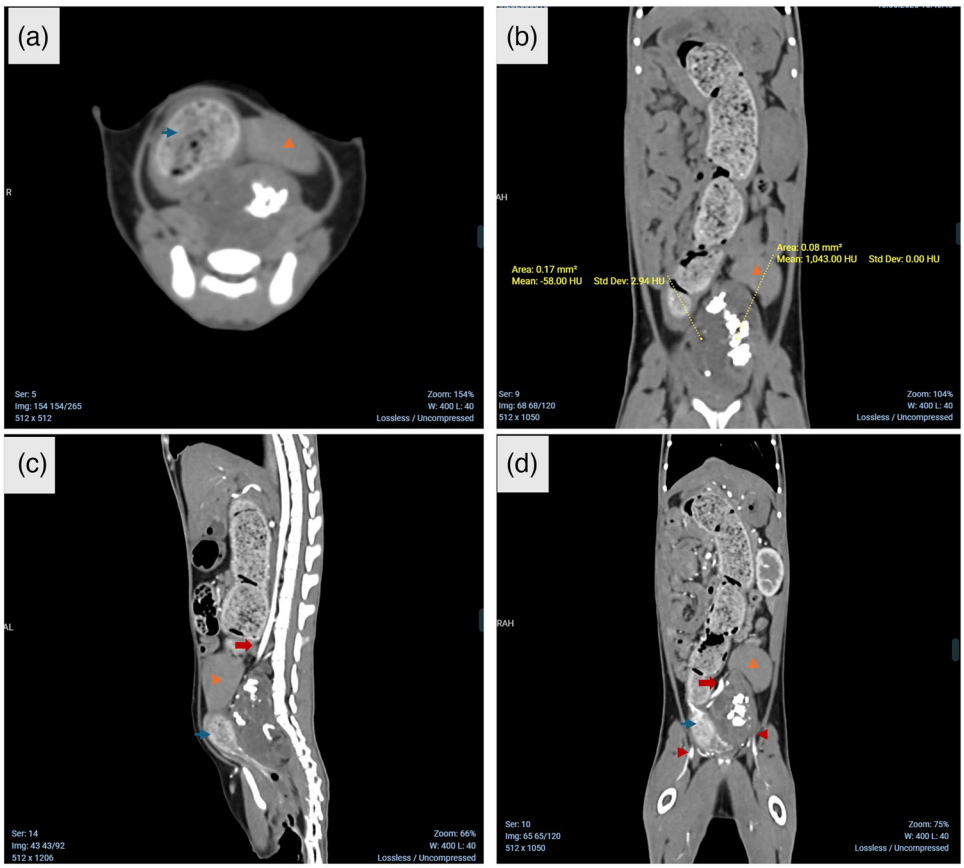

FIGURE 2 (a and b) Non-contrast transverse and dorsal computed tomography (CT) images demonstrate a space-occupying lesion with heterogeneous internal composition located within the pelvic region, measuring approximately 4.5 × 2.5 × 2.5 cm. The mass causes ventral displacement of the colon (blue arrow) and urinary bladder (orange triangle). Attenuation measurements obtained from the dorsal images reveal areas with values of −58 HU (SD 2.94), consistent with fat-density tissue, and regions measuring 1043 HU (SD 0), compatible with densely mineralised tissue. (c and d) Contrast-enhanced sagittal and dorsal CT images acquired during the arterial phase demonstrate the abdominal aorta (thick red arrow) and the bilateral iliac vascular structures (thin red arrows). The mass exerts a marked mass effect on the adjacent vascular structures and is localised between major arterial vessels.

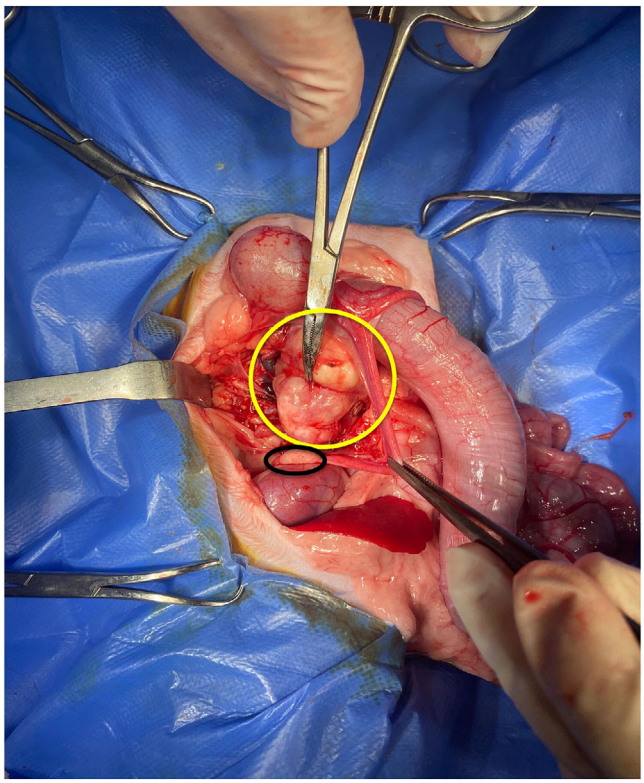

FIGURE 3 Intraoperative appearance during laparotomy. The pelvic mass (yellow circle) is seen adjacent to the intestinal loops, while the left ovary (black circle) is grossly separate from the lesion.

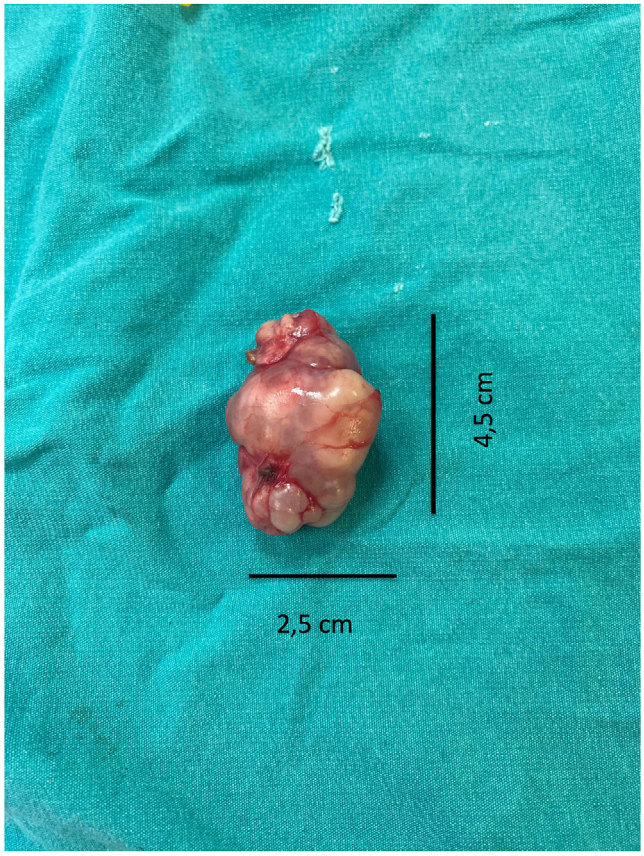

FIGURE 4 The excised mass is ovoid and focally multilobulated, with a smooth external surface, measuring approximately 4.5 × 2.5 × 2.5 cm.

The specimen was fixed in 10% neutral buffered formalin for 24 hours. Following routine processing and paraffin embedding, 4–5 μm sections were prepared and stained with haematoxylin and eosin. Histological evaluation was performed using light microscopy.

Histopathological examination showed a cystic and solid lesion composed of mature ectodermal and mesodermal tissue elements (Figure 5A–D). The cystic spaces were lined by keratinising stratified squamous epithelium, and the lumen contained concentrically arranged lamellar keratin. The supporting stroma contained well-differentiated glandular structures lined by cuboidal to low columnar epithelium, mature bone tissue and well-differentiated hyaline cartilage. No immature neuroectodermal or other embryonal components, marked cellular atypia, infiltrative growth or malignant transformation were identified in the examined sections. These findings supported a diagnosis of extragonadal mature cystic teratoma.

DIFFERENTIAL DIAGNOSIS

Differential diagnoses for a pelvic mass in a young cat included ovarian neoplasia, abscess, granuloma, mesenchymal neoplasia, developmental cystic lesions, dermoid/epidermoid cyst and other mineralised soft tissue masses. The combination of fat density and mineralised components on CT was strongly suggestive of a teratomatous lesion, while intraoperative separation from both ovaries and histopathology supported an extragonadal mature cystic teratoma.

TREATMENT

Complete surgical excision was performed. For localised mature teratomas, complete excision is considered the treatment of choice and is expected to be curative when no immature or malignant components are present.

OUTCOME AND FOLLOW-UP

Postoperative recovery was uneventful, and the cat was discharged in good clinical condition. Follow-up information obtained from the owner indicated that the cat remained clinically well, with normal appetite and defecation. No clinical signs suggestive of recurrence or postoperative complications were reported during the follow-up period. No repeat imaging or histopathological re-evaluation was performed; therefore, absence of recurrence was assessed clinically.

DISCUSSION

Extragonadal teratomas are exceptionally rare in cats.[8] Previously reported locations include the intracranial region, retrobulbar space, head and neck, oropharyngeal region, perineal region and tail.[4–6,8,9] The present case, involving a pelvic mass in an 8-month-old Scottish Fold cat, adds to the limited veterinary literature and supports inclusion of extragonadal

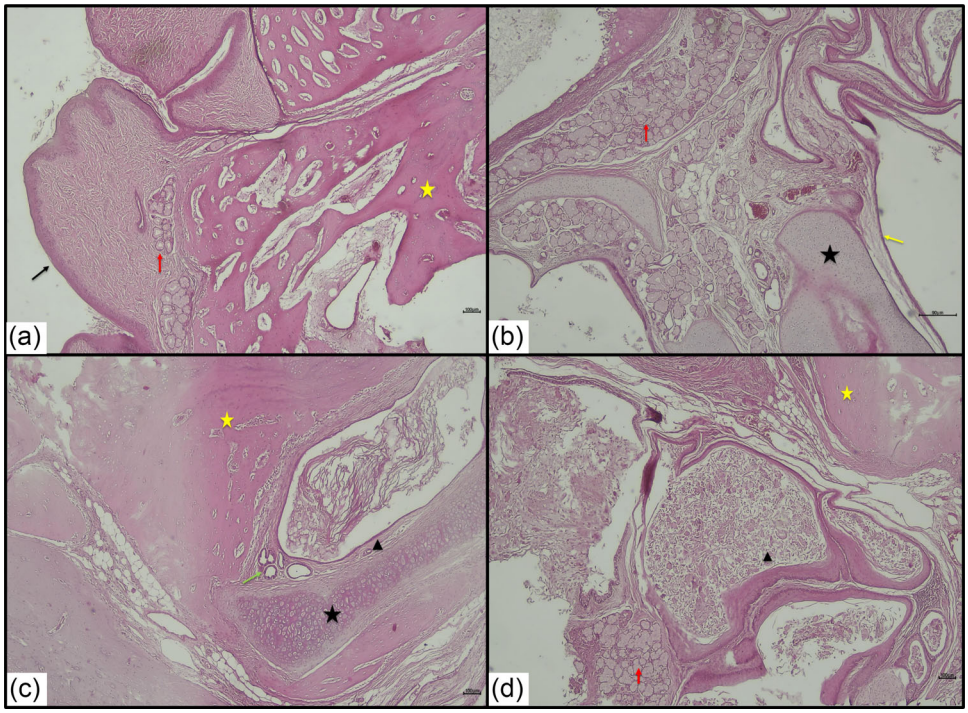

FIGURE 5 Cat, extragonadal mature cystic teratoma, haematoxylin and eosin. (A) Stratified squamous epithelium (black arrow), glandular structures (red arrow) and mature bone tissue (yellow star). Scale bar = 100 μm. (B) Glandular structures (red arrow), hyaline cartilage (black star), and a cyst wall with surface keratinisation and scattered keratin lamellae (yellow arrow). Scale bar = 90 μm. (C) Mature bone (yellow star), hyaline cartilage (black star), a cystic structure lined by keratinising squamous epithelium and filled with lamellar keratin material (arrowhead), and adjacent glandular structures lined by cuboidal epithelium (green arrow). Scale bar = 100 μm. (D) Glandular structures (red arrow), mature bone tissue (yellow star) and keratinised cyst content (arrowhead). Scale bar = 100 μm.

germ cell tumours among the differential diagnoses for pelvic or caudal abdominal masses in young cats.

The pathogenesis of extragonadal teratomas is generally attributed to aberrant migration or ectopic arrest of primordial germ cells during embryogenesis.[10] Primordial germ cells arise outside the developing gonads and migrate towards the genital ridges; misplaced germ cell rests along or near this route may subsequently undergo neoplastic differentiation.[2,10] The pelvic location in the present case is anatomically compatible with this proposed mechanism. However, as embryological origin cannot be directly demonstrated in a single clinical case, this interpretation should be regarded as a plausible pathogenetic explanation rather than a proven mechanism.

Histologically, the lesion contained keratinising stratified squamous epithelium, glandular structures, hyaline cartilage, and mature bone, without immature, embryonal or malignant components in the examined sections. These features are consistent with a mature cystic teratoma and are comparable to previously reported feline extragonadal teratomas, in which mature tissue derivatives predominate.[6,8]

Advanced imaging was central to preoperative assessment. CT demonstrated a well-defined pelvic mass with mixed attenuation, including fat-density areas and coarse mineralised components. In human radiology, fat attenuation within a cystic mass, with or without calcification, is highly suggestive of mature cystic teratoma.[11] In this case, CT provided detailed delineation of the anatomical relationship between the mass and the rectum, colon, pelvic structures, and adjacent musculature, while demonstrating no evidence of osseous invasion, thereby contributing significantly to surgical planning. In addition, contrast-enhanced imaging revealed that the mass was in proximity to the abdominal aorta and the bilateral iliac vessels; despite this, no appreciable contrast enhancement or internal vascularisation was identified within the lesion. The preoperative recognition of these features was valuable for surgical risk assessment and facilitated safe intraoperative manipulation of the mass.

Intraoperative exploration was essential for confirming the extragonadal nature of the lesion. Both ovaries were grossly normal and anatomically separate from the mass, excluding a direct ovarian origin on surgical assessment.

Most reported mature feline extragonadal teratomas have followed a favourable clinical course after complete excision.[6,8] This cat recovered uneventfully and remained clinically well according to the owner's follow-up reports. Nevertheless, because repeat imaging was not performed, the outcome should be interpreted cautiously.

Taken together, this case reinforces that extragonadal teratoma, although rare, should be considered in young cats presenting with well-defined pelvic or caudal abdominal masses, particularly when imaging reveals a combination of fat and mineralisation. A multimodal approach combining radiography, CT, surgical exploration and histopathological examination is essential for accurate diagnosis and appropriate management.

AUTHOR CONTRIBUTIONS

Murat Karabagli and **Esra Acar** performed the clinical examination, diagnostic work-up and surgical treatment. **Ozge Erdogan Bamac** performed the pathological evaluation and interpreted the histopathological findings. **Sinem**

Yaren Guzelbakan and **Ozge Erdogan Bamac** supervised the pathological assessment. **Sinem Yaren Guzelbakan** drafted the manuscript. All authors contributed to data interpretation, critically revised the manuscript and approved the final version.

CONFLICT OF INTEREST STATEMENT

The authors declare no conflicts of interest.

FUNDING INFORMATION

No specific grant from any funding agency in the public, commercial or not-for-profit sectors was received for this case report. Diagnostic and treatment costs were covered by the owner as part of clinical care.

ETHICS STATEMENT

This report describes the diagnosis and treatment of a client-owned cat presented for clinical care at an accredited veterinary teaching hospital. Diagnostic imaging, surgery and histopathological examination were performed as part of standard veterinary care and with the owner's informed consent. According to institutional and national requirements, formal ethical committee approval was not required for this single clinical case report. Written informed consent for publication of the case details and images was obtained from the owner.

ORCID

Sinem Yaren Guzelbakan https://orcid.org/0009-0005-3777-2738
Esra Acar https://orcid.org/0000-0002-9322-3910
Ozge Erdogan Bamac https://orcid.org/0000-0002-0352-4841
Murat Karabagli https://orcid.org/0000-0002-3936-1730

REFERENCES

1. Salzillo C, Imparato A, Fortarezza F, Maniglio S, Lucà S, La Verde M, et al. Gonadal teratomas: a state-of-the-art review in pathology. Cancers. 2024;16(13):2412.
2. Oosterhuis JW, Looijenga LHJ. Testicular germ-cell tumours in a broader perspective. Nat Rev Cancer. 2005;5(3):210–22.
3. Basaraba RJ, Kraft SL, Andrews GA, Leipold HW, Small D. An ovarian teratoma in a cat. Vet Pathol. 1998;35(2):141–44.
4. Chénier S, Quesnel A, Girard C. Intracranial teratoma and dermoid cyst in a kitten. J Vet Diagn Invest. 1998;10(4):381–84.
5. Wray JD, Doust RT, McConnell F, Dennis RT, Blunden AS. Retrobulbar teratoma causing exophthalmos in a cat. J Feline Med Surg. 2008;10(2):175–80.
6. Van Goethem B, Bosmans T, Chiers K. Surgical resection of a mature teratoma on the head of a young cat. J Am Anim Hosp Assoc. 2010;46(2):121–26.
7. Kennedy PC, Cullen JM, Edwards JF, Goldschmidt MH, Larsen S, Munson L, et al. Histological classification of tumors of the genital system of domestic animals. 2nd ed. Washington (DC): Armed Forces Institute of Pathology; 1998.
8. Sirivisoot S, Siripara N, Arya N, Techangamsuwan S, Rungsipipat A, Kasantikul T. Case report: mature extragonadal teratoma at the proximal part of the tail in a kitten. Front Vet Sci. 2022;9:1003673.
9. Yuzbasioglu-Ozturk G, Gulcubuk A, Ozturk-Gurgen H, Demirutku A, Akcasiz ZN, Ozkul S. An unusual case of oropharyngeal mature teratoma in a kitten. Iran J Vet Res. 2023;24(4):365–68.
10. Wylie C. Germ cells. Cell. 1999;96(2):165–74.
11. Outwater EK, Siegelman ES, Hunt JL. Ovarian teratomas: tumor types and imaging characteristics. Radiographics. 2001;21(2):475–90.

How to cite this article: Guzelbakan SY, Acar E, Bamac OE, Karabagli M. Extragonadal mature cystic teratoma in a cat. Vet Rec Case Rep. 2026;14:e70547. https://doi.org/10.1002/vrc2.70547

MULTIPLE-CHOICE QUESTION

The histopathological examination revealed a cystic lesion composed of keratinising stratified squamous epithelium, glandular structures, hyaline cartilage and mature bone. What is the most likely diagnosis?

POSSIBLE ANSWERS TO MULTIPLE-CHOICE QUESTION

A) Epidermoid cyst
B) Dermoid cyst
C) Extragonadal mature cystic teratoma
D) Retroperitoneal abscess

CORRECT ANSWER

C) Extragonadal mature cystic teratoma.

The presence of mature epithelial and mesenchymal tissues, including squamous epithelium, glandular structures, cartilage and bone, supports a diagnosis of mature teratoma. The intraoperative absence of continuity with either ovary supports an extragonadal origin.