European Journal of Cardio-Thoracic Surgery 44 (2013) 567–569
doi:10.1093/ejcts/ezt163 Advance Access publication 22 March 2013

CASE REPORT

Vascular thoracic outlet syndrome developed after minimally invasive repair of pectus excavatum†

Burcu Kılıç, Ahmet Demirkaya, Akif Turna* and Kamil Kaynak

Department of Thoracic Surgery, Istanbul University, Cerrahpasa Medical School, Istanbul, Turkey

* Corresponding author. Cami Sok. Muminderesi Yolu. No:32/22, Sahrayicedid, Istanbul, Turkey. Tel: +90-505-258-1581; fax: +90-216-411-6651; e-mail: akif.turna@gmail.com (A. Turna).

Received 3 January 2013; received in revised form 22 February 2013; accepted 24 February 2013

Abstract

The Nuss procedure is a minimally invasive surgical repair technique for pectus excavatum with fewer delayed complications compared to open procedures. We report the case of a 22-year-old man with deep pectus excavatum who developed vascular thoracic outlet syndrome after the Nuss procedure. Further evaluation demonstrated that the first rib was causing severe obstruction of the right subclavian artery. The patient showed clinical features of subclavian artery compression. A first rib resection, division of the anterior scalene muscle and fibrous bands provided complete relief of the complaints. The forced structural and spatial changes produced by the elevation of the depressed upper chest might have caused this complication. Vascular thoracic outlet syndrome should be kept in mind as a possible complication in patients who have undergone minimally invasive repair of pectus excavatum, and this complication can be treated by first rib resection.

Keywords: Pectus excavatum • Nuss procedure • Thoracic outlet syndrome • Vascular compression • First rib resection • Complication

INTRODUCTION

Pectus excavatum is a congenital chest wall deformity in which several ribs and the sternum grow abnormally, producing a concave, or caved-in appearance in the anterior chest wall [1]. It has been reported to be the most common chest wall deformity and is more common in men [1]. A minimally invasive technique to correct pectus excavatum was first performed in 1987 by Donald Nuss [2]. This minimally invasive correction consists of the placement under the sternum of a steel bar bent into the desired chest shape, by video-assisted thoracoscopic surgery. The bar is removed after a minimum of 2 years. This approach has shown excellent functional and cosmetic results [2] and has been performed on an increasing number of patients. However, complications, including a number of major early complications, such as heart perforation, pneumothorax and pleural effusion, have been reported to occur after minimally invasive repair [2].

CASE REPORT

The minimally invasive Nuss procedure was performed in a 22-year-old male patient with pectus excavatum deformity. The Haller index measured on preoperative thoracic computed tomography was 4.7. The surgical correction was performed as described by Nuss [3], with insertion of two bars. A stainless-steel stabilizer was placed on the left side of the upper bar, and lower bar was stabilized with 2-0 polydiaxanone sutures laterally at two points. The postoperative chest X-ray was normal, and the patient was discharged on the sixth postoperative day.

After 1 month, the patient presented at the out-patient clinic with pain in both arms. The right arm and hand were diffusely cold and weak, and we noticed that there was no right-sided radial pulse in the costaclavicular position and with the hyperabduction manoeuvre. The signs were mostly attributable to arterial compression, whereas there was no sign of venous occlusion. There was no hypoaesthesia or anaesthesia. Possible compression of the subclavian artery between the clavicle and the first rib was confirmed by arterial Doppler ultrasonography (Fig. 1). An anterograde magnetic resonance arteriogram of the subclavian artery demonstrated that the subclavian artery was occluded by the first rib during extension of the right arm (Fig. 2). Filling of the subclavian artery was normal on computed tomography angiographic examination of the right upper extremity. The artery was partly compressed during right arm abduction and external rotation on its course between the clavicle and the first rib.

Non-steroidal anti-inflammatory therapy (i.e. ketorolac) did not alleviate the symptoms. In order to treat this complication, the first rib, anterior scalene muscle and all fibrous adhesions around the first rib were resected via an axillary incision under general anaesthesia. Postoperatively, the patient had no complaints. The right radial pulse was palpable and normal postoperatively. The patient was discharged after 3 days. He did well and had no complaints during the following 3 years. The bar was removed after 3 years without any complications and with an excellent cosmetic result.

† Presented at the 18th European Conference on General Thoracic Surgery, Valladolid, Spain, 30 May–2 June 2010.

© The Author 2013. Published by Oxford University Press on behalf of the European Association for Cardio-Thoracic Surgery. All rights reserved.

Downloaded from https://academic.oup.com/ejcts/article-abstract/44/3/567/635752 by guest

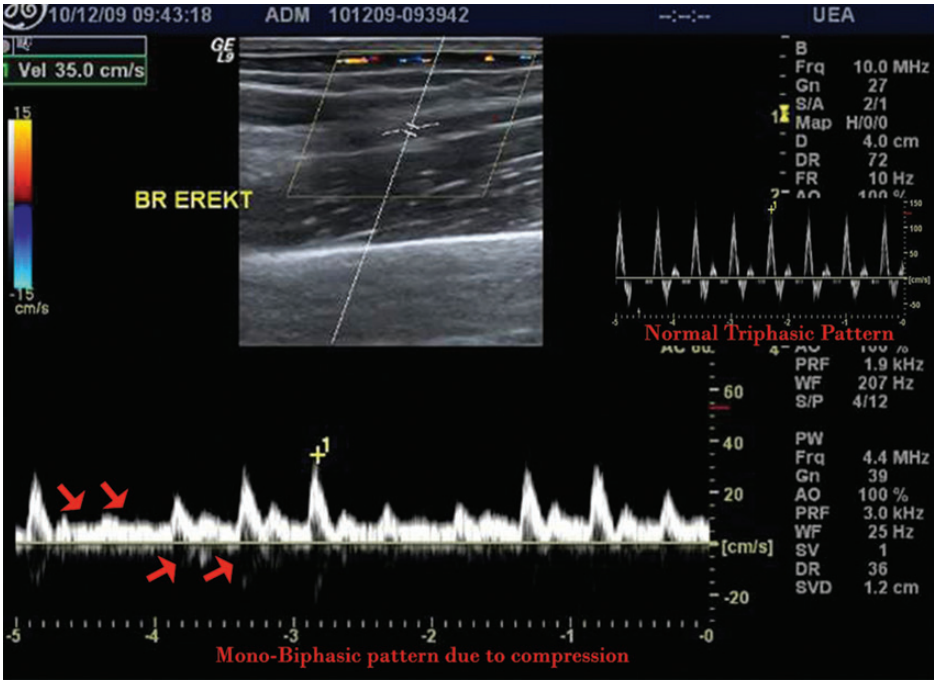

Figure 1: Colour Doppler ultrasound confirming the reduction of the blood flow in the compressed subclavian artery (mono-biphasic pattern) when the right hand of the patient was extended.

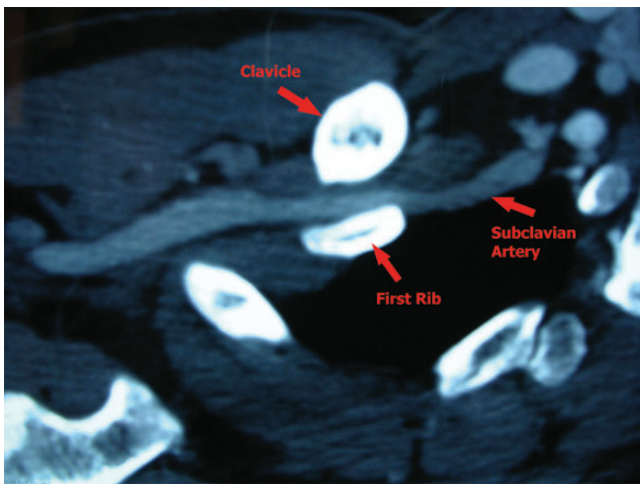

Figure 2: The computed tomography scan showing an important compression of the right subclavian artery between the right clavicle and first rib.

DISCUSSION

The minimally invasive repair of pectus excavatum has been accepted as a 'state-of-the-art' procedure for this deformity [2]. Hebra *et al*. reported that the most common complication was bar displacement or rotation requiring reoperation (9.2%), whereas pneumothorax requiring tube thoracostomy was reported in 4.8% of patients [3]. Less common problems included infectious complications (2%), pleural effusion (2%), thoracic outlet obstruction (0.8%), cardiac injury (0.4%), sternal erosion (0.4%), pericarditis (0.4%) and pseudoaneurysm of the anterior thoracic artery (0.4%) [3]. Rarely encountered complications include thoracic outlet syndrome, pericarditis and blood loss requiring transfusion.

We report herein a rare case of an early mechanical complication associated with the Nuss procedure. The complication consisted of an acute obstruction of the right subclavian artery caused by the placement of the Nuss bar. Removal of the first rib with adhesions immediately resolved the compression. Removal of the bar would also have provided relief from the pathology.

Thoracic outlet syndrome that developed after the Nuss procedure has been reported by Lee *et al* [4]. The patient showed clinical signs of brachial plexus compression on postoperative day 3. The authors reported that they initially failed to persuade their patient to accept removal of the bar, because their patient was dissatisfied with his previous distorted body. As treatment, the authors removed the bar after 2 months. However, they reported that the claw-hand deformity did not improve [4] even after bar removal. In most cases of thoracic outlet syndrome, compression is shown to occur within the interscalene triangle. We considered that the interscalene triangle, the borders of which are the anterior and middle scalene muscles and the first rib, was influenced by the mechanical forces created by insertion of the bar. Lee and colleagues depicted the possible mechanism of thoracic outlet syndrome created by bar insertion [4].

Perioperative mechanical compression of the vena cava has been reported in the literature to cause severe haemodynamic problems [5]. However, the bar itself was deemed to be responsible directly for the obstruction of the inferior vena cava.

In the Nuss procedure, the deformed costal cartilages and sternum are lifted by the pectus bar without any resection. The force needed to elevate the deformed costal cartilages and sternum is proportional to the depth of the chest wall deformity. When an unbearable complication develops following the Nuss procedure, the first possible resolution is to remove the bar. However, patients with severe chest wall deformities are usually reluctant to permit removal of the bar. For this reason, we

Downloaded from https://academic.oup.com/ejcts/article-abstract/44/3/567/635752 by guest on 05 March 2020

performed surgery for the thoracic outlet syndrome rather than removing the bar. Consequently, our patient remained satisfied, and the bar was removed after 3 years with an excellent cosmetic outcome. Fortunately, our patient had never any neurological compressive symptoms.

To our knowledge, vascular thoracic outlet syndrome due to the Nuss opereration has not previously been reported in the literature.

Increasingly, the minimally invasive repair of pectus excavatum has been used as the procedure of choice, because it has the advantages of a smaller scar and is less invasive than cartilage resection-based procedures. The surgeon should be aware of thoracic outlet syndrome as a possible complication of the Nuss procedure.

ACKNOWLEDGEMENT

We wish to thank Ezel Ersen for preparing the figures.

Conflict of interest: none declared.

REFERENCES

[1] Williams AM, Crabbe DC. Pectus deformities of the anterior chest wall. Paediatr Respir Rev 2003;4:237–42.
[2] Nuss D, Kelly RE Jr, Croitoru DP, Katz ME. A 10-year review of a minimally invasive technique for the correction of pectus excavatum. J Pediatr Surg 1998;33:545–52.
[3] Hebra A, Swoveland B, Egbert M, Tagge EP, Georgeson K, Othersen HB Jr *et al*. Outcome analysis of minimally invasive repair of pectus excavatum: review of 251 cases. J Pediatr Surg 2000;35:252–7; discussion 257–8.
[4] Lee SH, Ryu SM, Cho SJ. Thoracic outlet syndrome after the Nuss procedure for the correction of extreme pectus excavatum. Ann Thorac Surg 2011;91:1975–7.
[5] Ballouhey Q, Leobon B, Trinchero JF, Baunin C, Galnier P, Gauzy JS. Mechanical occlusion of the inferior vena cava: an early complication after repair of pectus excavatum using the Nusss procedure. J Pediatr Surg 2012;47:E1–3.

Downloaded from https://academic.oup.com/ejcts/article-abstract/44/3/567/635752 by guest