Uniportal pure robotic-assisted thoracic surgery—technical aspects, tips and tricks

Diego Gonzalez-Rivas[1,2#], Veronica Manolache[2,3#], Mugurel Liviu Bosinceanu[2], Javier Gallego-Poveda[4], Alejandro Garcia-Perez[1], Mercedes de la Torre[1], Akif Turna[5], Natalia Motas[2,3,6#]

[1]Department of Thoracic Surgery and Minimally Invasive Thoracic Surgery Unit (UCTMI), Coruña University Hospital, Coruña, Spain; [2]Department of Thoracic Surgery, Policlinico di Monza, Oncology Hospital Monza, Bucharest, Romania; [3]University of Medicine and Pharmacy "Carol Davila", Bucharest, Romania; [4]Department of Cardio-Thoracic Surgery, Lusiadas Hospital, Lisbon, Portugal; [5]Department of Thoracic Surgery, Cerrahpasa Medical School, Istanbul University-Cerrahpasa, Istanbul, Turkey; [6]Department of Thoracic Surgery, Institute of Oncology "Prof. Dr. Al. Trestioreanu", Bucharest, Romania

Contributions: (I) Conception and design: D Gonzalez-Rivas, N Motas, V Manolache; (II) Administrative support: V Manolache, ML Bosinceanu; (III) Provision of study materials or patients: D Gonzalez-Rivas, V Manolache, ML Bosinceanu, J Gallego-Poveda, A Garcia-Perez, M de la Torre, A Turna; (IV) Collection and assembly of data: N Motas, V Manolache, M de la Torre; (V) Data analysis and interpretation: D Gonzalez-Rivas, N Motas, V Manolache; (VI) Manuscript writing: All authors; (VII) Final approval of manuscript: All authors.

[#]These authors contributed equally to this work.

Correspondence to: Diego Gonzalez-Rivas. Department of Thoracic Surgery and Minimally Invasive Thoracic Surgery Unit (UCTMI), Coruña University Hospital, Coruña 15008, Spain. Email: Diego.Gonzalez.Rivas@sergas.es; Natalia Motas. Department of Thoracic Surgery, Institute of Oncology "Prof. Dr. Al. Trestioreanu", Bucharest 022328, Romania. Email: natalia.motas@gmail.com.

Abstract: The uniportal access for robotic thoracic surgery presents itself as a natural evolution of minimally invasive thoracic surgery (MITS). It was developed by surgeons who pioneered the uniportal video-assisted thoracic surgery (U-VATS) in all its aspects following the same principles of a single incision by using robotic technology. The robotic surgery was initially started as a hybrid procedure with the use of thoracoscopic staplers by the assistant. However, due to the evolution of robotic modern platforms, the staplers can be nowadays controlled by the main surgeon from the console. The pure uniportal robotic-assisted thoracic surgery (U-RATS) is defined as the robotic thoracic surgery performed through a single intercostal (ic) incision, without rib spreading, using the robotic camera, robotic dissecting instruments and robotic staplers. There are presented the advantages, difficulties, the general aspects and specific considerations for U-RATS. For safety reasons, the authors recommend the transition from multiportal-RATS through biportal-RATS to uniportal-RATS. The use of robotic dissection and staplers through a single incision and the rapid undocking with easy emergent conversion when needed (either to U-VATS or to thoracotomy) are safety advantages over multi-port RATS that cannot be overlooked, offering great comfort to the surgeon and quick and smooth recovery to the patient.

Keywords: Robotic-assisted thoracic surgery (RATS); uniportal RATS (U-RATS); single port RATS; robotic lobectomy; minimally invasive thoracic surgery (MITS)

Submitted Apr 09, 2022. Accepted for publication Jun 06, 2022.
doi: 10.21037/atm-22-1866
View this article at: https://dx.doi.org/10.21037/atm-22-1866

Introduction

Robotic-assisted thoracic surgery (RATS) proved advantageous by its three-dimensional view and excellent manoeuvrability, offering great comfort to the surgeon. The patients receive a quick and smooth recovery, usually within a program of enhanced recovery after surgery (ERAS). In cancer patients, the excellent lymph node dissection performed by RATS offers the best possible outcome for

© Annals of Translational Medicine. All rights reserved.

the patient and professional satisfaction for the surgeon.

Benefits of RATS approach are easy to understand: improved visualization; instruments with 7 degrees of freedom performing safely complex manoeuvres in vascular and nodal dissection (1,2); lymph node dissection (lymphadenectomy) easy to perform due to the wristed arms of the robotic instruments, use of bipolar energy and grasping instruments on both hands (3,4); regarding lymph node dissection, there are data showing the superiority of the robotic lymphadenectomy compared to video-assisted thoracic surgery (VATS) (4), and data presenting the similarity of lymphadenectomy between VATS and RATS (5); generally, RATS offers oncological results similar to open and VATS approach (6-13).

One disadvantage of RATS is the high cost (14), making RATS affordable usually in selected hospitals. The disadvantage of being an in-development approach turns into an advantage because it is improved by experienced thoracic surgeons in uniportal VATS (U-VATS) and RATS (4).

In exchange, VATS is much more affordable in costs and instruments and offers similar results as open surgery regarding lymph node dissection and general oncological results; compared to RATS, VATS has the disadvantages of rigid tools and limited visibility (6).

At this moment, there is no real debate on VATS versus RATS (15), and further, U-VATS versus newborn U-RATS (which is defined in the "Main body" section). Discussions should be more about different paths from open thoracic surgery to minimally invasive thoracic surgery (MITS) because no one keeps the ultimate truth. We should rely on evidence and experience.

Main body

U-RATS

We define the pure U-RATS as the robotic thoracic surgery performed by a single intercostal (ic) incision, without rib spreading, using the robotic camera, robotic dissecting instruments and robotic staplers.

The evolution of the uniportal approach is growing very fast with the help of the latest technology during the last decade. Since our group performed the first U-VATS lobectomy in the world in 2010 (16) we improved the technique for more and more complex cases thanks to the acquired experience, narrowed instruments, better HD cameras and powered more angulated staplers. In 2018 we developed the technique for lobectomy and thymectomy via the subxiphoid or subcostal approach by using the single port (SP®) robotic platform in the cadaveric model (17). In the meantime, waiting for the validation of this new robot for thoracic surgery, we decided to adapt the Davinci Xi® to develop the U-RATS approach to performing the first pure robotic cases in the world in September 2021 in Spain. Since then, we have performed more than 100 anatomic resections including all segmentectomies, sleeves, double sleeves and carinal resections.

In this article, we will define this new access through a single incision showing in detail the technical aspects of every procedure, with advantages and drawbacks at this time of development.

The main advantages of the U-RATS (*Figure 1A*,*1B*) are:

- The single ic incision—3–4 cm length, placed anterolaterally, used for working, specimen extraction and chest tube placement;
- Interchangeable grasping energy instruments in both hands with fine movements and excellent control;
- Use of the most modern technology of robotic intelligent staplers (not possible with the SP Xi®—the single existing dedicated system for single-port access);
- Quick emergent conversion in case of uncontrolled bleeding, undocking being rapid and conversion possible to U-VATS or thoracotomy;
- An in-developing technique performed, improved, and standardised by surgeons who pioneered and perfected the U-VATS approach;
- The willingness of the industry to develop and improve robotic accessories for uniportal thoracic robotic surgery.

Difficulties in performing U-RATS, until this moment of technical development, are:

- It is mandatory for the surgeon to be a U-VATS experienced surgeon, and is recommended to have experience in the robot. For that, we recommend the transition from multiportal-RATS to U-RATS doing a few cases with biportal-RATS (two-ports RATS) before starting U-RATS.

For two-ports RATS we recommend performing the utility incision in the 5th ic space and additional incision in the 7th ic space. The camera must be placed in the upper part of the incision as in U-VATS and work is performed with triangulation of the instruments placed in the lower part of the incision

© Annals of Translational Medicine. All rights reserved.

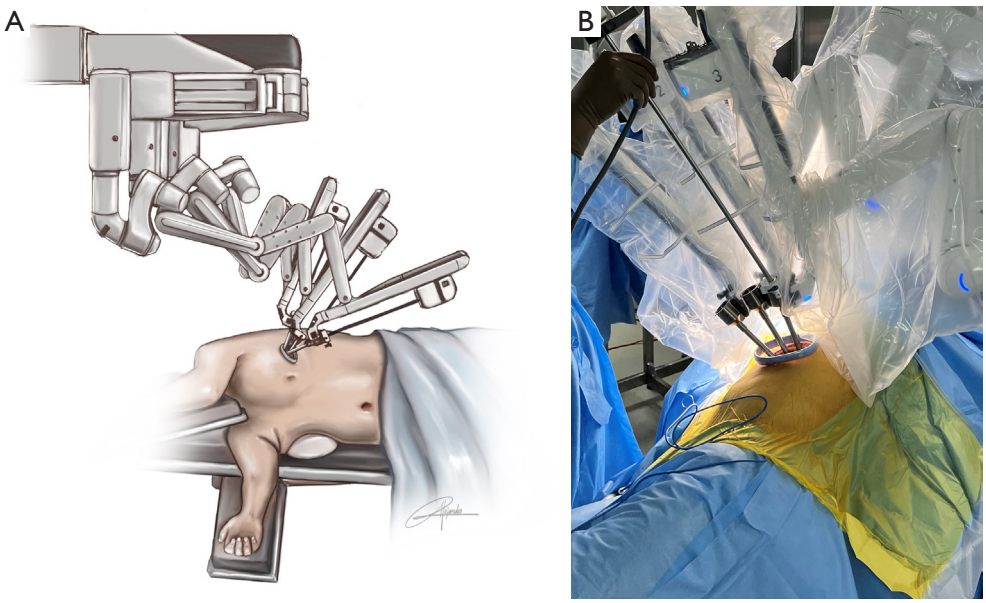

Figure 1 Set up and port placement of Davinci Xi® through a single incision—schematic drawing (A) and intraoperatory aspect (B).

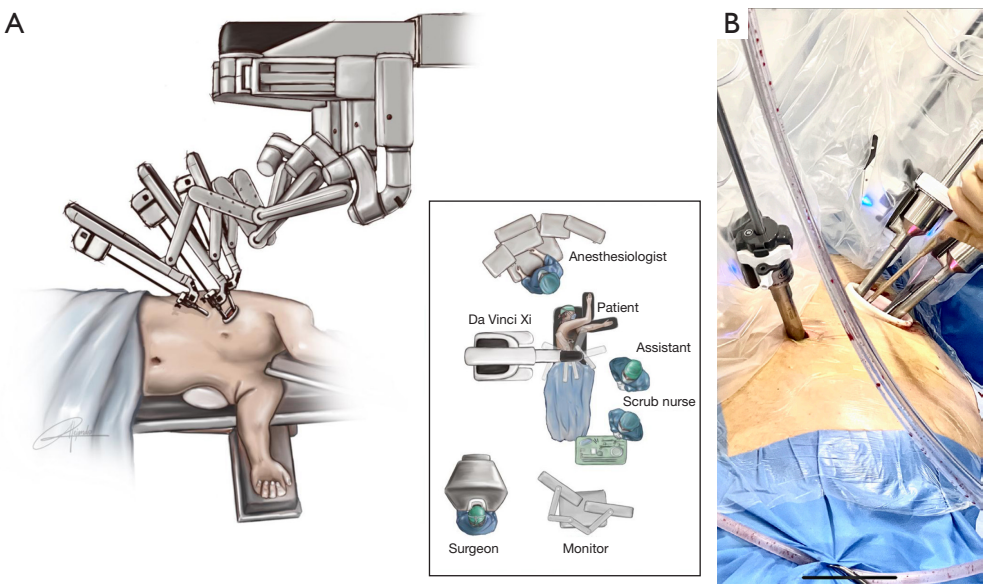

Figure 2 Set up and port placement of Davinci Xi® by using 2 ports—schematic drawing of the robotic arms and room setting (A) and intraoperatory aspect (B).

and in the accessory port. We advise the surgeon to be confident with this biportal robotic approach before moving to U-RATS (*Figure 2A*,*2B*):

- ❖ U-RATS is not easy to learn as a technique, implying technical details and equipment, so at this moment it is not accessible to every surgeon;
- ❖ The intraoperatory movements (instrumentation) in U-RATS are different compared to multiportal-RATS—in order to avoid collision of instruments;
- ❖ The help of the assistant is difficult to offer and highly demanding, so the assistant surgeon must be skilled and well informed, familiarised with

© Annals of Translational Medicine. All rights reserved.

uniportal access technique;

- If the incision is too high or too low for the lobectomy to be performed, it becomes difficult to place the robotic staplers;
- While learning curve, U-RATS is a time-consuming procedure from the technical point of view—in order to optimise the space, 8 mm trocars are used through the single incision while dissecting; for stapling, the anterior 8 mm trocar must be changed with a 12 mm trocar, fitting the stapler.

Yang and colleagues described in 2021 a single incision for performing a right upper lobectomy using Da Vinci Robotic Surgery System Xi® completed by instruments designed for VATS approach (dissector, grasper, suction, staplers), as a hybrid U-RATS-VATS (18).

Developing and improving aspects of U-RATS are:

- Related to surgical technique, to identify and perfect new movements specific for uniportal robotic but different from U-VATS;
- Robotic adaptations to an appropriate thoracic single port for vascular resection—either allowing the use of specifically designed staplers for U-RATS or eliminating the need for staplers by developing the vascular sealing devices for larger pulmonary vessels.

For MITS surgeons experienced in tri-portal VATS, it is a natural way to perform RATS; but for many thoracic surgeons who are confident using U-VATS, an implied path towards robotic surgery could be using the robotic arms on a unique incision—U-RATS.

General technical aspects in U-RATS

- Main differences compared to U-VATS are presented in *Table 1*;
- Three robotic arms: the most posterior arm is used for the camera and the middle and anterior ones for working—as U-VATS configuration;
- Trocar placement parallel above the surgical wound and cross instrumentation inside the pleural cavity (*Video 1*);
- A basic robotic tool kit must contain: monopolar, bipolar, cold grasper and cautery spatula; we are mostly using Maryland Bipolar Forceps, Cadiere Forceps, Tip-Up Fenestrated Grasper and Monopolar Spatula; handling the instruments is the same as in multiportal RATS;
- Long curved suction and long grasper (subxiphoidian type)—for assistant;
- No need for CO_2 insufflation or air seal, and no need for ports for each trocar, except for the camera one (used for camera protection), thus allowing more space for the trocars and avoiding clutching;
- Lobe retraction for adequate exposure—preferably using an arm instrument to avoid collision with the grasper or with the suction (*Video 2*);
- Remember to correctly apply the stapler on the bronchus and close the membranous part against the cartilaginous part, for as less tension closure as possible and to minimising the risk of complications;
- After chest tube placement, correct closure of the single access is mandatory, avoiding free spaces between layers and around the chest drain—this prevents wound complications and facilitates ERAS;
- Do not forget to have prepared in the operating room the instruments for VATS and for open thoracic surgery.

Specific considerations

- Recommended arm placement:
  - On the right (*Figure 3A*):
    - Use arms No. 2, 3 and 4; cancel arm No. 1
    - Arm No. 2: camera
    - Arm No. 3: left hand
    - Arm No. 4: right hand
  - On the left (*Figure 3B*; *Video 1*):
    - Use arms No. 1, 2 and 3; cancel arm No. 4
    - Arm No. 3: camera
    - Arm No. 1: left hand
    - Arm No. 2: right hand
- All 3 arms joints parallel at the top and centred in FLEX position;
- All 3 arms rotated towards the anterior;
- Targeting—place the laser in the upper part of the skin incision, at the posterior location (*Figure 4*);
- If the incision is too high and difficulties in stapler angulation are encountered, simply retract the trocar (as much as necessary) and gain more space inside the thorax;
- In U-RATS we use the U-VATS configuration of instruments—but in some specific parts (for anatomical and exposure reasons) we may need to change the configuration, with the camera in the centre and arms on lateral sides, as it may happen in sleeve suturing;

© Annals of Translational Medicine. All rights reserved.

Table 1 Technical differences between U-VATS and U-RATS

Issue addressed	U-VATS	U-RATS
Incision	4–5th ic space, between anterior and mid-axillary lines	6–7th ic space, between anterior and mid-axillary lines
Wound protector	Useful	Very useful
	When missing, cleaning the camera is repeatedly needed	When missing, cleaning the camera is repeatedly needed
	Although annoying, cleaning the camera is an easy process	Removing the camera from the trocar for cleaning and repositioning is time-consuming
Camera	30°	30°
Instruments	VATS type	3 robotic arms
	Camera	Camera
	Grasper	Holding
	Dissection	Working/stapler
	Stapler	2 VATS instruments: long curved suction and long curved grasper (subxiphoid length)
	Suction	
Access into the thorax (e.g., strong adhesions)	Difficult for anterior part or chest wall next to the wound protector	Difficult for chest wall next to the wound protector
Tilt the table	Recommended if needed for better exposure	Not recommended
Lymph node stations (mediastinal)	All stations accessible	All stations accessible
	Difficulties for subcarinal (station 7), especially for left U-VATS	Excellent manoeuvrability
		Fewer difficulties
Bleeding control	When needed, conversion to open is rapid and easy to perform	When not controlled by U-RATS, undocking is rapid and the conversion is easy to perform:
	Standardised by practice and international expert consensus [2019 (19)]	To U-VATS
		To thoracotomy
Anaesthesia with single-lung ventilation	Strongly recommended	To date, general anaesthesia with single-lung ventilation is mandatory
	Intermittent ventilation may be used	
	Non-intubated technique may be used in selected cases	
Assistant help	± skill demanding	Skill demanding, must follow the surgeon's movements
	Holding the camera	Most difficult: use of VATS instruments between moving robotic arms
	Exposure	

U-VATS, uniportal video-assisted thoracic surgery; U-RATS, uniportal robotic-assisted thoracic surgery; ic, intercostal.

- ❖ In addition, it could be necessary for some parts of the procedure (e.g., adhesions) to switch the angulation of the camera, to 30° up;
- ❖ In case of conversion, having the arms into the same incision makes undocking rapid. The conversion to U-VATS or to open surgery is chosen by surgeons according to their own competence, surgical comfort, and case particularities. We make these recommendations:
  - ◆ For U-RATS performed through 5–6th ic space the access is through the same incision (for U-VATS) or enlarging the uniport for open;
  - ◆ For U-RATS performed through 7–8th ic space, if needed to convert to open, we recommend doing a classic anterior thoracotomy in the 4–5th ic space.

© Annals of Translational Medicine. All rights reserved.



Video 1 Port placement and docking on the left side.



Video 2 Set up of robotic arms and coordination with the assistant during the U-RATS procedure. U-RATS, uniportal robotic-assisted thoracic surgery.

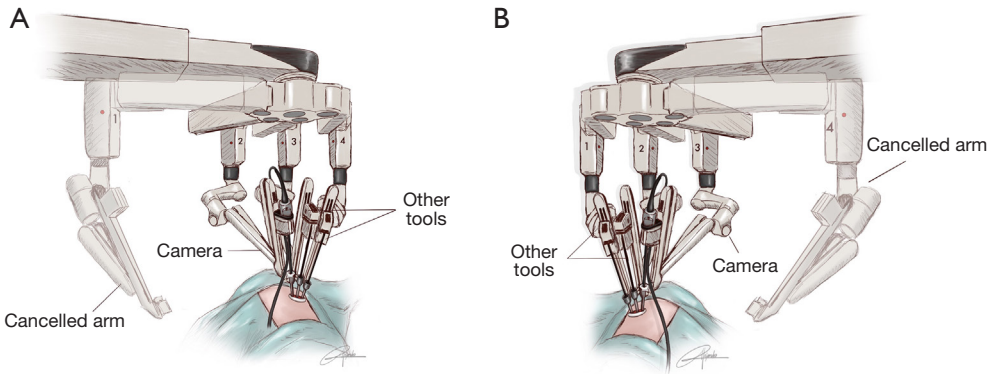

Figure 3 Drawing showing arm placement on the right side (A) and on the left side (B).

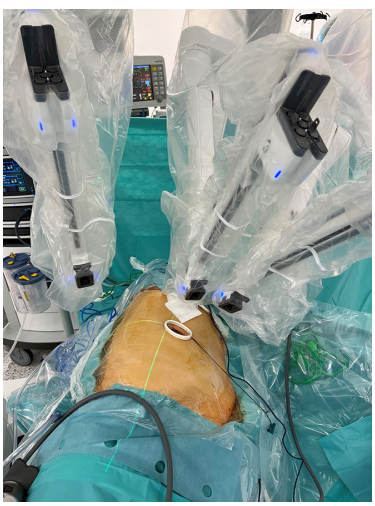

Figure 4 Laser location for targeting.

Operative technique: basic concepts for lobectomies and lymph node dissection

Right upper lobectomy (20,21) (Video 3)

The incision is placed in the 6–7th ic space, between anterior and middle axillary lines. After the initial evaluation, the dissection is performed and the hilum-first approach is recommended, from anterior to posterior, with artery-vein-bronchus steps or vein-artery-bronchus, depending on anatomy particularities and surgeon's preference. In U-RATS, vein first (*Figure 5*) and then artery (anterior trunk) (*Figure 6*) seems more natural because the angle for stapling the vein is not as difficult as in U-VATS. A vessel loop may be very helpful. Artery-bronchus-vein seems more improbable in U-RATS than in U-VATS because of the inferior and anterior approach.

© Annals of Translational Medicine. All rights reserved.

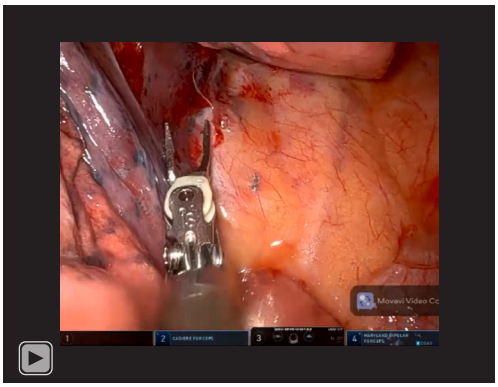

Video 3 U-RATS right upper lobectomy. U-RATS, uniportal robotic-assisted thoracic surgery.

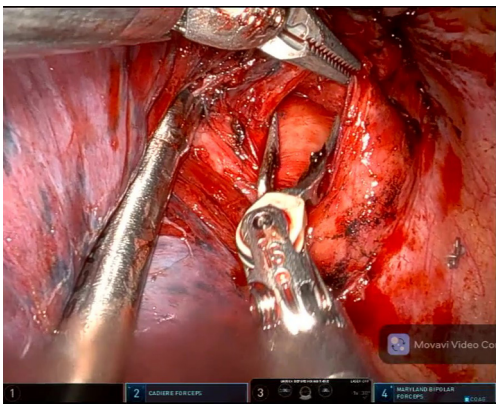

Figure 5 Dissection of RUL vein during upper lobectomy. RUL, right upper lobe.

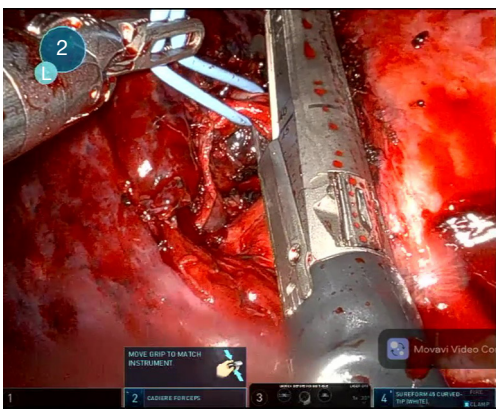

Figure 6 Division of truncus anterior with robotic staplers during upper lobectomy.

During dissection, grasping and mobilising the upper lobe is much easier handled with the robotic fenestrated bipolar grasper than a VATS grasper, in order to avoid collision between arms; this is especially true when performing the rotation trick for stapling the vessels (20,21).

The suction trick from the U-VATS (20,21) may be difficult to perform when stapling the bronchus, so attention must be towards identifying A2, the posterior ascending artery—if A2 artery is the main reason for conversion in U-VATS, let us not make the same mistake in U-RATS.

For identification of the right upper lobe (RUL) bronchus is helpful to dissect the lymph node (station 11s, interlobar superior) that is always present at the base of the RUL bronchus, between it and bronchus intermedius. Dissecting the posterior aspect of the bronchus is less difficult than in U-VATS. We advise checking the remnant lung inflation before firing the bronchial stapler.

For fissure stapling, remember to dissect and identify the middle lobe artery and to free the upper lobe vein venous stump—the stapler will be between them. The fissure less or fissure-last technique became the usual approach in U-VATS right upper lobectomy.

Of course, anatomical structures must be correctly identified—arterial anterior trunk and the rest of the pulmonary artery, veins for upper lobe and middle lobe, even the vein for lower lobe, and also the anatomical variations must be identified. Bronchial variations and anomalies must be known from the preoperatory bronchoscopy.

Lymph nodes from hilar and intrapulmonary stations are removed during dissection, as usual (*Figure 7*).

For malignancy, suspected or proved, systematic mediastinal lymph node dissection is to be performed. For stations paratracheal, superior 2R and inferior 4R, and prevascular 3a, the technique is similar to U-VATS, but the use of energy grasping instruments in both hands makes the robotic lymphadenectomy a very delicate, satisfying and efficient manoeuvre (*Figure 8*). For subcarinal station 7 dissection (*Figure 9*), swapping configuration left-right may be useful; as far as now, we concluded that the lung is better retracted with suction by the assistant, leaving both instruments of the first surgeon to advance the dissection.

Right lower lobectomy (20,21)

The incision is placed in the 6–7th ic space, between

© Annals of Translational Medicine. All rights reserved.

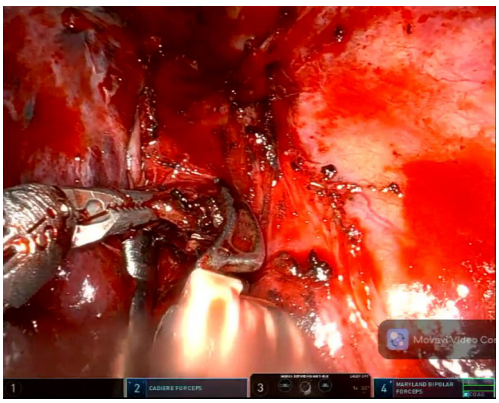

Figure 7 Hilar lymph node dissection.

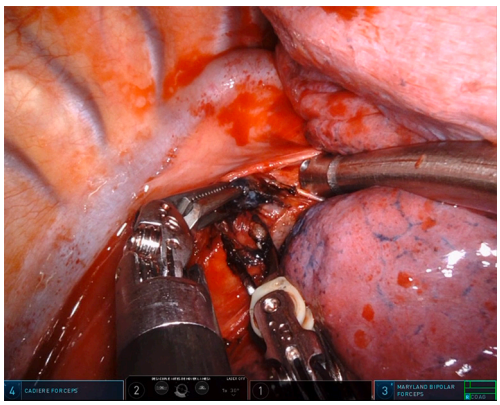

Figure 9 Right subcarinal lymph node dissection.

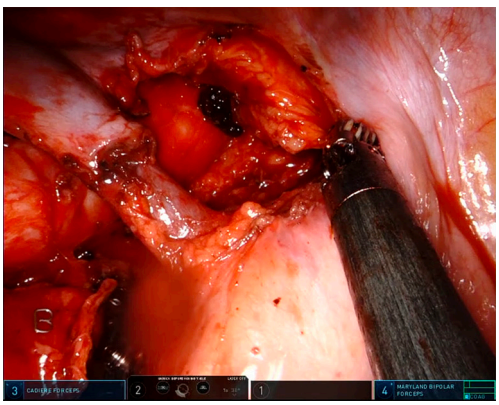

Figure 8 Surgical image of paratracheal space after a radical paratracheal lymph node dissection.

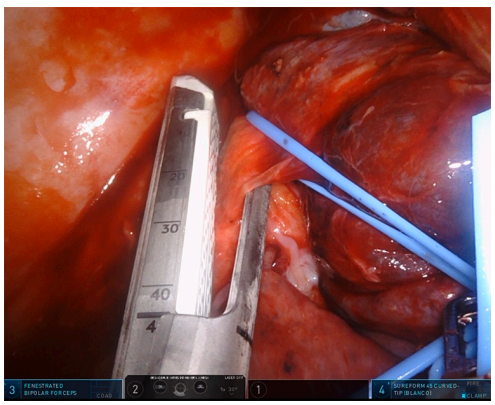

Figure 10 Stapler insertion for inferior vein during right lower lobectomy.

anterior and middle axillary lines. Most of us start from the inferior—so the first step is the section of the pulmonary ligament with the excision of the lymph nodes from station 9 (pulmonary ligament) and 8 (paraesophageal) and dissection of the inferior vein and the middle lobe vein. Rarely, a single right pulmonary vein can be extrapericardial identified—in this case, dissection must be correctly performed in order to preserve the venous supply from the middle and upper lobes. Posterior dissection of the mediastinal pleura is necessary for further exposure of the vein and bronchus. When stapling the vein, the impact against the spine is somehow smaller than in U-VATS because of the lower access and more oblique direction of working, towards the cranial (*Figure 10*).

For right lower lobectomy is essential to identify and preserve the arterial and bronchial structures of the middle lobe, otherwise, an inferior bilobectomy will result.

After the vein, we can continue completing the fissure between the middle and lower lobe, then dissecting the pulmonary artery. For completing the fissure, an important landmark is the lymph node station 11i (interlobar inferior)—it is always present at the top of the fissure, marking the bifurcation between the middle lobe artery and basal trunk.

The basal and A6 arterial branches can be divided together or separately, minding the anatomical variations and protecting the middle lobe artery (this can emerge, sometimes, lower than the A6). After the artery, the posterior part of the fissure is divided (*Figure 11*) and then the bronchus is dissected and stapled. As usual, dissection of the lymph nodes is mandatory for accuracy of anatomical identification and for oncological reasons (intrapulmonary stations 11, 12, 13). The stapling line must be as oblique as necessary to preserve the middle lobe bronchial lumen—the disposition

© Annals of Translational Medicine. All rights reserved.

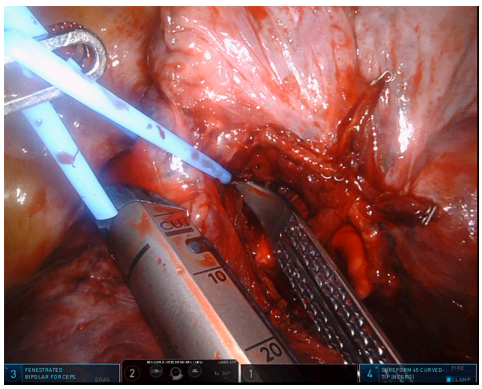

Figure 11 Stapling the posterior part of the oblique fissure during right lower lobectomy.

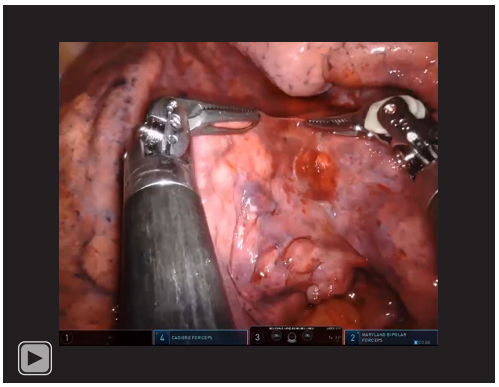

Video 4 U-RATS middle lobectomy. U-RATS, uniportal robotic-assisted thoracic surgery.

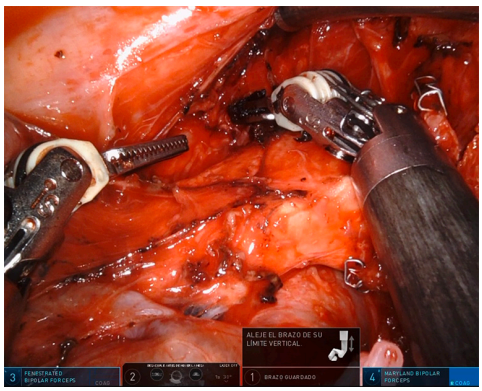

Figure 12 Subcarinal lymph node dissection during right lower lobectomy.

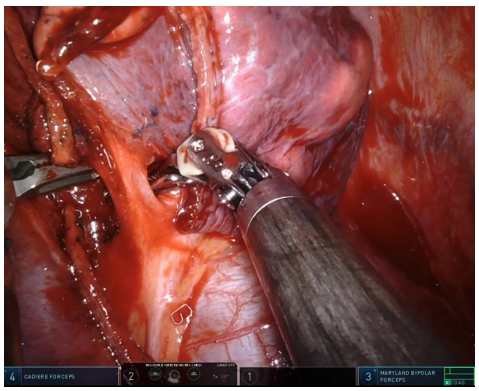

Figure 13 Dissection of vein during middle lobectomy.

of the middle lobe and apical inferior B6 bronchi are to be known from preoperatory bronchoscopy. Always verify the inflation of the middle lobe before firing the stapler. Again, the impact of the stapler against the spine can be minimised by retracting the lower lobe laterally and cranially.

After the vein, we can proceed to the bronchus, artery and fissure—the fissure-last technique. This may be done if the fissure is incomplete or as the surgeon's preference.

If the fissure is complete, the lower lobectomy can be performed as in open, beginning with an artery approach in the fissure.

For malignancy, lymph node dissection is completed with station 10 (hilar) and superior mediastinal stations (*Figure 12*).

Middle lobectomy (20,21) (Video 4)

The incision is placed in the 6–7th ic space, between anterior and middle axillary lines, more anterior than for the other right lobectomies. After intrathoracic evaluation, the exposure is obtained by retracting the middle lobe laterally and posteriorly, in order to dissect the hilum from the anterior. Usually, the oblique fissure is present (at least partially) and the horizontal fissure is absent.

U-RATS offers a more oblique approach than U-VATS for middle lobectomy, and the hilum is not anymore so close to the port. That is why, after correct identification of the middle lobe vein (*Figure 13*), this is stapled more easily that in U-VATS. More space is obtained for the stapler if the oblique fissure is completed between middle and lower lobes.

Then the middle lobe bronchus is identified (*Figure 14*) and carefully dissected not to injure the artery behind, and stapled. Now the traction must be gentle not to avulse the arteries from the main pulmonary artery. The middle

© Annals of Translational Medicine. All rights reserved.

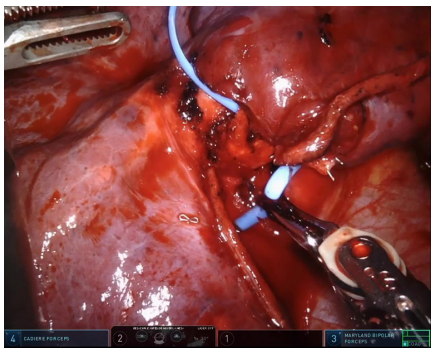

Figure 14 Dissection of bronchus during middle lobectomy.

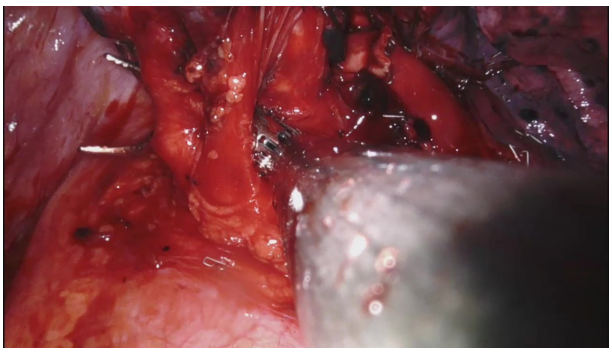

Figure 16 Dissection of apico-anterior trunk during left upper lobectomy.



Figure 15 Division of middle lobe artery with robotic staplers.

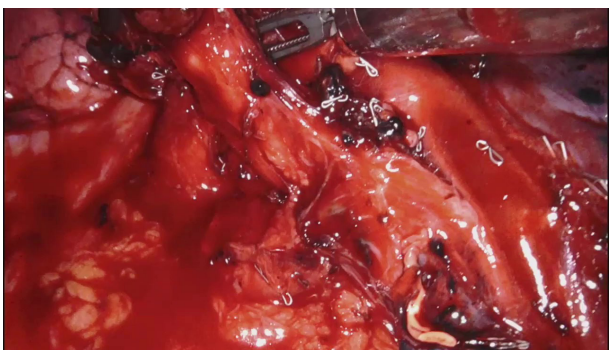

Figure 17 Dissection of left upper lobe bronchus.

lobe may have 1, 2 or 3 arteries—they must be recognised and divided with staplers (*Figure 15*) or vascular clips (2 clips proximally and an energy device distally). Fissure-last is performed, leaving the distal stumps on the detached middle lobe.

During dissection, intrapulmonary lymph nodes are excised.

For malignancy, lymph node dissection is performed in hilar and mediastinal stations.

Left upper lobectomy (20,21)

The incision is placed in the 6–7th ic space, between anterior and middle axillary lines. The technique is similar to that on the right side. It is important to evidence both veins in order to avoid stapling the possible single left pulmonary vein, which imposes the left pneumonectomy.

First time the hilar dissection must evidence the superior vein and the first 2–3 arterial branches; the dissection anterior, superior and posterior the hilum is concomitant with the lymph node dissection from stations 10, 5 and 6. Stapling of the vein is performed using the rotation trick and the suction trick (20,21) or using a loop, then are stapled the first 2—anterior and apical—(sometimes 3) arterial branches (*Figure 16*), and sometimes a single stapler can be used. If the vein is difficult to approach, arterial branches can be resected first, then the vein.

Dissection of the bronchus must be carefully done because on its posterior part lies the pulmonary artery. The U-RATS offers a more inferior view and somehow facilitates the dissection at this moment if the exposure is correctly done (*Figure 17*).

If the fissure is present, it can be opened anterior for approaching the lingular artery(-ies) and identifying the rest of the arteries for the upper lobe (for the left upper lobe could be between 2 and 7 branches). The stapler on the bronchus is inserted while protecting the interlobar pulmonary artery and is not fired before checking the inflation of the lower lobe.

If the fissure is absent, the bronchus is followed by the

© Annals of Translational Medicine. All rights reserved.

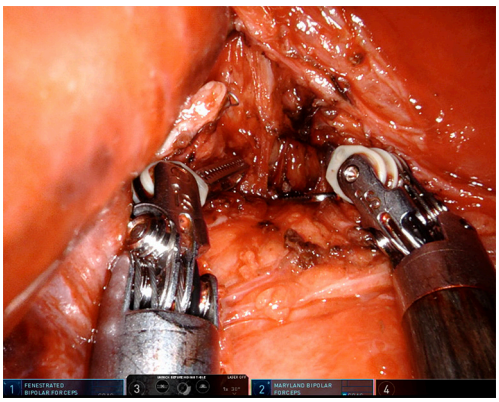

Figure 18 Left subcarinal lymph node dissection.

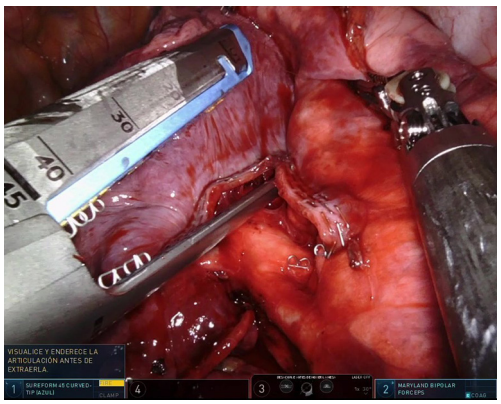

Figure 19 Stapler insertion for division of fissure during left lower lobectomy.

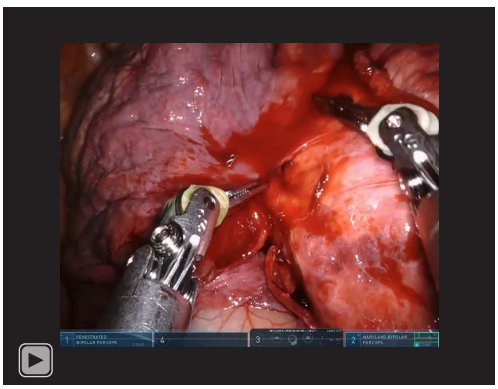

Video 5 U-RATS left lower lobectomy. U-RATS, uniportal robotic-assisted thoracic surgery.

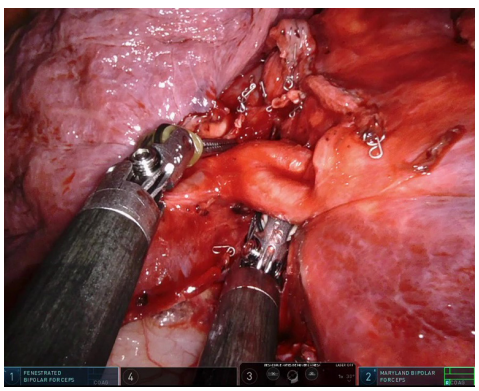

Figure 20 Dissection of basal artery during lower lobectomy.

rest of the arteries and the traction applied to the upper lobe must be gentle not to avulse the branches from the pulmonary artery. In the end, the fissure is completed in the known manner.

If necessary, lymph node dissection in the subcarinal station 7 is performed, and also stations 9 and 8, from a posterior approach, as in U-VATS (*Figure 18*).

Left lower lobectomy (20,21) (Video 5)

The incision is placed in the 6–7th ic space, more lateral than on the right side because of the heart position in front of the single access.

If the fissure is present, we follow the steps as on the right side: retraction of the lobe cranially and dissection of the pulmonary ligament, taking the corresponding lymph nodes; approaching the inferior vein (after excluding a single left pulmonary vein); then open the anterior fissure; dissection and division of the arteries (A6 and basal trunk) after identification of the lingular artery(-ies); completion of the fissure in posterior; exposure of the lobe laterally and posteriorly with dissection and division of the bronchus, after inflation test, protecting the pulmonary artery that runs behind and cranial to bronchus.

An alternative is to start with fissure completion (*Figure 19*) and artery(-ies) approach (*Figure 20*), then vein (*Figure 21*) and bronchus last.

If the fissure is absent or if desired by the surgeon, the fissure-last approach (bottom-to-top) is performed: the pulmonary ligament and the inferior vein, then the bronchus, artery and last the fissure.

During vascular and bronchial dissection, the intrapulmonary

© Annals of Translational Medicine. All rights reserved.

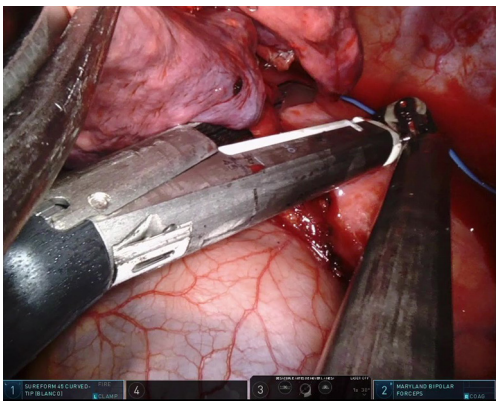

Figure 21 Division of inferior vein with robotic stapler.

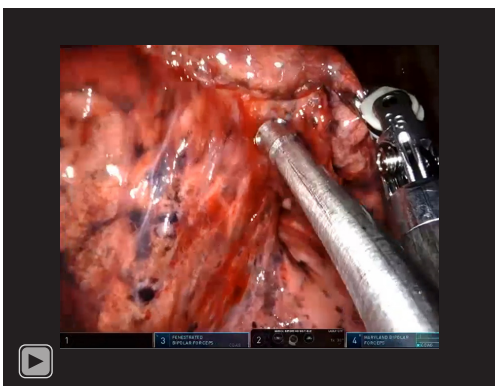

Video 6 U-RATS right lower sleeve lobectomy. U-RATS, uniportal robotic-assisted thoracic surgery.

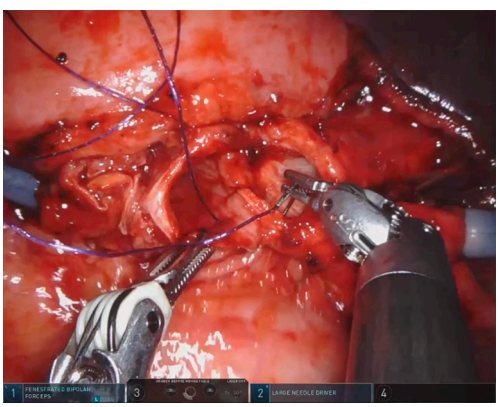

Figure 22 Bronchial anastomosis during left upper double sleeve lobectomy.

lymph nodes are excised, as usual. For malignancies, hilar (station 10), subcarinal (station 7), and mediastinal superior stations (subaortic 5 and paraaortic 6) are dissected.

Sleeve resections (Video 6)

Although technically more demanding, sleeve resections can be performed through a single incision by using the DaVinci Xi® platform thanks to advancements in imaging systems, instrument design and experience in minimally invasive surgery accumulated during the past two decades. Due to certain tumor characteristics, such as size and central location, sleeve resections pose more challenges than conventional resections. At the same time, the technical complexity increases when the operation is conducted via a single 3–4 cm incision (22-24).

For the sleeve resections in U-RATS we recommend placing the incision at the level of the 5th ic space (normally in U-VATS is placed at the 4th ic space). The best port placement for the right side is the camera on the 2nd arm, Maryland on the left hand (3rd arm) and needle holder on the right hand (4th arm). On the left side, we recommend the camera on the 3rd arm, Maryland on the left arm (2nd) and needle holder on the right hand (1st arm). For the anastomosis, the best strategy is to use a barbed suture, and we recommend performing a running suture, one thread of 35 cm with 2 needles, 17 mm size every needle (*Figure 22*).

The other option is to perform the anastomosis in 2 parts, using 2 barbed sutures, one for the posterior wall and another for the anterior wall. First, the posterior wall of the anastomosis is performed and then the anterior wall with another threat. Both are tied at the most anterior portion. We consider this type of suture more reliable and safer in RATS because we don't loose the tension while doing the anastomosis (the maintenance of the tension by the assistant during the procedure could be very difficult).

For vascular anastomosis, the technique is also completely different compared with U-VATS where we use to keep the threads with tension out of the incision (synthetic, monofilament, nonabsorbable polypropylene suture 5/0 double-needle, 70 cm length is preferred). Due to the interference with robotic arms, the thread must be short, and anastomosis should be performed in two rows as we do with the bronchus. For this anastomosis, we

© Annals of Translational Medicine. All rights reserved.

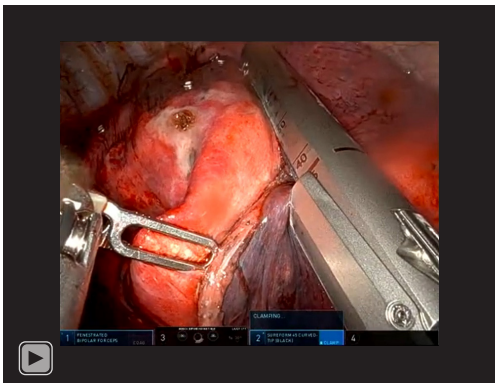

Video 7 U-RATS left anatomic segmentectomy S8. U-RATS, uniportal robotic-assisted thoracic surgery.

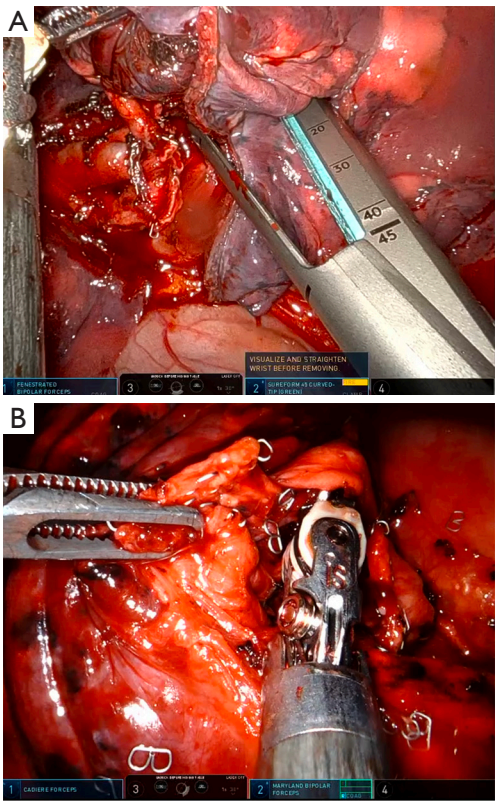

Figure 23 Segmentectomy steps facilitated by robotic tools. (A) Placement of stapler for intersegmental division after anatomic segmentectomy S8. (B) Dissection of A9 during anatomic segmentectomy S9-10.

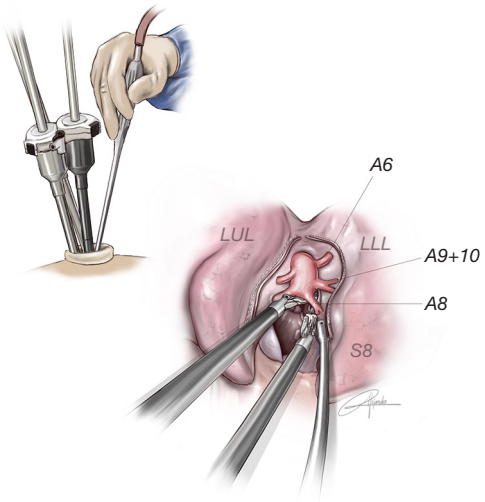

Figure 24 Drawing showing the help of the assistant with the long-curved suction during anatomic segmentectomy. LUL, left upper lobe; LLL, left lower lobe.

recommend using a special fine diamond needle holder and extra care must be taken with the tension of the thread in order to avoid rupture during the anastomosis.

Anatomic segmentectomies (Video 7)

The U-RATS technique is very suitable for anatomic segmental resections, especially for the segments located more posteriorly where the robot provides more manoeuvrability and a deeper 3D view compared with U-VATS (*Figure 23A*,*23B*). We have not seen any limitation to perform segments in upper or lower lobes by using the U-RATS technique.

The incision for U-RATS segmentectomies follows the same ic space as for the corresponding lobectomies.

The characteristics of some of the sharper instruments used with the robot, such as the Maryland or the bipolar fenestrated facilitate the dissection in the distal anatomy of segments and subsegments and also the removal of deeper intrapulmonary lymph nodes. The coordination and help of the assistant with the use of long curved suction are

© Annals of Translational Medicine. All rights reserved.

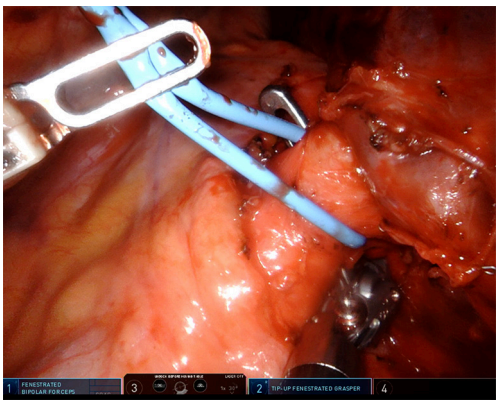

Figure 25 Dissection of main pulmonary artery with the use of a long curved "Tip-up" instrument.

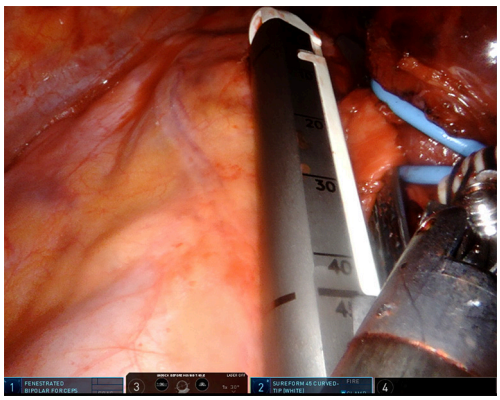

Figure 26 Division of left main pulmonary artery with the robotic stapler.

mandatory for better exposure (*Figure 24*).

In addition, the greatest angulation of the robotic staplers with the improved control by the surgeon and the 90-degree angulation for the applicator of polymer ligating clips makes the U-RATS a very good technique to perform anatomic segmentectomies in expert hands. The robot also offers the possibility of using indocyanine green, improving the visualization of the intersegmental plane.

Despite all these advantages provided by the robot, the perfect knowledge of anatomy is mandatory for a successful anatomic resection (21,25,26).

Pneumonectomy

Parenchymal sparing procedures are always preferred when operating on a patient with a centrally located cancer (21) but in some cases, the tumor involves both lobes making a pneumonectomy necessary in order to accomplish a curative procedure. The robotic platform with the precise instruments and the deeper 3D view is a very good tool when pneumonectomy is needed allowing a very good dissection around the main pulmonary artery and main bronchus.

The incision is placed not upper than the 6th ic space, in order to be able to angulate the stapler for the main bronchus.

We recommend the use of a tool called "Tip up" (*Figure 25*), for dissection of the main pulmonary artery and also for dissection and retraction of the main bronchus, especially on the left side in order to achieve a short stump after division with staplers. Due to the lack of tactile feedback, we must be very careful with the dissection of the main pulmonary artery in order to avoid catastrophic complications. We must double-check and be sure we have good manoeuvrability with the robotic stapler once is inserted into the chest cavity before placement into the main pulmonary artery (*Figure 26*).

Conclusions

At present time, we can conclude that U-RATS presents advantages that cannot be overlooked, but, on the contrary, developed for the benefit of our patients:

U-RATS offers the incredible advantage of robotic staplers through the single anterior incision, so the potential rough, jerky movement of the VATS staplers (in inexperienced hands) placed on vessels is avoided, and the risk of vascular avulsion is minimised.

A cost-efficiency approach for some patients with limited indications is to start with U-VATS and explore the resectability, and switch to U-RATS for the lung resection and lymph node dissection, for full benefit of robotic advantages.

One of the most important advantages of U-RATS is a quick emergent conversion in case of uncontrolled bleeding, undocking being rapid; the access into the thorax can be done either by U-VATS or by thoracotomy, depending on the situation and the preference of the surgeon.

The main disadvantage of U-RATS is its high cost. The lack of experience in uniportal access into the thorax is the main limitation in performing the U-RATS.

We must accept the fact that a new surgical approach may grossly depend on the industry to fully develop and cover a large field of thoracic surgery pathology, and the industry and experienced surgeons must keep a close collaboration in order to achieve the best for our patients.

© Annals of Translational Medicine. All rights reserved.

Acknowledgments

Funding: None.

Footnote

Provenance and Peer Review: This article was commissioned by the Guest Editor (Calvin S. H. Ng) for the series "Lung Cancer Management—The Next Decade" published in *Annals of Translational Medicine*. The article has undergone external peer review.

Peer Review File: Available at https://atm.amegroups.com/article/view/10.21037/atm-22-1866/prf

Conflicts of Interest: All authors have completed the ICMJE uniform disclosure form (available at https://atm.amegroups.com/article/view/10.21037/atm-22-1866/coif). The series "Lung Cancer Management—The Next Decade" was commissioned by the editorial office without any funding or sponsorship. The authors have no other conflicts of interest to declare.

Ethical Statement: The authors are accountable for all aspects of the work in ensuring that questions related to the accuracy or integrity of any part of the work are appropriately investigated and resolved.

Open Access Statement: This is an Open Access article distributed in accordance with the Creative Commons Attribution-NonCommercial-NoDerivs 4.0 International License (CC BY-NC-ND 4.0), which permits the non-commercial replication and distribution of the article with the strict proviso that no changes or edits are made and the original work is properly cited (including links to both the formal publication through the relevant DOI and the license). See: https://creativecommons.org/licenses/by-nc-nd/4.0/.

References

1. Yang S, Guo W, Chen X, et al. Early outcomes of robotic versus uniportal video-assisted thoracic surgery for lung cancer: a propensity score-matched study. Eur J Cardiothorac Surg 2018;53:348-52.
2. Oh DS, Reddy RM, Gorrepati ML, et al. Robotic-Assisted, Video-Assisted Thoracoscopic and Open Lobectomy: Propensity-Matched Analysis of Recent Premier Data. Ann Thorac Surg 2017;104:1733-40.
3. Demos DS, Tisol WB. Robotic thoracic lymph node dissection for lung cancer. Video-assist Thorac Surg 2020;5:17.
4. Ricciardi S, Davini F, Zirafa CC, et al. From "open" to robotic assisted thoracic surgery: why RATS and not VATS? J Vis Surg 2018;4:107.
5. Toker A, Özyurtkan MO, Demirhan Ö, et al. Lymph Node Dissection in Surgery for Lung Cancer: Comparison of Open vs. Video-Assisted vs. Robotic-Assisted Approaches. Ann Thorac Cardiovasc Surg 2016;22:284-90.
6. Gokce A, Sezen CB. Superior Technology of Lung Cancer Surgery: Robotic Surgery. Clin Surg 2020;5:2945.
7. Cerfolio RJ, Ghanim AF, Dylewski M, et al. The long-term survival of robotic lobectomy for non-small cell lung cancer: A multi-institutional study. J Thorac Cardiovasc Surg 2018;155:778-86.
8. Liang H, Liang W, Zhao L, et al. Robotic Versus Video-assisted Lobectomy/Segmentectomy for Lung Cancer: A Meta-analysis. Ann Surg 2018;268:254-9.
9. Lee BE, Shapiro M, Rutledge JR, et al. Nodal Upstaging in Robotic and Video Assisted Thoracic Surgery Lobectomy for Clinical N0 Lung Cancer. Ann Thorac Surg 2015;100:229-33; discussion 233-4.
10. Casiraghi M, Galetta D, Borri A, et al. Ten Years' Experience in Robotic-Assisted Thoracic Surgery for Early Stage Lung Cancer. Thorac Cardiovasc Surg 2019;67:564-72.
11. Yang HX, Woo KM, Sima CS, et al. Long-term Survival Based on the Surgical Approach to Lobectomy For Clinical Stage I Nonsmall Cell Lung Cancer: Comparison of Robotic, Video-assisted Thoracic Surgery, and Thoracotomy Lobectomy. Ann Surg 2017;265:431-7.
12. Li C, Hu Y, Huang J, et al. Comparison of robotic-assisted lobectomy with video-assisted thoracic surgery for stage IIB-IIIA non-small cell lung cancer. Transl Lung Cancer Res 2019;8:820-8.
13. Zirafa CC, Cavaliere I, Ricciardi S, et al. Long-term oncologic results for robotic major lung resection in non-small cell lung cancer (NSCLC) patients. Surg Oncol 2019;28:223-7.
14. Veronesi G, Novellis P, Voulaz E, et al. Robot-assisted surgery for lung cancer: State of the art and perspectives. Lung Cancer 2016;101:28-34.
15. Guo F, Ma D, Li S. Compare the prognosis of Da Vinci robot-assisted thoracic surgery (RATS) with video-assisted thoracic surgery (VATS) for non-small cell lung cancer: A Meta-analysis. Medicine (Baltimore) 2019;98:e17089.
16. Gonzalez D, Paradela M, Garcia J, et al. Single-port video-assisted thoracoscopic lobectomy. Interact Cardiovasc

© Annals of Translational Medicine. All rights reserved.

Thorac Surg 2011;12:514-5.
17. Gonzalez-Rivas D, Ismail M. Subxiphoid or subcostal uniportal robotic-assisted surgery: early experimental experience. J Thorac Dis 2019;11:231-9.
18. Yang Y, Song L, Huang J, et al. A uniportal right upper lobectomy by three-arm robotic-assisted thoracoscopic surgery using the da Vinci (Xi) Surgical System in the treatment of early-stage lung cancer. Transl Lung Cancer Res 2021;10:1571-5.
19. Liu L, Mei J, He J, et al. International expert consensus on the management of bleeding during VATS lung surgery. Ann Transl Med 2019;7:712.
20. Gonzalez-Rivas D, Sihoe ADL. Uniportal VATS Lobectomy. In: LoCicero J 3rd, Feins RH, Colson YL, et al. editors. General Thoracic Surgery. 8th edition. Philadelphia, PA, USA: Wolters Kluwer Health, 2019:475-96.
21. Gonzalez-Rivas D, Sihoe ADL. Important Technical Details During Uniportal Video-Assisted Thoracoscopic Major Resections. Thorac Surg Clin 2017;27:357-72.
22. González-Rivas D, Garcia A, Chen C, et al. Technical aspects of uniportal video-assisted thoracoscopic sleeve resections: Where are the limits? JTCVS Tech 2020;2:160-4.
23. Gonzalez-Rivas D, Garcia A, Chen C, et al. Technical aspects of uniportal video-assisted thoracoscopic double sleeve bronchovascular resections. Eur J Cardiothorac Surg 2020;58:i14-22.
24. Soultanis KM, Gonzalez-Rivas D. Uniportal video-assisted sleeve resections: how to deal with specific challenges. J Thorac Dis 2019;11:S1670-7.
25. Hernandez-Arenas LA, Purmessur RD, Gonzalez-Rivas D. Uniportal video-assisted thoracoscopic segmentectomy. J Thorac Dis 2018;10:S1205-14.
26. Nomori H, Okada M. Illustrated Anatomical Segmentectomy for Lung Cancer. Tokyo: Springer Japan, 2012.

Cite this article as: Gonzalez-Rivas D, Manolache V, Bosinceanu ML, Gallego-Poveda J, Garcia-Perez A, de la Torre M, Turna A, Motas N. Uniportal pure robotic-assisted thoracic surgery—technical aspects, tips and tricks. Ann Transl Med 2022. doi: 10.21037/atm-22-1866

© Annals of Translational Medicine. All rights reserved.