Original Article

Acta Vet Eurasia 2026; 52: 1-8

Frontal Sinus Morphology in Domestic Cats and Dogs: Associations with Body Size, Age, and Skull Conformation

Ebru Eravcı YALIN[1], Tomasz SZARA[2], Yusuf ALTUNDAĞ[3], Barış Can GÜZEL[3], Joanna BONECKA[4], Ozan GÜNDEMIR[5,6]

[1]Department of Surgery, Istanbul University-Cerrahpaşa Faculty of Veterinary Medicine, İstanbul, Türkiye
[2]Department of Morphological Sciences, Institute of Veterinary Medicine, Warsaw University of Life Sciences, Warsaw, Poland
[3]Department of Surgery, Namik Kemal University Faculty of Veterinary Medicine, Tekirdağ, Türkiye
[4]Department of Small Animal Diseases and Clinic, Institute of Veterinary Medicine, Warsaw University of Life Sciences, Warsaw, Poland
[5]Department of Anatomy, Istanbul University-Cerrahpaşa Faculty of Veterinary Medicine, Istanbul, Türkiye
[6]Osteoarchaeology Practice and Research Centre, Istanbul University-Cerrahpaşa, Istanbul, Türkiye

Cite this article as: Yalın, E. E., Szara, T., Altundağ, Y., Güzel, B. C., Bonecka, J., & Gündemir, O. (2026). Frontal sinus morphology in domestic cats and dogs: associations with body size, age, and skull conformation. *Acta Veterinaria Eurasia*, 52, 0010 doi: 10.5152/actavet.2026.26010.

Abstract

The frontal sinus is a highly variable cranial structure among carnivores, influenced by factors such as skull morphology, body size, and developmental stage. This study provides a comparative morphometric analysis of frontal sinus volume and internal surface area in domestic dogs (*Canis familiaris*) and cats (*Felis catus*) using 3D segmentation and measurement techniques. Computed tomography scans of 32 animals (dogs: $n = 18$; cats: $n = 14$) wee analyzed, and relationships with body weight, age, skull indices (cranial index, skull index), species, and sex were assessed. Results showed that dogs possessed significantly larger frontal sinus volumes and surface areas compared to cats, reflecting interspecies differences in skull architecture. Body weight was strongly and positively correlated with both sinus volume and surface area, while cranial index exhibited a significant negative association with sinus dimensions, indicating reduced pneumatization in brachycephalic skulls. Skull index demonstrated weaker correlations, and sex was not a significant factor. Both volume and surface area were tightly correlated, suggesting proportional scaling of mucosal surface with cavity size. Age-related differences were evident, with incomplete sinus pneumatization in juveniles, aligning with developmental patterns reported in prior studies. These findings highlight species, body size, and cranial conformation as primary determinants of frontal sinus morphology, while sex exerts minimal influence. The results provide novel reference data on frontal sinus surface area, complementing volume-based metrics and reinforcing the clinical and anatomical importance of considering breed-related skull morphology in veterinary imaging, diagnosis, and surgical planning.

Keywords: Anatomy, computed tomography, morphometric analysis, paranasal sinuses, veterinary imaging

What is already known on this topic?

- *Frontal sinus morphology varies widely in carnivores, and skull conformation matters: brachycephalic animals often have reduced/absent frontal sinuses, while dolichocephalic animals tend to have better-developed sinuses.*
- *Computed tomography (CT) with 3D reconstruction enables accurate quantitative assessment of paranasal sinuses (e.g., volume-based measurements) and supports clinical imaging and surgical planning.*
- *Despite existing anatomical knowledge, quantitative evidence is still limited on how body size, cranial proportions, and age jointly shape frontal sinus dimensions.*

Introduction

Paranasal sinuses are air-filled cavities within the skull that open into the nasal cavity (Alsafy et al., 2022; Blanton & Biggs, 1969). Their presence, number, and size vary widely among species. While their exact functions remain under debate, several hypotheses have been proposed. One widely accepted view suggests that these cavities lighten the skull and help warm and humidify inhaled air (Díaz Martínez et al., 2024). Another prominent hypothesis proposes that sinuses occupy areas of the skull where mechanical strength is not required, thus adding flexibility to cranial shape; they may also play a role in dissipating stresses generated during mastication (Curtis & Van Valkenburgh, 2014). Among these structures, the frontal sinus is of particular interest. Large herbivorous mammals, such as horses and cattle, possess multiple, extensive paranasal sinuses, whereas members of the order Carnivora typically have smaller and simpler sinus systems (Díaz Martínez et al., 2024). In small carnivores like cats and dogs, the principal paranasal sinuses are the frontal sinus and the maxillary recess; cats may also develop a small sphenoidal sinus, whereas dogs lack sphenoidal and palatine sinuses entirely (Losonsky et al., 1997). The feline frontal sinus is typically a single compartment, while in dogs, it is divided into rostral, lateral, and medial parts (Díaz Martínez et al., 2024). Notably, skull conformation strongly affects sinus development: brachycephalic breeds often exhibit significantly reduced or absent frontal sinuses, whereas dolichocephalic breeds tend to have well-developed frontal sinuses (Wolfer et al., 2021).

Corresponding Author: Ebru Eravcı Yalın • **E-mail:** ebru.eravciyalin@iuc.edu.tr

Received: January 16, 2026 • **Revision Requested:** March 10, 2026 • **Last Revision Received:** March 31, 2026 • **Accepted:** April 28, 2026 • **Publication Date:** July 13, 2026 • **DOI:** 10.5152/actavet.2026.26010

Available online at actavet.org

This work is licensed under a Creative Commons Attribution-NonCommercial 4.0 International License.

What this study adds on this topic?

- *Provides a CT-based 3D segmentation dataset in 32 domestic cats and dogs and reports both frontal sinus volume and internal surface area as quantitative outcomes (including species-level reference values).*
- *Shows that body weight is the strongest independent determinant of sinus size (volume and surface area increase markedly with weight), while cranial index has an additional negative effect (smaller sinuses in relatively broader/shorter skulls); age and skull index did not add significant independent effects in the final models.*
- *Demonstrates that sex is not a significant factor, and surface area scales closely with volume, supporting proportional scaling of mucosal surface with cavity size.*

Advances in medical imaging have enabled the precise volumetric study of the paranasal sinuses (Iturralde-Garrote et al., 2023; Köhler et al., 2021). Computed tomography (CT) provides high-resolution cross-sectional images that can be reconstructed in three dimensions, enabling the accurate measurement of sinus cavities (Lee et al., 2022; Morales Bordon et al., 2024). Several volumetric studies have applied CT imaging to quantify sinus dimensions and compare interspecies and breed-related differences. For example, Curtis and Van Valkenburgh (2014) used CT scans to perform a quantitative analysis of frontal sinus morphology across canids, felids, and hyenids, providing one of the first numerical assessments of variation in carnivore sinuses. Similarly, recent studies on domestic and large cats have employed maximum intensity projection and volumetric rendering techniques to visualize and measure the nasal cavity and paranasal sinuses, resulting in detailed anatomical reconstructions (Díaz Martínez et al., 2024). Earlier veterinary research by Losonsky et al. (1997) represents one of the first CT-based descriptions of the normal nasal cavity and paranasal sinuses in cats, laying the groundwork for future imaging studies. Modern CT-based 3D modeling techniques now enable precise volumetric assessment of sinus morphology, providing valuable reference data for understanding species and breed variability and supporting diagnostic imaging, surgical planning, and the investigation of sinus-associated diseases.

Despite the extensive anatomical literature on carnivores, quantitative studies examining the frontal sinus remain limited, particularly in relation to how body size, cranial proportions, and age interact to shape this structure. Given the role of the frontal sinus in taxonomy, species identification, and forensic assessments, there is a need to establish a clear understanding of which biometric and morphological variables most strongly influence its size and form. This study, therefore, aims to systematically evaluate the contributions of body weight, age, and cranial indices to frontal sinus dimensions in carnivores, providing a robust reference framework for future anatomical, morphometric, and comparative studies.

Materials and Methods

The study was conducted in accordance with local legislation and institutional requirements and the research was approved by Istanbul University-Cerrahpasa University (Date: 26.09.2025 , Number: 2025/98). Written informed consent was obtained from all animal owners prior to inclusion in the study.

This study was conducted using CT images of domestic cats (*Felis catus*, $n = 14$) and dogs (*Canis familiaris*, $n = 18$) that were evaluated at the Istanbul University-Cerrahpasa Veterinary Health Practice and Research Center Only individuals without a history of cranial trauma or evident sinus pathology were included to ensure the anatomical integrity of the measurements.

All CT images were acquired using a siemens somatom scope (vc30b) scanner. The scanning protocol was standardized for all animals, with a slice thickness of 0.6 mm, a tube voltage of 110 kV, and a current of 28 mA, resulting in a total scanning time of approximately 14 seconds per subject. Animals were positioned in sternal recumbency with the head extended to ensure consistent orientation and minimize motion artifacts. The acquired Digital Imaging and Communications in Medicine images were reviewed for quality control using the scanner's proprietary software, and all datasets were exported for segmentation and analysis.

Three-dimensional reconstructions of the frontal sinus were created using 3D Slicer (version 5.6), a widely used open-source software for medical imaging analysis (Fedorov et al., 2012). Segmentation was performed manually using a combination of threshold-based selection and slice-by-slice contour refinement to ensure anatomical accuracy. Each frontal sinus cavity was segmented individually, with care taken to accurately delineate sinus boundaries, thereby avoiding artifacts and overestimation (Figure 1). After segmentation, the Segment Statistics module of 3D Slicer was used to calculate sinus volume (mm^3) and internal surface area (mm^2) from the reconstructed 3D models. All reconstructions and measurements were performed by a single experienced investigator to minimize inter-operator variability, and each model was visually inspected to confirm anatomical accuracy.

To investigate cranial conformation, two established morphometric indices were calculated: the cranial index (CI), defined as the ratio of maximum width of the neurocranium (euryon–euryon) to cranial length (akrokranion–nasion) multiplied by 100, and the skull index (SI), defined as the greatest frontal breadth divided by total skull length, also multiplied by 100 (Evans & de Lahunta, 2013; Getty, 1975). These indices allowed classification of skull types into brachycephalic, mesaticephalic, and dolichocephalic conformations, providing an additional perspective on morphological variability. Body weight

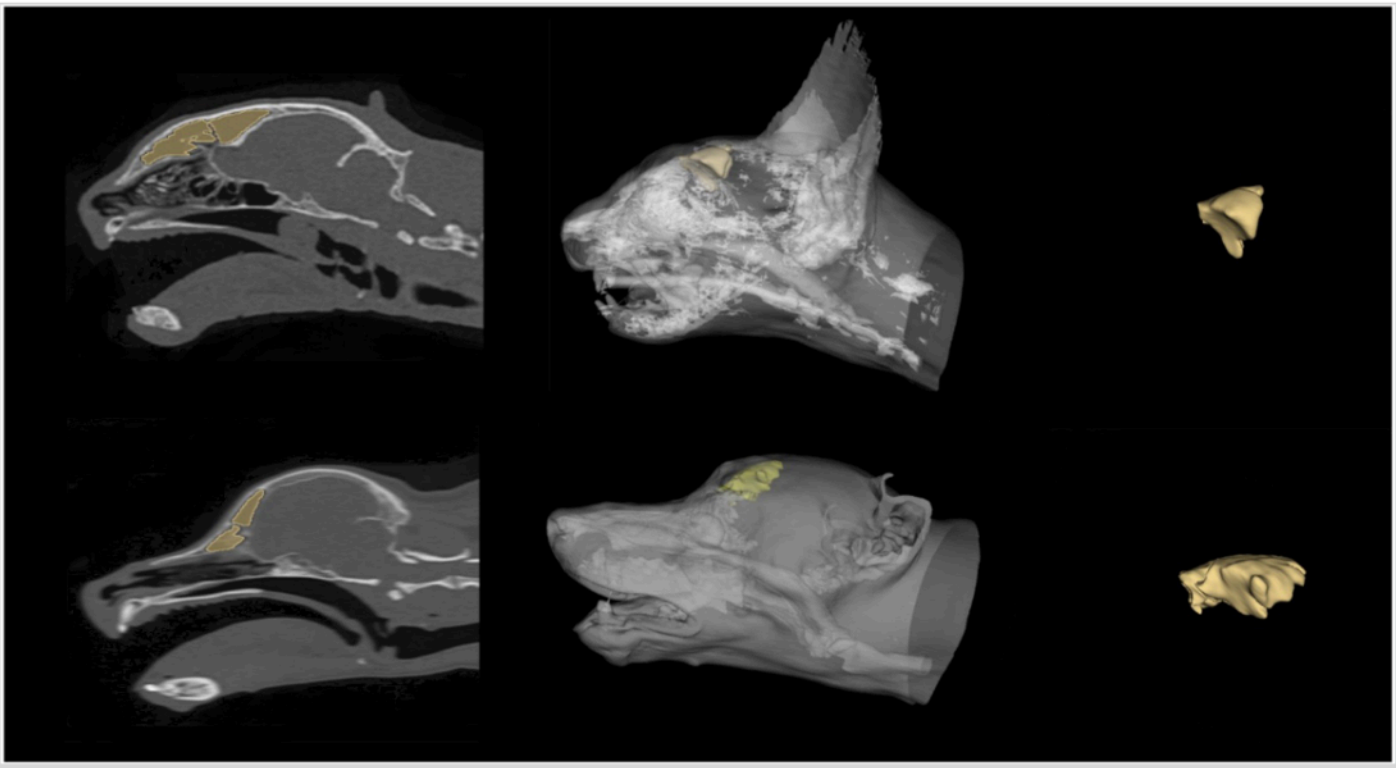

Figure 1.
CT-Based Segmentation and 3D Reconstruction of the Frontal Sinus in Domestic Cats (Top Row) and Dogs (Bottom Row), Showing Sagittal CT Sections with Highlighted Sinus Regions (Left), 3D Models Within Skull Context (Middle), and Isolated Sinus Structures (Right).

and age of each animal were obtained from hospital records, ensuring precise demographic data for statistical analysis.

All statistical analyses were conducted in R (version 2024.09.1), a reproducible environment for advanced statistical computing (R Core Team, 2024). Data exploration included summary statistics, visual inspection of distributions, and the detection of outliers. Two-way analysis of variance (ANOVA) was used to assess the effects of species and sex on frontal sinus volume and surface area. To examine predictors of sinus morphology, linear regression analyses were performed separately for each predictor (age, body weight, CI, and SI) and subsequently combined in multiple regression models to evaluate independent effects. Stepwise regression with Akaike's Information Criterion was applied for optimal model selection. Visualization was performed using the ggplot2 package, producing scatter plots, regression plots, and boxplots to illustrate group differences and trends (Wickham, 2016).

Results

Relationship Between Surface Area and Volume

The dataset includes measurements from 32 individuals, representing both cats and dogs, with a balanced representation of males and females. Cats consistently show smaller frontal sinus dimensions, with average volumes of around 2,200 mm^3 in females and 3,000 mm^3 in males, and surface areas averaging approximately 1,560 mm^2 and 1,840 mm^2, respectively. Dogs, on the other hand, display substantially larger frontal sinuses, with female dogs averaging about 13,800 mm^3 in volume and 5,600 mm^2 in surface area, while males average roughly 19,700 mm^3 in volume and 7,600 mm^2 in surface area.

The relationship between surface area and volume is well illustrated in the scatter plot, where cats form a tight cluster with little variation between sexes, while dogs occupy a wider range on both axes (Figure 2). Male dogs are particularly distinct, occupying the higher end of both volume and surface area values, demonstrating broader cranial diversity within this group.

Effect of Species and Sex: Results

The two-way ANOVA results revealed that differences between species are statistically significant for both frontal sinus volume and surface area (volume: $p \approx .0012$; surface area: $p \approx .0033$). In contrast, sex showed no significant effect, either as a main factor or in interaction with species (all $p > .2$).

Model performance further supports this conclusion, with R^2 values of around 0.62 for both surface area and volume, indicating that a substantial proportion of variance can be explained solely by species differences.

Determinants of Frontal Sinus Morphology: The Influence of Body Size, Age, and Cranial Indices

The analysis of frontal sinus measurements in cats and dogs reveals clear differences in the influence of body size and cranial proportions on sinus development. When examining age and body weight as predictors, body weight emerges as the single strongest factor explaining variation in both sinus volume and surface area (Figure 3).

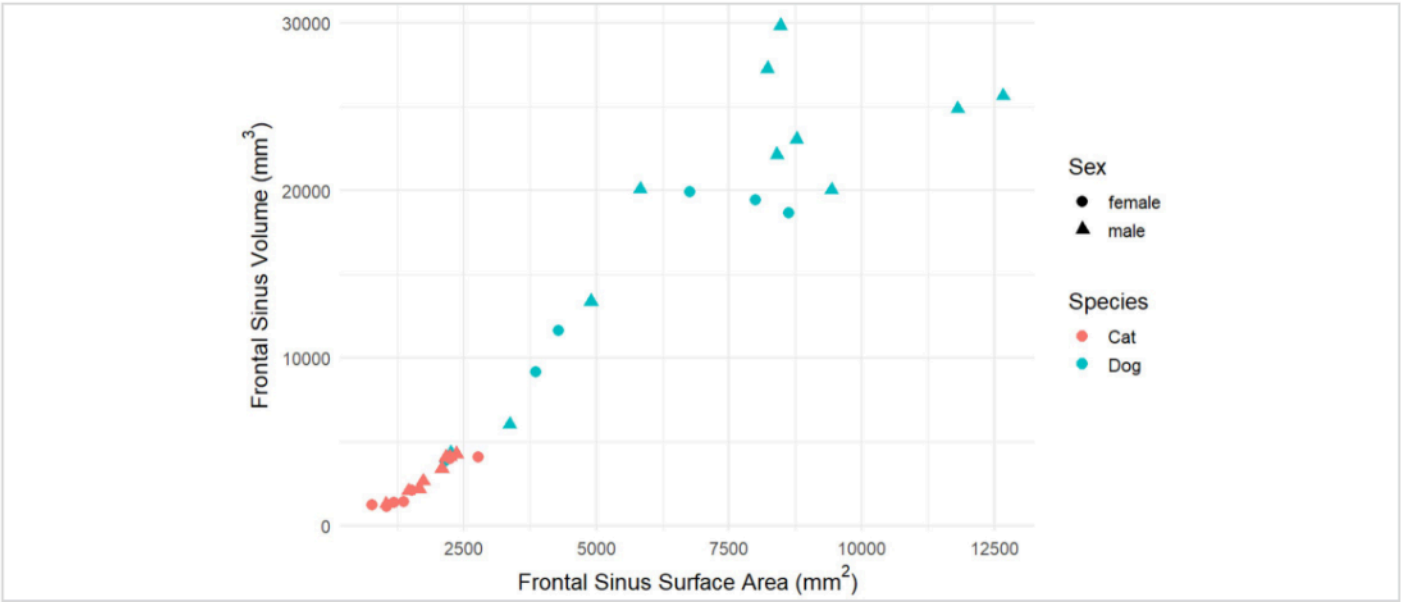

Figure 2.
Scatterplot of the Frontal Sinus Volume and Surface Area by Species and Sex.

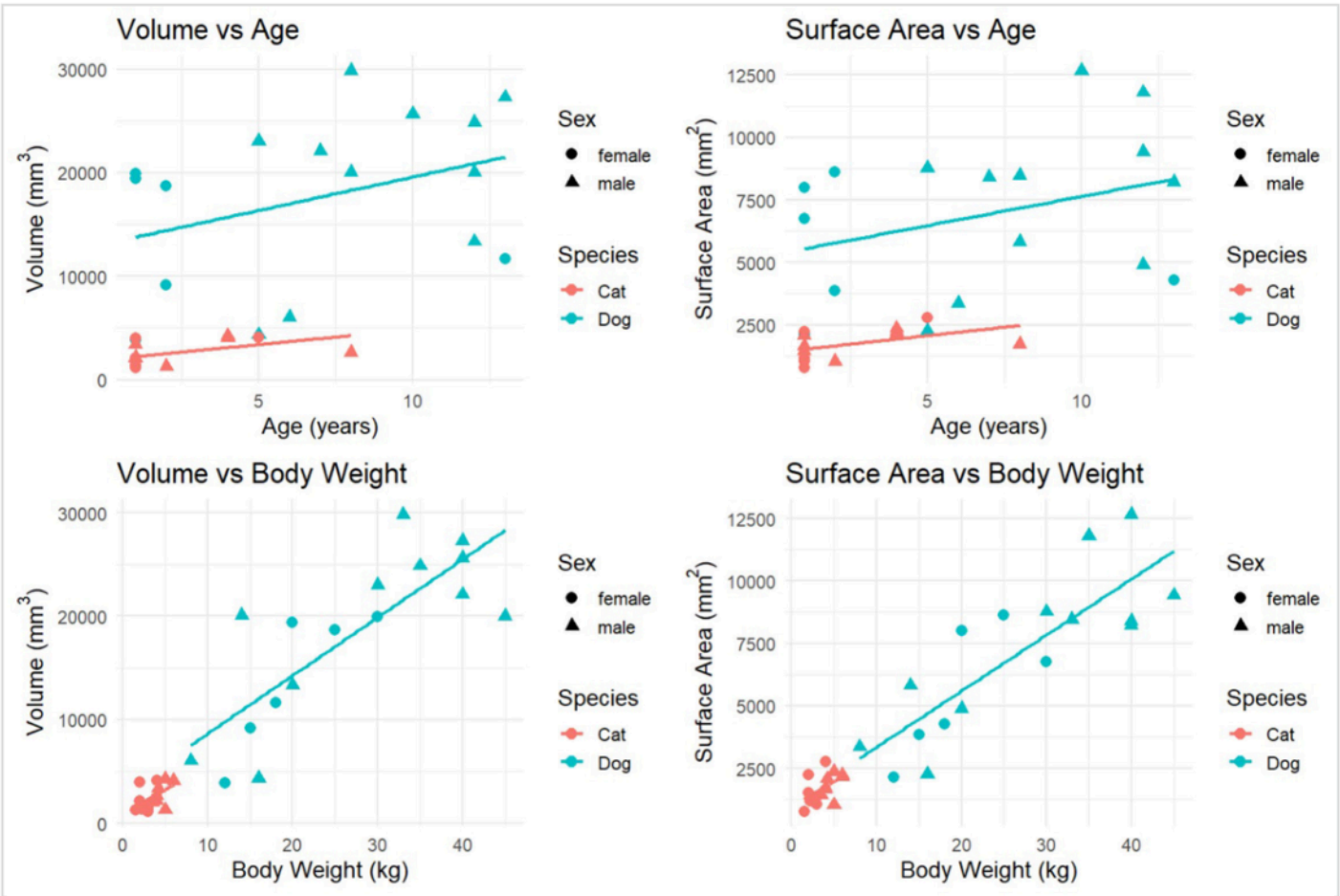

Figure 3.
Regression Plots Between the Frontal Sinus Volume, Surface Area, Age, and Body Weight.

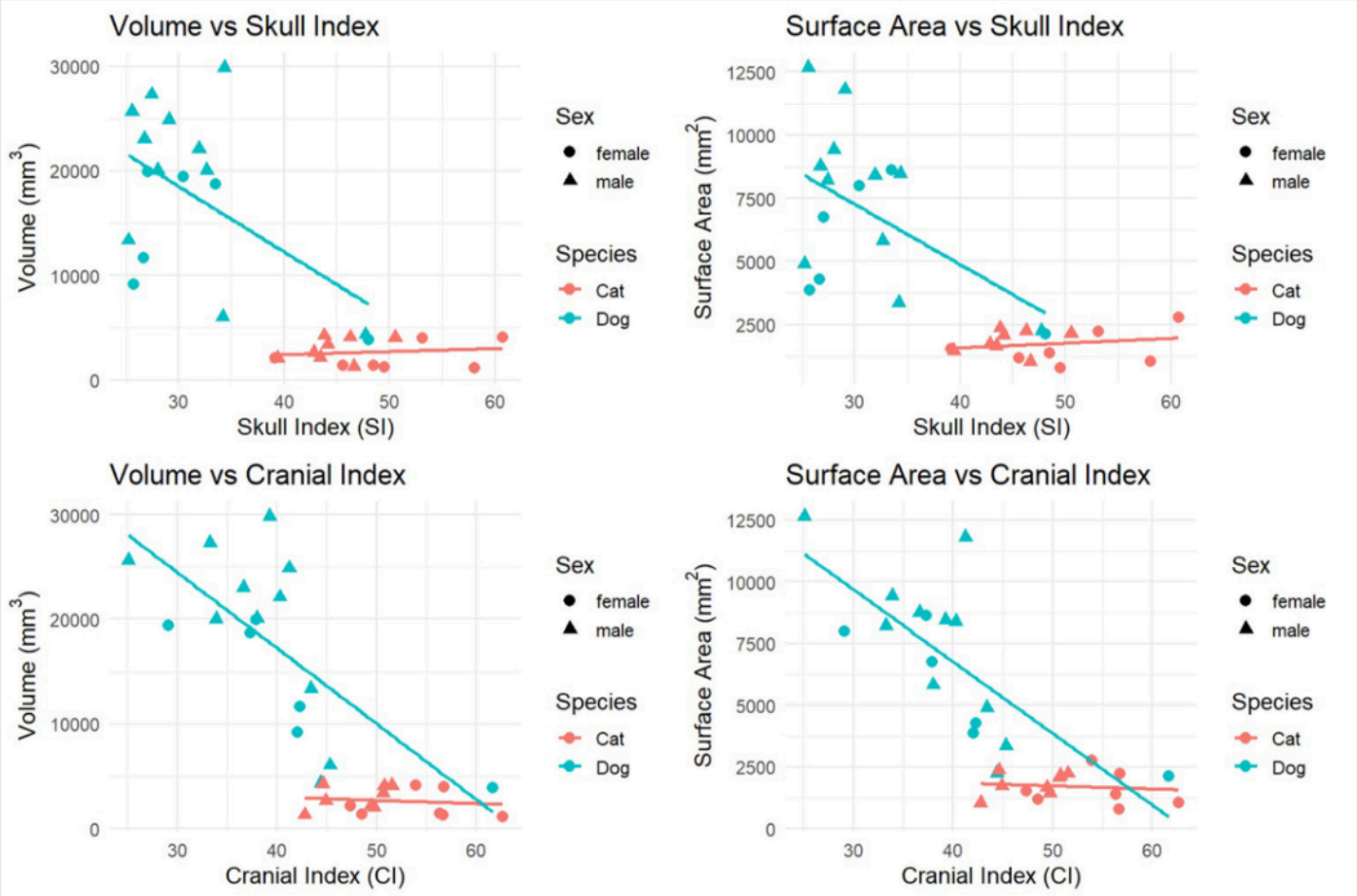

Figure 4.
Regression Plots Between the Frontal Sinus Volume, Surface Area, and Skull and Cranial Indices.

For every kilogram of body weight, frontal sinus volume increases by approximately 625 mm^3 and surface area by about 233 mm^2, with both relationships being highly significant ($p < .0001$). These models explain over 85% of the variation in sinus volume and surface area ($R^2 \approx 0.85$). In contrast, age shows no statistically significant association with sinus dimensions.

When assessing cranial indices, the CI shows a meaningful negative association with both sinus volume and surface area ($p \approx .01$ for volume and $p \approx .004$ for surface area), whereas the SI displays weaker or non-significant effects (Figure 4). Although these indices provide insight into cranial proportions, the models based on CI and SI explain only about 66%–67% of the variation in sinus dimensions, which is notably lower than the explanatory power of body weight.

Multivariate Regression Analysis of Determinants of Frontal Sinus Dimensions

The multivariate regression and stepwise model selection analyses identified the variables that most strongly influence frontal sinus volume and surface area (Figure 5). The findings show that body weight is by far the most significant and independent predictor for both measurements. On average, each additional kilogram of body weight corresponds to an increase of approximately 520 mm^3 in sinus volume and 187 mm^2 in surface area, highlighting its dominant role. Cranial index also demonstrated a significant negative effect, indicating that cranial proportions have an impact on sinus size independent of body size. In contrast, age and SI did not contribute significantly.

The explanatory power of these models is high, with R^2 values of approximately 87% for volume and 88% for surface area. Overall, these results show that frontal sinus size is primarily driven by general body size, while cranial proportions play a secondary role, fine-tuning the sinus dimensions.

Discussion

This study addresses that gap by examining the relationships between frontal sinus volume and surface area in relation to body size, age, and cranial proportions in carnivores. The findings indicate that sinus size is primarily determined by overall body size, while cranial indices play a secondary role in refining its dimensions. Multivariate regression and model selection analyses clearly identified body weight as the strongest and most independent determinant of frontal sinus size. The observation that each kilogram of body weight is associated with significant increases in both sinus volume and surface area highlights the strong correlation between this structure and overall body dimensions. This supports previous findings suggesting that frontal sinus morphology is closely aligned

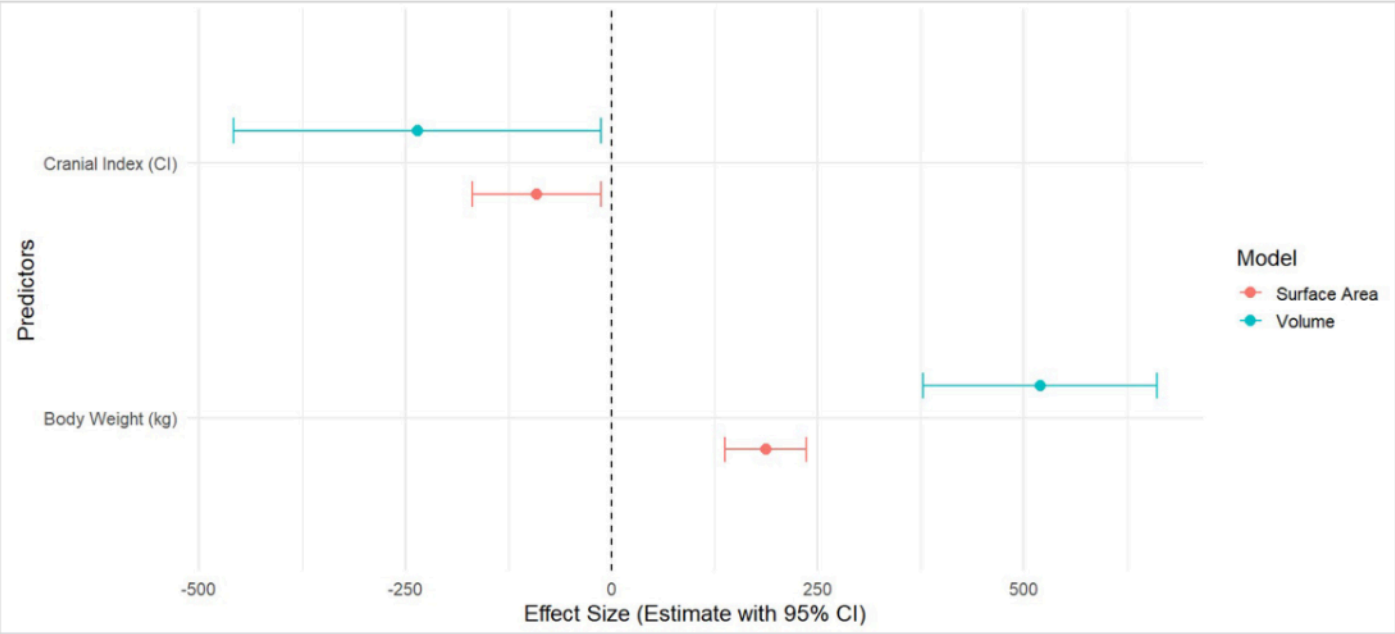

Figure 5.
Predictors of Frontal Sinus Dimensions. This Plot Displays the Estimated Effects of Body Weight and CI on Frontal Sinus Volume (Blue) and Surface Area (Red) Based on Regression Models. Points Represent Regression Coefficients (Effect Sizes), and Horizontal Lines Show the 95% Confidence Intervals. Values to the Right of Zero Indicate a Positive Association, While Values to the Left Indicate a Negative Association.

with the scale of the skull and respiratory structures. In contrast, age was not a significant factor, implying that frontal sinus morphology is largely established early in life and remains relatively stable once growth is complete.

The negative association of the CI with sinus volume and surface area further demonstrates that cranial proportions exert an independent influence over sinus dimensions. Individuals with relatively shorter and broader skulls tend to have smaller frontal sinuses, reflecting the interplay between skull architecture and the development of paranasal air spaces. The lack of significance for the SI suggests that CI may be a more sensitive metric for understanding cranial variation in this context. These findings underscore the importance of detailed morphometric approaches in enhancing the understanding of cranial adaptation patterns and their relationship to sinus development.

The significant interspecies differences in frontal sinus volume and surface area observed in this study underscore the strong role of species-specific cranial architecture and overall body size in shaping sinus morphology. The markedly larger frontal sinuses in dogs compared to cats align with their generally larger cranial dimensions, an expected scaling relationship rather than a surprising finding, and may also reflect broader species-level adaptive differences. In contrast, the lack of a measurable sex effect suggests that frontal sinus size is relatively stable between males and females, indicating that sexual dimorphism is not a major source of variation in this region. Collectively, these results suggest that comparative anatomical and morphometric assessments of the frontal sinus should prioritize species identity and body size as primary explanatory variables, while considering sex as a secondary factor with limited influence. This supports the use of frontal sinus metrics as a robust taxonomic marker for distinguishing species, with minimal confounding from intraspecific variation related to sex.

The average frontal sinus volume in dogs in this sample was about one order of magnitude greater than in cats. This difference is consistent with the overall disparity in skull size and indicates that frontal sinus development differs between the two species. This divergence may be linked to functional factors, as larger carnivores such as dogs are thought to have evolved more complex paranasal sinuses, potentially related to olfaction and to the conditioning of inspired air (Buzek et al., 2022; Díaz Martínez et al., 2024). Paranasal sinuses contribute to warming and humidifying air as it moves through the respiratory tract (Díaz Martínez et al., 2024), and the larger sinus surface area observed in dogs may provide an advantage for air conditioning given their generally higher ventilation volumes. In contrast, the smaller frontal sinus in domestic cats may be sufficient for their lower airflow requirements. Overall, the findings show that dogs have more developed frontal sinuses than cats, which is consistent with previous anatomical reports (Curtis & Van Valkenburgh, 2014; Díaz Martínez et al., 2024).

In dogs, brachycephalic individuals with short muzzles frequently had very small frontal sinuses, whereas mesaticephalic and dolichocephalic dogs had well-developed sinuses. This pattern is consistent with reports that marked brachycephaly is associated with frontal sinus hypoplasia or aplasia (Ekenstedt et al., 2020). In breeds such as Bulldogs and Pugs, the frontal sinuses can be markedly reduced or completely absent (Evans & de Lahunta, 2013; Ekenstedt et al., 2020). Richardson and Mathews (1995) also reported that some brachyce-phalic dogs show no discernible frontal sinus on imaging. The results align with these observations, since brachycephalic dogs in this sam-ple had negligible sinus volumes, indicating that a shortened skull conformation limits sinus pneumatization.

Dogs with more elongated skulls tended to have larger sinus volumes and in some cases a more complex internal structure, including

multiple compartments. This matches the findings of Kupczyńska et al. (2005), who reported that dolichocephalic dogs may have three distinct frontal sinus chambers on each side. In this dataset, the CI correlated inversely with sinus volume. Individuals with a high CI, indicating broader and shorter skulls, generally had minimal sinuses, while those with a lower CIx, indicating narrower and longer skulls, had larger sinuses. A similar relationship has been described in cats. Schmidt et al. (2017) found that highly brachycephalic Persian cats described as peke face often had very small or absent frontal sinuses compared with doll face Persians and domestic shorthair cats and that extreme brachycephaly was sometimes accompanied by malformations in the frontal region. In the feline sample, brachycephalic cats when present also tended to have smaller sinuses. Overall, the findings support the view that skull conformation is a major determinant of frontal sinus anatomy, and that selection for brachycephalic head shape can substantially reduce or eliminate the frontal sinus (Ekenstedt et al., 2020; Schmidt et al., 2017). This may also be clinically relevant because reduced sinus spaces and altered drainage pathways have been associated with chronic upper airway problems in brachycephalic animals, including conditions such as chronic rhinitis that may be aggravated by impaired sinonasal function (Packer et al., 2015).

Body size was strongly associated with frontal sinus dimensions in this study, with a significant positive correlation between body weight and sinus volume across the sampled animals. In dogs, larger breeds generally had larger sinuses, whereas very small dogs tended to have minimal sinus volumes. This pattern is consistent with previous quantitative work showing that canine upper airway spaces scale with body size. For example, Czichon et al. (2022) reported a strong correlation between dog body weight and nasal cavity volume (r around 0.87). In cats, where body size varies less, the relationship was weaker, although the largest cat also had the largest sinus volume among felines. Overall, these findings indicate that body and skull size place an upper limit on sinus size and help explain why dogs typically have larger frontal sinuses than cats (Curtis & Van Valkenburgh, 2014). Both species normally possess frontal sinuses (Allen et al., 1999; Evans & de Lahunta, 2013), but absolute volume scales with cranial size, as expected for paranasal sinuses in larger animals (Dyce et al., 2010).

A novel aspect of the work was evaluating frontal sinus internal surface area together with volume. These two parameters were closely correlated in both species, and larger sinus volumes were accompanied by proportionately larger internal surface areas with an approximately linear relationship. This expected geometric scaling still matters biologically, because mucosal surface area relates directly to functions such as mucus production and air filtration and conditioning. In this sample, increased surface area did not appear to result from greater internal complexity. Instead, sinuses tended to scale up while maintaining broadly similar form, so surface area increased in step with volume. Few veterinary anatomy studies report sinus surface area, as most focus on volume or linear dimensions (Kupczyńska et al., 2005). By presenting both measures, the authors show that although dogs have substantially larger sinuses than cats in absolute terms, surface area scales predictably with volume in both species. In this dataset, dogs with the largest sinuses had surface areas far exceeding those of cats, which may have functional and clinical relevance, including differences in airflow and heat exchange and potentially a larger mucosal field for diseases such as sinonasal aspergillosis.

Conclusion

The results indicate that body size should be treated as a core variable when interpreting frontal sinus morphology, with cranial indices offering complementary information about how skull conformation relates to sinus development. The reference values reported here can support future anatomical, forensic, and taxonomic work by providing a baseline for comparing frontal sinus measurements across carnivores. The same framework is also relevant for clinical contexts, where interpreting sinus anatomy benefits from accounting for both overall size and cranial shape.

Data Availability Statement: The data that support the findings of this study are available on request from the corresponding author.

Artificial Intelligence Usage Statement: The authors declared that no Artificial Intelligence tool was used in the preparation of the manuscript.

Ethics Committee Approval: Ethics committee approval was received for this study from the ethics committee of Istanbul University-Cerrahpasa (Date: 26.09.2025, Number: 2025/98).

Informed Consent: Written informed consent was obtained from the owners of the animals who participated in this study.

Peer-review: Externally peer-reviewed.

Author Contributions: Concept - E.E.Y., O.G.; Design - O.G., T.S.; Supervision - E.E.Y.; Resources - E.E.Y., T.S., O.G.; Materials - Y.A., B.C.G., O.G.; Data Collection and/or Processing - Y.A., J.B.; Analysis and/or Interpretation - E.E.Y., O.G.; Literature Search - E.Y.Y., T.S., O.G.; Writing Manuscript - Y.A., B.C.G., J.B.; Critical Review - E.E.Y., B.C.G., O.G.

Declaration of Interests: The authors declare that they have no competing interest.

Funding: This study did not receive any specific grant from funding agencies in the public, commercial, or not-for-profit sectors.

References

Allen, H. S., Broussard, J., & Noone, K. (1999). Radiographic findings in cats with chronic nasal disease. *Journal of Feline Medicine and Surgery*, *1*(2), 75–81. [CrossRef]

Alsafy, M. A., El-Gendy, S. A., & Rutland, C. S. (2022). Anatomical guide to the paranasal sinuses of domestic animals. In *Updates on veterinary anatomy and physiology*. IntechOpen. [CrossRef]

Blanton, P. L., & Biggs, N. L. (1969). Eighteen hundred years of controversy: The paranasal sinuses,. *American Journal of Anatomy*, *124*(2), 135–147. [CrossRef]

Buzek, A., Serwańska-Leja, K., Zaworska-Zakrzewska, A., & Kasprowicz-Potocka, M. (2022). The shape of the nasal cavity and adaptations to sniffing in the dog (Canis familiaris) compared to other domesticated mammals: A review article. *Animals*, *12*(4), 517. [CrossRef]

Curtis, A. A., & Van Valkenburgh, B. (2014). Beyond the sniffer: Frontal sinuses in Carnivora. *Anatomical Record*, *297*(11), 2047–2064. [CrossRef]

Czichon, F., Reiter, A., Meier, V., & Rohrer Bley, C. (2022). Relative tumor volume has prognostic relevance in canine sinonasal tumors treated with radiation therapy: A retrospective study. *PLOS One*, *17*(5), e0269083. [CrossRef]

Díaz Martínez, E., Arencibia Espinosa, A., Soler Laguía, M., Ayala Florenciano, M. D., Kilroy, D., García García, M. I., Martínez Gomariz, F., Sánchez Collado, C., Gil Cano, F., Jaber, J. R., & Ramírez Zarzosa, G. (2024). The bony nasal cavity and paranasal sinuses of big felids and domestic cat: A study using anatomical techniques, computed tomographic images reconstructed in maximum intensity projection; volume rendering and 3D models. *Animals*, *14*(17), 2609. [CrossRef]

Dyce, K. M., Sack, W. O., & Wensing, C. J. G. (2010). *Textbook of veterinary anatomy* (4th ed). Elsevier, Amsterdam.

Ekenstedt, K. J., Crosse, K. R., & Risselada, M. (2020). Canine brachycephaly: Anatomy, pathology, genetics and welfare. *Journal of Comparative Pathology*, *176*, 109–115. [CrossRef]

Evans, H. E., & de Lahunta, A. (2013). *Miller's anatomy of the dog* (4th ed). Elsevier, Amsterdam.

Fedorov, A., Beichel, R., Kalpathy-Cramer, J., Finet, J., Fillion-Robin, J. C., Pujol, S., Bauer, C., Jennings, D., Fennessy, F., Sonka, M., Buatti, J., Aylward, S., Miller, J. V., Pieper, S., & Kikinis, R. (2012). 3D Slicer as an image computing platform for the Quantitative Imaging Network. *Magnetic Resonance Imaging*, *30*(9), 1323–1341. [CrossRef]

Getty, R. (1975). *Sisson and Grossman's the anatomy of the domestic animals* (5th ed). Saunders, Philadelphia.

Iturralde-Garrote, A., Sanz, J. L., Forner, L., Melo, M., & Puig-Herreros, C. (2023). Volumetric changes of the paranasal sinuses with age: A systematic review. *Journal of Clinical Medicine*, *12*(10), 3355. [CrossRef]

Köhler, L., Schulz-Kornas, E., Vervuert, I., Gittel, C., Winter, K., Berner, D., & Gerlach, K. (2021). Volumetric measurements of paranasal sinuses and examination of sinonasal communication in healthy Shetland ponies using computed tomography. *BMC Veterinary Research*, *17*(1), 41. [CrossRef]

Kupczyńska, M., Makowiecka, M., Skibniewski, M., Galanty, M., & Bissenik, I. (2005). Morfologia zatoki czołowej psa. *Medycyna Weterynaryjna*, *61*(9), 1011–1014.

Lee, S., Fernandez, J., Mirjalili, S. A., & Kirkpatrick, J. (2022). Pediatric paranasal sinuses: Development, growth, pathology, and functional endoscopic sinus surgery. *Clinical Anatomy*, *35*(6), 745–761. [CrossRef]

Losonsky, J. M., Abbott, L. C., & Kuriashkin, I. V. (1997). Computed tomography of the normal feline nasal cavity and paranasal sinuses. *Veterinary Radiology and Ultrasound*, *38*(4), 251–258. [CrossRef]

Morales Bordon, D., Suárez-Cabrera, F., Ramírez, G., Paz-Oliva, P., Morales-Espino, A., Arencibia, A., Encinoso, M., Ventura, M. R., & Jaber, J. R. (2024). Study of the normal crested porcupine (Hystrix cristata) nasal cavity and paranasal sinuses by cross-sectional anatomy and computed tomography. *Veterinary Sciences*, *11*(12), 611. [CrossRef]

Packer, R. M. A., Hendricks, A., Tivers, M. S., & Burn, C. C. (2015). Impact of facial conformation on canine health: Brachycephalic obstructive airway syndrome. *PLOS One*, *10*(10), e0137496. [CrossRef]

R Core Team (2024). *R: A Language and Environment for Statistical Computing*. R Foundation for Statistical Computing. Retrieved from https://www.R-project.org/

Richardson, E. F., & Mathews, K. G. (1995). Distribution of topical agents in the frontal sinuses and nasal cavity of dogs: Comparison between current protocols for the treatment of treatments for nasal aspergillosis. *Veterinary Surgery*, *24*(6), 476–483. [CrossRef]

Schmidt, M. J., Kampschulte, M., Enderlein, S., Gorgas, D., Lang, J., Ludewig, E., Gerlach, K., & Ondreka, N. (2017). Relationship between brachycephalic head features in modern Persian cats and dysmorphologies of the skull and internal hydrocephalus. *Journal of Veterinary Internal Medicine*, *31*(5), 1487–1501. [CrossRef]

Wickham, H. (2016). *ggplot2: Elegant graphics for data analysis*. Springer, Berlin.

Wolfer, N., Wang-Leandro, A., Beckmann, K. M., Richter, H., & Dennler, M. (2021). Intracranial lesion detection and artifact characterization: Comparative study of susceptibility- and T2-weighted imaging in dogs and cats. *Frontiers in Veterinary Science*, *8*, 779515. [CrossRef]