15th International Congress of Histochemistry and Cytochemistry

"From Molecules to Diseases"

ABSTRACT BOOK



ICHC 2017

Kervansaray Lara Hotel, ANTALYA

May 18 - 21, 2017

Turkey

www.ichc2017.com

in memory of

Prof. Dr. Suzan Dağlıoğlu
1953 - 2017

15th International Congress of Histochemistry and Cytochemistry

"From Molecules to Diseases"

ICHC 2017

Kervansaray Lara Hotel, ANTALYA
May 18 - 21, 2017

Turkey



Dear Colleagues,
On behalf of the Turkish Society for Electron Microscopy, it is my pleasure to welcome all the participants of 15th International Congress of Histochemistry and Cytochemistry (ICHC 2017) in Kervansaray Lara Hotel and Exhibition Center, Antalya, Turkey.

First of all, as the Organization Committee of ICHC 2017, we would like to share our deep sorrow about the loss of our beloved Vice Chair of the Congress, Past President of Turkish Society for Electron Microscopy, Dearest Friend Prof. Dr. Suzan Dağlıoğlu, who passed away on April 2 nd 2017. We would like to extend our sincerest condolences to her family and to her colleagues. ICHC 2017 is dedicated to the memory of Prof. Dr. Suzan Dağlıoğlu.

During the organization period of ICHC 2017, we had an excellent collaboration with members of the Organization Committee, Scientific Programme Committee and International Scientific Advisory Board to whom we would like to extend our special appreciations.

We gratefully acknowledge the excellent support and teamwork provided by Organization Secretariat, FIGUR INTERNATIONAL, PCO of ICHC 2017.

We wish to express our gratitude to all the sponsoring companies for their financial supports.

A special thank is for Mr. Ibrahim Zaman, a Master of Photography, for his fabulous Photography Show ''My Beloved Turkey", during the Opening Ceremony.
During planning of ICHC 2017, we have tried to bring the worldwide histochemists together by creating an environment for close cooperation, collaboration and exchange of information. We thoroughly believe that the congress program, under the theme"From Molecules to Diseases"is inspiring with a considerable amount of keynote, plenary and invited speakers in the field of Histochemistry and Cytochemistry.

The program will include: 1 Keynote, 5 Plenary, 34 Invited Lectures (including Society- sponsored and Journal-sponsored sessions), 21 Scientific sessions with 59 Short Oral Presentations and 2 Poster Sessions 275 Poster Presentations.

As the highlights of The Opening Ceremony: David Glick Lecture, by Prof. Dr. John Couchman, and Keynote Lecture by Prof. Dr. Ron van Noorden will be delivered. Paul Nakane Prize will be presented to Prof. Dr. Toyoshi Fujimoto during the Opening Ceremony. Photography Show ''My Beloved Turkey", by Mr. Ibrahim Zaman will be performed during the Opening Ceremony.

''Let the Seniors share their expertise with Juniors" and ''Young Histochemists Awardees" Sessions, as well as 3 Workshops will be within the Scientific Programme and provide a unique opportunity for young histochemists to get acquainted with outstanding researchers.

A sponsored company-based exhibition with technical presentations will display the latest advancements in this field.
Welcome Reception, Gala Dinner and Closing Ceremony with Farewell Party are among the Social Programme of ICHC 2017. Post- congress tours will be an excellent opportunity to discover the beautiful city of Antalya and its surroundings during spring time.

On behalf of the Organization Committee of ICHC 2017, we would like to wish you a compelling and successful ICHC 2017 with lively discussions in a stimulating scientific atmosphere by scientific contributions of more than 300 distinguished experts in the field of histochemical and cytochemical techniques and their applications.

As stayed by Mustafa Kemal ATATURK, the Founder of the Republic of Turkey, ''Our True Mentor In Life is Science" , we believe in the strength of science in uniting people and nations in the whole world.
We sincerely hope you will have a delightful stay in the beautiful city of Antalya.

Best Regards,
On behalf of the Organization Committee of ICHC 2017,
Serap ARBAK
President
ICHC 2017 & International Federation of Societies for Histochemistry and Cytochemistry
(IFSHC) & Turkish Society for Electron Microscopy



Dear Colleagues,

I would like to welcome you all to the 15 th International Congress of Histochemistry and Cytochemistry in Antalya, Turkey. The Turkish Society of Electron Microscopy first applied for the organization of this meeting under the auspices of the International Federation of Societies for Histochemistry and Cytochemistry (IFSHC) at the ICHC 2004 in San Diego, USA. Thanks to the persistence of Professor Serap Arbak, the President of the IFSHC, and other members of the Organizing Committee, and despite many unforeseeable events, our Turkish hosts have succeeded in organizing this well-planned congress distinguished by highly attractive scientific and social programs.

The mission of the IFSHC is to promote communications and co-operation among scientists throughout the world who are interested in the fields of microscopy, histochemistry, immunocytochemistry and cell biology. The IFSHC supports the David Glick lecture, Paul Nakane Prize and Young Histochemists which highlight the achievements of cell imaging sciences. The scientific program of the Congress based on the theme "From Molecules to Diseases" covers new applications of microscopic techniques both in basic cell reasearch and clinical studies that will be presented by the leading world experts.

I am sure that ICHC 2017 will provide an opportunity not only to attend the sessions and symposia organized by prominent scientists but also to interact and network with other participants both on formal occasions such as sessions or poster presentations and during informal gatherings at the exhibitions and social events.

Zbigniew Kmiec
Secretary-General
International Federation
of Societies for Histochemistry and Cytochemistry

INDEX

Committees	8
Program at a Glance	10
Scientific Program	11
David Glick Lecture	19
Keynote Lecture	20
Planery Lectures	22
Invited Speakers	28
Young Histochemist Awardees	64
Workshops	72
Oral Presentations	74
Poster Presentations	148
Sponsoring Societies & Journals	496
Sponsoring Companies	497

COMMITTEES

President	Serap ARBAK	(Acıbadem University)
Vice President	Suzan DAĞLIOĞLU	(Istanbul University)
Vice President	Melek ÖZTÜRK	(Istanbul University)
Secretary General	Selma YILMAZER	(Istanbul University)

International Scientific Programme Committee

Serap ARBAK	Turkey
John COUCHMAN	Denmark
Petek KORKUSUZ	Turkey
Ron van NOORDEN	The Netherlands
Melek OZTURK	Turkey
Selma YILMAZER	Turkey

Local Organization Committee

Abit AKTAŞ	Istanbul University	Sevinç İNAN	Izmir Economy University
Ranan Gülhan AKTAŞ	Maltepe University	Mehtap KUTLU	Anadolu University
Serap ARBAK	Acıbadem University	Melek ÖZTÜRK	Istanbul University
Alp CAN	Ankara University	Serap ŞİRVANCI	Marmara University
Nur ÇAKAR	TOBB University	İsmail SEÇKİN	Istanbul University
Yurdagül CANBERK	Istanbul University	Matem TUNÇDEMİR	Istanbul University
Suzan DAĞLIOĞLU	Istanbul University	Selma YILMAZER	Istanbul University
Feriha ERCAN	Marmara University	Deniz YÜCEL	Acıbadem University
Elif GÜZEL	İstanbul University		

International Scientific Advisory Board

IFSHC

	President	Serap ARBAK	Turkey
	Secretary-General	Zbigniew KMIEC	Poland
	Treasurer	Hinke MULTHAUPT	Denmark
	Councilor	Raymond COLEMAN	Israel
	Councilor	Tetsuro TAKAMATSU	Japan
Susan BROOKS	United Kingdom	C J van NOORDEN	The Netherlands
John COUCHMAN	Denmark	Paolo ONORI	Italy
Ramazan DEMİR	Turkey	Robert Y. OSAMURA	Japan
Charles FREVERT	USA	Margit PAVELKA	Austria
Qutayba HAMID	Canada	Reinhard RACHEL	Germany
Pavel HOZAK	Czech Republic	Sanja STIFTER	Croatia
Bruno HUMBEL	The Netherlands	Gulgun ŞENGÜL	Turkey
Erdal KARAÖZ	Turkey	Çevik TUFAN	Turkey
Agnes KITTEL	Hungary	Zahra ZAKERI	USA
He LI	China	J van ZOOLEN	The Netherlands
Rossana C. N. MELO	Brazil		

Jury Members for "Best Poster Award ICHC 2017'

Moderators: Mehtap KUTLU (Turkey) • Engin YENILMEZ (Turkey) • Deniz YÜCEL (Turkey)

Belgin CAN	Turkey	Irina KOLOTUEVA	Switzerland
Jerry Edward CHIPUK	USA	Emel KOPTAGEL	Turkey
Çiğdem ELMAS	Turkey	Nesrin ÖZFILIZ	Turkey
Süheyla GONCA	Turkey	Engin YENILMEZ	Turkey
Figen KAYMAZ	Turkey	Melda YILMAZ	Turkey
Serçin KARAHUSEYİNOĞLU	Turkey		

Jury Members for "Best Micrograph Award ICHC 2017'

Moderator: Melek ÖZTÜRK (Turkey)

Alp CAN	Turkey	İbrahim ZAMAN	Turkey
İsmail SEÇKİN	Turkey	Servet SEZGİN	Turkey
Zahra ZAKERI	USA		

THURSDAY / 18.05.2017

08:00 – 18:00 **REGISTRATION**

09:00 – 13:00
- WORKSHOP-1 HALL 1
- WORKSHOP-2 HALL 2
- WORKSHOP-3 HALL 3

12:30 IFSHC - FIRST DELEGATE'S MEETING

13:00 – 14:00 **LUNCH**

15:00 – 15:45 **OPENING CEREMONY HALL A**

15:45 – 16:45 **DAVID GLICK LECTURE HALL A**

16:45 – 17:45 **KEYNOTE LECTURE HALL A**

17:45 – 18:00 **Paul Nakane Prize Award Ceromony**

18:00 – 19:30 **WELCOME RECEPTION**

FRIDAY / 19.05.2017

09:00 – 18:30 **REGISTRATION**

09:45 – 10:30 **PLENARY LECTURE 1 HALL 1**

10:30 – 11:00 **COFFEE BREAK**

HALL 1	HALL 2	HALL 3
S-1 Epigenetics and Molecular Cytogenetics Oral presentation	S-2 Cellular Aging and Cell Death-I	S-3 Developmental and Reproductive Biology-I
S-4 Glycobiology		Oral presentations

11:00 – 12:00

12:00 – 13:00

13:00 – 14:00 **LUNCH**

14:00 – 14:45 **PLENARY LECTURE 2 HALL 1**

HALL 1	HALL 2	HALL 3
S-5 Cancer Biology -I	S-6 Calcified Tissues, Biomaterials and Regenerative Medicine	S-7 Stem Cells-I
S-8 In Vivo Imaging	Oral presentations	Technical Presentation

14:45 – 15:45

15:45 – 16:45

16:45 – 17:30 **POSTER SESSION - I & COFFEE BREAK**

HALL 1	HALL 2	HALL 3
	S-9 Cellular Aging and Cell Death-II Oral presentations	

17:30 – 18:30

20:00 **SOCIAL PROGRAMME**

SATURDAY / 20.05.2017

09:00 – 18:30 **REGISTRATION**

09:45 – 10:30 **PLENARY LECTURE 3 HALL 1**

PLENARY LECTURE 4 HALL 1

10:30 – 11:00 **COFFEE BREAK**

HALL 1	HALL 2	HALL 3
S-10 Correlating Light and Electron Microscopy	S-11 Developmental and Reproductive Biology-II	S-12 Pathology and Clinical Medicine-I
S-13 Structure and Function of the Cell	Oral presentations	Oral presentations

11:00 – 12:00

12:00 – 13:00

13:00 – 14:00 **LUNCH**

IFSCH - (HALL 4) SECOND DELEGATE'S MEETING

14:00 – 14:45 **PLENARY LECTURE 5 HALL 1**

HALL 1	HALL 2	HALL 3
S-14 Techniques in Immunohistochemistry	S-15 Neuroscience	S-16 Pathology and Clinical Medicine-II
Oral presentations	Oral presentations	Oral presentations

14:45 – 15:45

15:45 – 16:45

16:45 – 17:30 **POSTER SESSION - II & COFFEE BREAK**

HALL 1	HALL 2	HALL 3
	S-17 Stem Cells-II Oral presentations	

17:30 – 18:30

20:00 **GALA DINNER**

SUNDAY / 21.05.2017

09:00 – 18:30 **REGISTRATION**

09:45 – 10:30
- Young Histochemist Awardees
- Let The Seniors Share Their Expertise With Juniors
- Technical Presentation

10:30 – 11:00 **COFFEE BREAK**

HALL 1	HALL 2	HALL 3
S-18 Developmental and Reproductive Biology-III	S-19 Advances in Image Analysis	S-20 Cancer Biology-II
Oral presentations	Oral presentation	Oral presentations

11:00 – 12:00

12:00 – 13:00

13:00 – 14:00 **CLOSING CEREMONY & FAREWELL PARTY**

14:00 – 14:45 **EXCURSION**

THURSDAY
18.05.2017

08:00 – 18:00 REGISTRATION

	HALL 1	HALL 2	HALL 3
09:00 – 13:00	**WORKSHOP-1** Immunogold staining Lecturers: S. Şirvancı, D. Akakın, Ö.T. Kaya (Marmara University, Turkey)	**WORKSHOP-2** Introduction to three-dimensional modeling and animation in histology and embryology Lecturer: T. Peker (Gazi University, Turkey)	**WORKSHOP-3** Basic stem cell culture techniques and applications Lecturers: I. Tuglu, S. Inan, E. Turkoz Uluer, I. Aydemir, P. Kilicarslan Sonmez (Celal Bayar University, Turkey)
12:30 – 13:00	**IFSHC FIRST DELEGATE'S MEETING** (HALL 4)		
13:00 – 14:00		LUNCH	LUNCH

15:00 – 15:45 **OPENING CEREMONY** - HALL A

Opening Remarks
Serap Arbak
President - ICHC 2017 & IFSHC & TSEM

Welcome Speech
Zbigniew Kmiec
IFSHC - Secretary-General

Photography Show
Ibrahim Zaman – My Beloved Turkey
Photographer

15:45 – 16:45 **DAVID GLICK LECTURE - HALL A**

John Couchman (Denmark)
Syndecans: receptors with signalling functions and roles cell adhesion and disease

Chair: Ron van Noorden (The Netherlands)

16:45 – 17:45 **KEYNOTE LECTURE - HALL A**

Ron van Noorden (The Netherlands)
What is new in histochemistry and cytochemistry

Chair: Serap Arbak (Turkey)

17:45 – 18:00 **Paul Nakane Prize Award Ceromony**

18:00 – 19:30 **WELCOME RECEPTION**

FRIDAY
19.05.2017

09:00 – 18:30 REGISTRATION

09:45 – 10:30 PLENARY LECTURE 1

Christopher Cremer (Germany)
Single molecule localization microscopy of nuclear genome nanostructure

Chair: Ron van Noorden (The Netherlands)

HALL 1

10:30 – 11:00 COFFEE BREAK

HALL 1

S-1
Epigenetics and Molecular Cytogenetics

Chairs: Christopher Cremer (Germany) &
Marion Cremer (Germany)

Marion Cremer (Germany) (Invited speaker)
Distinct 3D nuclear topography of active and inactive regulatory sequences studied with super-resolution fluorescence microscopy

Milena Georgieva (Bulgaria) (Invited speaker)
Epigenetic significance of higher-order chromatin organization in health and disease

Oral presentation
Odontoclastic differentiation ability of human dental pulp cells in the presence of triethylene glycol dimethacrylate.
Zeynep Öncel Torun, Deniz Torun, Barış Baykal, Ali Oztuna, Fatih Yesildal, Ferit Avcu (Turkey)

S-4
Glycobiology

Chair: John Couchman (Denmark)
Gunnar Pejler (Sweden) (Invited speaker)
Serglycin proteoglycan: regulating apoptosis and protease-dependent epigenetic events

HALL 2

S-2
Cellular Aging and Cell Death-I
(Sponsored by International Cell Death Society)

Chairs: Zahra Zakeri (USA) & Richard Lockshin (USA)

Zahra Zakeri (USA) (Invited speaker)
Viral infection and cell death

Richard Lockshin (USA) (Invited speaker)
Relationship of cell death and aging

Jerry Edward Chipuk (USA) (Invited speaker)
Mitochondrial division and melanoma: Causes and Consequences

Raymond Birge (USA) (Invited speaker)
Phosphatidylserine sensing by TAM receptors regulates AKT-dependent chemo-resistance and PD-L1 expression

HALL 3

S-3
Developmental and Reproductive Biology-I

Chairs: Çiler Çelik Özenci (Turkey) & Oya Evirgen (Turkey)

Çiler Çelik Özenci (Turkey)(Invited speaker)
Blastocyst and the receptive endometrium: it takes two to tango

Oral presentations
The role of trophoblastic items in oocyte culture
Hilal Kabadayı, Kemal Özbilgin, Hafize Seda Vatansever (Turkey)

Influence of estrogen receptor α phosphorylation at serine 309 on male reproductive function of mice
Zhen Li, Jinhua Wei, Binfang Ma, Pang Cheng, Jie Zhao, Xiao Feng, Yuanqiang Zhang (China)

Two-dimensional and three-dimensional endometrial co-cultures:novel approaches for {In-vitro} implantation models
Sercin Karahüseyinoğlu, Deniz Yücel, Gizem Nur Şahin, Kübra Sarı, Ahmet Kocabay, Ali Cihan Taşkın (Turkey)

The relation of Adam2 (Fertilin), catsper, Sox5, septin 12 and histone 3 expressions with the function of spermatozoa in male infertility
Sercin Karahüseyinoğlu, Şule Ayla, Özge Biçeroğlu, Kübra Sarı, Gizem Nur Şahin, Tuba Varli Yelke (Turkey)

The effect of different vitrification solutions and devices on cat ovarian tissue
Ferda Topal Çelikkan, Murside Ayşe Demirel, Duygu Baki Acar, Sinan Özkavukcu, Seçkin Salar, Esra Atabenli Erdemli, Ayhan Bastan (Turkey)

The role of CX3CL1 in fetal-maternal interaction during human gestation
Elif Kervancıoğlu Demirci (Turkey), Lois A. Salamonsen (Australia), Martin Gauster (Austria)

12:00 – 13:00 (HALL 1 continues)

13:00 – 14:00 LUNCH

14:00 – 14:45 PLENARY LECTURE 2

Vasıf Hasırcı (Turkey)
The Dialog Between Biomaterials and Cells

Chair: Giuseppe Musumeci (Italy)

HALL 1

FRIDAY 19.05.2017

	HALL 1	HALL 2	HALL 3
14:45 15:45	**S-5** **Cancer Biology -I** **Chairs:** Gülperi Öktem (Turkey) & Agnes Kittel (Hungary) **Agnes Kittel (Hungary)** (Invited speaker) Extracellular vesicles and their potential applications in cancer research **Nihal Karakaş (Turkey)** (Invited speaker) In vivo imaging of therapeutic efficacy in stem cell implanted brain tumors.	**S-6** **Calcified Tissues, Biomaterials and Regenerative Medicine** **Chairs:** Petek Korkusuz (Turkey) & Giuseppe Musumeci (Italy) (Sponsored by Acta Histochemica) **Petek Korkusuz (Turkey)** (Invited speaker) Cell gate of osteoporosis **Giuseppe Musumeci (Italy)** (Invited speaker) (Sponsored by Journal of Functional Morphology and Kinesiology) The effects of physical activity, tissue engineering and mechanobiology on articular cartilage **Yannis Missirlis (Greece)** (Invited speaker) All the appropriate signals are necessary for engineering proper tissues: a prerequisite for successful tissue engineering	**S-7** **Stem Cells-I** **Chairs:** Marius Z. Ratajczak (USA) & Erdal Karaöz (Turkey) **Marius Z. Ratajczak (USA)** (Invited speaker) Current status and future of stem cell therapies - novel view on stem cells isolated from adult tissues **Erdal Karaöz (Turkey)** (Invited speaker) Stem cell applications on neuro-muscular degenerative disorders: bench to bedside **Alp Can (Turkey)** (Invited speaker) Stem cell approaches contributing to the therapy of ıschemic cardimyopathy
15:45	**S-8** **In Vivo Imaging** **Chairs:** Ralph Meuwissen (Turkey) & Alper Özgür Karaçalıoğlu (Turkey) **Ralph Meuwissen (Turkey)** (Invited speaker) Advances in noninvasive imaging: Implications for pre-clinical research **Alper Özgür Karaçalıoğlu (Turkey)** (Invited speaker) In vivotracking of biologic molecules: from the cell to small laboratory animals	**Oral presentations** Differential proteomics analysis of axolotl's regenerating tail *Turan Demircan, İlknur Keskin, Gürkan Öztürk, Ahmet Tarık Baykal (Turkey)* The behavior of menstrual blood-derived stem cells on electrospun polymeric fibers *Deniz Yücel, Hazal Gezmiş, Seçil Demir, Gamze Torun Köse, Nesrin Hasirci, Vasif Hasirci (Turkey)* The effect of electro magnetic fields on stem and cancer cell *İbrahim Mehmet Tuğlu, Mehmet Gümüşay, Suna Sayğili, Şamil Öztürk, Mahmut Özkut, Işıl Aydemir, Adnan Kaya (Turkey)*	**Technical Presentation-I** **Chair:** Gülnur Kızılay Özfidan (Turkey) Cytation™ 5 Cell Imaging, BioTek, Andreas Riger (USA)
16:25 16:45			
16:45 17:30	**POSTER SESSION - I & COFFEE BREAK**		
17:30 18:30		**S-9** **Cellular Aging and Cell Death-II** **Chairs:** Sevda Müftüoğlu (Turkey) & Marianne Pedersen (Denmark) **Oral presentations** Biological activities of natural compounds extracted from {rhamnus alaternus} plant *Wissem Bhouri, Ines Bouhlel, Leila Chekir Ghedira (Tunisia)* Endocannabinoid induced apoptotic cell death on endometriotic cells *Elif Bilgiç, Emine Elif Güzel Meydanlı, İrem Akar, Sevil Köse, Eda Karaismailoğlu, Alp Usubütün, Petek Korkusuz (Turkey)* Effect of folic acid on testicular toxicity induced by bisphenol A in male Wistar rats *Özay Güleş, Mustafa Yıldız, Zahid Naseer (Turkey)* The role of p97/VCP (Valosin containing protein) in mouse Sertoli cell's autophagy and protein degradatio *Sevil Çayli, Tuba Ozdemir Sanci, Cansu Şahin, Hilal Nakkas, Seda Ocakli (Turkey)* Stem cell-induced differential gene expression profiles associated with apoptosis, necrosis and anoikis: Novel insights into cell death mechanisms in prostate cancer *Cuneyd Parlayan, Şule Ayla, Guvanch Ovezmyradov, Gunel Mukhtarova, Gülperi Öktem*	
21:00	**SOCIAL PROGRAMME**		

SATURDAY 20.05.2017

09:00 18:30 **REGISTRATION**

09:00 09:45

PLENARY LECTURE 3
Bruno M. Humbel (Switzerland)
Correlative Light and Electron Microscopy Approaches in Cell Biology
Chair: Alberto Luini (Italy)
HALL 1

09:45 10:30

PLENARY LECTURE 4
Nadine Peyrieras (France)
3D+time imaging data and image analysis for the reconstruction of multilevel dynamics in animal morphogenesis
Chair: Gunnar Pejler (Sweden)
HALL 1

10:30 11:00 **COFFEE BREAK**

HALL 1

S-10
Correlating Light and Electron Microscopy

Chairs: Bruno M. Humbel (Switzerland) & Irina Kolotueva (Switzerland)

Albero Luini (Italy) (Invited speaker)
Visualizing multi-protein complexes by correlative video-light and electron microscopy

Irina Kolotueva (Switzerland) (Invited speaker)
Array tomography for small asymmetric samples: a direct 3D correlative light and electron microscopy method

S-13
Structure and Function of the Cell

Chairs: Hinke Multhaupt (Denmark) & Arzu Karabay Korkmaz (Turkey)

Hinke Multhaupt (Denmark) (Invited speaker)
Heparan sulfate synthesis enzymes are distributed across the Golgi apparatus

Arzu Karabay Korkmaz (Turkey) (Invited speaker)
Septins as the fourth elements of the cytoskeleton and a new substrate for microtubule severing enzyme p60-katanin

HALL 2

S-11
Developmental and Reproductive Biology-II

Chairs: Cristina Pujades (Spain) & Necdet Demir (Turkey)

Cristina Pujades (Spain) (Invited speaker)
Building the inner ear: cellular dynamics of neurosensory progenitors during embryonic development

Oral presentations

Pregnancy with an embryo derived from a germinal vesicle stage oocyte and birth of a healthy baby in a stimulated IVF cycle
Barış Baykal, Cem Korkmaz, Cihangir Mutlu Ercan, Seyit Temel Ceyhan, Salih Kozan (Turkey)

The effect of antioxidants to angiogenesis on uterine transplantation
Tuğba Uğurlu, Candan Özoğul, Gülistan Sanem Sarıbaş, Seren Gülşen Gürgen, Seda Nur Akyol, Bahar Kartal (Turkey)

Immunohistochemical localization of certain nervous system markers on the testis and epididymis of rat during postnatal period
Feyzullah Beyaz, Emel Ergün, Mehmet Özbek, Levent Ergün (Turkey)

Investigation of obstructive uropathy for histopathologic changes and apoptosis ın urinary system of adriamycin-exposed rat fetuses
Şule Yalçın, Işık Ünal, Elif Kırlı, Pergin Atilla, Sevda Müftüoğlu, İbrahim Karnak (Turkey)

Histochemical study of the ovaries in {Piezodorus lituratus} (Fabricius, 1794) (Heteroptera: Pentatomidae)
Zekiye Suludere, Selami Candan, Irmak Polat, Damla Amutkan, Nurcan Özyurt Koçakoğlu (Turkey)

Cytochemical aspects of sporoderm development in {Pancratium Maritimum} L
Sevil Tütüncü Konyar (Turkey)

HALL 3

S-12
Pathology and Clinical Medicine-I

Chairs: Elisabetta Falcieri (Italy) & Mara Pilmane (Latvia)

Elisabetta Falcieri (Italy) (Invited speaker)
How many types of cell death? The crucial role of morphology

Mara Pilmane (Latvia) (Invited speaker)
The 16 years follow-up results of cleft research in Latvian population

Oral presentations

The influence of different fixatives and preparation methods on morphology, immunohistochemistry and molecular analyses
Lone Bojesen, Dorte Skriver Jensen, Wojciech Skovrider Ruminski, Nadja Beekhuijen, Reema Butt, Anne Mette Wenning, Birgitte Bols, Estrid Høgdall, Hanne Bjørn (Denmark)

Structural effects of microneedling and topical retinol palmitate on burn wounds
Elçin Servet Alpat, Burak Kaya, Hilal Nakkaş, Pınar Bayram, Şule Kızıl, Belgin Can, Serdar Mehmet Gültan (Turkey)

Exposure to a continuous 900-MHz electromagnetic field for 1 hour a day throughout middle and late adolescence alters the morphological structure and some biochemical markers of the female rat kidney at postnatal day 60
Derya Öztürk Okatan, Ersan Odacı (Turkey)

Functional characterization of p.T10M and p.S345Y mutations in HNF1A gene in MODY patients
Özlem Yalçın Çapan, Oğuzhan Fatih Baltacı, Ece Selçuk Şahin, Ergül Berber (Turkey)

Impairments of oxidant/antioxidant levels and some morphological changes in the adult female rat heart following exposure to a continuous 900-MHz electromagnetic field for 1 hour a day throughout middle and late adolescence
Hatice Hancı, Derya Öztürk Okatan, Ersan Odacı (Turkey)

Effects of propolis against cisplatin induced experimental kidney damage in rats
Esin Yuluğ, Sibel Türedi, Engin Yenilmez, Yüksel Aliyazıcıoğlu, Selim Demir, Serap Özer Yaman, Ahmet Menteşe (Turkey)

11:00 12:00
12:00 13:00

13:00 14:00 **LUNCH**

IFSCH
SECOND DELEGATE'S MEETING (HALL 4)

SATURDAY
20.05.2017

PLENARY LECTURE 5
Pavel Hozak (Czech Republic)
Uncovering roles of lipids in genome regulation
Chair: Melek Öztürk (Turkey)
HALL 1

14:00
14:45

HALL 3	HALL 2	HALL 3
S-14 **Techniques in Immunohistochemistry** **Chairs:** Marija Plodinec (Switzerland) & Lone Bojesen (Denmark)	**S-15** **Neuroscience** **Chairs:** Selma Yılmazer (Turkey) & Marc Davenne (France)	**S-16** **Pathology and Clinical Medicine-II** **Chairs:** Hale Kırımlıoğlu (Turkey) & Emel Koptagel(Turkey)
14:45 15:45 **Marija Plodinec (Switzerland)** (Invited speaker) Mechanobiology of epithelia on native basement membranes - relevance for cancer cell invasion & clinics **Bilal E. Kerman (Turkey)** (Invited speaker) An in vitro approach to understanding myelination and myelin disorders	**Marc Davenne (France)** (Invited speaker) The axon initial segment: a novel site of neuronal dysfunction in multiple sclerosis? **Erdinç Dursun (Turkey)** (Invited speaker) Vitamin D perspective in neurodegeneration and Alzheimer's disease: the genetic background and the cellular mechanisms	**Hale Kırımlıoğlu (Turkey)** (Invited speaker) Rejection Pathology In Liver Transplantation
Oral presentations Differences in ımmunohistochemical localization and distribution of galectin-1 and -3 in rat testes and epididymis during postnatal development *Emel Ergün, Mehmet Özbek, Feyzullah Beyaz, Levent Ergün, Hikmet Altunay, Nevin Kurtdede, Nuh Yıldırım, Özge Özgenç (Turkey)*	**Özhan Eyigör (Turkey)** (Invited speaker) Immunonohistochemical Assessment of Neuronal Activation in Neuroendocrine Systems **Oral presentations** Revealing physical and functional ınteraction between p60-katanin and p53 *Şirin Korulu (Turkey)*	**Oral presentations** The ultrastructural ınvestigation of slit diaphragm protein expressions and filtration barrier features in some human podocytopathies *Mustafa Yilmaz, Kezban Kibar, Banu Coşkun Yilmaz, Iclal Gürses, Ahmet Kıykım (Turkey)* The role of curcumin in streptozotocin-induced hepatic damage and the trans-differentiation of hepatic stellate cells *Hesham Noaman Abdelraheem Mustafa (Saudi Arabia)*
15:45 16:45	Immunohistochemical evaluation of the autoantibodies in surgically treated MTLE-HS patients *Ayşegül Fırat, Fadime Irsel Tezer Filik, Işık Ünal, Burçak Bilginer, Figen Kaymaz, Figen Söylemezoğlu, Serap Saygı (Turkey)* Investigation of dose-dependent ultrastructural alterations after topical lithium treatment in peripheral nevre injuries by transmission electron microscope *Emre Kocman, İlknur Dağ, Tayfun Sengel, Erdem Söztutar, Mediha Canbek*	Changes in histological structure and biochemical markers in the adult male rat pancreas following exposure to a continuous 900-MHz electromagnetic field for 1 hour a day throughout adolescence *Gökçen Kerimoğlu, Ersan Odacı (Turkey)* Acute alterations in the morphology and biochemistry of the female rat liver following continuous 900-megahertz electromagnetic field (1 hour per day) administration throughout middle and late adolescence *Derya Öztürk Okatan, Ali Kulaber, Ersan Odacı (Turkey)* A histopathological and biochemical evaluation of oxidative injury in the sciatic nerves of male rats exposed to a 900-megahertz electromagnetic field throughout all periods of adolescence *Gökçen Kerimoğlu, Canan Güney, Şafak Ersöz, Ersan Odacı (Turkey)* The risk assessment of Gd2O3:Yb3+/Er3+nanocomposites as dual-modal nanoprobes for magnetic and fluorescence imaging *Long Huang, Fukang Xie, Li Li (China)* Lipopolysaccharide-induced liver damage is prevented by ginkgo biloba extract 761 and flunixin meglumin in septicemia *Tuba Parlak Ak, Burcu Gül Baykalır, Ismail Seven, Gürdal Dağoğlu, Mine Yaman (Turkey)* Immunohistochemical evaluation of effects of bevacizumab on radiation injury after stereotactic radiosurgery *Ayfer Aslan, Alp Ozgun Borcek, Zeynep Bengisu Kaya, Ozgur Ocal, Erkut Baha Bulduk, Ozge Petek Erpolat Tater, Murat Uçar, Figen Kaymaz (Turkey)*
16:45 17:30	**POSTER SESSION - II & COFFEE BREAK**	
17:30 18:30	**S-17** **Stem Cells-II** **Chairs:** İbrahim Tuğlu (Turkey) & Aydan Özgörgülü (Turkey) **Oral presentations** The role of stem cell on the reproductive organs *İbrahim Tuğlu, Işıl Aydemir, Mahmud Özkut, Fatma Öztürk, Alican Gümürdü, Rehime Ablumiti, Dila Sal (Turkey)* Optimizing hydroxy apatite based scaffold with harmony of stem cells for tooth tissue engineering *Alev Cumbul, P. Neslihan Taşlı, Gül Merve Yalçın Ülker, Ünal Uslu, Fikrettin Şahin (Turkey)* Comparison of immunological properties of mononuclear cells between acute myeloid leukemia patients and healthy donors *İlkay Pişkin, Yasin Köksal, Fatma Karaca Kara, Neşe Yaralı, Meltem Özgüner (Turkey)* Amniotic Fluid derived stem cells and its multilineage differentiation *A S M Golam Kibria, Özlem Özden Akkaya, Korhan Altunbaş, Metin Erdoğan, Artay Yağcı (Turkey)*	
20:00 23:30	**GALA DINNER**	

SUNDAY 21.05.2017

09:00 – 15:30 REGISTRATION

HALL 1

08:45 – 09:45

Young Histochemist Awardees
Chairs: Hinke Multhaupt (Denmark) & Zbigniew Kmiec (Poland)

Debora Burini (Italy)
Morphological study of chondrocyte cell death in patients affected by chondrocalcinosis

Sara Escudeiro-Lopes (Czech Republic)
Characterization of Lamin A / Phosphatidylinositol-4,5-bisphosphate complex

Özlem Tuğçe KAYA (Turkey)
Ultrastructural Examination of Doublecortin, GABA and VGLUT1 Levels in the Dentate Gyrus of Absence Epileptic Rats

Jacek Kiezun (Poland)
The expression of galanin receptors (GALR1, GALR2 and GALR3) in colorectal cancer

Mohammed Khurshed (The Netherlands)
IDH1-mutated gliomas rely on anaplerosis of glutamate and lactate whereas IDH1 wild-type gliomas rely on glycolysis and acetate anaplerosis

09:45 – 10:30

Let the Seniors Share their Expertises with Juniors

HALL 2

Technical Presentation-II

Chair: Şahin Sırmalı (Turkey)

New Tools for 3D Electron Microscopy,
ZEISS, Joerg Lindenau (Germany)

HALL 3

10:30 – 11:00 COFFEE BREAK

11:00 – 13:00

S-18
Developmental and Reproductive Biology-III
Chairs: Ramazan Demir (Turkey) & Ayşegül Uysal (Turkey)

Oral presentations

T-2 toxin disrupts sertoli cell barrier via changes in tight and adherent junctional proteins in SerW3 cells
Elif Karacaoğlu, Güldeniz Selmanoğlu (Turkey)

Nesfatin-1 protects against torsion-induced testicular oxidative injury in rats
Sevil Arabacı Tamer, Alper Yıldırım, M. Kutay Köroğlu, Özge Dağdeviren Çevik, Feriha Ercan, Berrak Ç. Yeğen (Turkey)

Histological examination of the effect of {lycium barbarum} (Goji Berry) on testis and epididymis of acrylamide treated young male rats
Havva İmran Özdemir, Aysel Kükner (Turkey)

Protective effects of melatonin on ovarian structures of rats exposed to environmental toxic agent 2,3,7,8-tetrachlorodibenzo-p-dioksin (TCDD)
Semir Gül, Mehmet Gül, Birgül Yiğitcan (Turkey)

Investigation of the effects of vitamin D treatment on the uterine structural changes in the experimental model with polycystic ovary syndrome: an ultrastructural and immunohistochemical study
Yurdun Kuyucu, Latife Seyran Çelik, Ebru Dündar Yenilmez, Abdullah Tuli, Ufuk Özgü Mete (Turkey)

HSP 70 Histological examination of the effect of {lycium barbarum} (Goji Berry) on testis and epididymis of acrylamide treated young male rats
Bülent Celpkulu, Mete Köksal, Halil Çiftçi, Fuat Dilmeç (Turkey)

Morphology, morphometric and biochemical parameters changes in the adult rat ovarium following continuous 900-megahertz electromagnetic field applied in middle and late-adolescence
Derya Özturk Okatan, Ersan Odacı (Turkey)

S-19
Advances in Image Analysis
Chairs: Nurhan Özlü (Turkey) & Çağdaş Son (Turkey)

Nurhan Özlü (Turkey) (Invited Speaker)
Proteomic analysis of Epithelial Mesenchymal Changes

Çağdaş Son (Turkey) (Invited Speaker)
Applications of Föster Resonance Energy Transfer and Split EGFP Techniques at Protein-protein Interaction Studies

Oral presentation

Effect of Systemic Magnesium Sulfate on Retina in Neonatal Rats with Hypoxic Ischemic Encephalopathy
Serhat Imamoğlu, Ebru Yalın Imamoğlu, Serkan Erdenöz, Lorina Haziri, Yağız Özdağ, Alev Cumbul, Ünal Uslu, Şamil Aktaş, Gökhan Pekel, Mehmet Şahin Sevim, Mustafa Nuri Elçioğlu, Fahri Ovalı (Turkey)

S-20
Cancer Biology-II
Chairs: Ayhan Bilir (Turkey) & Gamze Tanrıöver (Turkey)

Ayhan Bilir (Turkey) (Invited Speaker)
The Autophagıc Activity of LICL on Different Tumor Cell Lines using Electron Microscopy

Oral presentations

Effects of paclitaxel, bevacizumab and metformin on PI3K/AKT pathway and angiogenesis in MDA-MB 231 breast cancer cell line
Fatma Fırat, Elgin Turkoz Uluer, Sevinç Inan (Turkey)

The Evaluation of the Distribution of CD133, CXCR1 and the tumor associated macrophages in different molecular subtypes of the breast cancer
Can Ilgın, Erdem Çomut, Çağlar Sarıgül, Selçuk Korkmaz, Enver Vardar, Sevda Fatma Müftüoğlu (Turkey)

Loss of histone H4K20 trimethylation predicts poor prognosis in bladder cancer
Nuray Varol, Cem Karaosmanoglu (Turkey)

Association between CAT C-262T polymorphism and CAT enzyme activity in patients with leukemia
Nazan Eras, Anıl Tombak, Naci Tiftik, Mehmet Berköz, Gözde Türköz, Etem Akbaş (Turkey)

Adjuvant therapeutic effect of cold atmospheric plasma on endometrium cancer cells
Işıl Aydemir, Utku Kürşat Ercan, Tülay Oludağ Mete, Sevinç Inan, Mehmet Ibrahim Tuğlu (Turkey)

Label-free investigation of cancer cell behavior using quantitative phase imaging
Vratislav Kostal, Jan Balvan, Michal Masarik (Czech Republic)

The effects of atmospheric plasma and oleocanthal on cancer cell migration
Işıl Aydemir, Utku Kürşat Ercan, Pınar Kılıçaslan Sönmez, Mesut Mete, Mehmet Ibrahim Tuğlu (Turkey)

13:00 – 14:00 CLOSING CEREMONY & FAREWELL PARTY

15:00 EXCURSION


Antalya
ICHC 2017


IFSHC

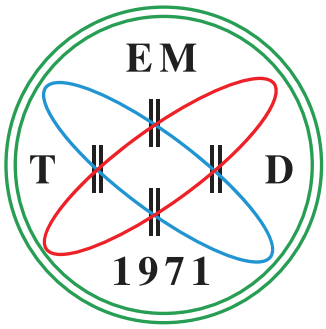
EM
T
D
1971

David Glick Lecture

Syndecans: receptors with signalling functions and roles cell adhesion and disease

John R. Couchman

University of Copenhagen, Denmark

Over 30 years ago, evidence accumulated that cell surface proteoglycans, some with hydrophobic properties, were involved in cell adhesion to extracellular matrix. Eventually, four members of the syndecan family of transmembrane proteoglycans were characterized, but their modes of action remained elusive. We have utilized a combination of imaging, immunochemistry, molecular and structural biology to address this question. Ligands for the syndecans can bind either their heparan sulphate polysaccharide chains, or the external portion of the core protein. Signaling and intracellular interactions are complex, but can be resolved into three parts. For example, syndecan-4 interacts with actin-associated proteins, protein kinase C and PDZ proteins. Interactions with α-actinin are essential for cytoskeletal organization, while signaling through protein kinase C impacts the activity of small G proteins of the Rho family, as well as regulating the gating of ion channels belonging to the TRPC (transient receptor potential canonical) group. In turn, therefore, syndecans regulate intracellular calcium levels, with impact on adhesion and migration. PDZ protein interactions regulate the trafficking of syndecans and may be essential in exosome biology. Finally, dysregulation of syndecan expression accompanies many diseases, including some tumours, cardiovascular disease and fibrosis.

Keynote Lecture

What's new in histochemistry and cytochemistry

Cornelis J.F. Van Noorden
Department of Medical Biology Academic Medical Center at the University of Amsterdam

Since Gomori stained activity of phosphatase in tissue sections in the 1930s, histochemistry and cytochemistry (H&C) developed into true disciplines that cannot be done without in science. Especially, in the second half of last century, tremendous progress was achieved in specificity, sensitivity and precision of localization of H&C methods. H&C can be defined as the disciplines that localize specific compounds, such as a specific sequence of DNA or RNA using in situ hybridization, a specific protein using immunoH&C or a product of activity of a specific enzyme using enzyme H&C. The latter method was developed by Gomori to visualize phosphatase activity in tissue sections or cell preparations, respectively, and this was in fact the initiation of H&C .
Especially immunoH&C has become indispensable for microscopic imaging, flow cytometry and cell sorting on the basis of fluorescent or coloured staining of one or more specific proteins in tissue or cell samples. Besides, in situ hybridization has become a valuable technology for the staining of specific sequences of DNA (e.g. DNA of viruses in a human tissue) or RNA (idem of RNA viruses or mRNAs to visualize where in a tissue or in which types of cells a specific gene is expressed). The third major approach, enzyme H&C or metabolic mapping1,2, that visualizes the product of a specific enzyme reaction as a fluorescent or coloured end product, became almost obsolete in the last 2 decades of last century. Metabolism was considered old fashioned in that time. How did this opinion change in the beginning of this century by the awareness that metabolism is very much involved in major complex diseases such as cancer and diabetes. This awareness initiated studies that targeted therapeutically metabolic pathways that are crucial for diseased tissue or cells. For example, specific mutations in genes encoding for enzymes such isocitrate dehydrogenase 1 and 2 are important steps in the development of a number of types of cancer such as glioma (primary brain tumors), acute myeloid leukemia, cholangiocarcinoma (tumors of bile ducts) or chondrosarcoma (tumors of cartilage)3. Metabolic mapping plays an important role in the search for therapies of types of cancer that have this mutation4. It is only one example of metabolic mapping where it has experienced a revival in the present century showing its new role in H&C.
The other major development is 3D histochemistry. Histochemistry has always been performed on thin tissue sections, but since the group of Deisseroth published their Clarity method to look through brain, 3D histochemistry has become the talk of the scientific world5. The principles of 3D histochemistry are clearing of the tissue, fluorescence labelling of specific proteins or structures, and visualization of the entire organs or tissue sample using confocal microscopy or light-sheet microscopy. Basically, two approaches exist for clearing of organs or tissue samples. The first one is removal of lipids of cell membranes from the organ or tissue. The lipids cause the opaqueness of tissues and removal of the lipids renders tissues transparent or clear which is the principle of Clarity. The other clearing method is based on matching the refractive index of the tissue sample and the solution in which the tissue sample is embedded . This method works for tissues that contain significant amounts of extracellular matrix (ECM)6. The central nervous system hardly contains ECM but large amounts of cell membranes and this makes Clarity ideal for brain but not for tissues that contain considerable amounts of ECM. These tissues can be cleared in solutions that have a similar refractive index such as in iDISCO and BABB methods6. The group of Erturk recently showed that an entire rat can be cleared using iDISCO methodology and fluorescence imaging can be performed in 3D in the intact animal7. Moreover, iDISCO and BABB can also be used to clear human tissues6, because perfusion of the tissue is not needed as is the case with Clarity. Therefore, Clarity can only be applied to experimental animals. The advantages of 3D histochemistry are enormous as molecular and cellular interactions can be studied directly in 3D instead of indirectly using reconstructions on the basis of images of large amounts of serial sections.
These developments in H&C in combination with the rapid developments in microscopy and nanoscopy make imaging of tissues and cells increasingly important tools in the life sciences.

Van Noorden CJF (2010) Imaging enzymes at work: Metabolic mapping by enzyme histochemistry. J Histochem Cytochem 58:481-497
Van Noorden CJF (2014) Metabolic mapping by (quantitative) enzyme histochemistry. Pathobiology of Human Disease: A Dynamic Encyclopedia of Disease Mechanisms, pp 3760-3774
Molenaar RJ et al (2014) The driver and passenger effects of isocitrate dehydrogenase 1 and 2 mutations in oncogenesis and survival prolongation. Biochim Biophys Acta 1846:326-341
Molenaar RJ et al (2015) Radioprotection of IDH1-mutated cancer cells by the IDH1-mutant inhibitor AGI-5198. Cancer Res 75:4790-4802
Chung K et al. (2013) Structural and molecular interrogation of intact biological systems. Nature 497:332-337
Azaripour A et al. (2016) A survey of clearing techniques for 3D imaging of tissues with special reference to connective tissue. Progr Histochem Cytochem 51:9-23
Pan C et al. (2016) Shrinkage-mediated imaging of entire organs and organisms using uDISCO. Nat Methods 13:859-867

Plenary Lectures

Single Molecule Localization Microscopy of Nuclear Genome Nanostructure

Christoph Cremer[1,2,3]
[1]Institute of Molecular Biology (IMB), D-55128 Mainz/Germany;
[2]Institute for Pharmacy and Molecular Biotechnology (IPMB), University Heidelberg & Kirchhoff-Institute for Physics (KIP), D-69120 Heidelberg/Germany;
[3]Department of Physics, University Mainz (JGU), D-55128 Mainz/Germany

The human genome has been decoded, but we are still far from understanding the regulation of all gene activities. A largely unexplained role in these regulatory mechanisms is played by the spatial organisation of the genome in the cell nucleus which has far-reaching functional consequences for gene regulation. Until recently, it appeared to be impossible to study this problem on the nanoscale by light microscopy. However, novel developments in optical imaging technology have radically surpassed the limited resolution of conventional far-field fluorescence microscopy (ca. 200 nm). These limits have been overcome by various super-resolution fluorescence microscopy (SRM) methods, such as Stimulated Emission Depletion (STED), Photoactivated Localization Microscopy (PALM), Structured Illumination Microscopy (SIM), or Stochastic Optical Reconstruction Microscopy (STORM)1. Here we report on a complementary SRM approach to study nuclear genome structure at the single cell/single molecule level, Spectral Precision Distance/Position Determination Microscopy (SPDM). SPDM, a variant of localization microscopy, makes use of conventional fluorescent proteins or single standard organic fluorophores in combination with standard or appropriately modified specimen preparation conditions, allowing to use the same laser frequency for both photoswitching and fluorescence read out2. Presently, this approach allows us to optically resolve nuclear structures in individual cells down to few tens of nanometer, and to perform quantitative analyses of individual small chromatin domains; of the nanoscale distribution of histones, chromatin remodeling proteins, and transcription, splicing and repair related factors. In addition, it has become possible to combine localization microscopy (SPDM) of nuclear DNA distribution, positioning up to around one million of individual DNA-bound fluorophore signals in an optical section within a 3D intact cell nucleus, with simultaneous measurements of the spatial positions of individual epigenetic histone marker molecules. The experimental results support recent models of functional nuclear nanostructure3. As a translational application, using dual-color SPDM, it became possible to monitor in mouse cardiomyocyte cells quantitatively the effects of ischemia conditions on the chromatin nanostructure (DNA)4,5. These novel "molecular optics" approaches open an avenue to study the nuclear landscape directly on the individual cell level at unprecedented optical and structural resolution.

1C. Cremer, B.R. Masters (2013) Resolution enhancement techniques in microscopy.Eur. Phys. J. H, Eur. Phys. J. H 38: 281–344. 2C. Cremer et al. (2011) Superresolution Imaging of Biological Nanostructures by Spectral Precision Distance Microscopy (SPDM), Biotechnology Journal 6: 1037 – 1051. 3T. Cremer et al. (2015) The 4D nucleome: Evidence for a dynamic nuclear landscape based on coaligned active and inactive nuclear compartments. FEBS LettersFEBS Letters 589: 2931–2943. 4I.Kirmes et al. (2015) A transient ischemic environment induces reversible compaction of chromatin. Genome Biology 16:246. 5A.Szczurek et al. (2017) Imaging chromatin nanostructure with binding-activated localisation microscopy based on DNA structure fluctuations. Nucleic Acids Research 2017, 1–11.doi: 10.1093/nar/gkw1301.

Keywords: Single Molecule, Localization, Microscopy of Nuclear Genome Nanostructure

The Dialog Between Biomaterials and Cells

Vasıf Hasırcı
BIOMATEN, METU Center of Excellence in Biomaterials and Tissue Engineering, and Dept. of Biological Sciences, Ankara, Turkey

The interactions between the cells and the artificial substrates they are deposited on involve constant mobility and feeling of the cell microenvironment. The structural and functional macromolecules constituting the extracellular matrix are a source of complex chemical and physical signals that guide cell morphology and fate. The deformability of the cells is defined by their phenotype, level of differentiation and also the of state of health and the final form they take is very much dependent on the topography and chemistry of their environment. Over the last decade we created a large number of micropatterned platforms with different chemistry, spacing and systematically varied feature organization to induce morphological changes in the cells and then later on the nuclei. As a result, certain clues about the cell-substrate relations have been obtained.

Keywords: biomaterial, substrate surface, cell, interaction, guidance, deformation

Correlative Light and Electron Microscopy in Cell Biology

Bruno M Humbel[1], Céline Loussert Fonta[3], Caroline Kizilyaprak[1], Heinz Schwarz[2], Jean Daraspe[1], Willy Blanchard[1]

[1]Electron Microscopy Facility, University of Lausanne, Lausanne, Switzerland

[2]Max-Planck-Institute for Developmental Biology, Tuebingen, Germany

[3]Nestle Research Center, Lausanne, Switzerland

In recent years correlative microscopy, combining the power and advantages of light and electron microscopy, has become an important tool for biomedical research.
Light microscopy has the advantage of easily searching large areas, even volumes, for the cells of interest, e.g., a special cell type in tissue, astrocytes in brain2 or for cells that have been modified either by transfections or by RNAi in a large population of non-modified cells. Also on thin sections, the low magnification of light microscopy and therefore ease of searching large areas are very beneficial to speed-up the analysis of rare events3. The predominant disadvantage of this technique, however, is that only the fluorescently labelled structures can be imaged in relation to each other.
Electron microscopy reveals the cellular ultrastructure a high resolution and individual organelles, even large protein polymers like cytoskeletal filaments or ribosomes can unequivocally identified. Proteins of interest can be labelled with colloidal gold. Searching for a few gold particles within a few cells of a large tissue, however, is very cumbersome and can be extremely time consuming if not impossible.
Seen the advantages of light and electron microscopy suggests that the optimal approach is to combine both techniques for cell biology research. Localisation of rare cellular events are followed and identified by (fluorescence) light microscopy, the high resolution data and fine localisation to cellular substructures are done by electron microscopy.
In this presentation we will describe the approach we have chosen to follow the cell(s) of interest from sampling the tissue until the analysis by electron microscopy4.

1Tsien, R.Y., Annu Rev Biochem 67 (1998). 509-544.
2Loussert Fonta, C., et al., J Struct Biol 189 (2015). 53-61.
3Schwarz, H. and B.M. Humbel, Methods Mol Biol 1117 (2014). 559-592.
4Loussert Fonta, C. and B.M. Humbel, Arch Biochem Biophys 581 (2015). 98-110.

Keywords: correlative microscopy, electron microscopy, light microscopy

3D+time imaging data and image analysis for the reconstruction of multilevel dynamics in animal morphogenesis

Nadine Peyriéras
Head of the BioEmergences laboratory CNRS-USR3695, Gif-sur-Yvette, France

We approach the understanding of Deuterostome early embryogenesis through the quantitative analysis and biomechanical modeling of cell dynamics from multiscale in vivo imaging data. The automated reconstruction of the cell lineage tree, annotated with nucleus and membrane segmentation, provides measurements for cell behavior: displacement, division, shape and contact changes. This quantitative data is used to derive statistical models for key parameters and calculate descriptors for tissue deformation. Confronting numerical simulations derived from multi-agent based biomechanical models with empirical measurements extracted from the reconstructed digital specimens is the basis for testing biological hypotheses. Further correlating cell behavior, tissue biomechanics and biochemical activities by comparing the patterns revealed by cell fate, kinematic descriptors or gene expression, is a step toward the integration of multi-level dynamics underlying morphogenetic processes.

Nuclear lipids contribute to intranuclear order and efficient DNA transcription

Pavel Hozak
Biology of the Cell Nucleus, Institute of Molecular Genetics ASCR, Prague,

Phosphatidylinositol 4,5-bisphosphate (PIP2) functions in the cell nucleus as a regulator involved in chromatin remodelling, transcription, and splicing. Since its involvement in RNA polymerase II (Pol II) transcription is still little understood, we studied the role of nuclear PIP2 in the organization of Pol II transcription complexes. We show that nuclear PIP2 associates with Pol II, transcriptional factors, nascent transcripts, and NM1 at the periphery of PIP2 islets. Integrity of PIP2 islets as well as the interaction of PIP2 with NM1 are necessary for Pol II transcription. We demonstrate that the transcriptionally active foci are preferentially positioned on the surface of PIP2 islets. We show that PIP2 is a major component of PIP2 islets, while RNA, ceramide and cholesterol constitute the minor part of their periphery. We suggest that PIP2 islets provide a platform for the proper arrangement of the complexes involved in Pol II transcription. We hypothesize that PIP2 islets, due to their heterogeneous multi-component nature, have a role in the spatial formation and maintenance of transcription factories and they thus participate in nuclear organization.
This work was supported by MEYS CR (LM2015062), GACR (GA15-08835Y), TACR (TE01020118)[b3] .

Keywords: cell nucleus, DNA transcription, phosphoinositides, lipids

Invited Speakers

[Epigenetics & molecular cytogenetics]

Distinct 3D nuclear topography of active and inactive regulatory sequences studied with super-resolution fluorescence microscopy

Marion Cremer[1], Volker J. Schmid[2], Felix Kraus[1], Yolanda Markaki[1], Andreas Maiser[1], Heinrich Leonhardt[1], Sam John[3], John Stamatoyannopoulos[3], Thomas Cremer[1]

[1]Department Biology II, Biocenter, Ludwig Maximilians University (LMU), Martinsried, Germany
[2]Institute of Statistics, LMU Munich, Munich, Germany
[3]Departments of Genome Sciences and Medicine, University of Washington, Seattle, WA 98195, USA

We describe the nuclear topography of transcription regulatory elements (TREs) in two human cell lines employing 3D-fluorescence in situ hybridization (3D-FISH), 3D structured illumination microscopy (3D-SIM) and a novel tool that enables quantitative 3D mapping of DNA targets on chromatin compaction defined nuclear landscapes. DNA probe sets of different complexity are targeted to sites harboring either active TREs identified by their DNAse I hypersensitivity (DHS+) or inactive TREs, which lack hypersensitivity (DHS-). The results of our initial study fit well within a recently proposed model for a functional nuclear organization, based on co-aligned active and inactive nuclear compartments, called the ANC-INC network model (Cremer et al., 2015. FEBS Letters 589). According to this model, chromatin domain clusters (CDCs) constitute the basic subunits of chromosome territories. CDCs pervade the nuclear space in a network-like manner and are organized as shell-like structures with layers of different chromatin compaction levels. The compacted inner core of CDCs represents the inactive nuclear compartment (INC) while active domains with decondensed chromatin form the peripheral layer of CDCs, named the perichromatin region (PR) which represents the nuclear compartment where transcription occurs. The PR lines the interchromatin compartment (IC), a contiguous channel system, which is connected to nuclear pores, permeates between CDCs and harbors nuclear bodies required for functions occurring within the PR. IC and PR together are therefore considered as the active nuclear compartment (ANC). We demonstrate that DNA segments harboring active TREs (DHS+) are highly significantly enriched within the ANC while larger segments lacking active TREs (DHS-) are enriched in the INC, suggesting positional changes of TREs between ANC and INC depending on their functional state.
From the methodological side issues of chromatin preservation after 3D-FISH experiments recorded at the level of super-resolution microscopy will be addressed in the talk.

Keywords: transcription regulatory sequences (TRE), DNAse I hypersensitive sites, super-resolution microscopy, chromatin domain, nuclear architecture, active / inactive nuclear compartment

[Epigenetics & molecular cytogenetics]

Epigenetic significance of higher-order chromatin organization in health and disease

Milena Georgieva[1], Dessislava Staneva[1], Bela Vasileva[1], Milena Draganova Filipova[3], Plamen Zagorchev[2], George Miloshev[1]

[1]Laboratory of Molecular Genetics, Institute of Molecular Biology, Bulgarian Academy of Sciences, Sofia, Bulgaria

[2]Faculty of Pharmacy, Department of Medical Physics, Biophysics and Mathematics, Medical University, Plovdiv, Bulgaria

[3]Department of Biology, Medical University, Plovdiv, Bulgaria

Introduction & Objectives: Chromatin is a DNA multi-protein complex in which the genome of eukaryotes is organized. Its main role is to store and protect the molecule of DNA, but also to genuinely modulate gene expression. Chromatin structure and dynamics are very important epigenetic mechanisms through which different genetic programs are performed in response to intrinsic and extrinsic environmental signals. This allows the cells and the organisms to response to these signals by changing its expression program. Multiple levels of chromatin organization exist and they have always been a challenge for the molecular biologists. The most elusive and yet sparsely known are the higher-order chromatin structures - the 30 nm fiber and structures above it like blobs and loops. In addition, chromatin is not static but is a very dynamic structure which through changes in its compaction controls gene expression.
Our main objective is to study in detail chromatin remodeling in response to different stress factors by which adaptation of cells and organisms to the surrounding environment is performed. Particularly we intend to reveal the main players in these processes and to spot crucial protein contacts within and with chromatin which are prerequisite for the process of remodeling.
Materials & Methods: Numerous different model organisms have been used in our studies including lower and higher eukaryotic cells, tissue biopsies and several laboratory animals. The methods used include standard molecular biology, biochemistry and biophysics methods like DNA and chromatin analyzing techniques, PCRs, techniques for genetic manipulations, Yeast two-hybrid system, differential scanning calorimetry, high resolution light and fluorescent microscopy and atomic force microscopy.
Results: We have shown that the linker histones are among the main players in chromatin remodelling. Especially, we have detected an important contact between the linker histones and chromatin remodelling complexes. Moreover, this contact proved to be crucial for chromatin remodelling in response to UV stress. By utilizing the developed by us Chromatin Comet Assay (ChCA) we have analyzed chromatin loop dynamics during ageing and stress adaptability of the cells. Using ChCA we have shown that chromatin loop structures have been abolished in mutants without the gene for the linker histone. Notably, these cells exhibited premature ageing phenotypes and inability to adequately react to stress.
Conclusions: Our results prove the significance of higher-order chromatin structure organization as a major epigenetic factor which controls the way cells react to stress. We have proved that cellular viability, adaptability and stress resistance are dependent on the proper chromatin organization, especially at its higher levels of compaction.
Keywords: epigenetics, higher-order chromatin organization, linker histones, Chromatin Comet Assay, ageing, cell death

[Cellular aging and cell death]

Viral infection and cell death

Zahra Zakeri
Department of Biology, Queens College and Graduate Center of the City University of New York, Flushing, NY, USA

Viruses employ several strategies to manipulate cell fate and maximize their replication potential during infection. Interacting specifically with cell death pathways allows virus to directly control the cell's decision to survive or die during infection. Here we present evidence on how dengue virus, the world's most lethal arthropod-borne virus, enhances its reproduction and persists in cells by activating autophagy, which protects infected cells. We have found that dengue 2 viruses induce autophagy and protect MDCK cells as well as several other types of cells from camptothecin (CPT), staurosporine (STS), and cycloheximide (CHX) and also from influenza virus (IAV) induced cell killing. This ability of dengue virus to induce autophagy and protection is dependent on activation of several stress and homeostatic pathways in the host cell. Viral gene NS4A is sufficient to induce both autophagy and protection alone. The induction of autophagy by whole virus and NS4A gene is conserved among the different serotypes. The increase of autophagy appears to be under regulation of ATM and ER stress signaling. These two stress pathways are linked, since experimental inhibition of ATM reduces the levels of the target proteins of PERK, and CHOP, after infection. The activation of ATM kinase and the specific UPR response PERK are also important to dengue-induced protection of cells. Induction of PERK highly correlates with a high flux of autophagy, along with increased viral infectivity, in infected MEF cells. Similar to the situation with Hepatitis C virus, production of ROS is dependent on PERK but only at later stages of infection and otherwise is independent of either ATM kinase or autophagy. This upsurge of ROS is nevertheless partially responsible for the maintenance of autophagy. Thus, high autophagy maintained by ATM and ER stress/ROS signaling, are potential targets for anti-dengue therapeutics.
Supported by NIH Grant # NIAID, NIH Program (1R15AI094351-01) to ZZ and the NIH NIGMS, MARC-USTAR grant T 34 GM070387

Keywords: virus,dengue,autophagy, apoptosis, reactive oxygen substances

[Cellular aging and cell death]

Relationship of cell death and aging

Richard A Lockshin
Department of Biological Sciences, St. John's University, Jamaica, NY USA; Department of Biology, Queens College of CUNY, Flushing, NY USA

Originally, interest in cell death and aging confused two topics, senescence of cells in culture and programmed cell death. Today we understand that senescence of cells, meaning their ceasing to divide, may play a role in the deterioration with age in the immune system but little else, and particularly not in the musculoskeletal and nervous systems. Programmed cell death is more complex. It usually takes the form of apoptosis, a caspase-driven process that is typically initiated in one of two ways: again, mostly in the immune system, interaction of a cell surface receptor with a cell- or invader-produced ligand results in the activation of caspase-8, which itself activates the effector caspases such as caspase-3. In most other situations, metabolic problems result in the release of cytochrome c and Apoptosis Initiating Factor from mitochondria, and these molecules in the cytoplasm activate caspase-9, which likewise activates the effector caspases. However many questions remain unanswered. First, although activation of caspase-3 is generally considered to be all-or-none and the irreversible step of programmed cell death, evidence is accumulating for activation of caspases in cells that do not die. The role of apoptosis-related caspases in non-lethal situations, and how they are limited, is completely unknown. Second, apoptosis is not the only means of death. In some situations autophagy and necroptosis are more prominent. Third and most important, autophagy and other signs of deterioration of cells indicate that, long before cells succumb, they are stressed by known and unknown factors. This is particularly true in the central nervous system where cells may be stressed for many years before they die. In these situations, blocking apoptosis will not protect them, for they will simply die through other means. It will be important for us to understand and recognize these stresses, and to recognize the thresholds at which the cells succumb to the stresses. In the long run, the pre-emptive approach of identifying and preventing or alleviating the stresses is likely to be our best approach to keeping the central nervous system, as well as other parts of the body, healthy into advanced age.

Keywords: apoptosis, autophagy, aging, neurons, caspase, immune system

[Cellular aging and cell death]

Mitochondrial division and cancer: causes and consequences

Jerry Edward Chipuk
Department of Oncological Sciences, Icahn School of Medicine at Mount Sinai, New York, USA

Mitochondrial division is essential for mitosis and metazoan development, but a mechanistic role in cancer biology remains unknown. Here, we examine the direct effects of oncogenic RAS G12V mediated cellular transformation on the mitochondrial dynamics machinery and observe a positive selection for dynamin related protein 1 (DRP1), a protein required for mitochondrial network division. Loss of DRP1 prevents RAS G12V -induced mitochondrial dysfunction, and renders cells resistant to transformation. Conversely, in human tumor cell lines with activating MAPK mutations, inhibition of these signals leads to robust mitochondrial network reprogramming initiated by DRP1 loss resulting in mitochondrial hyper-fusion and increased mitochondrial metabolism. These phenotypes are mechanistically linked by ERK1/2 phosphorylation of DRP1 serine 616; DRP1 S616 phosphorylation is sufficient to phenocopy transformation- induced mitochondrial dysfunction, and DRP1 S616 phosphorylation status dichotomizes BRAF Wt from BRAF V600E positive lesions. These findings implicate mitochondrial division and DRP1 as crucial regulators of transformation with unexpected leverage in chemotherapeutic success.

Keywords: Mitochondria, Cancer, Oncogenes, Therapy

[Cellular aging and cell death]

Phosphatidylserine sensing by TAM receptors regulates AKT-dependent chemo-resistance and PD-L1 expression

Raymond B Birge[1], Canan Kasikara[1], Sushil Kumar[1]
[1]Rutgers, Biomedical and Health Sciences, Department of Microbiology, Biochemistry and Molecular Genetics, New Jersey Medical School, 205 South Orange Ave, Newark, NJ 07103, USA

Abstract: Tyro3, Axl and Mertk (TAMs) are three homologous receptor tyrosine kinases that bind vitamin K- dependent endogenous ligands, Protein S (ProS1) and Growth arrest specific factor 6 (Gas6), and act as bridging molecules to promote PS-mediated clearance of apoptotic cells (efferocytosis). In recent years, it has become appreciated that TAMs are overexpressed in a vast array of tumor types, whereby the level of expression correlates with the tumor grade and the emergence of chemo and radio resistance to targeted therapeutics. TAMs have also been implicated as inhibitory receptors on infiltrating myeloid- derived cells in the tumor microenvironment that can suppress anti-tumor immunity. In addition to TAM overexpression, externalized PS is also concomitantly up-regulated in the tumor microenvironment, suggesting a PS/TAM receptor axis operates in the tumor microenvironment. Previously, we developed chimeric TAM reporter cell lines comprised of the extracellular domains of each TAM fused to the intracellular domains of the IFNR1, and reported that each TAM receptor had a unique pattern of activation by Gas6 or ProS1, as well as unique dependency for PS on apoptotic cells and PS liposomes for activity. In the present study, we leveraged this system to engineer epithelial cells that express WT TAMs, and show that while each TAM can promote PS-mediated efferocytosis, AKT-mediated chemo- resistance, as well as up-regulate the immune checkpoint inhibitory ligand PDL1 on tumor cells, Mertk is most dominant in the aforementioned pathways. Functionally, TAM-mediated efferocytosis could be partially blocked by PS targeted antibodies 11.31 and Annexin V, demonstrating the existing of a PS/PS- R (TAM-receptor)/PD- L1 axis that operates in epithelial cells that may drive immune escape in the tumor microenvironment. Finally, these studies provide a molecular rationale that anti-PS, anti-TAM, and anti- PD-L1 based therapeutics may have therapeutic merit as combinatorial checkpoint inhibitors in cancer.

Keywords: Phosphatidylserine, apoptosis, efferocytosis, oncogene, immune escape, cancer immunology

[Developmental and reproductive biology]

Blastocyst and the receptive endometrium: it takes two to tango

Ciler Celik Ozenci
Department of Histology and Embryology, Akdeniz University, Antalya, Turkey

Embryo implantation requires a reciprocal interaction between the blastocyst and endometrium and is associated with complex regulatory mechanisms. Members of the class O of forkhead box transcription factors (FOXO) have important roles in metabolism, cellular proliferation, stress resistance, and apoptosis. FOXO proteins have emerged as key mediators of cell fate because of their ability to regulate either pro-apoptotic genes or genes involved in differentiation, cell cycle arrest, oxidative defenses, and DNA repair. In recent years, FOXO's have been implicated as important players in the regulation of multiple physiological functions of reproduction and fertility. We have studied FoxO1, FoxO3, and FoxO4 expression patterns during normal mouse pregnancy and in various mouse models including pseudo-pregnancy, artificial decidualization. Our results will focus on our findings regarding the presence and possible regulation of FoxO transcription factors in pre-implantation embryos and during peri-implantation period in mice with respect to the embryo-endometrial cross talk. This study has been supported by TUBITAK with grant numbers 114S384 and 215S868..

Keywords: Embryo development, Mouse, FoxO transcription factors

[Glycobiology]

Serglycin proteoglycan: regulating apoptosis and protease-dependent epigenetic events

Fabio R Melo[1], Aida Paivandy[1], Gabriela Calounova[1], Benjamin R Sabari[2], Giuliano Zabucchi[3], C David Allis[2], Gunnar Pejler[4,1]
[1] Swedish University of Agricultural Sciences, Department of Anatomy, Physiology and Biochemistry, Uppsala, Sweden
[2] The Rockefeller University, Laboratory of Chromatin Biology and Epigenetics, New York, NY 10065, USA
[3] University of Trieste, Department of Life Sciences, Trieste, Italy
[4] Uppsala University, Department of Medical Biochemistry and Microbiology, Uppsala, Sweden

Abstract: Regulated histone proteolysis or "clipping" of N-terminal core histone tails to remove sites for post-translational modifications, has been suggested as a potential epigenetic mechanism. However, data supporting a biological relevance of this mechanism is limited. Here we show that serglycin proteoglycan bound to tryptase, a complex previously thought to be confined to the secretory granules of mast cells, truncates nucleosomal histone 3 (H3) and H2B and that its absence results in cell age-dependent accumulation of the epigenetic mark, lysine 5-acetylated H2B (H2BK5ac). Moreover, the accumulation of H2BK5ac in tryptase-deficient mast cells was accompanied by an induction of non-mast cell lineage genes and extensive morphological alterations, altogether suggesting a loss of cellular identity. These findings introduce histone clipping through a serglycin proteoglycan:tryptase axis as a novel epigenetic regulatory mechanism.

Keywords: serglycin, proteoglycans, tryptase, epigenetics, mast cells, histones

[Cancer biology]

Extracellular vesicles and their potential applications in cancer research

Agnes Kittel[1], Xabier Osteikoetxea[2], Barbara Sódar[2], Katalin Szabó Taylor[2], Edit Irén Buzás[2]

[1]Department of Pharmacology, Institute of Experimental Medicine, Hungarian Academy of Science, Budapest, Hungary

[2]Department of Genetics, Cell- and Immunobiology, Semmelweis University, Budapest, Hungary

Broad range of highly different molecules, from proteins to microRNAs or DNA can circulate stably in blood or in other body fluids in small extracellular vesicles.

These extracellular vesicles (EVs) are cell-derived submicron structures displaying the characteristics of their mother cells. In the last decade piles of evidence have been accumulated that their concentration and composition in the circulation are associated with different pathological conditions including tumors. In consequence circulating EVs from diseased tissues may serve as biomarkers for different types of cancer, too. Extracellular vesicles derived from cancer cells have been shown to contribute to horizontal cellular transformation, cellular reprogramming, functional alterations, even metastasis. It has been published that in case of malignancy EV number is correlated with tumor aggressivenes – metastasis or survival.

Identification of the tumour-derived material carried by EVs would be especially useful in rapidly developing types of cancers e.g. glioblastoma or in pancreatic cancers of poor prognosis where typically several years pass between the appearance of the non-metastatic founder cell and the initiating mutation.

Although EVs isolated from different body fluids would help the early and reliable detection, the more accurate diagnosis and they may prevent deaths from metastatic diseases, the reliable isolation of EVs from body fluids, especially from blood, has not been solved yet.

One of the main tasks of EVs research today is to develop a reliable protocol for the isolation and identification of circulating extracellular vesicles. Our work is a precious contribution to this important process.

Different types of extracellular vesicles released from a platelet. /modified from György et al, Cell. Mol. Life Sci. (2011)/

Keywords: extracellular vesicles, pancreatic cancer, biomarker

[Cancer biology]

Targeted toxin releasing stem cells for the treatment of brain tumors

Nihal KARAKAŞ
Istanbul Medipol University

In cancer research, targeted therapeutics including recombinant toxin fusions are promising therapeutic candidates for fightening against the malignancies. Mainly, recombinant toxin fusions are composed of two units: a binding region targeting a receptor on cancer cell surface and a linked functional toxin that can execute cell death. Binding region of a targeted toxin molecule can be either a ligand or an antibody fragment, and the killer part can be a bacterial or plant toxin. Since the targeted toxins are able to attach cancer cell surface selectively via their receptor recognizing partners and induce cell death via protein synthesis inhibition with their toxic components, they have been believed as the potential cell killers for various cancers.
Although the preclinical studies of toxin delivery resulted in highly good response to cancer therapy, unfortunately following clinical studies were faced with poor therapeutic outcomes (especially in solid tumors) caused by the limitations such as systemic toxicity, insufficient tissue penetration and short half life of chemotherapeutic agents. On the other hand, as a delivery strategy for targeted toxins, stem cells will be proper carriers as they have known with their migration capacity towards the tumor sites even including microdeposits and continuous delivery of therapeutics with onsite therapeutic fabrication. Furthermore, stem cells can be collected individually and engineered to secrete therapeutics which can enable their clinical translation from bench side to bed side. In line with this, we engineered lentiviral vectors bearing targeted toxins involving Pseudomonas exotoxin (PE) against the most malignant form of brain tumors, glioblastome multiform (GBM) (Shah lab., Harvard Medical School, Boston). These targeted toxins were directed towards a mutant form of interleukin-13 receptor (IL13Rα2) that selectively binds to cancer cells. Our results showed that human stem cells secreting targeted toxins have significant therapeutic effect on both GBM cell lines and patient derived GBM cells via inhibition of protein synthesis as a result of toxin action. Regression of GBM recurrence upon therapeutic stem cell delivery was monitored by bioluminescence imaging and thus, therapeutic stem cells increased long-term survival of mice. We reported for the first time that the stem cells secreting chimeric cytotoxins (IL13-PE) directed towards IL13Rα2 showed significant therapeutic efficacy with increased survival rates when implanted into the GBM tumor resection cavity in mice brains.
In conclusion, use of toxin releasing stem cells can be applied not only for brain tumors but also for other malignancies that meet with therapeutic limitations. Therefore, these preclinical studies will lead us to develop an onsite toxin delivery strategy by stem cells against several cancers that will eventually be compatible with clinical trials. While our study has a strong basis since it has efficient pre-clinical results against GBM brain tumor, it will may provide major contribution to the cancer therapies by determination of effectiveness on various cancers.

Keywords: Pseudomonas exotoxin, stem cells, cancer
Ref. [Stuckey DW*, Hingtgen S*, Karakas N, Rich B, Shah K. “Engineering toxin-resistant therapeutic stem cells to treat brain tumors”, Stem Cells, (Oct. 2014) *authors equally contributed.]

Keywords: Pseudomonas exotoxin, stem cells, cancer

[Calcified tissues, biomaterials and regenerative medicine]

Cell Gate of Osteoporosis

Petek Korkusuz
Hacettepe University, Facuty of Medicine, Department of Histology & Embryology, 06100 Ankara, Turkey

Bone mineral density (BMD) decrease, deterioration of histological architecture and increased risk for fragility fracture define osteoporosis (OP). Frequency of postmenopausal fractures is increasing. OP bone regeneration methods are therefore becoming more important to reduce the burden of treatment. OP degenerate and degrades bone, joint cartilage and skeletal muscle tissues. Skeletal muscles deteriorate after ovariectomy (OVX). This structural and functional loss is TNF-alpha pathway dependent and it partially recovers by TNF-alpha antagonist administration. Breakdown of the joint cartilage matrix and chondrocyte apoptosis occurs after OVX. Bisphosphonates increase bone mineralization and are clinically used in the treatment of OP. It also protects articular chondrocytes from degeneration and reduces apoptosis rates in OVX models. The BMP gateway is known to induce callus formation. Absorbable collagen sponges containing recombinant BMP-2 enhance bone repair in segmental tibial defects of OVX rats. The BMP-2 encoding mesenchymal stem cells (MSC) induce critical bone defect regeneration, which makes them prospering candidates for cellular therapy in OP. Boron containing nano hydroxyapatite (BnHAp) is produced, characterized, tested with MSCs and, found to improve BMD, bone volume and surface in OVX rat femurs. Advancements in stem cell and nano-biomaterial technology have lead current precision medicine strategy based on correcting impaired autogenous microenvironment. This lecture will address to the promises and the challenges in the field of regenerative medicine, related to the cell gates of OP.

Keywords: Osteoporosis, mesenchymal stem cell, bone, muscle, cartilage, nanobiomaterial

[Calcified tissues, biomaterials and regenerative medicine]

The effects of Physical Activity, Tissue Engineering and Mechanobiology on Articular Cartilage

Giuseppe Musumeci
Department of Biomedical and Biotechnological Sciences, Human Anatomy and Histology Section, School of Medicine, University of Catania, Via S. Sofia 87, 95125, Catania, Italy.

Introduction: Osteoarthritis (OA) is a degenerative disease of the articular cartilage, and it represents one of the most common causes of disability in the world. It leads to social, psychological and economic costs with financial consequences. Different OA treatments are usually considered in relation to the stage of the disease, such as surgical management, pharmacologic and non-pharmacologic treatments. In relation to mild OA, non-pharmacologic and behavioural treatments are recommended because they are less invasive and better tolerated by patients. All of these treatments used to manage OA are problematic, but solutions to these problems are on the horizon. Until today, there has been very little information regarding the physical treatment of this important disease to help medical doctors and patients in the choice of the best-adapted training to manage pain and disability limitations in patients with OA. The aim of this report is to find some answer in the management of OA through physical therapy treatment.
Materials and Methods: All data suggest that training exercise is considered an effective instrument for the treatment of mild OA. For this reason, we have chosen to study the effects of physical activity in an in vivo animal model of OA and the effects of mechanical loading on articular cartilage in an in vitro 3D model through the use of a bioreactor.
Results: These results demonstrated the cell signaling correlated to the mechanical loading, some aspects of the mechanobiology and the positive and negative effects of the mechanical loading on articular cartilage in both in vitro and in vivo model.
Conclusions: The benefits of the mechanical loading on articular cartilage have both short- and long-term effectiveness.

Keywords: Physical Activity, Tissue Engineering, Mechanobiology, Articular Cartilage, Morphology, Immunohistochemistry

Calcified tissues, biomaterials and regenerative medicine]

All the appropriate signals are necessary for engineering proper tissues: a prerequisite for successful tissue engineering

Yannis Missirlis
Mechanical Engineering and Aeronautics Department, University of Patras, Greece

The highly interdisciplinary area of tissue engineering, by its nature, involves several fields of research from basic materials development to stem cell handling to clinical applications.
While the need for quick applications is driven by necessity we are still far away from understanding how the hybrid system of material scaffolds cells biomolecules operates optimally either in vitro (in a bioreactor) or in vivo. In our effort to monitor some basic responses of particular cells to specific environments we have developed a bioreactor able to supply a multitude of mechanical cues, singly or in combination to endothelial cells.
In this presentation we will provide evidence of the importance of substrate stretching and frequency of stretching, of the shear rate of the flowing feeding medium on top of the cells, and of a simulated microgravity environment to the morphological adaptation of the cells and the rearrangement of its cytoskeletal proteins for each particular adaptation. It will also be shown how the combination of these signals correlates with specific gene expressions.

[Stem cells]

Current status and future of stem cell therapies - novel view on stem cells isolated from adult tissues

Mariusz Ratajczak[1]

[1]Stem Cell Institute at James Graham Brown Cancer Center, University of Louisville, Louisville, Kentucky, USA

[2]Department of Regenerative Medicine, Warsaw, Poland.

Regenerative medicine is searching for stem cells with the potential to differentiate into all three germ layers. A promising candidates are induced pluripotent stem cells, but unfortunately they bear the risk of teratoma formation and there are several concerns about their genomic instability. In meantime evidence accumulated that adult tissues harbor a population of very rare stem cells endowed with broad differentiation potential. These dormant, cells described as very small embryonic-like stem cells (VSELs) display several epiblast/germline markers what suggest their embryonic origin and developmental deposition in adult tissues. Recently, we found that VSELs do express several sex hormone (SexHs) receptors and respond in vivo by proliferation to SexHs stimulation. Moreover, since VSELs share several markers characteristic of migrating primordial germ cells (PGCs) and can be specified into long-term hematopoietic hematopoietic stem cells (LT-HSCs) and mesenchymal stem cells (MSCs), this observation sheds new light on the BM stem cell hierarchy. Nevertheless, in spite of the expression of pluripotent stem cell markers, changes in the epigenetic signature of some imprinted genes (e.g., by erasure of imprinting at the Igf-2–H19 locus) in VSELs are involved in their resistance to Igf-1/Igf-2 signaling and keep these cells in adult tissues in quiescent state. As reported in several emergency situations related to organ damage (e.g., heart infarct, stroke, skin burns), VSELs can be activated and mobilized into peripheral blood and in appropriate animal models contribute to tissue organ/regeneration. Interestingly, their number correlates with life span in mice and we noticed a positive effect of regular physical exercise and calorie restriction on ameliorating age-dependent depletion of VSELs from adult tissues. Recently, to bring these cells for potential clinical applications we developed an efficient ex vivo expansion strategy for these cells in chemically defined medium supplemented with follicle stimulating hormone (FSH), luteinizing hormone (LH) and bone morphogenic protein-4 (BMP-4), after activation of DNA methyltransferase 3L (DNMT3L) in these cells by exposure to valporic acid or nicotinamide. This chemically defined medium re-methylates erased parentally imprinted loci in VSELs, and allows for effective ex vivo expansion.

Keywords: Stem Cells, regenerative medicine, stem cell therapies, VSELs

[Stem cells]

Current status and future of stem cell therapies - novel view on stem cells isolated from adult tissues

Erdal Karaöz[1,2]
[1]Liv Hospital, Center for Regenerative Medicine and Stem Cell Research & Manufacturing (LivMedCell)
[2]İstinye University, Faculty of Medicine, Department of Histology&Embryology, İstanbul

Stem cells have the capability of self-renewal and differentiation into a wide range of cell types with various potential clinical and therapeutic applications. Stem cells are providing hope for many diseases that are currently in need of effective therapeutic methods, including neurodegenerative disorders like; stroke, amyotrophic lateral sclerosis, Alzheimer's disease, Parkinson's disease and as well as muscular dystrophy disorders like Duchenne Muscular Dystrophy and Facio-scapulo-humeral Muscular Dystrophy.
For this aim, numerous pre-clinical studies have been achieved and\or in progress on different types of stem cells including, induced pluripotent stem cell (IPS), embryonic stem cell (ESC) and neural stem cells. But there are some complications on the clinical utilization of these cells, due to the reason of ethical issues and especially because of the potential of formation of teratomas via IPSs and ESCs. For this reason, as we glance to the clinical trials ongoing nowadays, we see that MSCs are studied intensely on clinical applications.
Due to the ideal characteristics of these cells for regenerative medicine, clinical interest in the use of MSCs has increased significantly over the past few years. Therapies with MSCs have shown promising results on neurodegenerative and muscular degenerative diseases. In addition to their capability of regulating inflammation, they can promote other beneficial effects, such as neuronal growth, decreasing free radicals, reducing apoptosis and releasing different neurotrophic factors which can assist the endogenous regeneration of the injured region.
The results of clinical trials carried out for the treatment of various diseases, especially including neuro-muscular degenerative disorders, via application of MSCs derived from umblical cord and manufactured in our own GMP facility, will be introduced in this presentation.

Stem Cell Approaches Contributing to the Therapy of Ischemic Cardimyopathy

Alp Can
Department of Histology and Embryology, Ankara University School of Medicine, Ankara, Turkey

Over the past two decades, several stem cell transplantation attempts have been performed in patients with ischemic cardiomyopathy (ICM), using both autologous and allogeneic stem cells, numerous stem/progenitor cell types, and various strategies to administer the stem cells. Although many studies reported promising results, they are/were all phase 1 or 2 studies with appropriately small numbers of patients, thus their conclusions must therefore be considered preliminary rather than a true cell replacement therapy. A recent meta-analysis assessing the results of all randomized clinical trials of stem cell therapy for patients with acute myocardial infarction (AMI) was performed, demonstrating no net beneficial effects on outcomes, except for a small improvement in ejection fraction (EF). Given these results, a reassessment of the rationale for the use of stem cells in cardiovascular disease would be appropriate. Most patients with ICM have had one or more previous clinically-recognized or clinically silent myocardial infarctions (MIs), with the development of progressive remodeling and left ventricle (LV) dysfunction occurring consequent either to an initial large injury to the LV or to smaller, repeated injuries occurring over time. Another abnormality in ICM patients, which might provide an important therapeutic target, is the presence of dysfunctional but viable myocardium (hibernation region, HR). Patients with ICM invariably have usually extensive areas of myocardial scar (necrotic region, NR). Almost all patients with ICM had myocardial scar, as detected by cardiac magnetic resonance imaging and SPECT/PET imaging. Importantly, ICM patients had areas of myocardial dysfunction due not to scar, but to dysfunctional viable myocardium (HR). HR provides a potential target for cellular therapeutic interventions. If the dysfunctional tissue consists of viable rather than damaged myocardium, LV function can presumably be improved. The potential of any therapy, including stem cells, to improve outcomes in ICM is related not only to its effects on restoring function to HR, but also to its capacity to improve processes that contribute to progressive deterioration of LV structure and function. On the basis of this conceptual framework, this presentation discuss the potential of stem cells to exert beneficial effects in ICM by considering the overlap between pathways believed to contribute to disease progression (other than atherosclerotic disease of the large coronary arteries) and the known activities of stem cells that could favorably influence these pathways. (Project #: 0741-STZ-2014)

Keywords: mesenchymal stromal cell, myocardial ischemia, cellular therapy

[In vivo imaging]

Advances in non-invasive imaging: implications for pre-invasive clinical research

Ralph Meuwissen
Izmir International Biomedicine and Genome Institute (IBG-Izmir) Dokuz Eylul University

Development and application of molecular non-invasive imaging techniques are becoming essential parts of preclinical research. It enables us to adapt and refine current preclinical in vivo models. Moreover, better imaging techniques dramatically increase the capacity of these models to test efficacy and safety of new treatments such as molecular-targeted therapeutics. Different approaches like optical imagining by way of bioluminescence and fluorescence or MRI, SPECT/PET and ultrasound will be shortly discussed. All these non-invasive imagine techniques have each their own specific advantages and abilities to quantify spatio-temporal changes of (drug) targets at cellular and molecular level in living animals. Furthermore, combining the design and specific use of genetically engineered mouse models (GEMMs) models that closely resemble human diseases like cancer, substantially strengthened the options of in vivo visualization of cancer-related processes over time. In addition, new (nano)techniques for probe synthesis and labelling have created imaging probes with the potential for basic research, as well as for translational and clinical applications. This led to the creation of more sophisticated cancer models addressing cancer-related research questions. This presentation will therefore focus on imaging approaches in animal cancer models and how they improve their functional application in translational medicine. and how these can help the translation of new therapies into the clinic. For this the flexibility, potential and limitations of each single or combined non-invasive molecular imaging technique will be discussed with respect to its use in preclinical cancer research.

Keywords: Advances in non-invasive imaging, implications, pre-invasive, clinical research

[In vivo imaging]

In VivoTracking of Biologic Molecules: From the Cell to Small Laboratory Animals

Alper Özgür Karaçalioğlu
Gülhane Education and Research Hospital, Ankara

In VivoTracking of Biologic Molecules: From the Cell to Small Laboratory Animals
Preclinical imaging modalities have been important to observe changes, either at the organ, tissue, cell, or molecular level, in animals that respond to physiological or environmental changes. Autoradiography is a powerful, high resolution, quantitative molecular imaging technique using X- ray film, phosphor imaging plates, beta imaging systems, or photo-nuclear emulsion to visualize molecules or fragments of molecules that have been radioactively labeled, and it has been used to study the tissue distribution of radiolabeled xenobiotics in biological models. Hence the cell or tissue localization of a biologic molecule labeled with a radioactive agent which is introduced into a metabolic pathway, bound to a receptor or enzyme, or hybridized to a nucleic acid can be traced by the autoradiography. Autoradiography involves the close apposition of solid specimens containing radiolabeled substance to a detector layer, such as photographic emulsions, film, phosphor imaging plates, and direct nuclear imagers/counters and there are two basic types. While, macro-autoradiography provides localization of radioactivity at the organs, organ systems, and/or whole-body sections, micro-autoradiography provides localization of radioactivity at the cellular level. Quantitative whole-body autoradiography using phosphor imaging technology provides high resolution images of the spatial distribution and matching tissue concentrations of molecule-related radioactivity throughout the body of laboratory animals. Microautoradiography is another autoradiographic technique that qualitatively resolves the localization of radiolabeled compounds to the cellular level in a histological preparation. The basic technique remained largely qualitative due to the limited linear range of quantification offered by nuclear emulsion detection systems, recent technologies of digital imaging systems that use of scintillation gas detectors or phosphor imaging systems are also used to perform the autoradiography and they have made quantification of radioactivity in tissues possible. In addition, novel techniques such as matrix-assisted laser desorption imaging mass spectrometry (MALDI-MSI), and Secondary Ion Mass Spectrometric (SIMS) imaging can positively identify the molecular identity and image the spatial distribution of the parent drug and/or their metabolites in the same samples used for whole-body and micro-autoradiography
Keywords: Autoradiography, macroautoradiography, microautoradiography

[Correlating light and electronmicroscopy]

Correlative microscopy for analysis of multi-protein complexes by multiplexing FRET-EM microscopy and automated microfluidic platforms

Alberto Luini[1], Vincenzo Manuel Marzullo[1], Giuseppe Coppola[2], Stefania Torino[2], Mario Iodice[2]

[1]Institute of Protein Biochemistry, National Research Council, Naples, Italy

[2]Institute for Microelectronics and Microsystems, National Research Council, Naples, Italy

Correlative microscopy (CLEM) combines GFP-based video-light microscopy with electron microscopy (EM) to integrate information about the dynamics and the ultrastructure of cellular objects of interest. Evolved from a relatively simple beginning in our laboratory (Polishchuk et al., JCB, 2000) CLEM it is now a sophisticated technology that can address different types of biological problems. The assembly and disassembly of protein complexes plays a central role in all cell functions, hence understanding cells requires visualizing protein complexes with spatio-temporal precision. Current fluorescence microscopy can efficiently determine localization and dynamics of individual proteins, but its ability to visualize complexes is limited to binary interactions and relies on complex manipulations. Here we propose a combination of antibody (Fab)-based probes with microfluidic technology to overcome these limits. The key developments are innovative probes that allow detection of protein-protein interactions by both long-range FRET measurements and by EM (being developed), coupled with an automated microfluidic platform for multiple serial observation (multiplexing). Microfluidics-based multiplexing FRET-EM microscopy can be designed to focus on complexes associated with the activation of oncogenic signaling pathways or of gene regulatory networks in cancer and can significantly expand the range and power of diagnostic approaches applicable to cancer biopsies.

Keywords: protein complex, fret microscopy,correlating microscopy, cancer diagnosis

[Correlating light and electronmicroscopy]

Array Tomography for Small Asymmetric Samples: a Direct 3D Correlative Light and Electron Microscopy Method

Irina Kolotueva[1], Agnes Burel[2], Marie Therese Lavault[2], Clement Chevalier[3], Sylvain Prigent[3], Stephanie Dutertre[3], Thierry Guillaudeux[3], Helmut Gnaegi[4]

[1]EM Facility, University of Lausanne, Lausanne, Switzerland

[2]MRic-TEM, Biosit, University of Rennes 1, Rennes, France

[3]MRic-photonic, Biosit, University of Rennes 1, Rennes, France

[4]Diatome SA, Helmstrasse 1, 2560 Nidau, Switzerland

The principal challenges in performing CLEM studies on multicellular samples are the initial recognition of the Rolume of Interest (ROI), and the subsequent correlation between light and electron microscopy (EM) acquisitions. Rare cellular events or specific cells in tissue volume are difficult to localize using standard EM procedures. Various procedures have been developed to address questions in cells in a monolayer, however, few solutions exist for polarized multicellular samples. In addition to the need for precise correlation, small model organisms (C. elegans, Drosophila, zebrafish) must be properly prepared for EM. To recognize the structures that compose multicellular organisms at the EM level, a microscopist would need to have profound knowledge of anatomy on ultrastructural level.
The Array Tomography (AT) workflow that we have developed for C. elegans and Drosophila whole animal analysis optimizes multicellular TEM imaging sample preparation to permit the efficient localization of fluorescent-labeled protein in these multicellular organisms via ultra-thin sectioning. HPF-QFS is an effective sample preparation method that maintains fluorescence in embedded samples (Fig 1A). Our two-step flat embedding procedure simplifies the generation of 3D maps, which can then be used to orient analysis within the animal, and to target section analysis precisely to the ROI. In addition, we modified our sectioning knife and its boat to facilitate the acquisition of "ribbons" of consecutive sections directly on silicon wafers. This method helps to reduce the dimensionality based on the knowledge of body landmarks of model organisms, using a combination of anatomical cues and of engineered landmarks, recognizable in both LM and EM.
The samples are serially sectioned and transferred on silicon wafer support, using the AT approach (Fig 1B). The ability to retain fluorescence in the embedded sample facilitates the recognition of the ROI and the correlation process, as the localization of the fluorescence on the serially sectioned "ribbon" on the wafer simplifies the location of this region in SEM (Fig 1C and 1D). The correlation in 3D volume and the reconstruction of 2D data is more precise and direct, as correlated either with standard or super resolution LM methods. This makes structure recognition more accessible and efficient: rather than deeply analyzing all sectional data, representative sections are first visually scanned and after initial recognition of the ROI, sections containing it can be thoroughly analyzed.
Answering questions in cell and developmental biology rarely requires the detailed analysis of thousands of sections, but frequently requires the localization of a particular cell or intercellular organelle. Our strategy for surface screening to better reach the complex goal of ROI localization. We demonstrate how our targeted method can be used in asymmetric samples by showing examples from studies in C. elegans and Drosophila.

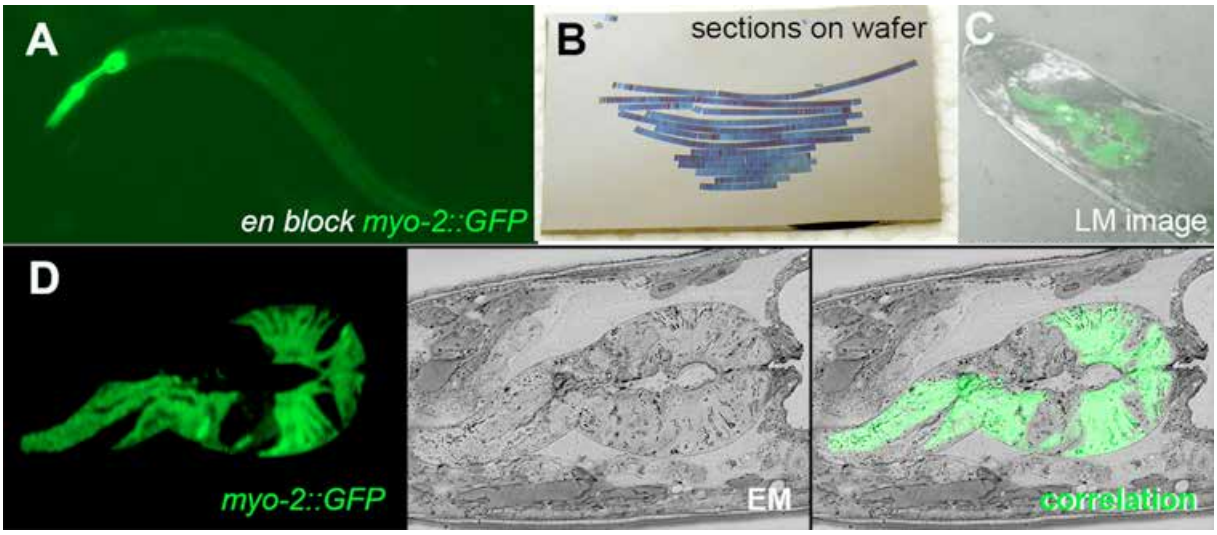

Figure 1. Array Tomography workflow
A. En bloc fluorescence of C. elegans pharyngeal muscles (green, GFP) after high pressure freezing and fast freeze substitution. B. AT sections on a silicon wafer. C. A representative section showing fluorescence, EM images, and their superposition.

Keywords: HPF-FS, CLEM, EM, Array Tomography, positional correlation

[Developmental and reproductive biology]

Building the inner ear: cellular dynamics of neurosensory progenitors during embryonic development

Sylvia Dyballa[1], Thierry Savy[2], Philipp Germann[3], Nadine Peyriéras[2], Cristina Pujades[1]
[1]Department of Experimental and Health Sciences, Universitat Pompeu Fabra, 08003 Barcelona, Spain
[2]Multilevel Dynamics in Morphogenesis Unit, USR3695 CNRS, 91190 Gif sur Yvette, France
[3]Systems Biology Unit, Center for Genomic Regulation, 08003 Barcelona, Spain

Reconstructing the lineage of cells is central to understanding how the wide diversity of cell types develops. Here, we provide the neurosensory lineage reconstruction of a complex sensory organ, the inner ear, by imaging zebrafish embryos in vivo over an extended timespan, combining cell tracing and cell fate marker expression over time. We deliver the first dynamic map of early neuronal and sensory progenitor pools in the whole otic vesicle. It highlights the remodeling of the neuronal progenitor domain upon neuroblast delamination, and reveals that the order and place of neuroblasts' delamination from the otic epithelium prefigure their position within the SAG. Sensory and non-sensory domains harbor different proliferative activity contributing distinctly to the overall growth of the structure. Therefore, the otic vesicle case exemplifies a generic morphogenetic process where spatial and temporal cues regulate cell fate and functional organization of the rudiment of the definitive organ.

[Pathology and clinical medicine]

How Many Types of Cell Death? The Crucial Role Of Morphology

Elisabetta Falcieri
Department of Biomolecular Sciences, Urbino University Carlo Bo, Urbino, Italy

Since 1980 cell death has been described, with continuously growing interest, in a variety of tissues and models. Its role in development, in adult tissue balance and in cell disorders or diseases appeared evident and represented the basis of numerous studies in mammal biology or pathology. After "necrosis", characterized by membrane disruption and organellar component swelling (A), a progressive attention was addressed to programmed cell death and to its intriguing patterns commonly referred as "apoptosis", showing a characteristic, actin-mediated, chromatin condensation (B,C), leading to the appearance of dense micronuclei (Salucci et al., 2015). Differently from necrosis, which is the cell response to lethal physical or chemical conditions, apoptosis is an active, genetically dependent mechanism. Both can be clearly identified by histochemical, ultrastructural or cytochemical approaches, and, in particular, apoptotic cell behavior, deeply involving nuclear domains, can be better highlighted by immunocytochemical methods. The possibility to correlate the DNA structural rearrangement -evident at ultrastructural level- to the identification of its cleavage sites -revealed by TUNEL reaction- allowed an important progress in apoptosis understanding (Burattini et al., 2009) (D).
Multiple technical approaches gave a fundamental contribution the study of less common, particular models. Cartilage cell death, widely described in human osteoarthrosis, even if affecting chondrocytes, cells surrounded by an extra-cellular matrix, displayed molecular and morphological characteristics relatively similar to those appearing in more usual models and "chondroptosis" (E, F) is now the object of growing interest (Battistelli et al., 2014).
The presence of cell death in a variety of muscle disorders stimulated us to study striated muscle tissue, a model even more particular, especially in the form of the differentiated, multinucleated myotube (G). The territorial influence of cytoplasm in experimental apoptotic response could be so demonstrated (H) (D' Emilio et al, 2010; Battistelli et al., 2015). The utilization of well known antioxidants or, more recently, new natural ones, obtained from olive oil, wine or other extracts (Burattini et al., 2013; Salucci et al., 2016) allowed us to further highlight apoptotic death as well as to suggest new molecules potentially counteracting apoptosis-related disorders.
In the last few years, "autophagy", an intriguing phenomenon characterized by progressive deletion of cell components, has been described with a growing interest. It seems to have a role in cell death progressing, also acting as a survival machinery. The possibility to associate the ultrastructural analysis to the immuno-cytochemical characterization of autophagosome components (I, L) allows to better highlight this mechanism.
I am grateful to drs. S.Burattini, M.Battistelli, S.Salucci, D.Curzi, F.Giordano and D.Burini for continuous, precious collaboration.

Keywords: necrosis, apoptosis, autophagy

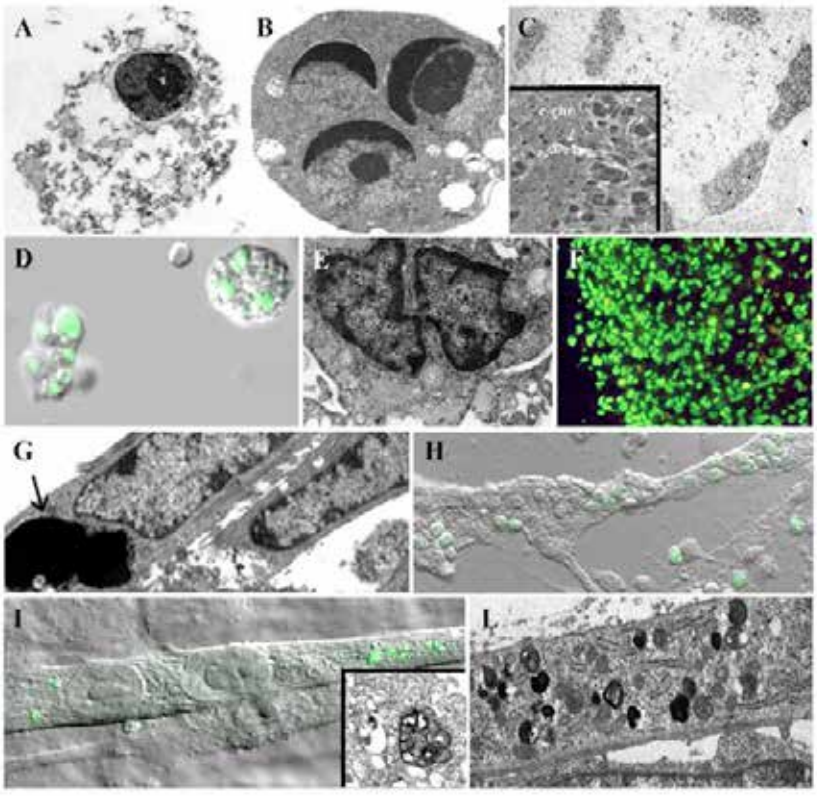

[Pathology and clinical medicine]

The 16 years follow-up results of cleft research in Latvian population

Mara Pilmane[1], Ilze Akota[2]

[1]Institute of anatomy and anthropology, Riga Stradins university, Riga, Latvia

[2]Institute of stomatology, Riga Stradins university, Riga, Latvia

Introduction and Objectives. Cleft lip palate (CLP) is common anomaly with still unknown morphopathogenesis. Thus, the aim of our work was the search for possible tissue factors responsible for the development of this malformation.
Materials and methods. More than 300 tissue biopsies were obtained during plastical surgery from more than 100 children. Children suffered by complete uni- or bilateral CLP and were grouped in accordance to their dentition age and type of CLP. Limited control material was obtained from upper lip frenuloplasty. By means of immunohistochemical method there were studied and analysed gene protein Msx1, IRF6, PAX9, Ryk9, VEGF, barx1, also growth factors, their receptors, remodelation/ regeneration factors, neuropeptides - FGF, FGF1R, EGFR, TGFβ, TGFβ3, MMP2, caspase, TIMP2, BMP2/4, OPG, VIP, SP, PGP 9.5, NGFR, Ki67, HoxB3, CD34, nestin immunoreactive structures. Results were evaluated semiquantitatively and by use of different statistical methods.
Results. TGFβ and TGFβ3R showed limited appearance into the soft, but not into the hard bone. MSX1 was absent in the bone, but marked epithelial cells especially in the mixed dentition age, when also numerous nestin-containing cells were observed. CD34 cells were detected mainly in blood vessel of children in primary dentition age. PAX9 and Ryk9 positive cells were seen in epithelium and connective tissue in tissue of both dentition age and different type of cleft. Part of children demonstrated long epithelial processes showing PAX9, Msx1, NGFR and HoxB3, but not confident Ki67 immunoreactivity that didn't correlate to the dentition age and/or type of cleft.
Commonly, CLP tissue showed increased expression of FGFR1, PGP9.5, CD34, and nestin, barx1 and Msx1 structures in primary dentition age, while NGF and NGFR appearance was decreased. CLP affected tissue of mixed dentition age displayed increase of bFGF, FGFR1, NGFR, PGP9.5, apoptosis, CD34, barx1, Ryk9 immunoreactive structures, but NGF was decreased. Factors like bFGF, FGFR1, PGP9.5, barx1 and apoptosis were increased in both dentition ages, while NGF and OPG decreased in CLP tissue without any correlation to the type of cleft and age. Some factors demonstrated variable distribution. So, NGFR increased in bilateral clefts, but TGFβ, TGFβ3, IRF6, BMP2/4 increased in uni-, bet decreased in bilateral clefts. MMP2/TIMP2 appearance possessed patterns of distribution.
Conclusions. CLP affected soft and hard tissue are able to express some factor for each other compensatory. Appearance of neuronal and mesenchymal primordial cells in CLP affected tissue depends on the dentition age. Oral epithelium is the dominating expression place for PAX9 and Ryk9 in CLP. Epithelial outgrowths positive for cellular differentiation and migration, but not proliferation markers seem to be tissue phenomenon developed by still unknown reasons. Commonly, there are limitations in expression of factors that do depend on the dentition age and/or type of cleft.

Keywords: immunocytochemistry, cleft, children

[Structure and function of the cell]

Heparan Sulfate Synthesis Enzymes are Distributed Across the Golgi Apparatus

Hinke A B Multhaupt
Biotech Research & Innovation Center, University of Copenhagen, Biocenter, 2200 Copenhagen N, Denmark

Heparan sulfate (HS) is present on a number of core proteins, distributed on cell surfaces, in basement membranes and extracellular matrices, or in intracellular granules. Moreover, heparan sulfate is essential for multicellular animal life. Of all post-translational modifications, substitution of core proteins with heparan sulfate glycosaminoglycans is perhaps the most complex. The chain is initiated by the successive transfer of one xylose, two galactose and a single uronic-acid residue to a serine residue to create a stem.

At this point if the heterodimeric EXT1/2 proteins transfer N-acetylglucosamine/ glucuronic-acid disaccharides, the chain becomes HS, while chondroitin synthases substitute N- acetylgalactosamine/glucuronic-acid disaccharides. The aim of this study is to map the fine distribution of the enzymes involved with HS chain assembly and modification. No information exists as to whether all are present in one large complex (the "heparanosome") or are distributed across the Golgi stacks. Confocal microscopy, Live Cell TIRF imaging and FRET, supported by biochemical analysis were used. Our data suggest that the enzymes are not present in a single entity. However, groups of synthesis and modifying enzymes are located together and interact with each other (e.g. EXT 1 and 2 heterodimers together with N- deacetylase/N-sulfotransferases). Furthermore, the location of complexes corresponds to the known processive nature of HS synthesis. Early modification steps appear to take place in the cis-Golgi, while our imaging data suggests that later modifications occur in the medial and trans-Golgi stacks. These results suggest that HS synthesis is indeed highly regulated but complex in terms of proteoglycan trafficking through the Golgi apparatus.

[Structure and function of the cell]

Septins as the fourth element of the cytoskeleton and a new substrate for microtubule severing enzyme p60-katanin

Arzu Karabay
Istanbul Technical University Molecular Biology-Biotechnology and Genetics Research Center, Turkey

p60-katanin, the small subunit of katanin protein, is an important protein being extensively studied. The C-terminal AAA (ATPases Associated with diverse cellular Activities) domain which has an ATPase activity that carries microtubule severing function, causes formation of short microtubule pieces from long microtubules. Microtubule severing is a very important cellular event which enables a rapid re-organization of microtubule network during cell division in the cells. Besides, microtubule severing takes important roles in the formation and branching of neuronal processes such as axons and dendrites.
Although p60-katanin is a popular protein that researchers widely work on, neither its functioning mechanisms nor its regulatory partners are clear enough. There are a few proteins identified so far that physically interact with p60-katanin. One of these proteins is the other subunit of katanin: p80-katanin. These two subunits exist as a heterodimer in the cells. Other identified regulatory proteins of p60-katanin are microtubule associated proteins such as Tau. However, none of its known regulatory partners was good enough in understanding the way of p60-katanin performs its function.
In identification of p60-katanin interacting proteins by using Yeast Two Hybrid screening system, we screened human brain cDNA library and identified 22 p60-katanin interacting candidates. Septin3, due its presence in high amount in pre-synaptic termini and having roles in synapse formation, axonal targeting and migration is chosen in this study to further investigate its interaction with p60-katanin. Since there remains an unsolved puzzle in the function of p60-katanin, our aim in this study was to analyze p60-katanin interacting protein Septin3 in detail and to reveal the interactions both in physical and functional manners and clarify the role of Septin3 on p60-katanin function both in mitotic cells and post-mitotic neurons.
Septin 3 is a novel member of the septin subfamily of GTPase domain proteins. The septin family consists of multiple genes and protein isoforms; in mammals, 13 septin genes encode for over 30 protein isoforms. Most Septin proteins are expressed in many tissues, but the Septin3 appears to be primarily expressed in brain. Septins are abundant in the central nervous system and are associated with many neurological diseases such as Parkinson's, Alzheimer's, Schizophrenia, and hereditary neuralgic amyotrophy. For instance, Septin2 Septin1, Septin4 was found to exist in neurofibrillary tangles. Moreover, it was also shown that Septin3 polymorphism may have a determinative role in the pathogenesis of Alzheimer's Disease.
Based on Tau's protective role on microtubules against p60-katanin, it is possible that Tau has a regulatory function in p60-katanin - Septin3 interactions and identification of Septin3 – p60-katanin and Septin3 – Tau interactions will help to determine the missing parts of the p60-katanin - Tau – Septin3 – Microtubule interaction puzzle, which is highly critical in neural differentiation and cytoskeleton based neurodegenerative disorders

Keywords: Septin, Katanin, Microtubule, Tau

[Techniques in Immunohistochemistry]

Mechanobiology of epithelia on native basement membranes - relevance for cancer cell invasion & clinics

M. Plodinec[1,2], P. Oertle[2], D. Assgeirson[2], W. Halfter[3], S. Eppenberger Castori[1], E.C. Obermann[1], A. Glentis[4], D. Matic Vignjevic[4], R.Y. Lim[2]
[1]Institute of Pathology, University Hospital of Basel, Basel, Switzerland,
[2]Biozentrum and the Swiss Nanoscience Institute, University of Basel, Basel, Switzerland,
[3]Eye Hospital, University Hospital Basel, Basel, Switzerland,
[4]CNRS, Institut Curie, PSL Research University, Paris, France

The onset of metastasis occurs when cancer cells invade and breach the basement membrane (BM) that provides mechanical support to epithelial tissues. Yet, it remains unclear what triggers cancer cells to breach the BM, and how 'triggered' cells breach the BM. We have established an in vitro assay using native BM interface for culturing epithelial cells. Using atomic force microscopy (AFM) with other high-resolution microscopies and TER (trans-epithelial resistance), we have correlated the mechanocellular attributes of the BM/epithelium interface to its biochemical and structural properties. We demonstrated that the internal limiting membrane (ILM) isolated from human retinas acts as a native substrate for culturing epithelial cells in terms of BM composition, architecture and stiffness. These are required to act jointly in order to achieve apico-basal polarity, tissue barrier formation and stiffness properties of the epithelial layer similarly to secretory epithelia in vivo. BMs also play a major role in tissue pathologies. For example, at the onset of malignancy and cancer progression in vivo, BM physically limits cancer cell invasion. It has been shown that cancer cells can perforate BM using proteolysis. However, the role of stromal cells in this process has not yet been resolved. Therefore, we examined if carcinoma-associated fibroblasts (CAFs) isolated from cancer patients promote cancer cell invasion through a BM. In the presence of CAFs, moderately invasive cancer cells by decreasing their stiffness are able to invade through native BM in a matrix metalloproteinase-independent manner. Using live imaging and atomic force microscopy, we could show that CAFs actively pull, stretch and soften the BM, forming gaps through which cancer cells can migrate. By exerting contractile forces, CAFs alter the organization and physical properties of native BM, making it permissive for cancer cell invasion. Finally, we propose that, in addition to proteolysis, mechanical interactions between CAFs and BM represent an alternative mechanism of BM breaching. Given the mechano-biological relevance, native BMs allow us to further understand how mechanosignaling occurs between the epithelia and the surrounding stromal layers at the BM interface both in physiological and pathological states.

[Techniques in immunohistochemistry]

An in vitro approach to understanding myelination and myelin disorders

Bilal Ersen Kerman
Istanbul Medipol University Histology and Embryology Department, Istanbul Turkey

Myelin facilitates neuronal electrical impulse propagation and provides trophic support to neurons by forming an isolating layer around axons. It is produced by specialized glial cells, oligodendrocytes in the central nervous system and Schwann cells in the peripheral nervous system. Improper development or loss of myelin, dysmyelination and demyelination respectively, occurs in many neurological disorders, such as multiple sclerosis, Pelizaeus–Merzbacher disease and other leukodystrophies, and as a consequence of spinal cord injury, leading to disruption of electrical impulse conductivity, atrophy of neurons, and permanent functional deficits. Dysmyelination and demyelination may be a direct consequence of glial and/or neuronal deficits or other cells such as the immune cells may cause and promote the injury. We developed an in vitro myelination model to complement the existing in vivo approaches. Through this model we have successfully observed myelin membrane wrapping the axons, explored genes with a potential to regulate myelination and modelled myelination disorders. I will share our results on each of these fronts.

Keywords: Myelin, oligodendrocyte, live imaging, multiple sclerosis,

[Neuroscience]

The axon initial segment: A novel site of neuronal dysfunction in multiple sclerosis?

Aysegul Dilsizoglu-Senol[1], Giulia Pinto[1], Maxime Beau[3], Vincent Guillemot[1], Christine Stadelmann[4], Jonas Ranscht[3], Boris Barbour[3], Catherine Lubetzk[i1, 2], Marc Davenne[1]
[1] Inserm U 1127, CNRS UMR 7225, Sorbonne Universités, UPMC Univ Paris 06 UMR S 1127, Institut du Cerveau et de la Moelle épinière, ICM, F- 75013, Paris, France
[2] AP-HP, Hôpital de la Pitié Salpêtrière, Paris, France.
[3] Ecole Normale Supérieure, Institut de Biologie de l'ENS (IBENS), Inserm U1024, CNRS UMR 8197, Paris 75005, France
[4] Institute of Neuropathology, University Medical Center Göttingen, 37075, Göttingen, Germany.

The axon initial segment (AIS) is the axonal domain just preceding the myelinated part of the axon and allows neurons to fulfill two of their main functions: first, it is the site where analog signals received from the neuron's somato-dendritic compartment are encoded into digital signals, which can be propagated along the axon to target cells. Indeed action potentials (APs) are generated at the AIS, due to the aggregation of voltage-gated sodium (Nav) and potassium (Kv) channels. Second, the AIS forms a barrier between somato-dendritic and axonal compartments, and thereby maintains the neuron's polarity, essential for its function in information transfer. The AIS is a plastic domain. Its length, position relative to the soma and its ion channels composition can be modified depending on physiological or pathological contexts, and such AIS modifications can have major impacts on neuronal function.
Multiple sclerosis (MS) is a chronic, inflammatory disease of the central nervous system characterized by demyelinating lesions, which leads to disorganization of nodes of Ranvier and failure in action potential propagation, responsible for clinical disabilities. Given strong similarities between AISs and nodes of Ranvier and the presence of auto-antibodies against AIS proteins found in sera from MS patients, AISs may well be also affected in MS. We thus decided to analyze AISs in both mouse models of MS and in tissue from MS patients. Results from these analyses will be presented.

[Neuroscience]

Vitamin D perspective in neurodegeneration and Alzheimer's disease: the genetic background and the cellular mechanisms

Erdinc Dursun, Duygu Gezen Ak, Selma Yılmazer
Istanbul University, Cerrahpasa Faculty of Medicine, Department of Medical Biology, Brain and Neurodegenerative Disorders Research Unit

Alzheimer's disease (AD) is the most common type of dementia in the elderly and is a progressive neurodegenerative disorder. Major hallmarks of AD type pathology include intracellular neurofibrillary tangles and extracellular amyloid plaque aggregations which cause alterations in neuronal calcium homeostasis, increase in oxidative stress, alteration in immune response and neurotrophic factor synthesis. These cellular changes in turn cause neurons losing their function and eventually lead them to death. These particular neurodegeneration processes in the affected areas of brain leads to dementia and a behavioral disorders and establish the AD type phenotype. Although still called as a vitamin, the vitamin D is secosteroid hormone that is produced over 750 million years on Earth and is synthesized by the certain enzymes in the bodies of the vertebrates. 1-25 dihydroxyvitamin D3 or 1-25 dihydroxycholecalciferol (1,25(OH)2D3) is the active form of vitamin D. Our studies in the last decade focused on the roles of vitamin D in brain, whether the genetic background of AD include the genes involved in vitamin D metabolism and what are the key mechanisms leading to neurodegeneration via vitamin D related cellular pathways. Our data in cultured neurons indicated that the calcium channels, neurotrophic factor synthesis and oxidative stress that are involved in AD type pathology can be primarily regulated by vitamin D and its pathways. In addition to these cellular changes the genetic biochemical data from our patients supported that the pathology of neurodegenerative disorders like AD involves not only vitamin D deficiency and vitamin D associated genes but also the inefficient utilization of vitamin D as we have defined the term "inefficient utilization of vitamin D" in the literature for the first time. Consequently, our studies indicated that AD might be interpreted as a result of a long-term hormonal imbalance in which the hormone is vitamin D, a secosteroid that has long been misnamed. These studies were supported by TUBITAK with project numbers 115S438, 214S586, 214S585 and 1111S200

Keywords: Alzheimer's disease, neurodegeneration, vitamin D, vitamin D deficiency

[Neuroscience]

Immunonohistochemical Assessment of Neuronal Activation in Neuroendocrine Systems

Özhan Eyigör
Department of Histology and Embryology, Uludag University Faculty of Medicine, Bursa, Turkey.

Endocrine regulation is one of the most important players in maintaining the homeostasis of the organism. Endocrine system is under the influence of neuroendocrine hormones and neuromodulatory peptides which are synthesized and secreted by neurons located mostly in the hypothalamus. These neurons are activated by external and/or internal stimuli and in response secrete their respective molecules. In addition to physiological and pharmacological tools to identify the neuronal activation, immunohistochemistry is also being used to locate the activated neurons in the hypothalamus. The transient expression of c-Fos protein following a stimulus has been considered as a marker of neuronal activation. In our laboratory we combine c-Fos immunohistochemistry with the immunohistochemistry for any neurohormone or neuropeptide and assess the expression of c-Fos in neuroendocrine neurons as the marker of activation. One approach we use is to administer different agents then locate and evaluate the activated neurons in response to these molecules. In this regard we conducted studies to show the effects of glutamatergic agonists on neuroendocrine neurons such as oxytocin, vazopressin, orexin or nesfatin. The results showed that these neurons are activated by glutamatergic stimuli. c-Fos immunohistochemistry can also be used to demonstrate the activation of neurons during a physiological state. Such experiments were performed in our laboratory in order to analyze the activation of GnRH neurons during the LH surge, orexin or vazopressin neurons after hyperosmotic states and nesfatin or neuronostatin neurons after refeeding. We also attempt to block the physiological activation of these neurons by administering glutamatergic antagonists and showed that the number of c-Fos-positive neurons is diminished, suggesting the physiological activation is blocked in part. The immunohistochemical assessment of neuronal activation can also be applied for behavioral studies. Studies are in preparation in our laboratory to assess the activation of nesfatin neurons after different stress applications. In addition to c-Fos expression, the presence of phosphorylated-CREB or phosphorylated-STAT proteins in neurons has also been considered as the marker of activation, which involves different intracellular pathways. All these marker proteins are located in the nuclei of the neurons which makes the bright field double immunohistochemistry possible, without needing immunofluorescence labeling. In this presentation, the advantages of immunohistochemistry for the demonstration of neuronal activation in the hypothalamus will be discussed by using examples from our laboratory as well as examples from the literature.
(Our studies cited in this presentation are supported in part by grants from TUBITAK, 104S286, 113S377)

Keywords: Neuronendocrine, c-fos, neuronal activation, immunohistochemistry

[Pathology and Clinical Medicine]

Rejection Pathology in Liver Transplantation

Hale Kırımlıoğlu

Univeristy of Acibadem, Department of Pathology, School of Medicine

Rejection Pathology In Liver Transplantation
Transplant rejection is a complex process in which a transplant recipient's immune system attacks the transplanted organ and tissue. Specific and acquired alloimmune response mediated by T cells cause to contact-dependent T cell cytotoxicity, granulocyte activation by either Th1 or Th2 derived cytokines, NK cell activation, alloantibody production and complement activation. Both cellular and antibody-mediated rejection (AMR) cause to rejection.
There are three types of rejection:
. Hyperacute rejection occurs within a few minutes after the transplant when the antigens are completely unmatched. This type of rejection is rare in liver transplantation.
. Acute cellular rejection may occur any time. Early acute rejection is common from the first week after the transplant to 3 months. Late acute rejection may have different histological appearances.
. Chronic rejection occurs when constant immune response against the new organ slowly damages the transplanted organ.
The Banff classification of liver allograft rejection, the diagnosis and grading acute and chronic cellular rejection was unified.
Histological assesments play an important role in the diagnosis and management of liver allograft rejection. Liver biopsy remains the gold standart for diagnosing acute and chronic rejection.
AMR is also important in early and late graft injury. The histologic diagnosis of AMR is difficult, immunohistochemical staining for C4d can be used as a marker for antibody-mediated damage.
Inflammation with the immunologic injury to bile duct epithelium and endothelium cause to histologic changes.
Main differential diagnoses are preservation/reperfusion injury, biliary obstruction, recurrent viral hepatitis, recurrent or Denovo autoimmune hepatitis, idiopathic post-transplant hepatitis, ischamic cholangiopathy. Especially the differantiation of rejection from recurrent hepatitis C remains difficult because of overlapping histologic features with rejection, both can ocur together.

[Advances in image analysis]

Proteomic Analysis of Epithelial Mesenchymal Transition

Nurhan Ozlu[1], Ozge Karayel[1], Cansu Uretmen Kagiali[1], Erdem Sanal[1], Nurcan Tuncbag[2]

[1]Koc University, Department of Molecular Biology and Genetics

[2]Middle East Technical University

Epithelial-Mesenchymal-Transition (EMT) plays an important role during carcinogenesis and tumor formation. Its major contribution to the tumor formation is through providing epithelial cells with the ability of invasion and metastasis. By this way, epithelial cells gain the capacity to disseminate from primary tumors to allow them to grow at a distant location. Cancer progression through the process of metastasis has been the focus of extensive research for years. However, the paradigms of the EMT process are less well understood. In this regard, examining the radical biochemical changes at both protein and post-translation modification levels during EMT are critically important to identify regulatory factors effecting EMT and metastatic behavior of carcinomas. In this study, we take advantage of the comparative proteomics and phosphoproteomics methods that we developed in our previous studies to comprehensively evaluate the biochemistry of a cell and its phosphorylation events as it undergoes EMT.

Keywords: cancer, proteomics, phosphoproteomics, cell biology, Epithelial-Mesenchymal-Transition

[Advances in image analysis]

Applications of Föster Resonance Energy Transfer and Split EGFP Techniques at Protein-protein Interaction Studies

Çağdaş Devrim Son
Middle East Technical University, Department of Biological Sciences, Ankara, TURKEY

G protein-coupled receptors (GPCRs) are membrane proteins that mediate physiological response to a diverse array of stimuli. In humans they mediate the action of hundreds of peptide hormones, sensory stimuli, odorants, neurotransmitters, and chemokines. GPCRs also are targets for ~40% of all currently marketed pharmaceuticals. These receptors have traditionally been thought to act as monomeric units. However, recent evidence suggests that GPCRs may form dimers as part of their normal trafficking and function. While the formation of GPCR dimers/oligomers has been reported to play important roles in regulating receptor expression, ligand binding, and second messenger activation, less is known about how GPCR dimers interact with G-proteins.
Adenosine 2A (A2A) and Dopamine 2 (D2) receptors are G-protein coupled receptors (GPCRs) known to dimerize in GABA containing neuron cells. These receptors have important roles in most psychiatric disorders such as schizophrenia, Parkinson disease and drug abuse illnesses. According to Gα subunit amino acid sequence homology, G proteins divided into four family Gs, Gi/Go, Gq/G11 and G12/G13. Some GPCRs can couple to only one type of G protein family. On the other hand many GPCRs couple to wide range of G-protein families. Overall, to investigate the combination of interaction between G proteins (Gs, Gi/Go, q11 and 12/13) and A2A, D2R, or A2A/D2 respectively, we performed Föster resonance energy transfer (FRET) and bimolecular fluorescence complementation (BiFC) assays, which have the advantage to analyze multiple protein-protein interaction in live cells using Confocal Microscope.

Keywords: GPCR, Dimerization, FRET, BiFc, G-protein

FRET

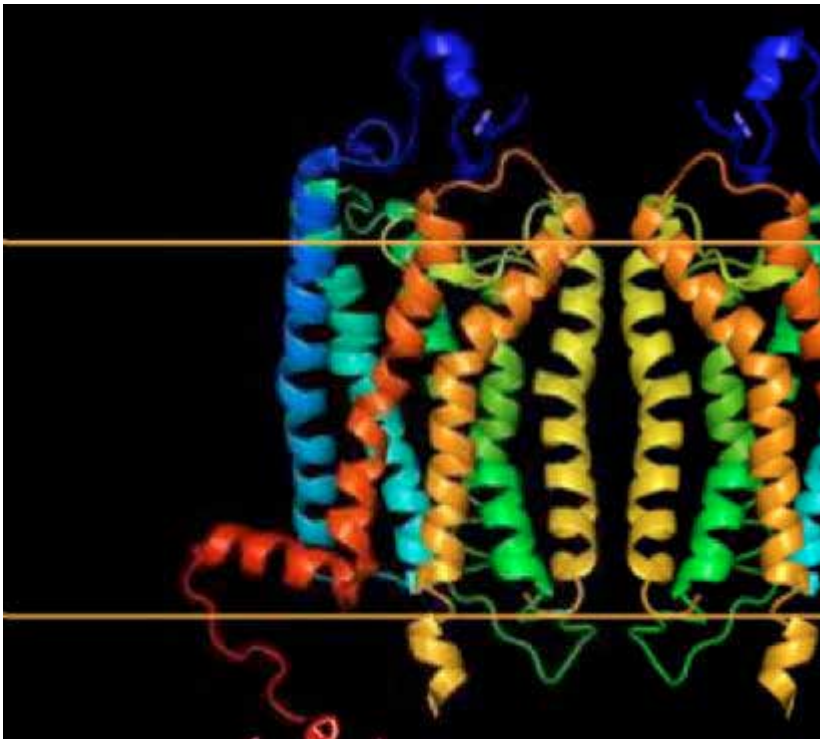

Dimerization of GPCRs can be detected using FRET experiments

[Cancer biology]

The Autophagic Activity of Lithium Chloride on Different Tumor Cell Lines Using Electron Microscopy

Ayhan Bilir[1], Agnes Archibong Omon[1], Irfan Aydın[2], Gülperi Öktem[3], Mine Ergüven[4], Ahmet Şükrü Aynacıoğlu[5]

[1]İstanbul Aydin University, Faculty of Medicine,Department of Histology and Embryology, İstanbul

[2]Beykent University, Associate's Degree Vocational School, Medical Laboratory Techniques Departments, İstanbul

[3]Ege University, Medical Faculty, Department of Histology and Embryology, Bornova, İzmir

[4]İstanbul Aydin University, Faculty of Engineering, İstanbul

[5]İstanbul Aydin University, Faculty of Medicine, Department of Medical Pharmacology

Abstract :Autophagy is an evolutionarily conserved process of self digestion that involves the catabolisim of cellular substrates to provide energy and macromolecules for metabolism [1]. Autophagy is initiated by the formation of a cup-shaped membrane known as the phagophore in the cytoplasm. The phagophore interacts with different proteins that enable elongation and formation of a double-membrane structure called the autophagosome/early autophagic vacuole. The autophagosome sequesters a portion of cytoplasm along with the target cellular component to be degraded. Following fusion, autophagosomes merge with multivesicular endosomes (early and late endosomes) which deliver lysosomal membrane proteins and proton pumps to form a structure called the amphisome/late autophagic vacuole. Fusion with multivesicular endosomes helps to acidify the interior of autophagosomes which is needed for the activation of lysosomal enzymes. Autophagosome are then trafficked along microtubules to the perinuclear region of the cell rich in lysosomes. Fusion of lysosomes and autophagosomes forms a vesicle called the autolysosome in which degradation of cellular cargo occurs (Fig. 1) [2].
Fig 1. Schematic diagram showing the stages of autophagy(http://enjournal.org/ArticleImage/0142EN/en-21-1-g001-l.jpg).

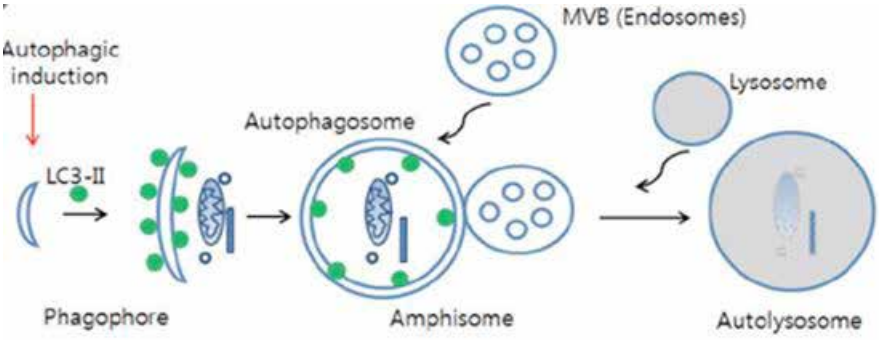

The formation of the autophagosome can be categorized into mammalian target of rapamycin (mTOR) dependent and independent pathways [1, 3]. mTOR acts by suppressing autophagy. Its activity is dependent on upstream signals like nutrition and energy levels of the cells. Downstream of mTOR, autophagy related genes (atg genes) regulate autophagy. Autophagosome formation requires 2 important Atg conjugations systems: Atg12-Atg5 and Atg8/LC3 phosphtidyl ethanolamine. The former participates in the formation and extention of the phagophore and autophagosome but dissociates from the autophagosome after fusion. LC3 participates in autophagosome formation and fusion and remains on the autophagosome after fusion. Also central to autophagy regulation is Beclin 1. It interacts with Vps34 which is key in autophagosome formation. Beclin 1 also interacts with several autophagy regulators that act by regulating Vps34 kinase activity [4].
Autophagy may be specific or non-specific. At basal levels, autophagy occurs constitutively to remove protein aggregations and damaged organelles. Specificity of autophagy is seen in chaperone-protein mediated autophagy and degradation of organelles such as mitochondria, peroxisomes, ribosomes and endoplasmic reticulum [5]
Autophagy plays important roles in physiological processes such as host defense, cellular aging and organelle turnover [3]. Its dysregulation has also been implicated in different pathologic lesions such as cancer, Alzheimer's, Huntington and Parkinson's disease [1]. Autophagy–induced degradation pathways may lead to autophagic cell death hence proper knowledge about autophagy inducers and suppressor may be instrumental in the treatment of different autophagy-related pathologie [6].
Lithium chloride (LiCl) is an alkali metal that has been used as an age-long treatment in bipolar affective disorder. Studies show that among its numerous cellular targets are its inhibition of glycogen synthase kinase-3β (GSK-3β) and inositol monophosphatase (IMPase) [7].
Lithium inhibits GSK-3β directly by competing with magnesium, a co-factor of GSK-3β. It also inhibits GSK-3β by activating Akt kinase [8]. Activation of Akt is regulated by PI3 kinase phosphorylation. Phosphatases and Wnt pathway inhibit GSK-3. Binding of Wnt proteins to their transmembrane receptor (frizzled) activates β-catenin. GSK-3β in complex with APC and axin maintain low β -catenin levels by phosphorylation which targets β -catenin for proteosomal degradation. This interaction between GSK3β and β-catenin is inhibited by Wnt signalling. Inhibition of GSK3-β by lithium mimics the Wnt pathway. It leads to cytoplasmic accumulation of β-catenin which translocates to the nucleus. In the nucleus it interacts with DNA-binding T-cell factors that activates Wnt-induced transcriptional programme. Outcomes of this signalling results in cell proliferation, cell fate specification and tissue homeostasis [9]. IMPase catalyses the conversion of inositol monophosphate into free inositol required by the phosphoinositol pathway. Lithium's Inhibition by IMPase leads to decreased free inositol which in turn decreases myo-inositol-1,4,5-triphosphate (IP3). IMPase inhibition by lithium and the resulting decrease in free inositol and IP3 has been shown to stimulate autophagy [7].

Ultrastructural studies of lithium's effect on different cancer types from our group support the pro-autophagic effect of lithium. Electron microscopic evaluation of sorafenib (an antineoplastic drug) and LiCl treated human glioblastoma multiforme cells revealed autophagic induction evidenced by the presence of autophagic vacuoles in the cells. Combination of both drugs was shown to further intensify the autophagic response of the cells [10]. The cytotoxic effect of lithium was demonstrated with its single and combination treatment with vinorelbine. Lithium and lithium-vinorelbine combination resulted in nuclear membrane break down of SH-SY5Y neuroblastoma cells (Fig. 2 A and B). However autophagy was shown to participate in resistance of the SH-SY5Y neuroblastoma cells [11]. These cumulative results show that the role of autophagy vary depending on the cancer cell type.

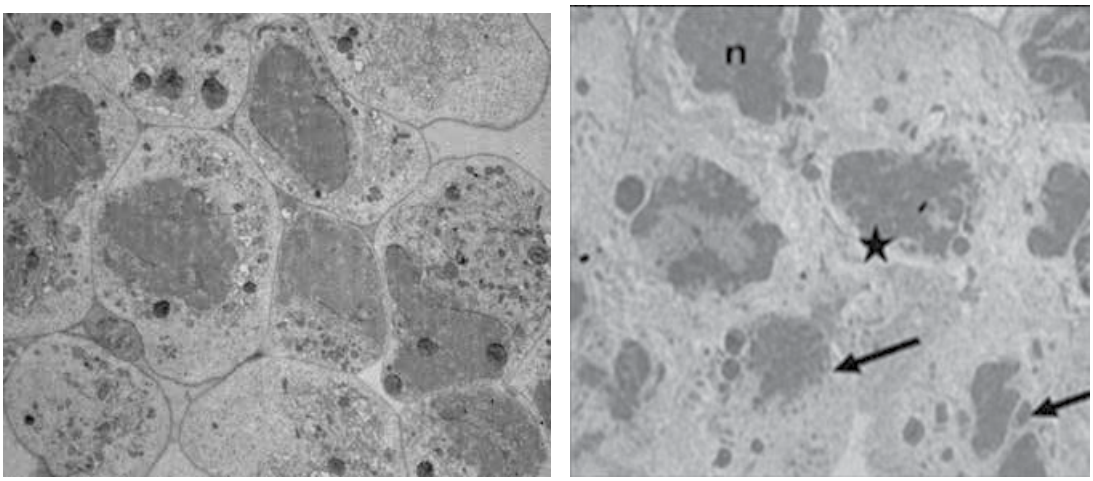

Fig. 2: Transmission electron micrographs of LiCl and LiCl + Vinorelbine treated SH-SY5Y spheroids. **A**. 24 hrs LiCl treated group. Arrow shows break down of nuclear membrane. Cytoplasmic membranes are intact. **B**. 24 hrs LiCl+ Vinorelbine combination group. Arrows show degenerating nuclei. Star shows indistinct cytoplasmic borders of cells. **n**: Nucleus [11].

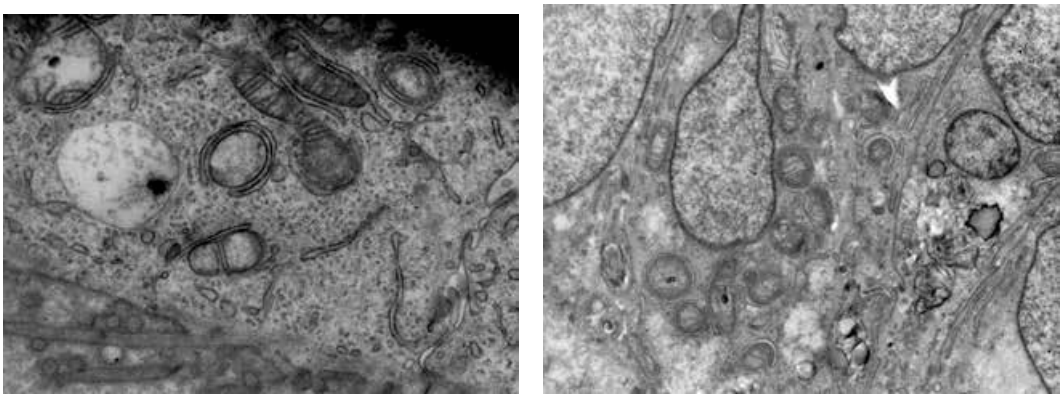

In Ishikawa endometrial cancer cell line, LiCl treated spheroids induced numerous autophagic vacuole formation. This autophagic response was increased on combination of LiCl and Imatinib mesylate (an antineoplastic drug). In addition severely damaged mitochondria were observed [12]. In line with this, single and combination treatment of LiCl and resveratrol on Ishikawa cells showed prominent mitophagy (Fig. 3 A, B, C and D)[Unpublished data], a specific form of autophagy targeted at removal of damaged mitochondria.

The role of autophagy in cancer remains controversial. Autophagy has been proposed to be tumor suppressive. It has also been reported to function as a cell death mechanism. Current available cancer therapies are often met by resistance to apoptosis. This highlights the need for alternative methods of treatment.

In light of this, our presentation aimed to show an ultrastructural scale, the autophagic cell death inducing effect of LiCl in combination with antineoplastic and antiproliferative agents. The outcome of autophagy has been shown to be dependent on the cell type or genetic background. As a result, more studies are required to elucidate the autophagic inducing effect of LiCl on different cancer types. Autophagy-induced cell death may prove promising in the treatment of cancer.

Keywords: Autophagic Activity, Lithium Chloride, Tumor, Cell Lines, Electron Microscopy

Young Histochemist Awardees

Morphological study of chondrocyte cell death in patients affected by chondrocalcinosis

Davide Curzi[1], Sara Salucci[1], Debora Burini[1], Francesco Fardetti[2], Alessandro Beccarini[2], Elisabetta Falcieri[1], Pietro Gobbi[1]
[1]Department of Biomolecular Sciences, University of Urbino Carlo Bo, Urbino, Italy
[2]Private hospital "Porta Sole", 06122, Perugia, Italy

Introduction & OBJECTIVES: chondrocalcinosis is a degenerative knee disease which usually characterizes the oldest population, where the cartilage degeneration is associated to crystal accumulations of calcium pyrophosphate dihydrate in the degenerated regions [1, 2]. In this work, the morphological features of cartilages and, in particular, of their chondrocytes, have been investigated in patients affected by chondrocalcinosis.
Materials & METHODS: cartilage specimens from femoral condyles have been investigated using histochemical analysis, microanalysis, transmission and scanning electron microscopy.
RESULTS: the morphological observations revealed a general impairment of the upper cartilaginous layers in the anatomical area particularly subjected to mechanical loading. In these sites, the cartilage middle layer displayed numerous empty lacunae and, where chondrocytes were present, they displayed necrotic features. However, a different type of apoptotic cell death characterized some of these chondrocytes, which displayed chromatin margination, an outer nuclear membrane detachment, cytoplasm vacuolization, a translocation of nuclear pores and a diffuse presence of autophagic vacuoles (Fig.1). This kind of cell death just observed in other diseases was called chondroptosis [3].
CONCLUSIONS: the study of chondrocyte behaviour and death appears to be essential to better understand cartilage disorders and possible regenerative treatment. The presence of chondroptosis in chondrocalcinosis could open a new research field in the study of this pathology and different pharmacological approaches.
References
[1] Abhishek et al. (2014) Epidemiology of calcium pyrophosphate crystal arthritis and basic calcium phosphate crystal arthropathy. Rheum Dis Clin North Am. 40(2):177-91.
[2] Ryu et al. (2014) The prevalence of and factors related to calcium pyrophosphate dihydrate crystal deposition in the knee joint. Osteoarthritis Cartilage. 22(7):975-9.
[3] Battistelli et al. (2014) Cell death in human articular chondrocyte: a morpho-functional study in micromass model. Apoptosis. 19(10):1471–83.

Keywords: Chondrocalcinosis, Chondroptosis, Necrosis

Figure

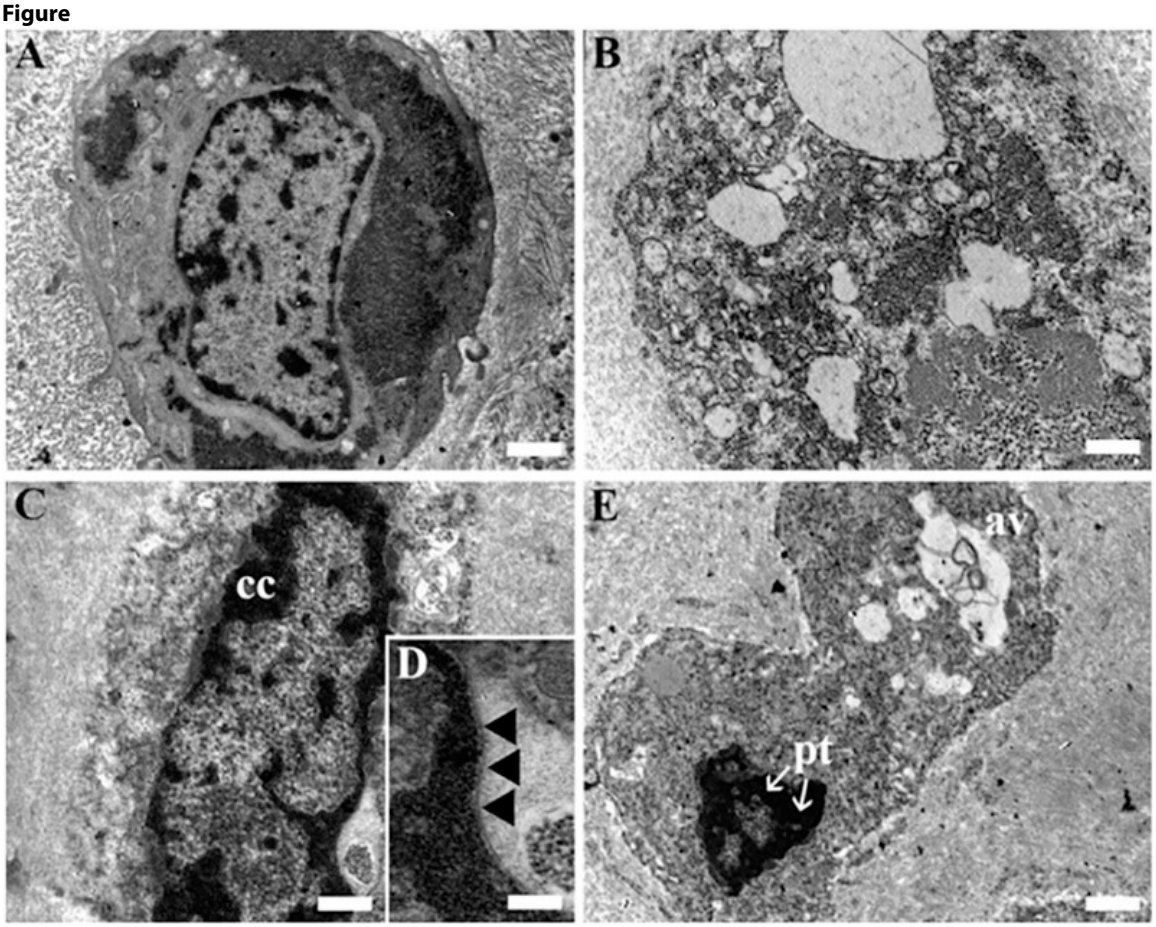

Figure 1. Transmission electron microscopy micrographs of healthy (A),necrotic (B) and chondroptotic chondrocytes (C, D, E). The latters revealed chromatin condensation (cc), nuclear membrane detachment (arrow-head), nuclear pores translation (pt) and, in the late stages, autophagic vacuoles (av).
Bars: A, B, C: 0.6 µm; D: 0.3 µm; E: 1.5 µm.

Characterization of Lamin A / Phosphatidylinositol-4,5-bisphosphate complex

Sara Escudeiro-Lopes, Lenka Jarolimová, Vlada V. Philimonenko, and Pavel Hozák
Institute of Molecular Genetics ASCR v.v.i. Department of Biology of the Cell Nucleus, Czech Republic

Lamins, intermediate filament proteins present in nuclear lamina, are important regulators of nuclear structural integrity as well as nuclear functional processes, such as transcription, DNA replication and repair, and epigenetic regulation. Mutations in lamin A cause a large variety of human diseases, known as laminopathies, including muscular dystrophies and progeroid syndromes. Phosphorylable serines in lamin A may play important roles in different cell processes. Our previous data demonstrate that lamin A forms a complex with nuclear myosin I (NM1) and phosphatidylinositol 4,5-bisphosphate (PIP2), and the formation of the complex might be modulated by lamin A phosphorylation status. Therefore, we used expression vectors for GFP-tagged lamin A with mutations of selected high-turnover phosphorylation sites - phosphomimetics and phosphorylation-deficient – prepared by site-directed mutagenesis. We compared the pattern of mutated lamins separated with 2D-electrophoresis with the wild type. The spots distribution of certain phosphomimetic mutants is more shifted to the acidic side, suggesting an importance of those serines for lamin A interactions with PIP2 and NM1. To understand the influence of these phosphorylations in the formation of lamin A complexes, we investigated the differences of protein binding partners that bound to lamin A compared to lamin A phospho-mutants. This revealed that some proteins bind to lamin A independently of phosphorylation on studied sites, while others require specific phosphorylations for the binding. We conclude that some phosphorylation sites might be crucial for PIP2-dependent interactions of lamin A, important for nuclear functions.

Acknowledgements: We would like to thank to the Grant Agency of the Czech Republic (17-09103S, 16-03346S and 15-08738S) for their financial support to this project. We would also like to thank for the institutional support due to the long-term conceptual development of the scientific organization (RVO: 68378050). The microscopy work was performed at the Microscopy Centre, Institute of Molecular Genetics AS CR, supported by the MEYS CR (LM2015062 Czech Bioimaging).

Ultrastructural Examination of Doublecortin, GABA and VGLUT1 Levels in the Dentate Gyrus of Absence Epileptic Rats

Ozlem Tugce Kaya[1], Duygu Gursoy[1], Cynthia Moore[2], Charles Kenneth Meshul[3], Filiz Onat[4], Serap Şirvancı[1]
[1]Department of Histology and Embryology, Marmara University Faculty of Medicine, Istanbul, Turkey
[2]Veterans Hospital, Portland, OR, United States
[3]Department of Behavioral Neuroscience and Pathology, Oregon Health and Science University, Portland, OR, United States
[4]Department of Pharmacology and Clinical Pharmacology, Marmara University School of Medicine, Istanbul, Turkey

The dentate gyrus (DG) of the hippocampus and the subventricular zone of the lateral ventricles are two distinct brain areas in which neurogenesis occurs during life time period. The relationship between neurological disorders and neurogenesis has been reported by recent studies. As an animal model for absence epilepsy, genetic absence epilepsy rats from Strasbourg (GAERS), is a strain in which neurogenesis has not yet been investigated. In the present study, we aimed to examine whether newly born neural cells form synapses with GABAergic and glutamatergic neurons and thus integrate into the local circuitry.
In this study, 21- and 3-month-old Wistar rats and GAERS were used. Brain tissues were obtained by intracardiac perfusion fixation and DG regions were dissected from the 300-µm-thick vibratome sections. Then, the tissues were processed for electron microscopic assessments and embedded in epon. Ultra-thin sections were obtained by using an ultramicrotome. Sections were double-labeled either for doublecortin (DCX), as a marker of immature neurons, and GABA or vesicular glutamate transporter 1 (VGLUT-1) using postembedding immunogold method. Labeled sections were photographed by the transmission electron microscope. NIH Image Analysis (Image J) program was used for the quantitative analysis.
In all groups, DCX was seen co-localized with GABA in axon terminals, dendrites and somata or with VGLUT-1 in axon terminals. While DCX-positive profiles including GABA showed a tendency to increase in 21-day-old groups compared to 3-month-old groups; profiles double-labeled for DCX and VGLUT-1 showed a tendency to increase in 3-month-old groups compared to 21-day-old groups. Besides, DCX labeling was significantly increased in profiles forming asymmetrical synapses compared to those forming symmetrical synapses.
In conclusion, our findings in the present study suggest that newly born neurons synapse with GABAergic and glutamatergic neurons and thus contribute to the local hippocampal circuitry in absence epileptic immature and adult rats.

Keywords: GAERS, doublecortin, GABA, VGLUT1, immunogold, electron microscopy

The expression of galanin receptors (GALR1, GALR2 and GALR3) in colorectal cancer

Jacek Kiezun, Przemyslaw Kwiatkowski, Janusz Godlewski, Bartlomiej Krazinski, Anna Kowalczyk, Zbigniew Kmiec
Department of Human Histology and Embriology, Faculty of Medical Sciences, University of Warmia and Mazury in Olsztyn, Poland

INTRODUCTION: Galanin (GAL) is a neuropeptide expressed in central and peripheral nervous system, including enteric nervous system (ENS). Concentrations of GAL are increased in the blood of colorectal cancer (CRC) patients and are associated with cell proliferation and tumor growth. GAL acts by binding to specific receptors (GALR1, GALR2 and GALR3). The aim of this study was to evaluate the expression of GALRs in the sections of the colon wall containing ENS plexuses close to the tumor invasion and in CRC tumor.
MATERIALS-METHODS: Samples of CRC tumors and colon wall tissue close and distant from the neoplastic tissue were obtained from 18 CRC patients. Localization of GAL was evaluated using immunohistochemistry (IHC). Distribution of GALRs-immunoreactive (GALR1-Ir, GALR2-Ir and GALR3-Ir) was measured in myenteric plexuses of studied tissues and analyzed using Wilcoxon signed-rank test. Results were expressed as means of groups ± SEM ($p<0.05$).
RESULT: IHC revealed GALR1, GALR2 and GALR3 immunoreactivity within the cells of intestinal epithelium, intestinal stromal cells, cancer cells, myenteric plexuses and was predominantly identified in cell cytoplasm. Strong GALR1-Ir was found in CRC cells, intestinal epithelium and stromal cells distant from the tumor. In turn, GALR2-Ir was stronger in cancer cells and stromal cells than in epithelial cells. GALR3-Ir was weaker in stromal cells than in cancer and epithelium. Relative mean area of GALR1-Ir, GALR2-Ir and GALR3-Ir in intestinal wall close to the tumor was lower (0.79±0.05%, 0.21±0.04% and 0.51±0.06%, respectively), than that in distant section of colon wall (1.65±0.11%, 0.51±0.05% and 1.22±0.09%, respectively).
CONCLUSIONS: To the best of our knowledge, this study is the first to demonstrate GALRs immunoreactivity in epithelium and stromal cells of human colon and CRC tumor cells. In addition, lower relative mean area of GALRs-Ir in myenteric plexuses in the vicinity of CRC tumor than in the muscularis located distantly from the tumor may suggest the lower sensitivity of cancer cells to GAL. Different expression of particular GALRs in cancer cells may suggest that they play distinct roles in transduction of GAL signal in CRC tumor cells. However, the mechanisms of GAL action in CRC cancer need further studies.

Keywords: galanin, GALR1, GALR2, GALR3, colorectal cancer

IDH1-mutated gliomas rely on anaplerosis of glutamate and lactate whereas IDH1 wild-type gliomas rely on glycolysis and acetate anaplerosis

M. Khurshed[1*], K. Lenting[2], R.J. Molenaar[1], W.P.J. Leenders[2], C.J.F. Van Noorden[1]

[1]Department of Cell Biology, Academic Medical Center, Meibergdreef 15, 1105 AZ Amsterdam, The Netherlands
[2]Radboudumc, Department of Pathology, PO Box 9101, 6500 HB Nijmegen, The Netherlands
*Corresponding author

Introduction: Hotspot mutations in isocitrate dehydrogenase 1 (*IDH1*^{MUT}) initiate low grade glioma (LGG) and secondary glioblastoma and induce neomorphic activity that converts α-ketoglutarate (α-KG) to the oncometabolite *D*-2-hydroxyglutarate (*D*-2-HG). This causes metabolic rewiring that is not fully understood and *in vitro* studies have shown that IDH1^{MUT} cancer cells rely on glutaminolysis, providing cells with α-KG via activities of glutaminase (GLS) and glutamate dehydrogenase (GLUD).
Results: We first show by *in silico* analysis of 269 IDH1 wild-type (*IDH1*^{WT}) and 408 *IDH1*^{MUT} gliomas, obtained from the The Cancer Genome Atlas (TCGA) database, that *IDH1*^{WT} gliomas have high expression levels of genes encoding for enzymes that are involved in glycolysis and acetate anaplerosis. On the other hand, the tricarboxylic acid (TCA) cycle, rather than glycolytic lactate production, is the predominant metabolic pathway in *IDH1*^{MUT} gliomas and is driven by lactate and glutamate anaplerosis to facilitate production of α-KG, and ultimately *D*-2-HG. *IDH1*^{WT}- and *IDH1*^{MUT}-related differences in expression were found in both LGG and glioblastoma. Furthermore, via *in situ* enzymatic activity mapping, we show in human gliomas and in xenocraft models that GLUD activity is increased and GLS activity is decreased in *IDH1*^{MUT} glioma, indicating that *IDH1*^{MUT} gliomas depend on glutamatolysis, rather than glutaminolysis. We show that transcript levels in our xenocraft models are in good agreement with our *in silico* analysis of the TCGA database. Finally, we confirmed the glutamate dependency of *IDH1*^{MUT} gliomas by MRS-flux analysis, whereas IDH1^{WT} gliomas show high lactate production.
Conclusions: We show that *IDH1*^{WT} gliomas have a typical Warburg phenotype and rely on acetate anaplerosis whereas *IDH1*^{MUT} gliomas are glutamate and lactate dependent. This metabolic rewiring in *IDH1*^{MUT} glioma, enables targeting of glutaminolysis rather than direct inhibition of *IDH1*^{MUT} for therapy. It diminishes the supply of glutamate-derived α-KG and directly inhibits the production of D-2-HG and simultaneously worsen the redox status of the glioma cells by inhibiting NAD(P)H production by GLUD. A candidate drug to inhibit GLUD is epigallocatechin-3-gallate gallate, a component of green tea that is currently receiving high interest as anti-cancer agent.

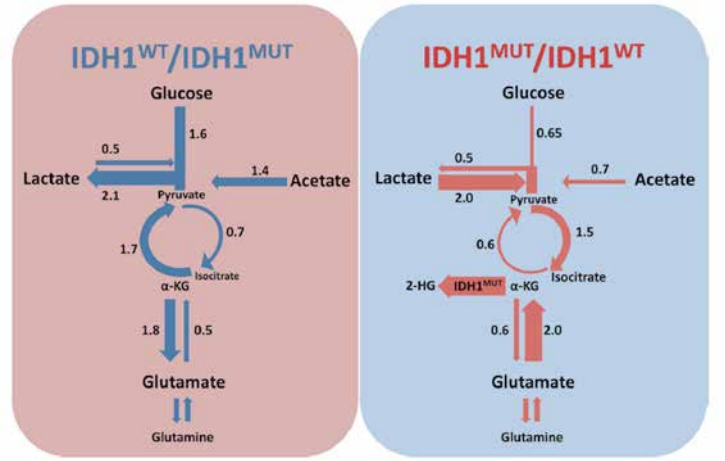

Rewiring of metabolism by *IDH1*^{MUT}. *IDH1*^{WT}/*IDH1*^{MUT} and *IDH1*^{MUT}/*IDH1*^{WT} ratios indicate contribution of a particular pathway as calculated on the basis of gene expression levels in *IDH1*^{WT} and *IDH1*^{MUT}, respectively.

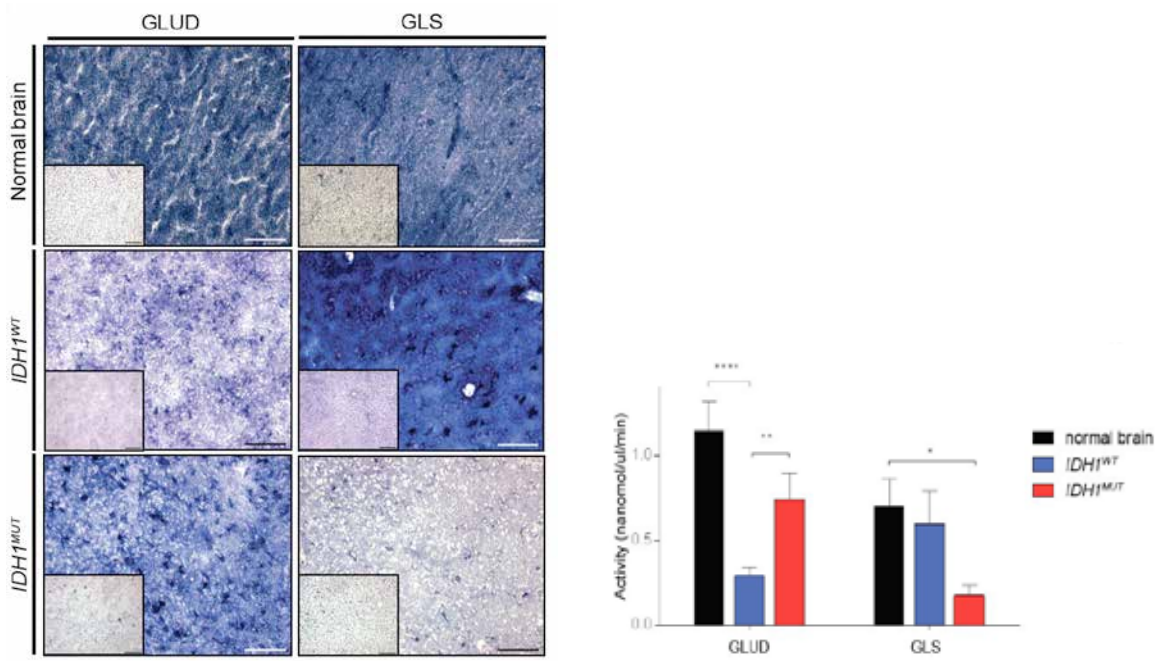

In situ metabolic mapping of glutamate dehydrogenase (GLUD) and glutaminase (GLS) activity in *IDH1*^{WT} and *IDH1*^{MUT} glioma. Representative examples of cryostat sections of normal brain, *IDH1*$^{WT/WT}$ (n=5) or *IDH1*$^{WT/MUT}$ (n=7) gliomas after in situ metabolic mapping and quantification of activity of GLUD and GLS.

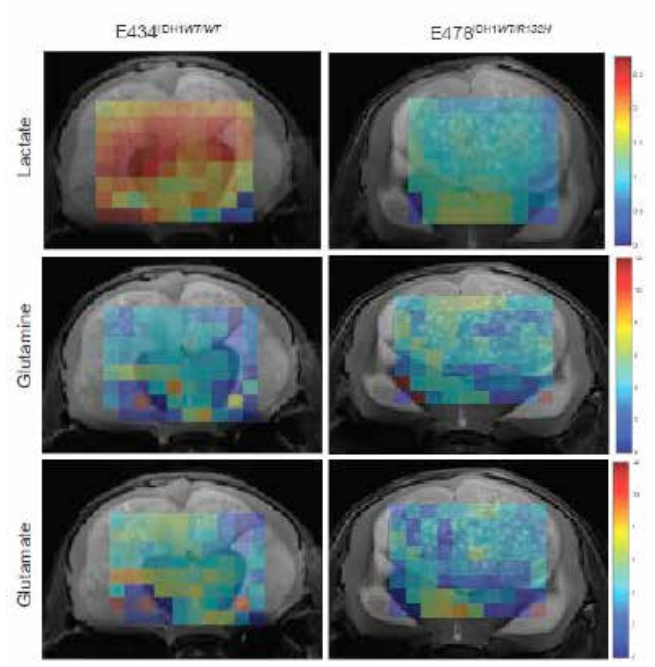

In vivo multivoxel MRSI of E434 and E478 xenografts. Local relative concentrations of lactate, glutamine and glutamate as acquired with multivoxel MRSI, mapped to corresponding T2-weighted MR images.

Workshops

WORKSHOP I: Immunogold Staining

S Şirvancı, D Akakın, ÖT Kaya (Marmara University, Turkey)

Immunogold labeling is one of the most valuable techniques used in electron microscopy to study biological molecules at the subcellular level. The aim of this workshop is to provide the participants the general overview of the basic principles of immunogold labeling under the guidance of our tutors, who have experience in immunogold staining techniques on brain tissue, and to promote collaboration between researchers. The workshop is primarily theoretical, covering the perfusion fixation for tissue collection, tissue processing and obtaining sections with ultramicrotome and immunogold labeling techniques for electron microscopy. Besides, videos supporting the topics will be shown during the workshop.

WORKSHOP 2: Introduction to Three-Dimensional Modeling and Animation In Histology and Embryology

T Peker (Gazi University,, Ankara, Turkey)

There are three-dimensional modeling and animation units in universities or associations in order to prepare visual materials such as photography, painting and animation in medicine and anatomy education especially in the universities at the developed countries such as; United States, Japan, China, and so on.
Together with the developing technology, the updating time of the information is shortened. This information may be outdated before a medical student is graduated. Presenting new information to the student in a rich way will provide them with a much shorter time to understand. On the other hand, the developments in computer hardware and software have brought a new field of research in the field of medicine and gave the flexibility, detail and speed of this area to the practitioners and artists as the classical methods can't give. In addition, it is possible to easily create three-dimensional model images by using computer based methods and to obtain animations from there.
If you go a little further; this powerful technology also makes it possible to create dynamic, interactive, and indistinguishable animations (such as virtual reality, augmented reality and hologram images). For these reasons, we aimed to prepare a workshop called «Introduction to 3D Medical Modeling and Animation in Histology and Embryology» in order to draw three dimensional modeling and animations by our colleagues working in Medical Faculties and to get their attention.

** Attendees wishing to attend the workshop should bring their computers with them. For those who can't bring computers, mirror projections will be projected.*
*** Due to the work being done with Cinema 4D during the workshop, Cinema 4D (R15,16,17 or 18) must be pre-installed and working on the computer.*

WORKSHOP 3: Basic Stem Cell Culture Techniques and Applications

I Tuglu, S Inan, E Turkoz Uluer, I Aydemir, P Kilicarslan Sonmez (Celal Bayar University, Turkey)

Stem cells have been increasingly used in the health field in recent times as a natural resource. This source takes place in an effective and functional manner in different fields with experimental and phase studies. The behavior of stem cells need to be known and understood so that the benefits and harms are well known before being widely used. It is important that our field of specialization plays a leading role in research of this subject and widens its area into this matter. For this purpose, we will explain the techniques of stem cell behavior, isolation, culture, proliferation, differentiation, freezing and thawing in the visual environment and will examine the behaviors, abilities and usage areas of the stem cells.

Oral Presentations

*DOI numbers were assigned to all abstracts which were accepted for ICHC 2017

10.5505/2017ichc.OP-01 [Epigenetics & molecular cytogenetics]

Odontoclastic differentiation ability of human dental pulp cells in the presence of triethylene glycol dimethacrylate

Zeynep Oncel Torun[1], Deniz Torun[2], Baris Baykal[3], Ali Oztuna[2], Fatih Yesildal[4], Ferit Avcu[5]

[1]Balgat Oral and Dental Health Center, Ankara, Turkey

[2]Department of Medical Genetics,Gulhane Medical Faculty, University of Health Sciences, Ankara, Turkey

[3]Department of Histology and Embryology, Gulhane Medical Faculty, University of Health Sciences, Ankara, Turkey

[4]Department of Medical Biochemistry, Diyarbakir Selahaddin Eyyubi Public Hospital, Diyarbakir, Turkey

[5]Memorial Ankara Hospital, Ankara, Turkey

Dental pulp tissue has an important impact on odontoclastic differentiation and function. Triethylene glycol dimethacrylate (TEGDMA) is the most important form of diluent monomers, which are found in the structure of resin monomers used in dentistry. Osteoblasts/stromal cells express receptor activator of nuclear factor (NF)-kB ligand (RANKL) in response to cytokines like 1α,25-dihydroxyvitamin D3 (1α,25(OH)2D3). The aim of this study was to examine the effects of TEGDMA and 1α,25-dihydroxyvitamin D3 on the odontoclastic differentiation induction potential of the dental pulp tissue on CD14+ monocytes. The groups in the study were:
i) Human dental pulp cells (hDPCs); ii) hDPCs + CD14+ cells; iii) hDPCs + 1α,25(OH)2D3; iv) hDPCs + CD14+ cells + 1α,25(OH)2D3; v) hDPCs + CD14+ cells + TEGDMA; vi) hDPCs + 1α,25(OH)2D3 + TEGDMA; vii) hDPCs + CD14+ cells + 1α,25(OH)2D3 +TEGDMA.
Methodologies used were: i) Evaluation of odontoclastic differentiation by flow cytometry and TRAP staining; ii)Investigation of apoptotic effects of TEGDMA with the Annexin V staining; iii) Evaluation of mRNA expression levels of OPG and RANKL genes by RT-PCR; iv) OPG and RANKL protein analysis by ELISA techniques.
TEGDMA caused less odontoclastic differentiation in comparison with the control group but odontoclastic differentiation showed increase in accordance with the dose of TEGDMA ($p<0.05$). mRNA and protein level of OPG gene was lower in TEGDMA treated pulp cells than control group ($p<0.05$). RANKL mRNA did not show any change in comparison with the control group ($p>0.05$), but RANKL protein level was higher than control group ($p<0.05$). TEGDMA revealed an increasing apoptotic effect on dental pulp cells in accordance with the dose.
As a conclusion, TEGDMA reduces the odontoclastic differentiation induction ability of hDPCs. However, odontoclastic differentiation ratios increment proportionally with the increasing concentration of TEGDMA.
This project has been supported by The Scientific and Technological Research Council of Turkey (TUBITAK) with project number 114S761

Keywords: human dental pulp cells, OPG, odontoclastin differentiation, RANKL, TEGDMA

10.5505/2017ichc.OP-02 [Developmental and reproductive biology]

The role of trophoblastic items in oocyte culture

Hilal Kabadayı[1], Kemal Ozbilgin[1], Hafize Seda Vatansever[2]

[1]Department of Histology and Embryology, Faculty of Medicine, Celal Bayar University, Manisa, Turkey

[2]Department of Histology and Embryology, Faculty of Medicine, Celal Bayar University, Manisa, Turkey, Near East University, Experimental Health Science Research Center, Nicosia, North Cyprus

Maturation is often segregated into nuclear-cytoplasmic events to delineate specific mechanisms and functions. Cytoplasmic maturation involves the cytoplasmic changes required to prepare the cell for fertilization, activation, and embryo development. Nuclear maturation refers to the meiotic process of chromosomal reduction to a haploid content. One of the reasons of woman infertility is the disruption of oocyte maturation which prevents fertilisation. In this study we aimed to investigate the role of trophoblastic items on oocyte maturation and oocyte arrest.
Trophoblast cells were isolated from E13.5-14,5 mouse placentas and transfered into DMEM HAMs F12 medium including 0.01% collagenase, 0,001% hyalurinidase and 0,5% bovine serum albumin for 30 min and cultured in M2 medium for 2 weeks. The cells were stained with anti-cytokeratin 7 for characterization. Prophase I, Metapahase I and Metapahase II oocytes were collected from 24, 36 and 48 hours after superovulation respectively and cultured in M2 media, trofoblast stem cells media (CM) and with trofoblast stem cells (TR) for 48 hours. Distributions of APC, MAD1, MAD2,RAS, MPF and cyclin B1 detected with immunofleurosence staining and DNA methylation were investigated.
Trophoblast stem cells were cultured and characterized with cytokeratin 7 distribution. After culturing of prophase I, metaphase I and metaphase II oocytes in M2, CM, TR medium, APC immunoreactivity was highest in prophase I oocytes which cultured in TR. MAD1 immunoreactivity was detected in metaphase II oocytes which cultured in TR. MAD2 immunoreactivity was higher in CM group, RAS immunoreactivity was weak in TR group. The immunoreactivity of cyclin B1 was weak in all groups, however MPF immunoreactivity detected in all oocytes of CM and metaphase II oocyte of M2. While the low level of DNA methylation was detected at CM metaphase II oocytes, the highest ratio was observed in M2 metaphase II oocytes.
In conclusions, trophoblast stem cells derived, cultured and characterized from mouse placenta. After culturing of different stages of oocytes in different culture condition, expression of signaling molecules which control the oocyte maturation were changed such as increased RAS, MPF and MAD2 immunoreactivity and decreased APC and cyclin B1 level. In addition, DNA methylation was also changed.

Keywords: Oocyte maturation, in vitro, trophoblast

10.5505/2017ichc.OP-03 [Developmental and reproductive biology]

Influence of estrogen receptor α phosphorylation at serine 309 on male reproductive function of mice

Zhen Li, Jinhua Wei, Binfang Ma, Pang Cheng, Jie Zhao, Xiao Feng, Yuanqiang Zhang
Department of Histology and Embryology, The Fourth Military MedicalUniversity, Xi'an,P.R.China

Introduction & OBJECTIVES: Recent studies in estrogen receptor α (ERα) knockout mice have demonstrated that the testicle development is abnormal, and that sperm recovered from cauda epididymis exhibit reduced motilities and fail to fertilize eggs in vitro. Phosphorylation at serine 305 (S305) site of ERα is sufficient to recruit coactivator SRC1, and to induce ERα activity in a ligand-independent manner. The ERαS309 site in mice is homologous with ERαS305 in human. This study was to investigate the influence of estrogen receptor α phosphorylation at S309 on male reproductive function of mice.
Materials & METHODS: ERαS309A knock-in (S309AERKI) mice were produced by mutating serine to alanine to abolish the ability of phosphorylation of ERα 309 site. The fertility of male mice was observed by mating studies and the morphology of testis, efferent duct and epididymis was investigated by H&E staining. Epididymal sperm motility was detected by computer-assisted sperm analyzer and the pH of epididymal fluid was determined by Hydrion pH paper. The expression of epididymal micro-environment related genes containing estrogen response element were examined by Real-Time PCR and Western blotting in both S309AERKI mice and pIRES2-ERαS309A transfected 293T cells.
RESULTS: The S309AERKI homozygous males were subfertile with dilated and thinner efferent ducts. Sperm numbers were normal whereas sperm motilities were lower than those of wild type mice. Analysis of the epididymal fluid revealed that the S309AERKI mice maintain a higher luminal pH throughout the epididymis. The expression levels of aquaporin 9 (AQP9) as well as carbonic anhydrase 12 (CA12) were reduced in the efferent duct and different segments of S309AERKI epididymis, respectively. In addition, ERαS309A mutant reduced the expression levels of AQP9 and CA12 in 293T cells.
CONCLUSIONS: These results indicate that phosphorylation at S309 site plays an important role in the process of ERα-mediated transcription to maintain a stable fluid/ion transportation in epididymal lumen where sperm quire their motility in mice. This study provides a basis for future research of the effectof S305 phosphorylation in ERα regulation of male reproductive function in human.

Keywords: ERα, phosphorylation, knock-in, male reproduction

10.5505/2017ichc.OP-04 [Developmental and reproductive biology]

Two-dimensional and three-dimensional endometrial co-cultures: Novel approaches for in-vitro implantation models

Sercin Karahuseyinoglu[1], Deniz Yucel[2], Gizem Nur Sahin[3], Kubra Sari[3], Ahmet Kocabay[4], Ali Cihan Taskin[4]

[1]Department of Histology & Embryology, Koç University School Of Medicine, Istanbul, Turkey

[2]Department Of Histology & Embryology, Acibadem University School Of Medicine, Istanbul, Turkey

[3]MS Reproductive Biology, Koç University, Graduate School Of Health Sciences, Istanbul, Turkey

[4]Animal Facility Center, Koç University College Of Sciences, Istanbul, Turkey

INTRODUCTION & OBJECTIVES
Successful implantation of an embryo depends on the synchronous development and cross talk between the hatched blastocyst and the endometrium. The process is driven by a highly complicated mechanism and requires dynamic interactions between endometrial cells and the endometrium, and apposition,adhesion,invasion steps.

The objective of this study is to reveal and compare the spatiotemporal dynamics of molecular and cellular interactions between the mouse blastocyst and the endometrial cells in 2D and a variety of 3D culture set-ups.
The main purpose of this study is to detect the most effective blastocyst culture method for in-vitro use.

MATERIALS & METHODS:
For each group representative type of culture system, 40-60 mouse blastocysts were used.
Two-dimensional set-ups were designed as i. routine IVF cultures, ii. adherent cultures composed of a mixture of endometrial epithelial and stromal cells. Three-dimensional cultures were constructed as i. cultures on endometrial cell covered polymeric films, ii. cultures that use extracellular matrix (Matrigel), iii. cultures on polymeric foams.
The groups were compared for temporal expression of a spectrum of adhesion markers (cadherins), invasion markers (types of collagen, matrix metalloproteinases) and functional markers (LIF, progesterone and estrogen receptors) at 24, 48 and 72 hours of culture throughout the implantation process. The expressions were demonstrated by IF/confocal microscope, WB and qRTPCR. Confocal microscope was also used for the estimation of the invasion depth of the blactocysts in different culture designs.
RESULTS:
LIF generally increases by 72 hours in IVF group(Fig1).The increase of e-cadherin, was observed mostly in the foam group at 48 hours. The film and foam has different 3D strcutrues (Fig2). Foam generally had a better support with its unique structure (Fig3), as in Progesterone receptor (PR), which is a functional and invasive marker (Fig4). MMP9 (matrix metalloproteinase 9), which is an invasive marker, increases at h72. MMP9 expression in 48 h is significantly less than 72h.
CONCLUSION:
With its pores that can lead invasion of the blastocyst, foam group has superior results regarding adhesion, invasion and functional markers. Matrigel group has comparable results. Both materials can be used for effective 3D culture models

Keywords: implantation, 2D, 3D, matrigel, polymeric carriers

Figure 2.

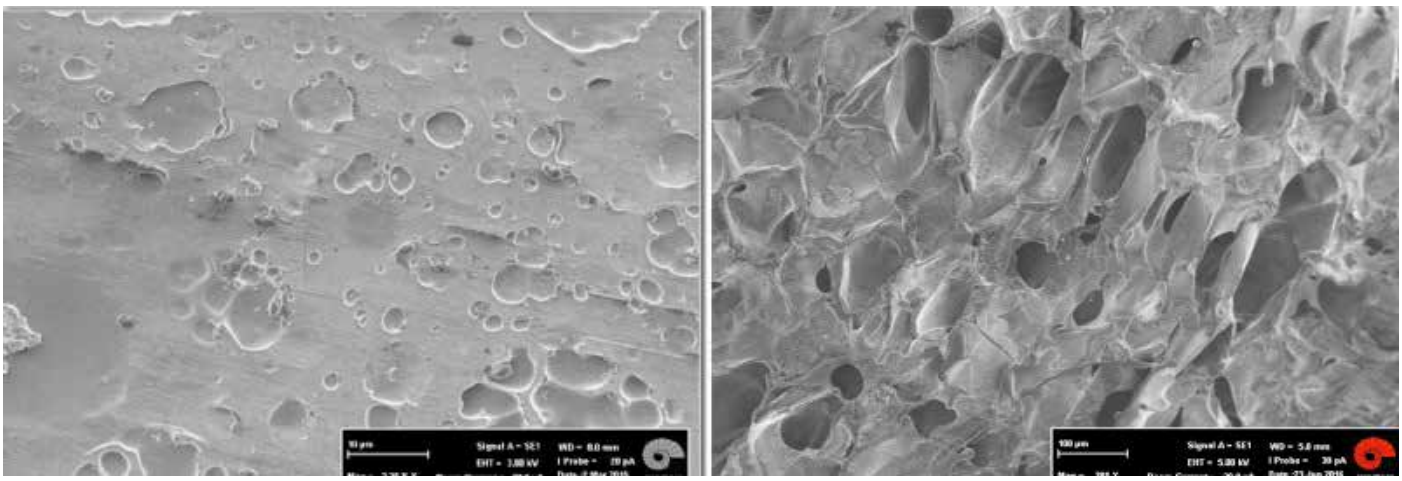

Polymeric carriers: film and foam

Figure 3.



Use of foam as a polymeric cell carrier. Foam has a structure composed of different sizes of pores (A and B arrowheads, C). The porous structure enables endometrial cells (D, yellow arrowheads) to spread on collagen coat (B and D, black arrows) and invade the area and gives oppurtunity to blastocyst (A, blue arrow) for invasion..

Figure 4.

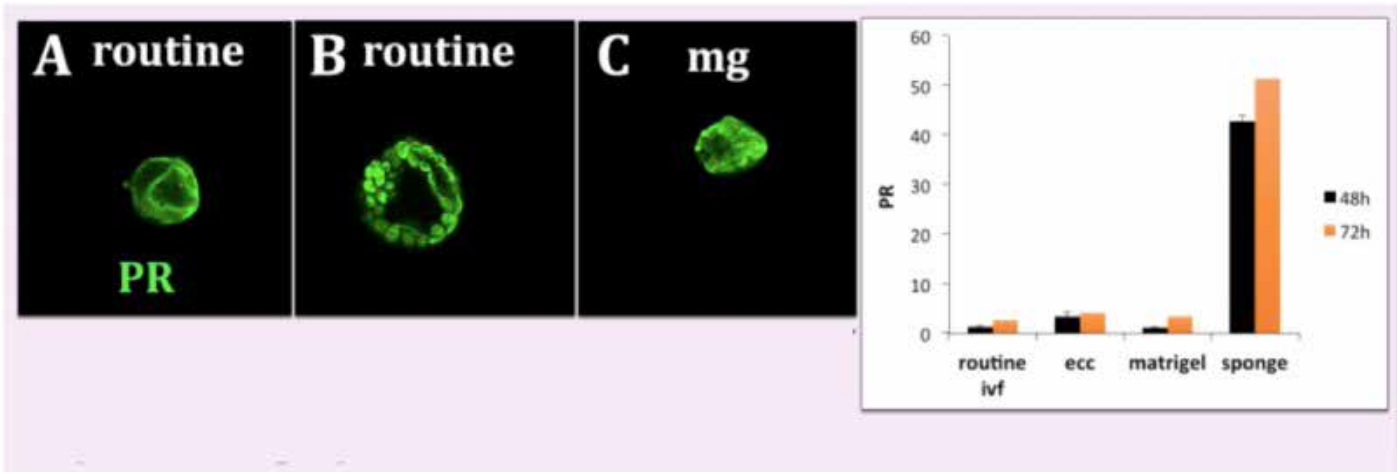

Progesterone receptor (PR) expressions of routine IVF (A,B) at hours 48 and 72, and MG(C) group at hour 48. qRTPCR revealed PR expression was significantly high compared to other groups.

Figure1.

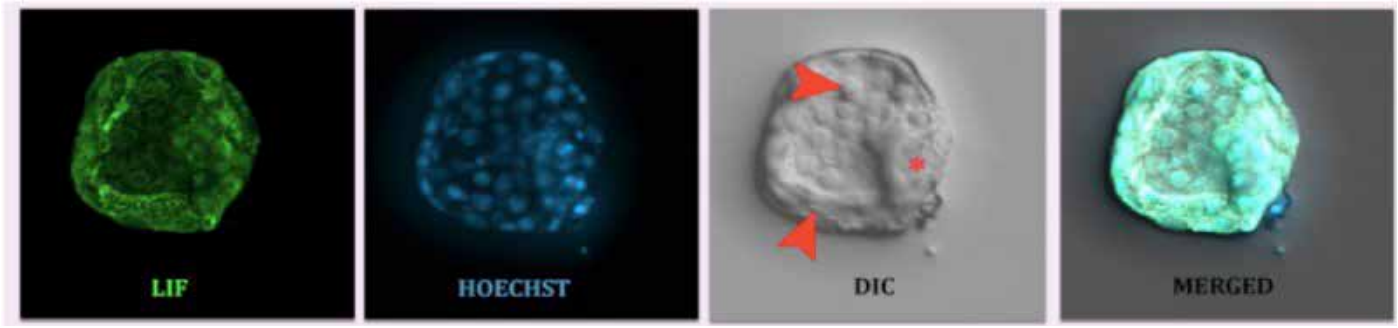

Blastocyst at 4AA stage at 24 hours of culture in the routine IVF group. Inner cell mass (*) and trophopectodermal cells (arrowheads) are well-preserved. LIF expression is noticed in the cells.

10.5505/2017ichc.OP-05 [Developmental and reproductive biology]

The Relation of Adam2(Fertilin), Catsper, Sox5, Septin 12 and Histone 3 Expressions With The Function Of Spermatozoa In Male Infertility

Sercin Karahuseyinoglu[1], Sule Ayla[2], Ozge Biceroglu[2], Kubra Sari[3], Gizem Nur Sahin[3], Tuba Varli Yelke[4]

[1]Department Of Histology & Embryology, Koç University School Of Medicine, Istanbul, Turkey

[2]Department Of Histology & Embryology, Medipol University School Of Medicine, Istanbul, Turkey

[3]MS Reproductive Biology, Koç University, Graduate School Of Health Sciences, Istanbul, Turkey

[4]IVF Clinics, Medipol University School Of Medicine, Istanbul, Turkey

INTRODUCTION & OBJECTIVES:
The proteins on the membrane of head and flagellum regions of spermatozoa are involved in the fusion of sperm and oocyte membranes, to facilitate the entrance of sperm in the extracelluar matrix area around the oocyte. Fertilin (ADAM 2), Catsper, Sox-5, Septin 12 and histone 3 are all important in critical functions of spermatozoa, as motility, fertilization ability and maturation.
The objective of this study to find out the correlation of expression of those proteins with semen parameters in normo and oligozoospermic patients.
The ultimate purpose of this study is to reveal the relationship between sperm function and morphology with the structural and functional proteins of sperm.
MATERIALS & METHODS:
Normozoospermic (n=30) and oligozoospermic (n=30) cases were used. Semen smears were used for motility evaluation, morphological analysis, immune fluorescent stainings, WB and RTPCR. Sperm motility and morphology were evaluated. Spermac stain kit was used for staining smears. TUNEL staining was used for DNA fragmentation. Anti- histone 3, septin 12, fertilin, catsper were used on smears, followed by secondary antibody staining, images were obtained by Zeiss LSM 780. For each staining 200 spermatozoa were counted. WB and RTPCR experiment were completed via routine protocols.
RESULTS:
Flagellar motion and oocyte-sperm fusion parameters revealed by catsper, fertilin and septin 12 were found significantly higher in normozoospermic groups depicted by IF, WB and RTPCR studies. Septin 12 and catsper stanings were correlated with spermac staining. Spermatozoa with flagellar deformities according to Kruger's strict criteria showed defective staining for septin and catsper. In these smears sperms with non progressive motility were found significantly higher. Sox 5 expression was strongly and histone 3 expression was inversely correlated with fertilin expression. DNA fragmentation difference was insignificantly correlated with the motility, fertilin expression and sperm count.
CONCLUSIONS
The most important function of sperm is fertilization, maintained by all flagellar motility, membrane fusion ability, mature and compact DNA. This study revealed the significant relations of some important basic proteins in function of the sperm. Inhibition of one or some of these proteins by specific anti-protein structures may be a novel approach for male contraception.

Keywords: sperm, motility, fertilin, catsper, septin12,histone

10.5505/2017ichc.OP-06 [Developmental and reproductive biology]

The effect of different vitrification solutions and devices on cat ovarian tissue

Ferda Topal Celikkan[1], Murside Ayse Demirel[2], Duygu Baki Acar[3], Sinan Ozkavukcu[4], Seckin Salar[5], Esra Atabenli Erdemli[1], Ayhan Bastan[5]

[1]Department of Histology and Embryology, Faculty of Medicine, Ankara University, Ankara, Turkey

[2]Laboratory Animal Care and Research Unit, Faculty of Pharmacy, Gazi University, Ankara, Turkey

[3]Department of Obstetrics and Gynecology, Faculty of Veterinary Medicine, Afyon Kocatepe University, Afyonkarahisar, Turkey

[4]Assisted Reproduction Center, Faculty of Medicine, Ankara University, Ankara, Turkey

[5]Department of Obstetrics and Gynecology, Faculty of Veterinary Medicine, Ankara University, Ankara, Turkey

INTRODUCTION: Still there were no standard protocols for preserving female genetic materials by cryopreservation. The objective of this study was to evaluate the effect of different ovarian tissue vitrification solutions and techniques on cat preantral follicles.
MATERIALS-METHODS: Aged 10-24 months' cat ovaries were collected by routine ovariohysterectomy (n: 7). They were divided into pieces as control and three different vitrification technique groups (CG (copper grid), NIV I (needle immersed vitrification) and NIV II). In CG group, the tissues were held in CPA (cryoprotectant agent) with final concentration (20% DMSO (dimethyl sulfoxide), ethylene glycol (EG) and 0.4 M sucrose). In NIV I and II groups, tissue pieces were placed in an acupuncture needle equilibrated in CPA with a final concentration of 15% and 12% DMSO, 15% and 12% EG and 0.5 M sucrose, respectively. After equilibration, tissues were plunged into liquid nitrogen and put into cryovials. Tissues were thawed and immersed into Bouins' and 2% glutaraldehyde solution. After tissue processing, brightfield and electron microscopic images were observed.
RESULTS: In brightfield microscopic investigation, follicles were seen healthy with regular oocytes and follicle cells in control group. Follicle cells and oocyte attachments were intact. In CG, NIV I and II groups, although healthy and degenerated follicles were observed, the degenerated follicles were dominant. Some of the degenerated oocytes were observed with eosinophilic cytoplasms and condense nuclei in vitrified tissues. In CG groups, the number of degenerated follicles were more than in the other experimental groups (fig1).
In ultra-thin sections, oocyte and follicle cells' nuclei were intact in non-degenerated follicles in control group. Although, many healthy oocytes and follicle cells were seen in vitrified groups, the number of degenerated oocytes and follicle cells were increased. In this structures, organelles were swollen, irregular spaces between the layer of follicle cells and oocytes were detected. Hydrops in extracellular spaces were significant, so dense collagen bundles became apparent (fig2).
CONCLUSION: Vitrification with NIV and CG methods caused variable degeneration on cat ovarian follicles. Morphology preservation could be changed according to the CPA concentrations. We suggested that, NIV methods were better than CG method in preservation.

Keywords: Ovarian tissue, feline, vitrification solution, vitrificaiton devices.

Figure 1

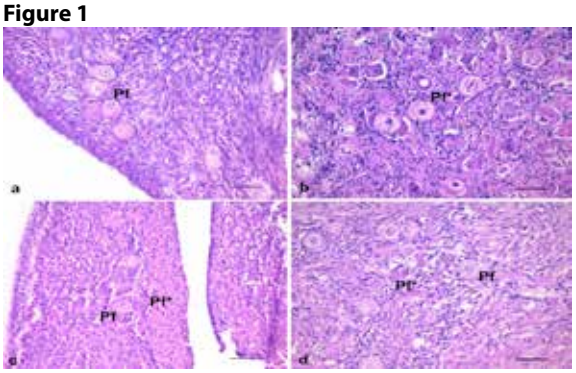

a; control group, b; CG group, c; NIV I group, d; NIV II group. Pf; healthy follicle, Pf; degenerated follicle. Hematoxylin-Eosin staining, scale bar: 50 micrometer.*

Figure 2

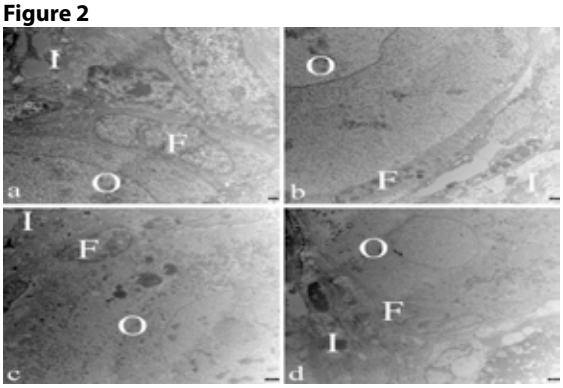

a; control group, b; CG group, c; NIV I group, d; NIV II group. O; oocyte, F; follicle cell, I; interstitium.

10.5505/2017ichc.OP-07 [Developmental and reproductive biology]

The role of CX3CL1 in fetal-maternal interaction during human gestation

Elif Kervancıoğlu Demirci[1], Lois A. Salamonsen[2], Martin Gauster[3]

[1]Department of Histology and Embryology, Marmara University School of Medicine, Istanbul, Turkey

[2]Hudson Institute of Medical Research and Monash University, Clayton, Victoria, Australia

[3]Institute of Cell Biology, Histology and Embryology, Medical University Graz, Graz, Austria

Embryo implantation and subsequent placentation require a fine balanced fetal-maternal cross-talk of hormones, cytokines and chemokines. Amongst the group of chemokines, CX3CL1 (also known as fractalkine) has recently attracted attention in the field of reproductive research. It exists both as membrane-bound and soluble isoforms. On the basis of current experimental evidence, fractalkine is suggested to regulate adhesion and migration processes in fetal-maternal interaction at different stages of human pregnancy. Expressed by uterine glandular epithelial cells, predominantly during the mid-secretory phase of the menstrual cycle, fractalkine appears to prime the blastocyst for forthcoming implantation. After implantation, fractalkine is suggested to regulate invasion of extravillous trophoblasts by altering their expression profile of adhesion molecules. With onset of perfusion of the intervillous space at the end of first trimester, fractalkine present at the apical microvillous plasma membrane of the syncytiotrophoblast may mediate close interaction of placental villi with circulating maternal blood cells.

Keywords: fetal-maternal cross-talk, fractalkine, implantation, invasion, trophoblast

Immunohistochemical double staining for fractalkine and CX3CR1 in human term placenta

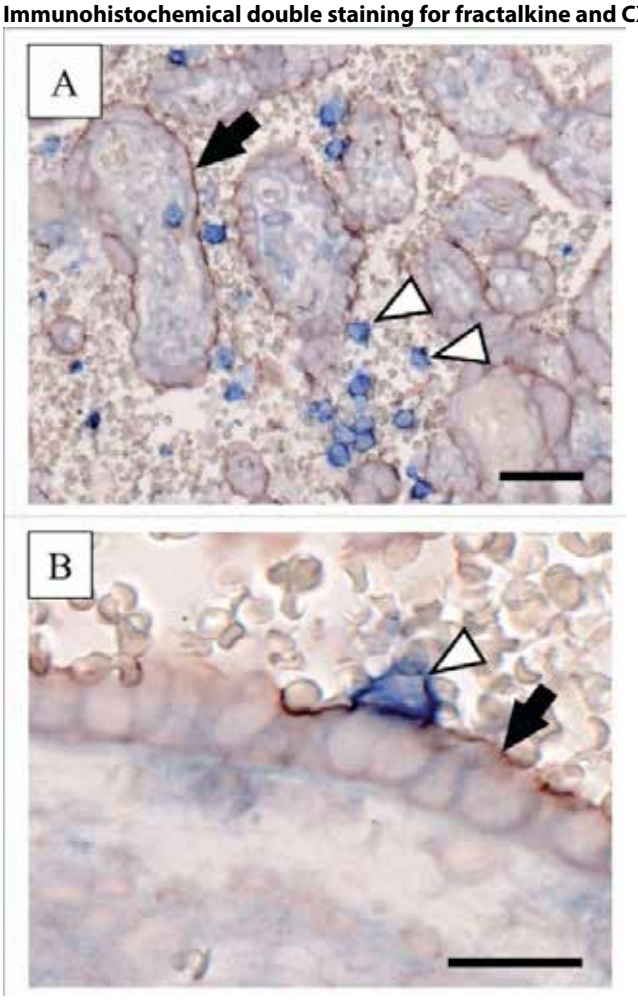

Human term placenta sections (5 µm) were stained with the MultiVision Polymer Detection System (Thermo Scientific), using monoclonal anti-human CX3CL1/ fractalkine antibody (clone 81513, R&D Systems, 1 µg/ml) and polyclonal anti-CX3CR1 antibody (C8354, Sigma-Aldrich, 0.5 µg/ml) (A) Immunohistochemical double staining of human term placenta localized fractalkine at the apical microvillous plasma membrane of the syncytiotrophoblast (red staining; arrow), whereas CX3CR1 was detected on circulating maternal blood cells (blue staining; arrowheads) in the intervillous space. (B) Tight contact of the fractalkine positive syncytiotrophoblast (arrow) and a CX3CR1 expressing maternal blood cell (arrowhead) was occasionally observed and suggest fractalkine/CX3CR1-mediated fetal-maternal interaction. Scale bars in A and B represent 50 µm and 20 µm, respectively.

Immunohistochemical staining for fractalkine and CX3CR1 in human postpartum decidua

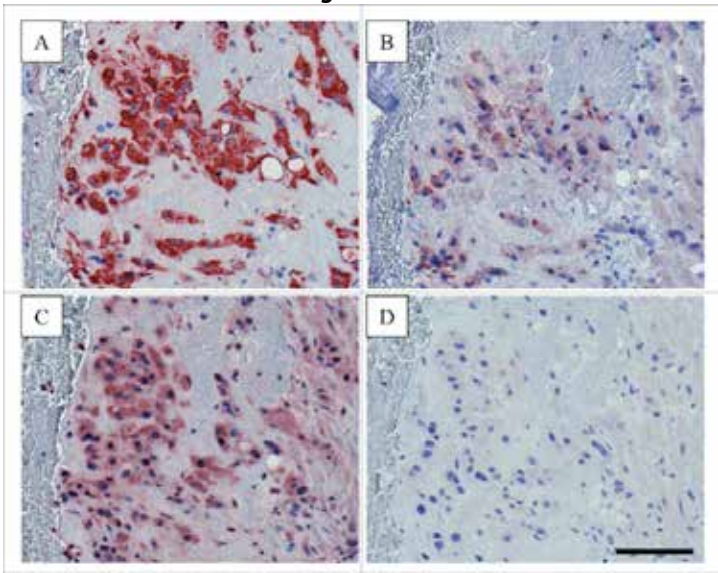

Serial postpartum decidua sections (5 µm) obtained from human hysterectomy were stained for (A) extravillous trophoblast marker HLA-G (using clone 4H84, BD Pharmingen, 0.25 µg/ml working concentration), (B) fractalkine (using monoclonal anti-human CX3CL1/fractalkine antibody, clone 81513, R&D Systems, 1 µg/ml), C) CX3CR1 (using polyclonal anti-CX3CR1 antibody C8354, Sigma-Aldrich, 2 µg/ml) and (D) Negative Control for Rabbit IgG Ab-1 (Neomarkers, Thermo Scientific, 2 µg/ml). Staining was performed using the UltraVision Large Volume Detection System HRP Polymer Kit (Thermo Fisher Scientific) Invading extravillous trophoblasts were positive for fractalkine and CX3CR1. Scale bar represents 100 µm.

Potential roles of fractalkine at different stages of pregnancy

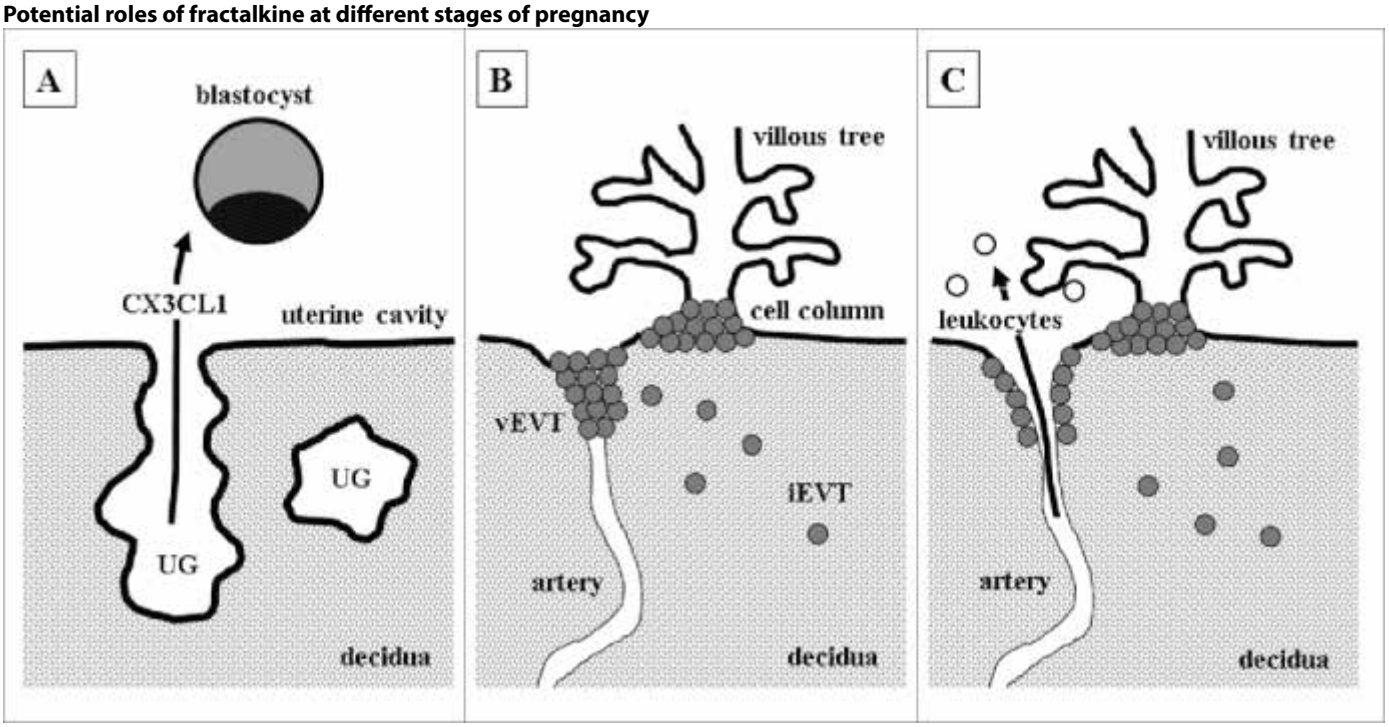

(A) Uterine glands (UG) secrete fractalkine (CX3CL1), which may prime the blastocyst for adhesion to the uterine epithelium and subsequent implantation. (B) After implantation, extravillous trophoblasts (EVT) detach from cell columns and start to invade as interstitial extravillous trophoblasts (iEVT) the decidua. Endovascular extravillous trophoblasts (vEVT) invade uteroplacental arteries and plug them. Fractalkine, either released by decidualized stromal cells, uterine natural killer cells, macrophages or EVT itself, may enhance invasion of vEVT in a paracrine and autocrine manner. (C) Dissolution of endovascular trophoblast plugs at the end of first trimester enables maternal blood flow into the intervillous space. Placental fractalkine, located on the surface of syncytiotrophoblast, mediates adhesion of maternal leukocytes to placental villi.

10.5505/2017ichc.OP-08 [Calcified tissues, biomaterials and regenerative medicine]

Differential Proteomics Analysis of Axolotl's Regenerating Tail

Turan Demircan[1], Ilknur Keskin[2], Gürkan Öztürk[3], Ahmet Tarık Baykal[4]

[1]Department of Medical Biology, International School of Medicine, İstanbul Medipol University, Istanbul, Turkey

[2]Department of Histology and Embryology, School of Medicine, Istanbul Medipol University, Istanbul, Turkey

[3]Department of Physiology, International School of Medicine, İstanbul Medipol University, Istanbul, Turkey

[4]Department of Medical Biochemistry, School of Medicine, Acibadem University, Istanbul, Turkey

Regeneration term is used to define tissue, organ or appendage renewal and functional restoration process of the damaged parts of the body after an injury. Ambystoma mexicanum, commonly named the Axolotl, is one of the unique vertebrates, which has a remarkable ability to regenerate its internal organs, central nervous system and extremities following the amputation. Hence, salamander Axolotl has been gaining importance to be utilized as a model organism for stem cell research due to its powerful regenerative capacity to extend our current understanding on the molecular mechanisms of regeneration. Regarding the shared molecular pathways between amphibians and mammals, the messages from Axolotl research has a great potential to be translated to mammalian studies. Generation of reference genomic, transcriptomic and proteomic datasets would provide a better elucidation of regeneration concept. In this study, we introduce the differential proteome analysis of the Axolotl tail section for day 0, 1,4 and 7 after amputation. Axolotl mRNA sequences were translated to protein sequences and annotated to create a proteome database. Blast of LC-MSMS data to annotated database, 1001 non-redundant proteins were identified. Among these proteins, 465 of them were significantly altered at different time points. Functional classification of identified proteins was performed by gene ontology searches and 32 of significantly changed proteins were found as putative essential players in spinal cord regeneration. To validate the presence of identified proteins, by in-situ antibody labeling was performed. Overall, this work expands the proteomics data of Axolotl and evaluation the underlying regeneration mechanisms to contribute to its establishment as a fully utilized model organism.

Keywords: Axolotl, Tail regeneration, Proteomics

10.5505/2017ichc.OP-09 [Calcified tissues, biomaterials and regenerative medicine]

The Behavior of Menstrual Blood-Derived Stem Cells on Electrospun Polymeric Fibers

Deniz Yucel[1], Hazal Gezmis[2], Secil Demir[2], Gamze Torun Kose[2], Nesrin Hasirci[3], Vasif Hasirci[3]

[1]Department of Histology and Embryology, School of Medicine, Acibadem University, Turkey

[2]Department of Genetics and Bioengineering, Faculty of Engineering and Architecture, Yeditepe University, Turkey

[3]BIOMATEN, Center of Excellence in Biomaterials and Tissue Engineering, Middle East Technical University (METU), Turkey

Tissue engineering aims to develop biological substitutes for damaged tissues to restore, maintain, or improve the structure and function of the tissue. Tissue engineered constructs are composed of cells, preferably the patient's own cells, and scaffolds which mimic the extracellular matrix. The physical and chemical properties of the scaffolds are important to provide the necessary support for cells to attach and proliferate. The fabrication of polymeric nano/micro fibers by electrospinning is a rapidly growing and attractive technique in the field of tissue engineering to prepare scaffolds. Stem cells are ideal cell sources to be used in tissue engineering applications with their ability to differentiate into various cell types. The purpose of this study was to investigate the behavior of menstrual blood-derived stem cells on electrospun polymeric fibers, such as their attachment, proliferation and response to scaffold topography. Random and aligned polymeric fibers were fabricated by electrospinning. Stem cells were isolated from menstrual blood, characterized by flow cytometry and expanded in vitro conditions. Menstrual blood-derived stem cells were seeded on fibrous mats. After culture for certain periods, proliferation of stem cells on electrospun mats was studied using MTS assay. The cell morphology on these scaffolds was investigated by confocal microscopy after FITC-Phallodin and DAPI staining for cytoskeleton and nucleus. Confocal microscopy results demonstrated that menstrual blood-derived stem cells were attached to the fibrous mats and responded to the topography of the scaffolds. Stem cells were spread in all directions on random fibers while the cells were oriented along the axis of the aligned fibers. Proliferation results showed that menstrual blood-derived stem cells were able to grow and increase in number on both electrospun polymeric fibers. The prepared construct composed of polymeric electrospun fibrous mat and menstrual blood-derived stem cells could be a promising approach to be used in tissue engineering applications. Acknowledgements: This study was supported by The Scientific and Technological Research Council of Turkey (TUBITAK) Project No SBAG 113S870.

Keywords: tissue engineering, stem cells, electrospun fibers

10.5505/2017ichc.OP-10 [Calcified tissues, biomaterials and regenerative medicine]

The effect of Electro Magnetic Fields on Stem and Cancer Cell

Ibrahim Mehmet Tuğlu[1], Mehmet Gümüşay[2], Suna Sayğili[1], Şamil Öztürk[1], Mahmut Özkut[1], Işıl Aydemir[1], Adnan Kaya[2]

[1]Department of Histology&Embriology, Manisa Celal Bayar University, Manisa, Turkey

[2]Department of Biomedical Tecnology, İzmir Katip Çelebi University, İzmir

The electromagnetic fields has a great impact for medical treatment. Their effect on medical treatment depends on cell behaviour which can be observed by in vivo and in vitro studies. Their effect on the stem cells and the cancer cell lines and the organs of experimental animals with morphological alterations are helpful to understand cell behaviour. Application of electomagnetic fields cause increase of proliferation, migration and improvement of wound healing with beneficial effects while they cause oxidative stress and cell death. Intrestingy, they reduce proliferation and increase apoptosis for cancer cells in different types of cell line. the effects of electromagnetic fields stimulation depend on the intensity and frequency of the EMF and the time of exposure to it. The minimal side effect with maximum beneficial treatment of these products suggest that they could be very useful for clinical trials.

Keywords: electromagnetic fields, stem cell, cancer cell line, oxidative stres, apoptosis,

10.5505/2017ichc.OP-11 [Cellular aging and cell death]

Biological activities of natural compounds extracted from *rhamnus alaternus* plant

Wissem Bhouri[1], Ines Bouhlel[2], Leila Chekir Ghedira[2]

[1]Institute of Biotechnology Beja, Faculty of Dental Medecin Monastir, Tunisia

[2]Faculty of Dental Medecin Monastir, Tunisia

Medicinal plants are an inexhaustible source of bioactive substances and natural compounds. Indeed, the secondary metabolites are the subject of much research in vivo as in vitro, including the search for new natural constituents such as phenolic compounds. That is why we have undertaken to study the plant Rhamnus alaternus, food plant, but also used in traditional medicine.
The decoction and R 3 O-ir molecule prepared from dried leaves of Rhamnus allow alaternus highlighting substances in these secondary metabolites such as flavonoids.
This study investigated the effects of decoction and R 3 O-ir molecule on the viability of cell lines of melanoma B16-F10 murine and human leukemia R7 and their antioxidant activities. we report that tested compounds inhibits cell proliferations, and enhance antioxidant activities using the cellular antioxidant activity assay (CAA).
In order to look for possible application in the cosmetics field, we studied the effect of decoction and R 3 O-ir molecule on melanogenesis of melanocytes B16-F10 by assessing their effect on the production of intracellular melanin and tyrosinase activity, a key enzyme in the melanin biosynthetic pathway.Furthermore our study demonstrated that tested compounds induces differentiation and stimulates melanogenesis and tyrosinase activity in B16-F10 cells.
A therapeutic effect sometimes may correspond to a better defense of the organism, the immunomodulatory effect of decoction and R 3 O-ir molecule was also investigated. Tested compounds significantly promote LPS-stimulated splenocyte proliferation and enhance humoral immune responses.. In addition, both compounds significantly enhance NK cell and CTL activities.
We conclude from this study that both decoction and R3O-ir exhibited an immunomodulatory effect which could be ascribed, in part, to its cytoprotective capacity via its anti-oxidant activity, and an interested effect on melagenosis cell lines, allows a possible integration of these compounds in cosmetic tanning products.

Keywords: Flavonoids,CAA,immunomodulatory effect,melanogenesis.

10.5505/2017ichc.OP-12 [Cellular aging and cell death]

Endocannabinoid induced apoptotic cell death on endometriotic cells

Elif Bilgic[1], Emine Elif Guzel Meydanlı[2], Irem Akar[3], Sevil Kose[3], Eda Karaismailoğlu[4], Alp Usubütün[5], Petek Korkusuz[1]

[1]Department of Histology and Embryology, Hacettepe University Faculty of Medicine, Ankara, Turkey

[2]Department of Histology and Embryology, Istanbul University Cerrahpasa Medical Faculty, Istanbul, Turkey.

[3]Stem Cell Research and Application Center, Hacettepe University Faculty of Medicine, Ankara, Turkey.

[4]Department of Biostatistics, Hacettepe University Faculty of Medicine, Ankara, Turkey.

[5]Department of Pathology Hacettepe University Faculty of Medicine, Ankara, Turkey

Endocannabinoids are lipid-structured molecules, acting mainly via their classical receptors CB1 and CB2. Endocannabinoids that are located in female genital tract play critical roles by mediating cellular apoptosis and migration (1). The etiopathogenesis of endometriosis which is a common disease presented by pathological ectopic endometrial foci, dysmenorrhea, and infertility is still not clear. Our group has recently studied the occurrence of endocannabinoidal system (2) in endometriotic. On the other hand endocannabinoid system mediated apoptotic mechanisms in endometriosis remain unknown. In this study endometrium adenocarcinoma cell line (Ishikawa), ovarian endometriosis cyst wall cell line (CRL 7566) and normal endometrial stromal cells were cultured with or without classical cannabinoid receptor CB1 and CB2 agonists (ACPA and CB65). The effect of cannabinoid agonists on cell death was investigated by flow cytometry (annexin-V / propidium iodide) and Tunel labeling. Immune labeling studies revealed a significant dose dependent CB1 and CB 2 receptor mediated apoptotic effect for endocannabinoidal system in adenocarcinoma, ovarian endometriosis cyst wall and the normal endometrial stromal cells ($p < 0.001$). In conclusion, endocannabinoids are suggested to play a patogenetic role in endometriosis by effecting apoptosis mechanisms. This may have a potential impact on anti metastatic therapies for endometriotic patients.

*This study was financially supported by Technical and Research Council of Turkey (TUBITAK, SBAG#112S217).

Keywords: Endocannabinoids, endometriosis, apoptosis

10.5505/2017ichc.OP-13 [Cellular aging and cell death]

Effect of folic acid on testicular toxicity induced by bisphenol A in male Wistar rats

Ozay Gules[1], Mustafa Yildiz[2], Zahid Naseer[3]

[1]Department of Histology and Embryology, Faculty of Veterinary Medicine, Adnan Menderes University, Aydin, Turkey

[2]Department of Occupational Health and Safety, School of Applied Sciences at Çan, Çanakkale Onsekiz Mart University, Canakkale, Turkey

[3]Department of Reproduction and Artificial Insemination, Faculty of Veterinary Medicine, Adnan Menderes University, Aydin, Turkey

In the present study, it was aimed to investigate the protective effect of the Folic Acid (FA) against Bisphenol A (BPA) induced toxicity in rat testis. A total of 28 adult male Wistar albino rats were used. The rats were randomly divided into four groups (7 rats per each group). The rats of control group were fed with corn oil (2 ml/kg/day). BPA (50 mg/kg/day) was given to BPA group. FA group was supplemented with FA (20 mg/kg/day). In FA+BPA group, firstly FA (20 mg/kg/day) was provided and 1 hour later the animals were treated with BPA (50 mg/kg/day). The BPA, FA and corn oil applications were administered to through oral gavage for a period of 14 days. At the end of the trial; triple staining method for histological and histomorphometrical examinations was applied to the testis sections. Also, TUNEL method for the analysis of apoptotic cells and immunohistochemical staining method (streptavidin-biotin-peroxidase complex) in order to examine the distribution of spermatogonial stem cells were used. Besides, sperm viability and morphology were examined with Eosin-Nigrosin staining method and the level of serum testosterone was measured. While the seminiferous epithelium height at stage VII-VIII and level of serum testosterone decreased in the BPA group compared to the control group, they increased in the FA+BPA group. Besides, while the number of TUNEL positive cells per tubule and the head, mid-piece and total sperm abnormalities were significantly higher in BPA group compared to control group, they significantly lower in FA+BPA group. Also, percentage of viable sperm was significantly lower in BPA compare to control group but it was significantly higher FA+BPA group. On the other hand, a significant difference wasn't found between groups in terms of spermatogonial stem cell parameters. As a conclusion, it was revealed that the toxic effects of BPA on testis could be minimized by FA protective effect.

Keywords: Apoptosis, bisphenol A, folic acid, histomorphometry, testis.

10.5505/2017ichc.OP-14 [Cellular aging and cell death]

The role of p97/VCP (Valosin containing protein) in mouse Sertoli cell's autophagy and protein degradation

Sevil Cayli[1], Tuba Ozdemir Sanci[1], Cansu Sahin[1], Hilal Nakkas[1], Seda Ocakli[2]

[1]Department of Histology and Embryology, Ankara Yildirim Beyazit University, Ankara, Turkey

[2]Department of Histology and Embryology, Gaziosmanpasa University, Tokat, Turkey

INTRODUCTION: p97/VCP plays critical roles in a broad range of diverse cellular processes including Golgi, endoplasmic reticulum(ER), and nuclear membrane reassembly, ER associated degradation(ERAD), the ubiquitin-proteasome system, cell cycle regulation, DNA repair, autophagosome maturation, and mitophagy. In our previous studies, p97/VCP expression was shown predominantly in Sertoli cells and moderately in germ cells of rat testis during the postnatal development. However, functions of p97/VCP in Sertoli cells were not studied until now. The aim of this study is to investigate the role of p97/VCP in the formation of autophagosome and the degradation of ubiquitinylated proteins in mouse Sertoli cells.
MATERIAL-METHODS: Sertoli cell lines(15P1) was used and maintained in DME supplemented with penicillin/streptomycin, 10% fetal bovine serum. Autophagy was induced with rapamycin(10 µg/ml) in mouse Sertoli cells and the formation of autolysosomes demonstrated with LAMP1 (autolysosomal markers) by using immunofluorescence and Western blotting. The expressional differences of autophagosomal (LC3B and p62) and autolysosomal markers(LAMP1 and LAMP2) in mouse Sertoli cells examined after supression of p97/VCP with proper siRNA's and blocking of p97/VCP activity with specific p97/VCP inhibitor. siRNA transfections were performed with Lipofectamine 2000(Invitrogen) according to manufacturers' protocol. Secondly, ubiquitinylated proteins in the cytoplasm of Sertoli cells evaluated by using immunofluorescence and Western blotting. Thirdly, in order to understand in which step of autophagy p97/VCP function, the interaction between autophagosomal-autolysosomal markers and p97/VCP studied by co-immunoprecipitation and co-localization experiments.
RESULTS: Under basal condition, the expression of p97/VCP, autophagosomal(LC3B and p62) and autolysosomal markers (LAMP1 and LAMP2) were shown in the cytoplasm of Sertoli cells. Loss of p97/VCP activity with VCP inhibitor and silenced p97/VCP(siVCP) results in autophagosome accumulation. After autophagic induction with rapamycin, these autophagosomes fail to mature into autolysosomes and degrade LC3. Autophagosomes (p62 and LC3B) have decreased localization with lysosomal markers (LAMP1) in siVCP-expressing cells and inactivated p97/VCP expressing cells. Additionally, ubiquitinylated protein aggregats significantly increased in siVCP-expressing Sertoli cells. Interaction of p97/VCP and autophagosomal markers (p62 and LC3B) in siVCP and kontrol si-expressing cells were shown by co-immunoprecipitation and immunofluorescence.
CONCLUSION: These data implicate that functional p97/VCP is required for autophagosome maturation and autophagic protein degradation.

Keywords: p97/VCP, Autophagy, Sertoli cell, Protein degradation, mouse

10.5505/2017ichc.OP-15 [Cellular aging and cell death]

Stem cell-induced differential gene expression profiles associated with apoptosis, necrosis and anoikis: Novel insights into cell death mechanisms in prostate cancer

Cuneyd Parlayan[1], Sule Ayla[2], Guvanch Ovezmyradov[3], Gunel Mukhtarova[4], Gulperi Oktem[5]

[1]Department of Biomedical Engineering, School of Engineering and Natural Science, Istanbul Medipol University, Istanbul, Turkey

[2]Department of Histology and Embryology, Faculty of Medicine, Istanbul Medipol University, Istanbul, Turkey

[3]Department of Biostatistics and Medical Informatics, International Faculty of Medicine, Istanbul Medipol University, Istanbul, Turkey

[4]Department of Stem Cell, Ege University Health Science Institute, Ege University, Izmir, Turkey

[5]Department of Histology and Embryology, Faculty of Medicine, Ege University, Izmir, Turkey

Introduction & OBJECTIVES: Cell death evasion in prostate may lead to the development of prostate cancer (PCa) and play key roles to influence PCa progression. Major cell death patterns are apoptosis, ncerosis and anoikis. Apoptosis and anoikis are "programmed" cell death mechanisms that former one is triggered by the healthy cells, and the latter one requires extracelluler matrix re-arrangement, but necrosis occurs rather abrubtly and is a premature cell death. One of the main reasons of oncogenesis is the evation of cell death mechanisms, thus understanding cell death mechanisms are essential to develop proper cancer treatments. Cancer stem cells (CSCs) are known to play critical roles in cell death resistance, traditional therapy resistance and tumor recurrence. Despite of the several research efforts, it is still not clear how CSCs may influence resistance to cell death and tradiational therapies. The aim of our study was to obtain novel insights into how CSCs influence cell death mechanisms in prostate cancer.
Materials & METHODS: We analysed stem cell-induced differential gene expression profiles associated with apoptosis, necrosis and anoikis by utilizing prostate cancer stem cell (Du145 cell line) with or wihtout stem cell treatment, prostate cell line itself and prostate epithelial cell line (RWPE1 cell line). Whole transcriptome sequencing data were comprehensively analyzed by using different bioinformatics tools and platforms including R (Bioconductor), CLC Bio Genomics Workbench version 8.5 (Qiagen), ClustVis (biit.cs.ut.ee/clustvis/), WebGestalt (webgestalt.org). Our results are currently being verified in vitro immunohistochemical methods.
RESULTS: There were 2564, 26, 134 genes found significantly differentially expressed in apoptosis, necrosis and anoikis respectively (Figure 1). Interestingly, there were 6 genes CASP8, CFLAR, BCL2L1, BID, RELA, RIPK1 were common in all three cell death mechanisms. Principle component analysis also indicated clear segregation between CSCs induced group and control group (Figure 2).
CONCLUSION: We found critical interplay within three major cell death mechanisms. Our findings may contribute to deeper understanding of the CSCs and their roles in cell death mechanisms in prostate cancer.

Keywords: Cell death, prostate cancer, stem cell, apoptosis, necrosis, anoikis

10.5505/2017ichc.OP-16 [Developmental and reproductive biology]

Pregnancy with an embryo derived from a germinal vesicle stage oocyte and birth of a healthy baby in a stimulated IVF cycle

Baris Baykal[1], Cem Korkmaz[1], Cihangir Mutlu Ercan[1], Seyit Temel Ceyhan[1], Salih Kozan[2]

[1]ART Centre, Department of Obstetrics and Gynecology, Gulhane Training and Research Hospital, University of Health Sciences, Ankara, Turkey

[2]Department of Medical Genetics, Gulhane Medical Faculty, University of Health Sciences, Ankara, Turkey

Three stages of maturation can be observed in oocytes collected in stimulated cycles: metaphase II, metaphase I and germinal vesicle stages. Germinal vesicle stage (GV) oocytes collected in stimulated cycles are usually thought to have no potential for developing into high grade and implantable embryos. In this case report, we present a clinical pregnancy with an embryo derived from a germinal vesicle stage oocyte and birth of a healthy baby.

In an IVF cycle of a 38 years old patient, who underwent controlled ovarian hyperstimulation with an antagonist protocol, five germinal vesicle stage oocytes were retrieved and they were let mature overnight in a HSA supplemented, bicarbonate buffered medium (G-IVF, Vitrolife, Sweden). The incubation medium was not an IVM medium. Four of the oocytes were matured and they were submitted to ICSI. Embryos derived from mature oocytes were transferred, but the patient failed to conceive on the fresh cycle. After embryo transfer, remaining three of the embryos with 6,7 and 8 blastomeres, derived from GV stage oocytes, were vitrified 72 hours after ICSI.

Three months later, two of the thawed embryos, derived from GV stage oocytes progressed into compact embryos 6 hours after thawing. They were transfered and beta-hCG levels on day 11 and 13 were 96.3 and 183 IU/L respectively. A singleton pregnancy was confirmed with one gestational sac and fetal heart beats during USG evaluation on the 7th gestational week. Amniocentesis was offered to the patient and it revealed normal karyotype. A healthy term male baby is born.

As a conclusion, GV stage oocytes from stimulated cycles can constitute a reserve for poor responder patients who have a few mature oocytes and some GV stage ooctes.

Keywords: GV stage oocyte, non-IVM medium, maturation, fertilization

10.5505/2017ichc.OP-17 [Developmental and reproductive biology]

The Effect of Antioxidants to Angiogenesis on Uterine Transplantation

Tuğba Uğurlu[1], Candan Özoğul[1], Gülistan Sanem Sarıbaş[1], Seren Gülşen Gürgen[2], Seda Nur Akyol[1], Bahar Kartal[3]

[1]Department of Histology and Embryology, Gazi University, Ankara, Turkey

[2]Department of Histology and Embryology, School of Vocational Health Services, Celal Bayar University, Manisa, Turkey

[3]Department of Histology and Embryology, Kafkas University, Kars, Turkey

It is important to maintain the microvascular, cellular and functional integrity of the organ during organ transplantation. Organ preservation solutions should be able to adapt to ischemia-reperfusion injury, reduce cellular damage and inflammation and maintain graft function. HTK (Histidine-Tryptophan-Ketoglutarate) is a widely used preservation solution for static cold storage in organ transplantation, especially with the consideration of lower price and more easy handling aspects. Acetyl L-carnitine acts as an antioxidant, protects against free radicals and prevents mitochondrial damage.

The aim of this study is to investigate the immunohistochemical expression of VEGFR-2 in donor uterus that was stored in HTK and HTK solution combined with Acetyl L-carnitine at different cold storage periods.

We used 24 female rats equally divided into four groups: group 1 had the uterus stored in HTK solution at +4 °C cold storage for 4 hours (h). Group 2, the uterine tissue was stored in HTK solution combined with Acetyl L-carnitine (10-8 M) for 4h at +4 °C. The same procedure with group 1 and 2 were repeated for 24h for groups 3 and 4 respectively. Histological investigation and immunohistochemical analysis were performed.

Histological findings showed that to store donor uterus in HTK solution at +4 ° C for 24h results in histological alteration in uterus. In this group, the epithelial-basal membrane integrity was destroyed. Epithelial cells were separated from the basal membrane and desquamated, cellular debris were observed in the lumen of uterus. In group 4, we observed normal histological structures in all three layers of uterus. We also found that immunoreactivity of VEGFR-2 in all layers of uterus from group 2 was lower than group 1 and these expression in the uterus of group 4 was lower than group 3.

We can concluded antioxidant Acetyl L-carnitine that added to the organ preservation solution HTK, has prevented the formation of free radicals, thus protect the uterus that was stored in short and long cold storage periods.

Keywords: HTK solution, Acetyl L-carnitine, Angiogenesis, Uterus

Figure 1

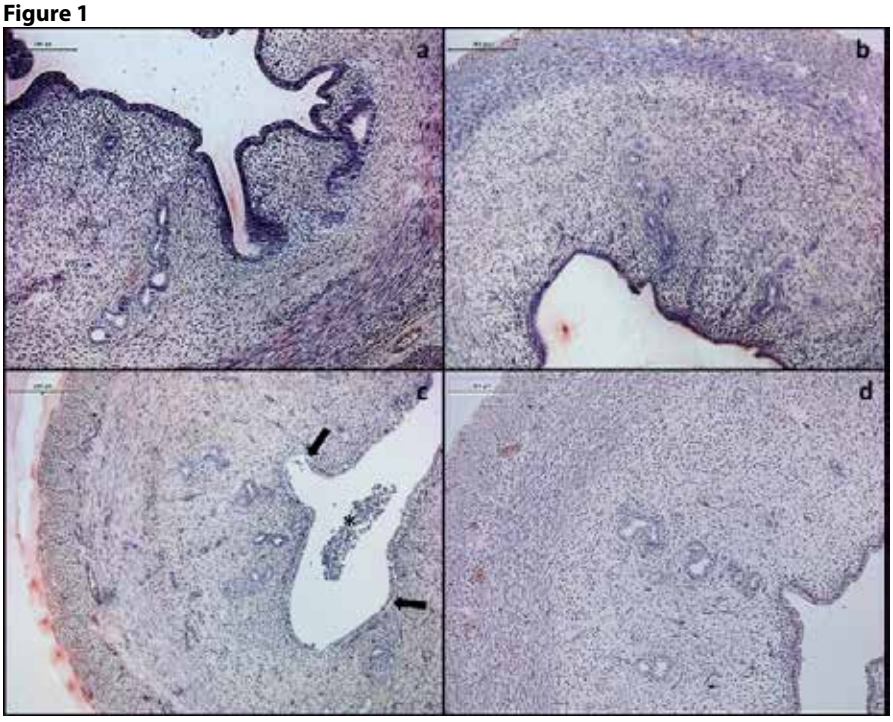

Histologic examination of all the groups. Normal microscopic appearance of the uterus in group 1 (a), group 2 (b) and group 4 (d). In group 3, the epithelial-basal membrane integrity was destroyed (black arrows) and cellular debris in the lumen of uterus (asterisk) (c). (H&E)

Figure 2

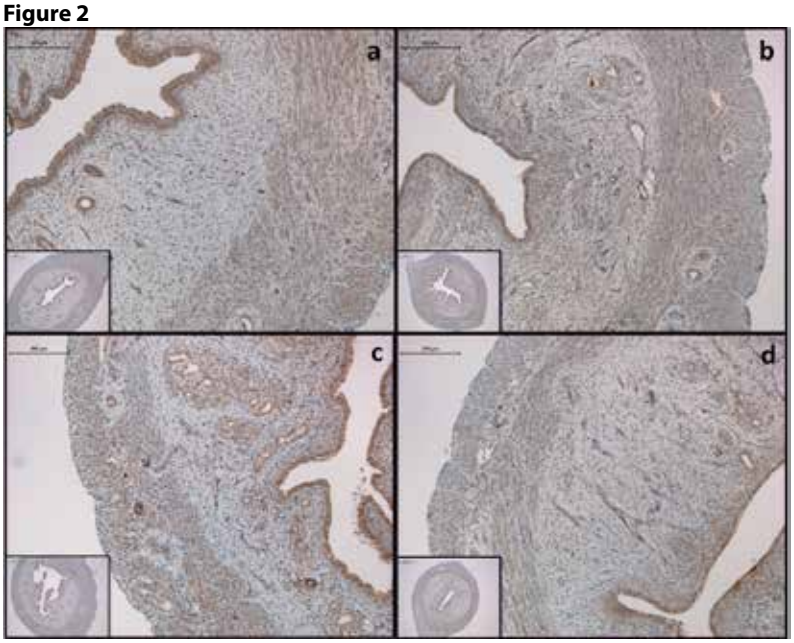

VEGFR-2 immunostaining of the uterus in group 1 (a), group 2 (b), group 3 (c) and group 4 (d). (DAB, Haematoxylin)

Table1

		Luminal Epithelium	Glandular Epithelium	Endometrial Stroma	Endothelium	Myom
Group 1	Mean±SD	3,67±0,52	3,00±0,63	3,17±0,75	3,17±0,41	3,17±0
	Median	4,00	3,00	3,00	3,00	3,00
	Minimum	3,00	2,00	2,00	3,00	2,00
	Maximum	4,00	4,00	4,00	4,00	4,00
Group 2	Mean±SD	2,17±0,41	1,00±0,00	1,17±0,41	1,67±0,52	1,17±0
	Median	2,00	1,00	1,00	2,00	1,00
	Minimum	2,00	1,00	1,00	1,00	1,00
	Maximum	3,00	1,00	2,00	2,00	2,00
Group 3	Mean±SD	3,67±0,52	3,00±0,63	4,00±0,00	3,83±0,41	3,83±0
	Median	4,00	3,00	4,00	4,00	4,00
	Minimum	3,00	2,00	4,00	3,00	3,00
	Maximum	4,00	4,00	4,00	4,00	4,00
Group 4	Mean±SD	1,33±0,52	1,00±0,00	2,50±0,84	3,00±0,63	1,17±0
	Median	1,00	1,00	3,00	3,00	1,00
	Minimum	1,00	1,00	1,00	2,00	1,00
	Maximum	2,00	1,00	3,00	4,00	2,00
p values*	Between groups	**<0,001**	**<0,001**	**<0,001**	**0,001**	**<0,00**
	Group 1-2	0,105	**0,008**	**0,047**	0,054	0,05
	Group 3-4	**0,002**	**0,008**	0,069	0,440	**0,00**

*Immunohistochemical descriptive data of the all groups. Statistically significant is indicated by bold characters, p<0,05. * Kruskal-Wallis and post-hoc analysis*

Acknowledgements This work has supported by Gazi University Scientific Research Project Unit, Ankara, Turkey [grant number:01/2014-07].

10.5505/2017ichc.OP-18 [Developmental and reproductive biology]

Immunohistochemical localization of certain nervous system markers on the testis and epididymis of rat during postnatal period

Feyzullah Beyaz[1], Emel Ergün[2], Mehmet Özbek[2], Levent Ergün[2]

[1]Erciyes University, Faculty of Veterinary Medicine, Department of Histology and Embryology, Kayseri, Turkey

[2]Ankara University, Faculty of Veterinary Medicine, Department of Histology and Embryology, Ankara, Turkey

The aim of this study was to invastigate the immunohistochemical localization of certain nervous system markers such as parvalbumin, synaptophysin, calretinin, drebrin, CNPase, NG2, COX2 and Iba-1 on testis and epididymis of rat during postnatal period using an immunohistochemical method. In experiment, postnatal Wistar albino rats divided four groups. Groups were designed for prepubertal (5 days old), pubertal (20 days old), postpubertal (50 days old) and adult (70 days old). A positive reaction for parvalbumin was in gonocytes at 5 days old rats, in acrosomes of spermatids, residuel bodies and epithelium of ductus epididymis at 50 and 70 days old rats. Immunoreactivity for synaptophysin was seen in peritubular myoid cells and myofibroblasts surrounding epididymal ducts at all ages of rats. Moreover additional labeling was determined as a granular staining in Sertoli cells and apical cytoplasm of principal cells in the epithelium of cauda epididymidis at 50 and 70 days old rats. A positive reaction for calretinin was in gonocytes at the 5 days old rats. Furthermore, acrosome of spermatids, residuel bodies, Leydig cells, cytoplasm of apical, basal and princible cells were stained at 20, 50 and 70 days old rats. Immunoreactivity for CNPase was in gonocytes and Leydig cells at 5 days old rats. Moreover, acrosomes of spermatids, cytoplasm of germ cells, spermatozoa, residuel bodies, Leydig cells and apical cytoplasm of principal cell in ductus epididymis were stained with anti-CNPase primary antibody at 20, 50 and 70 days old rats. A positive immunoreaction for drebrin was seen in gonocytes at the 5 days old rats. Sertoli cells, Leydig cells and spermatozoa in testis and principle cells, basal cells and narrow cells in ductus epididiymis was stained with drebrin at 50 and 70 days old rats. We determined a positive labeling for NG2 in cytoplasm of apical and basal cells in ductus epididymis at 50 and 70 days old rats. This study firstly demonstrates the immunohistochemical expression of certain nervous system markers such as parvalbumin, synaptophysin, calretinin, drebrin, CNPase, NG2, COX2 and Iba-1 on testis and epididymis of rat during postnatal period and discusses their functional relationship.

Keywords: Rat, postnatal period, nervous system markers, Immunohistochemistry, testis, epidisymis

10.5505/2017ichc.OP-19 [Developmental and reproductive biology]

Investigation of obstructive uropathy for histopathologic changes and apoptosis in urinary system of adriamycin-exposed rat fetuses

Sule Yalcin[1], Işık Ünal[2], Elif Kırlı[1], Pergin Atilla[2], Sevda Muftuoglu[2], Ibrahim Karnak[1]

[1]Department of Paediatric Surgery, Hacettepe University Faculty of Medicine, Ankara, Turkey

[2]Department of Histology & Embryology, Hacettepe University Faculty of Medicine, Ankara, Turkey

The aim of this study is to analyse prenatal occurrence of bilateral megaureters with bladder hypoplasia by aid of adriamycin rat model, with investigation of histopathologic changes and apoptosis in urinary system.We suppose to provide additional data for pathophysiology of megaureter and obstructive uropathy association, with the goal of better understanding the correct diagnostic and therapeutic approach. Female Wistar rats were time-mated, and pregnancy was confirmed by positive vaginal smear next morning.Rats(n=30) were injected intraperitoneally with adriamycin and control rats (n=10) were injected with saline on 7, 8 and 9th days of gestation.Fetuses were recovered by cesarian section on the 21st day of gestation,examined for malformations and urinary tract were harvested from kidneys to urethra. Specimens were processed for paraffin embedding,sections were stained with H&E for histopathological evaluation,apoptosis were investigated with TUNNEL. Mann-Whitney-U test was used for statistical analysis.Fetuses in adriamycin group revealed bilateral megaureter, bladder hypoplasia/agenesis, with associated anomalies of renal agenesis, ureter agenesis, short tail in some of them whereas saline group had no associated anomaly.In histopathologic evaluation of saline group kidney, ureter and bladder were observed with their Subcapsular cortical nephrons and juxtamedullary nephrons.Beneath the capsule, a nephrogenic mesenchymal zone was found where new glomeruli in different stages of maturation were present.In adriamycin group,less mature smaller sized glomeruli were evaluated as a undeveloped glomerulus at subcapsullar region.However tubular structures cannot be differentiated as proximal or distal tubules.Juxtamedullary nephrons were almost completed but they were appeared with toxic effect of adriamisin having degenerative cells, detached podocytes &dilatations of capillary.Some glomerules of juxtamedullary nephrons had sloughed podocytes within the enlarged urinary space.Proximal tubule cells revealed eosinophilic cytoplasm,pyknotic nucleus, intracellular vacuolization.Distal tubules had similar degenerative cells.In medulla,collecting ducts appeared with small clustures of degenerative cells within the lumen close to the dilated vasa recta.Ureters and bladder were observed with apoptotic cells within their transitional epithelium and smooth muscle cells.The apoptotic index was calculated for renal cortex,medulla,epithelial-smooth muscle layers of ureter and bladder,for both groups.Apoptotic index was found to be significantly higher in adriamycin group,at layers of bladder epithelium (p:0.003),ureter epithelium-smooth muscle (p:0.04),but there was no significant difference in other parts.

Keywords: Adriamycin, obstructive uropathy, apoptosis

Figure-1

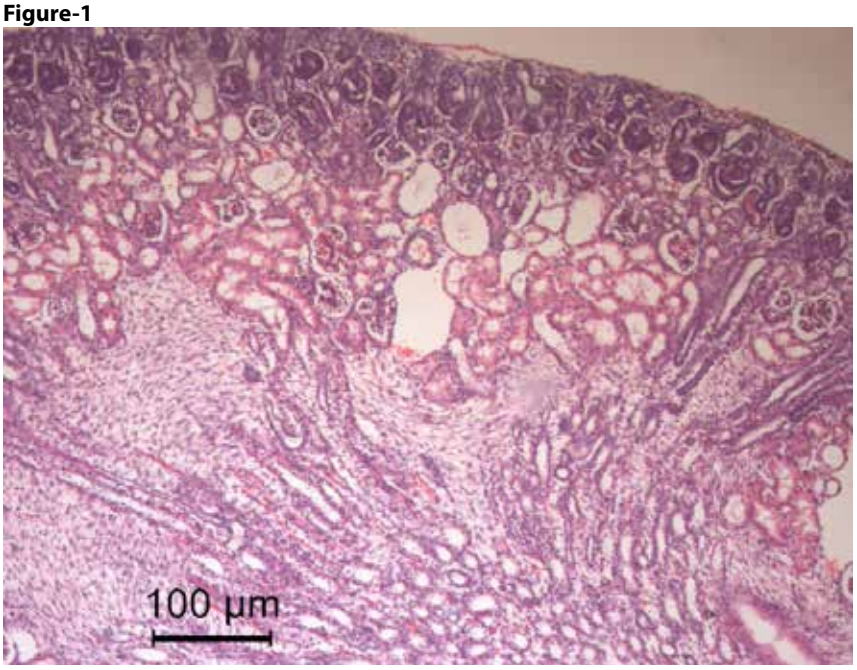

In adriamycin group less mature glomeruli were found in the subcapsuler part of the renal cortex. Proximal tubule cells revealed eosinophilic cytoplasm.There are dilated capillaries between tubules. Kidney, H&E, X200 objective.

Figure-2

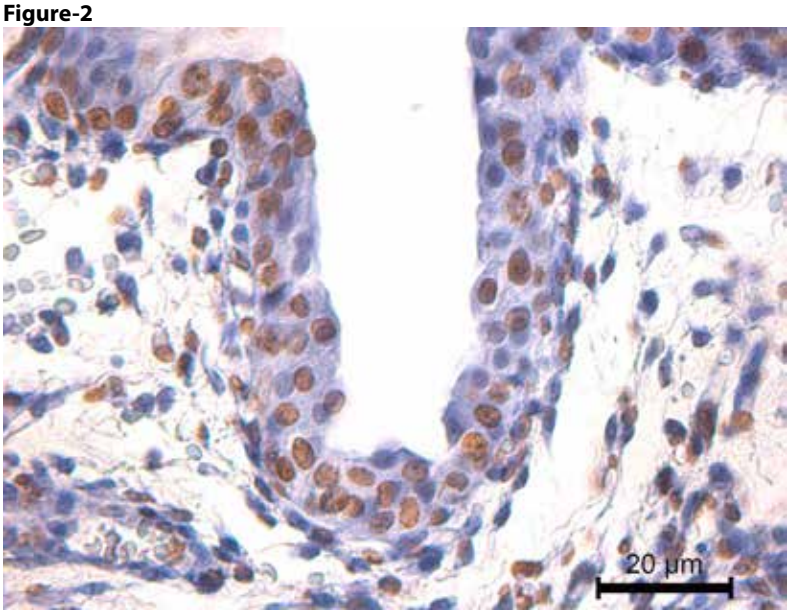

In adriamycin group apoptotic cells within the epithelium of the urinary bladder. Urinary bladder, TUNEL-Hematoxylin, X630 objective.

10.5505/2017ichc.OP-20 [Developmental and reproductive biology]

Histochemical Study of the Ovaries in *Piezodorus lituratus* (Fabricius, 1794) (Heteroptera: Pentatomidae)

Zekiye Suludere, Selami Candan, Irmak Polat, Damla Amutkan, Nurcan Özyurt Koçakoğlu
Department of Biology, Faculty of Science, Gazi University, Ankara, Turkey

Piezodorus lituratus (Fabricius, 1794) (Heteroptera: Pentatomidae) is a widespread species that can be detected in different number of population from Edirne to Erzurum in Turkey. In addition, they exist in Caucasian, China, Iran, Turkistan and Mediterranean countries including Africa. In adult or nymph stage of *P. lituratus*, they can cause the loss of the products owing to feeding with the leafs, roots, seeds or seedlings of the Leguminosea family. Therefore, *P. lituratus* has a great economical importance. The aim of this study is to describe the structure and histochemical features of the ovaries which are the main organs of the female reproductive system in *P. lituratus*.
Adult female specimens of *P. lituratus* were gathered over the wild plants near Ankara in June and July 2016. The ovaries of female *P. lituratus* were dissected out and fixed in Formaldehyde. After fixation, the specimens were washed, dehydrated and embedded in paraffin blocks. The sections were cut at the 6µm thickness from the paraffin blocks and stained with the Mallory's trichrome and PAS-Fast green counterstain. The slides were examined under an Olympus BX51 light microscope and photographed with an Olympus E330 digital camera. The female reproductive system in *P. lituratus* is composed of a pair of ovaries, a pair of lateral oviducts, a median oviduct, spermatheca and accessory glands. Each ovary has 7 ovarioles. Ovarioles are surrounded by a thin sheath. The oocytes in different stages of development can be observed in the ovarioles. The mature oocytes have the chorion outermost and the vitellus inside. The vitellus is PAS positive.
Acknowledgement: We express our thanks to Gazi University, BAP for supporting this research with project number 05/2016-14.

Keywords: Insect, female reproductive system, histology, histochemistry, light microscope

10.5505/2017ichc.OP-21 [Developmental and reproductive biology]

Cytochemical Aspects of Sporoderm Development in *Pancratium Maritimum* L

Sevil Tütüncü Konyar
Department of Biology, Trakya University, Edirne, Turkey

Introduction
In this study, cytochemical alterations of sporoderm (pollen wall), and microspore cytoplasm in *Pancratium maritimum* L. were investigated from free microspore stage to mature pollen grain stages to determine the chemical composition of sporoderm, microspore and pollen cytoplasm. The primary aim of this study was to provide data for embryological and taxonomic studies.
Materials and Methods
Anthers at different stages of development were fixed and embedded in Epon according to the usual method. For light microscopy studies, 1-µm transverse sections were cut using ultramicrotome. Semi-thin sections were stained with toluidine blue for general histological observations, periodic acid–Schiff (PAS) reagent for the identification of insoluble carbohydrates; with Sudan black B for lipids, and with Coomassie brilliant blue for detecting proteins. The transmission electron microscopy was also used to observe the detailed structure of the pollen wall.
Results
PAS test
At the early free microspore stage, ektexine and endexine layer of sporoderm gave positive reaction to PAS test. At the vacuolated microspore stage, both the ektexine and the endexine stained pink but as the development progressed, the stainability of columellae for PAS decreased gradually.
Coomassie brilliant blue test
At the early free microspore stage, in contrast to endexine, the ektexine showed a weak reaction to protein test. However, at the vacuolated microspore and early bicellular pollen grain stages, ektexine also gave a strong reaction to protein test. At mature pollen grain stage, exine layer showed a weak reaction to Coomassie brilliant blue test.
Sudan black B test
At the early free microspore stage, the footlayer of the ektexine presented a weak reaction to lipid test. At the vacuolated microspore stage, only some parts of the ektexine stained black. However, at the early bicellular pollen grain stage, sporoderm gave negative result for lipid test. In mature pollen grains, the ektexine gave positive reaction to Sudan test.
The intine layer gave a strong positive reaction to PAS test and a weak positive reaction to protein test.
Conclusion
The chemical composition of sporoderm shows variations during development. Mature exine contains sporopollenin associated with lipids, a small amount of protein and polysaccharides.

Keywords: Pollen wall, Pollen cytochemistry, PAS test, Sudan Black B, Coomassie brilliant blue

Figure 1

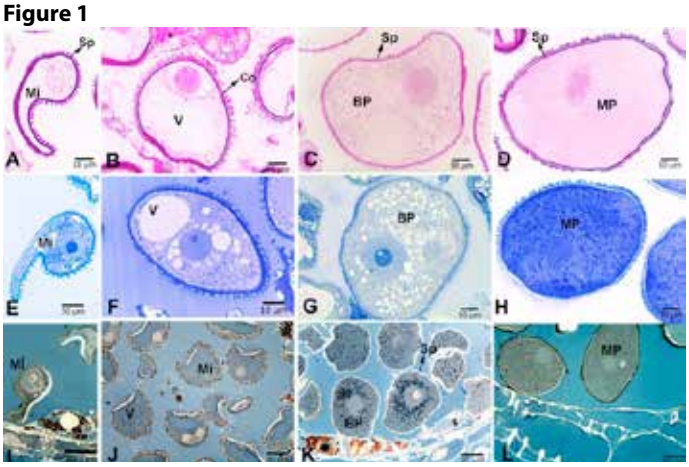

Figure 1: Light micrographs of transverse sections of anthers showing the cytochemical changes occurring in the composition of the sporoderm and microspore/ pollen cytoplasm. A-D PAS staining for insoluble polysaccharides; E-H Coomassie brilliant blue staining for proteins; I-L Sudan black B staining for detecting lipids. A, E, I: Early free microspore stage; B, F, J: Late vacuolated microspore and early bicellular pollen grain stages; C, G, K: Bicellular pollen grain stage; D, H, L: Mature pollen grain stage. (BP: bicellular pollen; Co: columellae; Mi: microspore; Sp: sporoderm; V: vacuole)

10.5505/2017ichc.OP-22 [Pathology and clinical medicine]

The influence of different fixatives and preparation methods on morphology, immunohistochemistry and molecular analyses

Lone Bojesen, Dorte Skriver Jensen, Wojciech Skovrider Ruminski, Nadja Beekhuijen, Reema Butt, Anne Mette Wenning, Birgitte Bols, Estrid Høgdall, Hanne Bjørn
Department of Pathology, Herlev and Gentofte Hospital, University of Copenhagen, Denmark

Formaldehyde is the most commonly used fixative in pathology, but it is carcinogenic and allergenic. Some studies have found that an alcohol based fixative made especially for molecular analysis gives similar morphology, a more intense background staining in the HE stain and varied results in immunohistochemistry staining. DNA and RNA was consistently better preserved and yielded longer fragments.
The aim of this study was to test this on samples from large intestine cut into small biopsies measuring approx. 2x2x4 mm, and fix them for 4 and 6 hours in either 4% neutrally buffered formaldehyde or Tissue Tek® Xpress® Molecular Fixative. We also decided to process them on either Tissue Tek® VIP® 5 or Tissue Tek® Xpress®. We examined the stains HE and Alcian PikroSirius, immunhistochemical analysis CD117, Ki67, Actin SMM-1, CK20 and PMS2. Furthermore DNA quality and quantity were evaluated using fragment analysis and RealTime PCR.
We found that the tissue shrinks in Molecular Fixative in varying degrees. The background staining with Eosin in the HE staining is intensified and the competitive staining of muscle and connective tissue in Alcian PirkoSirius is not optimal. Immunohistochemical staining varies and is largely dependent on the specific antibody; in the 5 antibodies we chose CK20 and PMS2 shows a decline in stainability in tissue fixed in Molecular Fixative, whereas Ki67, Actin SMM-1 and CD117 showed no difference between the different variables. The molecular analysis performed showed a tendency toward a better quality and quantity using Molecular Fixative. Furthermore it has been observed that method of tissue preparation may also influence the molecular results, depending on the analysis performed.
The conclusion is that Molecular Fixative is not optimal for substitution of Formaldehyde as a routine fixative for traditional diagnosis on the examined tissue, but may be superior for molecular diagnostic.

Keywords: Fixatives, processing, Molecular Fixative, Formaldehyde, rapid processing, conventional processing

10.5505/2017ichc.OP-23 [Pathology and clinical medicine]

Structural effects of microneedling and topical retinol palmitate on burn wounds

Elçin Servet Alpat[1], Burak Kaya[1], Hilal Nakkaş[2], Pınar Bayram[3], Şule Kızıl[3], Belgin Can[3], Serdar Mehmet Gültan[1]

[1]Department of Plastic Reconstructive and Aesthetic Surgery, Ankara University, Ankara, Turkey

[2]Department of Histology and Embryology, Yildirim Beyazit University, Ankara, Turkey

[3]Department of Histology and Embryology, Ankara University, Ankara, Turkey

Burns are one of the most important health problems all around the world. In spite of major improvements in burn care during the past 30 years, mortality and morbidity rates of such injuries are still high. Even if the patients survive from burn, their wounds continue to cause a big problem for them. Although there is progress at treatment of burn wounds, there is no consensus on treatment options. In this study we aimed to investigate the effects of microneedling and vitamin A knowing that both have regenerative properties on skin.
24 male Wistar albino rats were divided into 4 groups randomly. After intraperitoneal anesthesia induction, the comb burn model was used to create the burn wound on rat dorsal skin. After 30 minutes, 3 groups received microneedling (Dr group), retinol palmitateplus microneedling (Dr+VitA) and only retinol palmitate (RP group), respectively. No treatment applicated to control group. Microneedling was applied for once and topical RP application was continued all along the study period. At the end of 28 days wounds are photographed for measurement and biopsied for histological investigation. After routine histological procedure tissue samples were analysed under light microscope by Hematoxylene-Eosin, Masson's Trichrome, Periodic Acid-Schiff, Verhoeff-Van Gieson stainings and anti-collagen type 1 and 3 as immunohistochemically. Reepithelization thickness, vascularisation, polymorphonuclear leukocyte infiltration and collagen synthesis and configuration were evaluated.
Wound area decrease was statistically significant only in Dr group animals together with a significant weight regain. Zone of stasis survival was observed clinically only in microneedled groups(Dr and Dr+VitA). Reepithelisation was almost complete in Dr group with a lesser degree of PMNL infiltration and vascularisation compared to other groups. Collagen type 1 synthesis was significant rather than type 3 in microneedled groups. New collagen conformation was similar to healthy skin collagen alignment. RP didn't disclose significant healing effect on any of those investigated properties.
As a result, by this study it is shown that microneedling has beneficial effects on burn wounds healing but more comprehensive studies are needed including different application frequencies and protocols.

Keywords: Microneedling, retinole palmitate, burn wound, stasis zone

10.5505/2017ichc.OP-24 [Pathology and clinical medicine]

Exposure to a continuous 900-MHz electromagnetic field for 1 hour a day throughout middle and late adolescence alters the morphological structure and some biochemical markers of the female rat kidney at postnatal day 60

Derya Öztürk Okatan[1], Ersan Odacı[2]

[1]Etlik Zübeyde Hanim Women's Health Training and Research Hospital Ankara, Turkey

[2]Department of Histology and Embryology, Faculty of Medicine, Karadeniz Technical University, Trabzon, Turkey

Introduction & OBJECTIVES: The effect on human health of the electromagnetic field (EMF) established by cell phones is the subject of major scientific research. This has concentrated largely on the effects on the head and neighboring organs of EMF emitted during cell phone use. However, since these phones are usually carried near the lumbar region (in trouser pockets or attached to belts, for example) when not in use it is inevitable that the kidneys will also be affected by EMF. Cell phones establish more EMF when they first ring, and this will again affect the kidneys. Investigation of the effects of EMF on the kidneys in adolescence is particularly important since cell phone use is greater in adolescence compared to adulthood. We investigated the effects on the kidneys of female rats exposed to a continuous 900-Megahertz (MHz) EMF for 1 hour daily in middle-late adolescence.
Materials & METHODS: Control (CGr), sham (SGr) and EMF (EMFGr) groups of eight animals each were established. 900-MHz EMF was applied to EMFGr rats every day on postnatal days 35-59 inside a cage in the EMF application system. A pseudo-EMF effect was applied to SGr rats. No procedure was performed on CGr rats. All animals were sacrificed on postnatal day 60. Right kidney tissues were subjected to routine procedures, sectioned and stained with hematoxylin and eosin (H&E). Biochemically, malondialdehyde, total antioxidant status (TAS) and total oxidant status were investigated in left kidneys, and the oxidative stress index (OSI) was calculated.
RESULTS: Histopathological analysis revealed no pathology in CGr or SGr. However, findings such as hemorrhage in glomerules, vacuolization and irregularity in the proximal and distal tubule epithelium, diffuse glomerular degeneration and edema, occasional degeneration in Bowman capsules, hemorrhage in the medullary region, impairments in nucleus location and morphology and tubular edema in the cortex were observed in EMFGr. Biochemical results indicated higher TAS and OSI levels in CGr compared to EMFGr and SGr ($p<0.05$) (Table 1).
CONCLUSIONS: Exposure to a continuous 900-MHz EMF for 1 hour daily during middle-late adolescence causes histopathological and oxidative changes in kidney tissue on day 60.

Keywords: Kidney, 900-MHz Electromagnetic field, adolescence, female rat

Table 1. Biochemical data for the control, sham and EMF groups' rat kidney tissues

Biochemical parameters	CGr	SGr	EMFGr
MDA (nmol/mg/tissue)	535.5±34.8876	733.012±94.0761	665.275±109.7082
TOS (µmol H2O2 equivalent / L)	11.1522±0.4737 a	8.2171±0.2271	9.4316±0.361
TAS (mmol Trolox equivalent/L)	1.1056±0.01	1.1167±0.01	1.114±0.0079
OSI	1.0085±0.0416 a	0.7358±0.0191	0.8461±0.0298

**p<0.05; n = 8 in each group; EMF, electromagnetic field; CGr, Control group; SGr, Sham group; EMFGr, EMF group; MDA, malondialdehyde; TOS, total oxidant status; TAS, Total antioxidant status; OSI, oxidative stress index a TAS and OSI levels in CGr increased compared to EMFGr and SGr (p<0.05)*

10.5505/2017ichc.OP-25 [Pathology and clinical medicine]

Functional Characterization of p.T10M and p.S345Y mutations in HNF1A Gene in MODY patients

Özlem Yalçın Çapan[1], Oğuzhan Fatih Baltacı[2], Ece Selçuk Şahin[2], Ergül Berber[1]

[1]Department of Molecular Biology and Genetics, İstanbul Arel University, İstanbul, Turkey

[2]Department of Molecular Biology-Biotechnology and Genetics, İstanbul Technical University, İstanbul, Turkey

Introduction&OBJECTIVES: Maturity-onset diabetes of the young (MODY) is a monogenic form of diabetes mellitus characterized by abnormal beta cell function, autosomal dominant inheritance, hyperglycemia, lack of auto-immunity in non-obese young patients. MODY3 associated with HNF1A gene mutations is the most common form of MODY. HNF1A is a transcription factor that regulates a number of liver-specific genes and genes involved in glucose metabolism. The aim of the study is to functionally characterize the HNF1A gene variations which were identified in MODY patients.
MATERIALS-METHODS: The functional properties of HNF1A gene variations (p.T10M, p.S345Y) which were identified in Turkish MODY patients were analyzed. The effects of the candidate mutations on HNF1A transactivation function were determined by dual luciferase reporter assay. The effects of mutations on the nuclear localization of HNF1A were analyzed by immunofluorescence confocal microscopy. DNA binding activity of mutant HNF1A and wild type proteins were also compared by colorimetric DNA-protein binding assay.
RESULTS: Dual luciferase assay results showed that both p.T10M and p.S345Y mutant proteins have similar transactivation activity as the wild type HNF1A. Immunostaining studies revealed that p.T10M mutant protein localize in the nucleus as the wild type HNF1A while p.S345Y mutant protein is in the cytoplasm. DNA binding ability of both p.T10M and p.S345Y mutant proteins were similar compared to wild type.
CONCLUSION: Preliminary results showed that mutant p.S345Y HNF1A proteins have reduced activities and malfunctions compared to wild type. Future studies will show whether they also effect the insulin secretion from pancreatic cells. This project (113S218) was supported by TÜBİTAK (The Scientific and Technical Research Council of Turkey).

Keywords: Maturity-onset diabetes of the young, Diabetes, HNF1A transcription factor, Nuclear localization

10.5505/2017ichc.OP-26 [Pathology and clinical medicine]

Impairments of oxidant/antioxidant levels and some morphological changes in the adult female rat heart following exposure to a continuous 900-MHz electromagnetic field for 1 hour a day throughout middle and late adolescence

Hatice Hancı[1], Derya Öztürk Okatan[2], Ersan Odacı[1]

[1]Department of Histology and Embryology, Faculty of Medicine, Karadeniz Technical University, Trabzon, Turkey

[2]Etlik Zübeyde Hanım Women's Health Training and Research Hospital Ankara, Turkey.

Introduction & OBJECTIVES: The easy availability of cell phones is constantly lowering the age of their use. Since 37% of people aged 12-17 have cell phones and use levels between the ages of 18 and 24 are as high as 97%, adolescents are more exposed than adults to the electromagnetic field (EMF) emitted. The heart is a vital organ that contracts continuously and can easily be affected by non-contraction or rhythmic stimuli due to its characteristic stimulation properties. The length of the antioxidant cycle in the heart, which consumes oxygen at a low level, is quite short, and it is therefore less protected than other tissues against reactive oxygen radical damage. We therefore investigated oxidant/antioxidant levels in addition to histopathological analyses of heart tissue of female rats exposed to a continuous 10h daily 900-MHz EMF in mid-late adolescence.
Materials & METHODS: Twenty-four Sprague Dawley rats aged 34 days were equally (n=8) divided into three groups. No procedure was performed on the control group (Gr-CNT). The sham group (Gr-SHM) was held in an EMF-cage without EMF exposure. The EMF group (Gr-EMF) was exposed to a 900-MHz EMF for 1 hour daily on postnatal days 35-59. Rats were sacrificed under anesthesia on postnatal day 60, and the hearts were extracted. Malondialdehyde (MDA), 8-hydroxydeoxyguanosine (8-OHdG), nitrotyrosine, catalase, superoxide dismutase and glutathione (GSH) were analyzed biochemically as oxidative stress markers. Total antioxidant status and total oxidant status were investigated and the oxidative stress index was calculated as a predictor of the antioxidant/prooxidant balance. Histopathological damage scores and observations were analyzed in sections stained with hematoxylin and eosin, Prussian blue or Masson's trichrome.
RESULTS: Histopathological analysis in Gr-EMF revealed disorganization in muscle fiber nuclei, diffuse hemorrhage, vacuolization between muscle fibers, cells with pyknotic nuclei tending to apoptosis and muscle fiber degeneration. Biochemical analysis revealed significantly higher MDA, 8-OHdG and GSH values in Gr-EMF compared to the other groups ($p<0.05$) (Table 1).
CONCLUSIONS: Our results show that changes may occur in morphology and oxidative stress biomarkers in the rat heart following exposure to 900-MHz EMF in mid-late adolescence.

Keywords: heart, rat, electromagnetic field, cell phone

Table 1. Biochemical analysis results for female rat heart tissues on postnatal day 60

Biochemical parameters	Gr-CNT	Gr-SHM	Gr-EMF
MDA (nmol/g tissue)	238.2 ± 69.7	251.4 ± 64.6	331.7 ± 99.4 a
8-OHdG (ng/g tissue)	112.7 ± 28.7	130.5 ± 20.8	141.5 ± 22.3 a
3-NT (nmol/mg protein)	0.45 ± 0.11	0.39 ± 0.12	0.49 ± 0.08
CAT (ng/mg protein)	49.1 ± 4.62	47.8 ± 7.96	59.8 ± 15.9
SOD (ng/mg protein)	17.9 ± 3.79	18.1 ± 4.90	21.0 ± 3.06
GSH (mg/g tissue)	11.8 ± 0.92	14.3 ± 3,03	14.4 ± 1.71 a
TAS (mmoltroloxEqui/L)	1.20 ± 0.03	1.38 ± 0.11	1.31 ± 0.08
TOS (µmol H2O2 Equi/L)	7.19 ± 0.31	6.52 ± 0.42	7.37 ± 0.37
OSI	0.59 ± 0.02	0.47 ± 0.03	0.56 ± 0.04

The data represent mean±SEM; (n = 8 for each group); MDA, malondialdehyde; 8-OHdG, 8-hydroxydeoxyguanosine; 3-NT, nitrotyrosine; SOD, superoxide dismutase; CAT, catalase; GSH, glutathione; TAS, total antioxidant status; TOS, total oxidant status; OSI, oxidative stress index; Gr-CNT, control group; Gr-SHM, sham group; Gr-EMF, EMF group a Gr-EMF MDA, 8-OHdG and GSH levels increased significantly compared to Gr-CNT and Gr-SHM ($p<0.05$ and $p<0.05$ respectively)

10.5505/2017ichc.OP-27 [Pathology and clinical medicine]

Effects of propolis against cisplatin induced experimental kidney damage in rats

Esin Yuluğ[1], Sibel Türedi[1], Engin Yenilmez[1], Yüksel Aliyazıcıoğlu[2], Selim Demir[3], Serap Özer Yaman[2], Ahmet Menteşe[4]

[1]Department of Histology and Embryology, Karadeniz Technical University, Faculty of Medicine, Trabzon, Turkey.

[2]Department of Medical Biochemistry, Karadeniz Technical University, Faculty of Medicine,Trabzon, Turkey.

[3]Department of Nutrition and Dietetics, Faculty of Health Sciences, Karadeniz Technical University, Trabzon, Turkey.

[4]Program of Medical Laboratory Techniques, Vocational School of Health Sciences, Karadeniz Technical University, Trabzon, Turkey.

INTRODUCTION &OBJECTIVES: Cisplatin is a chemotherapeutic agent used to treat various types of cancer. Nephrotoxicity is the most prevalent adverse effect of the drug. We investigated the protective effects of propolis against cisplatin-induced kidney injury.
MATERIALS &METHODS: 36 male Sprague-Dawley rats were divided into six equal groups: a control group, receiving 50 mg/kg/day propolis (14 days, p.o.) and 100 mg propolis (14 days, p.o.), single-dose cisplatin (7 mg/kg, i.p), cisplatin (7mg/kg, i.p) + propolis (50 mg/kg/day, p.o., 14 days) and cisplatin (7 mg/kg, i.p) + propolis (100 mg/kg, p.o., 14 days). Rats were sacrificed on the 14th day. Kidney tissues were removed for histopathological and biochemical analyses. Histopathologically, tissues were evaluated in terms of dilation in Bowman's space, tubular dilation, vacuolization and degeneration in tubular epithelial cells, degeneration in glomerular structure and edema. Semi-quantitative scoring between 0 and 4 was performed. Total oxidant status (TOS), total antioxidant status (TAS), oxidative stress index (OSI), ischemia-modified albumin (IMA) and malondialdehyde (MDA) levels were measured in tissue and blood specimens.
RESULTS: Normal morphology was observed in the control, propolis (50 mg/kg/day) and propolis (100 mg/kg/day) groups at light microscopy. Degeneration in tubular epithelial cells, edema and tubular dilation increased significantly in the cisplatin group compared to the control group ($p<0.05$). Glomerular degeneration, vacuolization in tubular epithelial cells and dilation in Bowman's space were observed in the cisplatin group, but these were statistically insignificant. Degeneration in tubular cells and dilation in Bowman's space decreased significantly in the cisplatin + propolis (50 mg/kg/day) and cisplatin + propolis (100 mg/kg/day) groups compared to the cisplatin group ($p<0.05$). Tubular dilation decreased significantly in the cisplatin + propolis (100 mg/kg) group compared to the cisplatin group ($p<0.05$). Serum OSI and MDA levels increased significantly in the cisplatin group compared to the control group ($p<0.05$). Serum MDA levels decreased significantly in the cisplatin+ propolis (50 mg/kg/day) and cisplatin + propolis (100 mg/kg) groups compared to the cisplatin group ($p<0.05$).
CONCLUSIONS: The application of propolis has partial protective effects in cisplatin-induced kidney injury, and these findings need to be supported with further studies involving different doses and durations.

Keywords: kidney, rat, cisplatin, propolis, oxidative stress

10.5505/2017ichc.OP-28 [Techniques in immunohistochemistry]

Differences in Immunohistochemical Localization and Distribution of Galectin 1 and-3 in Rat Testes and Epididymis During Postnatal Development

Emel Ergün[1], Mehmet Özbek[2], Feyzullah Beyaz[3], Levent Ergün[1], Hikmet Altunay[1], Nevin Kurtdede[1], Nuh Yıldırım[1], Özge Özgenç[1]

[1]Department of Histology and Embryology, Faculty of Veterinary Medicine, Ankara University, Ankara, Turkey

[2]Department of Histology-and Embryology, Faculty of Veterinary Medicine, Mehmet Akif Ersoy University, Burdur, Turkey

[3]Department of Histology-and Embryology, Faculty of Veterinary Medicine, Erciyes University, Kayseri, Turkey

Introduction & Objectives: Galectins are a family of carbohydrate-binding proteins (lectins) found in many animal cells and tissues, small molecular weight, which do not require calcium for their functions, and play a role in cell growth, activation, cell-cell and cell extracellular matrix interactions. This study was conducted to determine immunohistochemically galectin 1 and -3 proteins which bind β-galactoside, postnatal developmental localization and expression in the epididymis and testes in healthy rats and to evaluate Leydig cells' the morphological and functional relationship with macrophages in terms of the presence of galectin proteins.
Materials & Methods: Testes and epiydidymis tissues taken from four groups Wistar albino rats at different stages of postnatal development constituted the material of the study. Each of the four groups composed of six rats were designed as prepubertal (5 days), pubertal (20 days), postpubertal (50 days) and mature (70 days). The streptavidin–biotin complex (Strept-ABC) immunoperoxidase technique was employed to detect immunohistochemical localization of galectin 1 and -3 proteins in testes and epididymis. The localization and distribution of these proteins were evaluated according to 14 spermatogenic stage in testes and 3 region [caput (including the initial segment), corpus ve cauda] in epididymis.
Results:Galectin 1 and -3 expression were identified in rat testes during postnatal development, these proteins were expressed different cells and present in epididymis. It was also determined that galectin 1 and -3 proteins synthesis varried according to the stage of postnatal development and the stages of spermatogenesis.
The macrophages and Leydig cells localized close to each other in CD68 immunstaining; while galectin 3 reaction is only seen in macrophages, galectin 1 and galectin 3 reaction both were observed in the Leydig cells.
Conclusions: As a result, it was concluded that both proteins may play a role in the development of the reproductive system, especially the galectin 3 had the effects the storage and mature of spermiyum due to the intense expression in corpus and cauda epididymis in rat.

Keywords: Epidididymis, galectin 1 and 3, immunohistochemistry, rat, testes,

10.5505/2017ichc.OP-30 [Neuroscience]

Revealing Physical and Functional Interaction between p60-katanin and p53

Şirin Korulu
Department of Molecular Biology and Genetics, İstanbul Arel University, İstanbul, Turkey

Microtubules are dynamic polymers and that can be re-organized by assembly and disassembly phases, known as dynamic instability depending on the need of the cell. Besides, microtubule severing proteins such as katanin have roles in microtubule reconfiguration. Katanin is one of the most studied microtubule severing protein and is composed of two subunits, the catalytic subunit p60-katanin and p80-katanin.
Microtubule severing mechanism of p60-katanin has been studied extensively for many years. However, interacting partners of p60-katanin are still very few. There are a few proteins identified so far that physically interact with p60-katanin. We have identified that p53 interacts with p60-katanin and this current study is specifically concentrated on the revealing of p53–p60-katanin structural interaction and the function of this interaction.
To this aim, the cellular localization of the interaction was analyzed. Furthermore, deletion constructs were prepared for both p53 and p60-katanin. To reveal the interacting domains of the proteins, pull down assay was performed for the designed deletion constructs. Finally, to reveal the signaling pathways affected by p53–p60-katanin interaction, comparative genome wide transcriptome analysis was performed for the cells that p53–p60-katanin interaction is both ensured and disrupted.
Since p53 is a critical protein between proliferation and differentiation, and p60-katanin has roles in both proliferation and differentiation, investigating effects of p53 on p60-katanin will shed light on not only the regulation of microtubule severing but also understanding the neurodegenerative diseases which indicate the correlations with reactivation of proliferation and degeneration of neurons and the molecular mechanism of p53-dependent changes of neurite retraction in neurodegeneration.

Keywords: p60-katanin, p53, Immunoprecipitation, Protein Interaction

10.5505/2017ichc.OP-31 [Neuroscience]

Immunohistochemical evaluation of the autoantibodies in surgically treated MTLE-HS patients

Aysegul Firat[1], Fadime Irsel Tezer Filik[2], Isik Unal[3], Burcak Bilginer[5], Figen Kaymaz[3], Figen Soylemezoglu[4], Serap Saygi[2]

[1]Department of Anatomy, Hacettepe University, Ankara, Turkey

[2]Department of Neurology, Hacettepe University, Ankara, Turkey

[3]Department of Histology and Embryology, Hacettepe University, Ankara, Turkey

[4]Department of Pathology, Hacettepe University, Ankara, Turkey

[5]Department of Neurosurgery, Hacettepe University, Ankara, Turkey

Introduction & Objectives
Epilepsy is one of the most common neurologic disease affecting many people worldwide. In many patients etiology is still unknown. In the recent years clinically detected autoantibodies in certain types of epilepsies attracted researches about the possible relation between the autoimmune parameters and epilepsies. In this study our aim was to evaluate the inflammatory parameters of surgically excised fresh frozen human brain samples in mesial temporal lobe epilepsy with hippocampal sclerosis patients.

Materials & Methods
Our study was composed of pathologically and radiologically proven 22 cases of MTLE-HS patients treated and followed in our neurology clinic. The patients were pharmacoresistant to the theraphy and were treated surgically by temporal lobectomy. Their pathological examinations confirmed the diagnosis. Post-surgically, frozen tissues were prepared to be stained with anti-NMDA receptor antibody, anti-Kv4.3 antibody, anti-GAD antibody, anti-NeuN antibody, anti-GFAP antibody and anti-CD3 and anti CD8 antibodies in order to evaluate the immunological parameters semiquantitatively.

Results
In our patient group there were 13 patients with typical sclerosis (HS-1), 2 patients with gliosis and 7 patients with atypical sclerosis (HS-2, HS-3 and HS-3 dysplasia) according to the ILEA classification. We have seen that there was a statistically confirmed difference betwwen CD3 and CD8 levels of patients with typical vs. atypical hippocampal sclerosis. In atypical HS patients there was not any immunoreactivity for the Kv4.3 receptors in both temporal lobe and hippocampus regions and also no immunoreactivity was observed for NMDA receptors in only hippocampus samples.

Conclusions
Immunotherapies of patients with neurological diseases have been changing very rapidly. Such descriptive studies with immunohistochemistry of frozen human tissue samples will help to evaluate the clinical outcome and improve the treatment of the patients. For such reasons we have to expand the patient number and make comparisons with CSF and serum values of the antibodies against neuronal tissues.

Keywords: MTLE-HS, autoantibody,İmmunohistochemistry

10.5505/2017ichc.OP-32 [Neuroscience]

Investigation of dose-dependent ultrastructural alterations after topical lithium treatment in peripheral nevre injuries by transmission electron microscope

Emre Kocman[1], Ilknur Dag[2], Tayfun Sengel[2], Erdem Söztutar[3], Mediha Canbek[4]

[1]Department of Plastic and Aestethetic Surgery, Medical Faculty, Eskişehir Osmangazi University, Eskişehir – TURKEY

[2]Central Research Laboratory, Application and Research Center, Eskişehir Osmangazi University, Eskişehir – TURKEY

[3]Department of Anatomy, Medical Faculty, Yeditepe University, Istanbul-TURKEY

[4]Department of Biology, Faculty of Science, Eskisehir Osmangazi University, Eskişehir – TURKEY

Introduction &OBJECTIVES: Peripheral nevre injuries are common and can be very debilitating leaading to poor quality of life. Contrary to the central nervous system, the peripheral nervous system has a significant capacity for renewal. However the functional outcome of peripheral nerve regeneration is often poor mainly because severed injured peripheral nerves may be too distant from their targets to re-establish a connection. Available treatments remain suboptimal. Lithium has been used for many years to treat bipolar disorder and is approved by the FDA. It has broad neuroprotective effects on the majority of neurodegenerative diseases. This experimantal study was conducted to investigate the ultrastructural effects of topical lithium administration with different doses on peripheral nevre regeneration. Materials &METHODS: Forty-eight adult male Sprague Dawley weighing 250-300 g were used. 10 mm sciatic nerve defect was bridged using a silicone conduit filled with at three different dosages lithium dilution. Animals were randomized into one control group and five experimental groups (n=8/group) administered the following (1) sham; control with no treatment (2)Nerve Autograft; (3)Only silicone conduit; (4)silicone conduit+1,5mEq lithium; (4)silicone conduit+2,5mEq lithium; (5)silicone conduit+5mEq lithium; (5)silicone conduit+15mEq lithium. At 12 weeks, sciatic nerve samples were harvested for transmission electronmicroscopic (TEM) analysis. RESULTS: To the best of our knowledge, this is the first report describing topical lithium administration on peripheral nerve injury area. 15 meq treated groups showed more ultrastructural improvement on electron microscopic studies when compared control groups. CONCLUSIONS: The results of this study revealed that the low and high doses of lithium have different effects in sciatic nerve injury. Lithium may be an effective neuroprotective and regenerative agent at 15mEq doses against peripheral nerve injuries depending on antiapoptotic effects.

Keywords: Peripheral nevre injury, Lithium, Regeneration, Transmission electron microscope

10.5505/2017ichc.OP-33 [Pathology and clinical medicine]

The Ultrastructural Investigation of Slit Diaphragm Protein Expressions and Filtration Barrier Features in Some Human Podocytopathies

Mustafa Yilmaz[1], Kezban Kibar[2], Banu Coşkun Yilmaz[2], Iclal Gürses[3], Ahmet Kıykım[4]

[1]Department of Histology and Embryology, Selcuk University,Konya,Turkey

[2]Department of Histology and Embryology, Mersin University,Mersin,Turkey

[3]Department of Pathology,Mersin University,Mersin,Turkey

[4]Department of Nephrology,Mersin University,Mersin,Turkey

Introduction&OBJECTIVES: Continuous and healthy maintenance of the filtration process in the kidney is possible by preserving the structure of the glomerular filtration barrier. Disruption of this barrier results in glomerular diseases. It seems to be important to understand podocyte injury and changes in slit diaphragm protein expressions for the diagnosis of glomerular diseases., While the prominence of the podocytes and the slit diaphragm in proteinuria is known, the underlying mechanism of this is still unknown. In addition, different results have been found as to whether there is a change in the expression of slit diaphragm proteins in different glomerulopathies. In our study, we aimed to determine changes in slit diaphragm proteins (nephrin, podocin, CD2AP, actin, p-cadherin) in human podocytopathies and to record morphological changes in podocytes and filtration barrier structure at electron microscopic level.
Materials&METHODS: Biopsy specimens of patients who had previously undergone renal biopsy and diagnosed with minimal change disease (MCD), focal segmental glomerulosclerosis (FSGS), membranous glomerulonephritis (MGN) and membranoproliferative glomerulonephritis (MPGN) were studied morphologically by ultrastructural analysis. We also performed immunoelectron microscopic labelling with anti-nephrin, CD2AP, podocin, actin and p-cadherin antibodies.
RESULTS: As a result of the morphological examination, different actin density patterns in different patient groups were seen at the effaced foot process sites of podocytes. This pattern difference dependent on the localization of the primary pathology of disease was assumed to be restricted to the certain pathological territories. We have observed that the filtration barrier and slit diaphragm structures of podocytes are variable in different disease groups. In immunoelectron microscopic staining, protein expressions except actin were decreased at all disease groups compared to the control (Table 1). Strongest labeling for nephrin and podocin was found in the MCD group within all disease groups (Figure 1, 2).
CONCLUSIONS: We think molecular changes in the structure of slit diaphragm are the main determinant of proteinuria. If the slit diaphragm structure is regular and the expression of the proteins is normal then the response to treatment will be efficient as well. As a result we concluded that evaluating these proteins may help in assessing the response to treatment.

Keywords: Actin, CD2AP, Slit Diaphragm, Nephrin, P-Cadherin, Podocin

Figure 1: Nephrin expressions in MCD group (A: X120.000, B: X120.000, C: X150.000, D: X120.000).

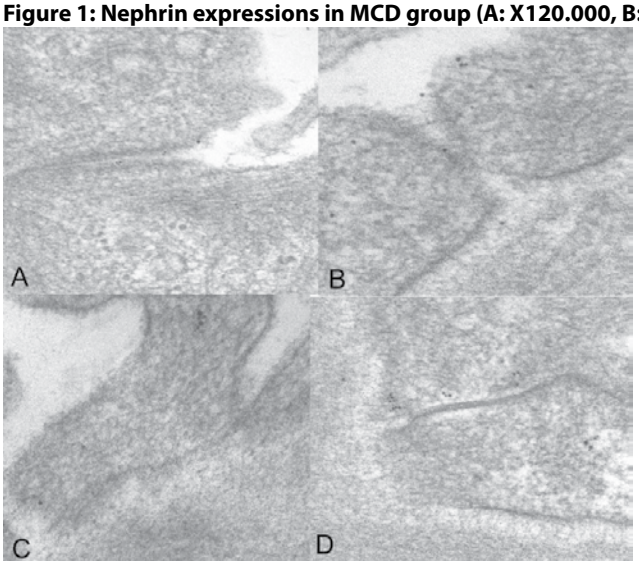

Figure 2: Podocin expressions in MCD group (A: X100.000, B: X120.000, C: X120.000, D: X100.000, E: X120.000, F: X120.000).

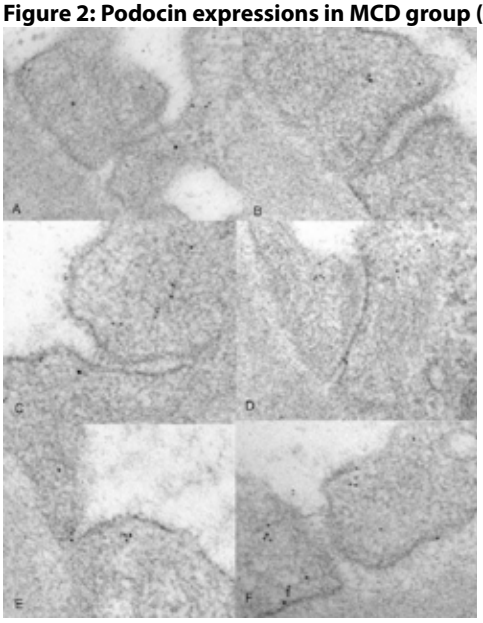

Table 1: Immunoelectron Microscopic Evaluation of Protein Expression Changes in Disease Groups.

Proteins	MCD Group	MGN Group	MPGN Group	FSGS Group
Nephrin	Decreased (+)	Decreased (++++)	Decreased (++)	Decreased (+++)
Actin	Increased (+++)	Increased (++)	Increased (+)	Decreased (++++)
CD2AP	Decreased (++)	Decreased (+++)	Decreased (+)	Decreased (++++)
P-Cadherin	Decreased (+)	Decreased (++++)	Decreased (+++)	Decreased (++)
Podocin	Decreased (+)	Decreased (++++)	Decreased (+++)	Decreased (++)

10.5505/2017ichc.OP-34 [Pathology and clinical medicine]

The role of curcumin in streptozotocin-induced hepatic damage and the trans-differentiation of hepatic stellate cells

Hesham Noaman Abdelraheem Mustafa
Anatomy Department, Faculty of Medicine, King Abdulaziz University, Jeddah, Saudi Arabia.

Diabetic patients frequently suffer from non-alcoholic steatohepatitis. The current study aimed to investigate the role of curcumin and the response of hepatic stellate cells in streptozotocin (STZ)-induced hepatic damage. Sixty male rats were divided into three groups. The normal control injected with a citrate buffer vehicle and the diabetic control group which was injected intraperitoneally (IP) with a single-dose of streptozotocin (50 mg/kg body weight) and a diabetic group was treated with an oral dose of curcumin at 80 mg/kg body weight daily for 60 days.
Results. Curcumin effectively counteracts oxidative stress-mediated hepatic damage and improves biochemical parameters. Alpha-smooth muscle actin (α-SMA) was significantly reduced, and insulin antibodies showed strong positive immunoreactivity with curcumin administration. These results optimistically demonstrate the potential use of curcumin, which is attributed to its antiradical/antioxidant activities and its potential β-cell regenerative properties. Also, it has the capability to encourage the trans-differentiation of hepatic stellate cells into insulin-producing cells for a period of time. In addition, as it is an anti-fibrotic mediator that inhibits hepatic stellate cell activation and the transition to myofibroblast-like cells, this suggests the possibility of considering curcumin's novel therapeutic effects in reducing hepatic dysfunction in diabetic patients.

Keywords: Curcumin, Hepatic stellate cells, Streptozotocin, Lipid peroxidation, Trans-differentiation.

Fig. 1

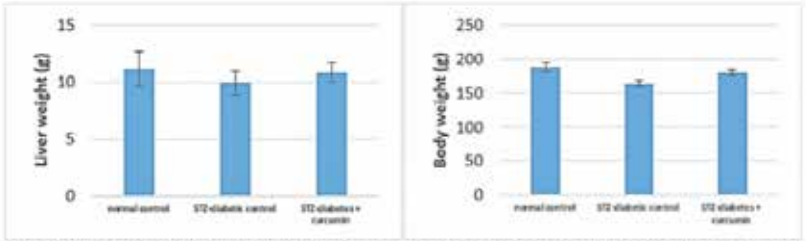

Fig. 1. Body and liver weight of different groups. The mean is given in columns, and error bars represent the standard deviation (SD).

Body and liver weight of different groups. The mean is given in columns, and error bars represent the standard deviation (SD).

Fig. 2

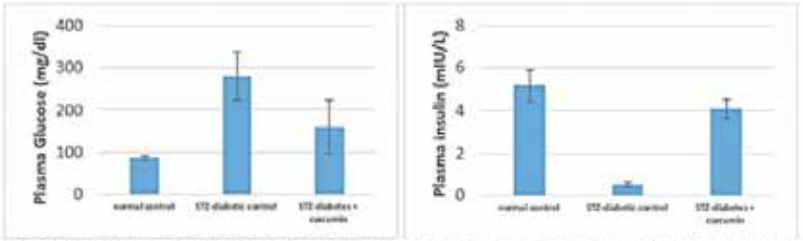

Fig. 2. Plasma glucose and insulin of different groups. The mean is given in columns, and error bars represent the standard deviation (SD).

Plasma glucose and insulin of different groups. The mean is given in columns, and error bars represent the standard deviation (SD).

Fig. 3

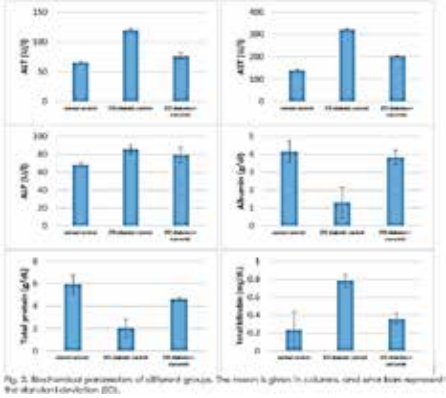

Biochemical parameters of different groups. The mean is given in columns, and error bars represent the standard deviation (SD).

Fig. 4

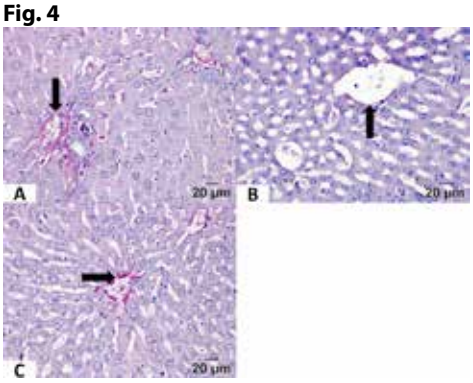

(A) Normal control group showed PAS-positive reaction (distribution of liver glycogen) (arrow); (B) diabetic control group showed few PAS-positive reaction (arrow); (C) curcumin treatment group showed mild PAS-positive reaction (arrow) (PAS, scale bar 20 µm).

Fig. 5

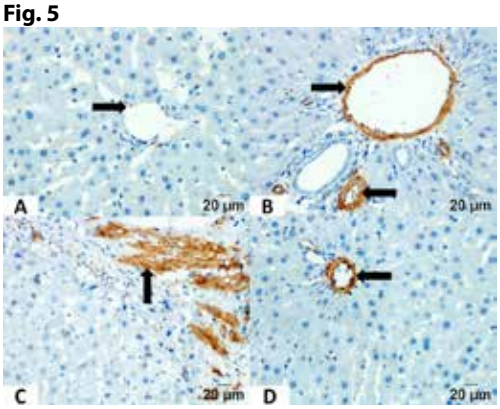

(A) Normal control group showed minimal immunostaining (arrow); (B) diabetic control group showed positive immunostaining (activated HSCs) in the media of the portal blood vessels and scattered in the periportal area (arrow); (C) the previous group with positive immunostained cells in the perisinusoidal spaces (arrow); (D) curcumin treatment group showed mild immunostaining (arrow) (α-SMA, scale bar 20 µm).

Fig. 6

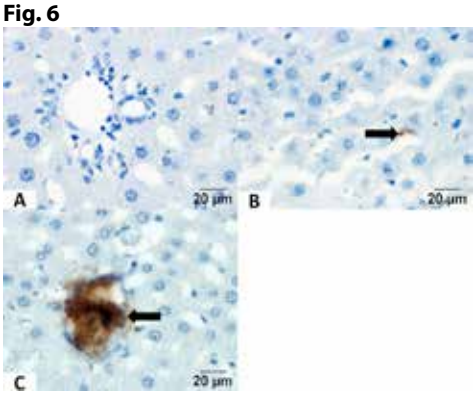

(A) Normal control group showed a negative immune reaction; (B) diabetic control group showed a minimal immune reaction; (C) the curcumin treatment group showed strong positive immunoreactivity (insulin-producing cells) (arrows) (insulin immune reaction, scale bar 20 µm).

Fig. 7

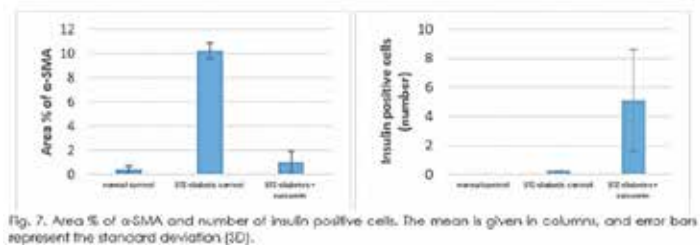

Fig. 7. Area % of α-SMA and number of insulin positive cells. The mean is given in columns, and error bars represent the standard deviation (SD).

Area % of α-SMA and number of insulin positive cells. The mean is given in columns, and error bars represent the standard deviation (SD).

Table 1.

	Normal control (n=20)	STZ-diabetic control (n=20)	STZ-diabetes + curcumin (n=20)
Liver weight (g)	11.14 ± 1.54	9.91 ± 1.04 P*<0.01	10.83±.85 P*>0.05 P**<0.05
Body weight (g)	187.65 ± 6.11	163.94 ± 4.9 P*<0.001	180.47 ± 3.89 P*<0.001 P**<0.001

*Body and liver weight of different groups. Values are means ± SD (n = 20 each group). ANOVA followed by Tukey's post hoc test. *P: compared to normal control. **P: compared to diabetic control.*

Table 2

Parameters	Normal control	STZ-diabetic control	STZ-diabetes + curcumin
Plasma Glucose (mg/dl)	87.14 ± 4.28	280.12 ± 57.24 P*<0.001	160.12 ± 63.27 P*<0.001 P**<0.001
Plasma insulin (mIU/L)	5.17± 0.73	0.54 ±0.11 P*<0.001	4.06 ±0.45 P*<0.001 P**<0.001
ALT (U/l)	65.4±1.2	119.6±2.3 P*<0.001	76.8±4.6 P*<0.001 P**<0.001
AST (U/l)	139.13 ± 3.82	321.35 ± 2.8 P*<0.001	204.68 ± 1.96 P*<0.001 P**<0.001
ALP (U/l)	68.1±2.3	85.2±4.6 P*<0.001	79.5±8.1 P*<0.001 P**<0.01
Albumin (g/dl)	4.14±0.6	1.3±0.87 P*<0.001	3.81±0.4 P*>0.05 P**<0.001
Total protein (g/dL)	5.94±0.89	2.03±0.78 P*<0.001	4.62±0.13 P*<0.001 P**<0.001
Total bilirubin (mg/dL)	0.24±0.20	0.78±0.07 P*<0.001	0.36±0.064 P*<0.05 P**<0.001

*Biochemical parameters of the different groups. Values are means ± SD (n = 20 each group). ANOVA followed by Tukey's post hoc test. *P: compared to normal control. **P: compared to diabetic control. ALT, alanine aminotransferase; AST, aspartate aminotransferase; ALP, alkaline phosphatase; mg/dl, milligrams per deciliter; mIU/L, milli-international units per liter; U/l, units per liter; g/dl, grams per deciliter.*

Table 3.

	Normal control	STZ-diabetic control	STZ-diabetes + curcumin
Hydropic swelling	0	+2	+1
Parenchymatous degeneration	0	+2	+1
Microvesicular vacuole	0	+0.5	+1
Macrovesicular vacuole	0	+0.5	+1
Focal necrosis	0	+2	+0.5
Inflammatory infiltrations	0	+1	+1
Fibrosis	0	+1	+0.5
Sinusoids hyperemia	0	+2	+1
PAS	+3	+1	+2

Histopathological findings of the liver. N = 20; Scale: No (0), mild (+1), moderate (+2), severe (+3).

Table 4.

	Normal control	STZ-diabetic control	STZ-diabetes + curcumin
Area % of α-SMA	0.43±0.28	10.20±0.62 P*<0.001	1.06±0.87 P*<0.01 P**<0.001
Number of insulin positive cells	0.00	0.28 P*>0.05	5.10 ± 3.5 P*<0.001 P**<0.001

*Mean ± SD of the area percentage of α-smooth muscle actin positive cells and the number of insulin-positive cells. Values are means ± SD (n = 20 each group). ANOVA followed by Tukey's post hoc test. *P: compared to normal control. **P: compared to diabetic control.*

10.5505/2017ichc.OP-35 [Pathology and clinical medicine]

Changes in histological structure and biochemical markers in the adult male rat pancreas following exposure to a continuous 900-MHz electromagnetic field for 1 hour a day throughout adolescence

Gökçen Kerimoğlu, Ersan Odacı
Department of Histology and Embryology, Medical Faculty, Karadeniz Technical University, Trabzon, Turkey

Introduction & OBJECTIVES: Cell phones, one of the main sources of electromagnetic fields (EMF) and an indispensible part of verbal and visual communications today, are used by more than half the world population. Their use is increasing among children and adolescents. This widespread use means that cell phones are the main source of exposure to EMF in adolescents. EMF from cell phones can cause oxidative stress in tissues by increasing free oxygen radicals and altering antioxidant defense mechanisms. Oxidative stress resulting from EMF can cause tissue injury by leading to apoptosis or necrotic cell death. Impairment of the morphology, biochemistry or functioning of the pancreas, a vital organ, will inevitably have serious consequences. No previous studies have investigated the effect of a 900-Megahertz (MHz) EMF on the adolescent pancreas. We used histopathological and biochemical methods to evaluate the effects of 900-MHz EMF applied throughout adolescence on the adult rat pancreas.
Materials & METHODS: 24 male Sprague Dawley rats aged 21 days were divided equally into three groups. One group (EMFGr) was exposed to the effect of a 900-MHz EMF inside a Plexiglas cage throughout the adolescent period (days 21-59) for 1 hour at the same time every day. Sham group (SGr) rats were placed inside the cage for 1 hour daily over the same period without being exposed to EMF. No procedure was performed on the control group (CGr). All rats were sacrificed and their pancreases removed at the end of the study. One part of the pancreas was used for biochemical and one for histopathological investigations.
RESULTS: Histopathological examination of sections stained with hematoxylin and eosin revealed no pathology in pancreatic tissues in any group. Islets of Langerhans and acini had normal morphological structures. Biochemically, malondialdehyde (MDA) levels in both EMFGr and SGr increased significantly while superoxide dismutase (SOD) levels decreased significantly compared to CGr. EMFGr glutathione (GSH) levels were statistically significantly higher and catalase (CAT) levels were lower compared to both CGr and SGr (Table 1).
CONCLUSIONS: The effects of oxidative injury in the pancreases of rats exposed to 900-MHz throughout adolescence can appear biochemically in adulthood.

Keywords: Pancreas, oxidative stress, electromagnetic field, male rat

Table 1. Biochemical data for the groups' pancreatic tissues

Biochemical parameters	Control group (CGr)	Sham group (SGr)	EMF Group (EMFGr)
MDA (nmol/mg/tissue)	20.97±0.74	24.44±1.54a	25.33±1.20a
SOD (mmol/min/mg tissue)	0.46±0.03	0.39±0.02b	0.36±0.01b
GSH (nmol/mg/tissue)	0.67±0.02	0.74±0.05	0.87±0.01c
CAT(mmol/min/mg tissue)	69.65±15.52	61.19±13.08	44.27±8.91d

The data represent mean±SD a EMFGr and SGr MDA levels increased compared to CGr ($p<0.01$ and $p<0.01$, respectively) b EMFGr and SGr SOD levels decreased compared to CGr ($p<0.01$ and $p<0.01$, respectively) c EMFGr GSH levels increased compared to CGr and SGr ($p<0.01$ and $p<0.01$, respectively) d EMFGr CAT levels decreased compared to CGr and SGr ($p<0.01$ and $p<0.01$, respectively)

10.5505/2017ichc.OP-36 [Pathology and clinical medicine]

Acute alterations in the morphology and biochemistry of the female rat liver following continuous 900-megahertz electromagnetic field (1 hour per day) administration throughout middle and late adolescence

Derya Öztürk Okatan[1], Ali Kulaber[2], Ersan Odacı[2]

[1]Etlik Zübeyde Hanim Women's Health Training and Research Hospital Ankara, Turkey.

[2]Department of Histology and Embryology, Faculty of Medicine, Karadeniz Technical University, Trabzon, Turkey

Introduction & OBJECTIVES: In addition to their benefits, technological devices also pose threats to human health. Cell phones are one of the main such devices. However, the serious effects on human health of the electromagnetic field (EMF) emitted during cell phone use are still the subject of serious scientific debate. The increasing growth in cell phone use, with adolescents making the most use of these, means that adolescents will inevitably be subjected to greater effects of EMF. EMF can cause oxidative stress and tissue damage by increasing reactive oxygen species and suppressing antioxidant defense system mechanisms. Studies have reported that EMF causes oxidative damage in tissues including the heart, kidney, brain and testes. We investigated the acute effects of 900-megahertz (MHz) EMF exposure throughout mid-late adolescence on the rat liver.
Materials & METHODS: The control (ContGr), sham (ShmGr) and EMF (EMFGr) groups consisted of seven female rats each. A 900-MHz EMF was applied to EMFGr rats every day on postnatal days 35-59 inside an EMF-cage. Sham procedures were applied to ShmGr rats in the same cage. No procedure was performed on ContGr rats. Rats were sacrificed and their livers removed on postnatal day 60. Some liver tissues were subjected to histopathological procedures, sectioned and stained with hematoxylin and eosin. Oxidative stress markers such as malondialdehyde, glutathione, catalase, superoxide dismutase (SOD), 8-hydroxydeoxyguanosine (8-OHdG) and nitrotyrosine were investigated in the remaining tissue. Total antioxidant status (TAS) and total oxidant status were investigated and the oxidative stress index (OSI) was calculated.
RESULTS: Histopathological analysis of sections revealed a normal hepatic morphology in ContGr and ShmGr. EMFGr sections, however, exhibited pathological findings including occasional irregularities in the radial arrangement of hepatocytes, cytoplasmic vacuolization, hemorrhage and sinusoidal expansion, and hepatocyte morphology impairment and edema. At biochemical analysis, EMFGr SOD values were significantly lower compared to the other groups. 8-OHdG values were significantly higher in both EMFGr and ShmGr than in ContGr.
CONCLUSIONS: Exposure to a continuous 900-MHz for 1 hour daily in mid-late adolescence may cause histopathological and biochemical changes in hepatic tissue in the acute period.

Keywords: liver, adolescence, electromagnetic field, female rat

Table 1. Statistical analysis of biochemical data for rat liver tissues

Biochemical parameters	ContGr	ShmGr	EMFGr
MDA (nmol/g doku)	385.5 ± 100.2	420.0 ± 60.1	445.4 ± 88.2
8-OHdG (ng/g doku)	99.5 ± 10.5	142.7 ± 8.9	120.4 ± 13.0 a
3-NT (nmol/mg protein)	0.45 ± 0.03	0.44 ± 0.05	0.47 ± 0.04
CAT (ng/mg protein)	43.9 ± 9.89	44.0 ± 11.2	45.9 ± 8.25
SOD (ng/mg protein)	13.4 ± 3.82	16.5 ± 3.84	11.9 ± 3.64 a
GSH (mg/g doku)	12.9 ± 2.80	14.7 ± 4.69	12.1 ± 3.09
TAS (mmoltroloxEqui/L)	1.13 ± 0.007	1.17 ± 0.02	1.16 ± 0.01
TOS (µmol H2O2 Equi/L)	9.27 ± 0.32	8.42 ± 0.36	8.02 ± 0.48
OSI	0.81 ± 0.02	0.71 ± 0.03	0.69 ± 0.04

The data represent mean±SEM.; (n = 7 for each group); MDA, malondialdehyde; 8-OHdG, 8-hydroxydeoxyguanosine; 3-NT, nitrotyrosine; SOD, superoxide dismutase; CAT, catalase; GSH, glutathione; TAS, total antioxidant status; TOS, total oxidant status; OSI, oxidative stress index; ContGr, control group; ShmGr, sham group; EMFGr, EMF group a EMFG 8-OHdG and SOD levels significantly differences to CG and SG ($p<0.05$ and $p<0.05$, respectively).

10.5505/2017ichc.OP-37 [Pathology and clinical medicine]

A histopathological and biochemical evaluation of oxidative injury in the sciatic nerves of male rats exposed to a 900-megahertz electromagnetic field throughout all periods of adolescence

Gökçen Kerimoğlu[1], Canan Güney[1], Şafak Ersöz[2], Ersan Odacı[1]

[1]Department of Histology and Embryology, Medical Faculty, Karadeniz Technical University, Trabzon, Turkey

[2]Department of Pathology, Medical Faculty, Karadeniz Technical University, Trabzon, Turkey

Introduction & OBJECTIVES: The effects on human health of the electromagnetic field (EMF) emitted by mobile phones, used by 7 billion people worldwide, has become an important subject of scientific research. Studies have suggested that the EMF emitted by mobile phones can cause oxidative stress in different tissues and age groups. Young people in adolescence, when risky behaviors and dependences increase, use mobile phones more than adults. The EMF emitted by mobile phones, which are generally carried in the pocket or in bags when not in use, will very probably affect the sciatic nerve. No previous study has investigated the effect on the peripheral nerve of mobile phone use in adolescence. This study was planned accordingly.
MATERIAL-METHODS: 24 male Sprague Dawley rats aged 21 days were divided equally into control (CGr), Sham (SGr) and EMF (EMFGr) groups. No procedure was performed on CGr rats. EMFGr were exposed to the effect of a 900-megahertz (MHz) EMF for 1 hour at the same time every day from postnatal days 21-59 (the entire adolescent period) inside a cage in the EMF apparatus. SGr rats were placed inside the cage for 1 hour every day without being exposed to EMF. All rats were sacrificed at the end of the study period, and 1 cm sections of sciatic nerve were extracted. Malondialdehyde (MDA), glutathione, catalase (CAT) superoxide dismutase (SOD) values were investigated biochemically in half of the right sciatic nerves tissue. The other halves of the nerve tissues were subjected to routine histopathological tissue procedures, sectioned and stained with hematoxylin and eosin (H&E), and Masson's trichrome.
RESULTS: Histopathological evaluation of preparates stained with Masson's trichrome and H&E revealed a normal appearance in Schwann cells and axons in all groups. However, there was marked thickening in the epineurium of sciatic nerves from EMFGr rats. MDA, SOD ve CAT levels were higher in EMFGr than in CGr and SGr at biochemical analyses. SGr SOD levels were also higher than in CGr (Table 1).
CONCLUSIONS: Exposure to a 900-MHz throughout adolescence causes oxidative injury and thickening in the epineurium in the sciatic nerve in male rats.

Keywords: Sciatic nerve, oxidative stress, electromagnetic field, male rat

A statistical comparison of biochemical analysis results from sciatic nerve tissues from rats in the three study groups

Biochemical parameters	CGr	SGr	EMFGr
MDA (nmol/mg tissue)	13.68 ± 0.90	14.66 ± 0.37	20.31 ± 1.85a
SOD(mmol/min/mg tissue)	0.04 ± 0.00	0.09 ± 0.06b	0.21 ± 0.03c
GSH(nmol/mg/tissue)	0.55 ± 0.01	0.58 ± 0.02	0.57 ± 0.04
CAT(mmol/min/mg tissue)	45.96 ± 7.89	57.81 ± 7.52	116.18 ± 21.87d

The data represent mean ± SD; CGr, Control group, SGr, Sham group; EMFGr, EMF group; MDA, malondialdehyde; GSH, glutathione; CAT, catalase; SOD, superoxide dismutase a EMFGr MDA levels increased compared to CGr and SGr (p = 0.004 and p = 0.004, respectively) b SGr SOD levels increased compared to CGr (p = 0.01) c EMFGr SOD levels increased compared to CGr and SGr (p = 0.004 and p = 0.01, respectively) d EMFGr CAT levels increased compared to CGr and SGr (p = 0.004 and p = 0.004, respectively)

10.5505/2017ichc.OP-38 [Pathology and clinical medicine]

The risk assessment of Gd2O3:Yb3+/Er3+nanocomposites as dual-modal nanoprobes for magnetic and fluorescence imaging

Long Huang[1], Fukang Xie[1], Li Li[2]

[1]Department of Histology and Embryology, Zhongshan School of Medicine, Sun Yat-sen University, Guangzhou510080, People's Republic of China

[2]State Key Laboratory of Oncology in South China, Imaging Diagnosis and Interventional Center, Sun Yat-sen University Cancer Center, Guangzhou510060, People's Republic of China

Our group has synthesized Gd2O3:Yb3+/Er3+ nanocomposites as magnetic/fluorescence imaging successfully in the previous study, which exhibit good uniformity and monodispersibility with a mean size of 7.4 nm. However, their systematic risk assessment remains unknown. In this article, the in vitro biocompatibility of the Gd2O3:Yb3+/Er3+ was assessed on the basis of cell viability and apoptosis. In vivo immunotoxicity was evaluated by monitoring the product of reactive oxygen species (ROS), clusters of differentiation (CD) markers, and superoxide dismutase (SOD) in Balb/c mice. No significant differences were found in cell viability, apoptosis, and immunotoxicity between our Gd2O3:Yb3+/Er3+ and gadodiamide which are used commonly in clinical. Few nanoprobes were localized in the phagosomes of the liver, heart, lung, spleen, kidney, brain, and tumor under the transmission electron microscopy (TEM) images. In addition, our products reveal good T1-weighted contrast enhancement of xenografted murine tumor. Therefore, the above results may contribute to the effective application of Gd2O3:Yb3+/Er3+ as molecular imaging contrast agents and dual-modal nanoprobes for cancer detection.

Keywords: Nanocomposites, Biocompatibility, Immunotoxicity, Magnetic resonance imaging, Tissue targeted imaging, Health effects

10.5505/2017ichc.OP-39 [Pathology and clinical medicine]

Lipopolysaccharide-Induced Liver Damage is prevented by Ginkgo Biloba Extract 761 and Flunixin Meglumin in Septicemia

Tuba Parlak Ak[1], Burcu Gül Baykalır[2], Ismail Seven[3], Gürdal Dağoğlu[4], Mine Yaman[5]

[1]Department of Nutrition and Dietetics, Munzur University, Tunceli, Turkey

[2]Department of Nursing, Fırat University, Elazığ, Turkey

[3]Department of Plant and Animal Production, Fırat University, Elazığ, Turkey

[4]Deparment of Pharmacology and Toxicology, Fırat University, Elazığ, Turkey

[5]Deparment of Histology and Embryology, Fırat University, Elazığ, Turkey

Oxidative damage has an important role in lipopolysaccharide (LPS)-induced sepsis. Ginkgo biloba extract 761 (EGb 761) has been reported to be a potent antioxidant. The aim of this study was to evaluate the possible modulatory effects of EGb 761 on the changes caused by LPS *E.coli O55:B5 serotype*-induced sepsis in the rat liver. Groups that consisting of six adult male Spraque-Dawley rats each were divided into control, LPS, Flunixin Meglumin, EGb 761, LPS plus Flunixin Meglumin and LPS plus EGb 761. All administrations were injected intraperitoneally and the study lasted seven days. Oxidative stress and serum parameters, tumor necrosis factor alpha (TNF-<), prostaglandin E2 (PGE2) and interleukin-1beta (IL-1ß), hepatic histological characteristics, feed intake, body weight and changes were evaluated in this study. The malondialdehyde (MDA), urea, aspartate aminotransferase (AST) and alanine transaminase (ALT) ($p<0.01$); glucose, creatinine, total cholesterol, triglyceride, high density lipoprotein (HDL), very low density lipoprotein (VLDL) ve low density lipoprotein (LDL) increased ($p<0.05$), while glutathione level (GSH) and superoxide dismutase (SOD) activity ($p<0.01$); catalase (CAT) activity, albumin and total protein decreased significantly in LPS group ($p<0.05$). In addition, MDA levels were reduced ($p<0.01$), but levels of GSH, SOD and CAT activities were increased significantly in LPS plus EGb 761 group. Serum TNF-α, IL-1β and PGE2 levels were increased significantly in LPS group compared with control group ($p<0.001$). These levels were decreased significantly in LPS plus EGb 761 and LPS plus Flunixin Meglumin groups compared with LPS group ($p<0.001$). LPS administration was observed histopathologically to cause significant increases necrotic, infiltrative and haemorrhagic changes as well as caspase-3 positive apoptotic cells in liver when compared with control group. Administrations of treatment agents plus LPS were minimized these histopathological changes and induced apoptosis in liver and normalized. In point of feed intake, body weight, and body weight changes were no significant differences ($p>0.05$). The study results show that LPS-induced sepsis may lead to severe liver damage, affecting both structure and function. Treatment of EGb 761 ameliorated the biochemical and pathological alterations on liver damage LPS-induced. Consequently, EGb 761 which has anti-inflammatory and antioxidant effect may be protects largely against this damage.

Keywords: LPS, sepsis, EGb 761, liver, oxidative stres, caspase-3

10.5505/2017ichc.OP-40 [Pathology and clinical medicine]

Immunohistochemical Evaluation of Effects of Bevacizumab on Radiation Injury After Stereotactic Radiosurgery

Ayfer Aslan[1], Alp Ozgun Borcek[1], Zeynep Bengisu Kaya[2], Ozgur Ocal[3], Erkut Baha Bulduk[4], Ozge Petek Erpolat Tater[5], Murat Uçar[6], Figen Kaymaz[2]

[1]Gazi University, Department of Neurosurgery, Ankara

[2]Hacettepe University, Department of Histology and Embryology, Ankara

[3]Yenimahalle State Hospital, Department of Neurosurgery, Ankara

[4]Eskişehir State Hospital, Department of Neurosurgery, Eskişehir

[5]Gazi University, Department of Radiation Oncology, Ankara

[6]Gazi University, Department of Radiology, Ankara

Stereotactic Radiosurgery (SRS) is used in treatment of brain pathologies. There are side effects as radiation injury characterized with edema and necrosis at peripheral normal tissue. These side effects are related with especially vascular damage and expression of mediators like vascular endothelial growth factor (VEGF). Bevacizumab, an anti-VEGF monoclonal antibody, is thought to be the most effective medicine to reduce these side effects. The aim of this study, to form experimental model in rats to describe effects of bevacizumab, following Gamma knife surgery (GKS) with different doses and to compare results of prophylactic and delayed onset use of bevacizumab.
54 adult Whistar rats are divided into nine groups according to two different SRS doses (%50 isodose 50 Gy and 100 Gy) and two different protocols of bevacizumab treatment (prophylactic and delayed onset). Rats were examined physically, neurologically, radiologically and immunohistopathologically. Rats were sacrified after 12 weeks of examination and then their right frontal lobes are used for immunohistochemistry. Hematoxylin and eosin (H&E) staining and VEGF and CD31 antibodies are used for immunohistochemistry. Immunohistochemical labeling for both antibodies at around necrosis and necrosis-free peripheral areas are evaluated by counting five areas in X40 magnification. Groups were compared statistically.
In irradiated animals, parenchymal color and consistency changes were observed in the right frontal lobe macroscopically. Parenchymal tissue loss and edema were seen in right frontotemporal region on MRI sections. Parenchymal tissue loss was assessed with histopatlogical study by considering neuron and glial cells loss, congestion, edema, vascular telangiectasia, and hemorrhage (Table 1), then classified (Table 2). Normal cortex and medulla structures were observed in Control, Treatment Only and Prophylaxis Only groups. In the GKS 50 Drug-free, Treatment, Prophylaxis and GKS 100 Drug-free, Treatment, Prophylaxis groups; parenchymal tissue loss, edema, neuron loss and decreased glia cells in necrosis area were observed. At the surrounding tissue of necrosis area, congestion, haemorrhage, and edema was detected. Immunohistochemical findings were found to be consistent with H & E findings.
As conclusion, degree of radiation injury was depended on bevacizumab protocol type. Although bevacizumab decreased radiation injury, this effect was only after prophylactic onset.

Keywords: Bevacizumab, Brain Radiation Injury, Stereotactic Radiosurgery, Vascular Endothelial Growth Factor (VEGF), CD31, Immunohistochemistry

GKS 50 DF5 VEGF x40



VEGF labeling

GKS 50 T3 VEGF x10

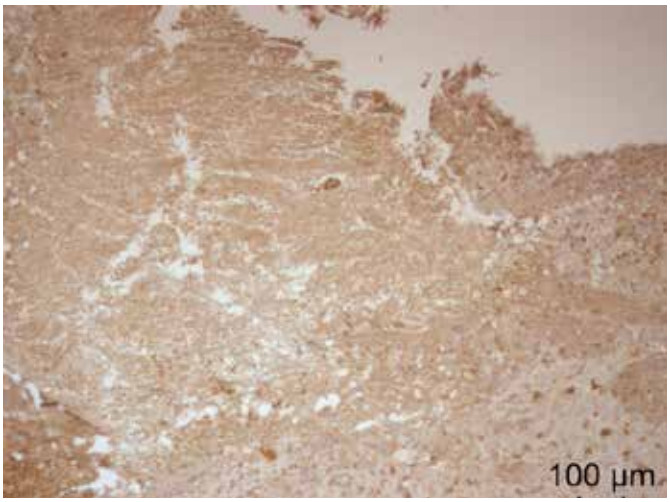

Necrosis area

TO5 CD31 x40

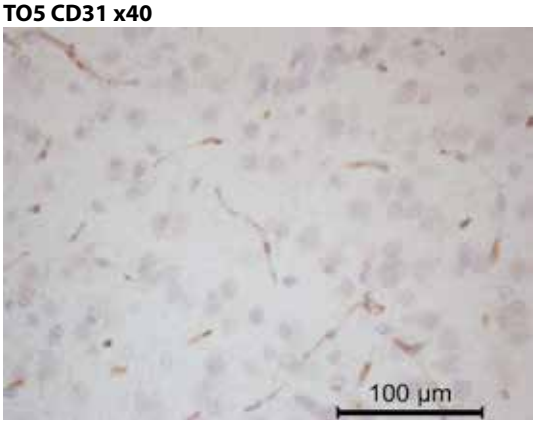

CD31 labeling

Table 1

Parameter / Severity	Absent		Prominent	Strong	Very Strong
Loss of neurons	0	1	2	-	-
Decrease of glia cells	0	1	2	-	-
Congestion	0	1	2	3	4
Edema	0	1	2	3	4
Vascular telangiectasia	0	1	2	3	4
Hemorrhage	0	1	2	3	4

Table 2

Grade	Total Score
Grade 0	0
Grade 1	1-5 points
Grade 2	6-10 points
Grade 3	11-15 points
Grade 4	16-19 points
Grade 5	20 points

10.5505/2017ichc.OP-41 [Stem cells]

The Role of Stem Cell on The Reproductive organs

Ibrahim Tuğlu, Işıl Aydemir, Mahmud Özkut, Fatma Öztürk, Alican Gümürdü, Rehime Ablumiti, Dila Sal
Dept. of Histology & Embryology, Faculty of Medicine, Celal Bayar University, Manisa, Turkey.

Infertitility is considered as a major health problem of recent century. Importance of stem cell is increasing so it is searched new features and supposed to be involved in the infertitility treatment where oxidative stress and apoptosis play importany role. We aimed to investigate the beneficial effect of the stem cells related to free radicals and cell death on testis and ovary. Biopcy model of wound healing was created in the rat testis and ovary with PPD syringe where stem cells were delivered by injection. Rats were divided into four groups including controls, sham, wound healing and wound healing with stem cell. After the creation of the wound, bone marrow-derived mesenchymal stem cells from the tibia of the mature rats and medium were administered to ovaries and testes. Following the applications, ovary and testis samples were investigated for oxidative stress and apoptosis by immunohistochemistry. In comparison with the medium and stem cell applications without a medium support, it was meaningfully determined that healing effect in testicles and ovaries were spotted specifically on the 7.day. Tissues were analysed for these staining by H-score and H-score results were determined using One-Way ANOVA test statistically. Our results show the positive effects which clinic applications can bring by displaying the great contribution of the stem cell application in the treatment of testicle and ovary damage. These findings suggest that transplantation of the mesenchymal stem cells may help to promote better enviroment for the reproductive organs by the effect on oxidative stress and apoptosis. The further studies of these results in the molecular level can lead the way to solve the problem of infertility, to increase the percentage of success in the IVF and ICSI techniques and more importantly to perform a differentiation from a somatic cell to a germ cell.

Keywords: Infertility, mesenchymal stem cells, testes, ovary, oxidative stress, apoptosis.

10.5505/2017ichc.OP-42 [Stem cells]

Optimizing Hydroxy Apatite Based Scaffold with Harmony of Stem Cells for Tooth Tissue Engineering

Alev Cumbul[1], P.neslihan Taşlı[2], Gül Merve Yalçın Ülker[3], Ünal Uslu[1], Fikrettin Şahin[2]

[1]Department of Histology and Embryology, Yeditepe University, Faculty of Medicine, Istanbul Turkey

[2]Department of Genetics and Bioengineering, Yeditepe University, Faculty of Engineering and Architecture, Istanbul Turkey

[3]Department of Oral and Maxillofacial Surgery,Okan University, Faculty of Dentistry, Istanbul, Turkey

INTRODUCTION: A key experimental trial in the regeneration of large oral and craniofacial defects is the neogenesis of osseous and ligamentous interfacial structures. Currently, oral regenerative medicine strategies are unpredictable for repair of tooth supporting tissues destroyed as a consequence of trauma, chronic infection or surgical resection.
METHODS: Here, this study shows mimicking immature tooth at the late bell stage design and construction of Hydroxy Apatite (HA) scaffolds for cell transplantation of human Adipose Stem Cells (hASCs), human Bone Marrow Stem Cells (hBMSCs) and Gingival Epitelial cells for the formation of human tooth dentin-pulp-enamel complexes in vitro (Figure 1). After 8 weeks, developing tooth scaffolds were excised, fixed in 4% formalin, embedded in paraffin and thin-sectioned. 0th, 4th, and 8th week samples were collected and stained. Analyses included: Hematoxylin and Eosin Y (H&E). Immunohistochemical analysis was performed to determine cell morphologies and immature tooth at the late bell stage with bone mophogenic protein 2, 4, 7 (BMP 2, 4, 7), amelogenin, collagen type 1 (COL1A), dentin matrix protein 1 (DMP 1), dentin sialo phosphoprotein (DSPP), vascular endothelial growth factor (VEGF) and Msx 1. Immunohistochemical staining to tooth shaped scaffold at the 0th 4th and 8th weeks were performed on paraffin sections. The biological contraction of dental tissues against each other was demonstrated by mRNA gene expressions, histopatologic observations and protein release profile by ELISA technique.
RESULT: The newly formed tissue like structures that grow and integrate within the HA designed constructs forming tooth cementum like tissue, pulp and bone structures (Figure 2, 3). These findings are important as they emphasize the potential biological effect of the hybrid scaffold system. This method also suggests potential for the clinical application of personalized tooth constructs that may allow regeneration of multi tissue lines essential for oral, dental and craniofacial engineering applications.

Keywords: Tooth Tissue Engineering, stem cell, Hydroxy Apatite Based Scaffold

figure 1

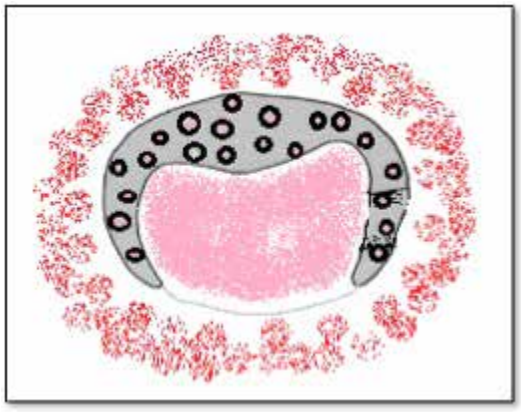

Figure 1. In vitro tooth shaped construct demonstration.

Figure 2

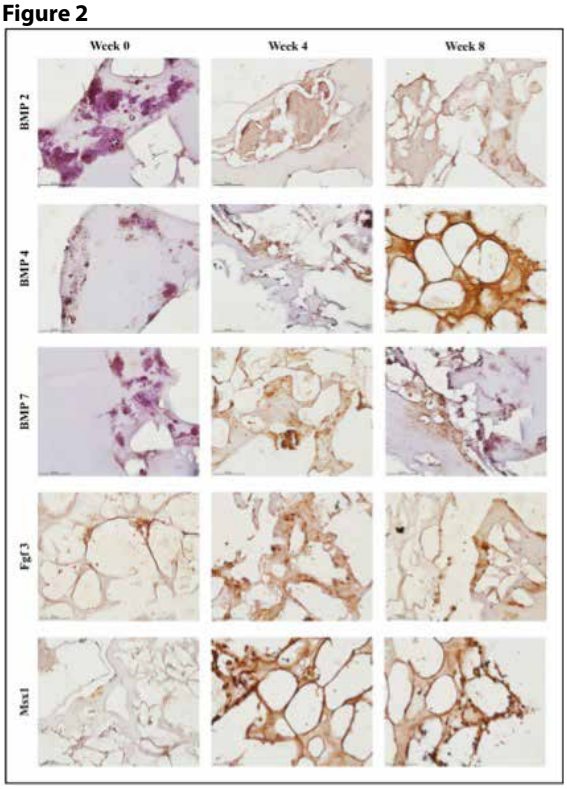

Figure 2. Specilized structures of cells seeded on HA hybrid scaffols for 8 week.

Figure 3

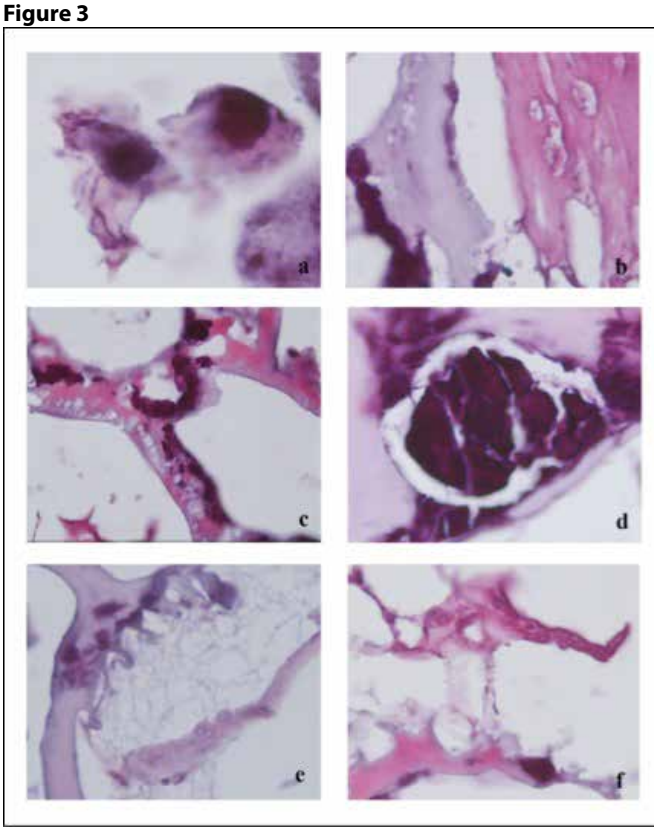

Figure 3. Time dependent immunohistochemical staining of tooth forming cells. Used antibodies are BMP 2, 4, 7, FGF 3 and Msx 1.

10.5505/2017ichc.OP-43 [Stem cells]

Comparison of immunological properties of mononuclear cells between acute myeloid leukemia patients and healthy donors

İlkay Pişkin[1], Yasin Köksal[2], Fatma Karaca Kara[3], Neşe Yaralı[4], Meltem Özgüner[1]

[1]Department of Histology&Embryology, Yildirim Beyazit University, Ankara, Turkey

[2]Department of Pediatric Hematology, Stem Cell Laboratory, Ankara Children's Hematology Oncology Education and Research Hospital, Ankara,Turkey

[3]Department of Medical Biochemistry, Ankara Children's Hematology Oncology Education and Research Hospital, Ankara,Turkey

[4]Department of Pediatric Hematology, Ankara Children's Hematology Oncology Education and Research Hospital, Ankara,Turkey

INTRODUCTION: A mitogen agent- phytohaemagglutinin (PHA) that is a lectin to crosslink different cell membrane glycoproteins, and is responsible for polyclonal activation of lymphocytes(O'flynn K et al.,1985). In this study we aimed to compare the immunological properties of mononuclear cells(MNCs) induced with or without a PHA stimulation of acute miyeloid leukemia (AML) patients and healthy donors.
MATERIAL-METHODS: MNCs obtained from peripheral blood of 4 AML patients and 3 healthy donors. For MNCs isolation procedure, the dansity-gradient centrifugation using Biocoll method was used to obtain from peripheral blood and were plated T-25 flasks with a PHA for 72 hours for activation of lymphocytes.(Table 1).For immunological assays, different sets of culture were generated as below: G1-Group 1(PHA(+) MNCs of AML patient),G2-group 2 (PHA(+) MNCs of healthy donor),C1-control 1(PHA(-) MNCs of AML patient),C2-control 2 (PHA(-) MNCs of healthy donor). For immunological assays to define the different stages of lymphocytes activation, we used mAb against CD3-PC7,CD4-FITC,CD25-PE, HLA-DR-ECD and CD69-PC5 by flow-cytometry.
RESULTS: We analyzed especially T lymphocytes phenotypically defined as CD3+CD69+,CD4+,CD25+, and CD3+HLA-DR+ in different culture conditions by flow-cytometry. The CD3+CD69+, CD3+HLA-DR+ and CD4+CD25+ activation profile of MNCs of G1 and C1 were similar after PHA exposure. The mean percentage of CD3+CD69+ cells (p=0,007), CD3+HLA-DR+ cells (p=0,001) and CD4+CD25+ cells (p=<0,001) were higher in C2 when compared with G2. Also, the mean percentage of CD3+CD69+ cells (p=0,005) and CD4+CD25+ cells (p=0,008) were higher in G2 when compared with G1. Finally, the mean percentage of CD3+HLA-DR+ cells (p=0,041) were higher in C2 when compared with C1(Table 2).
CONCLUSION: We defined and compared different stages of lymphocytes activation in AML patients and healthy donors. MNCs of healthy donors with a PHA stimulation were found to be consistent with the literature of the expression of T-cell surface markers. However, the expression pattern of MNCs of AML patients indicated that they do not mount an effective immune response to PHA. We concluded that the defective transcription of IL-2 receptor alfa (CD25) expression on lymphocytes could be the reason for lower expression of T-cell surface markers in AML patients.

Keywords: Acute myeloid leukemia, flow-cytometry, lymphocytes, mononuclear cells, phytohaemagglutinin

Figure 1. Inverted microscope images of mononuclear cells (MNCs) derived from peripheral blood of AML patient

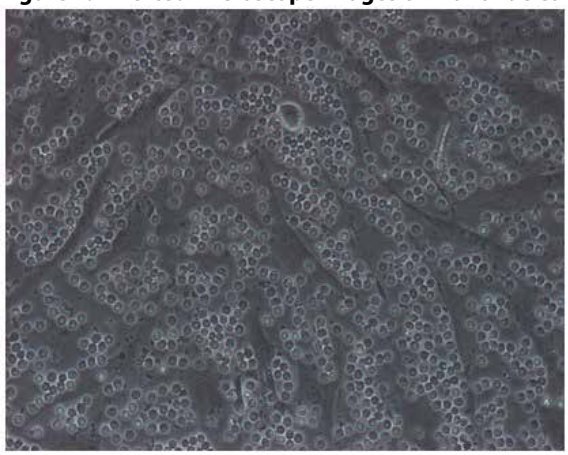

Inverted microscope images of mononuclear cells (MNCs) derived from peripheral blood of AML patient-Olympus CKX41-40x

Figure 2. Inverted microscope images of mononuclear cells (MNCs) obtained from peripheral blood of AML patient

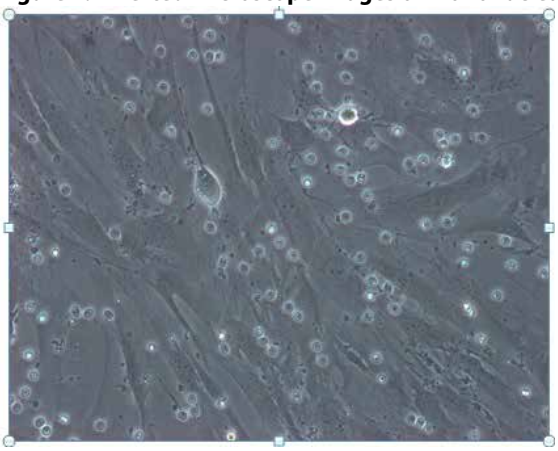

Inverted microscope images of mononuclear cells (MNCs) obtained from peripheral blood of AML patient-Olympus CKX41-40x

Figure 3. Inverted microscope images of mesenchymal stromal cells derived from bone marrow co-culture with MNCs of AML patient



Inverted microscope images of mesenchymal stromal cells derived from bone marrow co-culture with MNCs of AML patient-Olympus CKX41-4x

Table 1. Activation time of cell surface markers of lymphocytes after PHA stimulation

Activation markers	Activation time
CD69(early activation marker)	4 hours
CD25(IL-2 receptor alfa)	12 to 24 hours
HLA-DR	48-60 hours

(Reference:Rea IM et al.,1999)

Table 2. Immunological assay by determination of activation markers of lymphocytes obtained from peripheral blood of AML patients and healthy donors

Activation markers	AML	AML	Healthy	Healthy	p val-ue (G1	p val-ue(G2&C2)	p val-ue(G1& G2)	p val-ue(C1 & C2)
CD3+_ CD69+	4,881	1,055	33,235	2,342		0,007	0,005	0,286
CD3+_ HLA-DR+	10,371	1,516	49,506	4,003		0,001	0,057	0,041
CD4+_ CD25+	10,794	5,354	44,289	2,704		<0,001	0,008	0,564

Data presented are percentages. Statistical significance is p <.05. G1 (grup 1):AML periferik MNC+PHA(+) G2(Grup 2): Healthy periferik MNC+PHA(+) Control 1:AML periferik MNC+PHA(-) Control 2:Healthy periferik MNC+PHA(-)

10.5505/2017ichc.OP-44 [Stem cells]

Amniotic Fluid derived stem cells and its multilineage differentiation

A S M Golam Kibria[1], Ozlem Ozden Akkaya[1], Korhan Altunbaş[1], Metin Erdoğan[2], Artay Yağcı[1]

[1]Department of Histology and Embryology, Faculty of Veterinary Medicine, Afyon Kocatepe University, Turkey

[2]Department of Medical Biology and Genetics, Faculty of Veterinary Medicine, Afyon Kocatepe University, Turkey

BACKGROUND: Amniotic fluid derived stem cells (AFSCs) stand between pluripotency and multipotency with low immunogenicity having better competency for regenerative cell therapy.

AIM: The present study was aimed to isolate AFSCs and characterize the multi-lineage potency and neurospheres formation with a view to apply in neurodegenerative diseases model.

MATERIALS-METHODS: AFSCs were isolated from amniotic fluid of pregnant Wister rat with fibroblast like morphology under monolayer cell culture. They were competently differentiated into osteogenic and adipogenic lineages as well as neurospheres formation after third passage of culture using lineage-specified differentiating medium in vitro. To assess the immunogenicity for possible allogenic application specified immunogenic markers MHC-I, MHC-II, CD40, CD80 and CD86 were evaluated by qPCR. They were continued to grow till ten passages and were calculated for doubling time (DT) and viability.

RESULTS: Plastic adherent monolayer cells showed fibroblast like cyto-morphology with limitless self renewal and lesser senescence. Accumulation of lipid vacuoles, deposition of extracellular calcium materials confirmed their multipotency. Spherical neurospheres generation as well as immunogenic markers expression provides hope for neurodegenerative therapy with allogenic prescription.

CONCLUSION: AFSCs has higher proliferation rate and multi-lineage potency. This study of AFMSCs can stand as a model for neurodegenerative diseases in animals and humans.

Keywords: Amniotic fluids, differentiation, immunogenic markers, regenerative medicine, stem cells.

10.5505/2017ichc.OP-45 [Developmental and reproductive biology]

T-2 Toxin Disrupts Sertoli Cell Barrier via Changes in Tight and Adherent Junctional Proteins in SerW3 Cells

Elif Karacaoğlu, Güldeniz Selmanoğlu
Faculty of Science, Department of Biology, Hacettepe University, Ankara, Turkey

Introduction & OBJECTIVES:
Mycotoxins are toxic fungal metabolites produced in agricultural products. T-2 toxin as a trichotecene mycotoxin contaminates cereals such as wheat, corn, barley, rye and oat. Although some studies exist on reproductive toxicity of T-2 toxin, there was no information about the effects on Sertoli cell junctional barriers. The purpose of the study is to reveal cytotoxic effects of T-2 toxin on Sertoli cells in the context of junctional barrier.
Matherial & METHOD:
SerW3 cells as Sertoli cell model were exposed to T-2 toxin doses (0, 12, 120 and 1200 ng/ml) for 24 and 48 hours. Tight and adherent junctional proteins such as occludin, ZO-1, N-cadherin and β-catenin were labelled with immunoflourescence. In addition occludin and N-cadherin protein expressions were detected by western blotting. Furthermore, cell barrier function was evaluated by transepithelial electrical resistance (TEER) measurement.
RESULTS:
Expressions of immunolabelled tight and adherent junctional proteins in SerW3 cells decreased in dose dependent manner when exposed to T-2 toxin doses. T-2 toxin caused decreases in expression of occludin and N-cadherin proteins. Additionally, TEER measurement values decreased in response to increasing T-2 toxin doses.
CONCLUSIONS:
As a result of the study, SerW3 cells barrier integrity disrupted when exposed to T-2 toxin doses, parallel with increasing cytotoxicity. This study was come into prominence for revealing the cytotoxic effects of T-2 toxin on Sertoli cells related to cell barrier function.
Acknowledgement: This study was a part of PhD thesis, and supported financially by TUBITAK (Project No: 212T238).

Keywords: SerW3 cells, T-2 toxin, TEER, occludin, N-cadherin

10.5505/2017ichc.OP-46 [Developmental and reproductive biology]

Nesfatin-1 protects against torsion-induced testicular oxidative injury in rats

Sevil Arabacı Tamer[1], Alper Yıldırım[1], M. Kutay Köroğlu[2], Özge Dağdeviren Çevik[3], Feriha Ercan[2], Berrak Ç. Yeğen[1]

[1]Departments of Physiology, School of Medicine, Marmara University, Istanbul, Turkey

[2]Departments of Histology and Embryology, School of Medicine, Marmara University, Istanbul, Turkey

[3]Departments of Biochemistry, Faculty of Pharmacy, Cumhuriyet University, Sivas, Turkey

Introduction & OBJECTIVES: Testicular torsion, a common surgical emergency, is associated with oxidative stress and an increased risk of infertility. Nesfatin-1 is a novel peptide with recently shown antioxidant, anti-inflammatory and anti-apoptotic properties. The purpose of this study was to investigate the possible protective effect of nesfatin-1 on torsion/detorsion (T/D)-induced oxidative testis damage and morphology of sperm and testis in rats.
Materials & METHODS: Under anesthesia, male pubertal Sprague-Dawley rats (180-230 g; n=24) had sham-operation with a left scrotal incision or they underwent testicular torsion by rotating the left testis 720° and fixing it for 2 h, which was followed by a 2-h detorsion. Rats in each group were treated intraperitoneally with either nesfatin-1 (0.3 µg/kg) or saline 10 min before the torsion or sham-torsion. At the end of the 4-h experimental period, testes were removed. Tissue levels of the oxidative stress marker 8-OHdG were measured by ELISA, and pro-inflammatory cytokines TNF-α and interleukin (IL)-6, caspase-3 and transcription factor CREB were measured by western blotting, where GAPDH was used as control for quantification. Epididymal spermatozoa were evaluated and hematoxylin-eosin stained sections of seminiferous tubules were scored by the modified Johnsen scoring method. Statistical analysis was performed by ANOVA and Student's t tests.
RESULTS: In saline-treated T/D group, a high percentage ($p<0.05$) of abnormal spermatozoa with head defects was observed, which was abolished in nesfatin-1-treated TD group. Most of the seminiferous tubules were degenerated with cell debris in the lumen, and vacuole formation was observed in decreased numbers of spermatogenic germ cells of saline-treated T/D group ($p<0.01$), while quite regular seminiferous tubules with intact germinal epithelium were observed in the nesfatin-1-treated T/D group, which had scores that were not different than those of the sham-operated group. Elevated levels of 8-OHdG, TNF-α, IL-6, caspase-3 and CREB in the saline-treated T/D group as compared to sham-operated group ($p<0.001$) were all reduced in nesfatin-1-treated T/D group ($p<0.05$-0.001).
CONCLUSION: The findings suggest that nesfatin-1 may have a therapeutic potential in decreasing torsion-induced oxidative stress, apoptosis and infertility.

Keywords: Nesfatin-1, testicular torsion/detorsion, oxidative stress, apoptosis, infertility

10.5505/2017ichc.OP-47 [Developmental and reproductive biology]

Histological Examination of the Effect of *Lycium Barbarum* (Goji Berry) on Testis and Epididymis of Acrylamide Treated Young Male Rats

Havva Imran Özdemir, Aysel Kükner
Department of Histology and Embriyology, Abant İzzet Baysal University, Bolu, Turkey

Introduction and Objectives
In this study, it is aimed to contribute to alternative mediciene by reducing oxidative stress which is resulted from the toxic effect of acrylamide and causes infertility.
Material and Method
2-3 months old wistar albino male rats are categorized into 4 groups which each of all consists of 6 rats as random. The groups are as follows: Acrylamide (ACR) group (n=6), ACR+ Goji berry (treatment) group (n=6), negative control group (n=6), positive control group (only goji berry treated) (n=6). ACR group is treated with 50 mg/kg ACR via gavage one time per day for 5 consecutive days. For treatment group,ACR is applied as former. Additionally, the group is treated with 200 mg/kg goji berry via gavage one time per day for 5 consecutive days. Positive control group is treated with 200 mg/kg goji berry extract one time per day via gavage for 5 consecutive days.
Results
According to routine histological stainings (H&E, Masson's Trichrome, and PAS) there is no big difference between 4 groups (Fig 1). In epididymises of ACR group sperm reserves are decreased compared to other groups (Fig 2).The difference is seen at immunohistochemical staining (TUNEL). The number of apoptotic cells is very high in ACR group compared to other groups (Fig 3).
Conclusion
According to stainings, it can be seen that acrylamide is toxic and effects fertility. It decreases sperm reservers and leads to apoptosis in spermatogonium cells. Lycium barbarum extract may decrease apoptosis which is shown in Fig. 3. It may be promising for reducing oxidative stress.

Keywords: Acrylamide, testis, goji berry,infertility

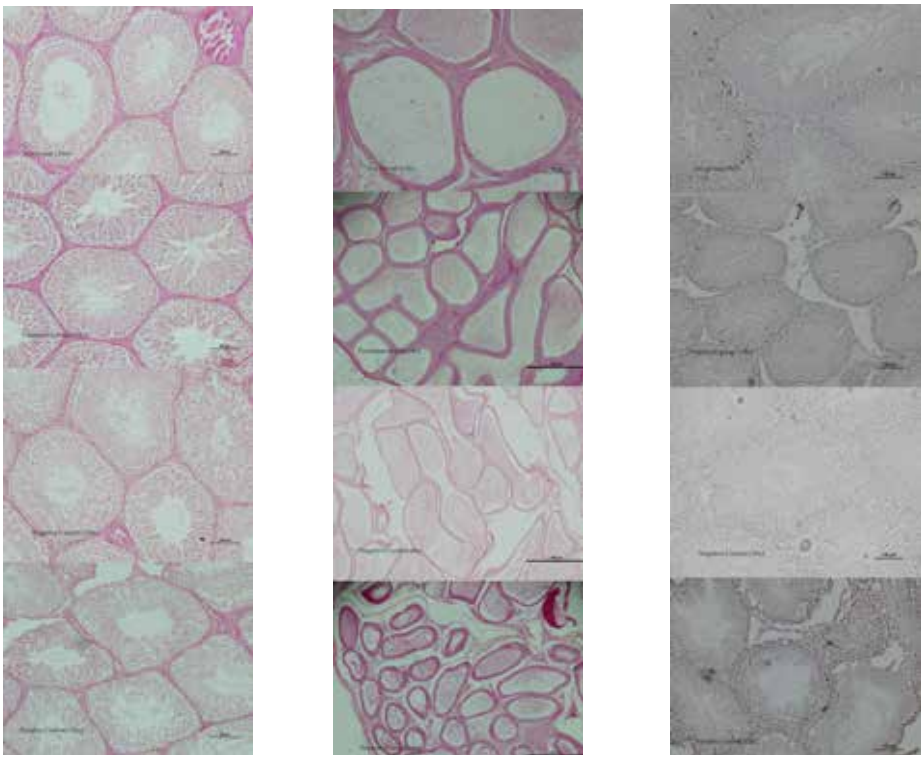

Fig 1 *It shows the differences of testis tissues between four groups*

Fig 2 *It shows the differences in epididymis between groups*

Fig 3 *It shows the diffrences of TUNEL stained testis tissues between groups*

10.5505/2017ichc.OP-48 [Developmental and reproductive biology]

Protective effects of melatonin on ovarian structures of rats exposed to environmental toxic agent 2,3,7,8-tetrachlorodibenzo-p-dioksin (TCDD)

Semir Gül, Mehmet Gül, Birgül Yiğitcan
Department of Histology and Embryology, İnönü University, Malatya, Turkey

Introduction & Objectives
In this study, we aimed to investigate the protective effects of melatonin over the ovarian tissues of female rats exposed to chronic 2,3,7,8-tetrachlorodibenzo-p-dioksin (TCDD) which is a prevalent and persistent environmental toxic agent.
Materials & Methods
Studies were performed on 72 female "Wistar albino" rats weighing 150-180 g. Animals were housed in cages under standard conditions at constant temperature (22°C) on a 12 h light: 12 h dark cycle. Control group (n=10) received nothing. Oil group (n=10) received corn oil (0,5 ml/kg/week x 16, g.g.). Alcohol group (n=10) received 5% ethanol (0,5 ml/kg/day x 16, i.p.). Melatonin (Mel) group (n=12) received melatonin (10 mg/kg/day x 16, i.p.). TCDD group (n=15) received TCDD (1µg/kg/week x 16, g.g.). TCDD + Mel group (n=15) received TCDD (1µg/kg/week, x 16, g.g.) and melatonin (10 mg/kg/day x 16, i.p.). After application, rats were decapitated and ovaries of the rats were taken. After tissue processing, ovarian sections were cut at thickness of 5 µm for light microscopic analysis and 80 nm for electron microscopic analysis.
Results
Weight increase was significantly lower in TCDD and TCDD + Mel groups compared to control groups (fig. 1). TCDD caused loose of proper ovarian cellular distribution and decrease in follicle and corpus luteum numbers (fig. 2, fig. 3-A,B,C). In TCDD group, stromal cells had pyknotic nucleus and undulation at nucleus periphery and there were large and irregular ordered hydrophilic vacuoles between stromal cells (fig. 3-E). Degenerated granulose cells and apoptotic bodies between granulose cells were detected (fig. 3-H). Necrosis at granulose cells and erythrocytes between granulosa cells were observed (fig. 3-L). In TCDD + Mel group, stromal cells were in normal ultrastructure appearance (fig. 3-F). Granulose cells were as generally polygonal shaped, euchromatic nucleus containing cells (fig. 3-M). Mitotic figures were seen between some of the granulose cells. Theca cells were evaluated at normal ultrastructural organization (fig. 3-I,M).
Conclusion
Demonstrated in this study that melatonin has a protective and curative role against the destructive effects of TCDD on ovarian tissues.

Keywords: TCDD, dioxin, ovary, melatonin Note: This work was supported by Scientific Research Projects Coordination Unit of İnönü University (BAP) and was presented as poster in Dioxin2016 congress on 29th Aug 2016 organised in Florence/Italy on.

Effect of TCDD on body weight

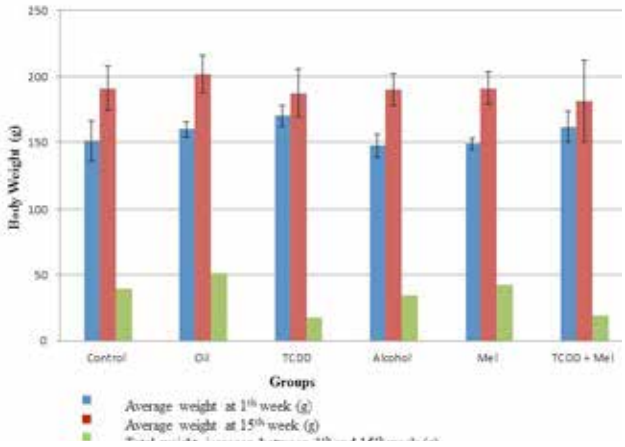

Increase of weight of rats from first week to last week in control (40 g), oil (51 g), mel (42.2 g) and alcohol (34.9 g) groups were close to each other and significantly higher than the TCDD (17.7 g) and TCDD + Mel (19.6 g) groups (p<0,05).

Effect of TCDD on the number of follicles and corpus luteum

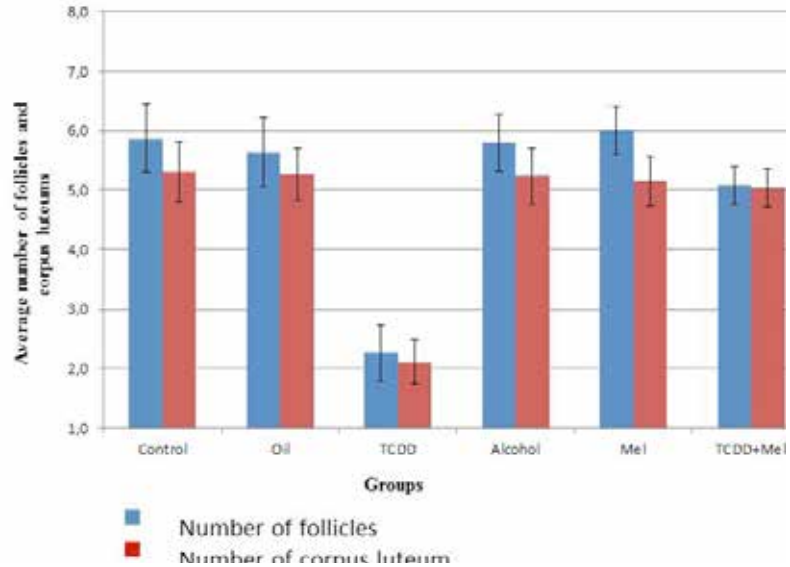

TCDD caused to a significant decrease in the average number of corpus luteum and follicles per tissue section (2,1 ± 0,7; 2,3 ± 0,8, respectively), whereas these numbers preserved in TCDD + Melatonin (TCDD + Mel) group (5,0 ± 0,8; 5,1 ± 0,8, respectively) and were similar to control group (5,3 ± 1,0; 5,9 ± 0,9, respectively).

Light and electron microscopic analysis

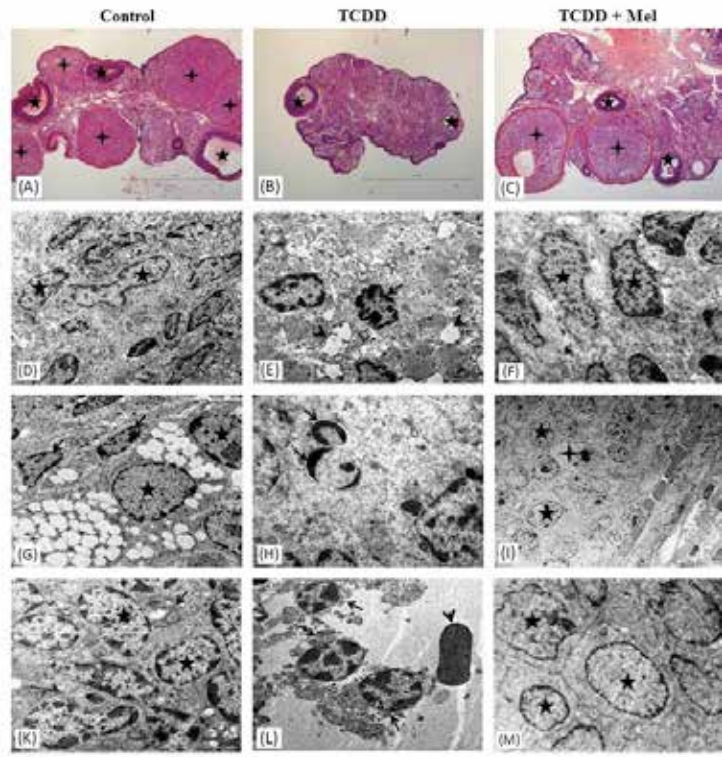

Ovary section with follicles (five-pointed stars) and copus luteum (four-pointed stars). B; Ovary section with reduced number of follicles (stars). C; Ovary section with many follicles (five-pointed stars) and copus luteum (four-pointed stars). D; stromal cells (stars). E; stromal cells with pyknotic and irregular ordered nucleus (stars) and vacuoles (arrow head). F; stromal cells (stars) with chromatin condansation at nuclear periphery. G; granulosa lutein cells (stars) and techa cells (arrows). H; apoptotic bodies between granulosa cells (arrows). I; granulosa cells (five-pointed stars) and mitotic figure (four-pointed star). K; granulosa cells (stars) and seconder lysosom (arrow). L; necrosis at granulosa cells (arrow) and erythrocyte (arrow head). M; granulosa cells with euchromatic nucleus (stars). (A-C: LM, Scale bar 100µm; D-M: TEM, Scale bar 2µm)

10.5505/2017ichc.OP-49 [Developmental and reproductive biology]

Investigation of the effects of vitamin D treatment on the uterine structural changes in the experimental model with polycystic ovary syndrome: an ultrastructural and immunohistochemical study

Yurdun Kuyucu[1], Latife Seyran Çelik[1], Ebru Dündar Yenilmez[2], Abdullah Tuli[2], Ufuk Özgü Mete[1]

[1]Çukurova University Faculty of Medicine, Histology and Embriology Department, Adana, Turkey

[2]Çukurova University Faculty of Medicine, Biochemistry Department, Adana, Turkey

INTRODUCTION&OBJECTIVES: Polycystic ovary syndrome (PCOS) is the most common endocrine-metabolic dysfunction in women of reproductive age, and a frequent cause of ovulatory dysfunction and hyperandrogenism. Several studies suggest an abnormal endometrial phenotype and function in women with PCOS. It has been noted that the endocrine and metabolic disorders developing in PCOS also affects the endometrium and increases the rate of endometrial hyperplasia and endometrial cancer 2-3 times. The uteri of those suffering from PCOS have not been much studied. In this study, we aimed to investigate the structural changes seen in the endometrium in experimental PCOS rat model and the effects of vitamin D treatment on these changes at immunohistochemical and electron microscopic levels.
MATERIALS&METHODS: We divided 24 immature rats into three groups. Two groups were injected with dehydroepiandrosterone (DHEA) and one of them were treated with 1,25(OH)2 D3 at the same time. The control group were injected with sesame oil for the corresponding lengths of time. At the end of the 28th day, the blood samples were collected for hormone analyses. The uterus tissues were prepared for light and electron microscopic examinations. Paraffin sections were stained with Masson Trichrome method to assess epithelial, stromal and endometrial thickness and Caspase-3 immunostaining was performed to show the presence of apoptotic cells.
RESULTS: Serum AMH and estradiol levels were significantly higher in the PCOS group than the control group and these values decreased in the vitamin D treatment group. There was no statistically significant change in serum progesterone levels between the groups. Endometrial, epithelial and stromal thickness were significantly increased in the PCOS group compared with the control group. But, these measurements were significantly decreased in the vitamin D treatment group compared to the PCOS group. Light and electron microscopic results of PCOS group showed an increase in apoptosis. In the PCOS group, immunohistochemical staining of Caspase-3 was found to be higher than in the control group, but staining decreased with vitamin D treatment.
CONCLUSIONS: Structural changes observed in endometrium may be related to implantation problems seen in patients with PCOS and vitamin D therapy may be beneficial in these patients.

Keywords: Uterus, vitamin D, immunohistochemistry, transmission electron microscopy

Figure 1

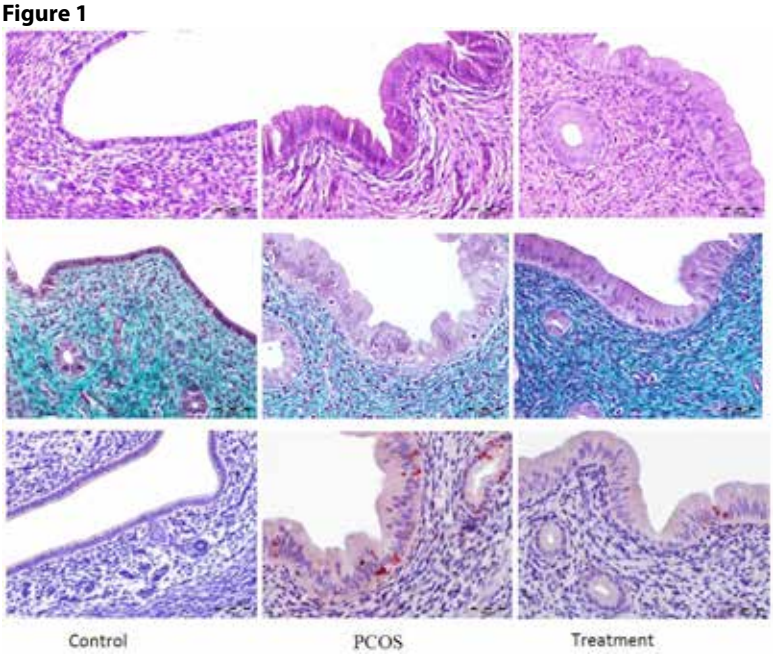

Figure 2

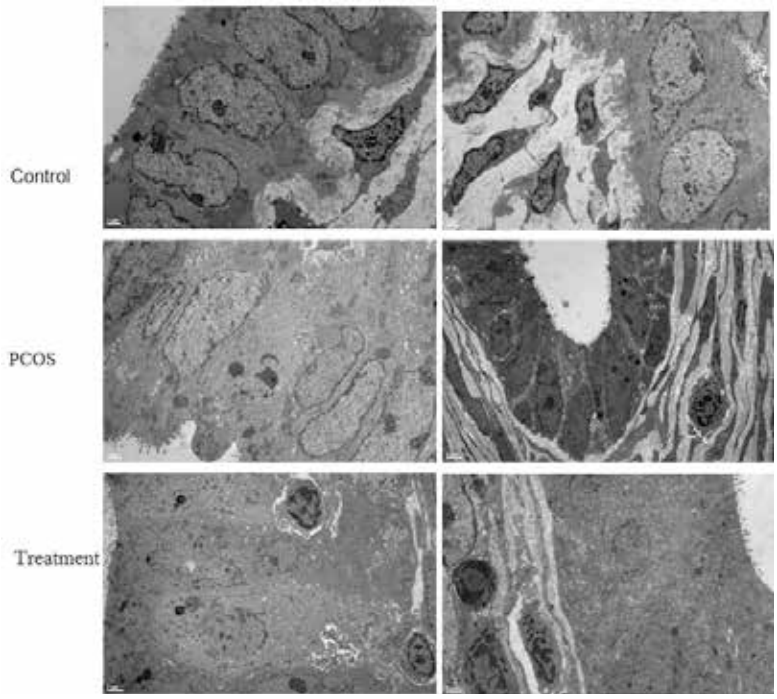

10.5505/2017ichc.OP-50 [Developmental and reproductive biology]

HSP 70 Staining of Sperms Obtained from Idiopathic Infertile Men Having Normal Sperm Parameters

Bülent Celpkulu[1], Mete Köksal[2], Halil Çiftçi[3], Fuat Dilmeç[4]

[1]Depertment of Urology, Kurtalan State Hospital, Siirt, Turkey

[2]Depertment of Histology and Embryology, Harran University, Şanlıurfa,Turkey

[3]Depertment of Urology, Harran University, Şanlıurfa,Turkey

[4]Depertment of Molecular Biology, Harran University, Şanlıurfa,Turkey

In the most of infertile men etiologic cause could not be found, and this condition is considered to be as idiopathic infertility. Heat shock proteins are very important for all stages of the cell metabolism including growth, differentiation, division and even cell death. It is shown that heat shock proteins are effective during spermatogenesis, and degradation of HSP 70-2 gene results failed mayosis and male infertility. In this study we aim to investigate the relationship between HSP 70 and infertility in males with normal sperm parameters. The study included 24 infertile males with normal sperm parameters and for control group 24 fertile male donors. Semen analysis was performed according to the World Health Organization guidelines. Immunofluorescence staining method was performed on spermatozoa by using anti hsp70 primary anticors (Santa Cruz). Staining of spermatozoa were scaled 0 to 3 and after 100 hundered cells counted, avarage values of each subject were determined. There was no statistically significant difference between sperm parameters and also staining scores the patient and the healthy group. We couldn't find any relationship with normozoospermic idiopathic infertility and HSP70, but further prospective studies with larger sample sizes are required to clarify the issue.

Keywords: HSP 70, Sperm, İnfertility, İmmunoflueresence

10.5505/2017ichc.OP-51 [Developmental and reproductive biology]

Morphology, morphometric and biochemical parameters changes in the adult rat ovarium following continuous 900-megahertz electromagnetic field applied in middle and late-adolescence

Derya Ozturk Okatan[1], Ersan Odacı[2]

[1]Etlik Zubeyde Hanım Gynecological Education Research Hospital, Ankara, Turkey

[2]Department of Histology and Embryology, Faculty of Medicine, Karadeniz Technical University, Trabzon, Turkey

Introduction & OBJECTIVES: To evaluate changes taking place in the ovaria of rats exposed to the effect of a 900-Megahertz (MHz) electromagnetic field (EMF) in middle and late adolescence.
Materials & METHODS: Twenty-four 34-day-old female Sprague Dawley rats were assigned equally into control, sham and EMF groups. EMF group rats were exposed to the effect of a 900-MHz EMF for 1 hour a day, at the same time every day between postnatal days 35 and 59, while inside an EMF cage. Sham group rats were kept inside the EMF cage for the same time between postnatal days 35 and 59 without being exposed to any effect. At the end of the study, ovaria were removed under anesthesia, blood specimens were taken, and the animals were sacrificed. Right ovarium tissues were subjected to routine procedures, sectioned and stained with hematoxylin and eosin, periodic acid shift and Masson's trichrome. Follicles were counted in ovarium sections stained with hematoxylin and eosin. The TUNEL method was used to evaluate apoptosis. Malondialdehyde, glutathione, catalase (CAT) superoxide dismutase (SOD), 8-hydroxy-deoxiguanosine (8-OHdG), 3-nitrotirosin (3-NT) and anti-mullerian hormone (AMH) values were investigated biochemically in left ovarium tissue and blood specimens. Total antioxidant status (TAS) and total oxidant status (TOS) were investigated in serum, and the oxidative stress index was calculated (OSI).
RESULTS: Histopathological examination of EMF group ovarium tissue revealed thinning in the zona granulosa and theca layers, shrinking in granulose cells, hyperchromasia, reduced mitotic activity and leukocyte infiltration in the follicles and stroma. Secondary follicle numbers in the EMF group were significantly lower than in the other groups. In terms of biochemistry, EMF and sham group SOD, CAT and AMH levels and EMF group 3-NT values increased significantly compared to the control group. EMA and sham group serum CAT and 8-OHdG values increased significantly compared to the control group, and EMF group TOS and OSI values were significantly higher compared to the sham and control groups.
CONCLUSIONS: 900-MHz EMF applied in middle and late adolescence may cause changes in the morphology and biochemistry of the rat ovarium.

Keywords: Electromagnetic field, middle and late adolescence, ovarium, rat

10.5505/2017ichc.OP-52 [Advances in image analysis]

Effect of Systemic Magnesium Sulfate on Retina in Neonatal Rats with Hypoxic Ischemic Encephalopathy

Serhat Imamoğlu[1], Ebru Yalın Imamoğlu[2], Serkan Erdenöz[3], Lorina Haziri[4], Yağız Özdağ[4], Alev Cumbul[4], Ünal Uslu[4], Şamil Aktaş[5], Gökhan Pekel[6], Mehmet Şahin Sevim[7], Mustafa Nuri Elçioğlu[3], Fahri Ovalı[8]

[1]Ophthalmology Department,Haydarpasa Training and Research Hospital, Istanbul, Turkey

[2]Neonatology Department,Umraniye Training and Research Hospital, Istanbul, Turkey

[3]Ophthalmology Department, Okmeydani Training and Research Hospital, Istanbul, Turkey

[4]Department of Histology and Embryology, Faculty of Medicine, Yeditepe University, Istanbul, Turkey.

[5]Departure of Underwater and Hyperbaric Medicine,Faculty of Medicine, Istanbul University, Istanbul, Turkey.

[6]Department of Ophthalmology, Faculty of Medicine, Pamukkale University, Denizli, Turkey.

[7]Department of Ophthalmology, World Eye Hospital, Istanbul, Turkey

[8]Faculty of Medicine, Medeniyet University, Neonatology Department, Istanbul, Turkey

Visual loss associated with brain damage, especially hypoxic–ischemic (HI) encephalopathy, is the most common cause of visual impairment in children. The aim of this study was to evaluate the effect of systemic magnesium sulfate (MgSO4) on retina in a neonatal hypoxic-ischemic rat model.

In this study, postnatal 7-day Sprague-Dawney rats (n=21) were used and rats were randomly divided into three groups equally. MgSO4-treated group received 0.1 cc MgSO4, injected intraperitoneally (IP) (275 mg/kg). HI group and sham group received 0.1 cc sterile saline IP. The pups in both MgSO4-treated group and HI group were anesthetized lightly with inhaled isoflurane, the right carotid artery was identified through a longitudinal neck incision, isolated from the nerve and vein and permanent surgical ligation with 5.0 surgical silk plus coagulation of carotid artery was performed. These pups were also exposed to hypoxia with a warm humidified 8/92% oxygen/nitrogen mixture for 2 h. Treatments were given three times: the first being just before ischemia, the second after hypoxia and the third 24 h after the second dose. Following deep isoflurane anesthesia, cardiac perfusion was performed. Serial sections of 15 µmthicknesses of paraffin-embedded blocks were obtained. The injury in retinal ganglion cell layer was evaluated histomorphometrically with Hematoxyline and Eosine technique. They were examined with Stereo Investigator version 11.0 image analysis program. Selected medium sections were marked with Vascular Endothelial Growth Factor Receptor-2 (VEGFR-2) by immunoassay. They were photographed by Leica DM6000B microscope and examined with a quantitative immunohistochemical analysis program (FIJI).

The level of VEGFR-2 expression was found significantly decreased in MgSO4-treated group when compared to the HI group ($p < 0.001$). VEGFR-2 expressions were found similar in both MgSO4-treated group and sham group (Table 1 and Figure 1). We also observed a significant decrease in retinal ganglion cells in the HI group (Figure 2 and Figure 3).

In conclusion, systemic administration of MgSO4 could decrease retinal VEGFR-2 levels and could preserve retinal ganglion cells in neonatal rats with hypoxic-ischemic encephalopathy.

This study was supported by Turkish Ophthalmology Society - Istanbul Branch and Haydarpasa Numune Training and Research Hospital.

Keywords: Hypoxic Ischemic Encephalopathy, Magnesium Sulfpate, retina, VEGF, rat

Figure 1

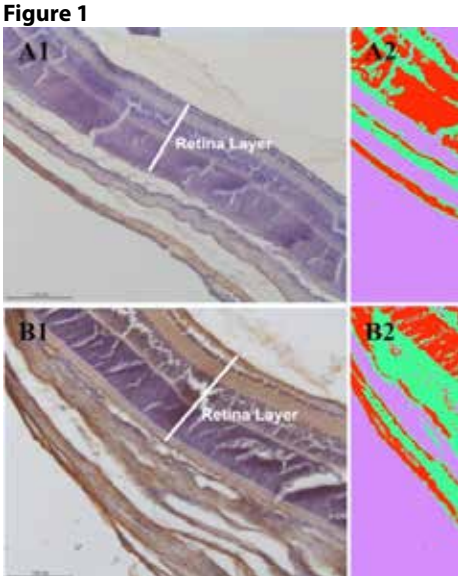

The level of VEGFR-2 expression in the eye tissue of neonatal rats. The sections on the left show immunohistochemical evaluation of VEGFR-2. The intensity of VEGFR-2 staining was found increased in retina and choroid layers in and sham groups, however it was reduced in the MgSO4-treated group. The sections on the right show evaluation of FIJI. The positive VEGFR-2 intensity, the negative VEGFR-2 intensity and the space area of eye tissue were demonstrated with green, red and purple colors, respectively. Groups: A1-2: Sham operated, B1-2: Hypoxic-Ischemic, C1-2: MgSO4-treated. The magnification is x 20. Scale bar represents 120 µm.

Figure 2

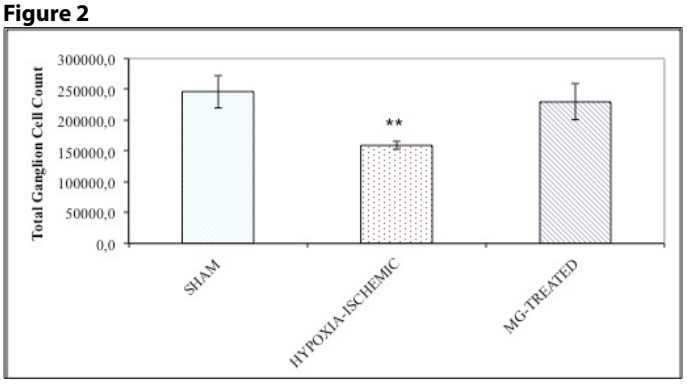

*Graphs comparing the Sham operated, Hypoxic-Ischemic, MgSO4-treated. Data are presented as the total number of retinal ganglion cells. Data are expressed as mean ± SEM (**p<0.01 compared to Sham operated and MgSO4-treated).*

Figure 3

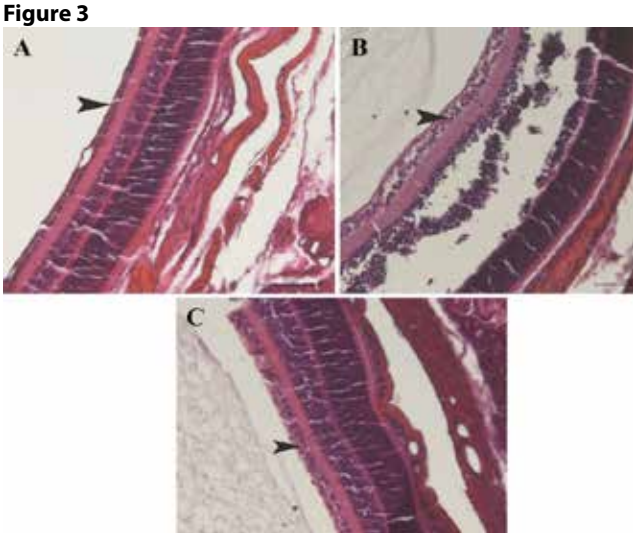

Comparison of histological cross sections of A (Sham operated), B (Hypoxic-Ischemic) and C (MgSO4-treated) groups. Black arrows show the retinal ganglion cells. Staining: Hematoxyline and Eosine, The magnification is x10. Scale bar represents 120 µm.

Table 1: VEGFR-2 expression of FIJI in the eye tissue of neonatal rats.

Groups (n=7)	Positive Intensity (Mean±Standard error)	Negative Intensity (Mean±standard error)	Space (Mean±standard erro, r)	
Sham group	7.65 ± 1.10	10.06 ± 0.41	17.90 ± 0.62	
Hypoxic-ischemic group	12.80 ± 1.08	5.70 ± 0.65	15.10 ± 0.69	
MgSO4-treated group	5.48 ± 0.99	11.92 ± 0.97	15.18 ± 1.48	*

VEGF expression of FIJI in the neotanal eye tissue. Data expressed as means ± SEM. Magnesium significantly prevented cell apoptosis in the retinal ganglion cells (p< 0,001). Table compares Sham operated, Hypoxic-Ischemic, Magnesium treated group. Data are presented as VEGF positive intensity compared to VEGF negative intensity between all groups. Data are expressed as mean ± SEM, (*): between Magnesium treated group and hypoxic-ischemic group, p<0.001), (#):between Magnesium treated group and Sham operated group, p<0.001)

10.5505/2017ichc.OP-53 [Cancer biology]

Effects of Paclitaxel, Bevacizumab and Metformin on PI3K/AKT pathway and Angiogenesis in MDA-MB 231 Breast Cancer Cell Line

Fatma Firat[1], Elgin Turkoz Uluer[1], Sevinç Inan[2]

[1]Department of histology embriyology, MANİSA CELAL BAYAR UNIVERSITY, MANISA, TURKEY

[2]Department of histology embriyology, IZMIR ECONOMY UNIVERSITY, MANISA, TURKEY

Breast cancer is the most common cancer worldwide. PI3K/AKT and Ras/Raf/MEK/ERK pathways are frequently dysregulated in cancer. In this study we aimed to investigate effects of Metformin which is used in diabetes treatment, chemotherapeutic drug Paclitaxel and anti angiogenic drug Bevacizumab on metastatic breast cancer cells MDA-MB-231 via indirect immunohistochemistry (IHC).
MDA-MB 231 cells were cultured in RPMI-1640 medium. After growing, we divided cells as bevacizumab (B), paclitaxel (P), metformin (M), (B+M), (P+M) ve (B+P+M) groups and the no treatment-control group and the IC50 dose of drugs was applied and the effect of 24th hour was evaluated. Cells were incubated with anti-AKT, anti-PI3K, anti-ERK, anti-PERK and anti-VEGF primary antibodies. Cells viewed under light microscope (Olympus BX40). The distribution of immunohistochemical intensities of primary antibodies were scored as mild (+), moderate (++), strong (+++) and very strong (++++). After counting the percent of positive staining cells, statistical significance was determined by ANOVA test. Significance was defined as $p<0.05$.
According to the IHC evaluation, AKT, PERK, ERK and VEGF immunoreactivities were increased when compare to the control group in B, P groups. In M treatment group ERK, VEGF and AKT immunoreactivities were decreased and PI3K was increased when compare to the other groups. In B+M group ERK, VEGF, AKT and PI3K immunoreactivities were increased, similer to the P+B and B+M+P groups ERK, AKT and PI3K immunoreactivities were incresed. And in M+P group PERK and ERK were decreased.
According to the immunohistochemical evaluation; treatment of B+M+P leads to MDA-MB 231 cells for 24 hours. However in recent studies, usage of antidiabetic drug M alone and/or combination with chemotherapeutic drugs showed controversial effects. In this study it was shown that alone administration of M was not effective while combination with P and B is more effective via AKT and ERK pathways.

Keywords: Chemotherapy. Antıdıyabetıc. Breast. Cancer.

10.5505/2017ichc.OP-54 [Cancer biology]

The Evaluation of the Distribution of CD133, CXCR1 and the Tumor Associated Macrophages in Different Molecular Subtypes of the Breast Cancer

Can Ilgın[1], Erdem Çomut[2], Çağlar Sarıgül[2], Selçuk Korkmaz[3], Enver Vardar[2], Sevda Fatma Müftüoğlu[1]

[1]Department of Histology and Embryology, Hacettepe University, Ankara, Turkey

[2]Department of Pathology, Bozyaka Training and Research Hospital, İzmir, Turkey

[3]Department of Biostatistics, Hacettepe University, Ankara, Turkey

INTRODUCTION: Breast cancer has different molecular subtypes which determine the prognosis and response to the treatment. CD133 is a marker for cancer stem cells in tumor microenvironment with diagnostic/therapeutic importance. The tumor associated macrophages (TAMs) interact with the cancer stem cells through the CXCR1 receptor. In this study, we hypothesized a possible difference in distribution of CD133, CXCR1 and TAMs among different subtypes of breast cancer.
MATERIALS-METHODS: We investigated expression of antigens in samples of the patients with luminal A (LA), luminal B (LB), HER2 overexpressing (HER2OE), triple negative (TN) subtypes of breast cancer (n=70) and control patients (n=10) without cancer diagnosis. We applied indirect immunohistochemistry and evaluated immunostaining.
RESULTS: CD133 expression was at the periphery and CXCR1 expression was at the central area of the tumor (Fig1 and Fig3). The cytoplasmic CXCR1, CD133 expressions and nuclear CD133 expression (prominent in TN subtype) were observed in patients. There was a statistically significant difference between the groups for CD133 (p=0.004), CXCR1 (p=0.002) H-Score values and M2 macrophages/whole TAM ratios (p=0.022). There was a weak positive correlation (r=0.249, p=0.035) Between the CD133 and CXCR1 H-scores (Fig1, Fig2 and Fig3).
CONCLUSION: This study showed the compartment specific expression of the CD133 and CXCR1 antigens in neoplastic cells. The use of CD133 as a stem cell marker may be limited in TN subtype, due to its heterogeneous expression. The changes of polarity of macrophages in postmenopausal breast tissue might be a marker for the evaluation of breast cancer risk in obese and old women.

Keywords: Breast cancer, tumor microenvironment, CD133 antigen, CXCR1 receptor, tumor associated macrophages

Figure 1



CD133 immunostaining, HRP-Mayer's hematoxylin, x40. Carcinoma in situ focus of a LA patient. The tumor mass has peripheral CD133 expression (*)

Figure 2

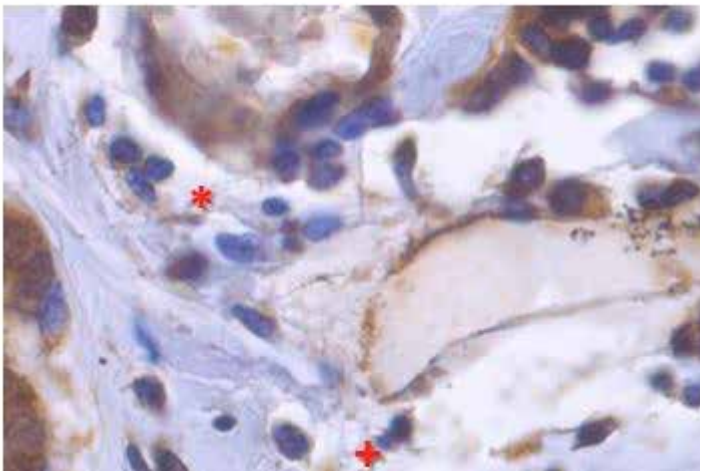

CD163 immunostaining. HRP-Mayer's hematoxylin, x40. Both infiltrating cells and tumor cells express CD163 antigen. The tumor, which belongs to LA subtype patients is surrounded by CD163+(+) and CD163- (*) infiltrating cells. CD163 expression is both cytoplasmic and membranous.

Figure 3

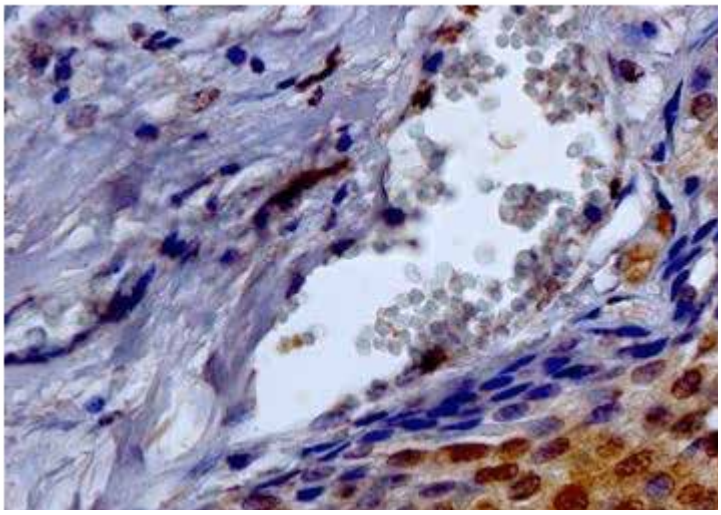

CXCR1 immunostaining. The compartment specific expression of CXCR1 antigen in carcinoma in situ focus of LA patient. Cytoplasmic and membranous expression of CXCR1 is at the central region of the carcinoma in situ focus (*).

10.5505/2017ichc.OP-55 [Cancer biology]

Loss of histone H4K20 trimethylation predicts poor prognosis in bladder cancer

Nuray Varol, Cem Karaosmanoglu
Department of Medical Genetics, Afyon Kocatepe University, Afyonkarahisar, Turkey

INTRODUCTION & OBJECTIVES: Epigenetics alterations play a pivotal role during carcinogenesis. DNA methylation intertwined with histone modifications and interplay in regulation of gene expression. Loss of histone H4 Lysine 20 methylation (H4K20me) is associated with multiple cancers, but its role in bladder cancer is unclear. Therefore, a goal of this study was elucidate the global H4, H4K20me1, H4K20me3 and enzymes responsible for these modifications in bladder cancer tissues.
MATERIALS & METHODS: Western blotting was performed for Histone 4(H4), H4K20me1, H4K20me3, SUV420H1 and PHF8 proteins on 18 bladder tumors and normal control samples.
RESULTS: By comparison with normal samples, our results indicated that H4K20 methylation (H4K20me1 and H4K20me3) levels demonstrated significant differences. H4K20me1, but not H4K20me3, was increased in bladder cancer tissue. An increased H3K20me1 protein level resulted from upregulated H4 protein level rather than overexpression of the histone H4K20 methltransferase enzyme SUV420H1, In contrast to increased H3K20me1 level, H4K20me3 protein level was decreased in tumor samples and also decreased between different tumor stages. It showed that there was inverse relationship between H4K20me1 and H4K20me3 in bladder cancer tissue. However, we observed that histone demethylase enzyme PHF8 protein expression level was increased in tumor samples.
CONCLUSIONS: H4K20me3 was decreased in bladder cancer as other types of cancers. This reduction H4K20me3 level was independent from H4K20me1 level in bladder tumor tissues. Reduced H4K20me3 level can due to overexpression of PHF8. In this study, we demostrated that the loss of H4K20me3 may be novel candicate for prognostic marker for bladder cancer patients.

Keywords: Histone modification, H4K20 monomethylation, H4K20 trimethylation, bladder cancer

10.5505/2017ichc.OP-56 [Cancer biology]

Association between CAT C-262T polymorphism and CAT enzyme activity in patients with leukemia

Nazan Eras[1], Anıl Tombak[2], Naci Tiftik[2], Mehmet Berköz[3], Gözde Türköz[4], Etem Akbaş[4]

[1]Department of Medical Genetics, Faculty of Medicine, Mersin University, Mersin, Turkey

[2]Department of Hematology, Faculty of Medicine, Mersin University, Mersin, Turkey

[3]Department of Pharmaceutical Technology, Faculty of Pharmacy, Yuzuncu Yil University, Van, Turkey

[4]Department of Medical Biology, Faculty of Medicine, Mersin University, Mersin, Turkey

INTRODUCTION and OBJECTIVES: ROS-induced DNA damage can result in mutagenic genetic alterations that can lead to initiation and progression of carcinogenesis; however, antioxidant defense enzymes can neutralize ROS. Catalase (CAT) is an endogenous antioxidant enzyme that catalyses the decomposition of hydrogen peroxide to water and oxygen. Genetic polymorphisms of CAT might alter ROS detoxification. The most common polymorphism of the CAT gene consists of a cytosine (C) to thymine (T) substitution in nucleotide 262 (-262C>T). This polymorphism influences transcription factor binding, reporter gene transcription and was described as being functionally associated with catalase levels. The purpose of our study was to investigate the possible association between CAT C-262T polymorphism and enzyme activity.
MATERIALS-METHODS: The case and the control groups consisted of 102 (32 ALL, 32 AML, 17 CLL, and 21 CML) (mean age: 51.3 ± 15.2; 50 females and 52 males) and 112 (mean age: 49.3 ± 12.8; 52 females and 60 males) individuals, respectively. PCR/RFLP was performed in order to identify the genotypes of both case and control group. CAT enzyme activity was measured by the method of Aebi.
RESULTS: The cases were slightly older, with a mean age of 51.3 as compared with 49.3 years for the controls. Distribution of gender was similar in both groups (p= 0.81). The ratio of T allele in control group was 25.9% and was 28.4% in case group (p=0.75). The frequencies of the CC, CT and TT genotypes in case group were 57.8%, 27.4% and 14.7%, respectively and 54.4%, 39.3% and 6.3% in controls, respectively. Compared with the CC genotype, OR values for CT and TT genotypes were 0.65 (95%CI, 0.36-1.19) and 2.21 (95%CI, 0.84-5.82), respectively. CAT enzyme activity of the individuals with TT genotypes belonging to CAT C-262T polymorphism was found 143.75±105.81 U/mL in control group, and decreased to 101.79±70.15 U/mL in leukemic patients, but this did not reach statistical significance (p=0.3).
CONCLUSIONS: These results suggest that CAT C-262T polymorphism and CAT enzyme activity do not play a significant role in the susceptibility to leukemia among Turkish Population. Furthermore, the gender might not an important risk factor for leukemia.

Keywords: Antioxidant, Leukemia, Oxidative stress, Catalase (CAT), Polymorphism

10.5505/2017ichc.OP-57 [Cancer biology]

Adjuvant therapeutic effect of cold atmospheric plasma on endometrium cancer cells

Işıl Aydemir[1], Utku Kürşat Ercan[2], Tülay Oludağ Mete[3], Sevinç Inan[4], Mehmet Ibrahim Tuğlu[1]

[1]Department Of Histology And Embryology, Faculty Of Medicine, Manisa Celal Bayar University, Manisa, Turke[y]

2Department Of Biomedical Engineering, Faculty Of Engineering And Architecture, İzmir Katip Çelebi University, İzmir, [T]urkey

3Department Of Obstetrics And Gynaecology, Perinatology, Faculty Of Medicine, Manisa Celal Bayar University, Manisa[4]Department Of Histology And Embryology, Faculty Of Medicine, İzmir University Of Economics, İzmir, Turk

Endometrial cancer is the most common carcinoma of the female reproductive tract. Type II endometrial tumors are generally more invasive, estrogen receptor and progesterone receptor (ER/PR) negative which MFE-319 endometrial carcinoma cell line is an example and aggressive form. Ishikawa cell line is an endometrial adenocarcinoma and estrogen receptor and progesterone receptor positive. Cold atmospheric plasma showed promising results in many cell lines for cancer therapy. The effect of cold atmospheric plasma were added to Cisplatin treatment on MFE-319 and Ishikawa cell lines for anticancer treatment.
Cisplatin were used at IC50 dose in culture and MTT was studied after 24 h treatment with cold atmospheric plasma. Then cells were stained immunocytochemically with PI3K/akt signal pathway which is critical for cell survival and cell growth markers PI3K, pErk1/2, Akt-1, pAkt-1/2/3 and also angiogenic factor VEGF. Immunoreactivities were evaluated H-score and analyzed using One-Way ANOVA test statistically. Signal molecules such as PI3K, pErk1/2, Akt-1and pAkt-1/2/3 were higher in control group compared to that of all other groups. Cisplatin was decreased the immunoreactivities of PI3K, pErk1/2, Akt-1 and pAkt-1/2/3. VEGF staining was the highest in control and was diminished in cisplatin application. All of these molecules were decreased after cisplatin treatment and the most effective group was combination of cold atmospheric plasma treatments.
These results were showed that cisplatin with products as alternative medicine resulted in more effective treatment in culture. These effects and mechanisms from signal molecules require further examination in experimental animal studies to confirm in biological tissues. The important effect of cold atmospheric plasma may give us clinical use and better patients quality life.

Keywords: Endometrial Carcinoma, Cisplatin, Cold Atmospheric Plasma, MFE-319, Ishikawa, PI3K/Akt.

10.5505/2017ichc.OP-58 [Cancer biology]

Label-free investigation of cancer cell behavior using quantitative phase imaging

Vratislav Kostal[1], Jan Balvan[1], Michal Masarik[2]

[1]TESCAN, Brno, Czech Republic

[2]Department of Physiology, Faculty of Medicine, Masaryk University, Brno, Czech Republic

Metastatic cancer have been known to use a large number of cellular mechanisms, which increase their resistance to chemotherapy. Some of them have been very rare (e. g. entosis), and can be easily left undetected by biochemical techniques or flow cytometry, which analyze large populations of cells. Because many of these mechanisms are associated with the changes in cancer cell morphology and relocation of cellular mass, they can be traced by time-lapse microscopy. Phase contrast or DIC microscopy have been commonly used methods for label free imaging of living cells. Although these techniques provide a good visual observation, the segmentation of cellular boundaries, which is a prerequisite for analyzing many parameters of individual cells (e.g. trajectory, mass, circularity), is very difficult.

Quantitative phase microscopy or imaging (QPI) allows detailed assessment of cell attributes due to the extremely high sensitivity in detecting even the smallest changes in mass density. This in turn allows very good segmentation of individual cells and further in depth analysis of many cellular parameters, such as mass changes, confluency, directionality, growth and many more. Based on these parameters, rare cells with unique behavior can be identified in large populations of cancer cells and eventually provide answers to origins of chemotherapy resistance.

Here, we used QPI as a method for a label-free quantification of unique proliferative properties of cancer cells and their changes in respect to various chemotherapeutic treatments. An examples of cell fate monitoring techniques and their use to evaluate rare variations in cancer cells chemotherapy response will be shown.

Keywords: label-free, quantitative phase imaging, cancer cell resistance, cell death, cell-cell interactions, entosis

10.5505/2017ichc.OP-59 [Cancer biology]

The Effects of Atmospheric Plasma and Oleocanthal on Cancer Cell Migration

Işıl Aydemir[1], Utku Kürşat Ercan[2], Pınar Kılıçaslan Sönmez[1], Mesut Mete[3], Mehmet Ibrahim Tuğlu[1]

[1]Department Of Histology And Embryology, Faculty Of Medicine, Manisa Celal Bayar University, Manisa, Turkey

[2]Department Of Biomedical Engineering, Faculty Of Engineering And Architecture, İzmir Katip Çelebi University, İzmir, Turkey

[3]Department Of Neurosurgery, Faculty Of Medicine, Manisa Celal Bayar University, Manisa

Cold atmospheric plasma cells, which have a wide use area, affects the processes of proliferation, migration and differentiation, but mechanisms of treatment are not fully known. Oleocanthal has anti-cancer, anti-inflammatory and anti-oxidative effects in vivo and in vitro conditions. In our study, we used MCF-7, MDA-MB-231 and NB2a cell lines and also adipose derived mesenchymal stem cells. The cells were exposed to different dilutions of oleocanthal and cold atmospheric plasma. After treatments MTT assay was applied to investigate cell proliferation rate and toxic effects of oleocanthal and cold atmospheric plasma. For cell migration test, cells were performed (+) plus shape using pipette tips. Cell proliferation and migration were evaluated in a semi-quantitative scoring system. Apoptosis and oxidative stress were assessed by TUNEL and NOS immunohistochemistry and immunoreactivities were analyzed using H-score method. According to MTT results, application of cold atmospheric plasma with oleocanthal significantly inhibited cancer cell proliferation migration whereas these parameters were increased in mesenchymal stem cells. However, immunoreactivities of NOS markers and TUNEL positivity were incresed in cancer cells whereas the opposite effect was observed in mesenchymal stem cells..
As a result of treatments, it was determined that cold plasma added to oleocanthal enhanced proliferation and migration in normal cells, which decreased proliferation and migration of cancer cells. It was thought that complementary treatment with a lesser side effect could provide a better quality of treatment using these agents.

Keywords: Cancer Cells, Mesenchymal Stem Cell, Oleocanthal, Cold Atmospheric Plasma, Oxidative Stress, Apoptosis.

Poster Presentations

*DOI numbers were assigned to all abstracts which were accepted for ICHC 2017

10.5505/2017ichc.PP-01 [Advances in image analysis]

Macroscopic and Microscopic Analyses of Chorioallantoic Membrane Assay for Angiogenesis

Yasin Ilgaz[1], Havva Ilgaz[2], Barış Baykal[1]

[1]Department of Medical Histology and Embryology, University of Health Sciences, Gulhane Faculty of Medicine, Ankara, Turkey

[2]Department of Hyperbaric Medicine, University of Health Sciences, Gulhane Faculty of Medicine, Ankara, Turkey

The chick chorioallantoic membrane (CAM) provides an in vivo model to study angiogenesis and evaluate several pro- and anti-angiogenic factors onto it surface, which are closely associated with cancer or inflammatory diseases. The CAM has been used since the early 1970's when it was adapted by Folkmann et al. While there have been, many variations developed over the years, the basic assay is performed by implanting via a membrane or directly containing the compound of interest on the chick embryo CAM through a hole cut in the egg shell. The subsequent incubation period ranges from 1-3 days, depending on the compound, after which time angiogenesis generally is analyzed by using macroscopic or stereomicroscopic images.

There are types of grading methods used for analyses of CAM results. In example evaluation of proangiogenic response; Zero describes a condition of the vascular network that shows no change from the time of treatment, 1 marks a slight increase in the vessel density associated with occasional changes in the course of vessels converging toward the implant; 2, 3, 4 and 5 indicate a progressive increase in vessel density associated with more pronounced changes in their course (Figure 1-A). Also vasoproliferative response is determined in that neovessels are counted contain inside a 1 mm diameter circle upon the CAM (the circle is drawn around the treatment area). Vessels branching dichotomically outside the circle are counted as 2, while those branching inside the ring are counted as 1 (Figure 1-B). These systems or similar grading systems are inefficient because they are present semi quantitative results.

WimCAM Assay is software product to quantitatively evaluate the angiogenesis in CAM membranes. Eventually, it gives seven result data associated with two quantitative parameters which are; number of segments and branching points. A segment is named premature vessel which is between two branching points. Branching points are parts of the premature vessel where two or more segments converge on (Figure 2).

Determining of results of CAM study are difficult process for researchers. Image Analysis Solutions possibly will help overcome this issue.

Keywords: Chorioallantoic Membrane, Angiogenesis, WimCAM assay

Figure 1

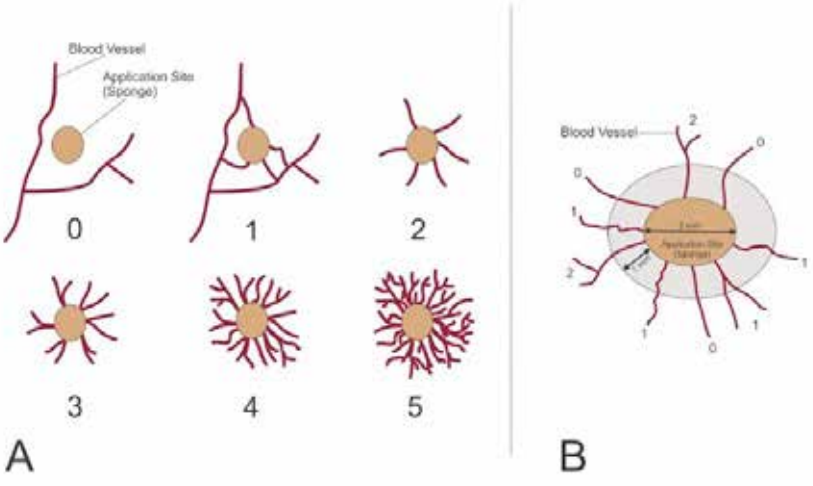

Figure 1: (A) Representative figures of proangiogenic response grading method. (B) Vasoproliferative response grading system.

Figure 2

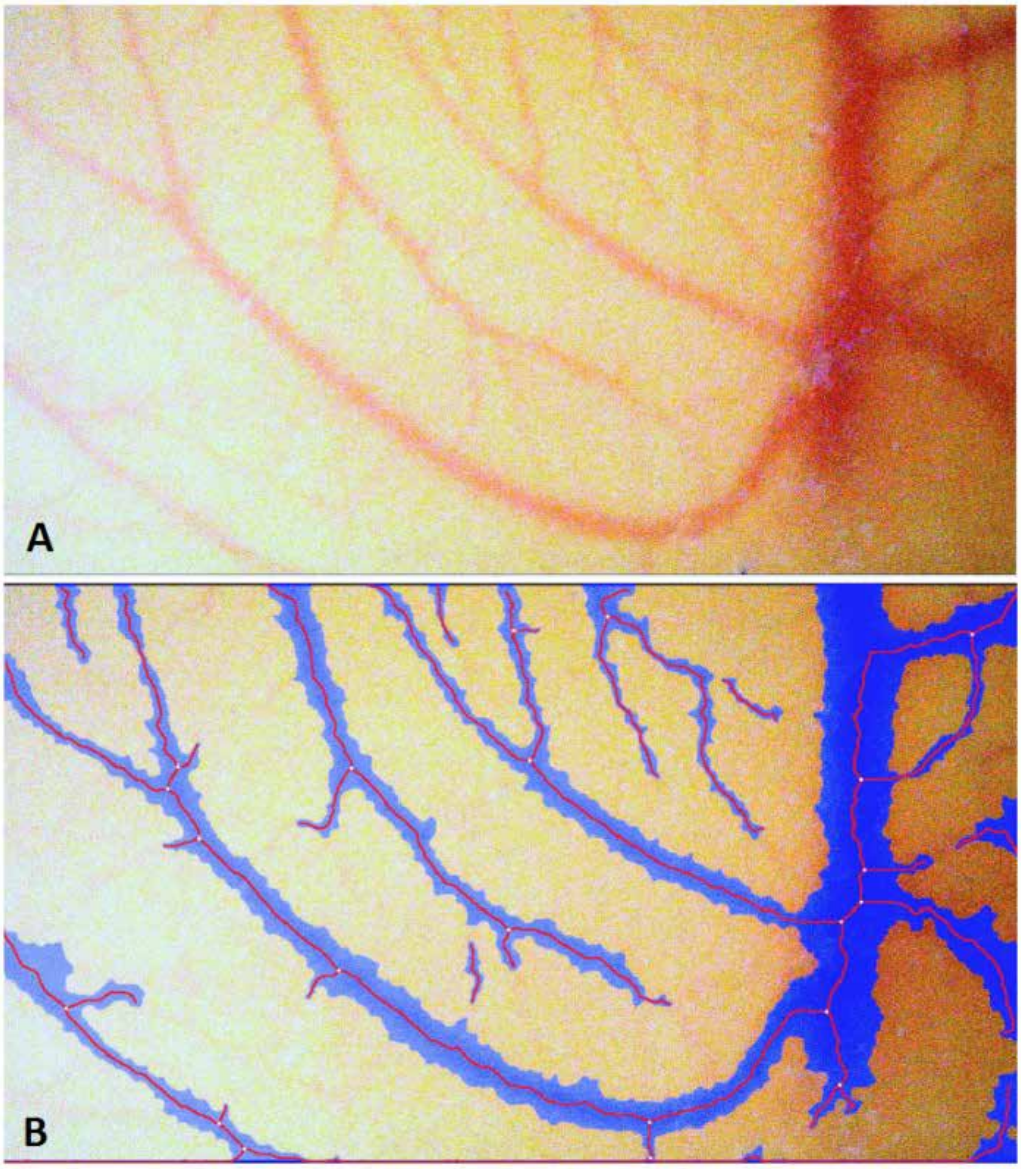

Figure 1: (A) The original stereomicroscopy image. (B) Resulting image of Wimasis-WimCAM; vessels (blue), premature vessel (red), and branching points (white) are marked

10.5505/2017ichc.PP-02 [Calcified tissues, biomaterials and regenerative medicine]

Histological Evaluation of Combined Effect of Parathyroid Hormone and Strontium Ranelate on Calvarial Bone Healing in Ovariectomized Rats

Funda Göker[1], Erdal Cevher[2], Selim Ersanlı[1], Emine Elif Güzel Meydanlı[3], Halim Işsever[4], Deniz Morina[2], Beyhan Ömer[5], Tuğba Ekiz Yılmaz[3], Elmire Dervişoglu[5], Volkan Arısan[1]

[1]Department of Oral Implantology, Istanbul University Faculty of Dentistry, Istanbul, Turkey

[2]Department of Pharmaceutic Technology, Istanbul University Faculty of Pharmacy, Istanbul, Turkey

[3]Department of Histology and Embriology, Istanbul University Cerrahpasa Faculty of Medicine, Istanbul, Turkey

[4]Department of Public Health, Istanbul University Istanbul Faculty of Medicine, Istanbul, Turkey

[5]Department of Biochemistry, Istanbul University Istanbul Faculty of Medicine, Istanbul, Turkey

Introduction&OBJECTIVES: Parathyroid hormone (PTH) enhances healing of bone. Strontium ranelate (SR) is an antiresorptive agent that increases bone formation. Reports about combined effects of PTH plus SR on local bone regeneration in state of osteoporosis are limited. This study searched the feasibility of using PTH and SR in combination to promote local bone repair of critical sized calvarial defects on ovariectomized rats.
Materials&METHODS: PTH and/or SR containing poloxamer (px) implant tablets with/without chitosan microparticles (mp) formed by crosslinking with tripolyphosphate as carriers were delivered to calvarial defects on rats. After bilateral ovariectomies, defects were created unilaterally on parietal bones of the animals and were grafted with suitable implant tablets. The treatment groups were as follows; (1) empty defects, (2) poloxamer (px)+chitosan microparticles (mp), (3) SR+px, (4) PTH+px, (5) PTH+px+mp, (6) PTH+SR+px, (7) PTH+SR+px+mp. Samples were obtained after sacrification at 4 and 8 weeks, stained with Hematoxylin-Eosin and Masson trichrome for histological and histomorphometrical evaluation of new bone formation and tissue response to biomaterial. Data were subjected to statistical analysis.
RESULTS: The quantitive and qualitative histological analysis revealed that calvarial defects treated with PTH+SR combinations showed statistically significant greater new bone formation than either treatment alone at both time intervals. When PTH is used alone, new bone formation promoted at 4 weeks but its efficiency declined at 8 weeks. On the other hand there was no positive effect of SR on bone formation at 4 or 8 weeks. Low tissue responses supported the good biocompability of chitosan/poloxamer scaffolds.
CONCLUSION: This present study demonstrated that PTH and SR combinations may have potential benefits to be considered as bone graft material to enhance bone healing of maxillofacial defects especially in compromised bone healing conditions.

Keywords: Parathyroid hormone, strontium ranelate, ovariectomized rat, critical size calvarial defect, bone healing

10.5505/2017ichc.PP-03 [Calcified tissues, biomaterials and regenerative medicine]

Evaluation of Osteogenically Induced Adipose Tissue Derived Mesenchymal Stem Cells on Fibrin Glue Coated Ceraform by Scanning Electron Microscope

Aysun Kılıç Süloğlu, Elif Karacaoğlu
Faculty of Science, Department of Biology, Hacettepe University, Ankara, Turkey

Introduction & OBJECTIVES: The use of adipose tissue derived mesenchymal stem cells (ADSC) as an autologous and self-replenishing source for bone tissue engineering provides promise for reconstructive surgery. Ceraform® (CR), is a synthetic calcium phosphate ceramic which has 65% hydroxyapatite and 35% tricalcium phosphate composition. The objective of this study was to characterize the attachment and viability of ADSC which were differentiated in to osteoblasts. Fibrin glue (FG) which potentially increases the cell adherence to CR and enhance the osteoinduction with also seeding ADSC on to it.
Materials & METHODS: In this study, ADSC were differentiated in to osteoblasts by osteogenic induction medium, and seeden on FG coated CR. At the time points of 1., 7., 14., 21. days of incubation, cells were fixed, coated with gold:palladium particles and visualized in scanning electron microscope (SEM).
RESULTS: The morphology of the CR scaffold and cells were observed by SEM. After 2 wk most pores were filled with new tissue as observed by SEM especially in FG coated CR groups when compared to non-coated CR groups. Besides, cells attached and proliferated, the calcification process occurred. In FG coated CR groups enhanced cell homing achieved.
CONCLUSIONS: These results showed that FG may be a good alternative in order to enhance cell attachment in bone grafts. Day 14 would be the best choise for osteoinduction as the cells were healthier, their connections were much more stronger, and infused successfully in to CR pores. Therefore, FG coated CR grafts would be a promising application with combination of osteoinduced ADSC in bone transplantation.
Acknowledgement: This study was financially supported by TUBITAK (Project No: 114Z112).

Keywords: adipse tissue mesenchymal stem cell, fibrin glue, Ceraform, scanning electron microscope

10.5505/2017ichc.PP-04 [Calcified tissues, biomaterials and regenerative medicine]

The Effect of Hyaluronic Acid Application on the Perisilicon Capsule Structure

Sedat Tatar[1], Ainura Sarybaeva[2], Kemal Fındıkçıoğlu[2], Cemile Merve Seymen[3], Çiğdem Elmas[3], Osman Latifoğlu[2]

[1]Department of Plastic, Reconstructive and Aesthetic Surgery, Kayseri Research and Training Hospital, Kayseri, Turkey

[2]Department of Plastic and Reconstructive Surgery, Medical School, Gazi University, Ankara, Turkey

[3]Department of Histology and Embryology, Medical School, Gazi University, Ankara, Turkey

Introduction and AIM: The purpose of this study, to investigate the effect of hyaluronic acid which is well known agent that effect wound healing and fibrosis in many different ways on perisilicone capsular formation that is a foreign body reaction that occurs in patients who receive silicone implants.
METHODS: 20 Wistar Albino rats were divided into 4 equal groups. Equal sized silicon blocks inserted the subcutaneus area of rat dorsum. Group 1A and 2A had only silicone block, group 1B and Group 2B was injected by 0,2 cc hyaluronic acid around silicone blocks. Group 1A and 1B were sacrified at fourth week, group 2A and 2B were sacrified at eighth week. The capsule thickness, collagen pattern, inflamatuar cells and fibrosis were determinated by Masson's Trichrome, HSP-47 and TGF-β1 stainings.
RESULTS: The capsule was composed of distinct layers, was similar in consistency in both groups, but of variable thickness, which differed significantly between each groups ($p<0.05$). Capsular thickness of Group 1B, which had hyaluronic acid was significantly had a thicker capsule. Group 2B had the thickest capsule and had the highest level of TGF-β1 which is a sign of fibrosis. HSP 47 levels were increased depending on amount of collagen towards Group 2B, but density of HSP 47 decreased towards Group 2B because of increased capsular thickness.
CONCLUSION: It was concluded that; the heat shock protein HSP-47 was found dense especially during the initial preiod of stress (1 month application groups), local hyaluronic acid administration was not prevent capsular contracture development but caused an increase of the thickness in the capsule. These data was also supported by TGF-β1 stainings. Crosslinked hyaluronic acid based fillers are useful material for soft tissue augmentation and correct wrinkles for aesthetical practice, but we have to be careful about these fillers if we want to use for decrease fibrosis and capsular thickness around silicone implants because of we saw negative effect on fibrosis and capsular formation.

Keywords: Capsul contracture, Hyaluronic acid, Perisilicon capsule formation, Silicon implant, Hsp-47, Tgf-beta 1

Figure 1



Figure 2

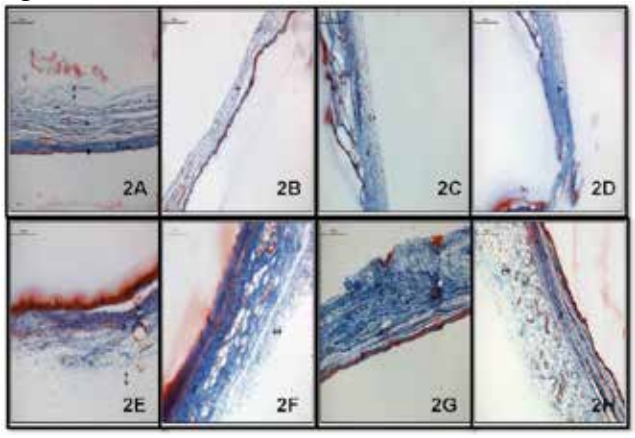

Figure 3

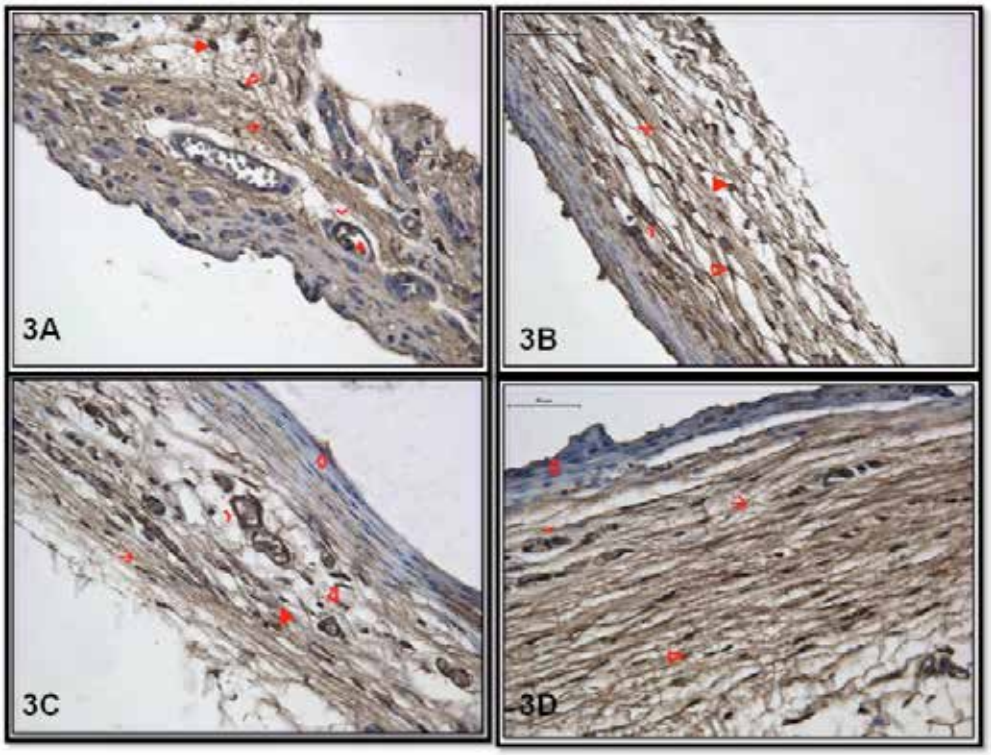

Figure 4

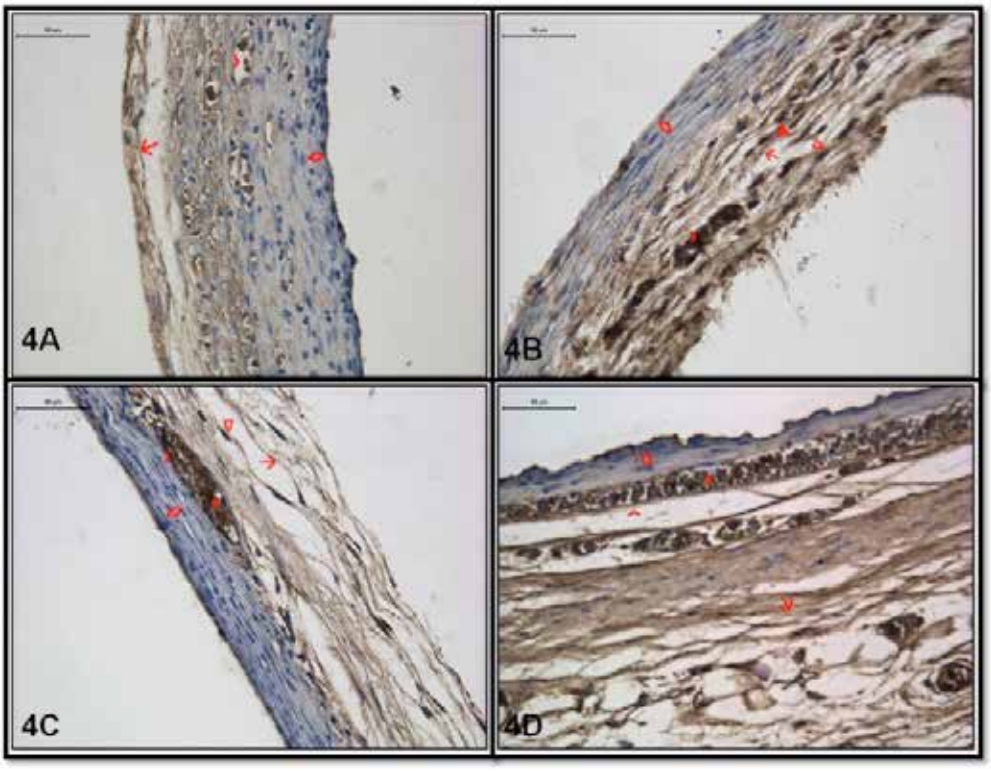

10.5505/2017ichc.PP-05 [Calcified tissues, biomaterials and regenerative medicine]

Comparing the effects of three different erythropoiesis stimulating agent [Erythropoietin, Methoxy polyethylene glycol-epoetin beta and Darbepoetin alpha] on wound healing

Ilknur Keskin[1], Mehmet Yalçın Günal[3], Nilüfer Aytürk[1], Bircan Kolbaşı[2], Mustafa Keskin[4], Ertuğrul Kılıç[3]

[1]Department of Histology and Embryology, Istanbul Medipol University, Istanbul, Turkey

[2]Regenerative and Restorative Medical Research Center (REMER), Istanbul Medipol University, Istanbul, Turkey

[3]Department of Physiology, Istanbul Medipol University, Istanbul, Turkey

[4]Department of Plastic And Reconstructive Surgery, Istanbul Medipol University, Istanbul, Turkey

The aim of the current study is to compare and assess the capacity of these three different erythropoiesis stimulating agents, Metoxy polyethylene glycol-epoetin,Darbepoetin alpha (DPO) and Erythropoietin (EPO) on rat wound healing model.
A total of 24 rats were divided into four groups. An excision wound was made on the back of the rat and treated with erythropoiesis stimulating agents.To assess the wound healing effects of the agents, photographic wound healing assessment was done by calculating wound surface area by an image analyzer. By light microscopic images, epidermal/dermal regeneration, granulation tissue thickness and angiogenesis analyzes were made. Finally, sections were imaged by confocal microscopy for immunoflorescence analyzes. AKT1, ENOS and JNK1 proteins both at the center of the wound and in the wound margin were evaluated.
Macroscopically the three different erythropoiesis stimulating agent used in this study showed significant increase in wound contraction rate, shorter epithelization time as compared to the control group but the difference three erythropoiesis stimulating agent was not significant.
The results of immunohistochemical staining revealed that in the three treatment groups AKT, ENOS and JNK-1 protein expressions at the wound had increased compared to the wound margins. But the differences between the treatment groups were not significant.
This study demonstrated that the new erythropoiesis stimulating agents may also have significant therapeutic potential for enhanced wound healing as much as Erythropoietin. Although these new two agents have a longer half-life and increased pharmacokinetic and pharmadynamic characteristics this did not led a better wound healing capacity than Erythropoietin.

Keywords: Wound healing, Erythropoietin, Methoxy polyethylene glycol-epoetin beta, Darbepoetin alpha, histopathology

10.5505/2017ichc.PP-06 [Calcified tissues, biomaterials and regenerative medicine]

The effects of an herbal mixture prepared from Uritica Diogia, Thymus Vulgaris, Glycyrrhiza Glabra, VitisVinifera, Alpinia Officinarum plants' oil-based extracts on wound healing

Irfan Taşdelen[1], Şule Ayla[2], Mehmet Yalçın Günal[3], Kaan Gideroğlu[1], Recep Demirhan[4], Özge Biçeroğlu[2]

[1]Center of Wound and Burn, Dr.Lütfi Kırdar Kartal Research Hospital İstanbul, TURKEY.

[2]Department of Histology and Embriyology, İstanbul Medipol University School of Medicine, İstanbul, TURKEY.

[3]Department of Physiology, İstanbul Medipol University School of Medicine, İstanbul, TURKEY.

[4]Department of Chest Surgery, Dr.Lütfi Kırdar Kartal Research Hospital, İstanbul, TURKEY.

A variety of medications and traditional approaches are used improve the process of wound healing. This agent is an herbal mixture and contains oil-based plants extracts from UriticaDiogia, Thymus Vulgaris, GlycyrrhizaGlabra, VitisVinifera, AlpiniaOfficinarum.
To investigate this agent that we prepared and standardised on wound healing, we used 28balb-c type mice in total; equally disturbed to four group.The first group is the control group to which we applied sunflower oil (sunflower oil is known to be not effecting the wound healing (reference molecule)). The second group is the comparison group to which we applied Vaseline and the third group is the herbal medication group that Vaseline and the herbal mixture was applied to. Lastly, the fourth group was called Madecassol group to which we applied a medical cream called Madecassol.
After wounding the mice, we applied the molecules andthe wound tissues were photographed. From the taken photographs, wound healing rates were calculated in digital measurement programs. After that, the wounded areas were cut out for fixation, and the tissues were buried in the paraffin.Hematoxylin-eosin (HE) and immunohistochemical (VEGF, FGF, collagen type I) staining and scoring were performed on five µm thickness sections from the tissues.
In the histopathological scoring, whereas less epidermal and dermal regeneration, medium dense granular tissue, four to five veins in each section were observed in the control and comparison group, in Madecassol and Medicine Group, we saw complete epidermal and dermal regeneration, dense granular tissue and more than seven veins in each section.
In the immunohistochemical scoring, a few staining was observed in some of FGF, VGEF and collagen 1 preparations of the control and comparison groups. In those groups were also some preparations which showed no staining. In the herbal medication group, we saw statistically significant increase in staining as well as we observed the same in Madecassol Group.
Consequently, our results indicate that the agent that we used can speed the healing process up andwe believe that this agent may be used as a medication after further investigations.

Keywords: Wound, healing, herbal agent

10.5505/2017ichc.PP-07 [Calcified tissues, biomaterials and regenerative medicine]

Effects of adipose drived stem cells in experimentally undescended testes rat model

Suna Saygili, Işıl Aydemir, Pınar Kılıçaslan Sönmez, Dila Hatun Sal, Fulya Gülbağça, Mehmet Ibrahim Tuğlu
Manisa Celal Bayar Üniversitesi Tıp Fakültesi Histoloji ve Embriyoloji Anabilim Dalı

Undescended testes is common clinical condition and it is started being treated late because generally not realised. In delayed situations testicles are damaged by the higher temperatures and can lead to infertility. Stem cells were found to be protective, curative in testicular damage and preventive in tumor formation, moreover, independent from what aim they are used, they were found to be unharmful. In this study, it was aimed that adipocyte derived stem cell (ADSC) treatment were thought to be investigated in the way of protective and curative effects in experimental undescended testes (EUT) damage.
In this study, Wistar male rats, which weighting 45±9 g and 16-19 days old were used and those who their testicles did not drop to scrotum. Rats were seperated in four groups control, EUT, EUT + media, EUT + ADSC. In control animals no application was done. In EUT group, testicle was stitched intraabdominally. In EUT+media group was injected 100 µl cell culture media. In EUT+ADSC group, animals were injected 1x106 ADSC in 100 µl media into the rete testis. On the day 3 and 7 after applications, testicles were dissected and weighted. Spermatogetic serial cell marker, VASA, for immunohistochemistry and TUNEL assay were performed. Data was analyzed using One-Way ANOVA test statistically.
In EUT applied testicles, oedemma and disassociation in between seminifer tubules, degeneration inside seminifer tubule, vacoulasation and picnotic cells and atrophic structures were observed. There were significant histopathologic differences via media and low amount of ADSC. With TUNEL the apoptotic death were shown. VASA staining was found to be high in positivity in early term, highest in control and decreased in early term, especially high in EUT group.
Undescended testes is an important problem of infertility and there are needs for methods to improve curability. Stem cells are substantial product for EUT treatment with everyday increasing potential. The positive contributions they gave to the testicles might be valuable findings in fields of infertility and assisted reproductive techniques. It is thought that stem cells based therapy is valuable to sustain a quality reproductivity.

Keywords: Undescended testes, stem cell, VASA, apoptosis, infertility

10.5505/2017ichc.PP-08 [Calcified tissues, biomaterials and regenerative medicine]

In Vitro Comparison of Cytotoxicity of Gutta Flow Bioseal, Gutta Flow 2, AH Plus and MTA Fillapex

Suna Karadeniz Saygılı[1], Gökhan Saygılı[2], Mehmet Ibrahim Tuğlu[1]

[1]Manisa Celal Bayar Üniversitesi Tıp Fakültesi

[2]İzmir Katip Çelebi Üniversitesi Diş Hekimliği Fakültesi

The aim of the study was to evaluate the cytotoxicity of Gutta Flow Bioseal (Coltene Whaledent, GmBHşCo KG,Langenau, Switzerland), Gutta Flow 2 (Coltene Whaledent), AH plus (Dentsply DeTrey, Konstanz, Germany) and MTA Fillapex (Angelus, Londrina, PR, Brazil) on L929 fibroblasts. Samples of the test materials Gutta Flow Bioseal, Gutta Flow 2, AH plus and MTA Fillapex were fabricated in teflon disks of 5 mm diameter and 3 mm thickness. L929 fibroblasts were exposed to extracts for 3 hours, 1 day, 3 and 7 days at 37°C with 5% CO2. Cell viability was evaluated by 3-(4,5-dimethylthiazolyl-2-yl)-2,5-diphenyltetrazolium Bromide (MTT). Apoptosis was determined by Terminal deoxynucleotidyl transferase-mediated dUTP nick end-labeling (TUNEL). The data were statistically analysed using analysed by using Kruskal Wallis test for comparison among groups and Dunn multiple comparison post test. The extracts of mixed GuttaFlow Bioseal were nontoxic at all experimental times ($p>0,05$), whereas the extracts of mixed MTA Fillapex and AH Plus were toxic to fibroblast cells ($p<0,001$). At 7 days, the number of viable cells in GuttaFlow 2 were more cytotoxic than that of control group and MTA Fillapex was more cytotoxic than AH Plus. The number of apoptosis in MTA Fillapex and AH Plus were more than others for 3 hours interaction ($p<0,001$). GuttaFlow sealers are less cyototoxic than MTA Fillapex and AH Plus. At all experimental times, the number of viable cells in GuttaFlow Bioseal were no difference statistically compared that of control group.

Keywords: L929, Cytotoxicity, TUNEL,

10.5505/2017ichc.PP-09 [Calcified tissues, biomaterials and regenerative medicine]

Histopathological and radiological correlation of stereotaxic biopsies obtained from non-palpable lesions which microcalcification detected in mammography

Fatma Dobur[1], Ceyhan Ugurluoglu[2], Seda Ozbek[3], Pinar Karabagli[2], Zeliha Esin Celik[2]

[1]Pathology Laboratory, Gumushane Public Hospital, Gumushane, Turkey

[2]Department of Pathology, Selcuk University, Konya, Turkey

[3]Department of Radiology, Selcuk University, Konya, Turkey

Mammography has changed show the form itself of breast cancer. Breast cancer is now can be diagnosed and treated smaller in size, even preinvasive period and before axillary metastasis. There are two different calcification according to view and chemical composition: calcium oxalate (type1) and calcium phosphate (type2). Calcium oxalate was associated with proliferate but non-invasive breast disease, calcium phosphate have been associated with benign tumors and invasive malignant tumors.
In Selcuk University Faculty of Medicine Department of Pathology, 66 stereotaxic biopsies obtained from non-palpable lesions which microcalcification detected in mammography were evaluated. Calcium oxalate / calcium phosphate was typing with the aid of histochemical Alizarin Red S (pH 4.1 to 4.3), von Kossa stains and polarized light. These two types of calcification determined relationship with histological diagnosis - especially lately we see increased detection "flat epithelial atypia" due to the presence of mammographic microcalcifications - and BI-RADS mammography category renewed in 2013.
In our study, while the entire calcium oxalates were found in the benign lesions, calcium phosphates were observed as benign and malignant lesions. Significant difference was found with benign / malignant lesions between calcium types and mammographic calcification morphologies. There was no significant relationship with diagnosis between mammographic calcification distributions and BI-RADS categories. In biopsies detected FEA, 2 calcium oxalate and 7 calcium phosphate were observed. The most common was reported as amorphous morphology, forming groups and BI-RADS category 4B.
Eventually it can said that including calcium oxalate biopsies can be considered in favor of benign. In recently studies, there is evidence to be determined type of calcium by the non-invasive spectrometric analysis. So it is possible that minimize the surgical procedures.

Keywords: Breast tumors, Calcium oxalate, Flat epithelial atypia, Mammography

Figure 1: Apocrine metaplasia, including calcium oxalate (H&Ex100)

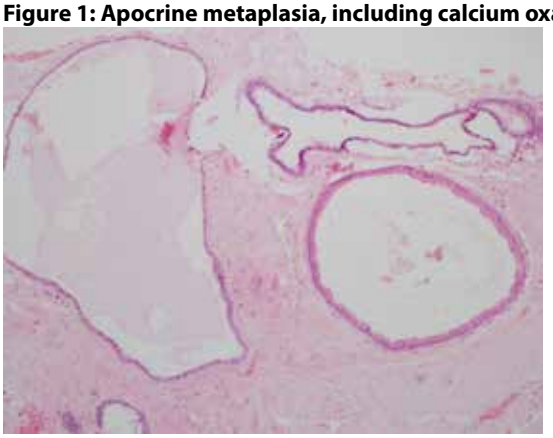

Figure 2: In the same area of apocrine metaplasia to reflux under polarized light

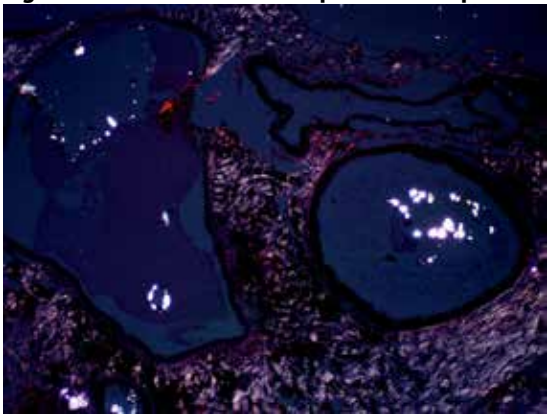

Figure 3: There is no staining with Alizarin Red S pH (4,1-4,3) in apocrine metaplasia



Figure 4: There is no staining with von Kossa in apocrine metaplasia



Figure 5: Mammographic image of apocrine metaplasia, showing microcalcifications linear distribution in amorphous morphology, BI-RADS 4B.

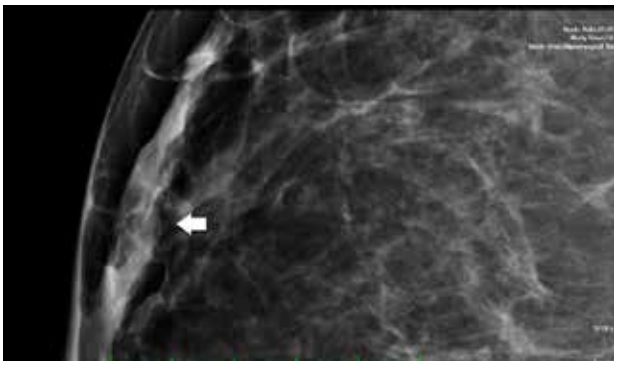

Figure 6: DCIS, including calcium phosphate (H&Ex100)

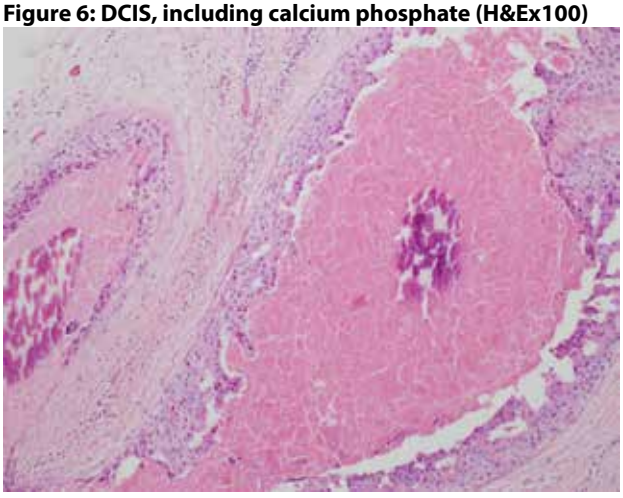

Figure 7: There is staining with Alizarin Red S pH (4,1-4,3) in DCIS



Figure 8: There is staining with von Kossa in DCIS



Figure 9: Mammographic image of DCIS, showing microcalcifications groups distribution in fine pleomorphic morphology, BI-RADS 4B.

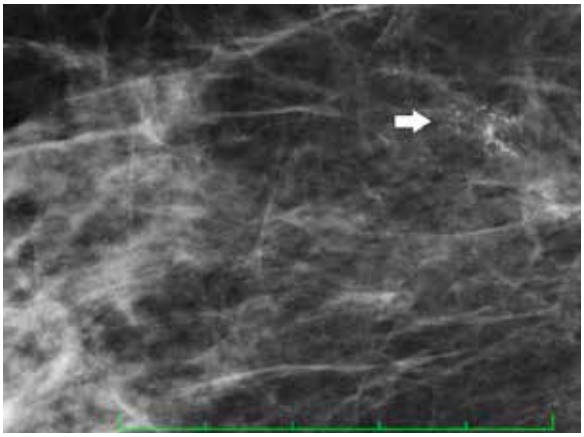

10.5505/2017ichc.PP-10 [Calcified tissues, biomaterials and regenerative medicine]

The viability evaluation of cartilage grafts prepared in different ways for rhinoplasty

Elvan Şahin[1], Gürkan Kayabaşoğlu[2], Sevinç Yanar[3], Fikrettin Şahin[4], Osman Nuri Keleş[5], Mahmut Sinan Yılmaz[6], Mehmet Güven[6]

[1]Department of Histology and Embryology, Medical School, Sakarya University, Korucuk, Sakarya, Turkey

[2]Otorhinolaryngology, Alle Klinik, Atasehir, Istanbul, Turkey

[3]Department of Medical Biology, Medical School, Kocaeli University, Izmit, Kocaeli, Turkey

[4]Department of Genetics and Bioengineering, Faculty of Engineering and Architecture, Yeditepe University, Istanbul, Turkey

[5]Department of Histology and Embryology, Medical School, Ataturk University, Erzurum, Turkey

[6]Department of Otorhinolaryngology, Medical School, Sakarya University, Korucuk, Sakarya, Turkey

INTRODUCTION & OBJECTIVES: Over the past 20 years, free cartilage grafts have been used extensively to provide shaping and structural support in nasal surgery. Cartilage grafts have a wide range of uses and advantages, but along with that utility come a source for complications. Numerous experimental and clinical studies have been performed to investigate the best preparation technique of harvested cartilage for grafts. Our study focuses on the modification of cartilage in three distinct ways: crushed, morselized, and diced. The investigation of viability of the cartilage samples prepared in different ways was performed using a confocal microscope.
MATERIALS & METHODS: In this study, cartilage samples were extracted from the ears of seven New Zealand rabbits and subsequently, were either diced, crushed or morselized to an amorphous state, or left unmodified (composite). The 4 different types of grafts were then implanted in the back regions of the rabbits (Figure 1).
After 3 months, the implanted grafts and the intact ear cartilage (control) were removed from sacrificed animals. 100 µm-thick cartilage sections were stained using a LIVE/DEAD® Viability/Cytotoxicity kit and then, examined using a confocal laser scanning microscope. Numerical densities of live and dead cells were estimated using a stereological investigation method (Figure 2).
RESULTS: Live cells were stained green color, and dead cells red. Analysis of the data obtained from the enumeration of live cells showed no statistically significant difference between the unmodified group and the control group. The diced, crushed, and morselized cartilage groups did show a statistically significant difference in terms of live cell count with the highest number of live cells in diced cartilage group. A statistically significant decrease in live cell count was detected in crushed cartilage group (Table 1).
CONCLUSION: In conclusion, our study shows that the viability of diced cartilage graft is greater than both crushed and morselized cartilage grafts.

Keywords: Cartilage graft, rhinoplasty, nasal surgery, viability, confocal microscope, stereology

Figure 1

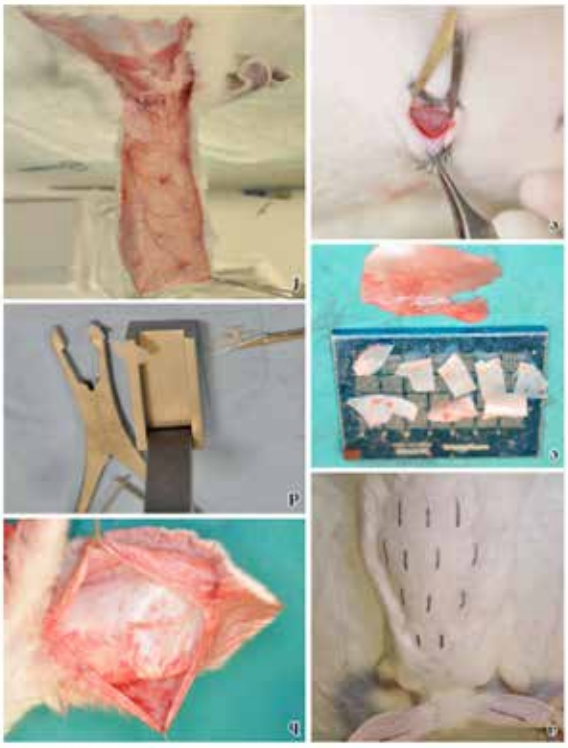

Cartilage graft preparation

Figure 2

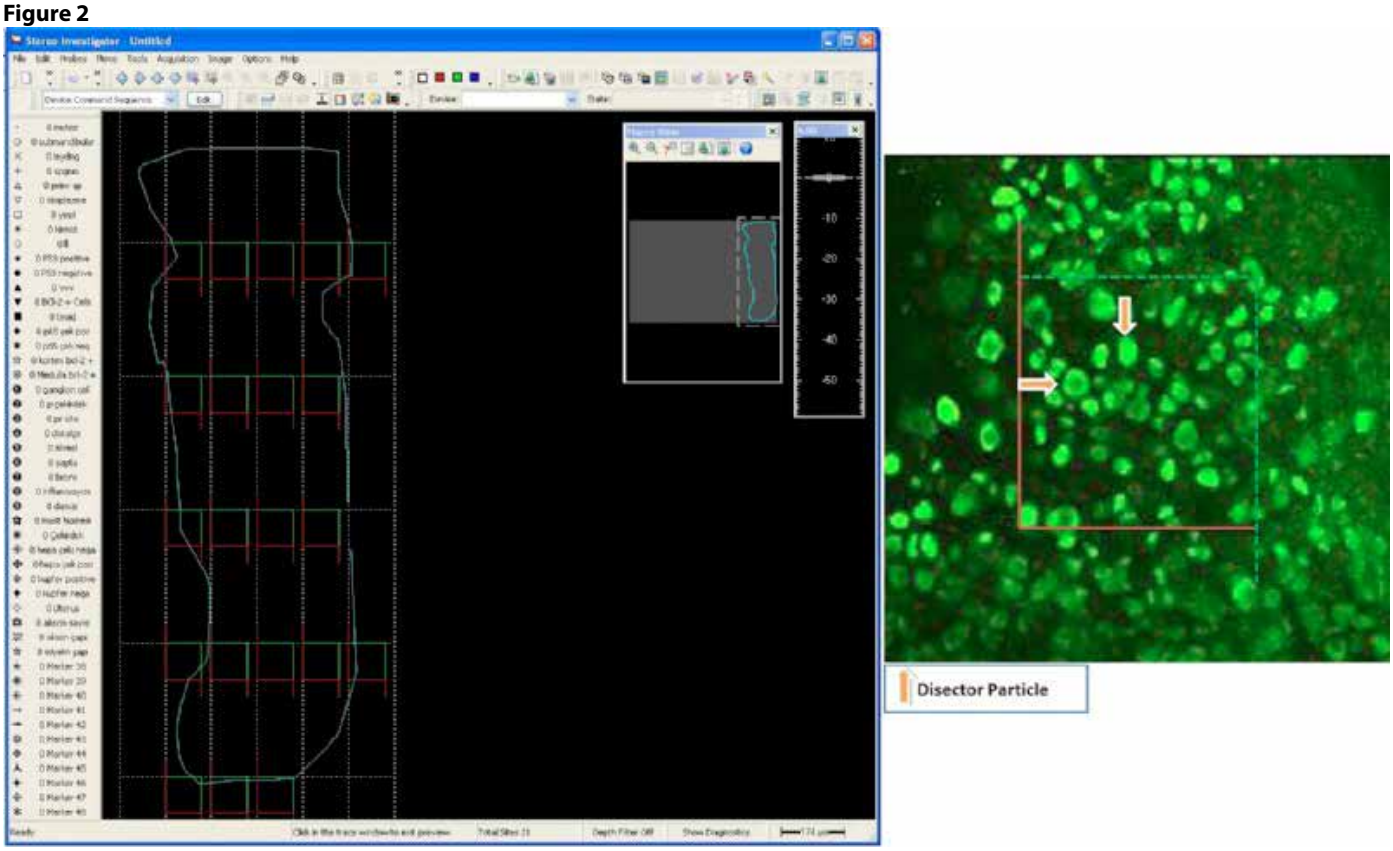

Stereoinvestigator image of live cells

Table 1. Effects of different treatments on the numerical density of live and dead cells in cartilage tissue of rabbits.

Treatment groups	Number of rabbits	Numerical Density of Live Cells (n/μm^3)	Numerical Density of Dead Cells (n/μm^3)
Control	7	0,000095±0,000001c	0,00000±0,000000c
Unmodified	7	0,000098±0,000005c	0,00009±0,000040b
Crushed	7	0,000030±0,000012d	0,00008±0,000031b
Diced	7	0,000137±0,000006a	0,00001±0,000003c
Morselized	7	0,000111±0,000008b	0,00012 ±0,000040b

Notes: Means in the same column by the same superscript letter are not statistically significantly different under the Duncan test (α=0.05). Results are mean±standard deviation.

10.5505/2017ichc.PP-11 [Calcified tissues, biomaterials and regenerative medicine]

Investigation of the biocompatibility of a novel multi walled carbon nanotube based scaffold in human breast cancer cell line MDA-MB-231

Pinar Kilicaslan Sonmez[1], Cengiz Kurtman[2], Mahmud Mustafa Ozkut[1], Eser Metin Akinoglu[4], Michael Giersig[3], Sevinc Inan[5], Kemal Ozbilgin[1]

[1]Department of Histology and Embryology, Faculty of Medicine,Celal Bayar University, Manisa, Turkey

[2]Faculty of Medicine, Ankara University, Ankara, Turkey

[3]Department of Physics, Freie Universitat Berlin, Berlin, Germany

[4]Max Planck Institute of Colloids and Interfaces, Postdam, Germany

[5]Department of Histology and Embryology, Izmir University of Economics, Izmir, Turkey

The application of bioengineered scaffolds is recently one of the crucial factors in tissue engineering. Multi walled carbon nanotube based nanostructured scaffold (MWCNTs) is a novel biomaterial and its effects in cell culture studies are not known yet. In this study we aimed to show biocompatibility of MWCNTs in human breast cancer cell line (MDA-MB-231).
MDA-MB-231 human breast cancer cells were cultered in cell culture medium RPMI 1640 containing 10% FBS, 1% L-glutamine, 1% penicillin-streptomycin. MWCNT based scaffold was washed with distilled water three times before the seeding cells onto the material. After that they were sterilized by ethylene oxide. MWCNT based scaffold was placed on one well of 12-well cell culture cluster and silicon reference was placed on another well and 1 9 105 cells were seeded in each well of 12-well cell culture cluster to obtain a confluent monolayer. The culture medium was changed every other day and the experiment was terminated one week after the start. The half of the incubated cells were collected by scraping for immunocytochemical staining. The cells were centrifuged and put on slides using drop method. Remaining cells on the surface of materials were fixed with glutaraldehyde to be imaged by scanning electron microscope.
The resulting out come from SEM analysis showed that the cells on the MWCNT-based scaffold proliferate widely. On the other hand the results of immunocytochemical staining of cells with Estrogen, Progesterone, MMP-2, MMP-9, PI3K, AKT and NF-KB primary antibodies showed that there was no significant difference between groups compared to hormone receptor status and their ability of proliferation, migration and metastasis. These results demonstrated that the MWCNT based scaffold is biocompatible for breast cancer studies so MWCNT based scaffold and these properties made it to plausible potential candidate for tissue engineering or other biomedical applications.

Keywords: MWCNTs, breast cancer, biocompatible

10.5505/2017ichc.PP-12 [Calcified tissues, biomaterials and regenerative medicine]

The effect of administration of nanoparticles on testis structure

Serkan Deveci[1], Merve Acikel Elmas[2], Deniz Yucel[2], Mehmet Selcuk Keskin[3], Sibel Demirci Delipinar[4], Ismail Seckin[4], Ahmet Sahin[3], Serap Arbak[2]

[1]Department of Urology, Bahcesehir University School of Medicine, Istanbul, Turkey

[2]Department of Histology and Embryology, Acibadem University School of Medicine, Istanbul, Turkey

[3]Department of Urology, Acibadem University, School of Medicine,,Istanbul, Turkey

[4]Department of Histology and Embryology, Istanbul University Cerrahpasa Faculty of Medicine, Istanbul, Turkey

The use of nanobiotechnology in human health has been increased in recent years. Drug carrier nanoparticles with their wide range of uses and advantages are promising approaches for the treatment of many diseases. The aim of this study is to investigate the effects of oral and local treatment of the silica based nanoparticles (diameter of 80 nm) on testis structure. In oral administration group, nanoparticles were applied to animals via gavage as 20 mg/kg. On the other hand, nanoparticles were applied topically to the penis in coconut oil as 2mg/cm2 for local application. Both local and oral applications were done every three days for 35 days, and the animals were sacrificed on day 35. Testes samples were prepared for paraffin sections. Sections were stained with Haematoxylin–Eosin (H&E) and Periodic acid–Schiff (PAS) reaction for light microscopical examination. H&E and PAS stained sections were evaluated for histopathological scoring and number of normal, regressive, degenerative or atrophic tubules were determined. In order to determine the localization and expression of occludin in seminiferous epithelium, samples were examined using semiquantitative and statistical analysis. For transmission electron microscopical examination, testes samples were fixed in 2.5% glutaraldehyde and processed for epoxy resin embedding. Normal morphology of seminiferous tubules were observed in control group. In both gavage and local groups, the number of normal tubules decreased while the number of regressive tubules has been increased. It was observed that the number of degenerative and atrophic tubules was higher in oral administration group compared to local application group. The immunohistochemical results showed that occludin immunoreactivity was higher in local group comparing to the oral administration group. Ultrastructural examinations demonstrated germinal epithelial damage which was less in local group compared to oral administration group. The results revealed that toxicity of silica nanoparticle on the male reproductive system is low in both applications, particularly in local application. Therefore, these silica nanoparticles would be used as a drug delivery system in the treatment of male reproductive system disorders for the further studies.

This study was financially supported by The Scientific and Technological Research Council of Turkey (TUBITAK)- project number 215S642.

Keywords: Microscopy, Testes, Occludin immunohistochemistry, Blood-testes barrier

10.5505/2017ichc.PP-13 [Calcified tissues, biomaterials and regenerative medicine]

Effects of revascularization when different alloplastic implant materials are used in adjacently with acellular dermal matrix

Sevin Fariz[1], Meryem Ilkay Karagül[2], Şakir Necat Yılmaz[2], Kezban Kibar[2], Merve Türkegün[3]

[1]Department of Plastic Reconstructive and Aesthetic Surgery, Numune Research and Education Hospital, Adana, Turkey

[2]Department of Histology and Embryology, Mersin University, Mersin, Turkey

[3]Department of Biostatistics and Medical Informatics, Mersin University, Mersin, Turkey

Introduction & OBJECTIVES: Autologous tissue transplantation is the gold standard in the repair of tissue defects. The aim of the present study was to determine the revascularization rate/amount in the acellular dermal matrix (ADM) when alloplastic implant materials (AIM) of different types are incorporated into the reconstruction.
Materials & METHODS: Wistar albino rats were allocated into three groups, each comprising seven rats: different AIMs (medpor, titanium, tricalcium, silicone) covered with ADM was inserted into different skin pouches created on thoracodorsal region of the rats and sampling was performed at Day 7 (Group I); at Day 14 (Group II); at Day 21 (Group III). In all groups, only ADM was inserted into the fifth skin pouche created on the right thoracodorsal region, which was used as the control (Figure 1). Specimens were fixed in 10% neutral buffered formalin solution and prepared for routine histologic evaluation. Sections were stained with hematoxylin-eosin and they were examined by light microscopy. Revascularization was evaluated quantitatively with immunohistochemistry by using anti-CD105 antibody for determining at different time zones.
RESULTS: Histopathological examination showed minimal revascularization in Group I, significantly increased revascularization in Group II and Group III. Used ADM and alloplastic implants revealed that there was a statistically significant increase in the number of the CD105-positive vessels obtained on the 7th, 14th and 21st day (Figure 2, 3 and Table 1). There was a significant difference between the evaluation days regarding the mean values of the vascularization numbers in the medpor, the titanium, the tricalcium and the silicone group (Table 2). The increase in the number of CD105-positive vessels was statistically significant between the 7th and 21st days in all groups (Figure 4). There was also a statistically significant difference between the 14th and 21st day regarding the vessel counts in the tricalcium group and the silicone group (Figure 4).
CONCLUSIONS: We conclude that distinct AIMs which are used adjacently to ADM has no adverse effect on the revascularization rate. This is the most wanted goal for soft tissue reconstruction. Revascularization is one of the major components of reconstructive surgery in the repair of clinical defects.

Keywords: Transplantation, acellular dermal matrix, alloplastic implant, revascularization

Figure 1

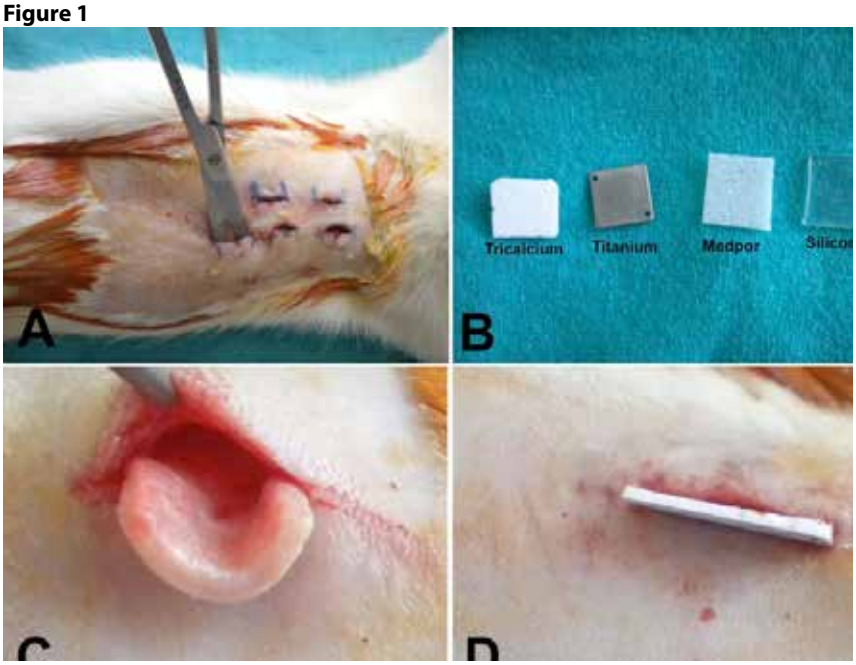

A) Different skin pouches created on thoracodorsal region of the rats. B) Used different alloplastic implant materials. C) The acellular dermal matrix and D) the tricalcium was inserted into skin pouche created on thoracodorsal region

Figure 2

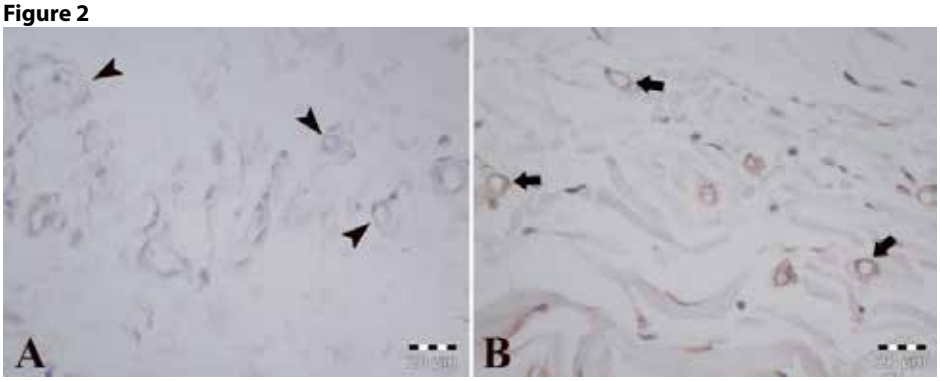

CD105 immunolabeling. A) CD105-negative vessels in the immunohistochemical negative control sections (arrowheads). B) CD105-positive vessels (arrows).

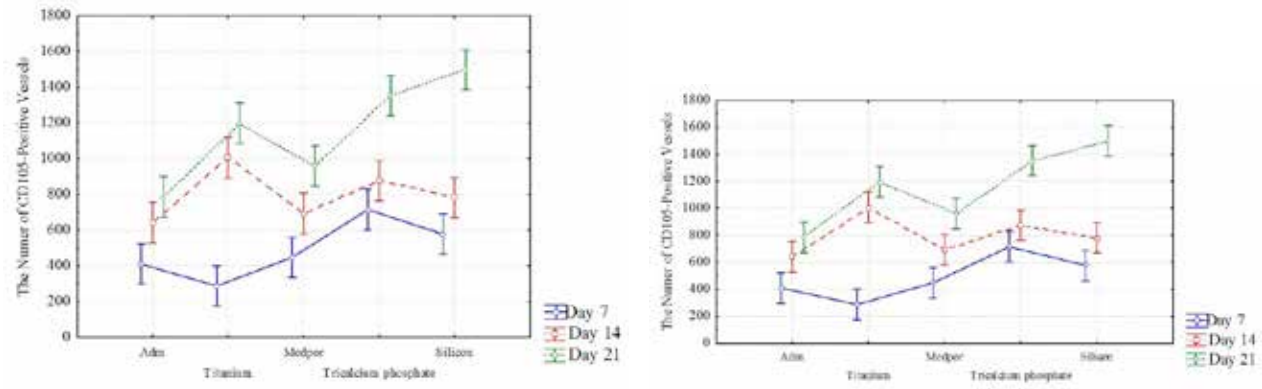

Figure 3 Graphical comparison of the CD105-positive vessel numbers regarding the ADM and alloplastic implants.
Figure 4 Graphical comparison of the CD105-positive vessel numbers regarding the ADM and alloplastic implants on the 7th, 14th and 21st day.

Table 1

	7. DAY	14. DAY	21. DAY
	Mean±s.d	Mean±s.d	Mean±s.d
ADM (CONTROL)	410,143±143,621	642,143±98,038	787,000±92,958
TITANIUM	287,285±83,910	1006,285±118,828	1198,285±66,737
MEDPOR	448,143±97,992	693,428±187,963	960,143±161,048
TRICALCIUM	715,285±79,611	876,000±162,811	1353,428±180,268
SILICON	577,428±192,598	782,714±215,065	1497,571±240,747
Total	487,657±190,770	800,114±201,850	1159,285±301,966
	pa <0,0001 F=11,665	pb =0,002 F=5,636	pc = <0,001 F=22,428

The CD105-positive vessel numbers regarding the ADM and alloplastic implants.

Table 2

	7. GÜN	14. GÜN	21. GÜN	
	Mean±s.d	Mean±s.d	Mean±s.d	
ADM (CONTROL)	410,143±143,621	642,143±98,038	787,000±92,958	pd=<0,0001 F=19,519
TITANIUM	287,285±83,910	1006,285±118,828	1198,285±66,737	pe=<0,0001 F=189,073
MEDPOR	448,143±97,992	693,428±187,963	960,143±161,048	pf=0,001 F=19,431
TRICALCIUM	715,285±79,611	876,000±162,811	1353,428±180,268	pg<0,0001 F=35,406
SILICONE	577,428±192,598	782,714±215,065	1497,571±240,747	ph<0,0001 F=34,672
Total	487,657±190,770	800,114±201,850	1159,285±301,966	

CD105-positive vessel numbers regarding the ADM and alloplastic implants on the 7th, 14th and 21st day.

10.5505/2017ichc.PP-14 [Calcified tissues, biomaterials and regenerative medicine]

The Effect of Alpha-Glucan on MAPK Signaling Pathway and Its Impact on Osteogenic Differentiation of Mesenchymal Stem Cells

Gokhan Duruksu[1], Leyla Kayiş[2], Zehra Seda Ünal Halbutoğulları[1], Gülçin Gacar[1], Yusufhan Yazır[1]

[1]Center for Stem Cell and Gene Therapies Research and Application, Kocaeli University, Kocaeli, Turkey

[2]Department of Stem Cells, Kocaeli University, Kocaeli, Turkey

Introduction & Objectives. The biomaterials show great variations in their mechanochemical characteristics. Such materials might not compatible with the biological systems and unable to support the cellular-events, like cell proliferation, viability or cell-differentiation. The surface coating with different materials can improve the main material. Alpha-glucan was isolated from the yeast-biomass to evaluate its potential use as a coating material for the tissue-engineering scaffolds and the cell-culture consumables. Osteogenic differentiation of mesenchymal stem cells (MSCs) on the alpha-glucan was particularly focused in this study.
Materials & Methods. After the isolation of alpha-glucan by hot-extraction, the alpha-glucan content was measured, and the toxicological evaluation was made by lactate dehydrogenase (LDH) and Wst-1 assays. After the incubation of human bone marrow derived MSCs on the coated culture flasks with alpha-glucan, the induction of core-MAPK-signaling-pathway proteins and osteogenic differentiation markers were evaluated by gene expression analyses.
Results. The analyses point out that this material didn't cause a significant decrease in the viability of the MSCs. According to LDH assay, alpha-glucan didn't show any significant toxic effect. Additionally, the coated surfaces gained improved characteristics for cell adhesion and proliferation. To determine the impact of alpha-glucan in the early-stage-osteogenic differentiation, the cells were induced chemically for 3-weeks, and gene expression analysis was performed to assess the signaling pathways. After 1-week, the expression of the early osteogenic differentiation marker, cFos, was increased without any chemical induction, followed by increased expression of earlyMAPK-pathway-proteins. With the differentiation supplements, the up-regulation of these expressions became more significant, especially those of JNK1 and MEKs. After 3-weeks culture, the effect of alpha-glucan on MAPK-pathway became stronger. The chemically induced cells on coated surface even showed intermediate-osteogenic differentiation markers in parallel to the stimulated MAPK-pathway.
Conclusions. We found that the coating of culture surface with alpha-glucan improved the efficiency of the early osteogenic differentiation by inducing the signaling of core-MAPK-pathway. The activation of this molecular pathway also regulated cell proliferation and survival, observed in the early-stage of this study. As a conclusion, alpha-glucan might be a choice for the coating material of scaffolds, and it can be used as biocompatible material in 3D-printing.

Keywords: Alpha glucan, Biomaterials, Mesenchymal Stem Cells, Osteogenic Differentiation, Surface Coating

10.5505/2017ichc.PP-15 [Calcified tissues, biomaterials and regenerative medicine]

Encapsulation of Beta Cell Line, BRIN-BD11, in Platelet-Rich Plasma - Calcium Alginate/Poly-L-Histidine/Alginate Microbeads

Gokhan Duruksu[1], Selen Polat[2], Leyla Kayiş[2], Nur Ekimci Gürcan[2], Gülçin Gacar[1], Yusufhan Yazır[1]

[1]Center for Stem Cell and Gene Therapies Research and Application, Kocaeli University, Kocaeli, Turkey

[2]Department of Stem Cells, Kocaeli University, Kocaeli, Turkey

Introduction & Objectives. Encapsulation is a widely used method, especially in the case when the cells must be protected from the external attacks. The development of a functional system, which supports the insulin production in response to the varying glucose-level in the medium while protecting cells from the immune attacks at the same time, is quite important for the long-term treatment of type-1 diabetes. Because of the harsh processing method in the production of alginate/poly-L-histidine/alginate (APA) microbeads, the viability might be significantly decreased and even become unsuitable for the transplantation. To overcome this problem, rat platelet-rich plasma (PRP), which consists of many growth factors and other biologically active compounds, were used. The aim was to show the supportive effect of PRP in the encapsulated BRIN-BD11 cells by preventing the cells from the cell-death.
Materials & Methods. In this study, rat beta cell lines, BRIN-BD11, were first encapsulated with alginate. Following the coating with poly-L-histidine, the microbeads were covered with a second layer of alginate to protect the cells from any external contact with other cells, like T-lymphocytes. Rat PRP were mixed with two different alginates (medium and high viscosity) preparations separately, and used in the encapsulation by cationic ions. The cell viability was assessed by CalceinA/Ethidium homodimer (EthD-1) staining and Wst-1 assay.
Results. The single alginate preparations gave no significant difference in the cell viability, but the application of poly-L-histidine improved the viability at 27.7% and 61.1% in the medium and high viscous alginate microbeads. The PRP addition to the alginate composition further increased the number of the viable cells to 1.44- and 1.95-folds, respectively. The insulin secretion from the beads was estimated by ELISA and insulin secretion in response to increased glucose level was determined. The insulin secretion was improved by the addition of PRP.
Conclusions. In conclusion, high viscous alginate preparation gave the best outcomes, and the PRP addition within the microbead structure substantially improved the cell viability and consequently the insulin secretion level. PRP supplemented APA-microbeads might have the potential to be used as cell vehicles in the treatment of type-1 diabetes.

Keywords: Alginate, Beta cells, Diabetes, Encapsulation, Insuline, Polypeptides

Figure 1.

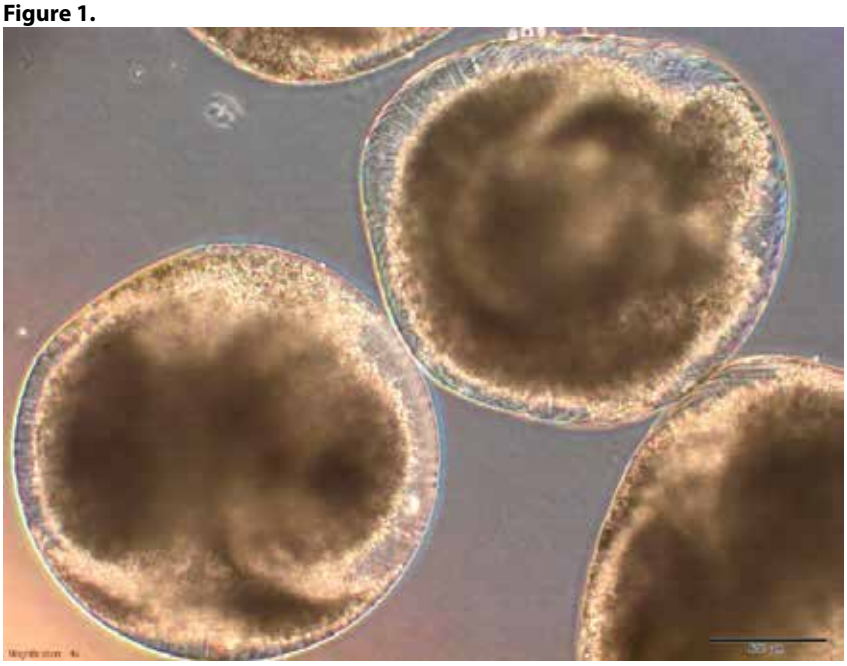

BRIN-BD11 cells encapsulated within calcium alginate/poly-L-histidine/alginate. Platelet-rich plasma (PRP) were mixed with the matrix to improve its stiffness and stability, and supporting the cells with growth factors at the same time.

10.5505/2017ichc.PP-16 [Cellular aging and cell death]

Comparison of the Neuroprotective Effects of Brimonidine Tartrate and Melatonin on Retinal Ganglion Cells

Deniz Marangoz[1], Emine Elif Güzel Meydanlı[2], Siğnem Eyüboğlu[3], Aslı Gümüşel[2], Ismail Seçkin[2], Bayram Yılmaz[3], Ilgaz Yalvaç[1]

[1]Department of Ophthalmology, Yeditepe University Faculty of Medicine, Istanbul, Turkey

[2]Department of Histology and Embryology, Istanbul Unıversity Cerrahpasa Faculty of Medicine, Istanbul, Turkey

[3]Department of Physiology, Yeditepe University Faculty of Medicine, Istanbul, Turkey

Glaucoma is a group of neurodegenerative conditions, which mainly involves the retinal ganglion cells (RGCs) and axons. It is the second leading cause of blindness worldwide. More than 60 million people are affected globally and it is estimated that more than 80 million people will be affected by 2020 and 10% of affected people will be suffering from bilateral blindness.
In this study we aimed to compare the neuroprotective effects of intraperitoneal injection of brimonidine tartrate (BRT) and melatonin (MEL) on retinal ganglion cells (RGCs) in a rat glaucoma model.
Thirty-six adult Wistar albino rats were allocated into six groups: Control (C), glaucoma (G), BRT, MEL, G+BRT, G+MEL. Glaucoma model was established by unilateral episcleral venous cauterization. At day 26, RGCs were retrogradely labeled with 3% Fluorogold, which was injected into the superior colliculus. Four days after intratectal injection, sacrification and enucleation were performed. TUNEL kit was used to label apoptotic RGCs and then apoptotic indices for each eye were calculated. Statistical analysis was performed by post hoc Holm-Sidak test after one-way ANOVA. Intraocular pressure (IOP) measurements were analyzed using Wilcoxon signed rank test.
Statistically significant IOP reductions were found in BRT, G+BRT and G+MEL groups. Intraperitoneal melatonin injections caused a significant IOP reduction only under glaucomatous conditions. Compared to G group, G+BRT group had lower apoptotic indices ($p<0.05$) and higher 3% Fluorogold-labeled cell counts ($p<0.05$). However, no statistical significance was found between G and G+MEL groups considering apoptotic index value and 3% Fluorogold-labeled cell counts ($p<0.05$). Brimonidine tartrate had a significant IOP reducing effect when applied systemically, in contrast to the reports in the literature. In addition, brimonidine tartrate appears to be neuroprotective on RGCs against glaucomatous injury. On the other hand, our research showed no neuroprotective effect of melatonin on retinal ganglion cells in glaucomatous neurodegeneration process.

Keywords: glaucoma, neuroprotection, retinal ganglion cell, melatonin, brimonidine tartrate

Figure 1

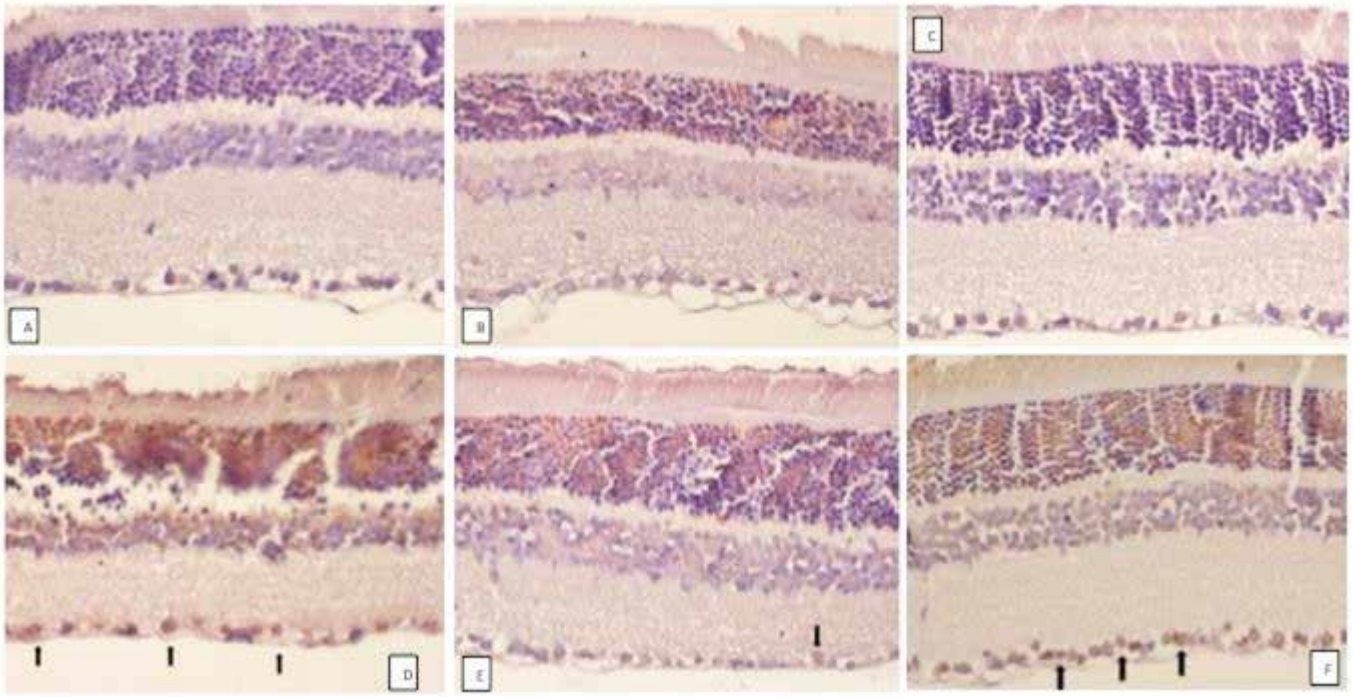

TUNEL-labeled apoptotic RGCs are seen in brown color (black arrows). More apoptotic cells are seen in groups G and G+MEL than in G+BRT group. Groups shown are as follows: A) C group, B) BRT group, C) MEL group, D) G group, E) G+BRT group, F) G+MEL group. 40X magnification.

Figure 2

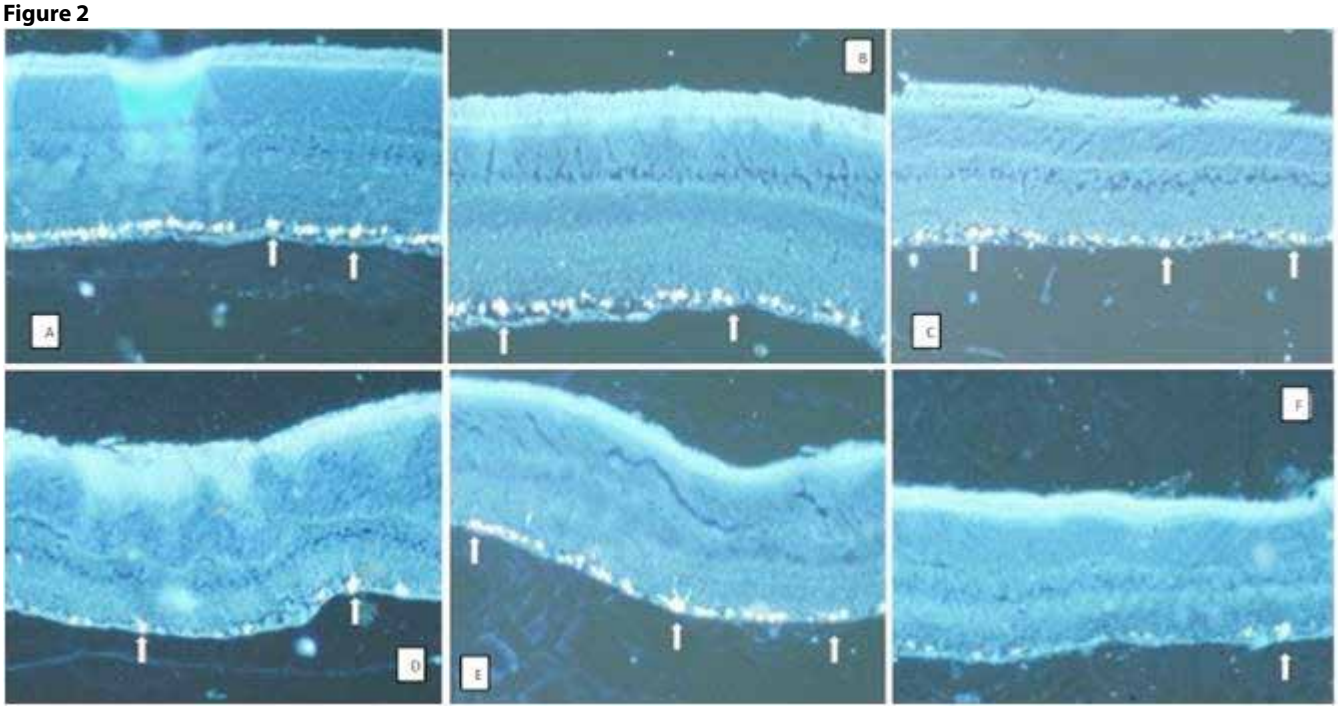

3% Fluorogold-labeled non-apoptotic cells are seen (white arrows). Nonapoptotic cells are very few in G and G+MEL groups when compared with the rest of the groups. Groups shown are as follows: A) C group, B) BRT group, C) MEL group, D) G group, E) G+BRT group F) G+MEL group. 20X magnification.

10.5505/2017ichc.PP-17 [Cellular aging and cell death]

Evaluation of the oxidant-antioxidant enyzmes and apoptosis of rats treated with vitamin E and selenium against monocrotalin induced hepatotoxicity

Gokhan Cuce[1], Halime Tuba Canbaz[1], Mehmet Enes Sozen[1], Fatma Hümeyra Yerlikaya[2], Serpil Kalkan[1]

[1]Necmettin Erbakan University, Meram Medical Faculty, Histology and Embryology, Konya, Turkey

[2]Necmettin Erbakan University, Meram Medical Faculty, Biochemistry, Konya, Turkey

Monocrotaline (MCT) is a plant-derived hepatotoxic pyrrolizidine alkaloid (PA), exposure to which is attributable to consumption of contaminated grains, herbal teas, and medicines. The present study was performed to investigate the protective antioxidant effects of selenium and vitamin E against liver damage induced by MCT.
Twenty-eight female Wistar–Albino rats were divided into four groups: a control group, an MCT-only group (300 mg/kg i.p.), an MCT + sodium selenite group (300 mg/kg i.p. + 0.25 mg/kg sodium selenite), and an MCT + vitamin E group (300 mg/kg i.p. + 200 mg/kg vitamin E). Sodium selenite and vitamin E were administered via gavage for 7 days.
The animals were then sacrificed, and liver tissues harvested into 10% formalin for tissue processing. After routine histological processing, paraffin blocks were prepared and sections 4-mm thick were cut. Anti-von Willebrand factor (vWF) immunohistochemistry, terminal deoxynucleotidyl transferase dUTP nick end-labeling (TUNEL), and hematoxylin and eosin (H&E) staining, were performed. Serum and liver tissue glutathione (GSH), catalase (CAT), and glutathione peroxidase (GPx) levels were measured.
Histopathological and TUNEL data showed a significant increase in liver damage in the MCT-only group compared to the controls. Histopathological and TUNEL staining indicated significant improvements in the MCT + vitamin E and MCT + selenium groups compared to the MCT-only group. MCT significantly reduced the serum levels of GSH and GPx and the liver level of GPx. Biochemical data indicated an significant improvement in serum GSH level in the MCT + vitamin E group compared to the MCT-only group.These observations suggest that vitamin E and selenium exert limited protective effects against the hepatotoxicity of MCT.

Keywords: Liver histopathology, TUNEL, vWF, CAT, GSH-GPx, monocrotalin

Figure 1

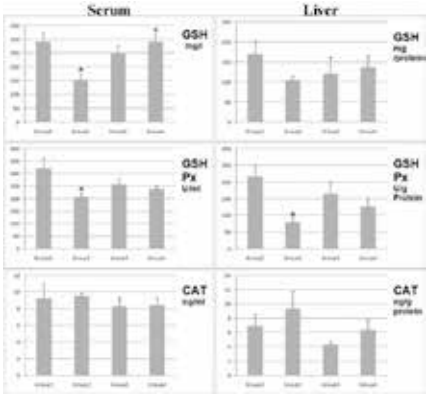

Representative serum and liver concentrations of GSH, GPx and CAT. Group 1, control; group 2, MCT only; group 3, MCT + Se; group 4, MCT + Vitamin E. *p < 0.05 vs. group 1; &p < 0.05 vs. group 2.

Figure 2

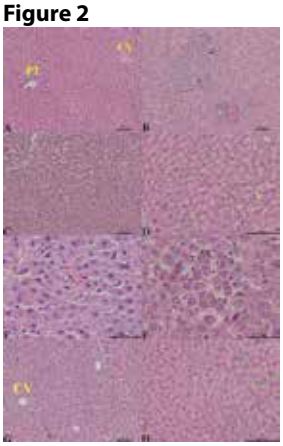

Representative H & E stained liver sections. A) Control group. B–F) MCT-only group. G) MCT + Vitamin E group. H) MCT + Se group. Black arrows indicate leukocyte infiltrations and necrosis. Green arrows indicate polyploidy. Yellow arrows indicate binucleate hepatocytes. Heterochromatin was observed in one

nucleus of the hepatocytes with two nuclei. Red arrows indicate pleomorphisms. Blue arrows indicate pyknotic nuclei and eosinophilic cytoplasm. PT, portal triad; CV, central vein.

Figure 3

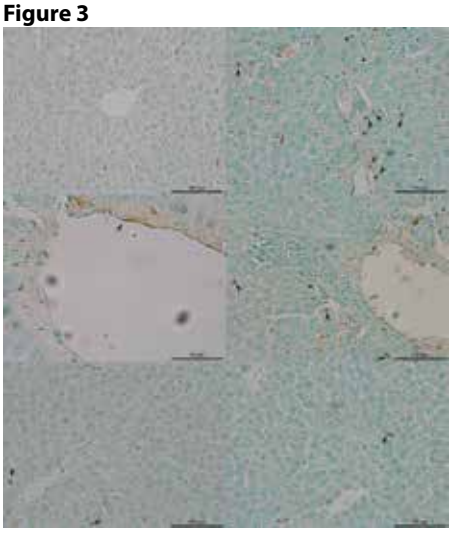

Representative TUNEL stained liver sections. A) Control group. B–D) MCT only group. E) MCT + Vitamin E group. F) MCT + Se group. Arrows indicate TUNEL-positive cells.

Figure 4

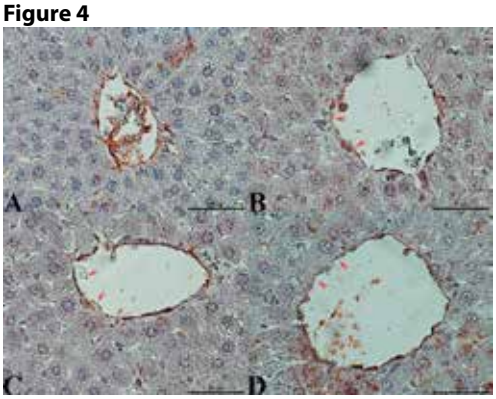

Representative anti-vWF antibody stained liver sections. A) Control group. B) MCT only group. C) MCT + Vitamin E group. D) MCT + Se group. Arrows indicate endothelial cells.

Table 1

	Control	MCT	MCT + Se	MCT + Vit E
TUNEL	1.28 ± 0.18	20. 14 ± 1.5a	6 ± 0.61 a,b	9 ± 0.81a,b
Histopathological score	0.28 ± 0.18	13.85 ± 0.55a	5.85 ± 0.63a,b	6.14 ± 0.26a,b

TUNEL and histopathology results, a:$p < 0.05$ compared to controls, b:$p < 0.05$ compared to MCT group.

10.5505/2017ichc.PP-18 [Cellular aging and cell death]

Investigation of the Ultrastructural Alterations of Oleuropein treated 3T3 and 5RP7 Cells

Hatice Mehtap Kutlu, Melike Çevik
Department of Biology, Faculty of Science, Anadolu University, Eskisehir, Turkey

Introduction and OBJECTIVES: Oleuropein is a phenolic compound that is derived from olive oil. It has many therapeutic properties such as anti-inflammatory and anti-bacterial and anticarcinogenic activities. Its anticarcinogenic effects has been shown in vitro in many cancer cell lines that didn't h-Ras transformed 5RP7 and 3T3 cells. This study aims at testing the effects of oleuropein on 5RP7 and 3T3 cells under transmission electron microscope.
MATERIALS-METHODS: The detected IC50 concentration of oleuropein for 24 hours by MTT colorimetric assay in our previous study was used for treatment of the test cells. Oleuropein exposed 5RP7 and 3T3 cells for 24 hours were fixed in glutaraldehyde overnight at +4 °C. Cells were post-fixed in osmium tetroxide, dehydrated in graded ethanol then embedded in EPON 812 epoxy. Sections obtained from the cells were stained in uranyl acetate and lead citrate then examined under transmission electron microscope.
RESULTS: IC50 concentration of oleuropein caused alterations in the cell ultrastructure such as ondulations and blebbings on cell's membrane. In addition, cell shrinkage, condensation and fragmentations of the nuclei, circular cells shape were alterations on oleuropein treated 3T3 and 5RP7 cells.
CONCLUSIONS: It has been found that oleuropein is highly cytotoxic in human lung adenocarcinoma cells A549 with an apoptosis promoting actions based on the ultrastructural changes detected under TEM. Consequently, oleuropein might be evaluated as an agent with potential for cancer treatment after developing a new therapeutic agent following further investigations.

Keywords: 5RP7, 3T3, Oleuropein, TEM, cancer, apoptosis.

10.5505/2017ichc.PP-19 [Cellular aging and cell death]

Investigation of Effects of Commercial Plant-Based Silymarin on Human Lung Adenocarcinoma Cells

Ece Kaya[1], Hatice Mehtap Kutlu[1], Gökhan Kuş[2]

[1]Department of Biology, Faculty of Science, Anadolu University, Eskisehir, Turkey

[2]Department of Health, Faculty of Open Education, Anadolu University, Eskisehir, Turkey

Introduction and OBJECTIVES: Silymarin is an agent found in Silybum marianum fruit and has many commercial products containing this agent as pure. The antioxidant biological effect of silymarin means ability to protect against free radicals and toxins production. Also in various in vivo studies it is shown that silymarin stops liver fibrosis and has a protective effect against formation of gallstones. In addition, has preventive and protective actions on toxin damage in the liver resulting from poisoning of various chemical compounds as well in acute and chronic hepatitis. The goal of this study is to investigate the potential of commercial silymarin to induce apoptosis in human lung adenocarcinoma cells (A549) including with morphological changes on A549 cells using confocal microscopy.
MATERIALS-METHODS: The cytotoxic effects of silymarin on A549 cells were determined by MTT colorimetric assay. Stock solution of commercial silymarin (in DMSO), was applied to A549 cells for 24 hours in different concentrations. The plates were read on ELISA reader at 570nm wavelength. For detecting the morphological changes, A549 cells were treated with the IC50 concentration of silymarin for 24 hours. After incubation, cells were stained with Alexa fluor-488 phalloidin and acridine orange and evaluated and photographed under confocal microscope.
RESULTS: Viability percentages of silymarin treated cells decreased in low drug concentrations and IC50 (33µM) value was calculated. This value altered the morphology of A549 cells causing disintegrated and deformed nuclei, cell skeleton and chromatin, holes on cytoskeleton as well as cell shrinkage.
CONCLUSIONS: On the basis on our results, it might be concluded that commercial silymarin showed high cytotoxicity on human lung adenocarcinoma cells and exerts a potential promising to be cytotoxic and anti-proliferative as well apoptosis triggering agent in cancer cells for design of pharmaceutical products but further deeper investigations are required.

Keywords: Silymarin, A549, Confocal microscopy.

10.5505/2017ichc.PP-20 [Cellular aging and cell death]

Investigation of the quercetin effect on apoptosis in diabetic nephropathy model rats induced by STZ

Eda Büyükçolpan Mirzataş, Matem Tunçdemir
Department of Medical Biology, Cerrahpasa Faculty of Medicine, Istanbul University, Fatih-Istanbul, Turkey.

INTRODUCTION&OBJECTIVES: Quercetin (3,5,7,3<,4<-pentahydroxyflavone) is a potent bioflavonoid widely distributed throughout vegetables and fruits (1). Quercetin has been reported to have many beneficial effects on human health, including cardiovascular protection, renoprotective, anticancer activity, anti-ulcer effects, anti-allergy activity, anti-inflammatory and anti-apoptotic effects (1,2,3). In this study, we investigated the renoprotective and anti-apoptotic effects of quercetin by evaluating the expression of apoptosis-regulatory genes that contribute to the kidney damage caused by diabetes in STZ-diabetic nephropathy model in rats.
MATERIALS&METHODS: 32 Wistar albino rats were divided into 4 groups of 8 each; Control, STZ-diabetic group (50 mg/kg, ip., single dose), STZ-diabetic group (50 mg/kg, ip. single dose)+Quercetin administered group (20 mg/kg/day, diluted in 4% ethanol, 30 days), and finally the fourth as Quercetin treated control group (20 mg / kg / day). The values of fasting blood glucose, body weight and urine microalbuminuria measured on the 1st, 15th and 30th days of the study. The kidneys of the animals removed by surgery under anesthesia on 31st day of the study. Immunohistochemistry was performed for morphological evaluation of the renal tissue sections by PAS staining and using bax, bcl-2, caspase-3 antibodies and TUNEL method applied.
RESULTS: At the end of study, blood glucose ($p<0.05$) and microalbuminuria ($p<0.001$) levels were significantly decreased in quercetin treated diabetic group compared to the untreated diabetic group. In the renal tissues of quercetin treated diabetic group, specific morphological changes was observed as the characteristic of diabetes. Immunostaining of antiapoptotic bcl-2, proapoptotic bax and caspase-3 was decreased compared to the untreated diabetic group. Apoptotic cells especially increased in the kidney tubuli of untreated diabetic group and on the contrary, a significant decrease was observed in the group that received a quercetin treatment.
CONCLUSIONS: Overall our results show that treatments of quercetin are effective and efficient in preventing renal tissue injury and reducing the expression of apoptosis releated proteins in experimental diabetic nephropathy.

REFERENCES:
1-Anjaneyulu M, et al. Clin Exp. Pharm. Physiol. 2004;31:244-248.
2-Gomes IB, et al. Lipids Health Dis. 2014;13:184-193.
3-Lu XL, et al. Biomed Pharmacother. 2017;85:658-671.

The present work was supported by the Research Fund of Istanbul University. Project No.52174

Keywords: STZ-diabetes, Kidney, Quercetin, Apoptosis

10.5505/2017ichc.PP-21 [Cellular aging and cell death]

Regulation of autophagy by p97/Valosin containing protein in preeclamptic human placenta

Sevil Cayli[1], Cansu Sahin[1], A. Zeki Ozsoy[2], Tuba Ozdemir Sanci[1], Seda Ocakli[3]

[1]Department of Histology and Embryology, Ankara Yildirim Beyazit University, Ankara, Turkey

[2]Department of Obstetrics And Gynecology, Gaziosmanpasa University, Tokat, Turkey

[3]Department of Histology and Embryology, Gaziosmanpasa University, Tokat, Turkey

INTRODUCTION: Autophagy is necessary to maintain homeostasis during cellular growth, development, and differentiation, and to protect cells from nutritional deficiencies or factors. Recently, it has been reported that autophagy increases in placenta-related obstetrical diseases such as preeclampsia and intrauterine growth retardation, although the mechanisms are stil unclear. Inparticular, regulation of autophagy by ubiquitin proteasome pathway (UPP) proteins, p97/Valosin containing protein and Small-VCP interacting protein (SVIP) has not been studied in preeclampsia. The objective of this study is to investigate the expression of UPP (p97/VCP and SVIP) and autophagic (p62 and LC3B) proteins in the normal and preeclamptic human placentas and to explore the regulatory mechanism of these proteins in autophagic pathway.
MATERIAL-METHODS: Placentas were collected after cesarean delivery from women with a normal term pregnancy (n =20) as well as from women with severe preeclampsia (n = 10). After collection of the samples from the central mid-portion between the basal plate and chorionic membrane, the placental tissues were snap-frozen in liquid nitrogen and stored at -80°C for Western blotting and embedded in paraffin for immunohistochemistry.
RESULTS: Compared with the placentas from normal pregnancies, the expression of p97/VCP was significantly reduced, however SVIP was significantly increased in the placentas from severe preeclampsia. Additionally, among autophagic proteins LC3-II and p62 expressions were significantly increased according to Western blotting and immunohistochemistry. Cytoplasmic immunostaining of p97/VCP and SVIP was observed in the cytotrophoblasts, syncytiotrophoblast and Hofbauer cells. Some of the stromal cells and endothelium were also immunpositive for p97/VCP. p62 and LC3B immunostaining were observed in syncytiotrophoblast and Hofbauer cells.
CONCLUSION: Our data suggests that increased expression of p97/VCP and SVIP in preeclampsia might be related to increased activation of autophagy and pathophysiology of preeclampsia.Therefore, our study highlights an important potential relationship between UPS and autophagic proteins in preeclampsia.

Keywords: Preeclampsia, p97/VCP, SVIP, autophagy, human placenta

10.5505/2017ichc.PP-22 [Cellular aging and cell death]

Morphological study of chondrocyte cell death in patients affected by chondrocalcinosis

Davide Curzi[1], Sara Salucci[1], Debora Burini[1], Francesco Fardetti[2], Alessandro Beccarini[2], Elisabetta Falcieri[1], Pietro Gobbi[1]

[1]Department of Biomolecular Sciences, University of Urbino Carlo Bo, Urbino, Italy

[2]Private hospital "Porta Sole", 06122, Perugia, Italy

Introduction & OBJECTIVES: chondrocalcinosis is a degenerative knee disease which usually characterizes the oldest population, where the cartilage degeneration is associated to crystal accumulations of calcium pyrophosphate dihydrate in the degenerated regions [1, 2]. In this work, the morphological features of cartilages and, in particular, of their chondrocytes, have been investigated in patients affected by chondrocalcinosis.
Materials & METHODS: cartilage specimens from femoral condyles have been investigated using histochemical analysis, microanalysis, transmission and scanning electron microscopy.
RESULTS: the morphological observations revealed a general impairment of the upper cartilaginous layers in the anatomical area particularly subjected to mechanical loading. In these sites, the cartilage middle layer displayed numerous empty lacunae and, where chondrocytes were present, they displayed necrotic features. However, a different type of apoptotic cell death characterized some of these chondrocytes, which displayed chromatin margination, an outer nuclear membrane detachment, cytoplasm vacuolization, a translocation of nuclear pores and a diffuse presence of autophagic vacuoles (Fig.1). This kind of cell death just observed in other diseases was called chondroptosis [3].
CONCLUSIONS: the study of chondrocyte behaviour and death appears to be essential to better understand cartilage disorders and possible regenerative treatment. The presence of chondroptosis in chondrocalcinosis could open a new research field in the study of this pathology and different pharmacological approaches.
References
[1] Abhishek et al. (2014) Epidemiology of calcium pyrophosphate crystal arthritis and basic calcium phosphate crystal arthropathy. Rheum Dis Clin North Am. 40(2):177-91.
[2] Ryu et al. (2014) The prevalence of and factors related to calcium pyrophosphate dihydrate crystal deposition in the knee joint. Osteoarthritis Cartilage. 22(7):975-9.
[3] Battistelli et al. (2014) Cell death in human articular chondrocyte: a morpho-functional study in micromass model. Apoptosis. 19(10):1471–83.

Keywords: Chondrocalcinosis, Chondroptosis, Necrosis

Figure

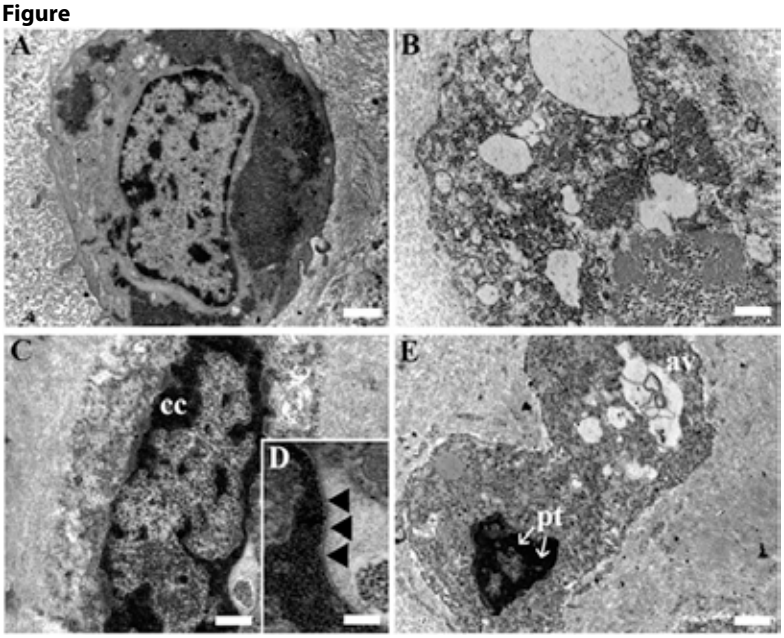

Figure 1. Transmission electron microscopy micrographs of healthy (A),necrotic (B) and chondroptotic chondrocytes (C, D, E). The latters revealed chromatin condensation (cc), nuclear membrane detachment (arrow-head), nuclear pores translation (pt) and, in the late stages, autophagic vacuoles (av). Bars: A, B, C: 0.6 µm; D: 0.3 µm; E: 1.5 µm.

10.5505/2017ichc.PP-23 [Cellular aging and cell death]

Autophagy modulation in preserving skeletal muscle integrity

Francesco Maria Giordano, Debora Burini, Sabrina Burattini, Barbara Canonico, Elisabetta Falcieri, Stefano Papa, Michela Battistelli, Sara Salucci
Department of Biomolecular Sciences, University of Urbino Carlo Bo, Urbino, Italy

Introduction & OBJECTIVES: autophagy represents a physiological mechanism responsible for cell homeostasis and its deregulation is involved in several conditions related to muscle mass loss such as aging, inflammatory diseases and disuse [1]. In our previous work, double membrane vesicles, suggestive of autophagy, appeared after chemotherapeutic treatments in myotubes [2]. Here, C2C12 skeletal muscle cells have been exposed to Etoposide (Eto), a cell-death and oxidative stress inducer, and to protein supplementation or deprivation before the trigger, to evaluate if these pre-treatments are able to modulate autophagy.
Materials & METHODS: Eto effect, as well as protein supplementation or deprivation before the trigger, have been evaluated by means of cytofluorimetric, morphological and molecular analyses in myotubes.
RESULTS: our study reveals that Eto treatment induces lysosomal compartment and endoplasmic reticulum dam-age, causing a peculiar accumulation of autophagic vacuoles and a dephosphorylation of Akt. Both pre-treatments, in particular the protein supplementation, are able to prevent myotubes damage and to reactivate the protein synthesis pathway.
CONCLUSIONS: these findings suggest that, in a skeletal muscle model in vitro exposed to a chemotherapeutic agent, a diet rich in protein could prevent the abnormal autophagic activation and avoid the resulting atrophic mechanism [3].
References
[1] Sandri et al. (2013) Misregulation of autophagy and protein degradation systems in myopathies and muscular dystrophies. J Cell Sci. 126, 5325-33.
[2] Salucci et al. (2013) The peculiar apoptotic behavior of skeletal muscle cells. Histol Histopathol. 28, 1073-87.
[3] Fanzani et al. (2011) Cisplatin triggers atrophy of skeletal C2C12 myotubes via impairment of Akt signalling pathway and subsequent increment activity of proteasome and autophagy systems. Toxicol Appl Pharmacol. 250, 312-21.

Keywords: C2C12 cells, etoposide, autophagy

Figure

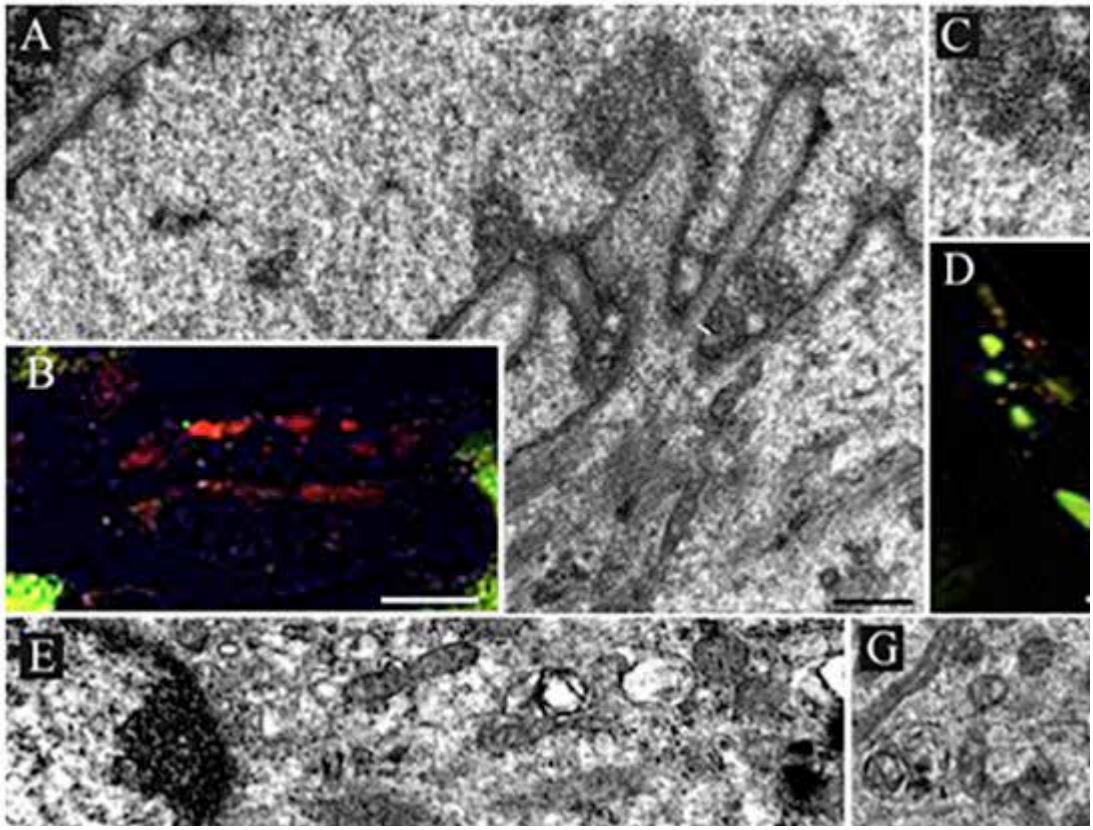

TEM (A, C, E, G) and acridine orange fluorescence images (B, D, F, H) of control condition (A, B), cells ex-posed to Eto (C, D) and those pre-treated with protein deprivation (E, F) or supplementation (G, H) before Eto exposure. Bars: 0.5µm for A, C, E, G; 20µm for B, D, F, H.

10.5505/2017ichc.PP-24 [Cellular aging and cell death]

Expression of ubiquitin in gestational diabetic and preeclamptic human placenta

Sevil Cayli[1], A. Zeki Ozsoy[2], Gülben Akcan[1], Cansu Sahin[1], Seyma Kipel[1], Seda Ocakli[3]

[1]Deparment of Histology and Embryology, Ankara Yıldırım Beyazıt University, Ankara, Turkey

[2]Department of Obstetrics and Gynecology, Gaziosmanpaşa University, Tokat, Turkey

[3]Deparment of Histology and Embryology, Gaziosmanpaşa University, Tokat, Turkey

INTRODUCTION: Gestational diabetes mellitus, the most common metabolic complication of pregnancy, is influenced by the placenta, and its prevalence directly increases with obesity. The ubiquitin proteasomal system (UPS) is the main regulator of both the functional and dysfunctional protein pool of mammalian cells. Thus, we believe that an impact on this system may also affect cellular functionality of human placenta. The goal of current study was to examine the expression and localization of ubiquitin and ubiqutinlated proteins in normal and pathologic placentas.
MATERIAL-METHODS: Placentas were collected after cesarean delivery from women with a normal term pregnancy (n =10) as well as from women with severe preeclampsia (n = 8) and gestational diabet (n = 4). After collection of the samples from the central mid-portion between the basal plate and chorionic membrane, the placental tissues were snap-frozen in liquid nitrogen and stored at -800C for Western blotting and embedded in paraffin for immunohistochemistry. Colocalization studies were performed by immunofluorescence.
RESULTS: Compared with the placentas from normal pregnancies, ubiquitin expression was significantly increased in preaclamptic and diabetic placentas. Ubiquitin and ubiquitinylated protein aggregates were observed in syncytiotrophoblast and Hofbauer cells (placental macrophages) in control and pathologic placentas. Colocalization studies showed that CD68 positive placental macrophages were also expressed higher level of ubiquitin in diabetic placentas.
CONCLUSION: Our data indicates that higher expression of ubiquitin in pathological placentas is an important sign for the functional studies in order to understand mechanism of these pathologies.

Keywords: Gestational diabet, human placenta, ubiquitin, immunohistochemistry, Western blotting

10.5505/2017ichc.PP-25 [Cellular aging and cell death]

Effects of morinda citrifolia (noni) juice on apoptosis and expression of neutrophil gelatinase-associated lipocalin in the kidney of rats exposed to 3-methyl-4-nitrophenol

Funda Yigit[1], Elif Ilkay Ikitimur Armutak[1], Osman Behzat Burak Esener[1], Ebru Gurel Gurevin[2], Muzaffer Basak Ulkay[1], Abit Aktas[1], Hasan Hakan Bozkurt[1], Suzan Daglioglu[1]

[1]Faculty of Veterinary Medicine, Department of Histology and Embryology, Istanbul University, Istanbul,Turkey

[2]Faculty of Science, Department of Biology, Istanbul University, Istanbul,Turkey

AIM: Morinda citrifolia (Noni), natural plant product, has been shown to have anti-apoptotic, anti-inflammatory and antioxidant effects. The environmental pollutant 3-methyl-4-nitrophenol (4-nitro-m-cresol, PNMC) is a component of diesel exhaust particles and a metabolite of the insecticide fenitrothion. The objective of this study was to investigate the effect of Noni juice on the expression of neutrophil gelatinase-associated lipocalin (NGAL) and apoptosis in the kidney of rats exposed to PNMC.
MATERIALS-METHODS: In the study, fifty-six adult male rats were allocated into eight groups. Control group received phosphate-buffered saline+0.05% Tween-80 (vehicle). First experimental group received only Noni and other experimental groups received 1, 10 and 100 mg/kg PNMC (S.C) alone or in combination with Noni (2 ml per rat by gavage) respectively for 5 days. At the end of the experimental period rats were sacrificed in ethics. The kidney tissues were removed and fixed in % 10 neutral formalin solution. Then tissue specimens were embedded in paraffin and sectioned (thickness, 5µm). The sections were immunohistochemically stained using neutrophil gelatinase-associated lipocalin (NGAL) antibody for the assessment of acute kidney injury. Apoptosis was assessed by immunohistochemistry for anti active caspase-3 antibody and terminal deoxynucleotidyl transferase dUTP nick end labeling (TUNEL) method in paraffin sections. IHC staining of NGAL and active caspase-3 were quantified using a histological scoring system (H-Score).
RESULTS: The H-Score of NGAL and active caspase 3 were significantly higher in all doses of PNMC alone groups than those of control and Noni alone recevied group ($P<0.001$). NGAL values in 1 and10 mg/kg PNMC + Noni groups and active caspase 3 values in 1, 10 and 100 mg/kg PNMC + Noni groups were decreased close to control group ($P<0.001$). The apoptotic index was significantly increased in PNMC alone recevied group ($P<0.001$) in comparison with all other groups. The apoptotic index was decreased close to control level when PNMC was combined with Noni ($P<0.001$).
CONCLUSION: In conclusion, in the present immunohistochemical study, we determined that Noni juice markedly alleviated the PNMC-induced renal injury and apoptosis in the kidney of rats.

Keywords: Noni, 3-methyl-4-nitrophenol, kidney, apoptosis, NGAL

10.5505/2017ichc.PP-26 [Cellular aging and cell death]

Effect of Selenium on Electromagnetic Field (Wi-Fi 2.4 GHz)-induced apoptosis in HEK293

Nural Pastacı Özsobacı[1], Matem Tunçdemir[2], Derviş Özçelik[1]

[1]Department of Biophysics, Cerrahpasa Faculty of Medicine, Istanbul University,Turkey

[2]Department of Medical Biology, Cerrahpasa Faculty of Medicine, Istanbul University, Turkey

INTRODUCTION & OBJECTIVES: There is a widespread use of 2.4 GHz electromagnetic radiation emitting devices especially in education. Recent studies show the adverse effects of electromagnetic fields (EMF) on tissues. It was reported that EMF induced apoptosis through reactive oxygen species(1,2). Selenium (Se) is trace elements for all organisms and it shows antioxidant properties by inhibiting oxidative damage being within the structure of and glutathione peroxidase (GSH-Px). Accordingly, some studies note that changes in the homeostasis of selenium effect apoptosis(3). Thus, the aim of this study is to investigate the effects of different doses of selenium on 2.4 GHz frequency EMF exposed human embryonic kidney cells (HEK293) by means of alterations in apoptosis and apoptotic proteins.
MATERIALS & METHODS: Our study was carried out with four different groups as, control, 2.4 GHz, 100nM Se + 2.4 GHz, 200nM Se + 2.4 GHz groups. 2.4 GHz groups were exposed to 2.4 GHz EMF for 1h and, the cells were incubated with a medium that prepared by adding 100-200 nM sodium selenite for 48h before EMF exposure. Apoptotic cells were detected by TUNEL method, caspase-3 and bcl-2 detection was performed with Streptavidin-biotin-peroxidase method by using active anti-caspase-3 and bcl-2 antibodies.
RESULTS: In the our study, EMF application significantly increased apoptotic cells and caspase-3 in HEK293 cells ($p<0,001$; $p<0,05$,respectively)(Fig1/B;Fig 3/B), but it significantly decreased bcl-2 ($p<0.001$) (Fig 2/B) according to control group. Two different doses of selenium application (100 nM;200 nM) before EMF significantly decreased apoptotic cells and caspase-3 ($p<0.001$; $p<0.001$)(Fig1/C,B; Fig 3/C,D), and also increased bcl-2 ($p<0.001$, $p<0.01$) (Fig 2/C,D) with respect to 2.4 GHz group.
CONCLUSIONS: Our findings show that EMF-caused apoptotic activation in HEK293 cells by suppressing the expression of bcl-2 and increasing caspase-3. Beside that, selenium supplementation prevented EMF-induced apoptosis by increasing the expression of bcl-2 and suppressing caspase-3. These findings suggest that selenium is a useful agent for the prevention of apoptosis caused by EMF exposure.
REFERENCES:
1.Çelik Ö, et al.J Chem Neuroanat.2016;75(Pt B):134-139
2.Kahya MC, et al.Biol Trace Elem Res. 2014;160(2):285-293.
3.Zeng H.Molecules.2009;23;14(3):1263-1278.

The present work was supported by the Research Fund of Istanbul University. Project No.51182

Keywords: HEK293, Selenium, EMF, Apoptosis

Figure 1: TUNEL assay of apoptotic HEK 293 cells of different groups.

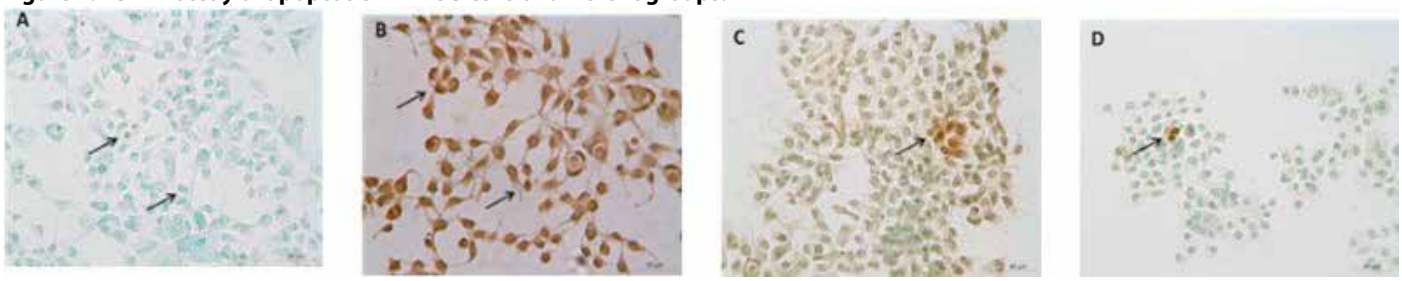

(A) Control group, (B) 2.4 GHz group, (C) 100 nM Se+2.4 GHz group, (D) 200 nM Se+2.4 GHz group. Contrast stain: Methyl Green (Bar: 40 µm). TUNEL positive cells (<)

Figure 2: Bcl-2 immunohistochemical staining of HEK 293 cells.

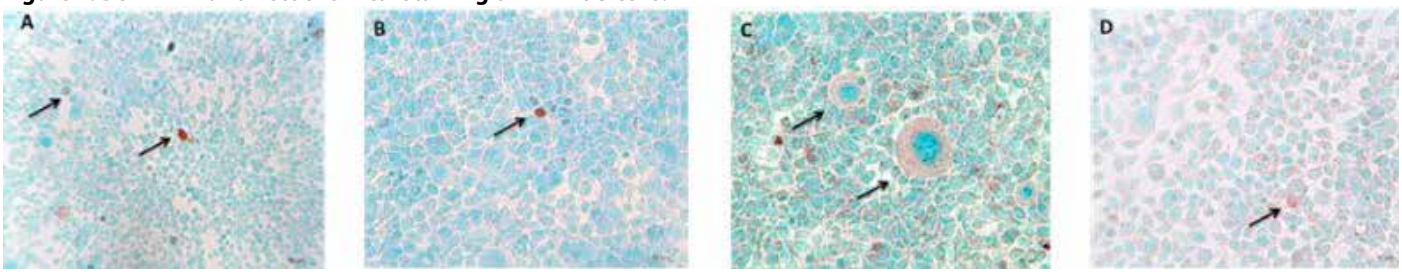

(A) Control group, (B) 2.4 GHz group, (C) 100 nM Se+2.4 GHz group, (D) 200 nM Se+2.4 GHz group. Contrast stain: Methyl Green (Bar: 40 µm). Bcl-2 Immunopositive cells (<).

Figure 3: Active Caspase-3 immunohistochemical staining of HEK293 cell.

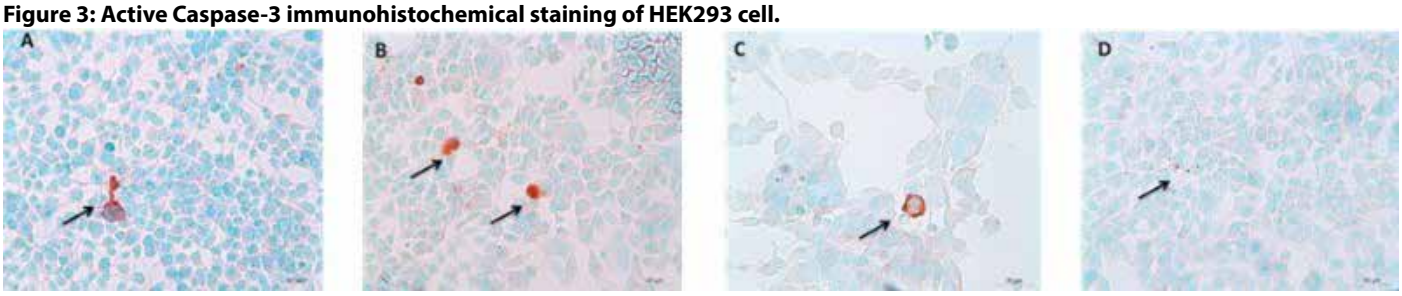

(A) Control group, (B) 2.4 GHz group, (C) 100 nM Se+2.4 GHz group, (D) 200 nM Se+2.4 GHz group. Contrast stain: Methyl Green (Bar: 40 µm). Active Caspase-3 Immunopositive cells(<).

10.5505/2017ichc.PP-27 [Cellular aging and cell death]

Investigation of Possible Protective Effects of Alpha Lipoic Acid on Ischemia-Reperfusion Induced Kidney Tissue

Burcu Gültekin[1], Seçkin Tuncer[2], Seda Çetinkaya[3], Aydan Özgörgülü[1], Nizamettin Dalkılıç[2]

[1]Department of Histology and Embryology, Necmettin Erbakan University, Konya, Turkey

[2]Department of Biophysics, Necmettin Erbakan University, Konya, Turkey

[3]Department of Histology and Embryology, Karatay University, Konya, Turkey

AIM: In this study, we investigated the possible positive effects of alpha lipoic acid on renal damage caused by infrarenal ischemia reperfusion (I/R) in rats by immunohistochemical methods.
METHODS: In this study male Sprague Dawley rats weighing 200- 250 g. (2,5-3 month) were used. The rats were randomly divided into four groups each having 10 animals. Under light anesthesia in IR group blood delivery is occluded from the infrarenal area of the abdominal aorta by using a vascular clamp, after 30 minutes the clamp was removed and blood delivery was allowed for 2 hours. In SHAM group, only clamp was not placed. I/R + ALA group alpha lipoic acid was injected (100mg/kg, i.p) for 3 days before the operation, then on the operation day the same procedure with IR group was performed. Animals in ALA group were received alpha lipoic acid (100mg/kg, i.p) every day for 3 days. The day after the last injection the animals were sacrificed and the tissues were collected. After routine histological follow-up techniques tissues were cut into 5 µm-thick sections. These sections were stained with hematoxylin-eosin for histological assessment. Mouse monoclonal Bcl-2 (1:100 dilution) antibody and Bax (1:100 dilution) antibody is used for immune evaluation of kidney tissue sections with streptavidin-biotin-peroxidase method.
RESULTS: Histopathological evaluation revealed that the renal tissues of the SHAM group had normal structure with no pathological changes. In the IR group, tubular lümen dilation, vacuolization, degeneration, and mononuclear cell infiltration were higher than those of the SHAM group. However no differences were observed between the SHAM and ALA group, in IR+ALA group tubular degeneration is continued but decrease in mononuclear cell infiltration and expansion of Bowmann's capsule cavity is determined.
Immunostaining evaluation showed that, the Bcl-2 expression was increased in renal tubules of SHAM and ALA group compared with IR and IR+ALA group. The Bax expression were found to be increased in SHAM and ALA as compared with IR and IR+ALA group.
CONCLUSION: Histopathological and immunohistochemical findings revealed that abdominal ischemia-reperfusion caused significant damage, but alpha lipoic has protective effects against ischemia-reperfusion related renal tissue injury.

Keywords: Ischemia, reperfusion,alpha lipoic acid,kidney

10.5505/2017ichc.PP-28 [Cellular aging and cell death]

Comparison of the healing effects of 3 different antioxidants on Cisplatin-induced pulmonary toxicity: A immunohistochemical and stereological study

Tugba Bal[1], Nurhan Akaras[1], Serdar Yigit[2], Hilal Atilay[1], Ozlem Ozgul Abuc[1], Elif Polat[1]

[1]Department of Histology and Embryology, Ataturk University, Erzurum, Turkey

[2]Department of Histology and Embryology, Kafkas University, Kars, Turkey

Introduction & OBJECTIVES: Chemotherapy, which has a great importane to cancer, is a treatment method. Many agents have been developed for use in chemotherapy treatment. Cisplatin (cis-diamminedichloroplatinum<, CDDP), one of these agents, has many side effects despite of therapeutic. Previous studies reported that cisplatin would toxic effects on many systems including pulmonary system. Many active ingredients are used to reduce the effect of toxic substances and to protect cells. In the present study we focused on Curcumin (CMN), Cape (Caffeic acid phenethyl ester) and Amifostine (ethiole) antioxidants. Aim of the this study was to compare the protective effects of Curcumin, Cape and Amifostine on Cisplatin-induced pulmonary toxicity via histopathological, immunohistochemical and stereological methods.
Materials & METHODS: 200 -300 g weighing, 30 Sprague-Dawley male rats were used in the experiment. The rats were randomly divided into five groups of six numbers as follows: (1) Control group, (2) Cisplatin group (5mg/kg-ip), (3) Cisplatin + CAPE (10 µmol/kg-ip), (4) Cisplatin + Amifostine (400 mg/kg-ip) and (5) Cisplatin + Curcumin (10 mg/kg-gavage). At the end of the experiment lung tissue samples were taken from all rats. Sections of 4 to 5µm thickness taken from each block were stained with Hematoxylin-eosin (H-E) and Caspase-3 Ab. All sections were stereologically evaluated using random sampling and fractionator method and immunopositive alveoler wall cell density was calculated. Statistical significance of the results (SPSS-19, one-wayANOVA) was evaluated according to $p < 0.05$.
RESULTS: In the cisplatin-treated group, capillary dilation, septal thickness, inflammatory cell infiltration and erythrocytes extravagation were observed when compared to the other groups. After cisplatin injection, it was significantly detected to inhibit the side effects caused by cisplatin in the Curcumin, Cape and Amifostine treated groups. These findings were supported immunohistochemical and stereological analysis as well. Although immunopositivity was significantly lower in Cisplatin + Amifostine and Cape groups than in the cisplatin group, no significant difference was found in the Curcumin group. Additionally, positive cell density in the Amifostine group was lower than in the Cape group.
CONCLUSIONS: Our study revealed clearly that cisplatin-induced pulmonary damage was significantly reduced by Amifostine and Cape antioxidants.

Keywords: Pulmonary toxicity, Cisplatin, Antioxidants, Caspase 3

10.5505/2017ichc.PP-29 [Cellular aging and cell death]

Effect of B-1,3-(D)-Glucan on Bortezomib-Induced Testis Damage in Rats. Unexpected Findings!

Nurhan Akaras[1], Tugba Bal[1], Hilal Atilay[1], Serdar Yigit[2], Ozlem Ozgul Abuc[1], Jale Selli[1]

[1]Department of Histology and Embryology, Ataturk University, Erzurum, Turkey

[2]Department of Histology and Embryology, Kafkas University, Kars, Turkey

Introduction & OBJECTIVES: Bortezomib which is effective treatment in multiple myeloma is an inhibitor of 26S proteasome. This inhibition makes the accumulation of poly-ubiquitinated proteins involved in a multitude of signaling pathways, therefore oxidative stres occurs. In this study, we aimed to determine protective role of beta glucan (BG) on testicular tissue damaged by bortezomib via oxidative stress.
Materials & METHODS: This study includes 36 male Sprague dawley rats divided into 6 groups. The groups are control group (group 1), BG (beta glucan) group (group 2), bortezomib 48h (group 3), bortezomib 48h+BG group (group 4), bortezomib 72h group (group 5) and bortezomib 72h+ BG group (group 6). At the end of the experiment, we obtained the testicular tissue of rats. Differences between the study groups, with regard to changes in the activities of antioxidant enzymes and the concentrations of conjugated dienes, were evaluated after this step. We measured the level of LPO, GSH, CAT, SOD and tissue samples were also evaluated as histopathological and immunohistochemical (Nf-kB).
RESULTS: The most conspicuous finding was increasing of LPO level in all experimental groups when compared with control group. This rising was highest at Group-4 and the second highest increasing was found at Group-2. Correspondingly, GSH and SOD levels, antioxidant agents, were found as lowest in Group-4 and Group-2. CAT levels were seen as decreased in every experimental groups. In histological examination we observed changes in the structures of seminiferous tubules, degradation in connective tissue and epithelial tissue both in the bortezomib and the beta glucan-induced groups. Varying degrees of nuclear and cytoplasmic Nf-kB immunpositivity was observed in some Sertoli cells and in basal region cells in all groups. The immunnegativity was observed in control group's spermatid cells but the most remarkable finding was immunpositivity in other groups' spermatid cells.
CONCLUSION: Obtained findings showed that beta glucan lead to oxidative stress in the testes as well as bortezomib. Unlike the literature, it has been observed that BG does not have protective effects on testes tissue.

Keywords: Bortezomib, Beta Glucan, Oxidative Stress, Testes, Nf-kB

10.5505/2017ichc.PP-30 [Cellular aging and cell death]

Investigation of the effect of aging on the collagens of the temporomandibular joint

Mehmet Demir[1], Mehmet Kemal Tümer[2], Mustafa Cicek[1], Atilla Yoldas[1]

[1]Department of Anatomy, Sutcu Imam University, Kahramanmaras, Turkey

[2]Department of Oral and Maxillofacial Surgery, Gaziosmanpasa University, Tokat, Turkey

Introduction & OBJECTIVES: Temporomandibular joint (TMJ) disorders are joint dysfunctions that arise in consequence of intra-articular or extra-articular pathologies. The bony surface of TMJ is covered by a thin fibrous capsule. The extacellular matrix of the fibrocartilaginous disk is generally comprised of collagens type 1 and type 2. Collagen, hyaluronic acid and proteoglycans, which are found in the matrix consisting of fibers and intercellular material, are large molecules. In this study, the effects of aging on the histopathological changes of TMJ and the existence and age related alterations of immunochemical expressions of type I collagen and MMP-2 proteins was aimed to be displayed.
Materials & METHODS: To this study, 14 Balb/C type white mice (50-80g) were included. Mice were divided into two groups of 7 subjects each. Groups were organized as Group I two month old young mice group (n=7) and Group II 18 month old mice group (n=7). Following the routine histological follow-ups tissue samples were embedded to paraffin blocks. Of the paraffin embedded tissues 4-5 µm thick sections were taken and immunohistochemical stainings of hematoxylin-eosin, type-1 collagen and MMP-2 were performed.
RESULTS: Collagen bundles showed sagittal and oblique localizations in the young mice, which were comprised of compact collagen bundle layers positioned alternately. While collagen bundle fragmentation was observed in the disks of old mice, some disk regions showed ruptures. In the young mice, the joint surface was unimpaired with a smooth outlining and visible blood vessels, on the other hand, in the old mice a decrease in blood vessels, structural impairments and dilatation in arterioles and venules were detected. In the TMJ tissues of the young mice type I collagen and MMP-2 expressions were increased, while they were decreased in old mice. In the MMP-2 H-score evaluation young mice showed significant increase compared to the old mice.
CONCLUSIONS: Occurrence of degenerations in the collagen structure of TMJ and decimation in the matrix metalloproteases were observed with age.

Keywords: Temporomandibular Joint, Collagens, Aging

10.5505/2017ichc.PP-31 [Cellular aging and cell death]

Investigation of the effect of aging on the aquaporins in the temporomandibular joint

Mehmet Kemal Tümer[1], Mehmet Demir[2], Mustafa Cicek[2], Atilla Yoldas[2]

[1]Department of Oral and Maxillofacial Surgery, Dentistry Faculty, Gaziosmanpasa University, Tokat, Turkey

[2]Department of Anatomy, Medical Faculty, Sütcü Imam University, Kahramanmaras, Turkey

Introduction & OBJECTIVES: Temporomandibular joint (TMJ), the most complicated joint of the human body. TMJ disorders are joint dysfunctions that occur due to intra-articular or extra-articular pathologies. Among the major effects of aging on the organism are alterations within the oral cavity and the surrounding tissues hold an important place. The structural alterations that occur due to aging also effect the TMJ over time and causes some structural and functional changes. We aimed to demonstrate the effect of aging on the aquaporins in the temporomandibular joint.
Materials & METHODS: In this study, 14 Balb/C White (albino) mice (50-80g) were used. Animals were divided into two groups of 7 subjects each. Groups were organized as Group I two month old young mice group (n=7) and Group II 18 month old mice group (n=7). Tissue samples were embedded to paraffin following the routine histological follow-ups. Of the paraffin embedded tissues 4-5 µm thick sections were taken and immunohistochemically stained with hematoxylin-eosin, aquaporin-1 (AQP-1) and aquaporin-3 (AQP-3).
RESULTS: While the joint surface was unimpaired with a smooth outlining and visible blood vessels in the young mice, in the old mice a decrease in blood vessels, structural impairments and dilatation in arterioles and venules were detected. Furthermore, in the TMJ tissues of the young mice a significant increase in the AQP1 and AQP-3 immune reactivity (+++) was observed while in the TMJ tissues of the old mice the AQP-1 immune reactivity was low (+)(p=0.001) and the AQP-3 immune reactivity was in intermediate levels (++)(p=0.001). In the H-score evaluation, cellular AQP-1 and AQP-3 immune reactivity was found significantly higher in the young mice than in the old mice (p=0.002).
CONCLUSIONS: We have observed that an increase in TMJ degeneration, a decrease in the extracellular-intracellular material exchange, and negative alterations in the number and structure of the water channels that are localized on the cell membrane occur with age.

Keywords: Temporomandibular Joint, Aquaporin, Aging

10.5505/2017ichc.PP-32 [Cellular aging and cell death]

The Effect of Zinc Oxide Nanoparticles and Cyclophosphamide on Testicular Histology, Apoptosis and Oxidane-Antioxidane Levels of Rats

Nureddin Atasoy[1], Gökhan Cüce[1], Tevfik Balcı[2], Mehmet Aköz[3], Halime Tuba Canbaz[1], Serpil Kalkan[1]

[1]department of histology and embryology, necmettin erbakan university, konya, turkey

[2]department of clinical biochemistry, osmaniye public health laboratory, osmaniye, turkey

[3]department of biochemistry, necmettin erbakan university, konya, turkey

Cyclophosphamide (CP) is a chemotherapeutic drug used in the childhood and adult malignancies. Zinc oxide (ZnO) is a multifunctional inorganic material and ZnO nanoparticles are one of the most common material used in various industrial fields. It is aimed to investigate; the effects of CP, known as causing damage to the testicles, and the effects of ZnO nanoparticle applications that studied not sufficient on testicular damage and apoptosis.
Rats were grouped into four as: I. Group (n=7) Control, II. Group (n=7) Cyclophosphamide (CP) (20 mg/kg/day ip), III. Group (n=7) Zinc oxide (ZnO) nanoparticles (300 mg/kg/day oral) and IV. Group (n = 7) CP + ZnO (20 mg/kg/day ip + 300 mg/kg/day oral). Elements were intraperitoneally injected and orally given to all groups for seven days. Hematoxilene-Eosine, TUNEL, Bax and Caspase-3 immunohistochemical techniques were applied to left testes. Right testes's tissue homojenants and oxidative stress markers (reduced glutation, catalase, TBARS) in blood serums were measured.
In Bax immunohistochemical staining, there was not a significant difference between Group 2 and Group 3, between all other groups there were significant differences. In Caspase-3 staining, a statistically significant difference between Group 1 – Group 2, Group 1 – Group 4, Group 2 – Group 4 and Group 3 – Group 4 were observed. According to the TUNEL method there were significant differences between all groups when compared to control group.
Serum levels of GSH and catalase were similar between Group 2 and Group 4 and were significantly different in all other groups. Serum TBARS levels showed significant differences between all groups. Tissue GSH levels were similar in Group 1 – Group 3 and Group 2 – Group 4, it showed significant differences between the other groups. Tissue levels of catalase, were similar in Group 2 – Group 3, significant differences were found in between the other groups. Tissue TBARS levels showed significant differences between all groups.
In conclusion, it was observed that zinc oxide has given less damage to the testicles than cyclophosphamide. Maximum damage was observed in combined group in the testes.

Keywords: Apoptosis, zinc oxide nanoparticles, cyclophosphamide, testicular

10.5505/2017ichc.PP-33 [Cellular aging and cell death]

Vitamin E and selenium treatment of monocrotaline induced kidney damage in rats

Gökhan Cüce[1], Mehmet Enes Sözen[1], Halime Tuba Canbaz[1], Fatma Hümeyra Yerlikaya[2], Fatma Öz Bağcı[1], Serpil Kalkan[1]

[1]Department of Histology and Embryology, Necmettin Erbakan University, Konya, Turkey

[2]Department of Biochemistry, Necmettin Erbakan University, Konya, Turkey

Monocrotaline (MCT) is a pyrrolizidine alkaloid derived from plants. MCT induces significant toxicity through its metabolites in multiple organs including kidney, liver and lung; exposure may occur by consumption of contaminated grains, herbal teas and medicines. We investigated effects of selenium (Se) and vitamin E against the toxic effects of MCT. Female Wistar albino rats were divided into four groups: a control group, an MCT group, an MCT + Se group, and an MCT + vitamin E group. Kidney tissues were harvested, fixed, processed to paraffin and sections were cut. Terminal deoxynucleotidyl transferase dUTP nick end-labeling (TUNEL), and hematoxylin and eosin staining were performed. Kidney tissue glutathione (GSH) and glutathione peroxidase (GPx) levels were measured. MCT significantly reduced the kidney GSH level and GPx activity. Na+Sel increases the kidney GPx activity and GSH level but there is no significant improvement compared to MCT group. Na+Sel increases apoptotic cell number significantly but can not form a significant alteration in histopathology score. Biochemical data indicated a significant improvement in kidney GPx activity and GSH level in the MCT + vitamin E group compared to the MCT group. Vit E increases apoptotik cell number and histopathology score significantly compared to MCT group. Vit E is more effective than NA+Sel to GSH level and GPx activity reduced by MCT in kidney.

Keywords: monocrotaline, Vitamin E, selenium, kidney, rats

10.5505/2017ichc.PP-34 [Cellular aging and cell death]

Investigation of protective effect of agomelatine in the brain cortex of rats exposed to high light stress: A histological and immunohistochemical study

Erdem Toktay, Elif Polat, Jale Selli, Tugba Bal, Nurhan Akaras
Department of Histology and Embryology, Ataturk University, Erzurum, Turkey

IIntroduction & OBJECTIVES: High light stress is known to cause oxidative stress damage in various organs in living organisms. Studies in the literature have shown that oxidative stress causes damage in tissues such as brain, liver, lung. Agomelatine, a good antioxidant, has been shown to reduce oxidative stress damage in recent studies. In this study, we aimed to demonstrate the protective effect of agomelatine against oxidative stress damage in the cerebral cortex of rats exposed to high light stress.
Materials & METHODS: 30 female Sprague Dawley rats, randomly divided into 5 groups, were used in the present study. The groups were Control group, 40mg/kg Agomelatine (AG) group, light stress (LS) group, LS + 10mg/kg AG group, LS + 40mg/kg AG group. The rats were exposed to high light stress for 24 hours for a week. Following the high light stress, rats were treated with low dose and high dose agomelatine (by gavage) for 14 days. Stress group was exposed to high light stress for 24 hours for 21 days. Only agomelatine was applied for 14 days in the AG treated group. In the control group any treatment were not used. At the end of the experiment, the brains of the rats were removed, histological sections were taken. After that the routine hematoxylin eosin and immunohistochemical (NF-κB and C-fos) stainings were performed.
RESULTS: According to histopathological findings, in the Control and AG groups normal brain cortex was observed. The shrinkage of neurons was detected in the LS group, but not in the LS + AG and the control groups. Immunohistochemical findings revealed that, NF-κB immunoreactivity was increased in neurons of the LS group, but in the LS + AG groups immunoreactivity was similar to the control group. C-fos immunostaining findings have also been shown, immunopositivity decreased in the LS group when compared to the control group, whereas C-fos immunoreactivity increased in the LS + AG groups.
CONCLUSION: In the light of the obtained findings, agomelatine was clearly thought to have a protective role in the oxidative stress damage caused by the high light stress.

Keywords: Agomelatine, Oxidative Stress, High-light Stress, Brain.

10.5505/2017ichc.PP-35 [Cellular aging and cell death]

Role of miR-503, miR-150 and miR-15a in Apoptosis and Cell Cycle in A549 and BEAS-2B Cell Lines

Hasan Dağli[1], Metin Kilinc[1], Ebru Temiz[2], Kaifee Arman[2]

[1]Department of Medical Biochemistry, University of kahramanmaraş sutcu Imam, Kahramanmaras, Turkey

[2]Department of Medical Biology, University of Gaziantep, Gaziantep, Turkey

Lung cancer is the top-line cause of cancer death worldwide. The role of miRNAs is unquestionable in lung cancer. For this purpose, the lung cancer cell line (A549) and epithelial bronchial cell line (BEAS-2B) were exposed to three different mimic miRNAs i.e. miR-503, miR-150 and miR-15a in the cell culture medium. Flow cytometry was used to determine cell cycle and the level of apoptosis in A549 and BEAS-2B. It was found that cells undergoing early and late apoptosis using miR-503 in A549 was greater as compared to BEAS-2B. When we analysed other two miRNAs, the cells were more undergoing late apoptosis but not in early apoptosis as compared to BEAS-2B. We conclude that miR-503 affects both in early and late apoptosis while miR-150 and miR-15a affects only late apoptosis. After analysing cell cycle, it was noticed that miR-503 affects the cell cycle maximum by inhibiting the progression of G0/G1 phase as compared to BEAS-2B. G2/M phase was inhibited maximum using miR-150 as compared to other miRNAs. S phase was inhibited maximum for miR-15a. Thus it was concluded that the used three different miRNAs inhibited the progression of cell cycle at different phases i.e miR-503 at G0/G1 phase, miR-150 at G2/M phase and miR-15a at S phase as compared to BEAS-2B.

Keywords: Apoptosis, Cell Cycle, MALAT1, A549, BEAS-2B

10.5505/2017ichc.PP-36 [Cellular aging and cell death]

Roles of miR-503, miR-150 and miR-15a in Osteosarcoma (U2OS) affecting Cell Cycle and Apoptosis

Hasan Dağli[1], Kaifee Arman[2], Esra Bozgeyik[2], Metin Kilinc[1]

[1]Department of Medical Biochemistry, University of kahramanmaraş sutcu Imam, Kahramanmaras, Turkey

[2]Department of Medical Biology, University of Gaziantep, Gaziantep, Turkey

Osteosarcoma is the most common malignant bone tumor in children and adolescents. It is a genetically unstable and highly malignant mesenchymal tumor of bone characterized by structural chromosomal alterations. Role of miRNAs is getting importance in osteosarcoma day by day. We selected three miRNAs i.e miR-503, miR-150 and miR-15a to investigate their role in osteosarcoma. The respective mimic miRNAs were used in the cell culture medium using osteosarcoma cell line (U2OS) and Human Umbilical Vein Endothelial Cells (HUVEC) as control. Flow cytometry was used to determine cell cycle and the level of apoptosis in both cell lines. The cells undergoing early apoptosis were more using both miR-15a and miR-150 while the cells undergoing late apoptosis were more using miR-15a. miR-503 had no considerable effect on apoptosis. After analysing cell cycle, it was noticed that miR-150 and miR-15a inhibited the cell cycle maximum at G2/M phase. G0/G1 phase was inhibited maximum for miR-503. It was concluded that the used three different miRNAs inhibited the progression of cell cycle at different phases in U2OS and HUVEC.

Keywords: miR-503, miR-150, miR-15a, HUVEC and U2OS

Cell cycle and the level of Apoptosis in both cell lines

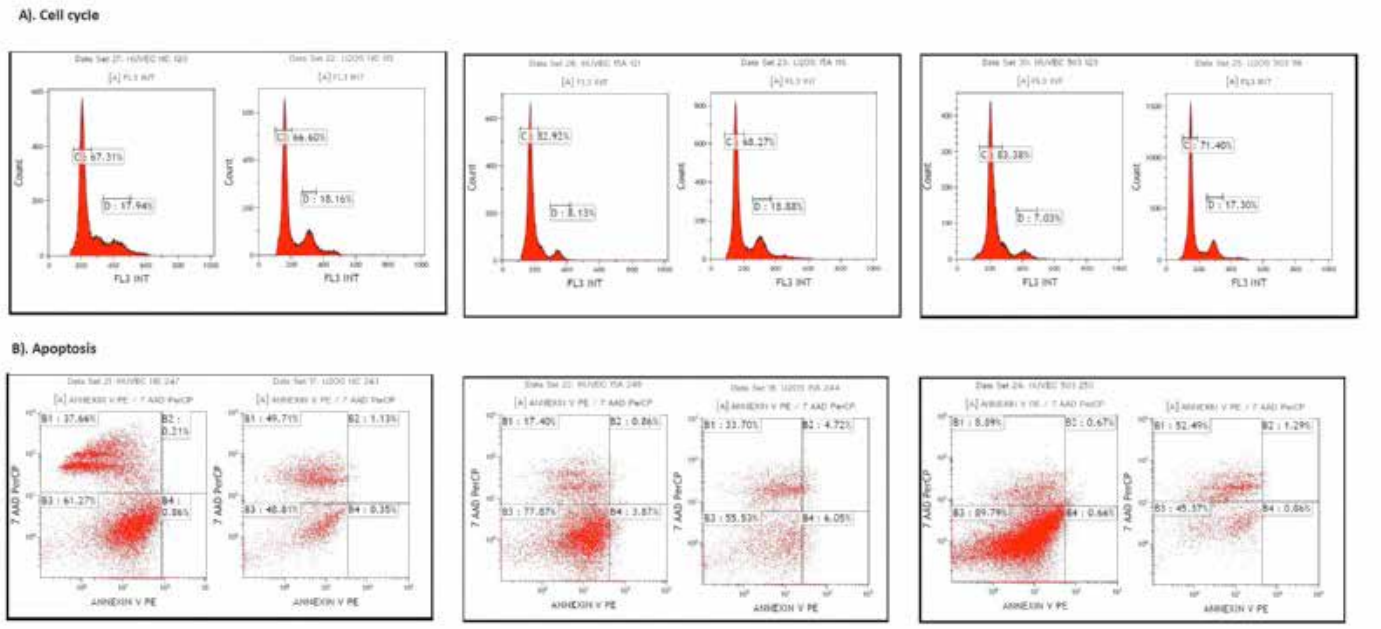

A).Analysing cell cycle in both cell lines B).level of apoptosis in both cell lines

10.5505/2017ichc.PP-37 [Cellular aging and cell death]

Apoptosis related genes and protein expression, depending on the radiation therapy role of the developing acute side effect in breast cancer patients

Tuba Mutlu[1], Matem Tunçdemir[1], Mustafa Akın[2], Merve Bostancı[1], Meltem Mete[1], Bahadır Batar[1], Mehmet Güven[1]

[1]Department of Medical Biology, Istanbul University, Cerrahpasa Medical Faculty, Istanbul, Turkey

[2]Department of Radiation Oncology, Istanbul University, Cerrahpasa Medical Faculty, Istanbul, Turkey

INTRODUCTION: Exposure to therapeutic doses of ionizing radiation (IR) may cause normal tissue reactions, such as acute and chronic side effects in cancer patients. It is considered that DNA repair and apoptotic pathways play an important role in response to IR and developing of radiotherapy-induced normal tissue reactions. In our study, we aimed to investigate the association of radiotherapy-induced acute side effects, with CASP3, NFKB and BCL-2 apoptotic pathway gene and protein expression levels, their changes in expression and cell apoptosis levels in breast cancer patients.
MATERIAL&METHODS: The study included 100 women with newly-diagnosed breast cancer, stratified into two group, a case group with acute side effects included 50 subjects and the control group without side effects included 50 subjects. Lymphocytes from each patient were cultured for 72 hr. at 37°C in CO2, followed by in vitro 2 Gray(Gy)gamma -irradiation of case and control lymphocytes; gene and protein expression analysis were performed by using quantitative reverse transcriptase-polymerase chain reaction (qRT-PCR) and western blotting techniques, respectively. Apoptosis analysis was performed subsequently. Cell apoptosis were examined by TUNEL method. Our results apoptotic analysis were calculated as the number of apoptotic cells per unit area.
RESULTS: According to the case group and the control group with the gene expression, protein expression and apoptosis analysis, we did not find any association between CASP3, NFKB and BCL-2 gene and protein expression levels, apoptosis results and acute side effects ($P>0.05$). On radiation sensitivity in normal tissue there is very little information and a limited number of studies on the effect of apoptosis gene and protein expression. For apoptotic mechanism that we think may be associated with acute response CASP3 (pro-apoptotic), NFKB and BCL-2 (anti-apoptotic) genes, we compare the levels of gene and protein expression, we did not detect a significant difference in both parameters. These results are consistent with our gene and protein expression findings.
CONCLUSIONS: Our study carries the distinction of being the first study to investigate the relationship between apoptotic process related gene and protein expression levels in breast cancer patients with radiation therapy after an acute risk of reactions in normal tissues.

Keywords: Apoptosis, TUNEL, Breast cancer, BCL2, CASP3, NFKB1

Fig 1.

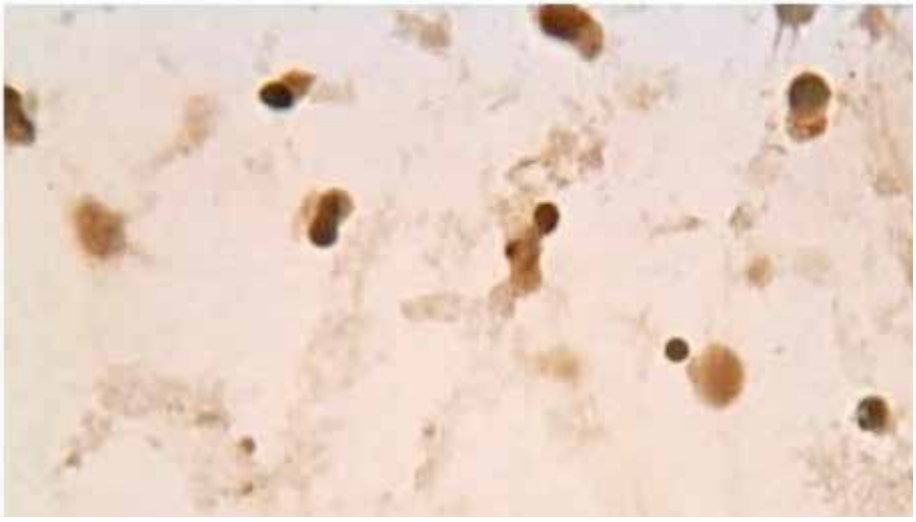

TUNEL staining of an experimental case. Cells with nuclei that stained dark brown were considered to be TUNEL-positive. Counterstaining: Methyl green. Bar, 20 µm

Fig 2.

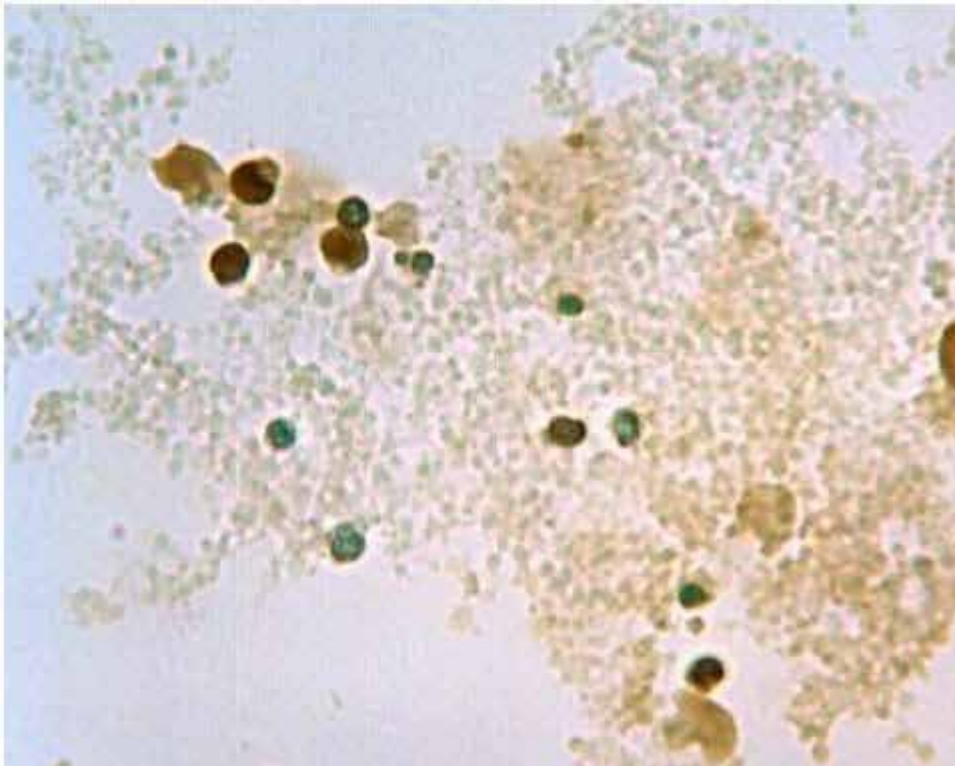

TUNEL staining of a control. Bar, 20 µm

10.5505/2017ichc.PP-38 [Cellular aging and cell death]

Prominent Roles of miR-503 and miR-15a in Breast Cancer (MCF-7) affecting Cell Cycle but not Apoptosis

Hasan Dağlı[1], Seher Kara Öngel[1], Kaifee Arman[2]

[1]Department Of Medical Biochemistry, University Of Kahramanmaraş Sütçü Imam University, Kahramanmaraş, Turkey

[2]Department Of Medical Biology, University Of Gaziantep, Gaziantep, Turkey

Breast cancer is dreadful cancer among women worldwide. miRNAs play an important role in breast cancer. For this purpose, the breast cancer cell line (MCF-7) and epithelial breast cell line (CRL-4010) were exposed to three different mimic miRNAs i.e. miR-503, miR-150 and miR-15a in the cell culture medium. Flow cytometry was used to determine cell cycle and the level of apoptosis in both cell lines. It was found that cells had no considerable effect on apoptosis using these miRNAs. There was almost no change in cells undergoing apoptosis in both cell lines after using these miRNAs. After analysing cell cycle, it was noticed that miR-503 affects the cell cycle of MCF-7 maximum by inhibiting the progression of S phase and G2/M phase as compared to CRL-4010. G0/G1 phase was inhibited maximum for miR-15a. It was concluded that the used three different miRNAs inhibited the progression of cell cycle at different phases i.e miR-503 at S and G2/M phase and miR-15a at G0/G1 phase as compared to CRL-4010. It was found that miR-150 has no effect on cell cycle in MCF-7 and CRL-4010.

Keywords: MCF-7, CRL-4010, Apoptosis. cell cycle

10.5505/2017ichc.PP-39 [Cellular aging and cell death]

Investigation of possible effects of alpha lipoic acid on ischemia reperfusion induced testis tissue

Seda Çetinkaya[1], Burcu Gültekin[2], Aydan Özgörgülü[2], Seçkin Tuncer[3]

[1]Department of Histology and Embryology, KTO Karatay University, Konya,Turkey

[2]Department of Histology and Embryology, Necmettin Erbakan University, Konya,Turkey

[3]Department of Biophysics, Necmettin Erbakan University, Konya,Turkey

AİM: Testis is sensitive to ischemia-reperfusion injury and therefore, ischemia and consecutive reperfusion cause an enhanced formation of reactive oxygen species that result in testicular cell damage and apoptosis. α-lipoic acid is a free radical scavenger and a biological antioxidant. It is widely used in the prevention of oxidative stress and cellular damage. We aimed to investigate the protective effect of α-lipoic acid on testicular damage in rats subjected to testicular ischemia-reperfusion injury.
METHODS: In this study male Sprague Dawley rats weighing 200- 250 g. (2,5-3 month) were used. The rats were randomly divided into four groups each having 10 animals. Under light anesthesia in IR group blood delivery is occluded from the infrarenal area of the abdominal aorta by using a vascular clamp, after 30 minutes the clamp was removed and blood delivery was allowed for 2 hours. In SHAM group, only clamp was not placed. I/R + ALA group alpha lipoic acid was injected (100mg/kg, i.p) for 3 days before the operation, then on the operation day the same procedure with IR group was performed. Animals in ALA group were received alpha lipoic acid (100mg/kg, i.p) every day for 3 days. The day after the last injection the animals were sacrificed and the testis tissues were collected. After routine histological follow-up techniques tissues were cut into 5 µm-thick sections. These sections were stained with hematoxylin-eosin and PAS for histological assessment. Mouse monoclonal Bcl-2 (1:100 dilution) antibody and Bax (1:100 dilution) antibody is used for immune evaluation of testis tissue sections with streptavidin-biotin-peroxidase method.
RESULTS: Histological evaluation showed that α-lipoic acid treatment reduced testicular cell damage and the Bcl-2 expression was increased in seminiferous tubules of SHAM and ALA group compared with IR and IR+ALA group. The Bax expression were found to be increased in SHAM and ALA as compared with IR and IR+ALA group.
CONCLUSION: Histopathological and immunohistochemical findings revealed that abdominal ischemia-reperfusion caused significant damage but LA is a potentially beneficial agent in protecting testicular I/R in rats.

Keywords: Testis,ischemia, reperfusion,α-lipoic acid

10.5505/2017ichc.PP-40 [Cellular aging and cell death]

Acrylamide has cytotoxic, apoptotic and anti-proliferative effects on mouse fibroblast cells

Varol Sahinturk[1], Sedat Kacar[1], Djanan Vejselova[2], Hatice Mehtap Kutlu[2]

[1]Department of Histology and Embryology, Faculty of Medicine, Eskisehir Osmangazi University, Eskisehir, Turkey

[2]Department of Biology, Faculty of Science, Anadolu University, Eskisehir, Turkey

Introduction & OBJECTIVES: Acrylamide is a toxic chemical agent found in various areas from textile, paper industry to wastewater treatment and from laboratory to our daily foods. Acrylamide formation has been observed especially in the foods processed at high temperature. NIH/3T3 mouse embryonic cell line is used as a standard fibroblast cell line. To our knowledge, there are a few studies which investigated the effects of acrylamide on NIH/3T3 cells. In the present study, we aimed to determine cytotoxic, apoptotic and anti-proliferative effects of acrylamide on NIH/3T3 cells.
Materials & METHODS: First, we performed MTT colorimetric assay and determined the half maximal inhibitory concentration, IC50 of acrylamide against NIH/3T3 cells for 24 h. Then, we searched death mode of NIH/3T3 cells by Annexin-V-FITC/PI assay and strengthened our results with caspase 3/7 assays. Lastly, we examined structural changes of acrylamide induced NIH/3T3 cells under TEM and confocal microscope at cellular and subcellular levels.
RESULTS: According to MTT assay, the viability of NIH/3T3 cells decreased dose-dependently after acrylamide treatment ($p<0.05$) and IC50 was found to be 6.73 mM. We found that total apoptotic cell percentage for acrylamide-treated cells was significantly greater than untreated cells in Annexin-V-FITC/PI assay ($p<0.05$). In addition, caspase 3/7 activity in acrylamide-treated NIH/3T3 cells was found significantly higher than that of untreated cells ($p<0.05$). Moreover, we observed membrane blebbing, cytoplasmic vacuolization, apoptotic body formation, nuclear fragmentation and condensations in TEM analysis and confocal microscopy.
CONCLUSIONS: These results suggest that IC50 of acrylamide against NIH/3T3 cells for 24 h is 6.73 mM and acrylamide has cytotoxic and anti-proliferative effects on NIH/3T3 cells and this effect is caused via apoptosis. This study is the unique in ascertaining effects of acrylamide on NIH/3T3 cells comprehensively. Additional studies are needed to elucidate the exact mechanism of acrylamide on these cells.

Keywords: Acrylamide, NIH/3T3 cell line, cytotoxicity, caspase 3/7, confocal microscopy

10.5505/2017ichc.PP-41 [Epigenetics & molecular cytogenetics]

The Epigenetic Analysis of the Effect of 17β-Estradiol and 1,25-Dihydroxyvitamin D3 on the Proliferation and Apoptosis Dynamics of Smooth Muscle Cells

Kezban Kibar[1], Şakir Necat Yilmaz[1], Derya Yetkin[1], Gülhan Orekici Temel[2], Ülkü Çömelekoğlu[3]

[1]Department of Histology and Embryology, Mersin University, Mersin, Turkey

[2]Department of Biostatistics and Medical Informatics, Mersin University, Mersin, Turkey

[3]Department of Biophysics, Mersin University, Mersin, Turkey

Introduction & OBJECTIVES: Our study was designed to investigate the possible role of estradiol and vitamin D in atherosclerotic vascular pathology and disease progression whether those hormones have beneficial or detrimental effects on vascular smooth muscle cells.
MATERIAL-METHODS: In the present study, cultured rat aortic smooth muscle cells were treated with estradiol and/or vitamin D in different concentrations. Real-time cell analysis was chosen as a method to report their proliferation dynamics. To determine the apoptotic rates of cells treated with different concentrations of the hormones, caspase 3 immunostaining method was performed and the apoptotic indices of the groups were compared. In addition, to determine the changes in estrogen receptors and epigenetic markers for DNA methylation, immunostaining for DNMT1, DNMT3a, ER-α and ER-β were carried out. Staining intensity between the groups was then evaluated.
RESULTS: Assessment of our findings revealed that the effect of the homones on the smooth muscle cell proliferation was not statistically significant (Figure 1). The hormone estradiol did not lead to apoptosis on the cells while vitamin D3 induced apoptosis in a dose-dependent manner (Figure 2, 3). The staining intensity was found to be different only for DNMT3a in some of the 72 hour hormone-treated groups (Figure 4, 5).
CONCLUSION: In the light of these findings, it is suggested that both estradiol and vitamin D play an important role in smooth muscle cell apoptosis and their effects are opposite to each other. It is also inevitable to conclude that these hormones may not be effective on the smooth muscle cell proliferation and they may exert their epigenetic effects on vascular smooth muscle cells over DNMT3a.
"This study was supported by the Research Fund of Mersin University in Turkey (2015-TP2-1363)."

Keywords: 1,25-Dihydroxy vitamin D3, 17β-Estradiol, Apoptosis, Epigenetics, Rat Aortic Smooth Muscle Cells.

Figure 1: Proliferation dynamics of rat aortic smooth muscle cells as shown by real-time cell analysis.

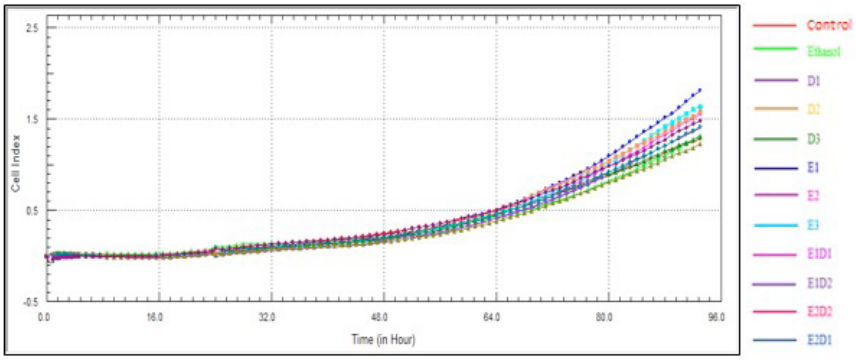

D1: 1 nM of vitamin D3; D2: 10 nM of vitamin D3; D3: 100 nM of vitamin D3; E1: 1 nM estradiol; E2: 10 nM of estradiol; E3: 100 nM of estradiol; E1D1: 1 nM of estradiol+1 nM of vitamin D3; E1D2: 1 nM of estradiol+10 nM of vitamin D3; E2D2: 10 nM of estradiol+10 nM of vitamin D3; E2D1: 10 nM of estradiol+1 nM of vitamin D3.

Figure 2: Caspase 3 immunostaining densities after 24 hr hormone treatment.

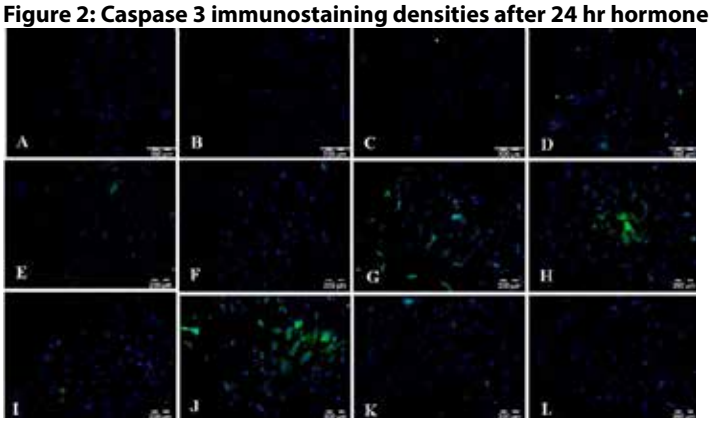

A: Control; B: 1 nM of estradiol; C: 10 nM of estradiol; D: 100 nM of estradiol; E: Ethanol (1: 20000); F: 1 nM of vitamin D3; G: 10 nM of vitamin D3; H: 100 nM of vitamin D3; I: 1 nM of estradiol+1 nM of vitamin D3; J: 1 nM of estradiol+10 nM of vitamin D3; K: 10 nM of estradiol+10 nM of vitamin D3; L: 10 nM of estradiol+1 nM of vitamin D3.

Figure 3: Comparison of apoptotic indices of ethanol (1:20000) with 1 nM of vitamin D3 (D1), 10 nM of vitamin D3 (D2) and 100 nM of vitamin D3 (D3) groups.

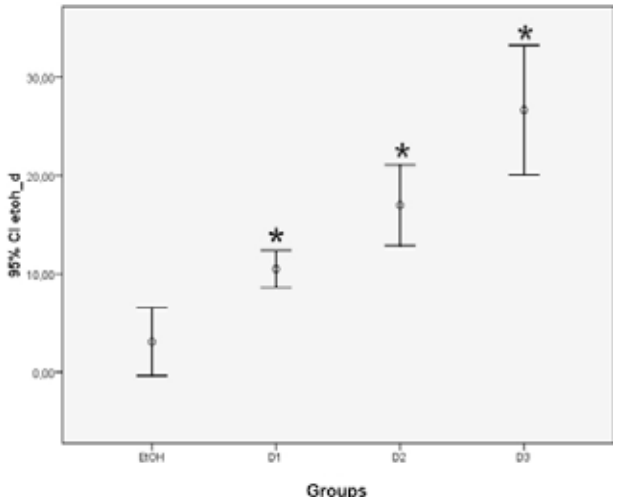

Figure 4: Comparison of DNMT3a labeling intensity between ethanol (1:20000) and 1 nM of vitamin D3 (D1), 10 nM of vitamin D3 (D2) and 100 nM of vitamin D3 (D3) concentration groups treated for 72 hours.

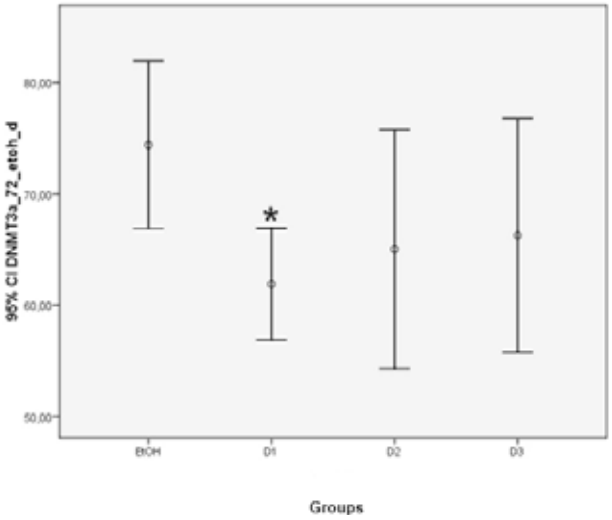

Figure 5: Comparison of the DNMT3a labeling intensity between ethanol (1:20000) with 10 nM of estradiol (E2), 10 nM of vitamin D3 (D2) and 10 nM of estradiol + 10 nM of vitamin D3 combined groups (E2D2) treated for 72 hours.

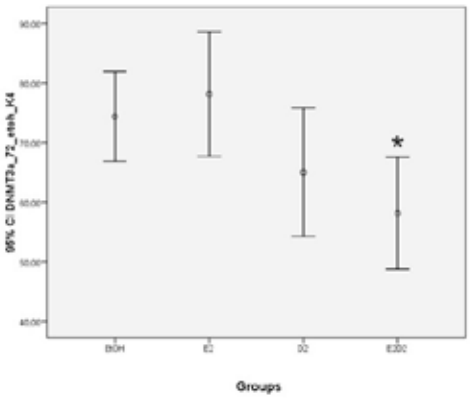

10.5505/2017ichc.PP-42 [Glycobiology]

Histochemical characterizations of glycoconjugates in the lingual glands of the sheep tongue

Serkan Erdoğan[1], Hakan Sağsöz[2]

[1]Department of Anatomy, Namık Kemal University, Tekirdağ, Turkey

[2]Department of Histology and Embryology, Dicle University, Diyarbakir, Turkey

Introduction & OBJECTIVES: Salivary mucins form a barrier between the oral mucosa and the bacterial flora, and form a protective layer against drying, mechanical destruction, external toxic substances and microbial toxins in the oral mucosa. In particular, sulfated mucins play an important role in the protection of the mucosa against bacterial adhesions. This research was aimed to reveal the histochemical features and mucin contents of the seromucous glands and von Ebner's glands in sheep tongue considering species-specific characteristics. We demonstrated changes in carbohydrate lateral chains of secretions of epithelial cells of the lingual glands.
Materials & METHODS: For that purpose, the tongues of ten sheep were evaluated. Periodic Acid Schiff for neutral mucins in glands (vicinal diol groups); Diastase-Periodic Acid Schiff for glycogen; Alcian Blue (pH 2.5) for acid mucins; Alcian Blue (pH 2.5)–Periodic Acid Schiff for neutral and acid mucins; Alican blue (pH 2.5)–Aldehyde Fuchsin for carboxylated and sulphated acid mucins; and Phenylhydrazine–Periodic Acid Schiff for periodate reactive acid mucins (N-acetyl sialomucins) were used as staining methods.
RESULTS: Neutral and weak sulfated mucins and N-acetyl sialomucins existed in seromucous glands, salivary duct epithelium and von Ebner's glands, but carboxylated acid mucins and N-acetyl sialomucins did not exist in seromucous and von Ebner's glands.
CONCLUSIONS: We determined that this mucin composition, serving as a physical barrier in the initial section of the digestive system, is quite similar to other mammal species investigated.

Keywords: Histochemistry, lingual glands, mucin, small ruminant.

10.5505/2017ichc.PP-43 [Glycobiology]

Functional Identification of Mucin Composition (MUC1, MUC1, MUC5AC, MUC6) in the Ovine Lingual Glands

Serkan Erdoğan[1], Hakan Sağsöz[2]

[1]Department of Anatomy, Namık Kemal University, Tekirdağ

[2]Department of Histology and Embryology, Dicle University,Diyarbakır, Turkey

Introduction & OBJECTIVES: The main function of mucins, covering the cell surface, has been reported to protect the mucosa against the bacterial penetration and invasion and they perform this protection acting like a trap ligand for microorganisms. This study was aimed to determine the mucin contents immunohistochemically and their possible functional roles in the seromucous glands and von Ebner's glands in the sheep tongue. We evaluated expression of proteins of mucin 1, mucin 2, mucin 5AC and mucin 6 in epithelial cells of the lingual glands to compare the molecular profiles of the mucins.
Materials & METHODS: For this purpose, the tongues of ten sheep were used. Strepavidin peroxidase method was used for the identification of the localizations of mucin genes; mucin 1, mucin 2, mucin 5AC and mucin 6. Regarding expressions of mucins, the evaluation was performed as semi-quantitative in cells exhibiting a positive reaction. The positive cells were scored in four levels according to their staining intensity.
RESULTS: We revealed that in seromucous glands, mucin 1, mucin 5AC and mucin 6 become localized only in duct's epithelial cells, whereas mucin 2 become localized in both glandular and duct's epithelial cells. By contrast with that we found that all mucins, observed in both von Ebner's glands and salivary ducts, became localized.
CONCLUSIONS: Considering functional effects of these results that we obtained; differences in mucins, secreted from glands, were evaluated as a reflection of the adaptation of physiological requirements, including the protection against bacterial colonization.

Keywords: Immunohistochemistry, tongue, mucins, sheep.

10.5505/2017ichc.PP-44 [In vivo imaging]

Use of 3D medical modeling and animation in the Histology and Embryology

Tuncay Veysel Peker[1], Suna Ömeroğlu[2], Saadet Özen Dizakar[3], Ismail Türkoğlu[4]

[1]Prof.Dr. Tuncay Veysel Peker (Gazi Üniversitesi Tıp Fakültesi Anatomi Anabilim Dalı, Ankara, Türkiye)

[2]Prof.Dr. Suna Ömeroğlu (Gazi Üniversitesi Tıp Fakültesi Histoloji ve Embriyoloji Anabilim dalı, Ankara, Türkiye)

[3]Arş. Gör. Saadet Özen Akarca Dizakar (Gazi Üniversitesi Tıp Fakültesi Histoloji ve Embriyoloji Anabilim dalı, Ankara, Türkiye)

[4]Arş. Gör. İsmail TÜRKOĞLU (Gazi Üniversitesi Tıp Fakültesi Histoloji ve Embriyoloji Anabilim dalı, Ankara, Türkiye)

Histology and Embryology is a science that visuality is important. The possibilities brought by computer technology for this purpose have also increased the use of visual materials in this area. In the field of medical education or scientific studies related to Histology and Embryology, 3D modeling method has found a current usage area.
Normal and histopathologic images obtained from our studies carried out in Histology and Embryology Department were evaluated in Leica DM 4000B Q Vin 3 program and three-dimensional modeling of these images were made by going out from these findings. Printed outs were taken from obtained 3D models by using 3D printer. Finally, the obtained digital materials were examined comparatively with classical histomorphological findings.
As a result, this powerful technology also makes it possible to create dynamic, interactive, and indistinguishable animations (such as virtual reality and enhanced reality). We think that the use of three-dimensional models related to microscopic structures in education of histology and embryology will meet the shortage in this area and will lead the researchers interested in the subject.

Keywords: 3D, medical modelling, medical animation, histoology and embryology

10.5505/2017ichc.PP-45 [Intracellular membrane dynamics]

Effect of acrylamide on mitochondrial potential and cell cycle of fibroblast cell lines

Sedat Kacar[1], Melike Cevik[2], Hatice Mehtap Kutlu[2], Varol Sahinturk[1]

[1]Department of Histology and Embryology, Faculty of Medicine, Eskisehir Osmangazi University, Eskisehir, Turkey

[2]Department of Biology, Faculty of Science, Anadolu University, Eskisehir, Turkey

Introduction & OBJECTIVES: Acrylamide is a colorless, odorless and readily water soluble chemical with the formula of C3H5NO. Acrylamide is utilized in many areas. After 2002, it was also revealed that acrylamide forms in foods following some processes e.g. frying, roasting and baking. Since then, acrylamide has been reported to be toxic to many tissues and organs. The effect of such a widespread chemical on fibroblast cells has not been investigated much due to very few studies conducted. In this experiment, we will search how acrylamide alters mitochondrial potential and cell cycle of fibroblast cells.
Materials & METHODS: We used two groups of acrylamide-treated and untreated for each experiment. In the acrylamide-treated group, 3T3 cells were treated with IC50 of 6.73 mM acrylamide for 24 h. After incubation of cells at 37 °C for with appropriate CO2 medium, mitochondrial membrane potentials and cell cycle of the cells were separately evaluated. At least 5×105 cells were used for analyses.
RESULTS: Acylamide-treated group has higher membrane-depolarized cells when compared to untreated cells ($p < 0.05$) with regard to mitochondrial membrane potential assay. As for the cell cycle analysis, cell percentage of G0/G1 cell cycle arrest in acrylamide-treated cells were greater than untreated cells, while S and G2/M phase cells were relatively same percentage.
CONCLUSIONS: This study shows that acrylamide may disrupt mitochondrial membrane potential and retain NIH/3T3 cells in G0/G1 phases of cell cycle. However, additional research is needed to ensure the exact underlying mechanism of acrylamide.

Keywords: Acrylamide, NIH/3T3 cell line, cell cycle, mitochondrial membrane potential

10.5505/2017ichc.PP-46 [Stem cells]

Does the function of colon cancer stem cells controlled by inflammatory microenvironment ?

Feyzan Ozdal Kurt[1], Remziye Kendirci[2], Canan Turkoglu[1], Hafize Seda Vatansever[3]

[1]Department of Biology, Faculty of Science, Celal Bayar University, Manisa, Turkey

[2]Department of Histology and Embryology, Faculty of Medicine, Celal Bayar University, Manisa, Turkey

[3]Department of Histology and Embryology, Faculty of Medicine, Celal Bayar University, Manisa, Turkey, Near East University, Experimental Health Science Research Center, Nicosia, North Cyprus

Cancer stem cells (CSCs) are a subpopulation of cancer cells involved in tumor initiation, resistance to therapy and metastasis. They have similar properties with normal stem cells but, they grow rapidly and differentiate to tumor cells. CSCs have the ability to drive continued expansion of the population of malignant cells. CSC fate is determinate by intrinsic and extrinsic pathways, including cytokine network. It is possible that cytokines induce many of the properties of cancer cells and CSCs. IL-6 and IL-8 induce elevated levels of CSC self-renewal in breast cancer, while IL-1β stimulates the stemness and invasiveness of CSCs in colon cancer. Since the mechanisms which control the stem cells increase and mutation are now better understood, we expect better cures to be developed for the diseases like cancer and many others.

In this study, the human metastatic colon carcinoma cell line (Colo 741) and human primary colon cancer cell line (HCT 116) were cultured in RPMI-1640 containing 10% FCS, 1% L-glutamine and 1% penicilin-streptomycine. Colon carcinoma stem cells were isolated from both types of cells by magnetic-activated cell sorting (MACS) technique and characterized by CD133 surface protein using immunohistochemical analyses. Magnetically labeled CD133+ and unlabeled CD133– both Colo 741 and HCT 116 cells were passaged after reaching 80% monolayer confluency. They were then fixed with 4% paraformaldyde and distributions of anti-IL-6, anti-IL-8, anti-beta-catenin, anti-c-myc and anti-cyclin D1 were investigated using indirect immunoperoxidase staining.

CD133+ both Colo 741 and HCT 116 cells were positively secreted IL-6 and -8 rather than CD133- cells. In addition, cell cycle controlling proteins (beta-catenin, c-myc and cyclin D1) were also differ in CD133+ cells.

Cytokines secreted by either cancer cells or surrounding stromal cells can induce tumorigenesis. Results from recent studies have revealed that the inflammatory microenvironment is able to promote oncogenesis. IL-1β promotes the self-renewal and oncogenic ability of gliomas, while IL-6 and IL-8 activate oncogenic ability of colon CSCs. For this reason, in this study we concluded that primary and metastatic colon cancer cells may release different cytokines to continuity for cancer and their characteristics.

Keywords: Cancer stem cells, colon, cell cycle, inflamation

10.5505/2017ichc.PP-47 [Stem cells]

An Analysis of Apoptosis and Wnt/Beta Catenin Pathway in The Interaction of Leukemic Cells and Mesenchymal Stem Cells Derived from Bone Marrow of Patients with Childhood Acute Lymphoblastic Leukemia and Healthy Donors

Tuba Ozdemir Sanci[1], Sevil Çayli[1], Ilkay Piskin[1], Yasin Koksal[2], H. Meltem Ozguner[1]

[1]Deparment of Histology & Embryology, Yıldırım Beyazıt University, Ankara, Turkey

[2]Deparment of Pediatric Hematology/Oncology, Stem Cell Laboratory, Ankara Childrens' Hematology/Oncology Education and Research Hospital, Ankara, Turkey

INTRODUCTION: Acute lymphoblastic leukemia (ALL) is the most common malignancy in childhood. Despite the high rate of cure, ALL is one of the leading causes of death in children. The bone marrow microenvironment plays an important role in the initiation and progression of leukemia. Various components of this microenvironment, particularly Mesenchymal Stem Cells (MSCs), regulate ALL cell survival, proliferation and drug resistance by producing growth factors, cytokines, and intracellular signals. The exact role of MSCs in leukemic cell survival is not well known, but probably they show their effects through secreting various cytokines, signals or interact with the leukemic cells. During hematopoiesis, the survival of progenitor cells is regulated both positively and negatively by various pathway. Apoptosis is a well-regulated cell death program that plays a key role in the control of cell homeostasis of the hematopoietic system. Aberrant activation of the Wnt pathway has also been observed in hematological malignancies. However, the role of Wnt pathway in the cross-talk between ALL cells and MSCs is uncertain and the effect of Wnt pathway on ALL development and progression needs to be assessed.
MATERIALS&METHODS: The apoptotic effects of MSCs of patients with childhood ALL and healthy donors on blastic cells were investigated in vitro by coculturing without cell-cell contact and providing cell-cell contact. After the interaction between cells, Bax, Bcl-2, Caspase 3 and β-catenin expression were determined by immunocytochemical methods in MSCs.
RESULTS: Compared with β-catenin expression, healthy groups showed cytoplasmic expression however patients especially have cell contact with blastic cells, showed nuclear expression. Additionally, Bcl-2, Bax and Caspase 3 expression of MSCs of patient groups without blastic cells contact were increased in comparison with patient group with blastic cells contact.
CONCLUSION: Our data suggests that increased nuclear expression of β-catenin and decreased Bcl-2, Bax and Caspase 3 expression in MSCs of patients have cell contact blastic cells might be related to leukemic cell survival. Wnt proteins released by activation of the Wnt/β-catenin pathway may have affected leukemic cell survival. Therefore, our study highlights an important potential relationship between leukemic cell apoptosis and Wnt/β-catenin pathway.

Keywords: Apoptosis, childhood acute lymphoblastic leukemia, mesenchymal stem cells, β-catenin,

10.5505/2017ichc.PP-48 [Stem cells]

Effects of keratinocytes that differentiated from mouse embryonic stem cells on wound healing under pressure of steroids on mice

Hasan Aydede[1], Erdem Obuz[1], Seda Vatansever[2], Elgin Turkoz Uluer[3], Mujde Kıvanc[3]

[1]Department of General Surgery, Faculty of Medicine, Celal Bayar University, Manisa, Turkey

[2]Department of Histology and Embryology, Faculty of Medicine, Celal Bayar University, Manisa, Turkey, Experimental Health Science Research Center, Near East University, Nicosia, North Cyprus

[3]Department of Histology and Embryology, Faculty of Medicine, Celal Bayar University, Manisa, Turkey

OBJECTIVE: The effects of corticosteroids on wound healing have been a topic of great interest among surgeons, internists, and dermatologists. The treatments of skin using autologous/allogenic skin grafts constitute differentiated adult or embryonic stem cells (ESC) are popular. The purpose of this study is to investigate effects of keratinocytes which derived from mouse embryonic stem cells on wound healing which is under the steroid suppression.
MATERIAL-METHODS: Embryoblasts which derived from mouse ESC, cultured on matrigel including BMP-4 for 10 days. Some of them were fixed in 4% paraformaldehyde and analyzed distribution of cytokeratin-8 and cytokeratin-14 with indirect immunoperoxidase method. Some of the cells were transferred to the surgical wound that is created on the neck region of the mice. Groups were designated as:
Group1: Only the surgical wound created group
Group2: Surgical wound created after steroid treatment group
Group3: Keratinocyte transferred after surgical wound created group
Group4: Keratinocyte transferred after surgical wound created and steroid treatment group
All samples were collected 1th, 5th and 10th day of surgical process for light microscopic analyses. Samples were fixed in 10% formalin and some of the paraffin sections were stained with H&E and the rest of the sections were stained with indirect immunoperoxidase technique in order to determine distributions of MCP-1, IL1β, TNFα, EGF, MMP2 and MMP9.
RESULTS: Cells which are differentiated from mouse ESC were positively stained with cytokeratin-8 and cytokeratin-14. The increased immunoreactivity of MCP-1, IL1β, TNFα, EGF, MMP2 and MMP9 molecules which are secreted from the wound healing area were seen in the cell transferred groups. While in the steroid treatment and wound group these molecules immunoreactivities were decreased.
DISCUSSION: In wound repair mechanism, cells, differentiated from ESC, are accelerate secretion of factors from early stage and effect positively during the wound healing. Wound healing was delayed because of the steroid treatment which suppressed the molecules that are secreted form the wound healing area. Therefore, keratinocytes could be use in clinical treatments of wound repair process.

Keywords: Embryonic stem cell, wound healing, steroid

10.5505/2017ichc.PP-49 [Stem cells]

Comparison of Some Surface Marker Expressions with Immunocytochemical and Flow Cytometric Methods in MSC Culture Passages 1 and 4

Gulsemin Cicek[1], Emine Utlu Ozen[1], Muharrem Cicek[2], Selcuk Duman[1], Tahsin Murad Aktan[1], Ayse Ozlem Gundeslioglu[3]

[1]Department of Histology and Embryology, Necmettin Erbakan University, Konya,Turkey

[2]Department of Histology and Embryology, Istanbul University, Istanbul, Turkey

[3]Department of Plastic and Reconstructive Surgery, Necmettin Erbakan University, Konya,Turkey

INTRODUCTION: The stromal vascular fraction(SVF) sheltered in the adult human adipose tissue contains preadipocytes, mesenchymal stem cells(MSC), fibroblasts,endothelial cells, macrophages, and smooth muscle cells.Adipose tissue-derived stromal stem cells are multipotent cells that can self-renewal, proliferate and differentiate.There are environmental conditions of the cells that provide and stabilize these essential features of the MSCs.Repair mechanisms in cellular treatments are achieved by these conditions.There are clusters of differentiation(CD) markers on the surface of there cells, which play a role in adhesion and migration or affect cell signaling pathways. MSCs express primarily CD44, CD73, CD90, CD105, CD166 on their surface while; HLA-DR, CD19 and CD34 are not expressed.The aim of this study is to evaluate surface marker expressions in the progressive culture passages of MSC.METHODS: SVF cells were harvested with enyzimatic reaction of human adipose tissue obtained from liposuction procedure.Cell cultivation was done with 25 cm^2 flasks by using DMEM with additives of 10% fetal bovine serum, penicillin-streptomycin and L-glutamin.When cellular confluence in culture flask reached 70-80%; the cells were detached and replated onto sterile culture flasks of to 25 cm^2 as 1000 cells per cm^2.Immunocytochemical stain and flow cytometric analysis was performed on P1 and P4 passages cells.The expression of CD19, CD44, CD90, CD105 in MSC was determined by immunocytochemistry using primary polyclonal antibodies (Bioss,USA) at a dilution of 1:150 with secondary avidin-biotin-peroxidase complex (Ultravision Detection System Anti-polyvalent,HRP,LabVision,USA).For flow cytometric analysis the cells were detached from the flask bottom and incubated in the dark for 30 min at +4°C temperature after being treated with conjugated antibodies anti-human CD105/FITC, anti-human CD90/PE, anti-human CD44/Alexa Fluor® 647 and anti-human CD19/PECy5 (MerckMillipore,Germany).RESULTS: Flow cytometric analysis showed that surface marker expressions are as; for P1:CD19 0,6%; CD44 96,2%; CD105 79,3%; CD90 97,7% and for P4:CD19 0,6%; CD44 93,4%; CD105 78,8%; CD90 96,8% positive in rates while immunocytochemical staining results also supported these results.In conclusion, we observed that between p1 and p4 passages there is not any significant difference in studied MSC surface marker expressions.Ethics approval:This study was conducted with the approval of the ethics committee of Meram Medical Faculty, Necmettin Erbakan University(Ref:2016/674)

Keywords: Stem Cell, Cell Culture, Immunocytochemistry

10.5505/2017ichc.PP-50 [Stem cells]

Anneksin-V/PI and Flow Cytometric Evaluation of MSC Culture Viability, Apopitosis and Necrosis

Selcuk Duman, Fatma Oz Bagcı, Gulsemin Cicek, Tahsin Murad Aktan
Department of Histology and Embriyology, Necmettin Erbakan University, Konya, Turkey

INTRODUCTION: Fat tissue is involved in glucose and lipid metabolism, reproduction, blood pressure control and immune systems for the organism. There is a special cell fraction named as SVF obtained under certain laboratory conditions, which can be used in tissue reconstruction, neural, muscle, bone and joint degeneration treatments. In SVF cell population especially Mesenchymal Stem Cells (MSC) have regenerative effects in treatments. Also MSCs are obtained very easily and can preserve their properties under culture conditions, which make them a good candidate for such treatment. AIM: To evaluate P2 and P4 of MSCs culture cell viability, early and late apoptosis / necrosis percent's. METHODS: After thawing MSCs vial, cells were cultivated for cell propagation as seeding 1000 cells per cm^2 in 25 cm^2 flasks. At passages 2 and 4 cells were detached for fluorescence and flow cytometric analysis. For this aim cell suspension was added to Annexin-V/PI (Roche, Germany) and incubation was held in 4°C, 30 minutes in dark. Flow cytometric analysis was performed and during microscopic observation 200 cells were counted. RESULTS: The viability, early apoptosis, late apoptosis and necrotic cell percentage of MSC for P2 and P4 was respectively 92-90; 2-3; 5-6 and 1-1 under microscopic investigation. The viability, early apoptosis, late apoptosis and necrotic cell percentage of MSC for P2 and P4 was respectively 94,2-91,8; 1,3-0,8; 3,7-5,9 and 0,8-1,5 under flow cytometric analysis. CONCLUSION: In two different passages of MSC similar results were obtained with two different techniques. This shows us that at least for these passages cells preserve their viability, apoptotic/necrotic properties.This work is supported by 131218024 Necmettin Erbakan University Meram Medical Faculty BAP.

Keywords: stem cell, apoptosis, viability, flow cytometer

10.5505/2017ichc.PP-51 [Stem cells]

The Osteogenic Effects of Parathormone on Programmable Cells of Monocytic Origin (PCMO) Derived from Peripheral Blood

Mustafa Caglar Kir[1], Melike Ozgul[2], Elgin Turkoz Uluer[2], Cevval Ulman[3], Sevinc Inan[4]

[1]Department of Orthopedics and Traumatology, Okmeydani Training and Research Hospital, Istanbul, TURKEY

[2]Department of Histology & Embryology, Faculty of Medicine, Manisa Celal Bayar University, Manisa, TURKEY

[3]Department of Biochemistry, Faculty of Medicine, Manisa Celal Bayar University, Manisa, TURKEY

[4]Department of Histology & Embryology, Faculty of Medicine, Izmir University of Economics, Izmir, TURKEY

AIM: Impaired bone healing can result from many pathologic conditions like severe trauma, bone tumors, and infection. This situation may cause serious patient morbidity. There is no publication about parathormone which is known as a regulator of bone remodeling and calcium metabolism whether effective or not on osteogenic differentiation of PCMO. The aim of this study was to investigate the osteogenic effects of continuous or intermittent applications of PCMO derived from peripheral blood.
MATERIAL-METHOD: Peripheral blood samples collected from healthy people were used in this in vitro study. The mononuclear cells were collected from buffy-coat of peripheral blood using Ficoll-Paque method. The isolated adhesive cells were generated to PCMO using dedifferentiation culture conditions for 6 days. The PCMO was identified by immunohistochemistry using anti-CD14, anti-CD45 and anti-CD90 primary antibodies. Then PCMO treated with continuous or intermittent parathormone (50 ng/mL) was seeded into osteogenic differentiation medium for 14 days. PCMO without parathormone was also seeded into osteogenic differentiation medium as control group. The two-different parathormone treated groups and the control group were compared by immunocytochemistry assay using anti-Collagen I, anti-Osteonectin and anti-Osteocalsin primary antibodies. The results were compared statistically with using ANOVA test.
RESULTS: To characterize PCMO, the immunoreactivities of CD14, CD45 and CD90 were evaluated. The immunoreactivities of CD14, CD45 and CD90 were seen as mild, moderate and strong, respectively. The osteogenic differentiation of PCMO with continuous or intermittent applications of parathormone effected distribution profiles of Collagen I, Osteonectin and Osteocalsin immunoreactivities which are detected increased in treated groups compared to control group($p<0.05$).
CONCLUSION: Tissue engineering strategy is to stimulate the mesenchymal stem cell differentiation and proliferation into osteoblasts by growth factors and hormones. The obtaining of stem cells from iliac crest or long bones may lead significant donor side morbidity. Thus, the investigations have been focused on PCMO derived from peripheral blood and the potential of PCMO differentiation into osteoblasts and chondroblasts. The intermittent and continuous application of parathormone promotes the osteogenic differentiation of PCMO and new treatment methods may be improved for bone healing disorders without donor site complications in the future.

Keywords: PCMO, Stem cell, Parathormone, Osteogenesis

10.5505/2017ichc.PP-52 [Stem cells]

Rab23 expression in prostate cancer stem cell

Gunel Mukhtarova[1], Sule Ayla[2], Cuneyd Parlayan[3], Gulperi Oktem[4]

[1]Department of Stem Cell, Ege University Health Science Institute, Ege University, Izmir, Turkey

[2]Department of Histology and Embryology, Faculty of Medicine, Istanbul Medipol University, Istanbul, Turkey

[3]Department of Biomedical Engineering, School of Engineering and Natural Science, Istanbul Medipol University, Istanbul, Turkey

[4]Department of Histology and Embryology, Faculty of Medicine, Ege University, Izmir, Turkey

Introduction & OBJECTIVES: Sonic Hedgehog signaling plays role in transformation of prostate basal/stem cells into prostate cancer stem cells (PCSCs) and regulates maintenance and survival of cancer stem cells.
Rab23 is a negative regulator of SHH that is predominantly expressed in the brain and functions downstream of Smoothened (SMO) and on upstream of GLI family zinc finger 1 (GLI1) proteins by controlling the subcellular localization of essential the SHH components.
To eliminate CSC, that drives tumor initiation, progression, cell death resistance, traditional therapy resistance and tumor recurrence, prevent metastasis and decrease drug resistance the SHH pathway inhibition provide a promising treatment target. Although, the SHH pathway activation has been strongly implicated in cancer progression, knowledge the role of Rab23 in SHH pathway activation in prostate cancer and CSC is unknown.
The goal of our study was to elucidate the role of Rab23 in prostate cancer (PCa) by assessing the mRNA and protein expression of Rab23 in PCa cell lines.
Materials & METHODS: We analysed gene expression profiles of SHH pathway including Rab23 in prostate cancer stem cell (Du145 CSC) comparatively to non-CSC (Du145 non-CSC), prostate cell line (Du145 cell line) and prostate epithelial cell line (RWPE1 cell line). Whole transcriptome sequencing was done on relevant experimental groups.
To investigate megalin protein expression and localization of Rab 23 on relevant experimental groups we used immunofluorescence staning assay and experimental groups were stained with Rab23 antibodies.
RESULTS: Our results reveal relation of Rab23 expression changes with SHH pathway activation in human prostate CSC may prove crucial in determination Rab23 role as biologic marker for inhibition of SHH pathway in CSC which will provide promising therapeutic target to eliminate CSC and to prevent metastasis, invasion and decrease drug resistance.
CONCLUSION: We obtained increased Rab23 gene and protein expression in CSC. For the determinea role of the Rab23 in the SHH pathway may reqiure larger study that including Rab23 gene silencing assay and drug resistance assay which effects Rab23 function.

Keywords: Rab23, prostate cancer, cancer stem cell, Sonic-hedgehog pathway.

10.5505/2017ichc.PP-53 [Stem cells]

'Comparison of Subcutan and Inguinal Adipose Tissue Derived Mesenchymal Stem Cells'

Hatice Erdost, Ece Çerçi, Cansel Güzin Özgüden Akkoç, Tuncay Ilhan
Department of Histology and Embriyology, Uludag University Veterinary Faculty, Bursa, Turkey

INTRODUCTION & OBJECTIVES: Mesenchymal stem cells(MSCs) are multipotent cells that maintain homeostasis in the body by regeneration and repair of damaged and aged tissues.
Adipose tissue derived stem cells (ASCs) are MSCs which can be obtained from different adipose tissue sources within the body. It is an abundant cell pool, that is easy to access and the cells can be obtained in large numbers, cultivated and expanded in vitro for the tissue engineering application.
The aim of this study was to compare between rat inguinal adipose tissue and subcutan adipose tissue derived MSCs. Especially, these cells were compared in terms of cell proliferation, osteogenic, chondrogenic and adipogenic differentiation potentials.
MATERIALS & METHODS: We used inguinal and subcutan fat pads of Sprague Dawley 12 week- old rats for in vitro primary cell culture. It was performed with the non-enzymatic explant culture method. After primary cell isolation was completed by non enzymatic method, fibroblastoid cells were obtained from subcutan and inguinal adipose tissue.
Two different kind groups of adipose tissues were harvested successfully and the images were captured between on the day of the 2nd. and 14th. Morfological view, viability, proliferation differences and differentiation capacity were evaluated by monitoring with inverted phase microscopy. At the end of the third passage, the cells were induced for differentiation into cells of adipogenic, osteogenic and chondrogenic lineage.
RESULTS: The comparison of the proliferation potential of the cells isolated from inguinal and subcutan adipose tissue demonstrated that the adipose-derived cells of the subcutan and inguinal had reached 70% confluence at the 1st passage on day 7 and day 14 respectively. Our findings have indicated that Sc-ADSCs and I-ADSCs may be ideal candidates for adult MSCs. However Sc-ADSCs are faster proliferation and differentation capacity than I-ADSCs. Hence, these results may reveal a different approach to solve the difficulties associated with regenerative application in veterınary medicine.
CONCLUSIONS: Finding of Sc-ADSCs indicate that it will be helpful to beneficially determine the new interactions. In the recent years MSCs population has attracted a great amount of attention among researchers in veterinary medicine.

Keywords: Mesenchymal stem cells, Subcutan Adipose Tissue, Inguinal Adipose Tissue, Differentiation

10.5505/2017ichc.PP-54 [Stem cells]

Effect of peripheral blood mononuclear cell in experimental model skin flap

Pinar Kilicaslan Sonmez[1], Isil Aydemir[1], Mahmud Mustafa Ozkut[1], Yavuz Kececi[2], Mehmet Ibrahim Tuglu[1]

[1]Department of Histology and Embryology, Faculty of Medicine,Celal Bayar University, Manisa, Turkey

[2]Department of Plastic and Reconstructive Surgery, Faculty of Medicine,Celal Bayar University, Manisa, Turkey

The experimental skin flap model is a good example of wound healing and it is known that bone marrow stem cell derived peripheral blood mononuclear cells (PBMC), significantly improve skin flap viability and perfusion with vascular and cellular activity. Mesenchymal stem cell applications are becoming increasingly relevant in clinical use. As an alternative to these products requiring intervention and being processed in GMP laboratories, PBMCs are less laborious and cost effective that can be obtained quickly and effectively. In this study PBMCs were evaluated in terms of efficacy in comparison with adipose tissue stem cells in culture medium.

PBMCs obtained from the inguinal region were evaluated in terms of survival, vascularization and cell death by administration of adipose tissue mesenchymal stem cells and peripheral mononuclear cells to the flap-removed areas by allogeneic transplantation. Histopathological examination and immunohistochemical staining with VEGF, TGF-beta1 were performed to measure necrotic area, apoptotic index, vascularization and wound healing.

Both stem cells were similar in terms of isolation, characterization and proliferation in the culture conditions. Histopathologically examined necrotic area and immunohistochemical staining revealed similar apoptosis, vascularization and wound healing.

As a result of these findings, peripheral mononuclear stem cells were found to be as effective as mesenchymal stem cells originating from adipose tissue in terms of flap viability, vascularization and efficacy. It is also thought that these cells, which have not undergone a lot of processing in the culture medium, can be used for cost effective wound management.

Keywords: Flap, wound healing, peripheral blood mononuclear cell, mesenchymal stem cells, vascularization, apoptosis

10.5505/2017ichc.PP-55 [Stem cells]

The Effect of Brown Adipose Tissue Orginated Stem Cells on Wound Healing in Diabetic Rat Model

Busra Sen[1], Ezgi Balkarli[2], Pelin Toros[1], Ecem Topac[1], Fatih Collu[1], Pinar Kilicaslan Sonmez[1], Isil Aydemir[1], Ibrahim Tuglu[1]

[1]Department of Histology and Embryology, Celal Bayar University, Manisa, Turkey

[2]Medical Faculty, Celal Bayar University, Manisa, Turkey

The adipogenic stem cell is a product used for skin wound healing. It is thought that the stem cells obtained in diabetic rats are not sufficient for this healing. Brown adipose tissue stem cell is an important source that can be used as an alternative. In this study, brown adipose tissue mesenchymal stem cell from the interscapular region is compared with white adipose tissue mesenchymal stem cells from the inguinal region for wound healing before the diabetic model. The contribution of stem cells taken before diabetes and stem cells taken after diabetes are investigated for their to healing in the wound model. The morphological, morphometric, histological and immunohistochemical methods is investigated for apoptosis after 14 days of treatment by placing the stem cells under the flap in the wound healing model in which 5 treatments are used for each application. It is found that the stem cell taken before diabetic is more functional and more proliferated than the stem cell taken after diabetic and the difference between them is significant. When the underlying flap application of the stem cell without diabetes is examined, there is no significant difference between brown and white adipose tissue in the improvement of the wound after 14 days of treatment. VEGF expression that investigated for apoptosis and vascularization does not show any significant change. The problems arised in skin wound healing because of diabetes and stem cells seem to be useful for better care. There is no significant difference between brown and white adipose tissue stem cells in terms of the contribution to both in vitro and in vivo healing. It is thought that taking the stem cell in a healthy period and keeping it according to the standards may be a clinically important product that can provide wound healing and increase the patient's quality of life when needed.

Keywords: Wound healing, Diabetes, Stem cell

10.5505/2017ichc.PP-56 [Stem cells]

Differential expression of mtor signaling pathway proteins in lichen planopilaris and frontal fibrosing alopecia

Ozlem Dicle[1], Ciler Celik Ozenci[2], Pinar Sahin[2], Eva Katharina Barbosa Pfannes[3], Annika Vogt[3], Berna Nazlim Altinok[1], Ulrike Blume Peytavi[3]

[1]Department of Dermatology and Venereology, Akdeniz University School of Medicine, Antalya, TURKEY

[2]Department of Histology and Embryology, Akdeniz University School of Medicine, Antalya, TURKEY

[3]Department of Dermatology and Allergy, Clinical Research Center for Hair and Skin Science, Charité-Universitätsmedizin, Berlin, GERMANY

Differential expression of mtor signaling pathway proteins in lichen planopilaris and frontal fibrosing alopecia
Introduction & OBJECTIVE: Primary cicatricial alopecia (PCA) are inflammatory diseases involving progressive and permanent loss of hair where hair follicles are replaced with fibrous tissue as a direct result of inflammatory infiltration. Lichen planopilaris (LPP), the most frequent cause of PCA, is a rare scalp disease that is histopathologically characterized by perifollicular lymphohistiocytic inflammatory reaction. LPP is observed in three different clinical types: classic type, frontal fibrosing alopecia and the Graham-Little-Piccardi-Lassueur Syndrome. Mammalian target of rapamycin (mTOR) is a pathway that combines intra- and extra-cellular signals and acts as a central regulator for the metabolism, growth and proliferation of cells. Down regulation of mammalian target of rapamycin (mTOR) signaling pathway has a variety of effects on the immune system and stem cell proliferation. The aim of this study was to investigate the expression of mTOR pathway in lichen planopilaris (LPP) and frontal fibrosing alopecia (FFA).
Materials & METHODS: Thirteen biopsy specimen of clinically active affected scalp area of patients (8 LPP, 5 FFA) and as control group, biopsies from 9 patients undergoing surgical excisions of sebaceous cysts and 9 biopsies of clinically unaffected scalp area of patients were included in the study. Immunohistochemical evaluation by using a panel of antibodies including mTOR, phospho-mTOR (Ser2448), phospho-S6K, phospho-4EBP1 (Thr37146), and phospho-tuberin (T1462) were performed on all tissue samples.
RESULTS: mTOR, p-mTOR, p-p70S6K and p-4EBP1 expressions decreased in different layers of hair follicles at different levels when compared to control samples and unaffected skin of patients (Figure 1-4). In patients affected samples p-tuberin showed low or high expression at different layers of hair follicle when compared to control samples and unaffected skin of patients (Figure 5).
CONCLUSIONS: To our knowledge, we have shown for the first time mTOR signaling pathway protein expression in human scalp hair follicles. Our results suggest that components of the mTOR signaling pathway may be affected in classic LPP and FFA pathogenesis.

Keywords: mTOR signaling pathway, primary cicatricial alopecia, lichen planopilaris, frontal fibrosing alopecia, hair follicle, hair diseases

Figure 1

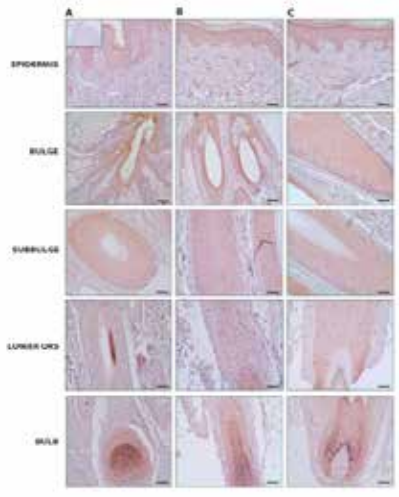

Evaluation of mTOR expression in histological sections of human hair follicles in controls and affected scalp of patients. (A: Control (healthy non-LPP subjects), B: control (healthy, clinically unaffected scalp of patients), C: Affected scalp of patients). Scale bar: 20µm.

Figure 2

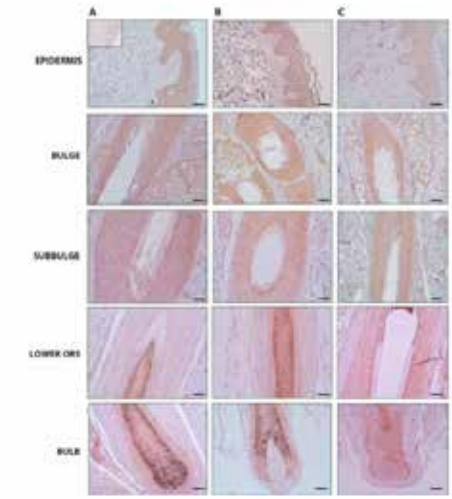

Evaluation of p-mTOR expression in histological sections of human hair follicles in controls and affected scalp of patients. (A: Control (healthy non-LPP subjects), B: control (healthy, clinically unaffected scalp of patients), C: Affected scalp of patients). Scale bar: 20µm.

Figure 3

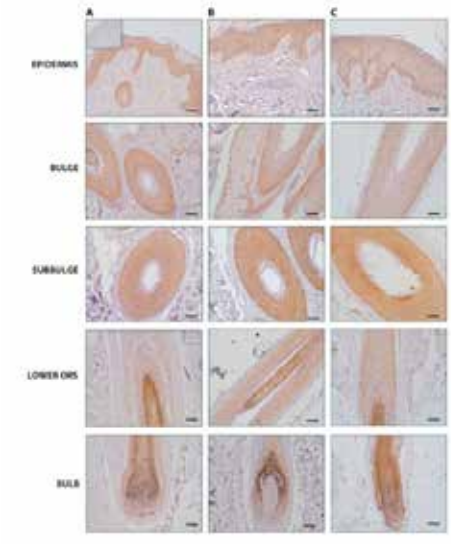

Evaluation of p-p70S6K expression in histological sections of human hair follicles in controls and affected scalp of patients. (A: Control (healthy non-LPP subjects), B: control (healthy, clinically unaffected scalp of patients), C: Affected scalp of patients). Scale bar: 20µm.

Figure 4

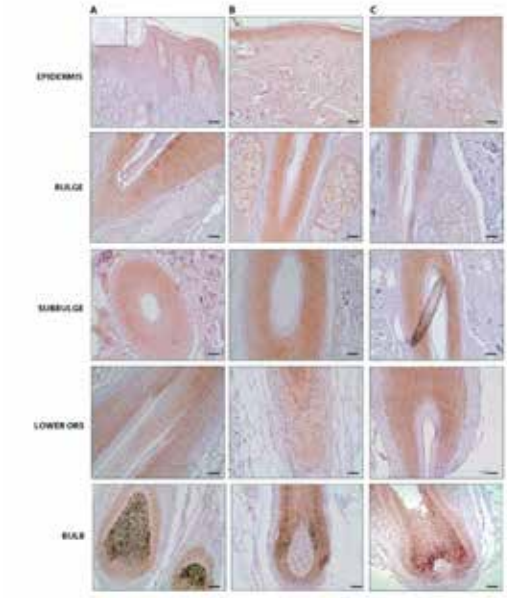

Evaluation of p-4EBP1 expression in histological sections of human hair follicles in controls and affected scalp of patients. (A: Control (healthy non-LPP subjects), B: control (healthy, clinically unaffected scalp of patients), C: Affected scalp of patients). Scale bar: 20µm.

Figure 5

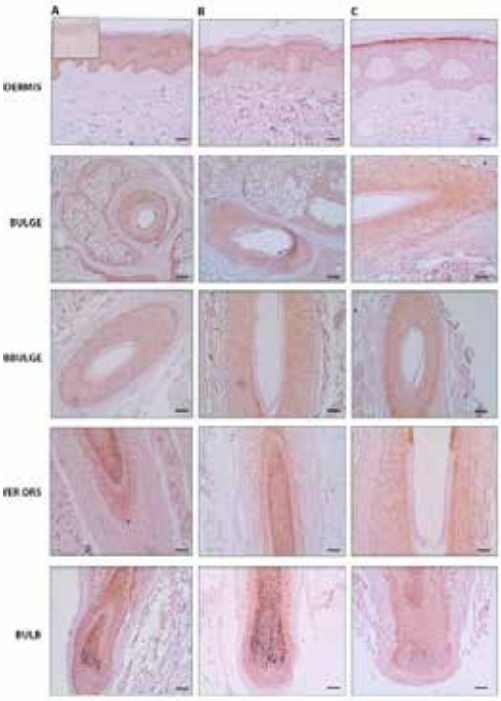

Evaluation of p-tuberin expression in histological sections of human hair follicles in controls and affected scalp of patients. (A: Control (healthy non-LPP subjects), B: control (healthy, clinically unaffected scalp of patients), C: Affected scalp of patients). Scale bar: 20µm.

10.5505/2017ichc.PP-57 [Stem cells]

Overview of Organoid Technology

Irem Inanç, Belgin Can
Department of Histology and Embryology, Ankara University Faculty of Medicine, Ankara, Turkey

Introduction& OBJECTIVES: An organoid is defined as a three dimensional (3D) structure, grown from stem and progenitor cells and consisting of organ-specific cell types, that selforganizes through cell sorting and spatially restricted lineage commitment. In recent years this technology has become very popular in many fields. In this study, we tried to summarize how organoid technology emerged and also we tried to emphasize the studies that contribute to this technology.
Materials& METHODS: Organoid technology is based on dissociation-reaggregation experiments. In 2009 Hans Clevers and colleagues constructed three-dimensional intestinal crypts and villi from isolated intestinal crypts and single Lgr5 (leucine-rich-repeat-containing G-protein-coupled receptor 5) cells. They used a medium containing matrigel and suitable factors for the development of crypts. These 3D structures showed a similar structure to the in vivo conditions. They composed of enterocytes, goblet, Paneth, enteroendocrine, and stem cells. In 2011, Sasai and colleagues generated 3D self-organizing optic-cup from mouse embryonic stem cells. In 2013 Madeline Lancester, Jurgen Knoblich and colleagues generated cerebral organoids from human pluripotent stem cell agregrates. In that study, researchers used organoids for modeling microcephaly from microcephaly patient skin biopsy. In 2013 Huch and her colleagues isolate Lgr5+ cells from bile ducts after liver damage and they generated hepatic organoids which displayed hepatocyte functions under in vitro conditions. In 2013 organoid technology applied to study primary intestinal organoids of people suffering from cystic fibrosis. In 2016 researchers generated human cerebral organoids expanded in size and display surface folding with PTEN (Phosphatase and tensin homolog) mutant gene. In 2016 Gabriel and colleagues showed that Zika strains efficiently infect neural progenitors in human brain organoids and cause premature differentiation in a way that closely resembles Zika-associated microcephaly.
RESULTS: Organoid research holds considerable potential for investigating human development and disease processes. With organoid technology, organs and various diseases can be modeled under in vitro conditions.
CONCLUSIONS: Organoids grown from stem cells and they display the three-dimensional architecture and physiology of intact organs. They offer unique possibilities for modeling and studying normal development and disease processes. Future applications could include tissue replacement therapy and organoid biobanking.

Keywords: organoid technology, organoids, stem cells

10.5505/2017ichc.PP-58 [Stem cells]

A Novel Isolation Method for Rat Brain Pericytes and Their Characterization

Ayşegül, Açıksarı[1], Gizem Turaç[2], Selen Polat[2], Gokhan Duruksu[1], Gülçin Gacar[1], Gülay Erman[2], Yusufhan Yazır[1]

[1]Center for Stem Cell and Gene Therapies Research and Application, Kocaeli University, Kocaeli, Turkey

[2]Department of Stem Cells, Kocaeli University, Kocaeli, Turkey

Introduction & Objectives. The blood-brain-barrier is ultra-structurally assembled by a monolayer of brain microvascular endothelial cells interconnected by junctional-complex. Astrocytes and pericytes regulate the transition of fluids, molecules and cells between the blood and the central-nervous-system. Pericytes are periendothelial vascular mural cells that form incomplete layer on the surface of capillary endothelial cells and both cell types are surrounded by the basal lamina. They have an important role in angiogenesis, and are considered as a potential reservoir for stem cells in tissue regeneration. These cells can be identified by their expression of PDGFRβ and NG2, in addition to the mesenchymal stem cell markers. Usually, pericytes were isolated from brain and retina tissues, which are rich in capillaries.
Materials & Methods. Pericyte isolation was performed by mechanical and enzymatic methods from young Wistar rat brain. The olfactory bulb, cerebellum, and medulla were dissected and the rest of the brain was minced. The tissues were digested with Collagenase, and following the washing, they were incubated in the Collagenase/Dispase solution. The resuspended cells were separated by Ficoll solution. The cells in the interphase were washed and cultured on collagen coated flasks in ECGM with 1% antibiotics and 2% FBS. The medium was refreshed twice a week. Upon reaching of 70-80% confluency, the cells were treated with trypsin and replated at the ratio of 1:3. The immunofluorescence staining for the pericyte markers NG2, α-SMA, CD146 and PDGFRβ was performed for characterization. GFAP was used as distinguishing markers of these cells from astrocytes.
Results. The isolated cells demonstrated typical pericyte-characteristics. On the second day, the cells were diffused and moved away from the tissue fragments and formed colonies. The heterogeneity of isolated cells in primary culture was disappeared in next passages. The cells were stained positive for the pericyte markers NG2, α-SMA, CD146 and PDGFRβ, and negative for GFAP.
Conclusions. In this study, pericytes were successfully isolated from rat brain tissue. The expression of pericyte markers was shown by immunofluorescence staining. In conclusion, we developed an alternative approach for high pure pericyte isolation and easy to practice method to their culture.

Keywords: blood brain barrier, cell isolation, pericytes, stem cells

10.5505/2017ichc.PP-59 [Structure and function of the cell]

Exogenous Melatonin Induces Histochemical Changes in the Duodenum of Diabetic Rats

Eda Duygu Ipek, Hulki Başaloğlu
Department of Anatomy, Adnan Menderes University Faculty of Medicine, Aydın, Turkey

Background and AIMS: Diabetes mellitus affects all organs and systems including the gastrointestinal tract, which plays a role in insulin secretion. Considering that the effects of melatonin on glucose homeostasis, and its antioxidant capacity, the aim of the present study was to investigate of the effects of melatonin on duodenum histochemistry in streptozotocin (STZ) induced diabetic rats.
METHODS: Thirty-two male Wistar Albino rats were distributed into the four groups of eight rats each; untreated diabetic rats (group D), diabetic rats treated with melatonin (group DM), nondiabetic rats treated with melatonin (group M), and control group (group C). Diabetes was induced by a single injection of STZ, 60 mg/kg of body weight, intraperitoneal (i.p.) in D and DM groups. Then, the rats in group M and DM began to receive 10 mg/kg i.p. dose of melatonin and the rats in group C began to receive physiological saline i.p. every day for six weeks. At the end of the six weeks, the animals were euthanized and the duodenum tissue samples were collected. Following routine histological procedure, Alcian blue (AB), Periodic acid Schiff (PAS) and AB/PAS stained slides were examined under a light microscope. Data were analyzed with SPSS version 21 program.
RESULTS: In groups D and DM, severity of PAS reaction was found to be weaker than the other groups, K and M. Furthermore, diabetic tissue samples were positively stained pink, while others were stained violet with PAS. In AB/PAS stained sections goblet cells were stained blue and their secretion characteristics were found to be more acidic in group D than others. Accordingly, the amount of acidic mucous substance into the lumen was higher in group D, compared to others.
CONCLUSION: Our data suggest that melatonin has an important role in mucous secretion characteristics and tissue histochemical properties of the duodenal tissue. Thus, it is possible that the duodenum as a target organ has an important role in the regulation of insulin release from human pancreatic islets. providing an explanation for severe gastrointestinal problems in diabetic patients.

Keywords: duodenum, experimental diabetes, melatonin, streptozotocin

Acidic mucous

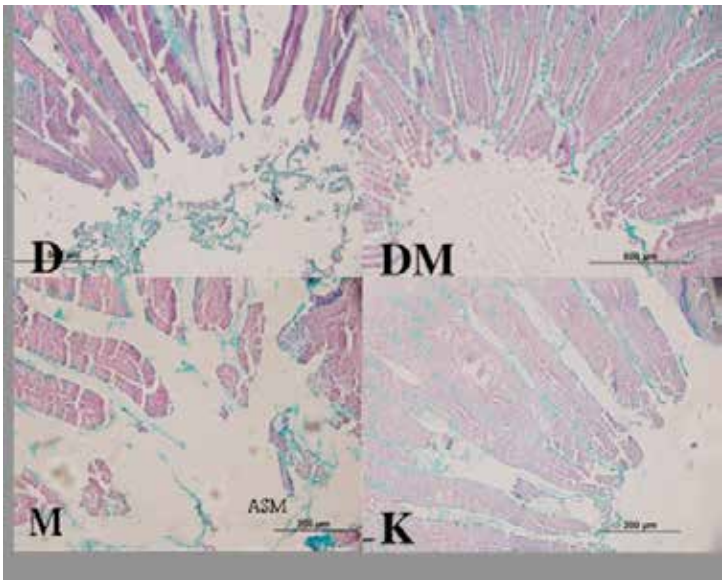

Amount of acidic mucous into the lumen

Mucous secretion characteristics

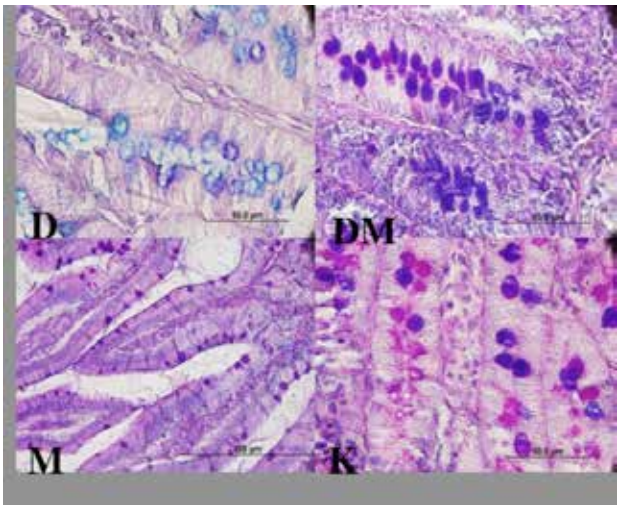

Mucous secretion characteristics

PAS reaction

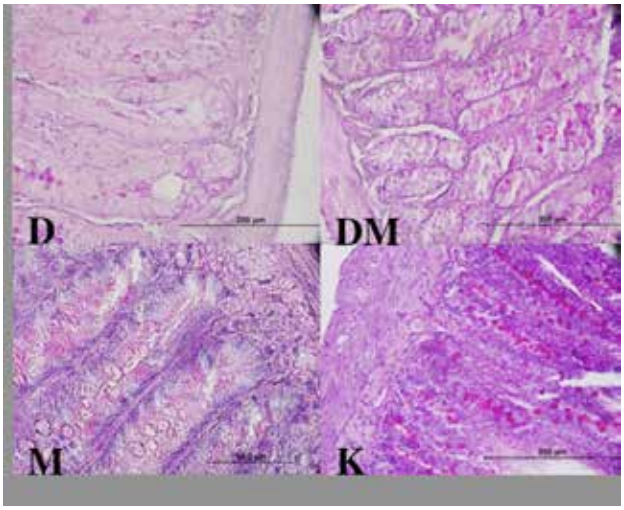

PAS reaction severity of the crypt

PAS reaction

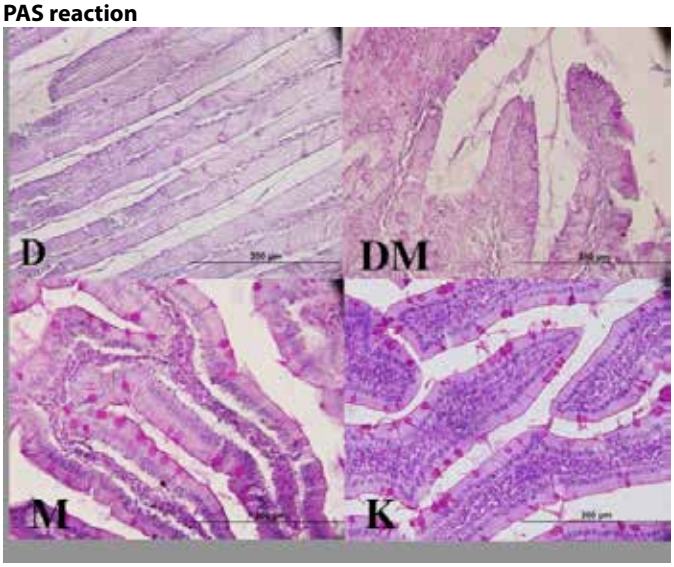

PAS reaction severity of the villi

10.5505/2017ichc.PP-60 [Structure and function of the cell]

Effects of curcumin on renal tubular cell apoptosis and related pathways in cisplatin-induced nephrotoxicity

Yeter Topcu Tarladacalisir[1], Melike Sapmaz Metin[2], Turan Karaca[1]

[1]Department of Histology-Embryology, Trakya University, Edirne, Turkey

[2]Health Services and Vocational Collage, Trakya University, Edirne, Turkey

Nephrotoxicity is the most important dose limiting side effect which is frequently encountered in the cisplatin chemotherapy. The aims of this study are determination of the protective effects of curcumin on cisplatin-induced renal tubular cell apoptosis and related pathways in kidney.
Eighteen male Wistar albino rats will use in this study. Animals were randomly divided into three groups (n = 6); the control, cisplatin (CP), cisplatin+curcumin (CP+CUR). Acut renal damage was induced by single dose of cisplatin (7,5 mg/kg) injected by intraperitoneally (i.p). The animals of curcumin treated group were received daily 200 mg/kg curcumin per os (p.o), starting from 2 days before the injection of cisplatin to the day of sacrifice. Fourty eight hours after cisplatin injection, samples of cardiac blood and right and left kidneys were harvested from the animals. In the present study, the major findings in the kidney of cisplatin injected rats are that the treatment of curcumin reduces (1) the development of kidney injury (histologically), (2) inflammatory resptonses (Myeloperoksidase (MPO) and Tumor necrosis factor-alpha (TNF-α), Interleukin-1β (IL-1β), Interleukin-6 (IL-6), Interleukin-10 (IL-10) levels), (3) the degree of lipid peroxidation (Malondialdehyde (MDA) level), (4) renal tubule cells apoptosis (terminal deoxynucleotidyl transferase –mediated deoxyuridine triphosphate in situ nick end-labelling (TUNEL) and active caspase-3 immunostaining) and expression of related proteins (p53, Fas ve Fas ligand (FasL) immunostaining), 5) activation of mitogen-activated protein kinases (MAPK) signaling pathway (p38 ve c-Jun NH2 terminal kinase (JNK)) by immunohistochemistry and 6) renal dysfunction (serum urea and creatinine).
In a conclusion, this study suggest that curcumin may contribute in protection against cisplatin nephrotoxicity by its antiapoptotic effects, in additin to antiinflamatuar and antioxidant properties.

Keywords: Cisplatin, nephrotoxicity, curcumin, apoptosis, rat

10.5505/2017ichc.PP-61 [Structure and function of the cell]

Regulation of Collagen-I by NF-kB on diabetic rat cutaneous wound model

Fatma Kübra Tombultürk[1,2], Matem Tunçdemir[1], Gönül Kanıgür[1]

[1]Department of Medical Biology, Cerrahpasa Medical Faculty, Istanbul University, Istanbul, Turkey

[2]Medical Laboratory Techniques, Vocational School of Health Services, Istinye University, Istanbul, Turkey

INTRODUCTION&OBJECTIVES: Late or inadequate wound healing is are serious clinical problem for patients with diabetes nowadays. The NF-kB gene is activated during the healing process. Which in turn may play a detrimental role on wound tissue remodelling and regeneration. NF-kB is also known to stimulate the production of collagen. During the wound healing process, the imbalance of collagen synthesis and degradation resulting in excess accumulation of dermal collagen can lead to the scar complications. Expression of the collagen-I gene increases remarkably at later periods of in vivo wound healing and is proportional to that of the NF-kB gene.This study aimed that investigated molecular mechanism of wound healing in Streptozotocin(STZ)-induced diabetic rats and non-diabetic rats.
MATERIALS&METHODS: For this purpose, full–thickness skin wounds were created on the backs of STZ-induced diabetic rats(60mg/kg,ip,single dose) and the control group by using wistar albino rats. We followed three full-thickness excisional wound models on the rats for 14 days.We take the biopsy wound after 0,3,7 and 14 days were injured, and than we examined NF-kB activation by ELISA, the amount of collagen-I with immunohistochemical staining.
RESULTS: In the control group; NF-kB activity decreased at day 7 and 14, although it showed a linear increase at day 3.In the diabetics,NF-kB activity, which increased linearly at days 0,3 and 7, decreased at day 14. Increased NF-kB activity on day 0 compared to control in diabetic group can be explained by hyperglycemia. In the controls and diabetics, the amount of collagen-I increases linearly from day 0 to 14.But the increase in collagen-I expression in the control was higher than in the diabetic group.NF-kB activity was also increased in diabetic wounds compare to the control.
CONCLUSIONS: The results indicated that diabetes may deteriorate the process of wound healing by influencing phases such as inflammation,NF-kB activity,collagen synthesis and wound contraction. Consequently extracellular matrix was found to create more quickly in nondiabetic wounds.These findings may provide new insight for understanding of molecular mechanism in wound healing in diabetics and non-diabetics.

REFERENCES:
1- T.J.Wess.Adv.Chem.2005;70:341-374.
2- G.P.Sidgwick.Eur.Acad.Dermatol.Venereol.2012;26:141-152.
3- J.B.Tang,et al.Hand Surg.2004; 29A:564-70.

The present work was supported by the Research Fund of Istanbul University.Project No.35048

Keywords: Nuclear factor kappa-B, Collagen, STZ diabetes, Wound healing

Figure 1: Immunoreactivity of Collagen-I.

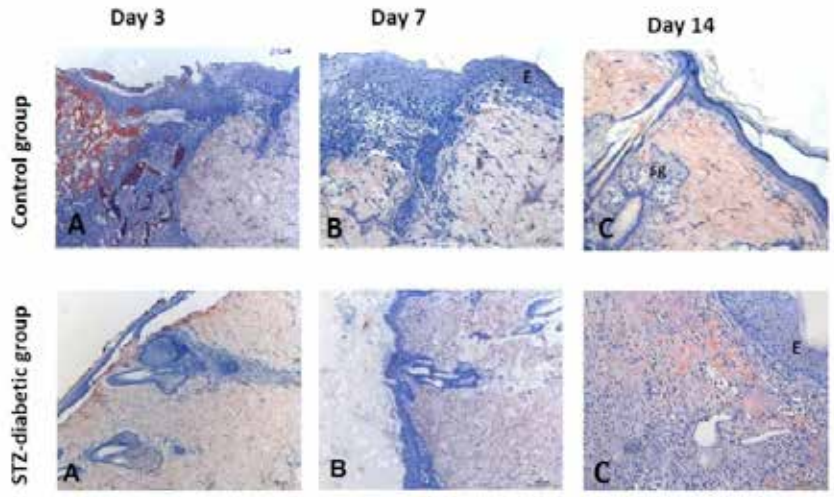

Expression of collagen I in wound healing process on days 3 (A), 7 (B), 14 (C) by immunohistochemical analysis. E: Epidermis; sg: Sebaceous gland; hy: hypodermis; <: St.Granulosum; sw: sweat gland.

Figure 2: NF-kB activity in the skin wound healing of non-diabetic control and STZ-diabetic groups according to days.

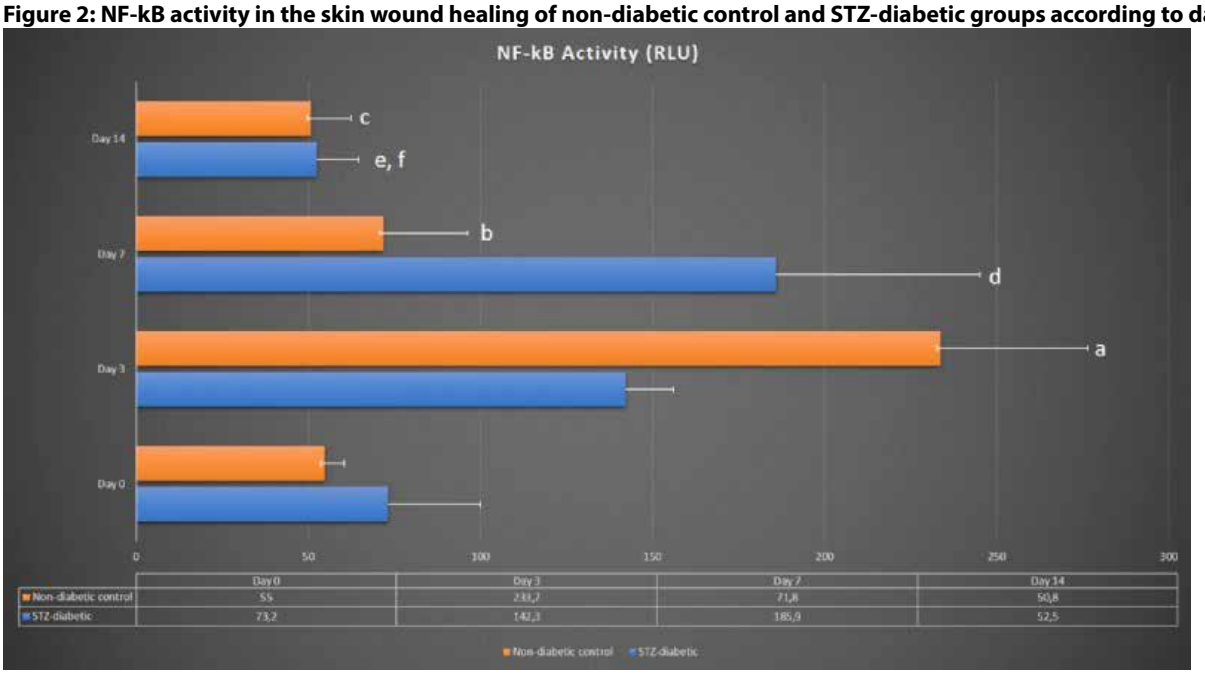

Data are given as mean±SD. Non-diabetic control and STZ-diabetic groups. a P<0.001 vs. day 0, b P<0.001 vs. day 3, c P<0.001 vs. day 3, d P<0.01 vs. day 0, e P<0.05 vs. day 3, f P<0.001 vs. day 7.

Figure 3: Collagen-I expressions in the skin wound healing of non-diabetic control and STZ-diabetic groups according to days.

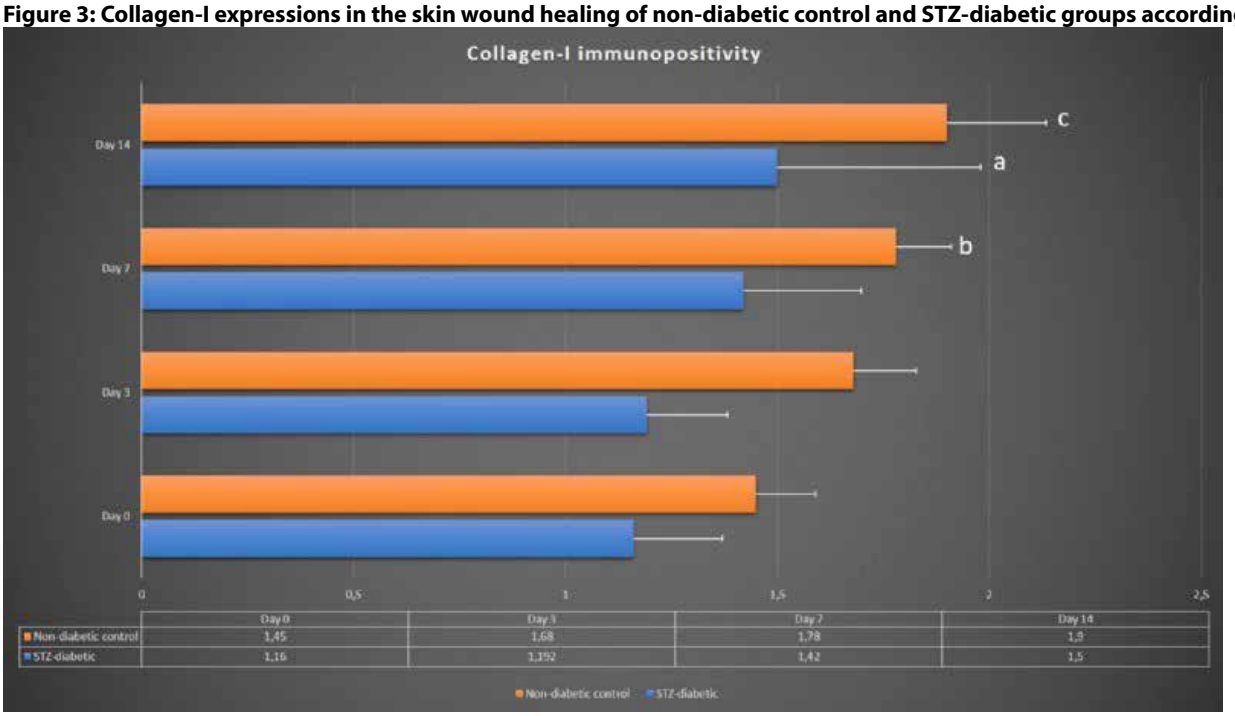

Data are given as mean±SD. a P<0,05 vs day 0, b P<0,05 vs day 0, c P<0,01 vs day 0.

10.5505/2017ichc.PP-62 [Structure and function of the cell]

Potential difficulties in transmission electron microscope observations of respiratory cilia axonemal complex

Oya Evirgen, Esra Erdemli, Emine Nazli Hayirli, Derya Ozdemir
Department of Histology and Embryology, Ankara University School of Medicine, Ankara, Turkey

OBJECTIVES: Primary ciliary dyskinesia(PCD) is a rare and genetically heterogenous group of recessive disorders with various ultrastructural defects of axonem and impaired ciliary motility resulting in chronic upper and lower respiratory tract disease, fertility problems and organ laterality defects. Transmission electron microscopic (TEM) analysis of cilia is still an important part of diagnosis and optimal fixation, processing and sectioning of the biopsies are neccessary to study the internal axonemal structure of cilia. In this study we try to check up the sample preperation and sectioning steps performed in our TEM laboratory.
MATERIALS-METHODS: Biopsies were obtained from either bronchial or nasal mucosa. The removed tissue sample and the pellet of lavage solution after centrifugation were resuspend and fixed in fresh 2,5% glutaraldehyde and processed as usual for ultrastructural analysis. The semi-thin sections stained with toluidine blue examined under light microscopy. After staining with uranyl acetate/lead citrate the different thickness of (85nm,100nm) ultra-thin sections were observed under LEO 906 E transmission electron microscope.
RESULTS: In semi-thin sections of nasal and bronchial biopsies showed normal ciliated respiratory epithelial cells and goblet cells. And some of semi-thin sections ciliated epithelial cells can not be observed. The ultra-thin sections showed transverse, oblique and longitudinal sections of cilia. Most of them have normal axonemal pattern with 9+2 configuration while in a few cilia showed microtubular disorganization.
CONCLUSION: TEM is often a useful tool in defining the ultrastructural defects of axonem and has been used for the diagnosis of PCD. But it can not be helpful to identify the PCD variants with normal ultrastructure. So recently new methods for diagnosis such as immunofluorescence analysis has been used to investigate the subcellular localization of the ciliary proteins. For TEM examination the biopsy site(nasal or bronchial), experience of clinician performing biopsy and accurate patient selection is important for a feasible ultrastructural analysis. Also an optimal specimen processing steps, achivement of sufficient number of high quality transverse sections of cilia is very important to study the internal axonemal structure of respiratory cilia.

Keywords: TEM, Respiratory cilia, Axonem ultrastructure

10.5505/2017ichc.PP-63 [Structure and function of the cell]

Dehp induced oxidative alterations in relation to DNA damage and proliferation in the rat liver

Melike Sapmaz Metin[1], Kıymet Tabakçıoğlu[2], Yeter Topcu Tarladacalisir[3], Yesim Hülya Uz[3], Imran Kurt Omurlu[4], Deniz Muratoglu[2]

[1]Health Services and Vocational College, Trakya University, 22030 Edirne, Turkey.

[2]Department of Medical Biology, Faculty of Medicine, Trakya University, 22030 Edirne, Turkey.

[3]Department of Histology and Embryology, Faculty of Medicine, Trakya University, 22030 Edirne, Turkey.

[4]Department of Biostatistics, Faculty of Medicine, Adnan Menderes University, Aydın

OBJECTIVES: Di-(2-ethylhexyl) phthalate (DEHP) is the most commonly used plasticizer in a variety of consuming products including PVC, toys, cosmetics, and pharmaceuticals. It is proposed that DEHP and certain phthalates may cause hepatocellular cancer by an oxidative damage-mediated mechanism(s). Therefore, the aim of the present study was evaluate the oxidative damage in the liver DNA and tissue related to DEHP exposure of the prepubertal, adult and ovariectomized rats.
Materials&METHODS: Prepubertal, adult and ovariectomized animals divided into three sets; first set from prepubertal, 21 days old female rats, the second set from sexually mature, virgin female rats and the third set from ovariectomized animals (Trakya University, Animal Care and Research Unit, Edirne, Turkey). Each set has a group received 1000mg/kg DEHP by gavage (10 consecutive days), and it's corresponding control group. At the end of the experiment cardiac blood and liver tissues were harvested. Paraffin inclusion was applied to the liver samples and hematoxylin and eosin staining was performed. Liver proliferation index was shown by proliferating cell nuclear antigen (PCNA) immunostaining and DNA oxidation analysed by Oxoguanine DNA glycosylase (OGG1) immunoreactivity. Real time-PCR analysis used was to measure the PCNA and OGG1levels in a basis of RNA. Also liver tissue malondialdehyde level were measured.
RESULTS: Cytoplasmic vacuolisation in the hepatocyte, sinusoidal dilatation and Kuppfer cell activation in the liver parenchyma were detected in the all DEHP exposed animals, markedly in intact adult rats. We showed increases in the levels of OGG1 by immunostaining and by PCR analysis of prepubertal group following DEHP exposure, as compared to adult groups. DEHP exposure increased the liver weights and PCNA indices in all groups. However, PCNA indices of the prepubertal DEHP groups were significantly higher than both of the adult groups. DEHP also increased liver tissue oxidation measured by malondialdehyde levels in all experimental groups.
DISCUSSION: DEHP caused liver damage in the different levels in prepubertal, adult and ovariectomized female rats. As prepubertal group showed the higher OGG1 and PCNA levels as well as tissue damage, we suggest that prepubertal period may be a primary target to DEHP liver.

Keywords: di-(2-ethylhexyl) phthalate (DEHP), liver, OGG, PCNA, rat

10.5505/2017ichc.PP-64 [Structure and function of the cell]

OPG and RANKL expression in different age groups of female rat femurs

Gizem Söyler, Cemre Nur Balcı, Hande Yılmaz, Tülin Fırat, Aysel Kükner
Department of Histology and Embryology, Abant Izzet Baysal University, Bolu, Turkey

INTRODUCTION: Osteoprotegerin (OPG) is a glycoprotein and a member of Tumour Necrosis Factor Alpha (TNF-α) family and synthesized from bone marrow cells and osteoblasts. OPG takes an active role on bone formation and destruction (1, 2).
Receptor Activator of Nuclear Factor Kappa-B Ligand (RANKL) is a member of TNF ligand family and synthesized from osteoblasts and bone stromal cells. RANKL involves osteoclast activation and bone destruction (3). RANKL binding to the RANK is inhibited by OPG, so osteoclast activation and bone destruption is blocked by OPG (4).
Aim of the study is observing OPG and RANKL expression under the light microscope in different age groups of female rat femurs.
METHOD: Wistar albino rats were used for this study. Five groups consisting of six individuals were identified according to the age as 1, 2, 8, 15, 24 months. All groups of individuals were selected randomly. Animals were anesthesized with xylasine and ketamine and femurs were removed into neutral formaline. To avoid differences in results, reproductive 2, 8, and 15 months animals were anesthesized in their proestrous cycle detected by vaginal smear.
Collected femurs were decalcified with 10% formic acid and tissues were embedded into the parafine blocks by routine histologic procedure. Paraffine sections were taken in 5µm.
Hematoxylene and eosin staining were made for identifing general structure of the tissues. To observe OPG and RANKL activation immunohistochemical procedure was followed. Evaluation was made under the light microscope.
RESULTS: Hematoxylene and eosin staining didn't show any structural difference between the groups. Immunohistochemical stained OPG and RANKL showed significant differences between the groups.
References:
1. Li Q and Verma IM. NF-κB regulation in the immun system. Nature Reviews, 2002; 2: 725- 735
2. Tsuda E, et al. Isolation of a novel cytokine from human fibroblasts that specifically inhibits osteoclastogenesis. Biochem Biophys Res Commun, 1997; 234: 137-142
3. Boyce BF, et al. Osteoprotegerin. the bone protector. is a surprising target for betacatenin signaling. Cell Metabolism, 2005; 2: 344-345
4. Theoleyre S, et al. The molecular triad OPG/RANK/RANKL: involvement in the orchestration of pathophysiological bone remodeling. Cytokine & Growth Factor Reviews, 2004; 15: 457-475
This study is supported by Abant Izzet Baysal University, Scientific Research Projects. Project No.: 2016.08.03.1080

Keywords: OPG, RANKL, Female rat, Femur

H&E 20x

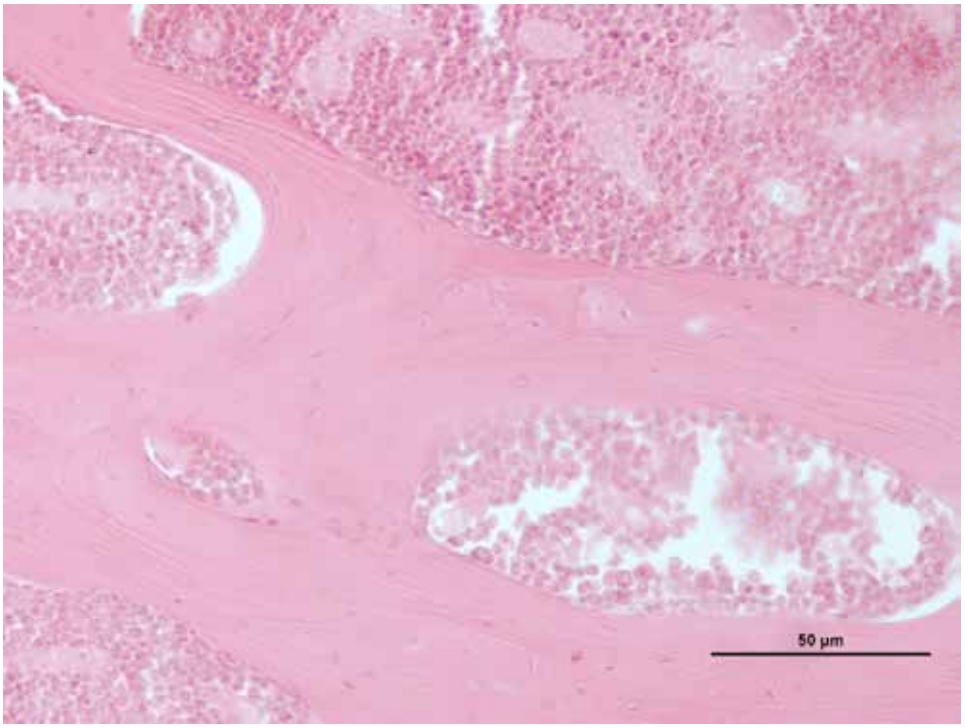

Hematoxylin and eosin staining (20X).

H&E 40x

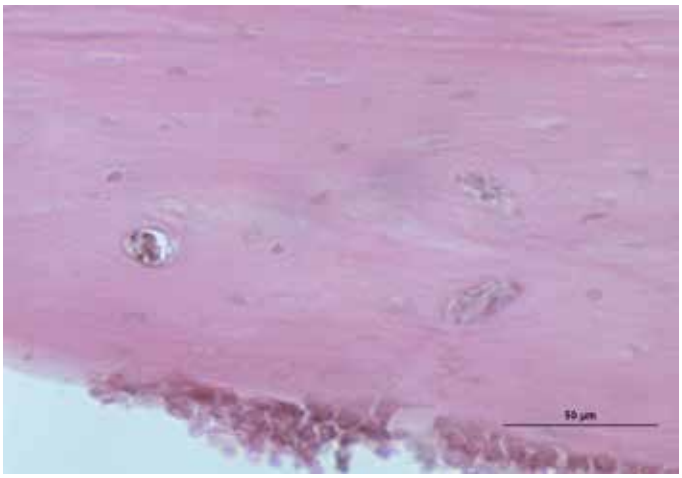

Hematoxylin and eosin staining (40X).

OPG 20x

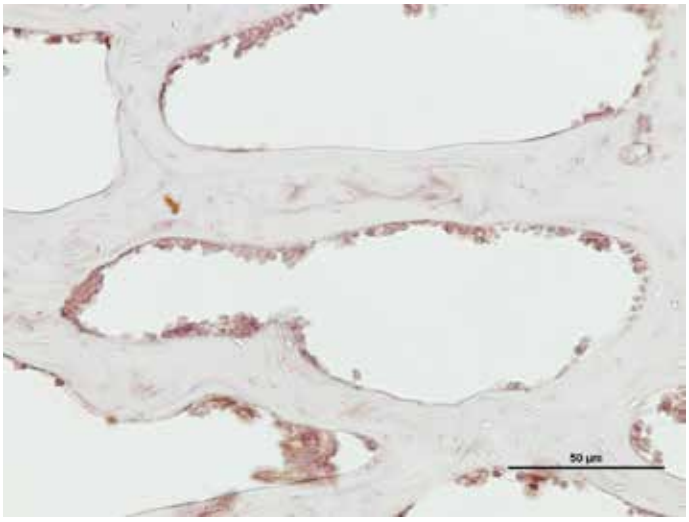

Immunohistochemical staining of 15 month rat femur to determine OPG expression of osteoblast cells (20X).

OPG 40x

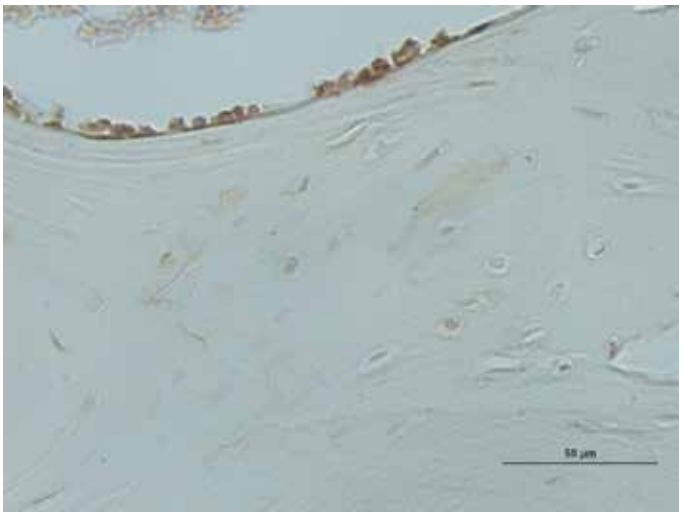

Immunohistochemical staining of 8 month rat femur to determine OPG expression of osteoblast cells (40X).

RANKL 20x

Immunohistochemical staining of 1 month rat femur to determine RANKL expression of osteoblast cells (20X).

RANKL 40x

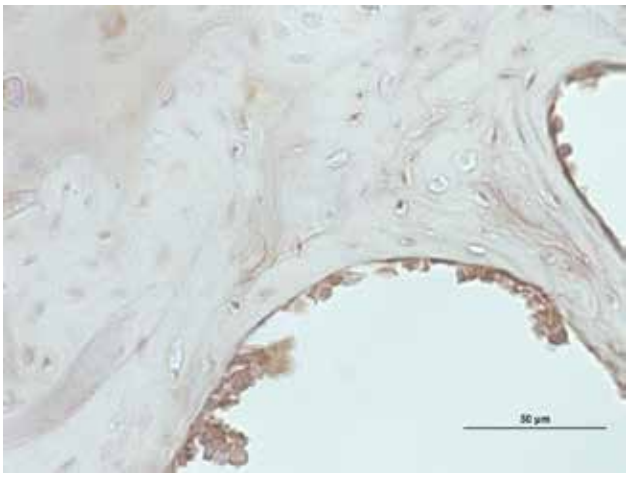

Immunohistochemical staining of 15 month rat femur to determine RANKL expression of osteoblast cells (40X).

OPG

OPG	1. Month	2. Month	8. Month	15. Month	24. Month
1. Month		1	0,01*	0*	0*
2. Month	1		0,01*	0*	0*
8. Month	0,01*	0,01*		0,5	0,01*
15. Month	0*	0*	0,5		0,08
24. Month	0*	0*	0,01*	0,08	

Correlation of OPG expression between the groups. p<0,05 is the significant level.

RANKL

RANKL	1. Month	2. Month	8. Month	15. Month	24. Month
1. Month		0,96	0*	0*	0*
2. Month	0,96		0,01*	0*	0*
8. Month	0*	0,01*		0*	0*
15. Month	0*	0*	0*		0*
24. Month	0*	0*	0*	0*	

Correlation of RANKL expression between the groups. p<0,05 is the significant level.

10.5505/2017ichc.PP-65 [Structure and function of the cell]

Immunolocalization of some immune cells in bursa of Fabricius of chukar partridge (Alectoris chukar)

Mehmet Erdem Akbalik[1], Serkan Erdogan[2], Berna Guney Saruhan[1], Hakan Sagsoz[1], Ugur Topaloglu[1]

[1]Department of Histology and Embryology, Faculty of Veterinary Medicine, Dicle University, Diyarbakır, Turkey

[2]Department of Anatomy, Faculty of Veterinary Medicine, Namık Kemal University, Tekirdağ, Turkey

Introduction & OBJECTIVES: The bursa of Fabricius is a lymphoepithelial organ that is found only in birds and this organ is necessary for B cell development. In this process, the cells acquire the necessary receptor property to recognize antigen, major histocompatibility complex and adhesion molecules. The goal of this study is to examine the localization and distribution of CD8, CD68, MHC-I and II positive cells in bursa of Fabricius of partridge.
Materials & METHODS: Ten healthy adult chukar partridges, 5 of which were female (360-420 g) and 5 were male (480-540 g), constituted the material of the study. Tissue samples taken from the bursa of Fabricius were fixed in formol-alcohol solution 18h, and followed routine histological processing, then were subjected to immunohistochemical staining methods.
RESULTS: It was revealed that CD8, CD68, MHC-I and II-positive cells were mainly localized in lamina propria and lymph follicles. Besides, no immunoreactivity was observed in the muscle layer.
CONCLUSIONS: It was suggested that expression of these factors play a role in immune response to provide benefit for immunological studies in avian species.

Keywords: Immunolocalization, immune cell, bursa of Fabricius

10.5505/2017ichc.PP-66 [Structure and function of the cell]

Diabetes asociated neuropathy in peripheral nerves which innervate leg muscles: An immunohistochemical study performed using histomorphometry and S100

Suna Ömeroğlu[1], Nadir Gülekon[1], Tuncay Peker[2], Suna Ömeroğlu[3], Feza Anıl[4]

Deterioration of the structure and function of peripheral nerves is referred to as Peripheral Neuropathy. The major cause of Peripheral Neuropathy is Diabetes Mellitus. The underlying pathology in Diabetes Mellitus is high blood glucose level and irreversible impairments in several systems, peripheral nerves in particular. MATERIAL-METHOD: Wistar Albino rats with a weight of 200 ± 20 gr were assigned to two groups in the study. 45mg/kg streptozotocin with a citrate buffer was intraperitoneally injected to the experimental group rats to induce diabetes. At the end of the 22-day period, leg muscles of rats were dissected after measuring their fasting blood sugar level. A significant difference was found using the Sihler's straining technique between the control group and the diabetes group in terms of the diameter of first major branch of tibialis caudalis and tibialis cranialis. Comparing minor branches in flexor digitorum longus, it was observed that the number of minor branches was higher in the control group compared to the diabetes group. It was detected that peripheral nerve axons innervating all parts of the leg lost their integrity in the diabetes group and vacualizations occurred in some axons, which implies hydropic degeneration. Also, thickening was observed in perineuriums of peripheral nerves.

Keywords: S100, Neuropathy, Peripheral Nerve, Perineurium, Diabetes Mellitus

10.5505/2017ichc.PP-67 [Structure and function of the cell]

Immunohistochemical detection of leptin, ghrelin and obestatin in the intestine of chukar partridge (Alectoris chukar)

Mehmet Erdem Akbalik[1], Hakan Sagsoz[1], Berna Guney Saruhan[1], Serkan Erdogan[2], Muzaffer Aydin Ketani[1]

[1]Deparment of Histology and Embryology, Faculty of Veterinary Medicine, Dicle University, Diyarbakir, Turkey

[2]Deparment of Anatomy, Faculty of Veterinary Medicine, Namik Kemal University, Tekirdag, Turkey

Introduction & OBJECTIVES: Leptin is a hormone that is mainly produced by the adipose tissue but ghrelin and obestatin have been isolated fundamentally from the stomach. These hormones are also synthesized in many other tissues, including gastrointestinal tract, placenta, skeletal muscle, and mammary epithelium, thus suggesting a wider role of these proteins. So the aim of this study was to evaluate the distribution of leptin, ghrelin and obestatin producing cells in the intestine of chukar partridge.
Materials & METHODS: The intestines of 10 adult chukar partridge (5 male and 5 female) was examined on the level of light microscope by using immunohistochemical methods. Tissues were fixed in formol-alcohol for 18h, dehydrated, cleared and then embedded in paraplast. Serial sections of 5 µm thickness were obtained from each parafin block and three slides were prepared from each sample.
RESULTS: Leptin, ghrelin and obestatin immunoreactivity were observed in the epithelial, some stromal and smooth muscle cells in the small and large intestine regions. Besides, endothelial cells of blood vessels showed moderate immunoreactivity for leptin. However, immunostaining for Ghrelin was prominently detected in the smooth muscle cells of the small and large intestine. Interestingly, some immunopositive cells for obestatin and ghrelin were seen in the epithelium.
CONCLUSIONS: The present study revealed a difference in the distribution of leptin, ghrelin and obestatin in the intestine. These findings indicate that leptin, ghrelin and obestatin may play a physiological role in the regulation of gastrointestinal functions.

Keywords: Leptin, ghrelin, obestatin, immunohistochemistry, intestine, partridge

10.5505/2017ichc.PP-68 [Structure and function of the cell]

A structural study of functional cells in hepatopancreas in *Maja squinado* (Herbst, 1788) (Decapoda, Brachyura)

Yasemin Aydin, Sezen Erdogan, Melike Erkan
Department of Biology, Istanbul University, Istanbul,Turkey

In the present study, histological structure of the hepatopancreas of *Maja squinado* (Herbst, 1788) (Decapoda, Brachyura) was examined. The samples were collected in the Dardanelles between March-April 2015. The samples collected were prepared for light microscopic examinations and stained by the histological stains (Hematoxylin-Eosin, Periodic Asit Schiff, Masson›s trichrome stain, Bromephenol blue, Alcian blue, Best carmine). Hepaotopancreas of *Maja squinado* is Brown-yellowish is a great organ with two lobes. The hepatopancreas located between most of the dorsal region of the cephalothorax and pyloric region of foregut. Two lobes the right and left of hepatopancreas are very close and these lobes are connected by a thin connective tissue. Right and left lobes are connected to primary duct. Primary ducts branch secondary ducts and secondary duct branches into hepatopancreatic tubules. The hepatopancreatic tubules of *Maja squinado* are composed of pseudostratified epithelium and each hepatopancreatic tubule consists of different cell types, which include the Embryonic (E), Fibrillar (F), Resorptive (R), Blister-like (B) and Midget (M) cells. E cells, which give the other hepatopancreatic cells, are cylindrical and have round nucleus that situated close to the basal. Also, E cells have brush border differently from other decapods. Synthesis of digestive enzymes takes place in the F cells. F cells are distinguished by triangular shape and basophilic cytoplasm. R cells, which stores lipid and glycogen, are cylindrically shaped and have characteristic sub-apical vacuoles. B cells which intracellular digestion is distinguished the other cells by one big digestion vacuole which stains with PAS, Bromephenol blue, alcian blue. The hepatopancreas of most Decapods does not have M cell, whereas differ from the other decapods the hepatopancreas of *Maja squinado* has M cell. Also, there are no brush border in M cells, which only the cell type that not reach the lumen.

Keywords: Hepatopancreas, {Maja squinado}, Decapoda, Histology, Histochemistry

10.5505/2017ichc.PP-69 [Structure and function of the cell]

Serum Prolidase Activity and Oxidative Status in Lung Cancer Cell Line (A549)

Hasan Dağli[1], Metin Kilinc[1], Ebru Temiz[2], Kaifee Arman[2], Uğur Arslanyürekli[2]

[1]Department of Medical Biochemistry, University of kahramanmaraş sutcu Imam, Kahramanmaras, Turkey

[2]Department of Medical Biology, University of Gaziantep, Gaziantep, Turkey

Non-small cell lung cancer is a disease in which malignant (cancer) cells develop in the tissues of the lung. There are a few types of non-small cell lung cancer. Smoking is the major risk factor for non-small cell lung cancer. Prolidase is a cytosolic imidodipeptidase, which specifically splits imidodipeptides with C-terminal proline or hydroxyproline 3. The enzyme prolidase plays an critical role in the breakdown of collagen as well as the intracellular protein especially in the last stage when peptides and dipeptides implicate a high level of proline. The aim of this study was to determine the levels of malondialdehyde (MDA), superoxide dismutase (SOD), catalase (CAT), glutathione peroxidase (GPx) and the relationship of antioxidant enzyme levels with serum prolidase levels in lung cancer cell line. For this purpose, the lung cancer cell line (A549) and epithelial bronchial cell line (BEAS-2B) were exposed to miRNA targeting MALAT1 in the cell cultur medium. Serum prolidase activity was measured spectrophotometrically. The determinations of MDA and antioxidant enzymes were performed spectrophotometrically. The results showed a significant decrease in SOD and CAT activities in A549 compared to the BEAS-2B. The present study demonstrate that serum prolidase activity and oxidative stress are significantly associated with the lung cancer and that the correlation between serum prolidase activity decreased serum level and markers of oxidative stress are represented as increased.

Keywords: prolidase, CAT, MDA, SOD, GPx

10.5505/2017ichc.PP-70 [Structure and function of the cell]

Effects of constant magnetic field of platelet function

Cigdem Bayram Gürel[1], Gülsel Ayaz[1], Handan Tuncel[2], Tunaya Kalkan[2], Nazmiye Kurşun[3], Turgut Ulutin[1]

[1]Department of Medical Biology, Medical Faculty of Cerrahpaşa, University of İstanbul, İstanbul, Turkey

[2]Department of Biophysic, Medical Faculty of Cerrahpaşa, University of İstanbul, İstanbul, Turkey

[3]Department of Biostatistic, Medical Faculty of Ankara, University of Ankara, Ankara, Turkey

Platelets secrete substances required for coagulation and inflammation, as well as membrane proteins are 4-7 microns in diameter through blood cells which are important tools. Although many studies have investigated the effects of today's magnetic field life cycle on the blood cells its mechanism of action is still unclear. Some studies suggest that especially low constant magnetic field activates leukocytes, increases their number, yet its effect on thrombocytes are not well established. We forsee that constant magnetic field may effect the functions of thrombocytes and enable there to survive longer outside of the body. For this reason we expose the thrombocytes to magnetic field with different power(2mT,5mT,40mT) in different time periods (5',15',30'). The measurements of thrombocyte aggregation were performed via agregometer in different time stops(0,24,40,48). ADP stimulates platelet aggregation. The 24h aggregation of the thrombocytes in response to 5mT 15 min. and 30 min. incubation was higher than that of the initial aggregation (slope p=0.008, Amplitude p=0.026). There were no difference between 15min. and 30min. The 48h measurement of 2 mT 15 min. and 30min. threated cells were higher than their initial measurements(p=0.038). With aggregation performed in 2mT is higher than the aggregation performed in 5mT(p=0,032). Platelet function responds to a magnetic field, and this response is a result worth further exploration.

Keywords: platelet function, constant magnetic field, agregation

10.5505/2017ichc.PP-71 [Structure and function of the cell]

Staining effect of Hibiscus sabdariffa extract on Human Blood Cells

Nilgün Güler, Nilgün Kusculuo

Hibiscus sabdariffa plant, popularly known using for the treatment of various diseases was not investigated as a source of dye for cytological studies using human blood cells. The aim of this work was to show staining effect of hibiscus extract on human blood cells. The natural dye source was H. sabdariffa L. Which is known as roselle, Punica granatum flower and potassium aluminum sulfate (alum=KAlSO4.12H2O), FeSO4, CuSO4.5H2O, were used as mordants or metal salts. Distilled water was used as solvent. Fresh, clean and air-dried hibiscus flowers were extracted with distilled water at 100°C for 30 minutes and then filtered. One drop blood, from a healthy 20 years old woman was spread as a peripheral on to ten glass slides and allowed to air-dry at room temperature. These slides were stained by soaking in hibiscus extract with/without alum (KAlSO4.12H2O) at 100°C for 60 minutes. Slides were washed with distilled water, air-dried and viewed at magnification of x100. The different blood cells were stained in shades of pink-red in alum mordant media at 100°C. As a result, Hibiscus sabdariffa has potential for use as a stain for study of human blood cells such as eosinophil a,basophil and neutrophil.

Keywords: Blood cells, Extract, Hibiscus sabdariffa L. Punica granatum, Stain,

10.5505/2017ichc.PP-72 [Structure and function of the cell]

Transmission Electron Microscopic Appearance of Melanosomes on the Pecten Oculi

Yasin Ilgaz[1], Sedat Develi[2]

[1]Department of Medical Histology and Embryology, University of Health Sciences, Gulhane Faculty of Medicine, Ankara, Turkey

[2]Department of Anatomy, University of Health Sciences, Gulhane Faculty of Medicine, Ankara, Turkey

INTRODUCTION&OBJECTIVES: Pigments are biological substances which has specific color and specific functions. For example, melanin is a dark pigment which protects us from UV damage by absorbing the UV radiation. Melanin is derived from the amino acid tyrosine and produced by melanocytes. On the other hand, high exposure to UV radiation may cause malignant melanoma which is a malign neoplasm of melanocytes. In humans skin color is determined by the concentration of melanin at the epidermal–dermal junction and induced by light. Pecten oculi is an anatomic structures found in the bulbus oculi of the avian species. It is an extension of the choroid to the vitreous body. It is a pigmented structure and believed to nourish the retina. Since melanogenesis is induced by light, we aimed to investigate the development of the melanosomes in the pecten oculi, in order to get information about the light-transmissivity of the eggshell.
MATERIALS&METHODS: Fertilized chicken eggs were used to evaluate the pecten oculi. Development of pecten oculi is completed in 17-18th-days in chickens. Thus evaluation was made in 19th-day of incubation. After sacrification, pecten oculi was extracted from bulbus oculi. For cross-section TEM analyze tissues were fixed with glutaraldehyde and washed with PBS solution. After dehydration and embedding, sectioning of samples was done with an ultramicrotome.
RESULTS: In all specimens melanosomes were observed in the pecten oculi (Figure 1). In literature it is suggested that melanin in the pecten oculi absorbs the light and decreases the damage to retina and to vessels within the pecten. Our finding indicates that eggshell is light-transmissive and it permits melanogenesis in the pecten of the avians.
CONCLUSIONS: Development of melanosomes within the pecten of the avian embryos seems to be useful for melanogenesis researches.

Keywords: Pecten oculi, Melanosomes, Transmission Electron Microscopy

Figure 1

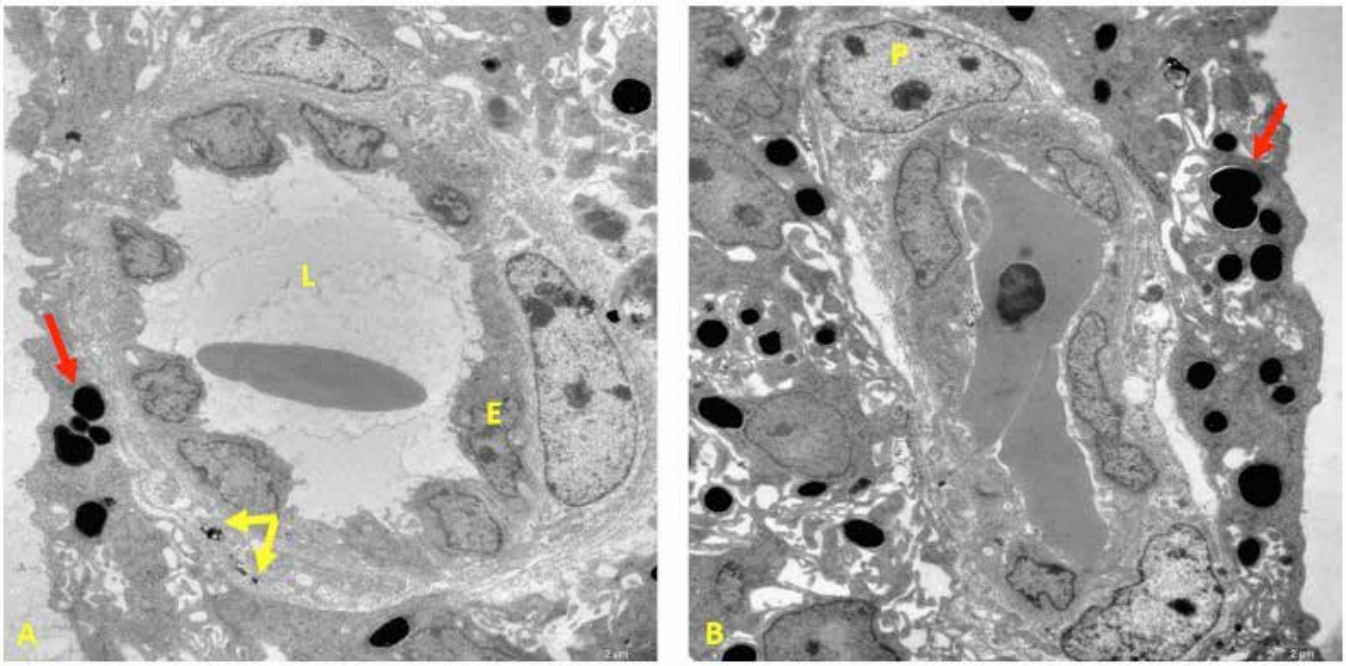

Cross section of the pecten oculi. Melanosomes (Red arrows), Lumen of the vessel (L), Endotel (E), Melanogenesis (Yellow arrows), Pericyte (P). Bar: 2 µm.

10.5505/2017ichc.PP-73 [Structure and function of the cell]

Histochemical properties of gastric mucins of Spermophilus xanthophrymnus in hibernation and active period

Feyzullah Beyaz[1], Narin Liman[1], Hakan Sağsöz[2], Sebahatin Köknur[1], Ergül Ergen[1], Ural Kemal Kavral[1]

[1]Erciyes University, Faculty of Veterinary Medicine, Department of Histology and Embryology, Kayseri, Turkey

[2]Dicle University, Faculty of Veterinary Medicine, Department of Histology and Embryology, Diyarbakır, Turkey

Introduction: S. xanthoprymnus is a terrestrial diurnal rodent and excelent hibernator. This study was performed to determine localization of gastric mucins of S. xanthophrymnus in hibernation and active period.
Materials & Methods
32 animals were used in this study and 16 animals were seperated as active period and 16 animals were housed in laboratory for 100 days of hibernation. AB/PAS and (HID)/AB stainings were used to examine gastric mucins.
Results: AB/PAS staining demonstrated that in cardia, the superficially located glands showed strong mixed reaction, while the deep glands displayed either AB (+) or PAS (+) reaction. Animals under hibernation had both weak AB (+) and PAS (+) reactions in the glandular corpus. At the fundus, superficially located glands showed strong mixed reaction, while secretory ducts of the glands and the glandular corpus displayed only PAS (+) reaction. Animals under hibernation had weak or no PAS (+) reactions in secretory ducts of the glands and the glandular corpus. At the pyloris, the superficially located glands and secretory ducts of the glands showed strong mixed reaction, while the deep glands displayed PAS (+) reaction. Animals under hibernation had weak PAS (+) reaction in secretory ducts of the glands and the glandular corpus.
HID/AB staining demonstrated that in cardia, the superficially located glands showed weak AB (+) reaction, while the deep glands displayed both strong HID (+) and weak AB (+) reaction. Animals under hibernation had weak AB (+) and no HID (+) reaction in the glandular corpus. At the fundus, the superficially located glands showed weak AB (+) reaction, while secretory ducts of the glands and the glandular corpus displayed HID (+) and AB (+) reaction. Animals under hibernation had no HID (+) reaction in secretory ducts of the glands and the glandular corpus. At the pyloris, superficially located glands showed weak AB (+) while the deep glands displayed both HID (+) and AB (+) reaction. Animals under hibernation had weak AB (+) and no HID (+) reaction in secretory ducts of the glands and the glandular corpus.
Conclusions: Gastric mucins contents in stomach remarkably alter during hibernation compared to active period.

Keywords: Gastric mucins, Spermophilus xanthophrymnus, hibernation, histochemistry, stomach

10.5505/2017ichc.PP-74 [Structure and function of the cell]

Protective Effects of Resveratrol and Melatonin on Carbon Tetrachloride Induced Kidney Damage

Birgül Yiğitcan[1], Mehmet Gül[2], Meltem Kuruş[2]

[1]Department of Histology and Embryology, İnönü University, Malatya, Turkey

[2]Department of Histology and Embryology,izmir Katip Çelebi University, İzmir, Turkey

AIM: The aim of this study was to investigate the protective effects of resveratrol and melatonin against carbon tetrachloride (CCl4) induced kidney injury, using biochemical and histological parameters. Carbon tetrachloride is a manufactured compaund that does not occur naturally and it is regarded as a toxic substance that cause localized cellular injury via a free radical mechanism. ın people exposure to CCl4 that expented period of time can damage the kidney, liver and nervous system.Resveratrol is a phytoalexin and synthezed in high concentrations in the shell of colored grape cultivas aganist biotic and stress conditions.Melatonin released by pineal gland, has many roles of biological and physiological processes of the body including cell renewal,strengthening of the immune system,body temperature regulation.

MATERİALS&METHODS: Studies were performed on 40 male Wistar albino rats weighing 150-180g.Group1:Saline,0.5ml,Group2:oliveoil,0 .5ml, Group3:oliveoil-CCl4,1ml/kg/gün(1/1),Group4:oliveoil-CCl4,1ml/kg+Resveratrol 10mg/kg,Group5:oliveoil-CCl4,1 ml/kg+Melatonin 20 mg/kg.These groups were given for 20 days intraperitoneally. The rats in five groups 21th day of experiment were sacrificed.After application,rats were decapitated and kidneys of the rats were taken.After tissue processing,kidney sections were cut at thickness of 5 µm for light microscopic analysis and 80 nm for electron microscopic analysis.Tubular damage,glomerular collapse and congestion,infiltration,i ntracellular edema were evaluated qualitatively as follows: 0:none,1:slight, 2:moderate, 3:severe changes,according to the extent of damage observed.

RESULTS: The kidneys of the control and oliveoil groups showed normal histologic features.CCl4 group,the affected glomeruli showed collapse. Some of the cortical tubules were dilated and some epithelial cells showed vacuolization, and detached from the basal membrane that visible in the lumen.Interstitial inflammatory cell infiltration and congestion were also seen. In the Group4 and group 5,the glomeruli were normal,sparse tubular changes were observed. In this groups,the affected tubules showed vacuolization,dilation and in the cortical area were seen depleted congestion and inflammation.Immunohistochemical analysis showed that CCl4 significantly increased the expression of cas-3 protein in the kidney when compared to control and oliveoil. by the treatment of resveratrol and melatonin the expression of cas-3 protein decrease when group4 and group 5 were compared with CCl4 group.

CONCLUSİON:Demonstrated in this study that Melatonin and Resveratrol have a protective and curative role against the destructive effects of CCl4 on kidney tissues.

Keywords: CCl4, Melatonin, Resveratrol, kidney

10.5505/2017ichc.PP-75 [Structure and function of the cell]

Dipeptidyl peptidase-4 inhibition causes liver regeneration in neonatal STZ-diabetic rats

Melek Öztürk[1], Fatma Kaya Dağıstanlı[1], Gamze Argün Kürüm[1], Müşerref Eşrefoğlu[2], Olgu Enis Tok[2], Gamze Tanrıverdi[3]

[1]Medical Biology Department, Cerrahpasa Faculty of Medicine, Istanbul University,Turkey

[2]Histology and Embryology Department, Medical Faculty, Bezmialem University, Turkey

[3]Histology and Embryology Department, Cerrahpasa Faculty of Medicine, Istanbul University,Turkey

Diabetes is the most common cause of liver disease in the world. DPP-4 (Dipeptidyl peptidase-4) is involved in the development of various chronic liver diseases and glucose intolerance-diabetes mellitus. Vildagliptin (VG), a DPP-4 inhibitor, regulates plasma glucose levels and insulin secretion. Oval (Ov) cells are hepatic precursors of hepatocytes and bile duct cells, and mediates liver regeneration. Proliferating and differentiating potential stemness cells or adult hepatocytes express alpha fetoprotein (AFP). STZ is a beta-cell toxin that can produce diabetes mellitus and it is induces hyperglycemia. We aimed to observe the effects of short term VG treatment on liver regeneration in neonatal STZ-diabetic (nSTZ) rats.

In this study four groups were performed; (1) control, (2) diabetic (n2STZ) (STZ;100mg/kg, ip injected second day after birth), (3) VG-treated diabetic (n2STZ+VG) (VG; 60mg/kg/day, oral during 8 days), and (4) only VG (VG; 60mg/kg/day, oral during 8 days). Blood glucose levels and body weights were measured. All liver tissue sections were stained with hematoxylin and eosin and PAS stain, also were immunohistochemically stained with Ov-6 (for hepatic precursor cells), PCNA (for proliferation index) and AFP (for retrodifferentiation) antibodies by the streptavidin-biotin peroxidase technique.

Blood glucose levels significantly increased in n2STZ groups compared to the other groups. Ov-6 is a marker for newly formed hepatocytes. Ov cells characterized by an ovoid nucleus, small size, and scanty cytoplasm were located predominantly in the periportal region and fibrosis septa on the n2STZ groups. In the n2STZ+ VG group intense Ov-6 staining were seen. Ov-6 immunostained cell were mainly located bile ducts and also some hepatocyte like cells which are located far from the portal regions. Additionally, the PCNA index was significantly improved in the n2STZ+ VG and VG groups ($p<0.001$) versus the nSTZ group. Increased AFP immunopositive cells were mainly located peripheral areas of the bile ducts and with in the paranchimal areas in the VG treated diabetic group compare to the STZ group.

Our evidence indicate that short term VG treatment enhances liver regeneration which is associated with oval cell expansion and retrodifferantion in neonatal STZ diabetic rats. In liver degeneration, DPP-4 inhibition may be a promising strategy for liver regenerative stem cells and a novel therapeutic approach.

Keywords: Liver regeneration, Oval cells, STZ-diabetes, DPP-4 inhibitor.

10.5505/2017ichc.PP-76 [Structure and function of the cell]

Septin3 involvement in microtubule - p60-katanin –tau interactions

Didem Baran, Burcu Sucu, Koray Kırımtay, Şirin Korulu Koç, Arzu Karabay
Istanbul Technical University Molecular Biology-Biotechnology and Genetics Research Center

Introduction & OBJECTIVES: Microtubule cytoskeleton is an interconnected network of filamentous polymers and regulatory proteins. The ability of a eukaryotic cell to resist deformation, stability and functioning of neurons depends on cytoskeleton. p60-katanin is a critical enzyme that severs microtubules to provide dynamicity for microtubules. Septin3 has been considered as the fourth cytoskeletal polymer and is the only Septin to be expressed almost exclusively in brain tissue, and is enriched in neurons. Although its function is not fully determined yet, by similarity it can form filaments and can regulate neuronal processes. Another neuron specific protein, Tau may have regulatory function for p60-katanin and Septin3 interaction as in p60-katanin and microtubule interaction. Here, we aimed to analyze p60-katanin interacting protein Septin3 in detail and to reveal the interactions both in physical and functional manners and clarify the role of p60-katanin function on Septin3 in mitotic RFL6 cells (Septin3 and Tau depleted) and in post-mitotic neurons.
MATERIAL-METHODS: p60-katanin and Septin3 were expressed in the cells separately or together to analyze function of p60-katanin on Septin3. Co-IP experiment was performed in order to identify physical interaction between p60-katanin and Septin3. Then, by immunostaining of primary neurons, localizations of p60-katanin and Septin3 were analyzed. Tau-Septin3 interaction was also analyzed by co-IP and immunostaining.
RESULTS: Findings indicated that Septin3 protein interacts with p60-katanin intrinsically. Immunostaining experiment showed that Septin3 and p60-katanin co-localize in the cell, but Septin3 filaments are disrupted in regions where p60-katanin is concentrated. Co-immunoprecipitation and immunostaining results pointed out that Septin3 protein interacts with Tau intrinsically, whereas p60-katanin and Tau have no physical interactions. Immunostaining experiments showed that Septin3, MTs and Tau co-localize.
CONCLUSIONS: These preliminary findings indicate that Septin3 is involved in the structure of MTs and p60-katanin interacts with Septin3 like microtubules and it may sever the filamentous structures formed by Septin3. Interaction of Septin3, MTs and Tau may weaken p60-katanin's ability of severing these polymers.

Keywords: Septin, Katanin, Microtubules, Tau.

10.5505/2017ichc.PP-77 [Techniques in immunohistochemistry]

The Structure of Spleen in the Long-Legged Buzzard (Buteo rufinus): Histological and Immunohistochemical Study

Hasan Asker[1], Buket Bakır[2], Nevin Kurtdede[3], Hikmet Altunay[3], Ebru Karadağ Sarı[4]

[1]Department of Histology and Embryology, Healthy Sciences Institute, Kafkas University, Kars, Turkey

[2]Department of Histology and Embryology, Faculty of Veterinary Medicine, Namik Kemal University, Tekirdag, Turkey

[3]Department of Histology and Embryology, Faculty of Veterinary Medicine, Ankara University, Ankara, Turkey

[4]Department of Histology and Embryology, Faculty of Veterinary Medicine, Kafkas University, Kars, Turkey

INTRODUCTION: The aim of this study was to examine the spleen of the long-legged buzzard (Buteo rufinus) by histologically and immunohistochemically.
MATERIAL-METHODS: The tissue materials were taken from three healthy long-legged buzzards provided by permission of the General Directorate of Nature Protection and National Parks (Ankara, Turkey).
Tissue samples were fixed in 10% formalin solution for 24 hours and alcohol-formol solution for 48 hours. Following routine histological processing the fixed samples were embedded in paraplast and serial sections were prepared.
The modified Mallory's triple staining was used to demonstrate the general structure of the spleen tissue. Methyl green pyronin (MGP) staining was applied to the sections to observe the plasma cells and pyroninophilic cells. Silver staining technique of Gordon and Sweets was performed for the reticular cells and reticular fibers. Alcian blue (pH 1.0) was used to display weak and strong sulfated mucins (mucosubstances). Immunohistochemical method was used to show the localization of catalase. The sections were examined under light microscope.
RESULTS: It was seen that the capsule surrounding the spleen was not creation trabeculae. Plasma cells and pyroninophilic cells were observed around the lymphoid follicles. It was determined that reticular cells and reticular fibers form the roof of the lymph follicles. Alcian blue (pH 1.0), positive reaction was observed in the endothelial cells and Schweigger-Seidel cells. Catalase immunoreactivity was seen especially in the cytoplasm of Schweigger-Seidel cells.
Consequently, determination of the histological structure and catalase immunoreactivity of the spleen on the long-legged buzzard by this study could be support for the future researches.

Keywords: Histochemistry, Catalase, spleen, long-legged buzzard

10.5505/2017ichc.PP-78 [Techniques in immunohistochemistry]

Immunohistochemical Examination of Cinnamon Extract Administration on the Distribution of NGF (Nerve Growth Factor) and Trk-A (Tyrosin Kinase A) Receptor on Diabetic Rats Pancreatic Tissue

Şükran Yediel Aras[1], Ebru Karadağ Sarı[2]

[1]Department of Histology-Embryology, Health Sciences Institute, Kafkas University, Kars, Turkey

[2]Department of Histology-Embryology, Faculty of Veterinary Medicine, Kafkas University, Kars, Turkey

INTRODUCTION: The aim of this study was to investigate the effect of cinnamon extract administration on distribution of NGF (Nerve Growth Factor) and Trk-A (Tyrosine Kinase A) receptors on diabetic rats pancreatic tissue by immunohistochemically.
MATERIAL-METHOD: In this study, 60 (30 male+30 female) Sprague Dawley rats were used. Experimental groups were defined as control, sham, cinnamon, diabetes and diabetes+cinnamon. For the formation of experimental diabetes (diabetes and diabetes-cinnamon groups), STZ injection was performed. After verifying diabetes, cinnamon extract was administered daily 200 mg /kg by oral gavage route for 14 days to cinnamon and diabetes-cinnamon groups. At the end of the experiment rats were euthanized by cervical dislocation and obtained pancreatic tissue. These tissue were embedded in paraffin after routine histological processing. The immunohistochemically methods were performed on the sections.
RESULTS: In all groups, body weight and fasting blood glucose obtained from male and female rats and the values were statistically evaluated. Between diabetes and diabetes+cinnamon groups with control were determined significant difference by statistically on female and male rats. NGF immunoreactivity was observed in acinus, the pars excretory, ductus excretoryus and islets of Langerhans on female and male rats pancreatic tissues of all groups. NGF immunoreactivity was decreased in the islets of Langerhans in diabetes group, increased in the diabetes+cinnamon group on female and male rats. Trk-A immunoreactivity was observed in acinus and the islets of Langerhans on female and male rats pancreatic tissues of the control, sham and cinnamon groups. Trk-A immunoreactivity was observed in the absence the islets of Langerhans on female and male rats pancreatic tissues of diabetes and diabetes+cinnamon groups.
CONCLUSION: Based on this result, it was determined that the cinnamon which is effective on blood glucose levels, has positive effect on the production of NGF but did not affect the releaseing Trk-A receptors.

Keywords: NGF, Trk-A, cinnamon, pancreas, immunohistochemistry

10.5505/2017ichc.PP-79 [Techniques in immunohistochemistry]

Immunohistochemical analysis of the anti-fibrotic effect of pirfenidone on epidural fibrosis in the post-laminectomy rat model

Deniz Billur[1], Yahya Güvenç[2], Mesut Emre Yaman[3], Yaşar Öztürk[2], Pınar Bayram[1], Şule Kızıl[1], Sevim Aydın[1], Erkan Kaptanoğlu[4]

[1]Department of Histology Embryology,Ankara University, Ankara, Turkey

[2]Yenimahalle Traning and Research Hospital, Department of Neurosurgery, Ankara, Turkey

[3]Memorial Hospital, Ankara, Turkey

[4]Marmara University, Department of Neurosurgery, Istanbul, Turkey

AIM: Postlaminectomy epidural fibrosis is one of the most frequent complications of lumbar surgery. This scar formation may be compressive and restricts the mobility of the nerve root that is most vulnerable against new discal protrusions and favors the presence of a stenosis of the neural canal (1). Various materials or drugs have been used to inhibit formation of epidural fibrosis and reduce the compressive effect on neural structures. Nevertheless, the effects are not satisfied.
Pirfenidone is a broad-spectrum anti-inflammatory and anti-fibrotic molecule that has been shown to inhibit the fibrosis progression in patients with idiopathic pulmonary fibrosis and animal models. Anti-fibrotic mechanism of pirfenidone is associated with antagonism of activities mediated by TNF-α and TGF-β (2).
In present study, pirfenidone was studied to investigate its anti-fibrotic effects on reducing epidural fibrosis after laminectomy in a rat model.
MATERIALS-METHODS: Thirty two Wistar albino rats were divided randomly into four equal groups: control, spongostan, systemic pirfenidone and local pirfenidone. Total L3-L5 laminectomy was performed in entire groups. 4 weeks following operation, animals were euthanized and samples were collected, fixed and stained with Masson's tricrom method. Anti-TNF-α, anti-IL-1, anti-α-SMA antibodies were used for immunohistochemistry evaluations. Intensities of immunoreactivities were scored as mild (1), moderate (2), strong (3) and very strong (4). H-score of each group was calculated using the formula: H-score= ΣPi (i+1) (i: intensity, Pi: percentage of stained cells for each intensity). H-score of each antibody for each group was analyzed comparatively by using the ANOVA statistical test.
RESULTS: Our data suggests that rats treated with pirfenidone at 4 weeks post-laminectomy had less, dura thickness, epidural fibrosis, scar tissue consistency and inflammatory response and arachnoidal involvement in comparison with the control and spongostan groups ($p<0.05$). Pirfenidone treated groups show weak labeling for anti-IL-1, anti-TNF-α and anti-α-SMA antibodies than control and spongostan groups ($p<0.05$). Moreover, by the local applicaton of pirfenidone we obtained better results than systemic administration for all parameters.
CONCLUSION: The results of our study suggested that pirfenidone has anti-fibrotic effects on epidural fibrosis, especially its effectiveness increased when it is used locally.

Keywords: Pirfenidone, immunohistochemistry, laminectomy, epidural fibrosis

10.5505/2017ichc.PP-80 [Techniques in immunohistochemistry]

Effect of diabetes on Gal-1 and Gal-3 expressions in the rat ovarial tissue

Berna Özdenoğlu[1], Serpil Ünver Saraydın[1]
[1]Department Of Histology Embryology,Cumhuriyet University Medicine Faculty, Sivas, Turkey

Diabetes mellitus (DM), is a metabolic disease occuring via insulin secretion deficiency from the pancreas and/ or an insufficiency of tissue response to insulin. In the present study, immunolocalizations of beta-galactose-binding proteins Galektin-1 and Galektin-3 in diabetic rat ovarium were shown and their relationship with diabetes have been demonstrated. In this study, 8-10 weeks old, 250-300 g weighing 50 mature female rats were used. In order to establish diabetes mellitus in those animals, 60 mg/kg-IV streptozotocin was injected to each animal. Rootin tissue processing steps were done to rat ovarial tissues for immunohistochemical investigation. Strong expressions of Galectin-1 and Galectin-3 were observed in the ovarial germinal epithelium and vascular endothelial. While the strongest expression of Galectin-1 was seen in the zona pellucida, Galectin-3 expression was strongest in the cytoplesmic regions of cells. Zona pellucida has 3 protein complexes (ZP1, ZP2, ZP3) in rats and in humans and they have the capability of recognizing the carbonhydrate fields in tissues. The strong expression of galektins in those regions could be the result of carbonhydrate binding properties expression of Gal-3 in the cytoplasmic regions of growing follicles could suggest the idea that Gal-3 could have effects on follicle growth. In conclusion, beta galactose-binding proteins Gal-1 and Gal-3 had stronger immunolocalization in diabetic rat ovarium when compared to the controls. Diabetes could increase the Gal-1 and Gal-3 expressions in the ovarial tissue.

Keywords: Galektin-1, galektin-3, ovary, diabetes, rat

10.5505/2017ichc.PP-81 [Techniques in immunohistochemistry]

Effects of Low Dose Mercury Exposure on Rat Pancreas During Gestational and Lactational Periods

Fatma Kaya Dagistanli[1], Sule Ozdas[2], Sabriye Karadenizli[3], Deniz Sahin[3]

[1]Department of Medical Biology, Cerrahpasa Medical Faculty, Istanbul University, Istanbul, Turkey

[2]Department of Medical Biology and Genetics, Medical Faculty, Istanbul Bilim University, Istanbul, Turkey

[3]Department of Physiology, Faculty of Medical, Kocaeli University, Kocaeli, Turkey

Mercury (Hg) is a heavy metal commonly found the environment permanently. It can also be transferred to the fetus through the placenta and to newborn offspring through breast milk. Pathophysiological effects of mercury on the function of β cells remain unknown. The aim of the study, effects of inorganic mercury exposure during the intrauterin and neonatal period on rat pancreatic tissue.
Eight pregnant rats were divided into 2 groups randomly: control (vehicle-saline solution im) or treated with mercury chloride for pregnancy and lactation period for 30 days. At 5. postnatal months, under ether anesthesia by applying perfusionanimals were sacrificed. Pancreatic tissues were removed, fixed in 4% neutral buffered formalin and embedded in paraffin wax, then cut into 4 µm thick sections and were finally immunohistochemical stained with insulin, somatostatin and glucagon antibodies. Also we extracted total protein from pancreatic tissues and t argeted proteins were shown by western blot. All values were analyzed with GraphPad statistical program.
Blood Glucose levels significantly increased in mercury treated group compared to the control groups ($p<0,05$). The sizes of islets and its containing insulin(+) cell numbers were decreased in the mercury treated group. Glucagon and somatostatin positive cells were increased within the islets in mercury treated group compared to the control group. Western blotting results were found to be compatible with the IHC results. According to the findings, it was concluded that intrauterine and neonatal period may create the risk of diabetes in later stages of the mercury exposure.

Keywords: Mercury, pancreas, diabetes

10.5505/2017ichc.PP-82 [Techniques in immunohistochemistry]

Immunohistochemical Distribution of Natriuretic Peptides and Their Receptors in Goat Heart

Mustafa Öztop[1], Özlem Erekli[2], Kenan Çinar[2]

[1]Department of Biology, Mehmet Akif Ersoy University, Burdur, Turkey

[2]Department of Biology, Süleyman Demirel University, Isparta, Turkey

Natriuretic peptides (NPs) are a family of structurally related peptides derived from separate genes. Three major members of the family recognized in mammals are atrial natriuretic peptide (ANP), brain natriuretic peptide (BNP), and C-type natriuretic peptide (CNP). NPs exert their actions through binding to specific high affinity receptors on the surface of target cells. Three classes of receptors have been identified. NPR-A is sensitive to ANP and BNP, NPR-B is highly specific to CNP, and NPR-C binds to all NPs with similar affinities. All three receptor types are widely distributed in a variety of tissues, including heart and vascular system.

This study aimed to determine the immunohistochemical distribution of natriuretic peptides (ANP, BNP and CNP) and their receptors (NPR-A, NPR-B and NPR-C) in atria and ventricles of male and female goat heart. Peroxidase-anti-peroxidase procedure was applied to 5 µm thick sections from formalin-fixed paraffin-embedded tissues.

Immunostaining results reveal that ANP, BNP and CNP immunoreactivity was found to be in atrial and ventricular cardiomyocytes, as well as in endothelial cells and smooth muscles of artery and vein media layer, with varying intensity of immunoreactivity, in both sexes. Immunoreactivity in cardiomyocytes was determined to be peri-cytoplasmic. In a similar way, NPR-A, NPR-B and NPR-C immunoreactivity was observed in endothelial cells and smooth cells including cardiomyocytes. NPR-C immunoreactivity was shown to be stronger than NPR-A and NPR-B antibodies, with a much weaker NPR-A immunoreactivity. Each NPR was widely distributed within the cardiac muscular cytoplasm rather than localized on the cell membrane. There was no expression of NPRs in the nucleus of myocardial cells. Peripheral immunostaining was observed in the cardiomyocytes. The reason why NPR-C antibody showed a stronger immunoreactivity in the cardiac tissue is closely associated with the fact that natriuretic peptides, ANP, BNP and CNP, remove from the circulation through NPR-C since it is a clearance receptor that is involved in natriuretic peptide degradation.

We can infer that these results will provide a basis for future works to understand whether the expression of natriuretic peptides and their receptors vary across goat and other domestic mammal species in sex and age dependent manner.

Keywords: Goat, natriuretic peptides, natriuretic peptide receptors, heart

10.5505/2017ichc.PP-83 [Techniques in immunohistochemistry]

A Stress-free Application System for Obtaining True Biochemical and Morphological Findings in Experimental Electromagnetic Field Exposure Studies in a Rat Model

Ersan Odacı
Department of Histology and Embryology, Faculty of Medicine, Karadeniz Technical University, Trabzon, Turkey

Introduction & OBJECTIVES: Experimental animals exposed to the effects of electromagnetic fields (EMF), such as rats, are often immobilized in tight spaces. In addition to the effect of EMF, rats are thus also subjected to stress. We describe, for the first time, a system in which rats can be exposed to the effect of EMF alone, without fear and stress, when investigating the effects of EMF using morphological and biochemical methods.
Materials & METHODS: The system is called the EMF application system. It consists of an ultra-high-frequency oscillator with an uninterrupted power source with an output power of approximately 300 mW and frequency adjusted to 900–2000 MHz. The oscillator is adjusted to the same frequency as a mobile phone. This is attached to a half-wave self-made dipole antenna made from a copper rod via a coaxial cable. The antenna is fixed in the center of the cage with an insulating wooden rod. The rod is attached equidistant from the right and left and front and rear edges of the cage. The central point of the rod is determined, and the antenna is attached to that point. The antenna is installed equidistant from the right and left sides and approximately 11 cm inside the open top of the cage. This is made of Plexiglas and is 40.5 cm (length) × 31.5 cm (width) × 40.5 cm (height) in size. Rats are allowed to move around freely inside the cage during applications in order to minimize stress resulting from immobility. Intensities of EMF are measured on the cage floor during EMF exposure in order to determine the distribution of EMF intensity in the region containing the rats using a broad band measuring device.
RESULTS: The same EMF effect is established at all point of the cage. Rats are thus exposed to the same intensity of EMF, without fear and stress. Power intensity and SAR values can be easily calculated by measuring the electric field on the cage floor.
CONCLUSIONS: The system elicits morphological and biochemical data resulting from the effect of EMF alone.

Keywords: EMF application system, rat, morphology, biochemistry

10.5505/2017ichc.PP-84 [Techniques in immunohistochemistry]

The Light Microscopic Investigation on the Ileal Peyer's Patches of Sheep in the Prenatal and Postnatal Periods

Mehmet Özbek[1], Alev Gürol Bayraktaroğlu[2]

[1]Department of Histologyand Embryology, Faculty of Veterinary Medicine, Mehmet Akif Ersoy University, Burdur, Turkey

[2]Department of Histology and Embryology, Faculty of Veterinary Medicine, Ankara University, Ankara, Turkey

Introduction & Objectives: Peyer's patches (PP) are lymphoid tissues that form the primer inductive part of the gut associated lymphoid tissue (GALT), which is located in ileum and jejunum. This study was conducted to investigate the development of sheep ileal PP in the prenatal and postnatal period.
Materials & Methods: Ileal tissue taken from fetuses and adult Akkaraman sheeps at different developmental periods were used as material. The Strept-ABC method was performed to demonstrate CD4 and CD8 positive lymphocytes. Crossman's triple staining was applied to the tissues fixed with Bouin's solution to observe general histological structure. In order to detect plasma cells, methyl green pyronin staining was done in tissues fixed with formol-alcohol.
Results: Anlagen of PP showing primordial dome structure was firstly observed at 73 days of gestation, while early anlagen of PP showing primordial dome-follicle structure was firstly seen at 96th days. As from 147th days of gestation, PP histomorphologically became mature. In fetal period, pyroninophilic cells were observed in interfollicular region (IF), germinal center (GC), corona (C) and dome region (D) while plasma cells weren't seen. In the postnatal period, plasma cells were detected in D and IF.
CD4+ and CD8+ lymphocytes were observed in the connective tissue between 70 and 95 days of gestation and these cells were presented in primordial follicle and submucosa between 95 and 120 days of gestation. It was detected that almost all interfollicular region consisted of CD4+ and CD8+ lymphocytes between 120-150 days of pregnancy.While CD4+, CD8+ lymphocytes were observed concentratedly in D, IF and lamina propria in the postnatal period, a small number of CD4+, CD8+ lymphocytes were seen in GC, C and FAE
Conclusions:
As a result, it was determined that PP developed in prenatal period without exogenous antigenic stimulation in sheep

Keywords: Fetus, ileum, Peyer's patch, sheep

10.5505/2017ichc.PP-85 [Techniques in immunohistochemistry]

Expressions of Ghrelin and Obestatin in the Sheep Tongue

Hakan Sağsöz[1], Serkan Erdoğan[2], Berna Güney Saruhan[1]

[1]Department of Histology and Embryology, Faculty of Veterinary Medicine, Dicle University, 21280 Diyarbakır, Turkey

[2]Department of Anatomy, Faculty of Veterinary Medicine, Namık Kemal University, 59030 Tekirdağ, Turkey

Ghrelin and obestatin are two peptides encoded by the same preproghrelin gene. Ghrelin is a powerful appetite stimulant and plays an important role in energy homeostasis. Its secretion is initiated when the stomach is empty, whereupon it binds to the growth hormone secretagogue receptor in the hypothalamus which results in the secretion of growth hormone. Ghrelin is thought to regulate multiple activities, including hunger, reward perception via the mesolimbic pathway, gastric acid secretion, gastrointestinal motility, and pancreatic glucose-stimulated insulin secretion. Obestatin plays an opposing role to ghrelin by promoting satiety and thus decreasing food intake, but this action is still debated. Recent reports suggest multiple metabolic roles for obestatin, including regulating adipocyte function and glucose metabolism. Contributing to the physiological relevance of this peptides, we used immunohistochemical methods for deterimining the expression of ghrelin and obestatin in the tongue, followed by semiquantitative analysis. In this study, 10 tongues were taken from 24 months' sheep raised in the same nutrient media, during usual slaughtering in private slaughterhouses serving in Tekirdağ province. In tongue, the ghrelin expressed in sitriated muscles and smooth muscle cells of middle layer of blood vessels only. Lingual epithelium, epithelial cells of salivary glands and ductal epithelial cells and stromal cells were negative. Obestatin reaction was determined in superficial cells of lingual epithelium and taste buds of circumvallate papillae. Ductal and epithelial cells of seromucous and von Ebner's glands had also reactions and even the expression was very strong in ductal epithelial cells. Moreover, obestatin expression in epithelial cells of secretory units of von Ebner's glands was stronger than in seromucous glands. There were no an expression in stromal and skeletal muscle cells. In conclusion, the expressions of ghrelin and obestatin in tongue suggest that they may effect the organizations of endocrine or paracrine mechanisms in these tissues or related organs.

Keywords: tongue, physiological mechanism, immunohistochemistry, obestatin

10.5505/2017ichc.PP-86 [Techniques in immunohistochemistry]

The Roles of Leptin in the Lingual Epithelium and Glands in Ovine Tongue

Hakan Sağsöz[1], Serkan Erdoğan[2], Berna Güney Saruhan[1]

[1]Department of Histology & Embryology, Faculty of Veterinary Medicine, University of Dicle 21280-Campus- Diyarbakır, TURKEY

[2]Department of Anatomy, Faculty of Veterinary Medicine, Namık Kemal University, 59030 Tekirdağ, Turkey

Leptin, a 16-kDa hormone, plays an important role in the control of food intake and in energy homeostasis both human and animals. Leptin is mainly produced in adipose tissue, which secretes this hormone into the blood. Leptin achives its spesific effects by interacting with the specific receptors located in central nervous system and in peripheral tissue. It plays role in neuroendocrine, reproductive, haemopoietic and metabolic control patways. We used immunohistochemical methods for determining the expression of leptin, followed by semiquantitative analysis. In this study, 10 tongues were taken from 24 months' sheep raised in the same nutrient media, during usual slaughtering in private slaughterhouses serving in Tekirdağ province. Leptin was strongly expressed in basal and parabasal epithelial cells and taste buds of fungiform and circumvallate papillae. While seromucous glands displayed waek reaction, von Ebner's glands had a strong reaction. Especially, leptin expression was quite strong in the duct epithelium of both gland types. In stromal cells and skeletal muscle cells and blood vessels, expressions were detected in variable densities. In conclusion, leptin expression was determined significantly in the sheep tongue, and when considered physiological function of the leptin,it may play strategic and helpful roles in arrangements of digestive functions and related pathways.

Keywords: tongue, physiological mechanism, immunohistochemistry, leptin

10.5505/2017ichc.PP-87 [Techniques in immunohistochemistry]

The Effects of Isradipine on Apoptosis and Endoplasmic Reticulum Stress in Pancreatic Islet Cells of The Neonatal Streptozotocin Diabetic Rats

Fatma Kaya Dagistanli[1], Hulya Zeynep Oktay[2], Onur Ercelik[2], Gamze Argun Kurum[1], Melek Ozturk[1]

[1]Department of Medical Biology, Cerrahpasa Medical School, Istanbul University

[2]Cerrahpasa Medical School, Istanbul University

Streptozotocin (STZ) induces insulin-dependent diabetes in experimental animals. Intracellular calcium levels increase in diabetic animals after induction by STZ. Hyperglycemia inhibits Ca2+-ATPase and increases intracellular calcium levels. Heat shock proteins (HSPs) are the largest family of transcriptionally regulated chaperone proteins that respond to cellular stress in order to aid in repair of protein damage and survival of normal cellular functions.7 We aimed to observe the effects of isradipine treatment on the islet cells apoptosis, endoplasmic reticulum (ER) stress, also on the regulation of islets morphology in neonatal streptozotocin (n-STZ) diabetic rats.
Four groups were used. On the second day after birth, 100 mg/kg STZ was given i.p. to the first and second groups. The first group was n-STZ diabetic. To the second group, starting from the 12th week, 5 mg/kg/day isradipine (i.p) was given for 6 weeks. The third group was non-diabetic and treated with 5 mg/kg/day isradipine for six weeks. The fourth group was control rats. Pancreas sections were immunostained using insulin, glucagon, somatostatin, GRP78 (ER stress marker), caspase-3, and PCNA antibodies. TUNEL assay and Caspase 3 were used for detection of apoptotic cells. All collected data were analyzed statically.
Blood glucose levels of untreated n-STZ diabetic rats were significantly higher than the other groups($p<0,001$). Islet sizes in n-STZ groups were detected decreasing compared to other groups.The glucagon and somatostatin positive cells were located in the periphery of the islets. In the n-STZ diabetic rats, the number of insulin positive beta cells was markedly reduced. The glucagon and somatostatin cells were centrally localized in the islets of n-STZ diabetic group, whereas their localization in the n-STZ+Isradipine group were similar to the control group. PCNA(+) cells in the islets of Isradipine group were significantly higher than the other groups ($p<0,001$). GRP78 ($p<0.01$) and caspase-3 ($p < 0,001$) positive cells increased in the islets of n-STZ diabetic group. Apoptotic cells were not seen in islets, mainly observed within exocrine tissue cells.
Isradipine, provides beneficial effects to prevent cell apoptosis via ER stress, and rearranges islet morphology in neonatal streptozotocin diabetic rats.

Keywords: Apoptosis, Endoplasmic reticulum stress, Neonatal STZ diabetic rat, Pancreas, Isradipine

10.5505/2017ichc.PP-88 [Techniques in immunohistochemistry]

Immunohistochemical distribution of ghrelin positive cells in the abomasum of sheep

Nesrin Özfiliz[1], Şerife Tütüncü[2], Hatice Erdost[1]

[1]University of Uludağ, Bursa, Türkiye

[2]University of Ondokuz Mayıs, Samsun, Türkiye

Introductıon and OBJECTIVES: Ghrelin is a novel peptide isolated from the rat and human stomach. Many investigations, most of which were biochemical and physiological have been published since then ghrelin was identified in 1999. In only a few histological studies ghrelin producing cells were immunohistochemically identified in the gastrointestinal tract. In this study, distrubition of ghrelin immunoreactive cells in the abomasus of sheep was investigated.
MATERIAL-METHODS: Awassi sheep were used in the study. The abomasum pieces were removed from 4 sheep after slaughtering and fixed with Bouin solution. Immunostaining was performed with a labelled avidin- biotin technique using polyclonal ghrelin antibody.
RESULTS: The present study showed that ghrelin immunpositive cells scattered throughout the mucosal layer of abomasum.
The cardia Region: Ghrelin immunopositive reaction was granular and located in intracytoplasmic and peculiar to perinuclear region of the glandular cells(Fig.1a, 2a).
The fundus Region: Ghrelin immunopositive reaction was granular and located in the cytoplasm, specifically in the apical region of the glandular cells(Fig.1b, 2b).
The proximal region of pylorus: Ghrelin immunopositive reaction was granular and located in the cell nucleus and paranuclear cytoplasm of the glandular cells (Fig.1c, 2c).
The main/distal pylorus: Ghrelin immunopositive reaction was granular and located in the cell nucleus and paranuclear cytoplasm of both glandular and surface epithelial cells (Fig.1d, 2d).
Negative controls did not give any spesific immunostaining for Ghrelin(Fig. 1e).
CONCLUSION: Wada et al. reported that ghrelin immunopositive cells were found in the mucosal layer of proventriculus. Rindi et al. demonstrated that ghrelin immunoreactive cells, in the human, canine and rodent stomach. Our results were consistent with those reports. Ghrelin immunopositive cells scattered troughout the mucosal layer of abomasum in the glandular stomach. Results of the previous studies on the ghrelin m RNA distrubition and ghrelin gene expression support our immunohistochemical results.
We have demonstrated that ghrelin immunopositive cells scattered throughout the mucosal layer of the sheep abomasum.

Keywords: Abomasum, Ghrelin, immunohistochemistry, sheep

Figure 1,

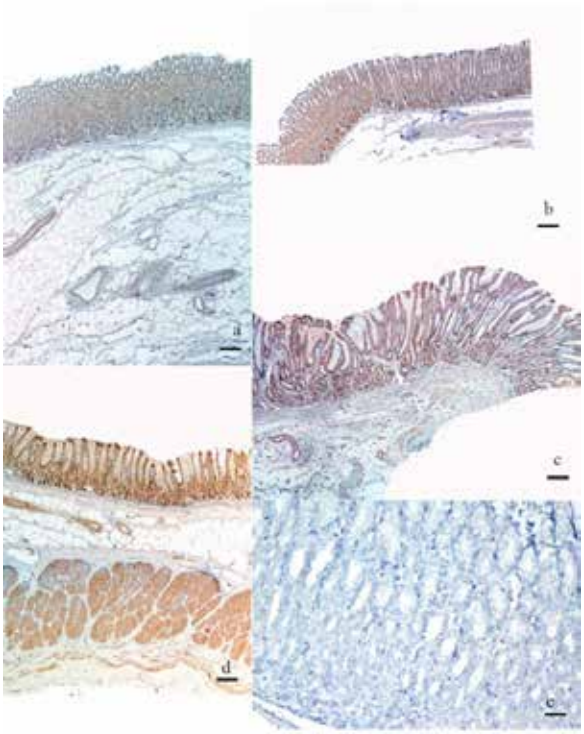

Figure 1. a, b, c, d. General view of cardia, fundus, proximal pylorus, and distal pylorus regions, Bar 350 µm, e. Negative control, Bar 140µm

Figure 2

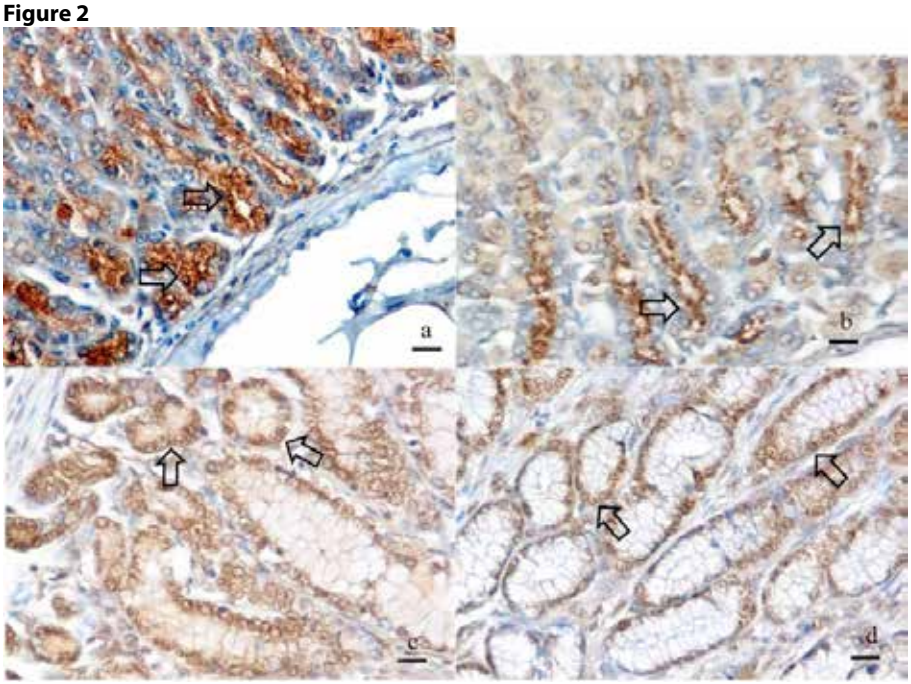

Figure 2. a, b,c, d. Ghrelin immunopositive reaction in cardia, fundus, proximal pylorus and distal pylorus regions, Arrows, Bar 35µm

10.5505/2017ichc.PP-89 [Techniques in immunohistochemistry]

The Effects of Cinnamon Extract Supplementation on Immunolocalization of Glial Cell Line Derived Neurotrophic Factor (GDNF) in Testis of Diabetic Rats

Buket Bakır[1], Şükran Yediel Aras[2], Hasan Asker[2], Sevda Eliş Yıldız[3], Ebru Karadağ Sarı[4]

[1]Department of Histology and Embryology, Faculty of Veterinary Medicine, Namik Kemal University, Tekirdag, Turkey

[2]Department of Histology and Embryology, Healthy Sciences Institute, Kafkas University, Kars, Turkey

[3]School of Health Sciences, Kafkas University, Kars, Turkey

[4]Department of Histology and Embryology, Faculty of Veterinary Medicine, Kafkas University, Kars, Turkey

The objective of this study was to determine whether cinnamon extract supplementation effects the immunolocalization of glial cell line-derived neurotrophic factor (GDNF) in the testis of diabetic rats. Sprague Dawley rats were divided randomly into five groups of six animals each as follows: control, sham, diabetes, cinnamon and diabetes+cinnamon. The control group received nothing, the sham group received intraperitoneally (i.p.) 50 mg/kg sodium citrate, the diabetes group was administered i.p. 50 mg/kg Streptozotocin (STZ) (dissolved in 50 ml citric acid+40 ml of disodium hydrogen phosphate buffer (pH: 4.5)) and the treatment groups (cinnamon and diabetes+cinnamon) received cinnamon extract (200 mg/kg by oral gavage) for 14 days. Streptavidin-Biotin-Peroxidase Complex method was used to investigate GDNF immunoreactivity in the rat testis. It was observed GDNF immunoreactivity was localized in the interstitial space in Leydig cells, the cells of the spermatogenic series (primer, seconder spermatocyte and spermatid). In conclusion, when compared to all groups, cinnamon extract administration was determined to increase the secretion of GDNF, which is known a regulator effects of spermatogonial differentiation in testicular tissue.

Keywords: Cinnamon, diabetes, GDNF, immunohistochemistry, testis

10.5505/2017ichc.PP-90 [Techniques in immunohistochemistry]

Allantoin, a purine metabolite, enhances regeneration of peripheral nerve following sciatic nerve injury in rats: stereological and immunohistochemical study

Burcu Delibaş, Mehmet Emin Önger
Department of Histology and Embriyology, Ondokuz Mayis University, Samsun, Turkey

Introduction & OBJECTIVES: Allantoin has numerous widely cited pharmacological purposes, including tissue regeneration and cell proliferation. Axonal regeneration is possible following the axonal injury. In this context, neuroprotective agents may increase the axonal regeneration. In this study; we investigated the possible functional and morphological effects of allantoin on sciatic nerve regeneration.
Materials & METHODS: The experimental injury model was designed with a force of 50 Newtons during 5 seconds with the help of pliers on the right sciatic nerve of rats in test group. Allantoin was administered intraperitoneally (10 mg/kg) to the test groups during 30 days following injury. Animals were sacrificed at the end of 30 days and nerve samples taken from animals were evaluated in terms of myelinated axon number, myelin sheath thickness, and axon diameter stereologically, in addition to immuhistochemical observation. The Electromiyography (EMG) and Sciatic Function Index (SFI) tests also were performed.
RESULTS: According to stereological evaluations no differences were found between allantoin given group and only crush group in base of myelinated axon number, myelin thickness, axon diameter and myelin thickness/axon diameter ratio. On the other hand, there were significant differences between two groups in increasing way in point of both amplitude and S100 expression levels.
CONCLUSIONS: The i.p. administration of allantoin may have beneficial effect on nerve healing.

Keywords: allantoin, peripheral nerve, stereology, s100

Fig 1

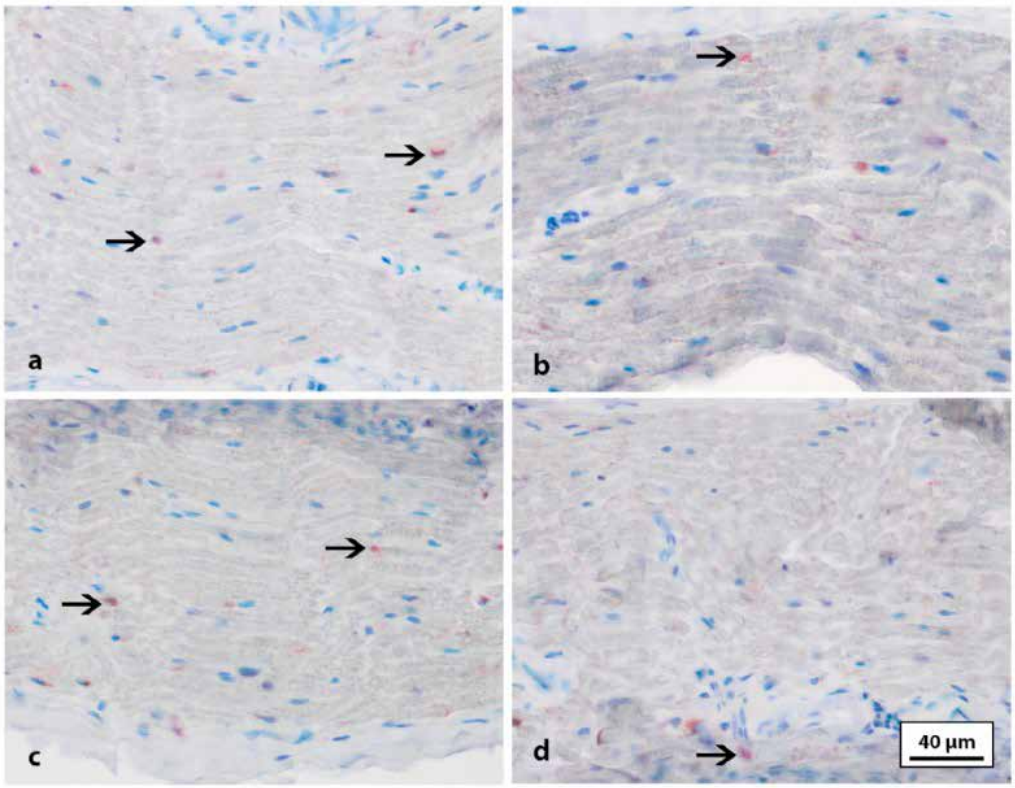

a. control, b crush, c. allantoin, d. crush+allantoin. The arrows shows the s100 expression in each group

Fig 2

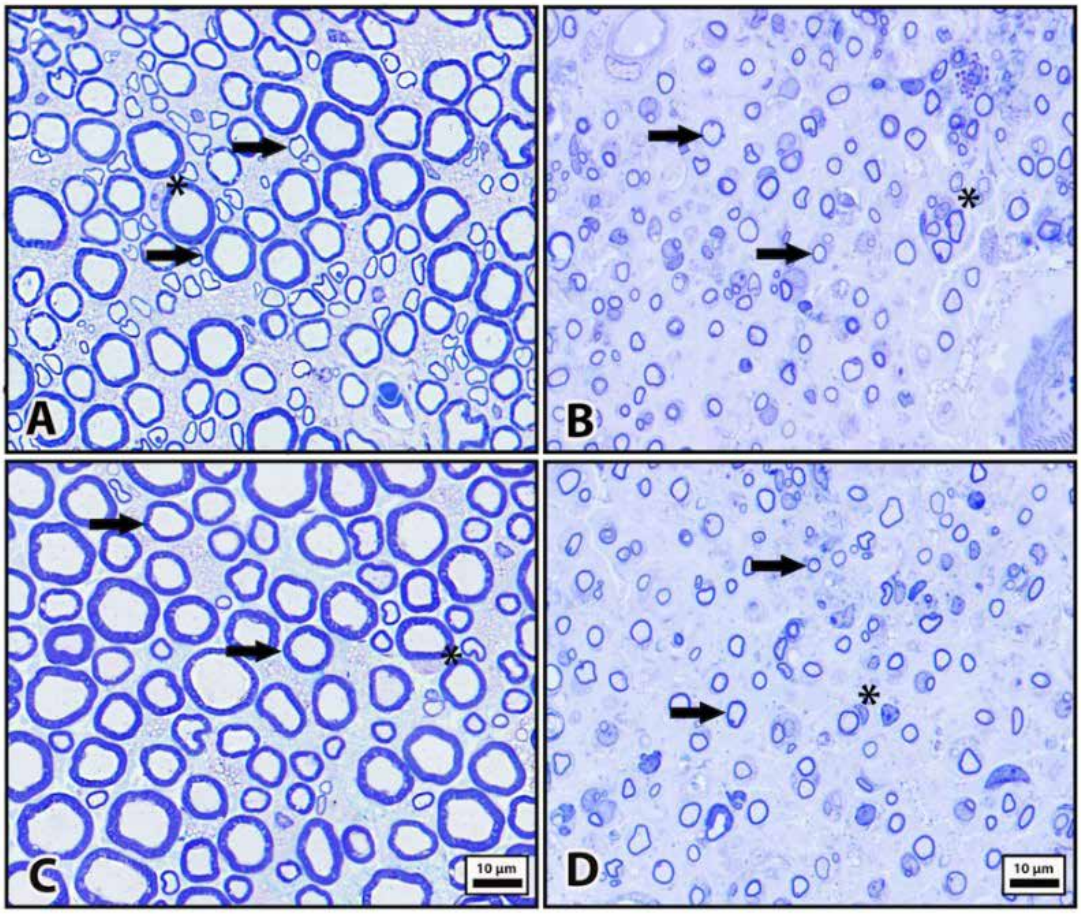

a. control, b. crush, c. allantoin, d.crush+allantoin. The arrows indicate myelinated nerves, asteriks(*) indicates Schwann cels

10.5505/2017ichc.PP-91 [Techniques in immunohistochemistry]

Distribution of Class II Major Histocompatibility Antigens in the Ductus Deferens of the Adult Bull and Ram

Berna Güney Saruhan[1], Serkan Erdoğan[2], Uğur Topaloğlu[1], Mehmet Erdem Akbalık[1], Muzaffer Aydın Ketani[1], Hakan Sağsöz[1]

[1]Dicle University Veterinary Medicine Faculty,Histology and Embriyology, Diyarbakır

[2]Namık Kemal University Veterinary Medicine Faculty, Histology and Embriyology, Tekirdag

MHC class II molecules thereby are critical for the initiation of the antigen-specific immune response. In this study, we investigated the distribution of MHC II-positive cells in the normal bull and ram ductus deferens (DD) using an immunohistochemical technique. The tissue samples of taken from 8 of the healthy and mature male bull and ram were collected from a local slaughterhouse. Streptavidin-biotin peroxidase complex staining was used to detect MHC II + cells. MHC II + cells were found in the surface epithelium, connective tissue, smooth muscle cell and some endothelial cells of the vessels in both species. In conclusion the present findings exhibited a specific pattern of distribution for MHC II proteins under study, suggesting a variable functional significance of the DD in the two different animal species.

Keywords: Ductus deferens, Bull, Immunohistochemistry, MHC Class II, Ram.

10.5505/2017ichc.PP-92 [Techniques in immunohistochemistry]

Expression of TLR2 in Sheep Ileum during Prenatal Development

Mehmet Özbek[1], Emel Ergün[2], Feyzullah Beyaz[3], Levent Ergün[2], Nuh Yıldırım[2], Özge Özgenç[2], Füsun Erhan[2]

[1]Mehmet Akif Ersoy University, Faculty of Veterinary Medicine, Department of Histology and Embryology, Burdur, Turkey

[2]Ankara University, Faculty of Veterinary Medicine, Department of Histology and Embryology, Ankara, Turkey

[3]Erciyes University, Faculty of Veterinary Medicine, Department of Histology and Embryology, Kayseri, Turkey

Introduction: The intestines are the biggest defense barrier of our bodies. More than 60% of immune cells are found in the intestinal mucosa and are ready to identify and control the presence of potential aggressors and prevent uncurbed inflammatory reactions. Toll like receptors (TLR), which are family of pattern recognition receptors, make a big contribution in repressing the activation of the inflammatory cascade to continue the stabilize of intestinal homeostasis and in promoting inflammatory responses to pathogens.
This study was conducted to examine the localization and expression of TLR2 in the prenatal period in the sheep ileum.
Materials & Methods: In this study, the distal ileums from ten sheep fetuses with gestational ages varying between 63 and 147 days were used as a material. Distal ileal tissue samples were fixed in Bouin's solution and passed through the standart histological procedures, and then embedded in paraffin. Immunohistochemical staining was performed with the primary antibody to TLR2 by using StreptAvidin Biotin (Strep-ABC) method.
Results: In the early stages of the prenatal period TLR2 expression was intensively observed on apical surfaces of intestinal epithelial cells. It was noted that this immunological reaction in intestinal epithelial cells diminished towards the end of the prenatal period. Cells with a strong cytoplasmic positive reaction were found among the intestinal epithelial cells. It was observed that the number of these cells increased towards the end of the prenatal period. Immunological reaction were observed the smooth muscle cells forming tunica muscularis and lamina muscularis at all period.
Conclusion: The appearance of TLR2 expression in sheep during the fetal period suggests that the innate immun system before birth is well prepared against bacterial invasion in the neonatal period. Strong positively responsive cells between the intestinal epithelial cells resemble enteroendocrine cells when literature reviews and cell morphology are taken into consideration.

Keywords: Ileum, Sheep, TLR2

10.5505/2017ichc.PP-93 [Techniques in immunohistochemistry]

Exploration of protein expression by immunohistochemistry of Toll-like receptor 2 (TLR 2) in rat testis and epididymis during postnatal development

Mehmet Özbek[1], Emel Ergün[2], Feyzullah Beyaz[3], Levent Ergün[2], Nuh Yıldırım[2], Özge Özgenç[2], Füsun Erhan[2]

[1]Mehmet Akif Ersoy University, Faculty of Veterinary Medicine, Department of Histology and Embryology, Burdur, Turkey

[2]Ankara University, Faculty of Veterinary Medicine, Department of Histology and Embryology, Ankara, Turkey

[3]Erciyes University, Faculty of Veterinary Medicine, Department of Histology and Embryology, Kayseri, Turkey

Introduction & Objectives: The testis is an immunoprivileged site, where the local cell-initiated testicular innate immune responses play a crucial role in defense against microbial infections. Toll-like receptors, which are members of pattern recognition receptors, are of great importance in ensuring the continuity of this protected environment of the testis.
This study was conducted to examine the localization and expression of TLR2 in the postnatal period in the rat testes and epididymis.
Materials & Methods: Wistar albino rat testis and epididymis tissues were used as material. Each of the four groups composed of six rats were designed as prepubertal (5 days), pubertal (20 days), postpubertal (50 days) and mature (70 days). The streptavidin–biotin complex (Strept-ABC) immunoperoxidase technique was employed to detect immunohistochemical localization of TLR2 in testes and epididymis.
Results: At 5 old day rats, expression of TLR2 was observed in peritubular myoid cells and TLR2 expression started to appear in some primary spermatocytes at 20 day old rats testis. At 50 day old rats, TLR2 expression was defined some spermatogenic cells in the tubules at various stages and at 70 day old day rats, Immun reaction was determined in both some spermatogenic cells and Sertoli cells. Some interstitial cells with weak immunoreactions were observed in all periods, while intense reaction of blood cells was observed. In epididiymis, TLR2 expression was observed some cells in connective tissue and some epithelial cells of epididymis.
Conclusions: The appearance of TLR2 in Sertoli cells after puberty suggests that TLR2 may contribute to the development of spermatogenic cells as well as being involved in innate immunity.

Keywords: Epididymis, Testis, TLR2,

10.5505/2017ichc.PP-94 [Techniques in immunohistochemistry]

The Effects of Cuminum Cyminum Supplementation on Interleukin 17 Secretion in Liver Tissue of Mice

Sevda Eliş Yıldız[1], Buket Bakır[2], Pınar Aksu Kılıçle[3], Hasan Asker[4], Süleyman Gül[5], Ebru Karadağ Sarı[6]

[1]Department of Midwifery, Faculty of Health Sciences, Kafkas University, Kars, Turkey

[2]Department of Histology and Embryology, Faculty of Veterinary Medicine, Namik Kemal University, Tekirdag, Turkey

[3]Department of Biology, Faculty of Science and Letters, Kafkas University, Kars, Turkey

[4]Department of Histology and Embryology, Healthy Sciences Institute, Kafkas University, Kars, Turkey

[5]Department of Molecular Biology and Genetics, Faculty of Science and Letters, Kafkas University, Kars, Turkey

[6]Department of Histology and Embryology, Faculty of Veterinary Medicine, Kafkas University, Kars – Turkey

The World Health Organization (WHO) estimates that 4 billion people, 80 percent of the world population, presently use herbal medicine for some aspect of primary health care. Cuminum cyminum showed wide range of pharmacological activities including antimicrobial, insecticidal, anti-inflammatory, analgesic, antioxidant, antidiabetic, anticancer, antiplatelet aggregation, hypotensive, contraceptive, immunological, anti-osteoporotic, bronchodilatory and many other pharmacological effects. The objective of this study was to investigate the effects of Cuminum cyminum on the liver distribution of interleukin 17 in mice. At the beginning of the experiment 16 female mus musculus mice were randomly divided into 2 groups as follows: control, and Cuminum cyminum group. While Cuminum cyminum group received 500 mg/kg of Cuminum cyminum extract which injected for 2 days. The control group received nothing. Crossman's triple staining was applied to tissue sections to examine histological structure of the liver. Streptavidin-Biotin-Peroxidase Complex method was used to investigate interleukin 17 immunoreactivity in the liver tissue. In terms of the histological structure of the liver, similar results were observed in the mice in the control, and Cuminum cyminum no different result was found. Interleukin 17 immunoreactivity was observed in each groups. Interleukin 17 immunoreactivity was diffusely observed in cytoplasm of the hepatocytes. Interleukin 17 immunoreactivity in the Cuminum cyminum group was slightly weaker than in the control group. In conclusion, when compared to Cuminum cyminum extract administaration was determined to decrease the secretion of interleukin 17, which is interleukin 17, has been implicated in liver, lung and skin fibrosis and tumorigenesis.

Keywords: Cuminum cyminum, Interleukin 17, liver, immunohistochemistry

10.5505/2017ichc.PP-95 [Techniques in immunohistochemistry]

Immunohistochemical Investigation of Trk-A Receptor Levels in Pancreatic Tissue of Cumin (Cuminum cyminum) Plant Essential Oil Treated-Mice

Şükran Yediel Aras[1], Buket Bakır[2], Sevda Eliş Yıldız[3], Pınar Aksu Kılıçle[4], Süleyman Gül[5], Ebru Karadağ Sarı[6]

[1]Department of Histology and Embryology, Institute of Health Sciences, Kafkas University, Kars – Turkey.

[2]Department of Histology and Embryology, Faculty of Veterinary Medicine, Namik Kemal University, Tekirdag- Turkey.

[3]Department of Midwifery, Faculty of Health Sciences, Kafkas University, Kars – Turkey.

[4]Department of Biology, Faculty of Science and Letters, Kafkas University, Kars – Turkey.

[5]Department of Molecular Biology and Genetics, Faculty of Science and Letters, Kafkas University, Kars – Turkey.

[6]Department of Histology and Embryology, Faculty of Veterinary Medicine, Kafkas University, Kars – Turkey.

This study was carried out to immunohistochemically investigate Trk-A receptor levels in the pancreas tissue of cumin (Cuminum cyminum) plant essential oil treated-mice. Twenty, eight-week-old female mice (Mus musculus) weighing 20 ± 1 gr. were used in the study. Mice were grouped into control group (n = 10) and treatment group (n = 10). Mice were fed ad libitum and were given free access to tap water. No intervention was performed to the mice in the control group. The rats in the experimental group were treated with 500 mg/kg of oral cumin essential oil every 24 hours for two days. At the end of the study, mice were sacrificed by cervical dislocation, and obtained pancreatic tissues were blocked in paraffin following routine histological processes. Triple staining was performed to sections taken from these blocks to examine the general histological structure of the pancreas. Immunohistochemical method was applied to determine Trk-A immunoreactivity in pancreatic tissue. Acini, intercalated ducts, interlobular ducts and excretory ducts were determined in the mouse pancreas. Immunohistochemical studies showed that all mice had Trk-A immunoreactivity in pancreatic tissue. Moderate immunoreactivity in the acini and weak immunoreactivity in the Langerhans islets and excretory ducts was detected in the pancreas tissue of mice in the control and treatment groups. Based on immunohistochemical results, it was concluded that cumin, which has diuretic, digestive system regulating, digestive facilitator, antimicrobial and antidiabetic effects in conventional medicine, has no effect on the level of Trk-A receptor release, which is secreted by pancreas and reported to regulate insulin metabolism.

Keywords: Cumin, pancreas, Trk-A

10.5505/2017ichc.PP-96 [Techniques in immunohistochemistry]

Extraction of Natural Histological Dye from red cabbage (Brassica oleraceae) and investigation of its staining property on the onion root cell

Nilgün Güler Kuşçuluo[1], H.Güzin Aslan[2], Nurhan Cücer[3]

[1]Erciyes Üniversity, Mustafa Çıkrıkçıoğlu Vocational School, Department of Chemistry Technology,Kayseri,Turkey

[2]Erciyes Üniversity, Faculty of Science, Department of Chemistry,Kayseri,Turkey

[3]Erciyes Üniversity, Faculty of Medicine,Department of Medicinal Biology , Kayseri,Turkey

Abstract: We performed staining onion root cell nuclei using natural dye, mordant and salicylic aldehyte by new procedure. The natural dye source was red cabbage (Brassica oleraceae), potassium aluminum sulfate (alum=KAlSO4) was used as mordant or metal salt. Distilled water was used as solvent. Both fresh and clean red cabbage leafs were extracted with distilled water at 100°C for 30 minutes and filtred. 1-3 Onion roots were stained in red cabbage extract with/without alumat 50°C for 90 minutes. After onion root cell was reacted with salicylic aldehyte.Staining procedure was repeated in alum and non alum media. But there was no staining in onion root cell nuclei. We conclude that red cabbage has potential as an alternative dye only with alum, without salicylic aldehyte for staining nucleus of biological materials.
Introduction: There are four primary sources from which natural dyes are available: plants, animals,minerals and soil[1,2]. Many plants and some animals have been identified as potentially rich in natural dyes or dye producers, and some of them have been used for natural dyeing for along time (3).Natural dyes are mostly derived from plant sources and they have used in textile, food, cosmetic, pharmaceutical and histological fields [2]. When there was no direct interaction between dyeing material and the dye stuff, various metal salts were used known as mordant agents like KAlSO4, FeSO4, CuSO4, so that obtained bright, dark colored materials [4,5].Some of the natural biological dyes such as carmine from cochineal (Dactylopius coccus) and hematoxylin from the logwood tree (Haematoxylum campecianum L.) are used for microscopy (6, 7). Another natural source is red cabbage whose leafs contain cyanidinemolecule whichhas the property of antioxidants and vitamins is shown in Figure 1. Cyanidine has chromophore (colorants) and oxochromo (color enhancer and linker) groups. These groups are shown in Table 1. So that it has a good dyeing and the indicator property (8).

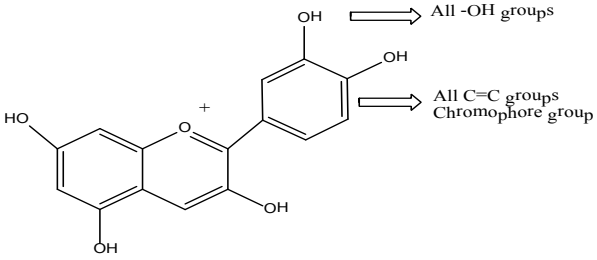

Figure 1.The Cyanidine Structure

KROMOFOR GRUPLAR		OKSOKROM GRUPLAR	
-N=N-	Azo	$-NH_2$	Amino
C=O	Carbonyl	-NHR $-NR_2$	Sübstitüe Amino
N(=O)=O	Nitro	-OH	Hydroxyl
		-SH	Thio alcohol
C=C	Ethylene	$-OCH_3$	Metoxy
C=S	Thioaarbonyl	$-SO_2H$	Sulphonic acid
-N=O	Nitroso	$-O-C_6H_5$	Phenolic

Table 1. Structure of oxochromo and chromophore groups

There are various proteins and molecules having structure of protein in the nucleus, cytoplasm and membranes of eukaryotic lives but Histone proteins are been only in cell nucleus. So that histone proteins have been thought coloring according to dyeing results which is occured only nucleus region [9].
In our previously study, we obtained from madder root extracts and we were stained Chromatin in the onion root cell nucleus. But we could

not clarify that was dyed with DNA, histone proteins in the chromosome structure ,non-histone proteins or amino acids[10]. In this study, dyeing proces is occured in nucleus by different plant extract and lowest temperature. As a first step staining of onion root cell with red cabbage extract with alum and non alum. At second step, onion root assembled with a number of chemical processes and then this cell stained in red cabbage extract with/ without Alum. Therefore, objective of this study was toinvestigate the extraction of natural dye from red cabbage(Brassica oleraceae) with distilled water and using alum, salicylic aldehyte,and then its staining property on the nucleus of onion root cell at suitable pH and temperature.

Materials and Methods

Materials: All the common laboratory chemicals used in the synthesis of the substance was purchased from commercial sources and used without further purification.

Preparation of plant extract: Red cabbage, obtained from Bafra (Samsun, Turkey) homogenized using IKA T-18 homojenizatör 20 gram from this pieces was placed into a beaker and 100 mililiters (w/v 20%) of distilled water was added. The mixture was boiled on hot plate for 30 minutes and filtered. The filtrate was stored in refrigerator at 4°C and was used for staining.

Utilization of Onion Root

The head part of onions was dipped in the beaker with water. After two days, when the new roots appeared, approximately 1- 1.5 cm of root tips were cut and transferred into a glass with 70% ethyl alcohol containing glass bottle. Root tips are stored at 4oC until dyeing.

Dyeing of Onion Root Cells: Three Eppendorf tubes were taken. Double experiment set was as fallows. One mL of dye extract was added into the first tube, 1 mL of dye extract and 0.05 g alum were added in to the second tube, and 2 pieces of onion root were placed into each tube. Each set were placed in water baths, at 50oC. Incubation with the 90 minutes duration. After the dyeing incubation time ends, root tips washed with distilled water then placed on to clean microscope slides. After putting cover slides on to the microscope slide onion root piece is squashing between the slide and cover slide. Photography of cells on the slides are determined and taken by light microscopy. These photographs are included in Figure 2.

Reaction of Onion root cell with salicyclic aldehyde: Onion root piece was subjected to the reaction with salicyclic aldehyde in ethanol 10% at 50°C above magnetic stirrer for seven days. The progress of the reaction by the precense of salicyclic aldehyde's odoor and structure of onion root pieces were followed by observing with microscope. At the end of the seventh day it is observed that the reaction wasn't occured. So that reaction was repeated by crushing of onion root pieces in agate mortar. The reaction was terminated when the characteristic odor of aldehyde disappeared and observed the more swollen state of onion roots. Cell dyeing procedure was applied to onion root pieces which are treated in this way.

Result and Discussion: The cell nuclei obtained from onion roots were stained with red cabbage extract in alum media. We understood that the painting without alum media was no succeed. This position was evident by microscopic examination. Figure 2 (a and b) is also included painted with red cabbage extract pictures of the cells nucleus derived from onion root with alum and without alum media. In other stage of our study, Onion root cell also were stained with named hematoxylin dye stuff. Hematoxylin dye stuff is sold at market. Nucleus of onion root cells stained blue color with red cabbage extract. At the same time nucleus of onion root cells stained purple-blue color with hematoxylin. This position is shown in figure 2(c). As it is shown from the pictures that stained with red cabbage extract nuclei of onion root cells are more clearly and the cell walls are more smooth.



(a) (b) (c)

Figure 2: Photographies of dyed onion root cells with red cabbage extract and Hematoxylin X100. (a)With Alum (b) Without Alum (c) Hematoxylin: Dyeing temperature was determined as 50°C for not causing the denaturation of the cell structure. Staining is not observed at temperatures below 50°C. We didn't study at 80°C temperatures because of the denaturation of cells. pH screening of dyeing was performed by painting work done in the 3-11 range. According to the results the optimum dyeing condition was determined as pH 6-8.

Red cabbage extract has dyestuff feature, because of –OH groups of Cyanidine molecule's. These are interacting with metal atoms in metal salt so chelat complexes are occured and the appearing chelate complexes are being colour in visible region. So that nucleuses of onion root cells which staining with red cabbage extract and alum were observed to be blue colour in light microcopy.The interesting aspect of our this study, at result reaction with salicylic aldehyde of onion root cells dyeings were realized in alum or non alum media. In this situation salicylic aldehyde was entered to reaction with NH2 which being R gruops of aminoacids in cell nucleus and was shutted to effective region, it can not interact with cells in this region, so chelat doesn't formate. For this reason, dyeing was not realized. To explain our this thinking, informations which will be light interaction of dyestuffs's with different aminoacids in cell nucleus will replace in our other publication.



(b) (c)

Figure 3: After dyeing light microscopy images of onion root cells which reacted with salicylic aldehyde and dyeing with red cabbage extract. (a) Dyeing with Alum (b) Before dyeing (c) Dyeing without Alum

When NH2groups of onion root cells were reacted by salicylic aldehyde. They were been inactive position. Inactivated cells stained with red cabbage extract. Staining of cell nucleus with alum and without alum media was not observed. This situation was showed in Figure 3. And at this position, NH2groups of histone protein's aminoacids which are being alot of numerous in cell nucleus are reacted with salicylic aldehyde then, cutting of chemical interaction with dyestuff is indicated. This situation will be explained in our second publication. It will be published with detail After our this publication.

Conclusion: In this performing publication. Obtaining onion root cells stained with red cabbage extract. In Studying optimum conditions were determinated as 50°C and pH range of 6-8. At the same time, this pH range is to studying range of many complex formation reaction. At first stage, pictures of cells which was stained with commercial dye named hematoxylin were compared with our staining cell pictures in this publication. Nucleus which stained with hematoxylin is more purple, nucleus which stained with red cabbage extract is seen as the most blue. At the second step. Cells are reacted with salicylic aldehyde. At result of this reaction, After physical processes, being some physical changes at onion root cells were seen not to occured dyeing in alum and non alum conditions. This case takes a base from amino acid ends of histon proteins which reacted with salicylic aldehyde and inactivated. At the moment, in our second study which currently going on this case was examinated as with detail by spectrofotometric methods. The red cabbage could be used as an alternative natural dye for histological nucleus staining with alum mordant.

REFERENCES

1- Cardon D. Natural dyes - sources, tradition, technology and science. Archetype Publications Ltd. London, 2007: 655-656.
2- Saxena S and Raja A.S.M. Natural Dyes: Sources, Chemistry, Application and Sustainability Issues. Springer Science 2014: 37-39.
3-Weiss W. Natural dyes: an international pursuit: a report on color congress. Surf. Design J.2002;27:12-15.
4-Uddin M.G. Effects of Different Mordants on Silk Fabric Dyed with Onion Outer Skin Extracts. Journal of Textiles. 2014; 1-8.
5-Swami C, Saini S and Gupta V.B. Extraction of a Natural Dye from Sesbania aculeata Plant. Journal of Textile and Apparel Technology and Management. 2012; 7 (4): 1-10.
6-Rodriguez LC, Mendez MA, Niemeyer HM. Direction of dispersion of cochineal (Dactylopius coccus Costa) with in the Americas. Antiquity. 2001; 75: 73-77.
7-Llewellyn BD. Stains File: a resource for histotechnologists/ dyes. Swehsc.pharmacy.arizona.edu/exppath/micro/histology.html (2003).
8- Chigurupati. Red cabbage dye for pharmaceutical use. Int. J.Pharm. 2002; 241(2): 293-299.
9- Campbell P.N. The targeting of proteins in Eukaryotic cells. Biochemical Education. Wiley Online Library 2010; 17(3): 114-116.
10- Cücer N. Guler N."Staining human lymphocytes and onion root cell nuclei with madder root"Biotech Histochem. 2005;80 (1): 15-20.

Keywords: Stain,Red cabbage, Brassica oleraceae

10.5505/2017ichc.PP-97 [Techniques in immunohistochemistry]

The protective effect of thymol against cisplatin-induced ototoxicity: An experimental animal study

Ilker Kocak[1], Ömer Faruk Ünal[1], Esra Aydoğan[1], Remzi Doğan[2], Dilek Akakın[3], Kutay Koroglu[3], Ömer Faruk Özer[4]

[1]Department of Otolaryngology, Koc University Hospital, Istanbul, Turkey

[2]Department of Otolaryngology, Bezmialem Vakif University Hospital, Istanbul, Turkey

[3]Department of Histology and Embryology, Marmara University School of Medicine, Istanbul, Turkey

[4]Department of Biochemistry, Bezmialem Vakif University, Medical Faculty, Istanbul, Turkey

INTRODUCTION and OBJECTIVES: This study aimed to assess the protective effect of thymol against cisplatin- induced ototoxicity via an evaluation of audiological, biochemical and histopathological parameters.
MATERIALS-METHODS: A total of 32 male rats were divided into four groups (control, cisplatin, thymol + cisplatin, and thymol) including eight rats each. 150 mg/kg/day thymol was given for 5 days, via oral gavage. Single-dose cisplatin (16 mg/kg) was also intraperitoneally administered. Distortion product otoacoustic emission (DPOAE) and auditory brainstem response (ABR) tests of both ears were carried out in all groups at the beginning of the study and also on day 6. Intracardiac blood samples were taken from the rats, and their cochleas were harvested, on day 6, in order to assess biochemical parameters including total oxidant status (TOS) and total antioxidant status (TAS) and histopathological parameters including outer hair cell (OHC) and stria vascularis damage and terminal deoxynucleotidyl transferase-mediated deoxyuridine triphosphate nick-end labeling (TUNEL).
RESULTS: On day 6, significant decreases in DPOAE values and significant increases in ABR thresholds were observed in group 2 (cisplatin), compared with the other groups ($p<0.001$). There was no significant difference between the pre- and post-treatment DPOAE and ABR results in groups 1 (control), 3 (thymol + cisplatin), and 4 (thymol) ($p>0.05$). Biochemichal analyses revealed that the TOS was significantly higher in group 2 (cisplatin) than in the other groups ($p<0.001$). The TAS value was significantly higher in group 3 (thymol+cisplatin) than in group 2 ($p=0.001$). The histopathological examinations of cochlea tissue showed that the stria vascularis and OHC injury scores were statistically significantly higher in group 2 (cisplatin) than in the other groups ($p<0.001$). In addition, a significant reduction in OHC and stria vascularis damage was observed in group 3 (thymol+ cisplatin) compared to group 2 (cisplatin) ($p<0.05$). Furthermore, there was significant reduction of the number of TUNEL-positive cells in group 3 (thymol+cisplatin) compared to group 2 (cisplatin) ($p<0.05$).
CONCLUSIONS: The audiologic tests, biochemical results and histologic findings revealed that thymol may exert a protective effect against cisplatin ototoxicity by increasing antioxidant levels and reducing oxidative stress parameters.

Keywords: Cisplatin, Thymol, Ototoxicity, Oxidant status, Antioxidant status, Apoptosis

10.5505/2017ichc.PP-98 [Techniques in immunohistochemistry]

Enhancing potential territories of the lateral thoracic artery based perforator flap via injections of adipose-derived stem cells

Asiye Kübra Göksu[1], Arzu Akcal[2], Tahsin Gorgulu[3], Kerim Unal[2], Nuray Erin[4], Gamze Tanriover[1]

[1]Akdeniz University, School of Medicine, Department of Histology, Antalya, Turkey

[2]Akdeniz University, School of Medicine, Department of Plastic and Reconstructive Surgery, Antalya, Turkey

[3]Bulent Ecevit University, School of Medicine, Department of Plastic and Reconstructive Surgery, Zonguldak, Turkey

[4]Akdeniz University, School of Medicine, Department of Medical Pharmacology, Antalya, Turkey

Lateral thoracic artery perforator flap is active and potential territories. Lateral thoracic vessels are entire dorsal section flap and much more important territories which provide to survive. Mesenchymal stem cell that multipotent cells has enough capacity to differentiate into mesodermal lineage such as osteocytes, adipocytes and chondrocytes as well ectodermal and endodermal lineages. Adipose-derived stem cells (ADSC) can secrete some cytokines which induce angiogenesis, anti-inflammatory response and anti-apoptosis. The aim of the study is to demonstrate that effects of angiogenesis in lateral thoracic artery perforator flap of the injected adipose-derived stem cells.
Mesenchymal stem cells were obtained from groin region fat tissue of rats following in-vitro culturing for 3 passages. These stem cells were characterized with flow cytometry analyses. The rats were divided into two groups: adipose-derived stem cell injected with PBS treatment group (T) and no injection in control group (C). Immunohistochemical markers were investigated to examine angiogenic properties. The lateral thoracic flaps were removed and evaluated to vascularization and also performed on CD11b (monocyte marker), CD54 (endothelial marker) and VEGFR2 (angiogenesis marker) proteins expression by using immunohistochemical staining. The expression pattern and intensity were evaluated by image-J analysis. All results were compared to control groups.
High levels of CD11b expression was observed in upper layers of skin, hair follicles and sebaceous gland and sudoriferous gland within them in skin flaps of the samples. In epidermis and vascular endothelial cells, macrophages and lymphocytes of dermis, intense CD54 expression was observed. Moderate expression of VEGFR2 in control group was elevated in stem cell injected groups related with the increase in hematopoietic stem cell production and newly formed vasculature.
In conclusion, despite CD11b and VEGFR-2 expressions were increased due to new formed vasculature, CD54 expression was not significantly affected in adipose-derived mesenchymal stem cell injected tissue.

Keywords: Mesenchymal stem cell, Adipose-derived stem cell, Lateral thoracic artery perforator flap.

10.5505/2017ichc.PP-99 [Techniques in immunohistochemistry]

The protective effects of folic acid and propolis aganist the toxic effects of valproic acid on prenatal testicular tissue

Gökşen Derya Relİs Köse, Gökçen Kerimoğlu, Neziha Senem Arı, Cansu Kaya, Esin Yuluğ, Engin Yenilmez
Department of Histology and Embryology, Faculty of Medicine, Karadeniz Technical University, Trabzon, Turkey

INTRODUCTON & OBJECTIVES: Approximately 0.3-0.7 % of pregnant women are epileptic. Seizures during pregnancy can damage the fetus and cause an increase in maternal mortality rate and birth complications. Therefore, antiepileptic use is also continued in pregnancy. Congenital malformations are mostly associated with exposure to antiepileptic drugs. Valproic acid (VPA) is one of the most prescribed antiepileptic drugs. Folic acid (FA) using is important in pregnancy. High dose FA supplementation is recommended for epileptic pregnant women. Propolis is a candle-like resin produced by honey bees. There are some flavonoids in propolis and they have highest free radical scavenging effect. It has been aimed to investigate the protective effects of folic acid and propolis against testicular damage that may occur in rat pups after the use of valproic acid in pregnant rats in this study.
MATERIALS & METHODS: Female and male Sprague Dawley rats weighing 180-250 gr and showing two regular cycles were left to mate. The first day that spermatozoa seen in the vaginal smear was accepted as the beginning of pregnancy. 4 groups were formed. No administration was applied to the control group. Valproic acid, valproic acid+folic acid and valproic acid+propolis were given to other groups respectively every day from 6th day until the birth. Male rats were sacrificed on postnatal 21th day. Then, they were examined histopathologically by using Hematoxylin-Eosin and TUNEL method.
RESULTS: Vacuolization in tubular epithelium, diffuse edema in the interstitial area and immature cells poured into the lumen were observed in the VPA group. In the treatment groups there was a significant improvement in these findings. In terms of the germinal epithelium thickness, a significant decrease was observed in the VPA group compared to the other groups and there was a significant increase in epithelial thickness in the treatment groups. Apoptotic cell number was also significantly increased in the VPA group compared to the control group.
CONCLUSIONS: The results have suggested that the use of VPA during pregnancy causes damage in pups' testes; folic acid and propolis have regenerative effects in testicular tissue. It needs to be supported by new studies at different doses.

Keywords: Testis, Prenatal, Valproic acid, Folic acid, Propolis

Results and evaluation of histological analysis of study groups

	Control	VPA	VPA+FA	VPA+Propolis
	mean± SD	mean± SD	mean± SD	mean± SD
Tubule Diameter	125,77±4,98	125,60±5,45	124,85±7,50	133,12±5,94
Epithelium thickness	46,86±2,47	39,64±2,06<	45,56±2,36<	49,97±2,44<
Apopitotic indeks	12,59±2,47	75,78±22,67<	57,60±3,24<	55,34±6,50<

VPA; (Valproic Acid), FA; (Folic Acid) <: Epithelium thickness was increased significantly compared to the control group (p<0,008) <: Epithelium thickness was decreased significantly compared to the VPA group(p<0,008) <: Apoptotic index was increased significantly compared to the control group(p<0,008)

10.5505/2017ichc.PP-100 [Techniques in immunohistochemistry]

Immunolocalization of ANP and CNP in Healthy and Pre-Eclamptic Human Placental Tissue

Özlem Erekli[1], Mustafa Öztop[2], Kenan Çınar[1]

[1]Department of Biology, Süleyman Demirel University, Isparta, Turkey

[2]Department of Biology, Mehmet Akif Ersoy University, Burdur, Turkey

Pre-eclampsia (PE), the leading cause of maternal and perinatal morbidity and mortality worldwide, affects 2-8% of all pregnancies worldwide. PE is characterized by the onset of hypertension from 20 weeks gestation and is associated with placental dysfunction and widespread maternal vascular endothelium. However, its underlying mechanism has remained elusive so far. C-type natriuretic peptide (CNP) is expressed in the decidua of the mouse placenta while atrial natriuretic peptide (ANP) expression has been demonstrated in the human placenta, especially in the cytotrophoblast tissue.

This study aimed to determine whether preeclampsia affects ANP and CNP expression in healthy and pre-eclamptic human placental tissues. The avidin-biotin complex was applied to 5 µm-thick formalin-fixed, paraffin-embedded human-placenta tissue sections mounted on poly-L-lysine–coated slides to demonstrate ANP and CNP immunoreactivity.

Immunostaining results reveal that weaker ANP and CNP immunoreactivity was in decidual cells of pre-eclamptic individuals. Cytotrophoblast cells had more intense immunoreactivity to ANP and CNP in the preeclampsia. Some blood cells showed immunostaining with ANP and CNP in both preeclampsia and control group. There were ANP and CNP staining in the atheromatous plaques seen in the vessels of preeclamptic patients. Intense immunostaining was observed in extravillous trophoblasts without any significant difference between both groups in terms of staining intensity. Weaker ANP and CNP staining were seen in the chorionic fetal vessels of the control group than of the preeclampsia.

Altered synthesis or action of autocrine or paracrine vasoactive factors such as ANP and CNP in endothelial or vascular smooth muscle cells may mediate changes in vascular resistance in pregnancy. When patients with pre-eclampsia develop hypertension, it may lead to an increase in the synthesis of ANP and CNP synthesized by chorionic vessels. This may act as a compensatory mechanism, thus preventing the fetus from being affected by the preeclampsia. Yet, results from different studies appear to be inconsistent. Our study has also several limitations such as the low number of patients and lack of biochemical data. It is, therefore, difficult to draw firm conclusions from the results, and further studies are needed which will examine a large group of samples.

Keywords: atrial natriuretic peptide, C-type natriuretic peptide, immunohistochemistry, preeclampsia

ANP-control

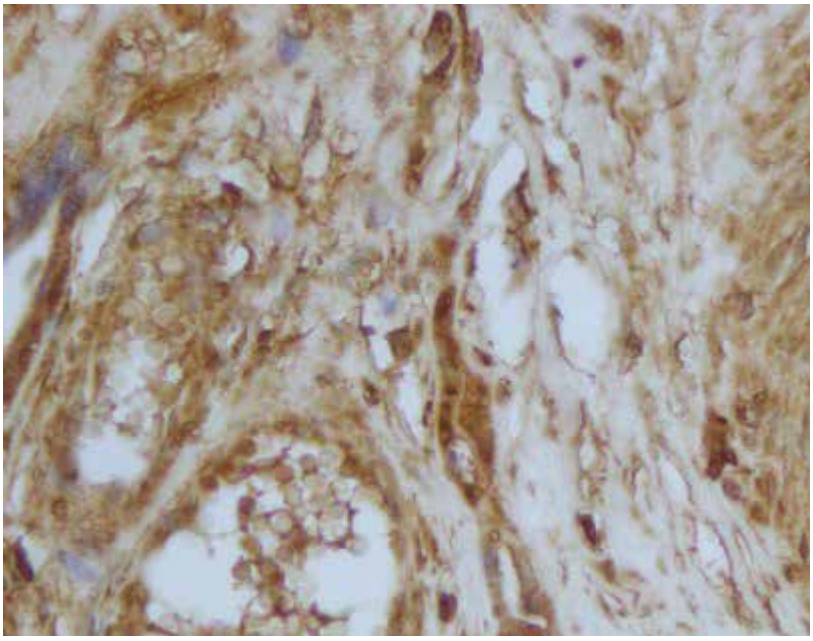

ANP-preeclampsia

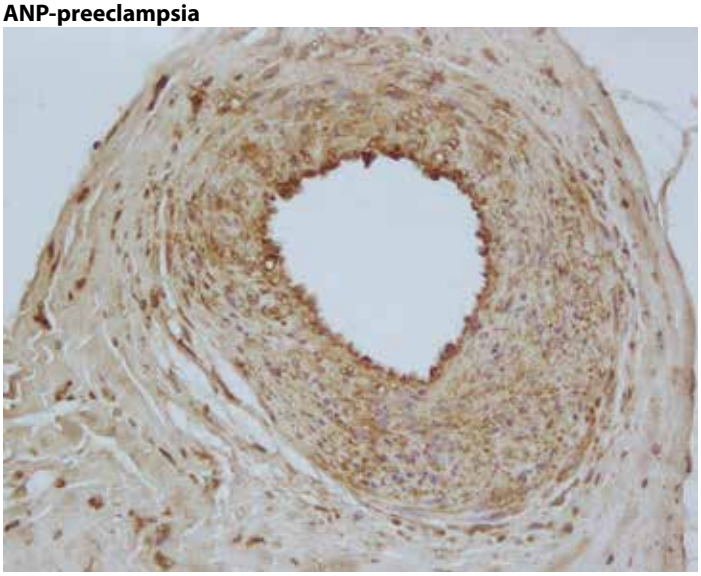

CNP-control

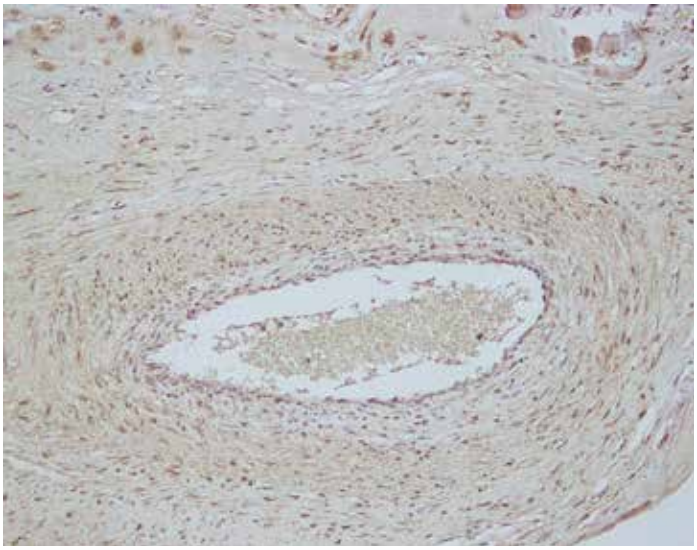

CNP-preeclampsia

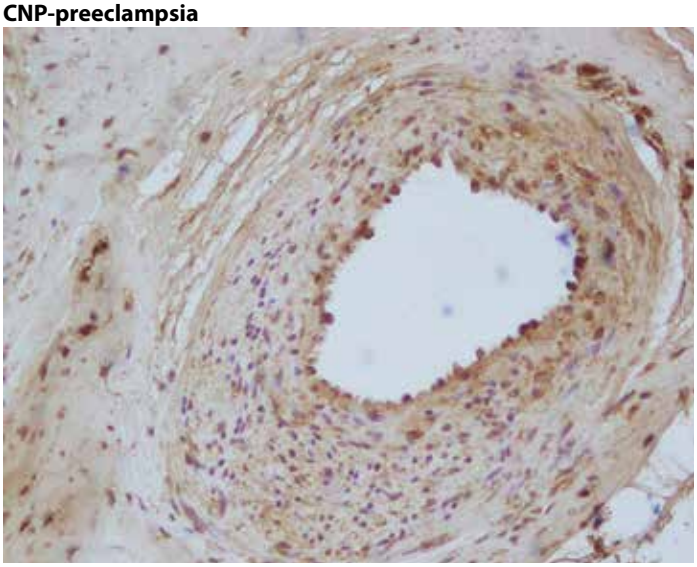

10.5505/2017ichc.OP-29 [Techniques in immunohistochemistry]

Immunohistochemical Distribution of Somatostatin in Stomach Tissues of Cinnamon Extract Supplementation Treated Diabetes Rats

Sevda Elis Yildiz[1], Buket Bakir[2], Şükran Yediel Aras[3], Serpil Dağ[4], Ebru Karadağ Sarı[5]

[1]Department of Midwifery, Faculty of Health Sciences, Kafkas University, Kars - Turkey

[2]Department of Histology and Embryology, Faculty of Veterinary Medicine, Namik Kemal University, Tekirdag, Turkey

[3]Department of Histology and Embryology, Institute of Health Sciences, Kafkas University, Kars, Turkey

[4]Department of Patology, Faculty of Veterinary Medicine, Kafkas University, Kars- Turkey

[5]Department of Histology and Embryology, Faculty of Veterinary Medicine, Kafkas University, Kars - Turkey

Diabetes is a complex, chronic illness requiring continuous medical care with multifactorial risk-reduction strategies beyond glycemic control. Cinnamon is a natural product of interest because it provide health benefits, such as the ability to lower serum lipids and blood glucose. We examined using immunohistochemistry the distribution of somatostatin in stomach tissues of Cinnamon Extract Supplementation treated streptozotocin (STZ) diabetes rats. At the beginning of the experiment 30 male Sprague-Dawley rats were randomly divided into 5 groups of 6 animals each: control, sham, diabetes, cinnamon, diabetes+cinnamon groups. The control group received nothing, the sham group received intraperitoneally (i.p.) 50 mg/kg sodium sitrate, the diabetes group was administered i.p. 50 mg/kg Streptozotocin (STZ) (dissolved in 50 ml citric acid+40 ml of disodium hydrogen phosphate buffer (pH: 4.5)) and the treatment groups (cinnamon and diabetes+cinnamon) received cinnamon extract (200 mg/kg by oral gavage) for 14 days. Stomach tissues sections were prepared and Crossman's triple staining was applied to tissue sections to examine histological structure of the stomach. The immunohistochemical localization of somatostatin in the stomach tissue was determined using the streptavidin-biotin-peroxidase method. We determined that on days 14 somatostatin immunoreactivty of the diabetes and diabetes+cinnamon groups was weaker than for the other groups. Weak immunoreactivity was found in the corpus mucosa and pyloric mucosa of the stomach in the diabates groups and strong immunoreactivity was found in the control, sham and cinnamon groups. In conclusion, when compared to diabetes groups, cinnamon extract administration was determined to increase the secretion of somatatostain which is somatostatin are important regulators of gastric acid secretion and alterations in their relative numbers may play a key role in gastroduodenal disease.

Keywords: Diabetes, cinnamon, stomach, somatostatin, rat

10.5505/2017ichc.PP-101 [Cancer biology]

Downregulation of Caveolin-1 by siRNA Targets Autophagosome of the Co-cultured Fibroblasts and Promotes Proliferation of Breast Cancer Cells

Shi Xiao Yu[1], Li Wen Lin[2], Xiao Liang[3], Meng Chuang[2]

[1]Department of Histology and Embryology, Basic Medical College, Nanchang University, Nanchang, China

[2]Key Laboratory of Medical Biology, Nanchang University,Nanchang, China

[3]Molecular Center Laboratory, Jiangxi University of Traditional Chinese Medicine, Nanchang, China

Under normal physiological conditions, Caveolin-1(Cav-1) is abundantly expressed in breast stromal fibroblasts. However, Cav-1 expression is reduced in stromal fibroblasts of the breast cancer microenvironment, and negatively correlated with the malignant potential of tumor cells. Breast cancer patients with low or negative Cav-1 expression in stromal fibroblasts often present a low survival rate, whereas the survival rates of those with high stromal Cav-1 expression levels are higher. Although the prognostic values of the downregulation of stromal Cav-1 in patients with breast cancer have been reported, the exact mechanism is unclear. Our experimental results are follows. (1) RT-qPCR and western blot results showed that Cav-1 siRNA interfered effectively in Cav-1 gene expression in fibroblast line ESF. (2) Cell proliferation experiment results showed that Cav-1 downregulation by siRNA promoted the proliferation of breast cancer cell line BT474 co-cultured with ESF/Caveolin-1siRNA after 48 hours of culture. (3) The results of immune fluorescent confocal laser microscope showed that the quantity of autophagosome was significantly increased in ESF/Cav-1siRNA co-cultured with BT474 cells. These results suggest that the event of Cav-1 downregulation could target autophagy of fibroblasts in breast cancer microenvironment, and this targeted regulation may association with the malignant proliferation of breast cancer cell.

Keywords: Caveolin-1, fibroblast, breast cancer, autophagy, siRNA, co-culture

10.5505/2017ichc.PP-102 [Cancer biology]

Immunohistochemical Evaluation of the Effects of the Treatment on Toll-Like Receptors on Breast Cancer Cell Lines

Melike Ozgul[1], Elgin Turkoz Uluer[1], Gamze Tanriover[2], Sevinc Inan[1]

[1]Department of Histology & Embryology, Faculty of Medicine, Manisa Celal Bayar University, Manisa, Turkey

[2]Department of Histology & Embryology, Faculty of Medicine, Akdeniz University, Antalya, Turkey

AIM: The aim of this study was to investigate the effects of PI3K inhibitor Wortmannin and angiogenesis inhibitor Thalidomide on Toll-Like Receptors (TLR) on breast cancer cell lines which have non-metastatic (67NR) and high metastatic (4T1) potential using immunohistochemical technique.
MATERIAL-METHOD: 67NR and 4T1 breast cancer lines were cultured in DMEM-F12, medium containing 5% FBS, 1% NEA, 1% L-glutamine and 1% penicillin/streptomycin. The cell lines were maintained at 37°C in 5% CO2, and passaged every 2-3 days. Doubling time of breast cancer cell lines were calculated and IC50 values were determined as 2,5 µM for Wortmannin and 50 µM for Thalidomide by using MTT assay. Cells were evaluated using avidin-biotin-peroxidase indirect immunohistochemistry technique. Anti-TLR2, anti-TLR4, anti-MyD88, anti-NFκB and anti-PI3K primary antibodies were performed after 24h and 48h drug administration. The distributions of immunohistochemical intensities of primary antibodies were graded semi-quantitatively as mild(1), moderate(2), strong(3) and very strong(4). H-Score values were calculated using the mean values of the staining intensities and the percentage of positively stained cells. Statistics were comparatively evaluated by using One-way ANOVA test.
RESULTS: On the control group of 67NR breast cancer cell line, immunoreactivity of TLR2 was seen as very strong. While immunoreactivity of MyD88 was seen as strong, immunoreactivities of TLR4, NFκB and PI3K were observed as moderate in this group. On the control group of 4T1 breast cancer cell line, immunoreactivities of MyD88 and NFκB were seen as strong, while immunoreactivities of TLR2, TLR4 and PI3K were observed as moderate/strong in this group. The significant decreasing immunoreactivity scores were determined in drug administered groups when compared to control groups ($p<0.05$).
CONCLUSION: It was first demonstrated by this study that Wortmannin and Thalidomide have an important role on TLR signaling pathway and related molecules on 67NR and 4T1 breast cancer cell lines. While it was determined that Wortmannin acts as an inhibitor of PI3K, Thalidomide acts as an inhibitor of NFκB. It was concluded that these drugs have significant role in cancer signaling pathways included invasion and metastasis. As future expectation, they might be used therapeutically in addition to classical treatments on cancer treatment.

Keywords: Breast Cancer Cell Lines, TLR, Wortmannin, Thalidomide, PI3K, Immunohistochemistry

The results of MTT assay

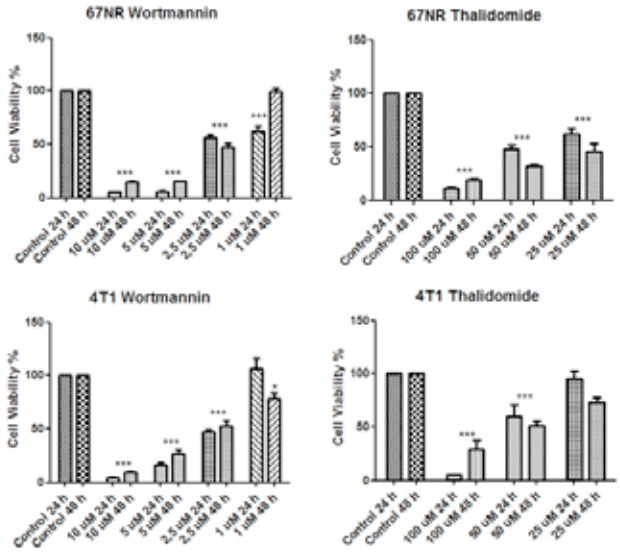

H-score values of each antibody on 67NR breast cancer cell line

	TLR2	TLR4	MyD88	NFκB	PI3K
Control 24 h	383,33 ± 5,8	209 ± 12,8	322,33 ± 7,1	255,67 ± 8,6	253,67 ± 7,5
Wortmannin 24 h	236,67 ± 23,6	171,67 ± 12,6	122,00 ± 12,1	180,00 ± 16	132,00 ± 8,9
Thalidomide 24 h	256,67 ± 5,8	202,67 ± 14,5	178,67 ± 20	114,67 ± 6,1	231,67 ± 3,1
Control 48 h	318,67 ± 12,9	218 ± 19,3	321,33 ± 4,5	253 ± 7	290,67 ± 4,0
Wortmannin 48 h	227,33 ± 24,9	152 ± 10,6	145,67 ± 25,9	157,67 ± 6,7	156,33 ± 5,5
Thalidomide 48 h	223,67 ± 24,6	215,67 ± 9	227,67 ± 13,6	163,33 ± 7,1	249,7 ± 18,2

H-score values of each antibody on 4T1 breast cancer cell line

	TLR2	TLR4	MyD88	NFκB	PI3K
Control 24 h	288,67 ± 12,1	265,33 ± 15,0	319,67 ± 6,1	330 ± 18,3	305,3 ± 12,9
Wortmannin 24 h	149 ± 13,5	219,33 ± 4,5	174 ± 4,6	126,67 ± 8	133,7 ± 15,2
Thalidomide 24 h	241,33 ± 9,0	221,67 ± 3,8	179,67 ± 13,6	178 ± 13,9	246 ± 14,9
Control 48 h	310 ± 18,0	301,67 ± 10,8	243,67 ± 7,1	386 ± 8,7	311,7 ± 20,2
Wortmannin 48 h	205 ± 13,2	177 ± 12,1	143,67 ± 11,9	233 ± 11,8	133,33 ± 7,0
Thalidomide 48 h	255,33 ± 26,1	228,67 ± 10,3	230,67 ± 20,1	187,67 ± 12,1	205,33 ± 9,6

The grafs of H-Score values on 67NR cell line

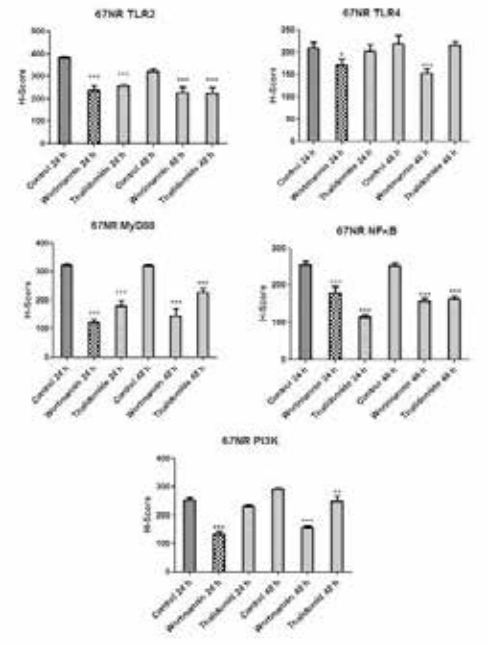

The grafs of H-Score values on 4T1 cell line

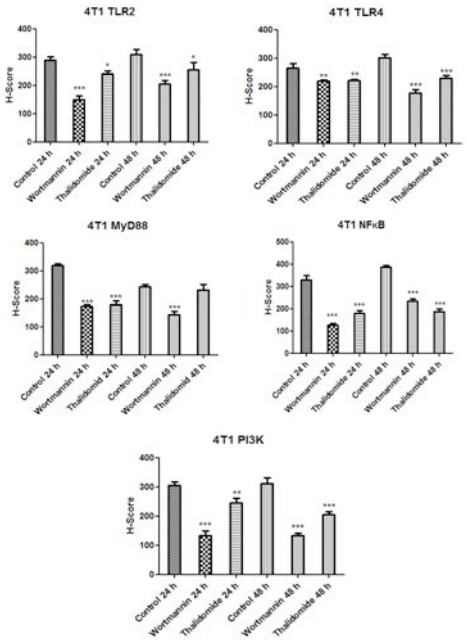

The immunohistochemistry micrografts of anti-TLR2 antibody

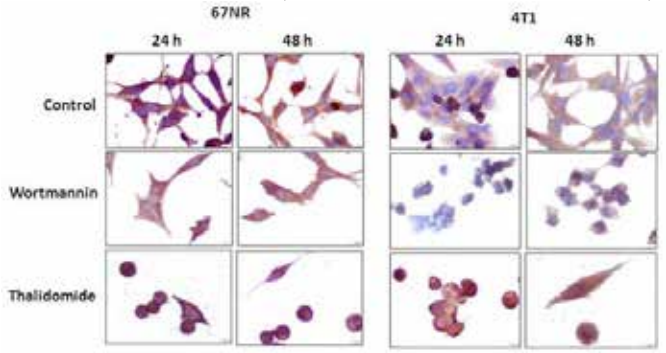

Figure: The immunohistochemistry micrografts of anti-TLR2 antibody.
Original Magnification: X400 **Bar:** 10 µm

The immunohistochemistry micrografts of anti-TLR4 antibody

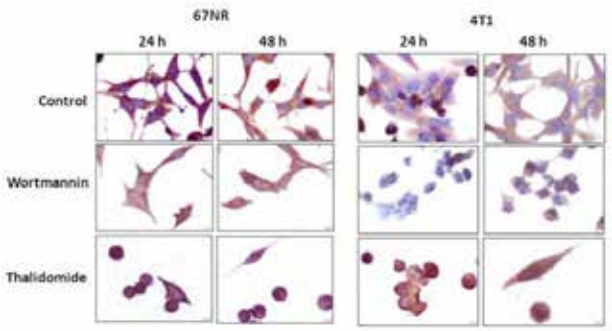

Figure: The immunohistochemistry micrografts of anti-TLR2 antibody.
Original Magnification: X400 **Bar:** 10 µm

The immunohistochemistry micrografts of anti-MyD88 antibody

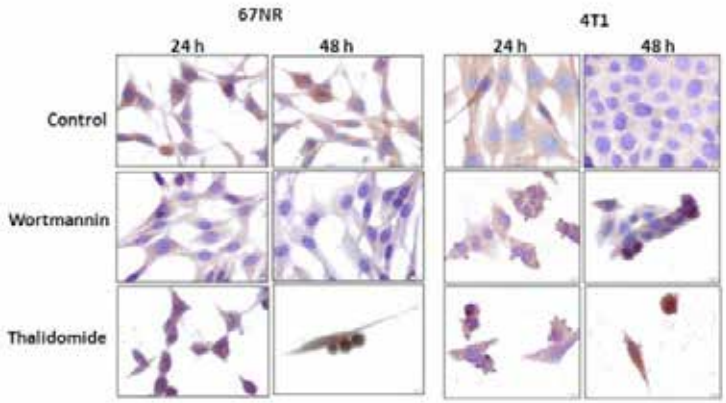

Figure: The immunohistochemistry micrografts of anti-MyD88 antibody.
Original Magnification: X400 **Bar:** 10 µm

The immunohistochemistry micrografts of anti-NFκB antibody

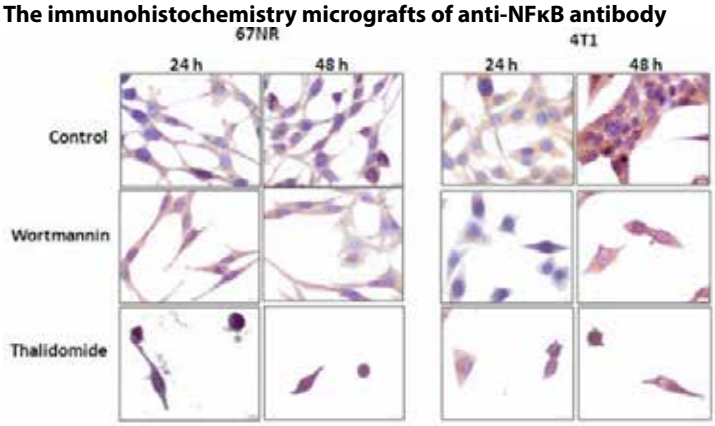

Figure: The immunohistochemistry micrografts of anti-NFκB antibody.
Original Magnification: X400 **Bar:** 10 µm

The immunohistochemistry micrografts of anti-PI3K antibody

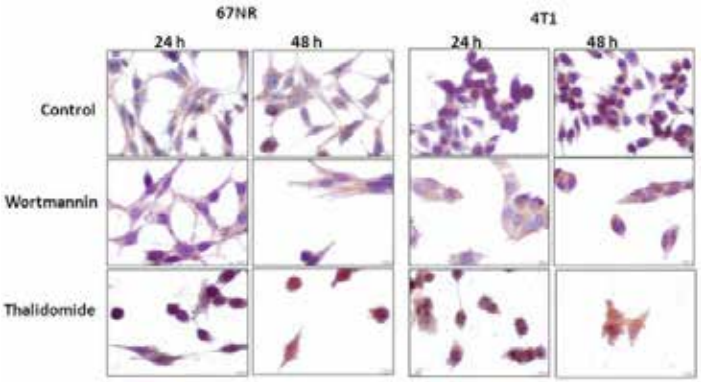

Figure: The immunohistochemistry micrografts of anti-PI3K antibody.
Original Magnification: X400 **Bar:** 10 µm

10.5505/2017ichc.PP-103 [Cancer biology]

In Vitro Cytotoxic and Antitumoral Effects of *Juniperus communis* Leaf and Berry Extracts on Castration-Resistant Prostate Cancer Cells

Işıl Ezgi Eryılmaz[1], Ünal Egeli[1], Gülşah Çeçener[1], Berrin Tunca[1], Saliha Şahin[2], Hulusi Malyer[3]

[1]Uludag University, Faculty of Medicine, Department of Medical Biology

[2]Uludag University, Faculty of Science and Art, Department of Analytical Chemistry

[3]Uludag University, Faculty of Science and Art, Department of Botany

INTRODUCTION & OBJECTIVES: Castration-resistant prostate cancer (CRPC) can not be effectively treated with available agents. Thus, new therapy approaches need to be developed. In recent years, *Juniperus* L. is thought to be among the plants that can be utilized in cancer therapy. In the present study, we investigated cytotoxic and antitumoral effects of *Juniperus communis* aqueous leaf and berry extracts on CRPC cells.
MATERIALS & METHODS: Cytotoxic and antitumoral effects of *Juniperus communis* L. var. *saxatilis* Pall. leaf and berry extracts on CRPC (DU145 and PC-3) and HUVEC control cells were evaluated using WST-1 assay, Annexin V analysis and Hoechst/PI staining. The effects of extracts on the expression levels of *MMP-2* and *MMP-9* were analyzed using RT-qPCR. Phenolic content of the extracts was determined by HPLC-DAD analysis.
RESULTS: Cytotoxic effects of the extracts on CRPC cells were time-concentration dependent. Maximum effects were observed at 72h. While 10µg/ml leaf extracts decreased cell viability 52,25% (p<0.001) and 59,8% (p<0.0001), 250µg/ml berry extracts decreased 41,75% (p<0.001) and 46,36% (p<0.001) for DU145 and PC-3, respectively. At the same exposure time with these concentrations, the inhibition rate was lower in HUVEC cells. According to morphological analysis, early apoptosis increased after 48h, late apoptotic and necrotic deaths were detected at 72h in DU145 cells. Based on Annexin V analysis, 10µg/ml leaf extract caused 26,8% apoptosis and 5,45% necrosis in DU145, 33,5% apoptosis and 3,10% necrosis in PC-3, 8,65% apoptosis and 4,55% necrosis in HUVEC cells. 250µg/ml berry extract caused 21,8% apoptosis and 4,30% necrosis in DU145, 28,85% apoptosis and 1,95% necrosis in PC-3, 8,05% apoptosis and 3,55% necrosis in HUVEC cells. The extracts were determined to contain phenolic compounds including chlorogenic acid, ferulic acid, kaempferol-3-glycoside, rutin and t-cinnamic acid. It was revealed that phenolic compounds were more abundant in leaf extract. According to RT-qPCR, the extracts significantly downregulated *MMP-2* and *MMP-9* expression levels.
CONCLUSIONS: This is the first study to investigate cytotoxic effects of *Juniperus communis* extracts on CRPC cells. We suggest that *Juniperus communis* is one of the important plant species for further investigations in CRPC treatment.

Keywords: {Juniperus communis}, prostate cancer, CRPC, cytotoxic effect

Annexin V histograms obtained after application of the extracts.

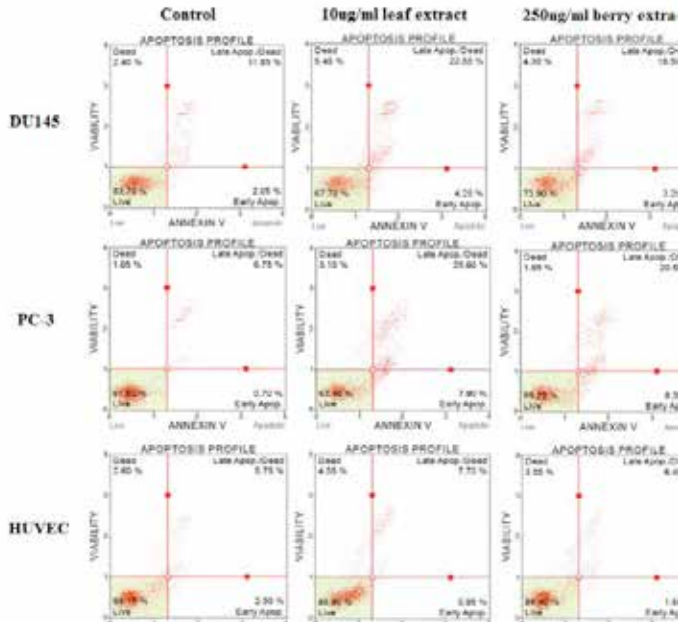

10.5505/2017ichc.PP-104 [Cancer biology]

Controlling of miRNA expression in primary and metastatic cell lines on hypoxia condition

Sevtap Gökalp[1], Tuna Onal[1], Elgin Turkoz Uluer[1], Cansu Gorgun[2], Hafize Seda Vatansever[3]

[1]Department of Histology and Embryology, Faculty of Medicine, Celal Bayar University, Manisa, Turkey

[2]Department of Biomedical Technologies, Graduate School of Natural and Applied Sciences, Ege University, Izmir, Turkey

[3]Department of Histology and Embryology, Faculty of Medicine, Celal Bayar University, Manisa, Turkey, Near East University, Experimental Health Science Research Center, Nicosia, North Cyprus

Cancer is a group of diseases involving abnormal cell growth with the potential to invade or spread to other parts of body. The most common types of cancer in males are lung, prostate, colorectal and stomach cancers, in females, breast, colorectal, lung and cervical cancers. Hypoxia is known as a condition characterized by the lack of oxygen, and effect on tumors has a critically important role on maintenance of cancer and cancer stem cell phenotype. Many studies have demonstrated the critical effect of hypoxia on cancer cells in different cancer types by showing the hypoxic resistance to chemotherapy and radiotherapy. miRNAs which are integral to the gene regulatory network is capable of controlling the expression of hundreds of protein coding genes and modulate a wide spectrum of biological functions, such as proliferation, differentiation, stress responses, DNA repair, cell adhesion, motility, inflammation, cell survival, senescence and apoptosis, all of which are fundamental to tumorigenesis. In this study we aim to identify miRNAs expressions by analyzing of Dicer, Drosha, eIF2α and eIF2C's distributions in different types of cancers.
To provide the hypoxic condition, a gas mixture of 5% CO2, 3% O2 and 94% N2 was used to create 3% hypoxic conditions and Colo-320, Colo-741, MCF-7 and M4A4 cell lines were incubated for 36 hours. As a control group, 5% CO2 humidified environment was used to provide normoxic conditions for 36 hours in an incubator. In immunohistochemical analysis, we investigated anti-dicer, anti-drosha, anti-eIf2α and anti-eIF2C distributions in all of them.
Dicer and Drosha immunoreactivities were increased on hypoxia in metastatic colon cancer cell line. eIF2α immunoreactivity, there is no differences between primary and metastatic colon cancer cell lines. Although Dicer and Drosha immunoreactivity were negative in control groups of MCF-7 cells, Drosha and eIF2α were increased after hypoxia. Dicer immunoreactivities were the same in two groups. eIF2C immunoreactivities were negative in all primary and metastatic colon and breast cancer cell lines. In conclusion, hypoxic condition may stimulate miRNA biogenesis in primary and metastatic cancers and also miRNA pathway may differently affected after this condition in primary and metastatic cancer cells.

Keywords: Cancer cell lines, hypoxia, micro RNA

10.5505/2017ichc.PP-105 [Cancer biology]

Protective Effects of Metformin Against Testicular Damage in Dunning Rat Prostate Cancer Model

Pınar Köroğlu[1], Omur Karabulut Bulan[1], Ismet Burcu Turkyılmaz[2], Ilknur Bugan[1], Seyhan Altun[1], Refiye Yanardağ[2]

[1]Department of Biology, Faculty of Science, Istanbul University, Istanbul, Turkey

[2]Department of Chemistry, Faculty of Engineering, Istanbul University, Istanbul, Turkey

Cancer is a serious health problem. Prostate cancer can be determined as the alteration of the balance between cell proliferation and cell death in the prostate which causes a malign increase of the organ volume(1). The aim of the work is to observe the possible protective effect of metformin on testicular damage in prostate cancer model. The reason for studying testicular tissue was its close functional association to prostate. Metformin is the drug that using in treatment of diabetes. Recently, the studies related to reduce the risk of cancer of the metformin have drawn attention(2).

In this study, Dunning prostate cancer model was formed in Copenhagen rats using high metastatic MAT-Lylu cells. Male Copenhagen rats were divided into three groups: 1) Control group: physiological saline was received during 14 days, 2) Cancer group: $2x10^4$ MAT-LyLu cells were received 3) Cancer+metformin group: metformin was received 250 mg/kg every day, following inoculation of MAT-LyLu cells. At the end of the experimental period testes tissues were taken. Tissues were stained with hematoxylin and eosin and periodic acid-Schiff reaction. The degree of histopathological damage in the seminiferous tubules were evaluated as: normal, regressive, degenerative and atrophic(3). Biochemically, glutathione, malondialdehyde, prostate specific antigen, protein carbonyl and nitric oxide levels and xanthine oxidase, myeloperoxidase activities were determined.

Control group had a normal testicular morphology and regular seminiferous tubules. In cancer group, the number of regressive and degenerative tubules significantly increased compared to control group. According to biochemical data, in cancer group, malondialdehyde, prostate specific antigen, protein carbonyl and nitric oxide values and xanthine oxidase and myeloperoxidase activities were increased compared to control group. The glutathione level in cancer group was decreased compared to control group. Administration of metformin mostly protected testicular tissue by restoring the biochemical and histological damage alterations.

It has been reported that metformin was used as protective agent to prevent high-fat diet induced testicular damage. Also, metformin administration improved the semen parameters, increased testicular weight and reduced testicular cell apoptosis(4). Our results showed that metformin has potential therapeutic effects on testes in prostate cancer model.

Keywords: Cancer, metformin, Mat-Lylu, testes, Copenhagen rat.

10.5505/2017ichc.PP-106 [Cancer biology]

Effect of Hypoxia on Proliferation Parameters in Primary and Metastatic Cancer Cell Lines

Tuna Onal[1], Elgin Turkoz Uluer[1], Remziye Kendirci[1], Feyzan Ozdal Kurt[2], Cansu Gorgun[3], Hafize Seda Vatansever[4]

[1]Department of Histology and Embryology, Faculty of Medicine, Celal Bayar University, Manisa, Turkey

[2]Department of Biology, Faculty of Sciences & Letters, Celal Bayar University, Manisa, Turkey

[3]Department of Biomedical Technologies, Graduate School of Natural and Applied Sciences, Ege University, Izmir, Turkey

[4]Department of Histology and Embryology, Faculty of Medicine, Celal Bayar University, Manisa, Turkey, Experimental Health Science Research Center, Near East University, Nicosia, North Cyprus

AIM: Colon cancer is one of the most common cancers in males around the world similarly breast cancer is the most common type of cancer in females. Hypoxia is microenviroment condition which is an effective factor in tumor formation and progression in many types of cancer. We aimed to investigate that the effect of hypoxia on proliferation parameters in primary and metastatic cancer cell lines.
MATERIALS-METHODS: Human primary colon (Colo-320) and breast (MCF-7), human metastatic colon (Colo-741) and breast (M4A4) cancer cell lines were used. They were cultured in RPMI-1640 media supplemented with 10% FBS, 1% L-glutamine, 1% penicillin and streptomycin until 80% confluency. All type of cells divided into two groups; the control group cultured with 5% CO2 and 37°C, the hypoxia group were cultured in hypoxia chamber which have a gas mixture of 5% CO2, 3% O2 and 92% N2 to provide the hypoxic condition for 36 h. After fixation with 4% paraformaldehyde, distribution of CD133, OCT-4 and Ki67 were analyzed using indirect immunohistochemistry method. Immunoreactivity intensities were evaluated as none (-), weak (1), moderate (2), strong (3). Immunostaning results were evaluated as H-SCORE in comparison with the One-Way ANOVA statistical test.
RESULTS: CD133 immunoreactivity was increased in all cells of hypoxia groups, also the positive stained cells and the intensity of the CD133 immunoreactivity were higher in both primary and metastatic colon cancer cells than breast cancer cells. The immunoreactivity of Oct-4 was observed as increased in all hypoxia groups compared to control groups. It was indicated that Oct-4 were detected in metastatic colon cancer cell line, primary and metastatic breast cell lines, except primary colon cancer cell line. Ki67 immunoreactivity indicated no differences in all type of cell in both groups.
CONCLUSION: It is well known that the hypoxia conditions have important roles on carcinogenesis and metastasis. In this study, taken together in vitro results, it was seen that the expressions of stem cell properties of the cells were on hypoxic condition. However, proliferation was not effected by hypoxia.

Keywords: Colon cancer, breast cancer, CD133, Oct-4, Ki67

10.5505/2017ichc.PP-107 [Cancer biology]

Can Hypoxia Effect Exosome Trafficking in Mouse Neuroblastoma Cell Line

Seda Vatansever[1], Elgin Turkoz Uluer[2], Tuna Onal[2], Sevtap Gokalp[2], Cansu Gorgun[3], Ibrahim Tuglu[2]

[1]Department of Histology and Embryology, Faculty of Medicine, Celal Bayar University, Manisa, Turkey / Experimental Health Science Research Center, Near East University, Nicosia, North Cyprus

[2]Department of Histology and Embryology, Faculty of Medicine, Celal Bayar University, Manisa, Turkey

[3]Department of Biomedical Technologies, Graduate School of Natural and Applied Sciences, Ege University, Izmir, Turkey

OBJECTIVE: Exosomes have diameter within the range of 30-100 nm and spherical to cupshaped nanoparticles with specific surface molecular characteristics, such as CD9 and CD63. Exosomes are demonstrated to have a close relationship with tumor development and metastasis. Hypoxia is an important feature of solid tumor especially advanced disease due to an imbalance in the supply and consumption of oxygen by tumor cells. Hypoxic tumor exhibits more aggressive phenotypes. Tumor cells under hypoxia can produce a secretion partly in the form of exosome that modulates the microenvironment to facilitate tumor angiogenesis and metastasis. This study aimed to investigate the hypoxic effect on exosomes in mouse neuroblastoma cell line.
METHODS: The mouse neuroblastoma cell line (NA2B) was purchased from the Animal Cell Culture Collection, HUKUK, (Ankara, Turkey). Cells were cultured in DMEM F-12 supplemented with 10% foetal calf serum and 1% L-glutamine. Cells were cultured in 24 well plate and divided into two groups. For hypoxic condition group; cells were exposed to 3%O2, 92%N2, 5%CO2 gas mixture to create 3% hypoxic condition for 36 hours in a hypoxia chamber. For the control group; cells were incubated under normal culture conditions in a humidified atmosphere at 37°C in 5% CO2. After 36 hours incubation cells fixed in 4% paraformaldehyde and were stained with indirect immunoperoxidase technique in order to determine distributions of CD9 and CD63. Results evaluated by H-SCORE in comparison with the One-Way ANOVA statistical test.
RESULTS: After hypoxia the cells have more cytoplasmic extensions that connect to each other. In hypoxic group CD9 immunoreactivity was mild while there was no CD9 immunoreactivity in control group. CD63 immunoreactivity was moderate in hypoxic group and mild in control group. Both CD9 and CD63 were increased after hypoxic condition.
CONCLUSION: Communication among tumor cells and between tumor cells and human organs is crucial for cancer progression. Exosomes are emerging as a major player in this communication, specifically in cancer development and progression. In this study, increased both CD9 and CD63 immunoreactivities in hypoxic group demostrated that exosomal trafficking may started to carry molecules or organalles for the modulation of tumor microenvironment and malignancies.

Keywords: Exosome, hypoxia, neuroblastoma, CD9, CD63

10.5505/2017ichc.PP-108 [Cancer biology]

Exosomes Secreted under Hypoxia Enhance Invasiveness and Stemness of Breast and Colon Cancer Cell Lines

Ibrahim Halil Gurcinar[1], Remziye Kendirci[2], Hilal Kabadayı[2], Hafize Seda Vatansever[3]

[1]Faculty of Medicine, Celal Bayar University, Manisa, Turkey

[2]Department of Histology and Embryology, Faculty of Medicine, Celal Bayar University, Manisa, Turkey

[3]Department of Histology and Embryology, Faculty of Medicine, Celal Bayar University, Manisa, Turkey, Near East University, Experimental Health Science Research Center, Nicosia, North Cyprus

Exosomes are small vesicles formed in vesicular bodies in the endosomal network and they are mainly involved in the transport of bioactive molecules between cells. Exosomes derived from tumor cells are essential for processes involved in tumor progression, including angiogenesis, tumor cell proliferation and immunoregulation. As a significant tumor feature, hypoxia can trigger cancer adaptive processes, induce malignant phenotype development, and promote drug resistance. Intratumoral hypoxia is a common microenvironmental stimulus that drives cancer progression and is associated with metastasis and patient mortality. In breast cancer, overexpression of HIF-1α or HIF-2α is associated with metastasis, treatment failure, and patient mortality. Hypoxia-induced exosome release was shown to be HIF dependent, although specific downstream target genes required for exosome release have not been identified.
In the present study, primary breast (MCF-7) and colon (Colo-320), and metastatic breast (M4A4) and colon (Colo-741 cancer cell lines were cultured under hypoxic (3% O2) and normoxic conditions to evaluate the effects of hypoxia on exosome production, HIF-1α secretion and stemness properties of cancer cells. The analyses were done using evaluation of distribution of CD9, CD63, CD133 and HIF-1α by indirect immunohistochemical staining.
Under hypoxic conditions, an increase in the number of exosomes in the primary cell lines (MCF-7 and Colo-320), determined by CD63 immunohistochemical staining was observed than metastatic cancer cell lines (M4A4 and Colo-741). CD9 staining was negative in all cells. However, CD133 immunoreaktivity was strongly detected in all of the cells under hypoxic condition. The similar HIF-1α staining was detected in all type of cells in both hypoxic and normoxic conditions.
Hypoxia can remarkably stimulate exosomal secretion from primary breast and colon cancer cells lines with increasing their stemness, therefore, exosomes in a tumor microenvironment may involved their stemness and metastatic properties to malignant state of aggressive tumours.

Keywords: Exosomes, Primary Cancer, Metatatic Cancer, Hypoxia

10.5505/2017ichc.PP-109 [Cancer biology]

Altered expression of RASSF1A and YAP1 genes is associated with progression of clear cell renal cell carcinoma

Piotr M Wierzbicki[1], Agnieszka Rybarczyk[1], Agata Wronska[1], Marcin Stanislawowski[1], Jakub Klacz[2], Tomasz Slebioda[1], Marcin Matuszewski[2], Zbigniew Kmiec[1]

[1]Department of Histology, Medical University of Gdansk, Gdansk, Poland

[2]Department of Urology, Medical University of Gdansk, Gdansk, Poland

INTRODUCTION: Clear-cell renal cell carcinoma (ccRCC) is the most common subtype of RCC (70-80%) and is associated with poor prognosis in 40% of cases mainly due to metastases in the course of the disease. The Hippo pathway is involved in cell proliferation, differentiation and apoptosis; its deregulation was observed in several types of cancers. RASSF1A is the upstream regulator (suppressor) whereas YAP1 is an effector protein (oncoprotein) of the Hippo pathway due to activation of TEAD1-4 oncogenes. The involvement of RASSF1A and YAP1 genes in ccRCC progression has not yet been studied.
MATERIALS-METHODS: Tissues were obtained from 86 ccRCC patients. RASSF1A and YAP1 mRNA levels were assessed in tumor and matched normal kidney tissue, and in 12 samples of local metastases by quantitative PCR (qPCR). Levels of RASSF1A and YAP1 proteins were semi-quantified by western-blot (WB) and their tissue localization was assesses by immunohistochemistry (IHC). The expression levels of RASSF1A and YAP1 were downregulated in ACHN, A498 and HEK293 cell lines using siRNA and the mRNA levels of Hippo effectors were assessed.
RESULTS: We found decreased levels of RASSF1A mRNA and protein in tumor and metastasized tissues in comparison to normal kidney. RASSF1A underexpression was associated with ccRCC progression and poor patients' outcome. The higher expression of YAP1 at mRNA or protein level was associated with ccRCC progression (Fuhrman's histological grading). IHC assessment revealed cytoplasmic localization of RASSF1A protein and cytoplasmic/nuclear location of YAP1 protein. The inactivation of RASSF1A expression in cells increased levels of YAP1 and TEAD1 transcription, whereas inactivation of YAP1 translation had no effects on RCC cell lines.
CONCLUSIONS: The involvement of Hippo pathway components in ccRCC progression may offer new molecular markers of RCC prognosis and new targets of therapy.
The study was supported by the National Science Centre (grant no: 2012/05/B/NZ4/02735).

Keywords: RASSF1A, YAP1, ccRCC, Hippo pathway

10.5505/2017ichc.PP-110 [Cancer biology]

The Importance of the PI3K/Akt Pathway on Endometrial Cancer Cell Lines by Using Immunohistochemistry

Elgin Turkoz Uluer, Isıl Aydemir, Oya Korkmaz, Damla Akogulları, Sevinc Inan
Department of Histology and Embryology, Faculty of Medicine, Celal Bayar University, Manisa, Turkey

OBJECTIVE:
Endometrial carcinoma (EC) is the most common gynecological cancer in the world. ECs are classified into two types based on clinicopathologic or endocrine features. Type-I ECs, which account for 80% of ECs, are estrogen-dependent and characterized by minimal myometrial invasion, arising from atypical complex hyperplasia, and typically affects pre- and perimenopausal women. Type-II ECs are more aggressive with invasion into myometrium and irresponsive to high estrogen stimulation due to the lack of ERα expression occurring mostly in postmenopausal women.
The PI3K signaling pathway has many roles, including regulation of cancer cell survival, proliferation, motility, and metabolism. Both genetic defects and environmental factors are involved in carcinogenesis and progression of EC via activation of multiple signal pathways including PI3K/Akt pathway. In this study, we aimed to investigate immune localizations of signal molecules which involved in PI3K/Akt pathway on endometrial cancer cell lines by using immunohistochemistry.
METHODS:
Non-invasive, Type-I EC cell line (Ishikawa cell line, ECACC) and invasive, Type-II EC cell line (MFE-319, DSMZ, ACC-423) were maintained in culture as adherent cells cultured in RPMI-1640 and DMEM F-12 respectively. Cells were cultured in 24 well plate and after confluency fixed in 4% paraformaldehyde and were immune-stained with indirect immunoperoxidase technique in order to determine the distributions of PI3K, pAKT, ERK1/2 and mTORC2. The immunoreactivity intensities were scored as mild(1), moderate(2), strong(3) and very strong(4). Results were evaluated by H-SCORE in comparison with the One-Way ANOVA statistical test.
RESULTS:
Immunoreactivities of PI3K, pAKT, ERK1/2 and mTORC2 were observed as very strong in MFE-319 cell line (Figure1, Table1). While immunoreactivities of ERK1-2 and mTORC2 were seen as strong in Ishikawa cell line; pAKT immunoreactivity was observed as moderate and PI3K immunoreactivity was seen as mild (Figure1, Table1).
CONCLUSION:
The immunohistochemistry results showed that PI3K/Akt pathway was activated in Type-II EC cell line MFE-319. While there was mild PI3K immunoreactivity in Type-I EC cell line but the downstream targets of PI3K were activated. Therefore PI3K molecule can be used as a prognostic factor for invasive Type-II EC and inhibition of the PI3K/Akt pathway can be used for treatment of EC.

Keywords: Endometrial carcinoma, PI3K/Akt pathway, immunohistochemistry

Distribution of the ERK1/2, mTORC2, pAKT and PI3K immunoreactivities of samples from Ishikawa and MFE-319 cell lines.

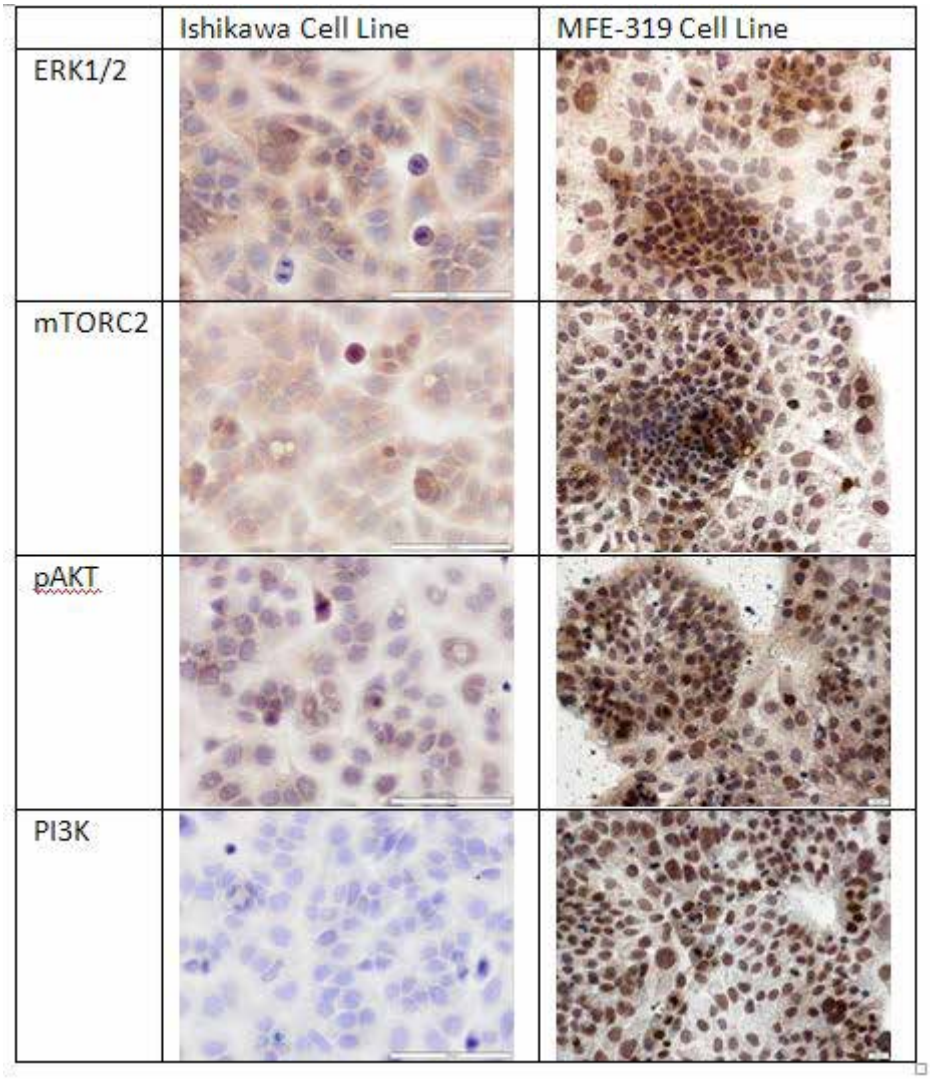

H-SCORE analysis of the ERK1/2, mTORC2, pAKT and PI3K immunohistochemical staining.

	Ishikawa Cell Line	MFE-319 Cell Line
ERK1/2	313	450
mTORC2	308	425
pAKT	227	400
PI3K	146	375

10.5505/2017ichc.PP-111 [Cancer biology]

Possible anticancer effect of Mirtazapine in SKOV3 cell lines

Ilknur Keskin[1], Hilal Eren Gözel[1], Duygu Gürsoy[2], Sibel Erdem[3], Gökhan Cüce[4]

[1]Department of Histology and Embryology, Medipol University, Istanbul

[2]Regenerative and Restorative Medical Research Center, Medipol University, Istanbul

[3]Department of Biochemistry, Medipol University, Istanbul

[4]Department of Histology and Embryology, Necmettin Erbakan University, Konya

Introduction & OBJECTIVES: Mirtazapine is an antidepressant with α adrenergic receptor blocking activity that reduces nausea, anorexia, sleep disturbance, and depression in cancer patients. To our knowledge, there are a few studies in the literature suggest that Mirtazapine may also have an anticancer activity. One study reported that Mirtazapine-applied rats hadn't suffered from severe dysplasia when the gastric adenocarcinoma was induced via applying N-methyl-N-nitro-N-nitrosoguanidine (MNNG). Another study shows that, due to having effects on histamines by inhibiting H1 receptor activity, Mirtazapine inhibits interleukin-6 synthesis in glioblastoma, which results slowing in cancer growth. In many cancers, including colon cancer, melanoma, multiple myeloma and prostate cancer, the cell growth is promoted by interleukin-6 synthesis. This knowledge led us to hypothesize that Mirtazapine can be a good candidate for cancer treatment and its anticancer effects are worth further investigation. With this aim, we wanted to evaluate ant-cancer property of Mirtazapine in cancer cell lines.
Materials & METHODS: In our experiment, different doses (0,1 µM to 10µM) of Mirtazapine and Paclitaxel, used as a control drug, were administered to SKOV3(adenocarcinoma) and HEK (as a control group) cell lines. Mtt assay was performed to measure cell viability. Based on these results, IC50 value of each drug was determined.
RESULTS: IC50 value of Paclitaxel was calculated as 100 µM and Mirtazapine's IC50 was determined as 26 µM in SKOV3 cell line. On the other hand, the IC50 value of Paclitaxel was obtained as 0,007 µM and Mirtazapine's was 0.0068 µM in HEK 293 cell line.
DISCUSSION: Our results indicate that IC50 values of two drugs in HEK293 and SKOV3 cell lines were close to each other. However, when the IC50 values for SKOV3 cell lines were compared, it is obvious that Mirtazapine is very effective even in the lower concentration than Paclitaxel. Furthermore, by having the advantage of less side effects, Mirtazapine might be a promising candidate to develop new drug repositioning strategies for treating adenocarcinomas.

Keywords: Mirtazapine, anticancer activity, SKOV3 cell line, adenocarcinoma

IC50 value of Mirtazapine in HEK

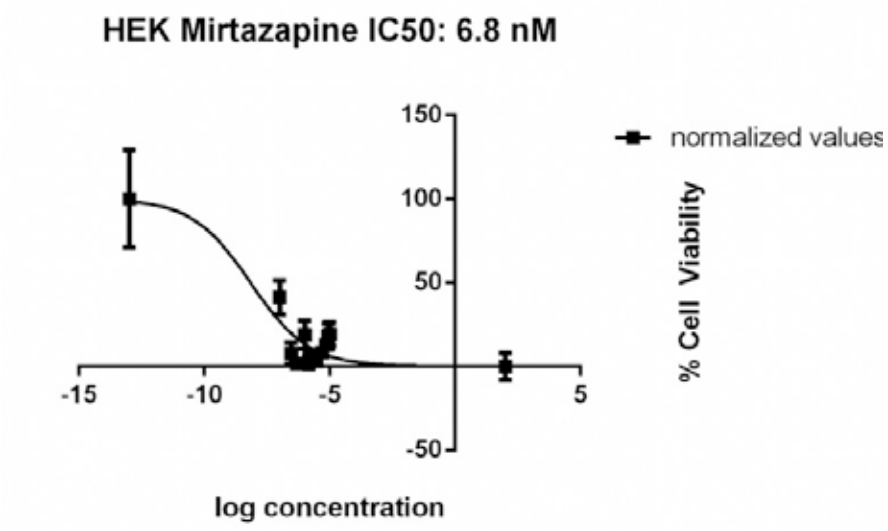

IC50 value of Mirtazapine in SKOV3

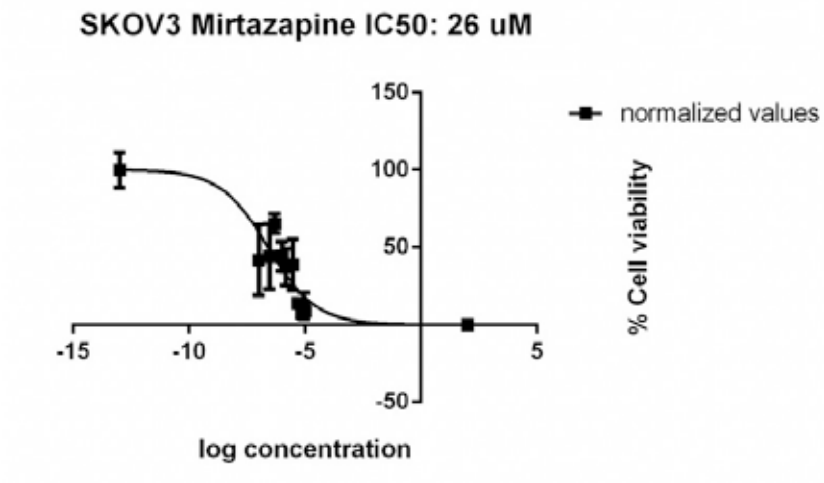

IC50 value of Paclitaxel in HEK

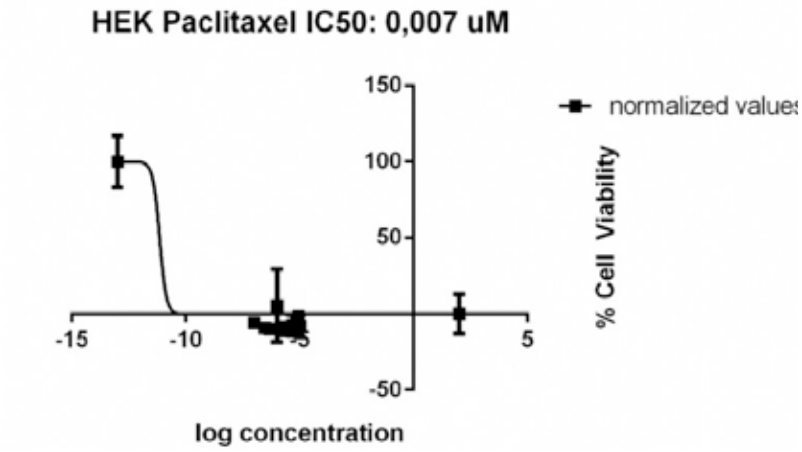

IC50 value of Paclitaxel in SKOV3

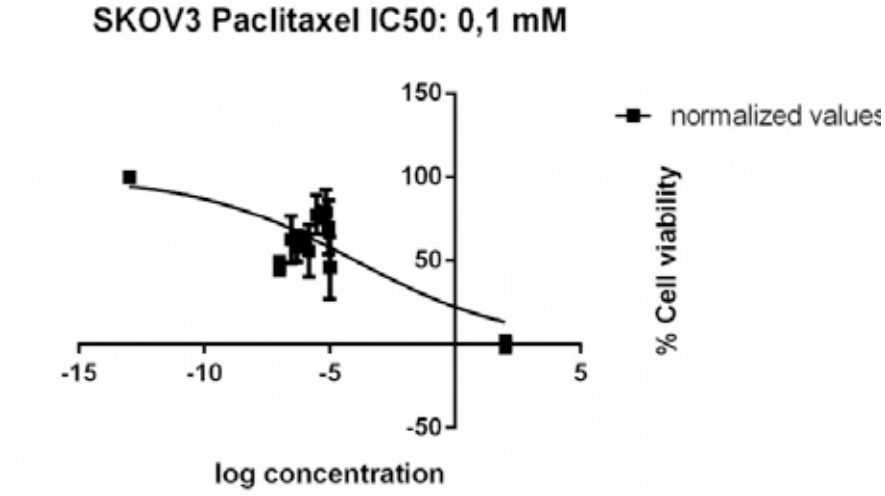

10.5505/2017ichc.PP-112 [Cancer biology]

L-Ferritin: a nonodevice to target Scara-5 postive cancer cells

Valeria Bitonto, Gian Luca Gonella, Diego Alberti, Silvio Aime, Simonetta Geninnati Crich, Juan C. Cutrin
Molecular Biotechnology Center, University of Torino, Italy

INTRODUCTION AND OBJECTIVES: Ferritin is an iron storage and transport protein composed by24 subunits arranged to form a nanocage capable of containing up to 4500 iron atoms. It is well known that many cancer cells reprogram iron metabolism in ways that result in net iron influx. In this context, exploiting the recognition of L-ferritins by the scavenger receptor member 5 (SCARA5) and H-ferritins by the TfR1, ferritin nanocages can be exploited to effectively target tumor cells. In particular ferritin, thanks to its peculiar ability to self-assemble and disassemble upon different pH conditions, can accommodate within its core different theranostic agents.
Herein we propose L-ferritin as a novel diagnostic agent for the visualization of neuroblastoma tumor cells.

MATERIALS-METHODS: A murine neuroblastoma cell line, N2a, was maintained as a monolayer culture in MEM Eagle modified medium. Cells were treated with different concentrations (0.5-1.5 µM) of horse spleen ferritin or rhodamine-labeled L-Apoferritin for 24 h. SCARA5 receptor was evaluated by mean of immunohistochemistry under fluorescent microscopy. L-ferritin internalization was assessed by MRI imaging and iron accumulation was estimated by ICP-MS.

RESULTS: 100% of N2a cells were positive for SCARA5 expression (figure 1a). After 24h of incubation with 20nM of L-apo rhodamine, all cells were positive for the internalization of the protein (figure 1b)
L-ferritin showed a dose-dependent uptake as proved by the increase in iron content inside cells (figure 1c). Ferritin internalization resulted in an increase in the MRI signal intensity (figure 1d).

CONCLUSIONS: L-ferritin nanoparticles have showed many appealing features such as good bioavailability and circulation time. In this context L-ferritin appears to be a powerful tool for both imaging and therapeutic purposes, considering also that its receptor is not expressed ubiquitously.
Here we show that L-ferritin, which is efficiently internalized by N2a, can be used to specifically target and visualize neuroblastoma tumor cells.

Keywords: Nanoparticles,L-ferritin, Molecular Imaging, Theranostic, Cancer Cells

Figure 1

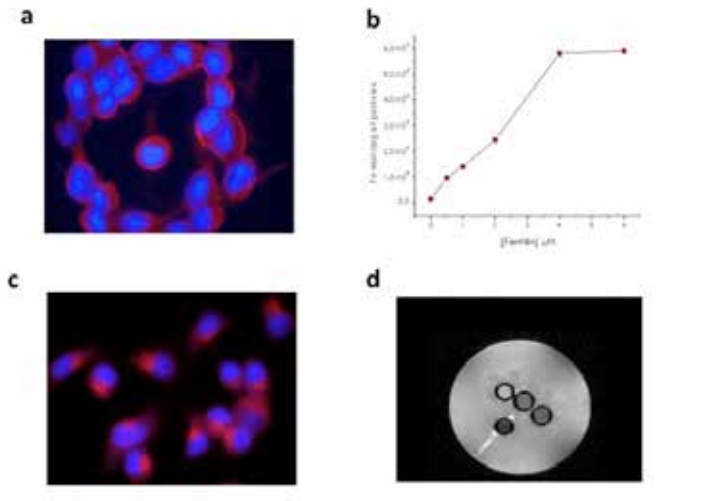

a Neuro2A cells fixed in methanol were first incubated overnight at 4°C with a rabbit monoclonal IgG anti SCARA5 (sc-98123 from Santa Cruz Biotechnology Inc, Dallas, Texas, USA) and then with a goat polyclonal IgG (H+L) Texas Red® labeled anti-rabbit antibody (Molecular Probe, Eugene, Oregon USA). b At 24 h post seeding, cells were incubated with increasing concentrations of L-ferritin. The iron content was evaluated by ICP-MS. The protein concentration, proportional to the cell number, was determined from cell lysates by the Bradford assay, using BSA as a standard. c After 24h of incubation with 20nM of L-apo rhodamine Neuro2A cells were fixed in PLP and analysed under fluorescent microscopy. d MRI image of Neuro2A cells after 24h of incubation with different concentration of L-ferritin (respectively 0, 0.5, 1 and 1.5 uM).

10.5505/2017ichc.PP-113 [Cancer biology]

Ferritins: novel theranostic agents to target neoplasms

Gianluca Gonella, Valeria Bitonto, Diego Alberti, Simonetta Geninnati Crich, Silvio Aime, Juan C. Cutrin
Molecular Biotechnology Center, University of Torino, Italy

INTRODUCTION: Net Fe influx appears as a metabolic reprograming hallmark of malignant neoplasms. Accordingly, cancer cells up-regulate Tfr1, the specific receptor for transferrin, to guarantee its incorporation. However, a growing body of evidence shows that expression of SCARA5 by tumors, the receptor for L-ferritin, allow them to incorporate more quantity of Fe due to the high capacity of ferritin cage to delivery it. Therefore, ferritin nanocages can be exploited to effectively target SCARA5 positive tumors. In particular ferritin, thanks to its peculiar ability to self-assemble and disassemble upon different pH conditions, can accommodate within its core different theranostic agents. Herein we propose L-ferritin as a novel diagnostic agent for the visualization of two murine breast cancer cell lines.
MATERIALS-METHODS: murine breast cancer cells lines, 4T1 and TUBO the last generated from a spontaneous tumor of Her2/neu transgenic BALBc mice, were maintained as a monolayer culture in MEM Eagle modified medium. Cells were treated with different concentrations (0.5-1.5 μM) of horse spleen ferritin or rhodamine-labeled L-Apoferritin for 24 h. SCARA5 receptor was evaluated by mean of immunohistochemistry under fluorescent microscopy. L-ferritin internalization was assessed by MRI imaging and iron accumulation was estimated by ICP-MS.
RESULTS: Although SCARA5 expression was positive for the two cell lines, the reaction was more intense for all the 4T1 cells (fig 1a). Accordingly, after 24h of incubation with 20nM of L-apo rhodamine, a strong internalization of the protein was observed in 100% 4T1 cells (fig 1b). Ferritin internalization resulted in a decrease in the MRI signal intensity, clearly evident for the 4T1 cells.
CONCLUSION: L-ferritin must be thinking to be a powerful tool to target tumor cells population, considering that its receptor is not expressed ubiquitously. Due to L-ferritin was efficiently internalized by 4T1 cells, the results here provided suggest that L-ferritin can be used to specifically deliver theranostic agent against those neoplasms SCARA5 positive.

References: 1) Geninatti Crich S, et al Nanoscale 7:6527-33, 2015; 2) Cutrin JC, et al Clinical Neuropathology 35: 135, 2016.

Keywords: Theranostic, MRI, Breast Cancer, Immunohistochemistry

Figure 1

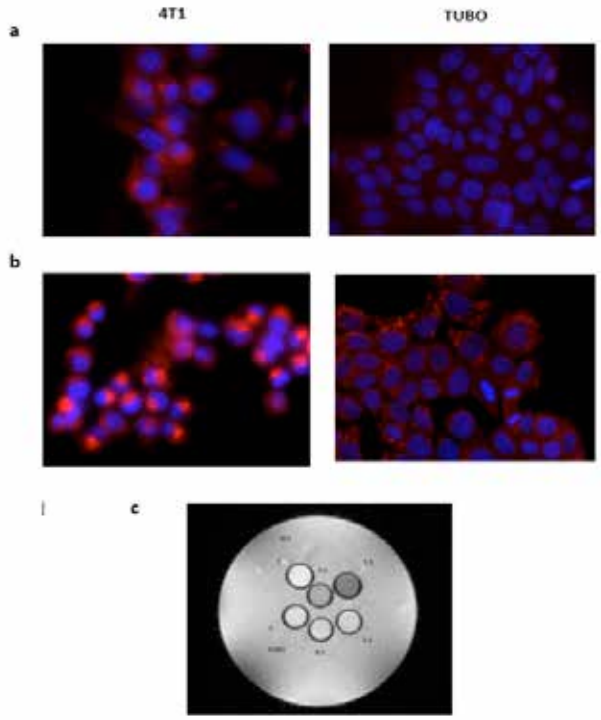

a 4T1 and TUBO cells fixed in PLP were first incubated overnight at 4°C with a rabbit monoclonal IgG anti SCARA5 (sc-98123 from Santa Cruz Biotechnology Inc, Dallas, Texas, USA) and then with a goat polyclonal IgG (H+L) Texas Red® labeled anti-rabbit antibody (Molecular Probe, Eugene, Oregon USA). b After 24h of incubation with 20nM of L-apo rhodamine 4T1 and TUBO cells were fixed in PLP and analysed under fluorescent microscopy. c MRI image of 4T1 and TUBO cells after 24h of incubation with different concentration of L-ferritin (respectively 0, 0.5 and 1.5 μM).

10.5505/2017ichc.PP-114 [Cancer biology]

Investigation of the Cytotoxicity of B13 on Human Lung Adenocarcinoma Cells

Hatice Mehtap Kutlu, Djanan Vejselova, Emre Çömlekçi
Department of Biology, Faculty of Science, Anadolu University, Eskisehir, Turkey

Introduction and OBJECTIVES: Ceramidases are enzymes that are involved in degradation of ceramides. Inhibition of ceramides has been proposed to increase cermide levels in the cells in turn causing cell death. In mammalian cells, accumulation of certain ceramide species in certain subcellular localizations might play a role in apoptosis, cell cycle arrest, and inhibition of cell motility. B13 has been reported to induce programmed cell death in different cancer cell lines via causing an increase in ceramide levels. In this study the cytotoxic effects of B13 on A549, human lung adenocarcinoma cell line by MTT (3-(4,5-dimethylthiazol-2-yl)-2,5-diphenyl-2H-tetrazolium bromide) colorimetric assay.
MATERIALS-METHODS: For a stock solution of B13 was prepared in dimethyl sulfoxide (DMSO) and further dilutions prepared in fresh culture medium were applied on A549 cells. For this purpose, A549 cells were incubated at 37°C in humidified atmosphere and exposed to concentrations of B13 for 24 hours. After the incubation period MTT was added in each well and the absorbance obtained from the living cells was read on Elisa reader. The percentages of viability and IC50 concentration of B13 for 24 hours on A549 cells were determined.
RESULTS: A549 cell's viability decreased in concentration-dependent manner after applied different B13 concentrations for 24 hours. The IC50 concentration of B13 on A549 cells was found to be 18µM. This might be considered as cytotoxic and anti-proliferative action of B13 on A549 cells.
CONCLUSIONS: On the basis of our results it can be concluded that B13 caused an increase in A549 cell viability in concentration-dependent manner and found to be highly cytotoxic to A549 cells for 24 hours. Consequently B13 inhibited the proliferation of A549 cells in short-time treatment but furhter investigations are needed for deeper useful results in caner treatment.

Keywords: Sphingolipid, B13, Lung cancer, Cytotoxicity, Cancer therapy.

10.5505/2017ichc.PP-115 [Cancer biology]

Examination of Ellagic Acid-Induced Morphological Changes on Lung Cancer Cells

Hatice Mehtap Kutlu, Merve Balıkçı
Department of Biology, Faculty of Science, Anadolu University, Eskisehir, Turkey

Introduction and OBJECTIVES: Ellagic acid is an anticarcinogenic substance found in blackberries, strawberries, groundnuts and many plant foods. Ellagic acid has been shown to has both preventative and remedial benefits almost in all types of cancer. Additionally, it is an antioxidant agent to trigger apoptosis in different cancer cell lines. Our study aimed to examine the potential apoptotic activities of commercial ellagic acid under A549 human lung adenocarcinoma cells by using confocal microscopy.
MATERIALS-METHODS: Cytotoxic effects of ellagic acid on A549 cells was detected via MTT assay. Dilutions prepared from the stock solution (in DMSO) of ellagic acid was applied on A549 cells for 24 hours at 37 0C and 5% CO2 in air. The plates were read on ELISA reader, at wavelength of 570 nm. For detecting the structural alterations IC50 concentration of ellagic acid was applied on A549 cell of 24 hours. Treated cells were stained with alexa flour-488 phalloidine and acridine orange then observed under concofal microscope.
RESULTS: Viability percentages were detected to decrease in concentration-dependent manner. IC50 value of ellagic acid on A549 cells for 24 hours was 30µM. Morphological changes detected via confocal microscopic evaluation were impairments in the damaged cell skeleton, chromatin condensation, cell shrinkage, nuclear fragmentation and other apoptotic characteristics in the nuclei.
CONCLUSIONS: According to our results, commertial ellagic acid caused structural changes in A549 cells being apoptosis trigering and highly cytotoxic under these cells. We can conclude that ellagic acid has cytotoxicity on A549 cancer cell line in low doses that might be a good inspirative data for further investigations of ellagic acid in direfent cancer types in order to discover an alternative agent for cancer treatment.

Keywords: Cytotoxcitiy, A549, Confocal microscopy.

10.5505/2017ichc.PP-116 [Cancer biology]

Niclosamide suppresses the proliferation of human epithelial ovarian cancer cells by inducing apoptosis and inhibiting Wnt/β-catenin signaling pathway

Ayşe Çakir Gündoğdu[1], Gülnur Take Kaplanoğlu[1], Hülya Sivas[2], Reyhan Varol[2], Cemile Merve Seymen[1]

[1]Department of Histology and Embryology, Faculty of Medicine, Gazi University, Ankara, Turkey

[2]Department of Biology, Faculty of Science, Anadolu University, Eskisehir, Turkey

Ovarian cancer is the most lethal gynecologic malignancy and since the current chemotherapeutic drugs are not effective enough, new methods of treatment are sought for. Niclosamide is an antihelminthic drug and it has been extensively studied for its anti-carcinogenic effects. In the present study, it is aimed to investigate the possible in vitro effects of niclosamide on ovarian cancer. Human ovarian epithelial adenocarcinoma cell line Ovcar-3 was used in the experiments. MTT assay was applied to investigate the cytotoxic effects of niclosamide on the cells. In order to assess the potency of niclosamide on Wnt/β-catenin signaling pathway that function in cell proliferation the β-catenin levels in the cells were analyzed by immunocytochemistry. The effects of the drug on apoptosis were detected by TUNEL method. All the assays were also performed for 5-fluorouracil (5-Fu) which is used as a therapeutic agent in cancer treatment routinely. The data for both drugs were assessed in comparison with each other and the references. It was found that niclosamide at 1 µM and 2 µM concentrations reduced cell viability, whereas 5-Fu showed its significant proliferation inhibitory effect at 10 µM and 20 µM. Niclosamide treatment decreased β-catenin staining in the cells significantly but 5-Fu did not affect β-catenin levels. Niclosamide led to an increase in apoptosis while this effect was weaker compared with 5-Fu. The statistical comparisons were made for each experiment and all differences among the groups were significant. The results indicate that niclosamide is effective on Ovcar-3 cell line at low concentrations, induces apoptosis and suppresses cell proliferation by inhibiting Wnt/β-catenin signaling pathway. In conclusion, these findings support clinical explorations to reposition niclosamide for ovarian cancer treatment as an alternative for current chemotherapeutics.

Keywords: Ovcar-3, niclosamide, 5-fluorouracil, Wnt/ β-catenin

Figure 1

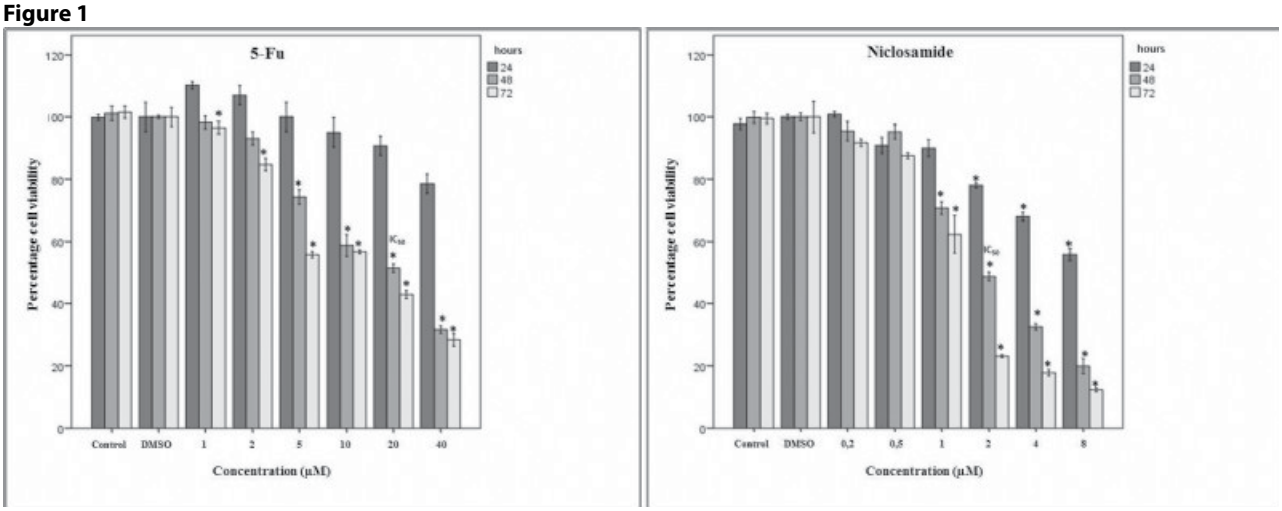

MTT test results for 5-Fu and Niclosamide on the Ovcar-3 cell line after 24 hours, 48 hours, and 72 hours (* p≤ 0.001)

Figure 2

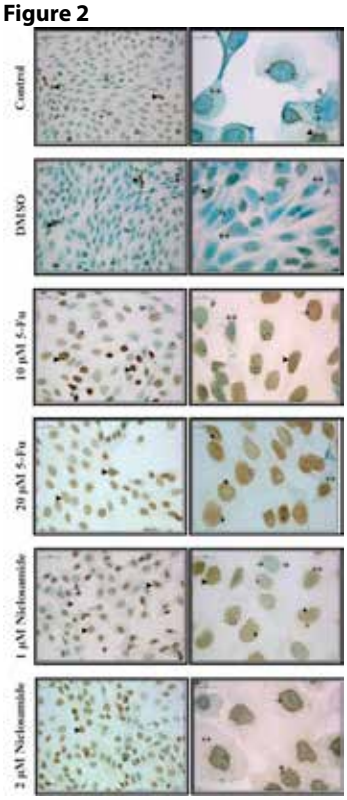

TUNEL staining of Ovcar-3 cells. TUNEL-positive cells (<), TUNEL-negative cells (Δ), nucleus (<), nucleolus (<), cytoplasm (<), weakly stained cells (<), ondulation on cell membrane (<), nucleus with damaged chromatin structure (+), nuclear fragments as apoptotic bodies (◊), lobulated nucleus (¶)

Figure 3

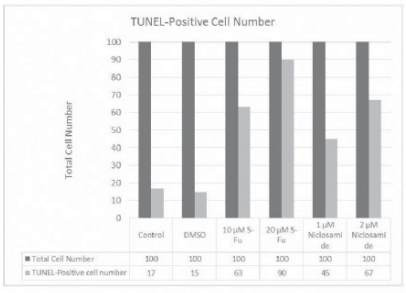

Groups	z	p	Significan
Control & DMSO	0,3858	0,700	p > 0.
Control & 10μM 5-Fu	6,6395	0,000	p < 0.0
Control & 20μM 5-Fu	10,3491	0,000	p < 0.0
Control & 1μM Niclosamide	4,2809	0,000	p < 0.0
Control & 2μM Niclosamide	7,1634	0,000	p < 0.0
DMSO & 10μM 5-FU	6,9587	0,000	p < 0.0
DMSO & 20μM 5-FU	10,6199	0,000	p < 0.0
DMSO & 1μM Niclosamide	4,6291	0,000	p < 0.0
DMSO & 2μM Niclosamide	7,476	0,000	p < 0.0
10μM 5-Fu & 20μM 5-FU	4,5028	0,000	p < 0.0
10μM 5-Fu & 1μM Niclosamide	2,5538	0,011	p < 0.
10μM 5-Fu & 2μM Niclosamide	0,593	0,553	p > 0.
20μM 5-Fu & 1μM Niclosamide	6,7937	0,000	p < 0.0
20μM 5-Fu & 2μM Niclosamide	3,9588	0,000	p < 0.0
1μM Niclosamide & 2μM Niclosamide	3,1339	0,002	p < 0.

Comparison of TUNEL-positive Ovcar-3 cell numbers between groups

Figure 4

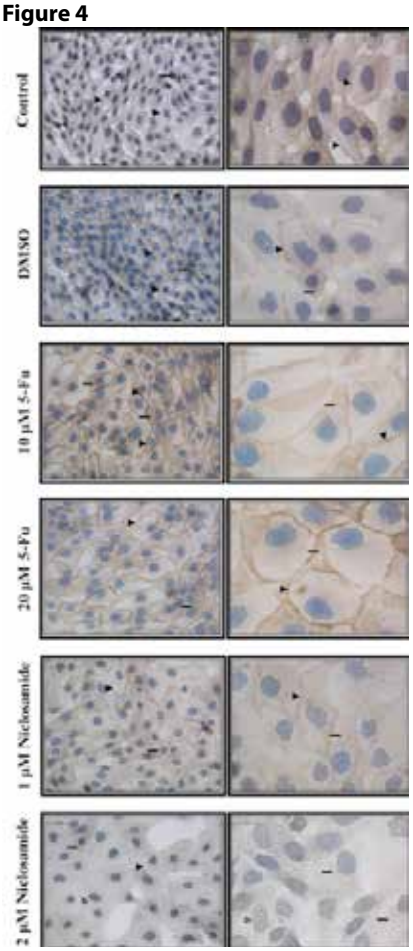

Immunocytochemistry analysis of Ovcar-3 cells stained with β-catenin antibody. membranous staining (<), cytoplasmic staining (<), negative staining (Δ)

Figure 5

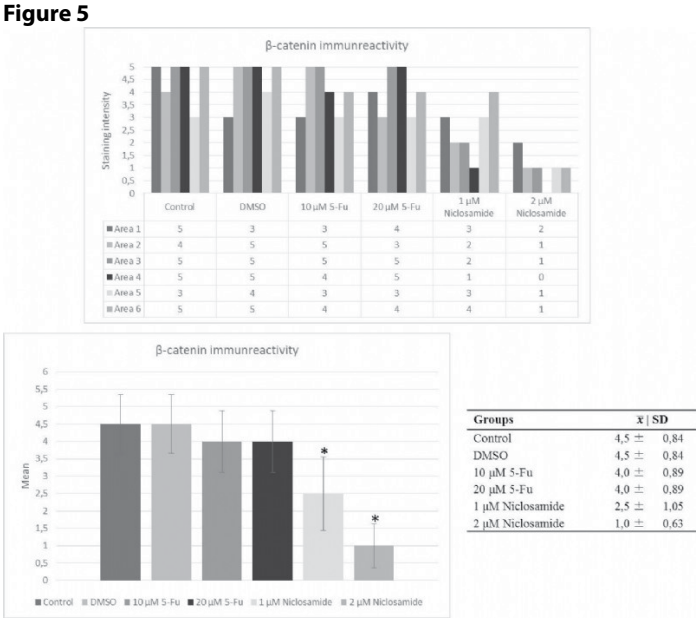

Groups	x̄ | SD
Control	4,5 ± 0,84
DMSO	4,5 ± 0,84
10 µM 5-Fu	4,0 ± 0,89
20 µM 5-Fu	4,0 ± 0,89
1 µM Niclosamide	2,5 ± 1,05
2 µM Niclosamide	1,0 ± 0,63

β-catenin staining intensity comparison between groups (*p < 0.001)

10.5505/2017ichc.PP-117 [Cancer biology]

Investigation of the effects of some endemic species of Onobrychis sp. on colon cancer cells

Muhammet Volkan Bülbül[1], Hanefi Özbek[2], Özlem Bahadır Acıkara[3], Serkan Özbilgin[3], Burçin Ergene Öz[3], Ekin Kurtul[4], Ilknur Keskin[1]

[1]Department of Histology and Embryology,Medipol University, Istanbul,Turkey

[2]Department of Pharmacology,Medipol University, Istanbul,Turkey

[3]Faculty of Pharmacy,Ankara University,Ankara,Turkey

[4]Department of Pharmacognosy,Ankara University,Turkey

Introduction & OBJECTIVES: In Turkey, the Ministry of Health declares the colorectal cancer is ranked 4th among all cancers. Besides traditional treatment options such as surgery and/or chemotherapy, medical plant based treatments are in high interest due to their high success rate of treatment and low risk of side effects. According to a study conducted by the World Health Organization, the 63% of anti-cancer drugs are obtained from the plants having big influence on cancer treatments.
Onobrychis sp. are perennial herbs of the Leguminosae family (Fabaceae).Onobrychis sp, a wild bait plant, is known to be endemically with twenty-seven species in Turkey. However, there is no study evaluating the anti-cancer effects of these species.
The aim of this study is to investigate the anti-cancer property of the herbaceous plant on colorectal cancer cell line. We have evaluated anti-cancer activity of four different species (*Onobrychis argyrea*,*Onobrychis galegifolia*, *Onobrychis tournefortii*, *Onobrychis albiflora*) of this genus against human colorectal cancer cells.
Materials & METHODS: Secondary colorectal cancer cells were incubated with different doses of plant herbal extracts either for 24 or 48 hours. Cell viability was tested using MTT assay.Apoptosis / necrosis kit was used to determine the death pathway of the cell.
RESULTS: The results revealed that cell viability and the concentration of the plant extract were inversely proportional. Among four different species, while *Onobrychis albiflora* is found to be the most active against colorectal cancer cell line (IC50 0,001396 g/mL), *Onobrychis argyrea* is found to be the least active (IC50 0,003287 g/mL). Cell death mechanism studies showed that apoptosis was the major pathway to cause cell mortality.
CONCLUSIONS: It is known that the Leguminosae family is one of the main sources of D-pinitol, which induces apoptosis in the MCF-7 cell line by inhibiting NF-kB pathway and inhibits metastasis in prostate cancer.We believe that cytotoxicity of the Leguminosae family strains that we used in this study is due to high D-pinitol content as described in the literature. MTT assays showed that these species are strongly cytotoxic on human colorectal cancer cell line and can be used to carry further studies.

Keywords: Colorectal cancer cells,MTT, Leguminosae Family,Apoptosis,Necrosis

10.5505/2017ichc.PP-118 [Cancer biology]

Investigating Of The Notch1 And Pakt 1/2/3 Immunoreactivities In Breast And Ovarian Cancer Cell Lines

Oya Korkmaz[1], Ilknur Keskin[1], Sevinç Inan[2]

[1]Department of Histology and Embriyology, Istanbul Medipol University Medicine Faculty, Istanbul, Turkey

[2]Department of Histology and Embriyology, Izmir Economi University Medicine Faculty, Izmir, Turkey

INTRODUCTION: Breast cancer represents the most common cancer among women throughout the world. It most commonly develops in cells from the lining of milk ducts and the lobules. MCF-7 cells are positive for estrogen and progesterone receptors. On the other hand, ovarian cancer is the most lethal of all gynecologic malignancies. There are four basic stages in ovarian cancer. Approximately 70% of the ovarian cancers are diagnosed at an advanced stage III or IV. SKOV-3 cells can form moderately well-differentiated adenocarcinoma consistent with ovarian primary cells.
The NOTCH1 and PI3K/AKT/mTOR pathway signaling pathways play many important key regulatory roles in cellular differentiation, proliferation, invasion and migration. The aim of this study was to investigate immunohistochemical distrubutions of NOTCH1 and pAKT 1/2/3 immunoreactivities in human breast and ovarian cancer cells.
METHODS: Cells from MCF-7 human breast cancer, SKOV-3 human ovarian cancer and control HEK cell lines were cultured in 6-well plate using DMEM, McCOY and DMEM medium, respectively. Cells were fixed with 4% paraformaldehyde for immunohistochemical analyses. Cells were incubated with anti-NOTCH1 and anti-pAKT1/2/3 primary antibodies. Intensity of immunoreactivities were evaluated by using semi-quantitative method, as mild (1), moderate (2), strong (3) and very strong (4) and analyzed statistically by using One-Way ANOVA test.
RESULTS: It was observed that increased immunoreactivities of NOTCH1 and pAKT1/2/3 in MCF-7 and SKOV-3 cancer cell lines compared to control HEK cells. While moderate to strong NOTCH1 immunoreactivity was detected in the cytoplasm of SKOV-3 cells; very strong pAKT1/2/3 immunoreactivity was observed in perinuclear region of these cells. Immunoreactivity of NOTCH1 was detected as mild to moderate in the cytoplasm of MCF7 cells; strong to very strong pAKT1/2/3 immunoreactivity was observed in the nuclei of these cells. NOTCH1 and pAKT immunoreactivities were observed as mild in the cytoplasm of control HEK cells ($p<0.05$).
CONCLUSION: In many biological and clinical aspects of breast and ovarian tumorigenesis; NOTCH1 and PI3K/AKT/mTOR signaling pathways appear to be involved include tumor initiation and progression, metastasis, resistance to chemotherapy, angiogenesis and epithelial-mesenchymal transition. The results of this study showed that these pathways represent attractive therapeutic targets in breast and ovarian cancers.

Keywords: Breast cancer, Ovarian cancer, Immunohistochemistry, NOTCH1, pAKT 1/2/3

NOTCH1 and pAKT 1/2/3 immunoreactivities in human breast and ovarian cancer cells

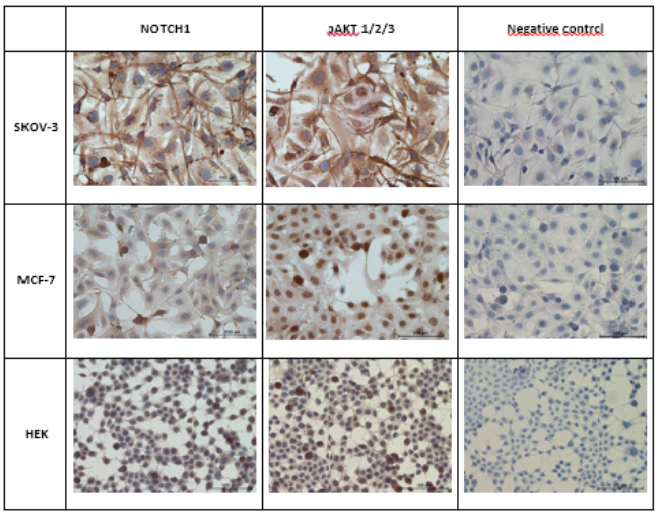

	NOTCH1	pAKT 1/2/3
SKOV-3	++/+++	++++
MCF-7	+/++	+++/++++
HEK	+	+

10.5505/2017ichc.PP-119 [Cancer biology]

Expression of Valosin containing protein and Small Valosin Interacting Protein in human testes tumours: A Tissue Microarray Study of 120 Cases

Hilal Nakkaş[1], Şeyma Kipel[1], Gülben Akcan[1], Cansu Şahin[1], Arslan Ardıçoğlu[2], Berrak Gümüşkaya Öcal[3], Sevil Çaylı[1]

[1]Department of Histology and Embryology, Ankara Yildirim Beyazit University, Ankara, Turkey

[2]Department of Urology, Ankara Yildirim Beyazit University, Ankara,Turkey

[3]Department of Pathology, Ankara Yildirim Beyazit University, Ankara, Turkey

INTRODUCTION: Valosin-containing protein (VCP), also called p97, is a AAA+ ATPase that has been shown to be involved in many cellular events. By recent studies it has been shown that p97/VCP plays a role in most of cancer types and recommended to use VCP inhibitors as a therapeutic agent. SVIP (small p97/VCP-interacting protein) was identified as one of many cofactors regulating the VCP function. However, there exist no information about the involvement of p97/VCP and SVIP in testicular human cancers. In this study, we aimed to investigate the expressional differences of p97/VCP and SVIP in different testicular cancers.
MATERIALS-METHODS: We used retrospectively 120 patients' archive materials who take different types of testes neoplasm (seminomas (n = 54), mixed germ cell tumours (n=39), embryonal carcinomas (n = 4), Sertoli cell adenoma (n=5), Leydig cell hyperplasia (n=7), diffuse large cell lymphoma (n=4), plasmocytoma (n=1), adenomatoid tumour (n=4), yolk sac tumours(n=1), liposarcoma(n=1)) diagnosis from urology and pathology clinics. We prepared new blocks from two different areas of these tumours by tissue-micro array technique and stained them with VCP and SVIP with immunohistochemistry. The evaluation of immunohistochemistry was done with Hscore analysis.
RESULTS: p97/VCP exhibited higher expression in both seminomas and mixed/non seminomatous tumors, compared with atrophic/benign tissue ($p < 0.001$). SVIP expression was lower than p97/VCP expression within the seminoma group ($p = 0.003$), but not within the mixed/nonseminomatous group. The majority of the tested testicular tumor cases (115/120, 96%) exhibited high protein expression of p97/VCP. In contrast, 4 out of 5 tested cases (80%) exhibited strong expression of SVIP in Sertoli cell tumors. The correlation between the protein expresions and clinical features of cases are underevaluation.
CONCLUSIONS: This study demonstrated that p97/VCP is a novel diagnostic marker for germ cell tumours and is also expressed frequently in Sertoli cell tumors. The high expression levels might be indicative for a treatment response to p97/VCP inhibitors which should be evaluated in further studies.

Keywords: Valosin containing protein, Small VCP interacting protein, testicular tumors

10.5505/2017ichc.PP-120 [Cancer biology]

Effect of Inula viscosa extract on apoptosis in human breast cancer cell line MDA-MB-231

Pınar Kılıçarslan Sönmez[1], Damla Akoğulları[1], Elgin Türköz Uluer[1], Fatih Çöllü[2], Mehmet Ibrahim Tuğlu[1]

[1]Department of Histology and Embrylogy, Celal Bayar University, Manisa, Turkey

[2]Department of Biology, Celal Bayar University, Manisa, Turkey

Inula viscosa known as a medicinal plant which has therapeutic properties in treatment of various diseases and particularly cancer. In this study we aimed to show its anti-proliferative and apoptotic effects on MDA-MB- 231 human breast cancer cell line. Air-dried leaves of Inula viscosa were subjected to soxhlet extraction process with ethyl acetate. Ethanolic extract was dried at 37 C. Then it was dissolved in distilled water. MDA- MB-231 cells were cultured in a 96-multiwell plate to determine the cell growth using the MTT assay. The 50% inhibitory concentration (IC50) for this plant was defined as the concentration producing 50% decrease in cell growth. Inula viscosa was found to inhibit the growth of MDA-MB- 231 cell lines in dose and time-dependent manner. In the other hand, cells were cultured in a 24-well plate to evaluate for iNOS , eNOS, VEGF, TGFβ and apoptosis by immunocytochemical staining and tunel assay. Statistical analysis was performed with the scoring. Inula viscosa extracts significantly inhibited cell growth in a dose-dependent manner in the tested cancer cell line MDA-MB- 231. We found that the toxic effect created by oxidative stress use apoptotic mechanisms. Data indicated that the treated MDA-MB-231 cell line exhibited a marked increase in apoptosis. The anticancer effect of this plant has been recently reported. Our results are in agreement with other data reported in literature showing that this plant contains some compounds that have anticancer potential. And our findings suggest that due to its anticancer potential, Inula viscosa may be used as an alternative for the management of cancer. Therefore future studies will focus on the identification of the molecules responsible for the anticancer activity.

Keywords: Anticancer, Inula viscosa, Antiproliferative, MDA-MB-231

10.5505/2017ichc.PP-121 [Cancer biology]

Anti-cancer effect of Mirtazapine against MCF-7, HCT-116 and MiaPaCa-2 cancer cells

Ilknur Keskin[1], Duygu Gursoy[2], Hilal Eren Gözel[1], Sibel Erdem[3], Gökhan Cüce[4]

[1]Department of Histology and Embryology, Medipol University, Istanbul, Turkey

[2]Regenerative and Restorative Medical Research Center, Medipol University, Istanbul, Turkey

[3]Department of Biochemistry, Medipol University, Istanbul, Turkey

[4]Department of Histology and Embryology, Necmettin Erbakan University, Turkey

Introduction & Objectives
Paclitaxel (taxol) is an organic molecule that promotes the polymerization of tubulin resulting in cell mortality by disrupting the normal microtubule dynamics required for cell division and vital interphase processes. Nowadays, Paclitaxel is used for the treatment of various cancers including breast, melanoma, lung, esophageal, prostate, bladder and solid tumors. On the other hand, Paclitaxel has many side effects including hypersensitivity reactions, neurotoxicity and hematological toxicities. Therefore, it is vital to discover effective and safe anticancer agents.
Mirtazapine is a psychiatric drug used to treat nausea, insomnia, and depression seen after chemotherapy and advanced cancer treatments. Moreover, it is reported that Mirtazapine may effect in slowing the rate of cancer growth. In this study, it is aimed to determine potential anti-cancer effects of Mirtazapine against different cancer cell lines and to compare its effectiveness with a well-known anticancer drug, Paclitaxel.

Materials & METHODS:
MiaPaCa-2 (pancreas), MCF-7 (breast) and HCT-116 (colon) cell lines were treated with gradually increasing 10 different doses (10 uM - 0,1 uM) of Paclitaxel and Mirtazapine separately. Cell viability was measured using MTT assay. The IC50 values of each drug for all cancer cell lines were determined.

RESULTS:
While Paclitaxel and Mirtazapine had similar IC50 values against MiaPaCa-2 cell line, the IC50 values of the two drugs were quite different for MCF-7 cell line. Paclitaxel's IC50 value was determined as 63 nM and Mirtazapine's IC50 value was determined as 1,2 uM against MCF-7 cell line. In the case of HCT-116 cell line, IC50 values were calculated as 42 uM for Paclitaxel, 3,3 uM for Mitazapine.

CONCLUSION:
Our results showed that Mirtazapine is more effective anti-cancer drug than Paclitaxel for HCT116 cell line. On the other hand, there was not a big difference in between two drugs against MiaPaCa-2 cell line. In addition, Mirtazapine was not as effective as Paclitaxel for MCF-7 cell line. It can be concluded that Mirtazapine might be a promising candidate for cancer treatment since it is already being used to diminish side effects of chemotherapy. Therefore, Mitrazipine's anticancer property is worth further investigation in different in vitro/in vivo models.

Keywords: MTT assay, Paclitaxel, Mirtazapine, HCT-116, MCF-7, MiaPaCa-2

HCT-116 Mirtazapine

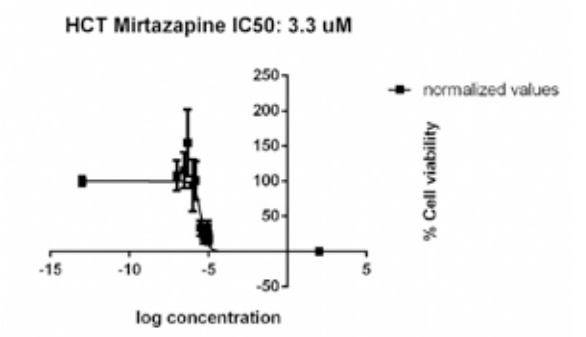

HCT-116 Paclitaxel

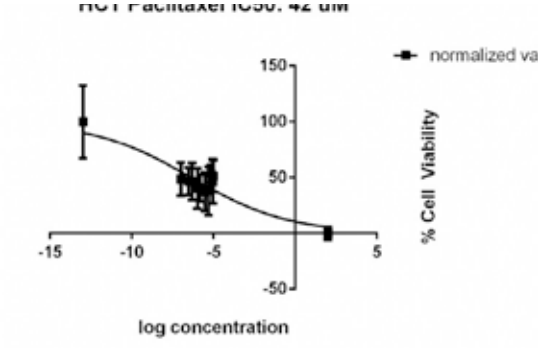

MCF-7 Mirtazapine

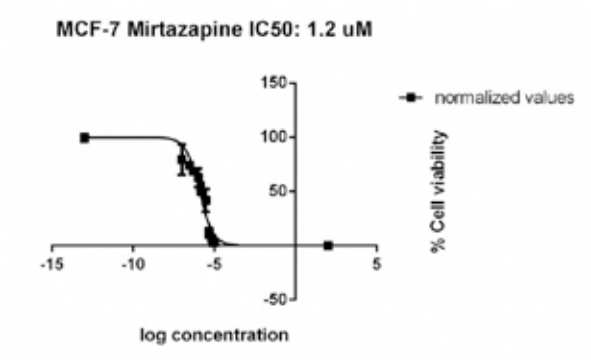

MCF-7 Paclitaxel

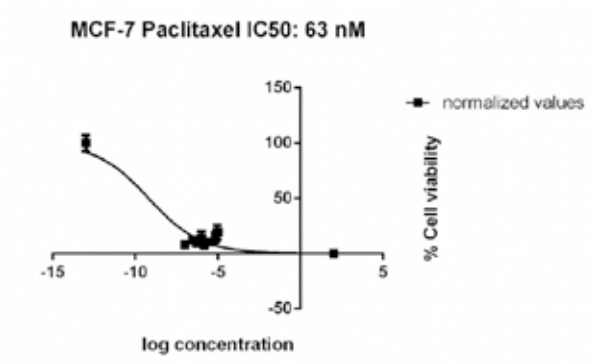

Miapaca Mirtazapine

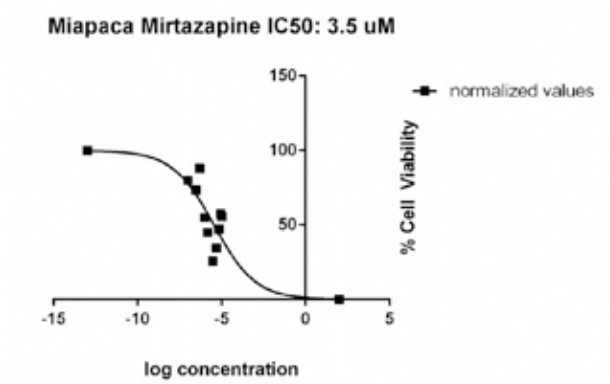

Miapaca-2 Paclitaxel

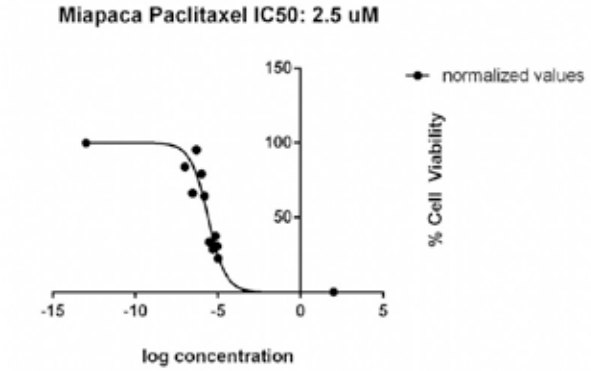

10.5505/2017ichc.PP-122 [Cancer biology]

Insignificant association between megalin expression in prostate cancer tissue and prostate cancer stem cells

Gulperi Oktem[1], Gunel Mukhtarova[2], Cuneyd Parlayan[3], Sule Ayla[4], Asli Cakir[5], Selcuk Guven[6]

[1]Department of Histology and Embryology, Faculty of Medicine, Ege University, Izmir, Turkey

[2]Department of Stem Cell, Health Science Institute, Ege University, Izmir, Turkey,

[3]Department of Biomedical Engineering, School of Engineering and Natural Science, Istanbul Medipol University, Istanbul, Turkey

[4]Department of Histology and Embryology, Faculty of Medicine, Istanbul Medipol University, Istanbul, Turkey

[5]Department of Pathology, Faculty of Medicine, Istanbul Medipol University, Istanbul, Turkey

[6]Department of Urology, Faculty of Medicine, Istanbul Medipol University, Istanbul, Turkey

Introduction & OBJECTIVES: An endocytic multiligand receptor megalin (LRP2, low density lipoprotein-related protein 2) is a transmembrane protein of approximately 600 kDa (encoded by LRP2) that known to mediate uptake and trafficking of of a vast number of ligands: nutrients including vitamin carriers (e.g., of vitamin B12 and vitamin D), apolipoproteins, albumin and signaling molecules. Megalin also known to modulate the signaling of sonic hedgehog (SHH), epidermal growth factor (EGF), and insulin-like growth factor-1 (IGF-1).
Megalin expressed by prostate epithelial cells. In cancer tissue and cell also have been shown increased megalin expression. This increased megalin expression provide more uptake of the nutrient and signal molecules in the rapidly growing cancer cells that show an increased demand for nutrients.
The aim of our study was to investigate megalin expression in prostate cancer tissue sample and prostate cancer cell line, to compare expression levels with patient clinical data and to explore potential associations with disease risk, recurrence/ progression, prostate-specific mortality, and possible interactions with primary ADT in hospital base study for the understand a role of megalin in tumor progression.
Materials & METHODS: Primary tumors (n = 92) were stained with megalin antibodies using immunohistochemistry and compared expression levels with clinical data.
We analysed gene expression profiles of megalin in prostate cancer stem cell (Du145 CSC) comparatively to non-CSC (Du145 non-CSC), prostate cancer cell line (Du145 cell line) and prostate epithelial cell line (RWPE1 cell line). Whole transcriptome sequencing was done on relevant experimental groups.
RESULTS: İn result immunohistochemical assay and transcriptom sequencing analysis we did not find significantly correlation beetwen megalin ekspression in patient sample tissue and prostate cancer cell line, prostate cancer stem cell line with patient clinical date
CONCLUSION: In conclusion, while, our finding did not support a role of megalin in tumor progression for the robustness of our results may reqiure larger study that include analisys of genetic variation within LRP2 gene and alternative splicing during LRP2 gene expression.

Keywords: megalin, prostate cancer, stem cell, immunohistochemistry.

10.5505/2017ichc.PP-123 [Cancer biology]

Viability and apoptotic activation of melatonin-treated human breast cancer cells

Elvan Şahin[1], Semin Gedikli[2], Abdulgani Tatar[3]

[1]Department of Histology and Embryology, Medical School, Sakarya University, Korucuk, Sakarya, Turkey

[2]Department of Histology and Embryology, Faculty of Veterinary Medicine, Ataturk University, Erzurum, Turkey

[3]Department of Medical Genetics, Medical School, Ataturk University, Erzurum, Turkey

INTRODUCTION & OBJECTIVES: Breast cancer is one of the most common types of cancer in the world and is located at the top of death rates resulting from cancer. An innovation of a novel agent for the treatment of this disease is among the primary goals of many researchers. In this study, we aimed to examine the effects of melatonin that is known as a powerful antioxidant with versatile effects in the modern medicine, on breast cancer.
MATERIALS & METHODS: To determine the cytotoxic doses of melatonin, it was applied on human breast cancer MCF-7 cell line at intervals of 10 nM-100 000 nM concentrations. The experimental groups were consisted of untreated control group and 8 treatment groups which were applied 10 nM, 25 nM, 50 nM, 100 nM, 1000 nM, 10 000 nM, 50 000 nM and 100 000 nM concentrations of melatonin on. After the treatments, cell viability values of 9 experimental groups were measured by MTT assay (Figure 1) and compared statistically with each other (Table 1). Then, apoptotic activity was investigated by using Bax and p53 immunostaining of MCF-7 cells (Figure 2).
RESULTS: The results showed that melatonin inhibited MCF-7 cell proliferation, indicating cytotoxic effects of melatonin on MCF-7 cells (Figure 1). Increased Bax and p53 immunpositivities were determined in the experimental groups which were treated with 1000 nM or higher concentrations of melatonin, suggesting that melatonin application may induce apoptosis in MCF-7 cells (Figure 2).
CONCLUSION: The findings of our study reveals that melatonin may be a candidate agent for the treatment of breast cancer.

Keywords: melatonin, MCF-7 cell line, viability, apoptosis, Bax, p53

Figure 1

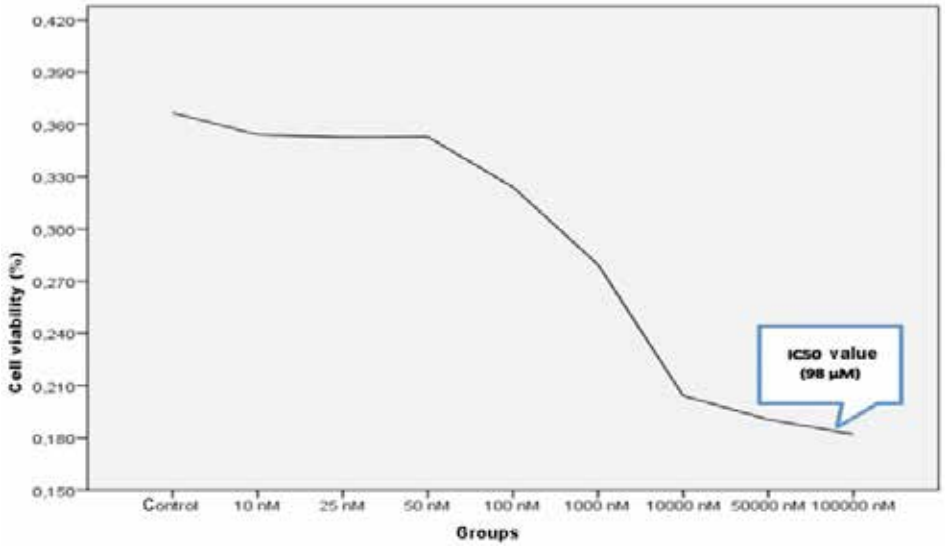

Viability of MCF-7 cells at the end of the 24-hour-melatonin application

Figure 2

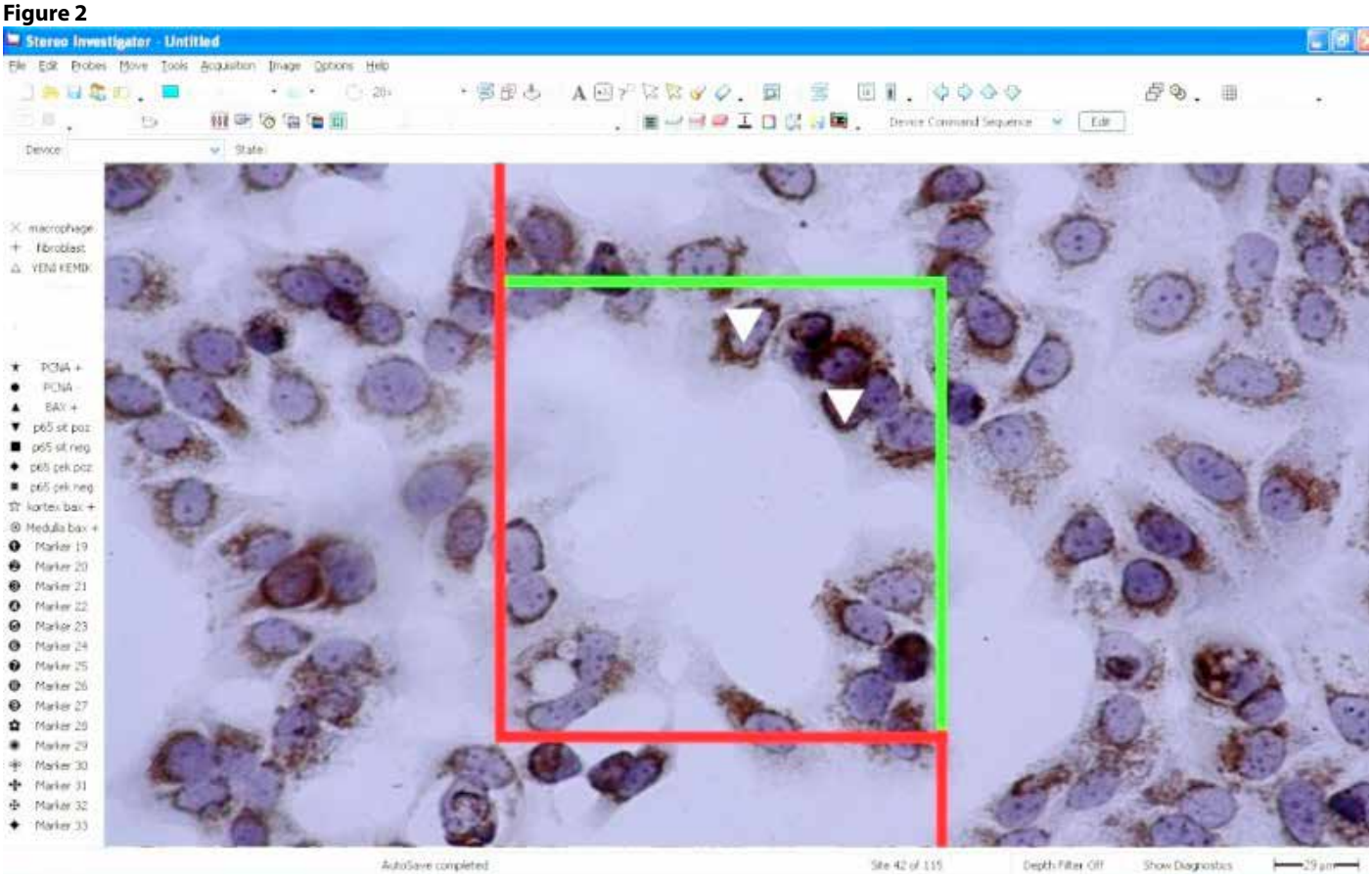

Stereological evaluation of Bax-immunostained MCF-7 cells by using "Fractionator Frame" method. White arrow heads show Bax-immunopositive cells.

Table 1. Viability values of MCF-7 cells treated with different concentrations of melatonin.

Experimental groups	Cell viability (%)
Control	0,3667± 0,0770a
10 nM melatonin	0,3542± 0,0525a
25 nM melatonin	0,3527± 0,0573a
50 nM melatonin	0,3528± 0,0544a
100 nM melatonin	0,3240± 0,0294a
1000 nM melatonin	0,2795± 0,0563b
10 000 nM melatonin	0,2041± 0,0416c
50 000 nM melatonin	0,1905± 0,0661c
100 000 nM melatonin	0,1820± 0,0305c

Notes: Means in the second column by the same superscript letter are not statistically significantly different under the One-Way-Anova, Post Hoc Duncan test ($p<0.05$). Results are mean±standard deviation.

10.5505/2017ichc.PP-124 [Cancer biology]

The Effects of CAPE and EGCG on Cyclooxygenase and Junctional Complexes in Breast Cancer Cell Lines

Sevinc Inan[1], Fatma Firat[2], Damla Akogullari[2], Elgin Türkoz Uluer[2]

[1]Department of Histology and Embryology, Faculty of Medicine, Izmir University of Economics, Izmir, Turkey

[2]Department of Histology and Embryology, Faculty of Medicine, Celal Bayar University, Manisa, Turkey

INTRODUCTION: Breast cancer is most frequent malignancy among women worldwide. Cyclooxygenase (COX) is an inducible enzyme, catalyzes a key step converting arachidonic acid to prostaglandins, is highly induced at inflammatory sites and during tumor progression. Epithelial cells present apical junctional complex connected to the actin cytoskeleton, which maintains the dynamic properties of this complex, tissue architecture and cell homeostasis. Studies have indicated that apical junctional complex alterations and actin cytoskeleton disorganization, plays critical role in epithelial cancer progression. Antioxidant Caffeic acid phenethyl ester (CAPE), a component of honeybee propolis, has been determined to have anti-oxidant, anti-inflammatory and anti-apoptotic properties. Also, Epigallocatechin gallate (EGCG) is the most abundant component of green tea catechins and has strong physiological activities. The aim of this study was to investigate the effects of CAPE and EGCG on COX and junctional complexes in vitro against two human breast adenocarcinoma cell lines using indirect immunohistochemistry.
Materials-METHODS: MDA-MB231 and MCF-7 cells were grown in RPMI 1640 medium supplemented with 10% fetal calf serum and penicillin/streptomycin. Cultured cells were maintained in humidified environment. Cells were treated with 10µm CAPE and EGCG for 24 h and stained with anti-COX1, anti-COX2, anti-ZO1, anti-ZO2, anti-JAM-A and anti-E-CAD primary antibodies using indirect immunohistochemical method. Scores of staining intensities were graded as mild, moderate, strong and very strong. The results were evaluated using ANOVA statistical test.
RESULTS: While immunoreactivities of COX-2, ZO-2 and JAM-A were observed as strong/very strong, immunoreactivities of COX-1, ZO-1 and E-CAD were observed as very strong/moderate in MCF-7 and MDA-MB231 cells, respectively (Table 1, Figure 1). It was determined that the immunoreactivities decreased using CAPE+EGCG treatment ($p<0.05$).
CONCLUSION: These results provided evidence for applications of EGCG and CAPE, which had an effect on cyclooxygenase and junctional complexes. JAM-A be negatively correlated with the migration of breast cancer cells. Junctional complexes are dysregulated in various cancers and are closely associated with the invasion and metastasis of cancers such as breast cancer. In conclusion, EGCG+CAPE might improve anticancer activity in in-vitro models via its anti-apoptotic and anti-cancer potentials. These might be target molecules which lead to a promising new therapeutic approach against cancers.

Keywords: Breast cancer, CAPE, EGCG, COX-2, JAM-A, E-CAD

Table 1

MDA-MB231	CAPE	CAPE+EGCG	EGCG	CONTROL
COX1	3	2	3	2
COX2	2	3	2	4
ZO1	2	2	2	2
ZO2	3	2	3	4
JAM-A	3	2	2	4
E-CAD	3	2	3	2
MCF-7	CAPE	CAPE+EGCG	EGCG	CONTROL
3	2	2	3	4
2	2	2	3	3
2	2	2	3	4
3	2	2	2	3
2	3	3	2	3
2	2	2	2	4

10.5505/2017ichc.PP-125 [Cancer biology]

Effects of Electromagnetic Field Applications on Cancer Cells

Pelin Toros[1], Mehmet Gumusay[2], Busra Sen[1], Ecem Topac[1], Pinar Kılıcaslan Sonmez[1], Isil Aydemir[1], Kamil Vural[3], Adnan Kaya[4], Ibrahim Tuglu[1]

[1]Department of Histology and Embryology, Celal Bayar University, Manisa, Turkey

[2]Department of Biomedical Technologies, Izmir Katip Celebi University, Izmir, Turkey

[3]Department of Pharmacology, Celal Bayar University, Manisa, Turkey

[4]Department of Electrical and Electronics Engineering, Izmir Katip Celebi University, Izmir, Turkey

PMEF uses small electrical stimuli to generate therapeutic changes in tissues. PEMF, a wide area of use, affects the processes of proliferation, migration, differentiation and the mechanisms of treatment are not fully understood. For this purpose, MDA cells with MCF-7 representing aggressive and non-aggressive cancer cells, to compare the processes of proliferation and differentiation in stem cells NB2A mouse neuroblastoma cells Neurite-proliferating and non-proliferating cells, also the effects of two different PEMF applications using mesenchymal stem cells to compare normal somatic cells were examined in terms of proliferation and wound healing.
MATERIALS & METHODS: PEMF was applied in two different ways 75 mHZ and 27 mHZ. Low and high frequency EMA was applied to the cells. The cells were compared in the HEPES buffer media after 5 hours of application except the incubator and after the overnight wait. The control group was the samples kept in the same environment but not applied. MCF-7, MDA, NA2b and Bone Marrow Mesenchymal Stem Cell were removed from the frozen medium and allowed to grow in culture medium. MCF-7, MDA, NA2b and Bone Marrow Mesenchymal Stem Cell were removed from the frozen medium and allowed to grow in culture medium. Cell proliferation process the effect of MTT on cell proliferation and migration was achieved by creating a scratch in the culture medium. Closure of the scratched areas by cells was evaluated by morphometric method. Oxidative stress induced by EMA and apoptosis were assessed by NOS and TUNEL immunohistochemistry.
CONCLUSION: As a result of the applications, it was observed that low-frequency EMA treatment increased proliferation in non-cancerous cells while stopping proliferation in cancerous cells. Findings suggest that low-frequency EMA application, which affects the proliferation and migration processes of cells with cancer therapy, has a better quality of recovery with fewer side effects and that life could be an important means of hope.

Keywords: Electromagnetic field, Cancer, NB2a, MCF-7, MDA, Stem cell

10.5505/2017ichc.PP-126 [Cancer biology]

Evaluation of eribulin mesylate efficacy on proliferation and apoptosis of C6 Glioblastoma cells

Hale Erbilir[1], Gamze Tanriverdi[2], Burcu Biltekin[2], Meral Koyuturk[2], Zeliha Yazici[1]

[1]Department of Pharmacology, Cerrahpasa Medical Faculty, Istanbul University, Istanbul, Turkey

[2]Department of Histology and Embryology, Cerrahpasa Medical Faculty, Istanbul University, Istanbul, Turkey

OBJECTIVE: Glioblastoma multiforme (GBM) is the most common type of cancer, among primary brain tumors in adults which is highly resistant and has a poor prognosis. Eribulin mesylate is a fully synthetic macrocyclic analogue of the marine natural product halichondrin B and leads to apoptosis by blocking cell cycle at G2/M phase. Resistant cancers treated with eribulin showed significant increase in survival rate. Despite it is used metatastatic breast cancer treatment many times, there are no adequate studies showing eribulin clinical efficacy in brain tumors. Therefore, the following study is designed to examine the efficacy of eribulin mesylate in the treatment of GBM.
MATERIAL-METHODS: In our study, potential proliferative and apoptotic effects of eribulin were evaluated on C6 glioblastoma cell line in vitro model. The proliferation was determined by BrdU labeling and apoptotic cell death by Caspase-3 labeling. To evaluate the effects of eribulin on cytoskeleton labeling with β-tubulin was performed. From the results of preliminary studies six groups were created for control and therapeutic doses of Eribulin (5 nM, 10 nM. 15 nM, 20 nM and 25 nM) at 24 and 48 hours incubation periods. Immunreactivity results were assessed by using H-SCORE analysis. Cell proliferation and apoptosis rates were determined by the percent of labeled cells.
RESULTS: In the doses of 15 nM, 20 nM and 25 nM eribulin significantly reduced proliferation index in C6 cells at 24 and 48 hours of incubation period ($p<0.05$). At the same time, the apoptotic index significantly increased in all treatment groups at 24 and 48 hours of incubation period ($p<0.05$). The cytoskeleton structure changed in all treatment groups at both 24 and 48 hours incubation period and it's verified by β-tubulin labelling.
CONCLUSION: Obtained results show that eribulin mesylate has potent antiproliferative and apoptotic effects on C6 glioblastoma cells. It can be used as an alternative treatment for the patient with resistant to current treatment in the future but there is a necessity for further studies to explain acting mechanism of Eribulin on angiogenesis and blood brain barrier.

Keywords: Eribulin mesylate, Glioblastoma multiforme, apoptosis, proliferation.

10.5505/2017ichc.PP-127 [Cancer biology]

Effects of a newly synthesized nano-silymarin compound on human breast cancer cell line

Hatice Mehtap Kutlu, Emre Çömlekçi, Ece Kaya
Department of Biology, Anadolu University, Eskisehir, Turkey

Introduction and OBJECTIVES: The aim of the study was to investigate the potential cytotoxic effects of silymarin loaded solid lipid nanoparticle on MCF7 cells and its effects on MCF7 cell ultrastructure.
MATERIALS-METHODS: The cytotoxic effects of nano-silymarin formulation on MCF7 cells were determined by MTT colorimetric assay. Stock solution of commercial silymarin (in DMSO), was applied to MCF7 cells for 24 hours in different concentrations. The plates were read on ELISA reader at 570nm wavelength. For detecting the morphological changes, MCF7 cells were treated with the IC50 concentration of silymarin-nano form for 24 hours. After incubation, cells were stained with Alexa fluor-488 phalloidin and acridine orange and evaluated and photographed under confocal microscope and transmission microscope.
RESULTS: Viability percentages of silymarin-nano treated cells decreased in low drug concentrations and IC50 (18µM) value was calculated. This value altered the morphology of MCF7 cells causing disintegrated and deformed nuclei, cell skeleton and chromatin, holes on cytoskeleton as well as cell shrinkage.
CONCLUSIONS: On the basis on our results, it might be concluded that silymarin-nano formulation form showed high cytotoxicity on human breast cancer cells and exerts a potential promising to be cytotoxic and anti-proliferative as well apoptosis triggering agent in cancer cells for design of pharmaceutical products but further deeper investigations are required.

Keywords: Silymarin, Nano-compound, MCF-7, Confocal microscopy, TEM.

10.5505/2017ichc.PP-128 [Cancer biology]

Investigation of NO Levels In A549 And Beas-2b Cell Lines

Hasan Dağlı[1], Seher Kara Öngel[1], Ebru Temiz[2], Metin Kılınç[1]

[1]Department Of Medical Biochemistry, University Of Kahramanmaraş Sütçü Imam University, Kahramanmaraş, Turkey

[2]Department Of Medical Biology, University Of Gaziantep, Gaziantep, Turkey

Nitric oxide is an important cellular signaling molecule involved in numerous physiological and pathological activity. It is a powerful vasodilator, stimulates smooth muscle relaxation, immunomodulation, neurotransmission and inhibits platelet aggregation. The large majority of the facus and knowledge about NO has revolved around the endothelial derivered NO. Endothelial NO synthase (eNOS) has been shown to have numerous other vascular protective effects including inhibision of platelet aggregetion and adhesion, promotion of angiogenesis and anti-inflammation. In this study, we investigated NO levels in the lung cancer cell line (A549) and epithelial bronchial cell line (BEAS-2B). For this purpose A549 and BEAS-2B cell lines were exposed to three different miRNAs miR-503, miR-150 and miR-15a targeting MALAT1 in the cell cultur medium. The determinations of NO levels were performed spectrophotometrically. The results were evaluated as NO nmol/ml. There was no significant difference in the NO levels of Beas-2b treated with three different miRNAs. However, a significant difference was found in the NO levels of A549 treated with three different miRNAs. Furthermore, the A459 showed an interesting increase in the NO levels treated with miR-503 and miR-15a as compared to the Beas-2b. In the light of these findings, we believe NO level to be an important parameter to be measured in A549 when angiogenesis increases in cancerous cells.

Keywords: NO, MALAT1, A549, BEAS-2B

10.5505/2017ichc.PP-129 [Cancer biology]

Quantitative Analyses of In-Vitro Tube Formation for Angiogenesis

Yasin Ilgaz[1], Barıs Baykal[1], Tugba Fatsa[2], Esra Erdogan[1]

[1]Department of Medical Histology and Embryology, University of Health Sciences, Gulhane Faculty of Medicine, Ankara, Turkey

[2]Stem Cell Laboratory, Gulhane Research Institute, University of Health Sciences, Ankara, Turkey

Angiogenesis is essential for developmental processes and wound healing, but is also associated with a variety of pathological conditions such as cancer or inflammatory diseases. The in-vitro tube formation assay, one of the widespread methods is being used by researchers in angiogenesis studies. To summarize the assay's method, human umbilical vascular endothelial cells are suspended in conditioned media and plated on basement membrane matrix (Matrigel). The endothelial cells form capillary like tubules and the tubules can be visualized using a phase contrast inverted microscope (Figure 1).
Plentiful approaches have been used to quantitate results of tube formation, but there is no consensus about the best quantification method and parameters. The number of tubules and junctions, areas of loops, branch sites and mean tubule length can be used as evaluation parameters of in vitro tube formation assay. These parameters are valuable for determining the effect of exogenous factors on angiogenesis. The number of tubules is easily calculated by using computer software like "ImageJ". A tube is considered to be the part of the tubular structure between two branching points or a branching site and a loose end. "Angiosys" and "Wimasis-WimTube" are other useful computerized automated analysis tools for detection of parameters other than tubule number (Figure 2). "The number of junctions" represents the linkage each cell has with each other. "The number of branch sites" is the number of connection points where three or more tubes converge. "Loop's area" is a region of the background enclosed by the tubular structure. "Mean Tube Length" is the arithmetic mean of the individual tube lengths. In addition to result images, resulting data are computed by both analysis software products without any additional tweaking or coding required. The number of tubules and junctions, areas of loops, branch sites and mean tubule length are potentially quantified parameters for the in-vitro tube formation assay.

Keywords: The In-Vitro Tube Formation Assay, Angiogenesis, Quantitative Analysis

Figure 1

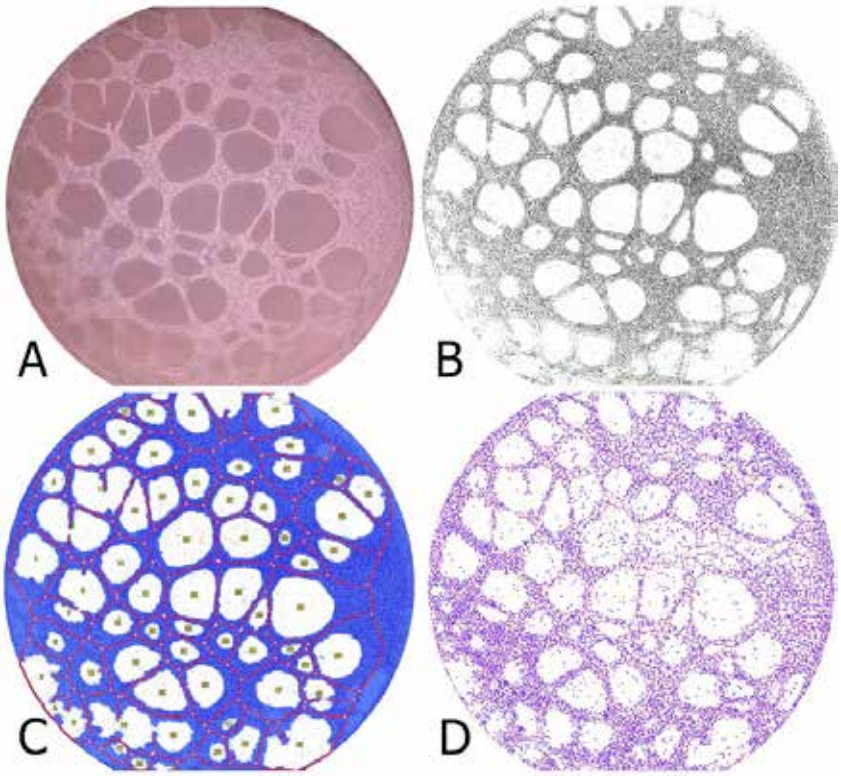

Figure 1: (A) The original phase-contrast image. (B) Image used for analysis. (C) Resulting image of Wimasis-WimTube. (D) Resulting image of Angiosys.

Figure 2

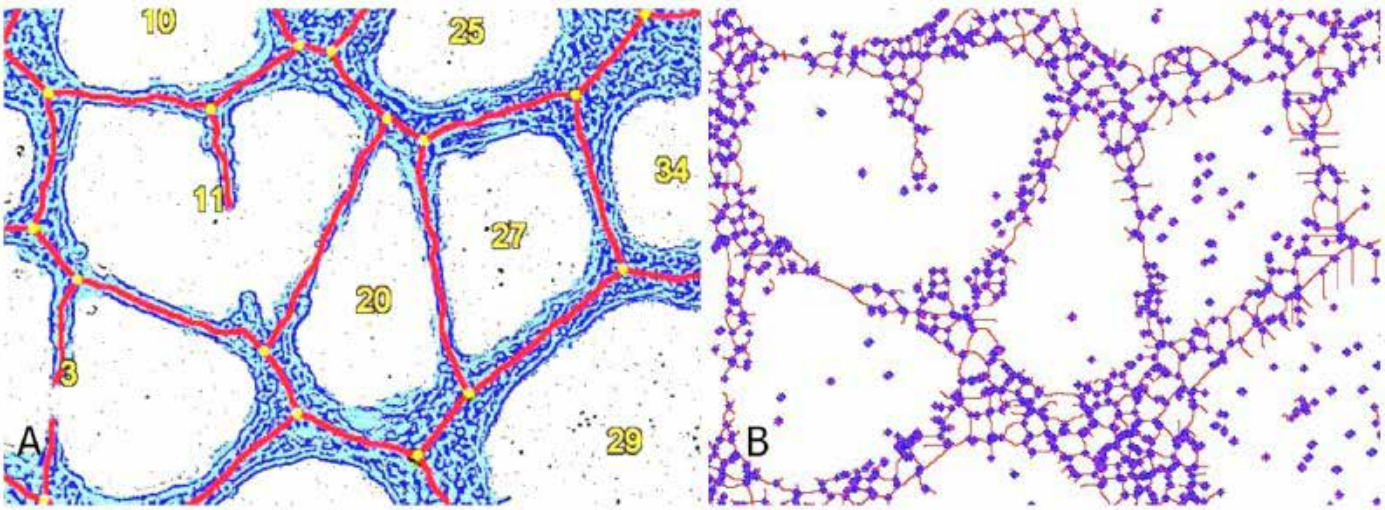

Figure 2: (A) Example of a resulting image of Wimasis-WimTube; tubes (red lines), branching points (yellow points) and loop's areas (regions with yellow numbers). (B) Example of a resulting image of Angiosys; vascular cells (blue dots), junctions of cells (red lines).

10.5505/2017ichc.PP-130 [Cancer biology]

The Apoptotic Effect of the Acetyl-11-keto-beta-boswellic acid (AKBA) to Anaplastic Thyroid Cancer

Ayşenur Kaya, Gülçin Gacar, Gökhan Duruksu, Zehra Seda Halbutoğulları, Gülay Erman, Yusufhan Yazır
Center for Stem Cell and Gene Therapies Research and Practice, Institute of Health Sciences, Department of Stem Cell, Kocaeli University, Izmit-Kocaeli, Turkey

Introduction & Objectives. Acetyl-11-keto-beta-boswellic acid (AKBA) is one of the derivatives of boswellic acid, which is known as an active component of Boswellia serrata gum resin. Due to its anti-carcinogenic effect, AKBA has caught the attention of a broad spectrum of researchers and clinicians. AKBA is known to regulate multiple cellular and molecular events associated with tumor development. On the other hand, thyroid cancer is the most common endocrine tumor. Among the various histopathological types of thyroid cancer, anaplastic one is the most aggressive type in this classification. In the present study, we aimed to investigate the in vitro effects of AKBA on the anaplastic thyroid cancer cell line, CAL62.
Materials & Methods. For this purpose, CAL62 were cultured in 6-well plates. Cells were maintained in Dulbecco's Modified Eagle Medium, supplemented with 10% fetal bovine serum, 2 mM glutamine, 100 U/l penicillin and 100 U/l streptomycin at 37°C in humid atmosphere, 5% CO2. After being attached to the surface, AKBA was added to the culture media to final concentration varying between 1.25-100 µM, and incubated for 3 days under normal culture conditions. The proliferation capacity and the viability of cells were measured by WST-1, and apoptosis was evaluated by AnnexinV-PI staining using flow cytometer, after 72 hrs of the supplementation of the culture with AKBA. The medium without AKBA was used as control in the assays. Each experiment was repeated three times.
Results. We found a decline in the cell proliferation at the concentration of 80µM AKBA compared to the control. The application of AKBA on the CAL62 cultures led to dose-dependent decrease in cell viability (AKBA at 60-100 µM). We obtained similar results in the ratio of the apoptotic cells (at <60 µM AKBA) according to the AnnexinV-PI staining compared to control.
Conclusions. In conclusion, we are in the belief that AKBA could provide a major direct support to stem cell therapy in the treatment of anaplastic thyroid cancer. The results also point out the possibility of AKBA-use being an alternative treatment option to many diseases.

Keywords: AKBA, Cancer Stem Cell, Boswellic Acid, Anaplastic Thyroid Cancer, Apoptotic Effect

10.5505/2017ichc.PP-131 [Cancer biology]

CD200-Induced treatment decreases Gr1+ cells in Spleen

Gamze Tanriover[1], Sayra Dilmac[1], Elnur Aliyev[1], Reginald M Gorczynski[2], Nuray Erin[3]

[1]Akdeniz University, School of Medicine, Department of Histology and Embriyology, Antalya, Turkey

[2]Toronto University, School of Medicine, Department of Immunology, Toronto, Canada

[3]Akdeniz University, School of Medicine, Department of Medical Pharmacology, Antalya, Turkey

Breast cancer is the most common cause of cancer-related deaths in women. CD200, a cell surface glycoprotein regulates inflammation, its effect on tumor progression and metastasis is defined as bidirectional. Carcinogenesis and metastasis may be induced by activation of the immune system. GR1 (Ly6G) is known as marker of myeloid-derived suppressor cells. High expression of GR1can be seen during tumor progression and its high expression in cell is associated with granulocyte phenotype. The aim of this study is to investigate the effects of CD200fc on Gr1+ cells.

4THM (4THM; 4T- Heart Metastatic cell line) cell line obtained from heart metastasis of 4T1 breast cancer cell line is used. These cells were orthotopically injected into the breast tissue of Balb/C female mice. After the tumor injection CD200-induced treatment and control groups divided into 14th day (midpoint) and then at the end of the 25th day (endpoint) time point. Mice were sacrificed at midpoint and endpoint time and primary tumor and spleen tissues were removed. CD200, CD200R1 and GR1 expressions were evaluated immunohistochemistry in primary tumor and spleen sections from paraffin blocks. Microscopic liver metastasis were also evaluated.

At the endpoint time, metastatic lesions were decreased in the CD200-induced treatment compared to 4THM group. CD200 and CD200R immunoreaction were increased endpoint time both primary tumors and spleens red pulp area. On the contrary, CD200 and CD200R1 reaction was poor in white pulp of the spleens in a treatment groups. The GR1 reaction was clearly seen in the red pulp of the spleen at the endpoint time in 4THM group. CD200fc treatment markedly decreased GR1 immunoreactivity.

Our results showed that CD200fc decreases Gr1+ cells which are likely to be myeloid-derived suppressor cells. Given the fact that Cd200fc is an anti-inflammatory molecule and CD200fc treatment markedly decreased liver metastasis, decreased Gr1+ cells may reflect decreased tumor-promoting inflammation. Further studies are required for possible therapeutic value of CD200 mimetics.

Keywords: 4THM, CD200-induced treatment, CD200, CD200R1, GR1

10.5505/2017ichc.PP-132 [Cancer biology]

E2F1 might be an effective role on cell fate in primary tumor by using mice breast cancer model

Sayra Dilmac[1], Mustafa Gokhan Ertosun[2], Nuray Erin[3], Osman Nidai Ozes[4], Gamze Tanriover[1]

[1]Akdeniz University, School of Medicine, Department of Histology and Embriyology

[2]Akdeniz University, School of Medicine, Department of Plastic and Reconstructive Surgery

[3]Akdeniz University, School of Medicine, Department of Medical Pharmacology, Antalya, Turkey

[4]Akdeniz University, School of Medicine, Department of Medical Biology and Genetics

Breast cancer is one of the causes of death in women due to the lack of effective treatment methods. The basic stage of tumor development is the uncontrolled division of tumor cells. Controlling of cell proliferation depends on the limited progression of the cell cycle. Many factors are involved in the cell cycle regulation. One of these factors, the E2F family which is the transcription factors, is the regulation of cell cycle and plays a role in apoptosis. Especially, E2F1 is considered to one of the proteins necessary for the entry into the S phase and the progression of the cell cycle. Phosphorylated Retinoblastoma protein break away E2F1 and E2F1 promotes the progression of the cell cycle by initiating the transcription of genes for DNA synthesis. E2F1 can also induce apoptosis via p53 activation and that regulates transcription of many pro-apoptotic genes, leading to apoptosis. Therefore in the present study we aimed to determine the role of E2F1 effects in cell proliferation in primary tumors which obtained from metastatic breast cancer cell lines.

4T1 (1x106 cells/mice) and 4TLM (1x106 cells/mice) metastatic breast cancer cell lines were orthotopically injected of 8-10 week old Balb/C female mice to form in vivo mice breast cancer model. 27 days after the injection, the mice were sacrificed and primary tumor tissues were removed and paraffin blocks were prepared. E2F1, Ki67, p53 and cleaved caspase-3 expressions were evaluated by immunohistochemistry in primary tumor sections.

E2F1 perinuclear staining was localized in the periphery of the tumor. Ki67 expression was also observed in the same area of the E2F1 perinuclear immunostainings. In addition, E2F1 was nuclear localized in the central part of the tumor which is a hypoxic area. It was remarkable that cytoplasmic p53 and cleaved caspase-3 immunoreaction were also localized in the central part of the tumor.

Our results suggested that nuclear localization of E2F1 might prefer to p53-mediated cell death. Also, perinuclear stainings of E2F1 showed that the cells might influence independently in their proliferative character. The results demonstrated that cellular localization of E2F1 might be an effective role on cell fate.

Keywords: E2F1, metastatic breast cancer, 4T1, 4TLM, immunohistochemistry, apoptosis

10.5505/2017ichc.PP-133 [Cancer biology]

The expression of galanin receptors (GALR1, GALR2 and GALR3) in colorectal cancer

Jacek Kiezun, Przemyslaw Kwiatkowski, Janusz Godlewski, Bartlomiej Krazinski, Anna Kowalczyk, Zbigniew Kmiec
Department of Human Histology and Embriology, Faculty of Medical Sciences, University of Warmia and Mazury in Olsztyn, Poland

INTRODUCTION: Galanin (GAL) is a neuropeptide expressed in central and peripheral nervous system, including enteric nervous system (ENS). Concentrations of GAL are increased in the blood of colorectal cancer (CRC) patients and are associated with cell proliferation and tumor growth. GAL acts by binding to specific receptors (GALR1, GALR2 and GALR3). The aim of this study was to evaluate the expression of GALRs in the sections of the colon wall containing ENS plexuses close to the tumor invasion and in CRC tumor.
MATERIALS-METHODS: Samples of CRC tumors and colon wall tissue close and distant from the neoplastic tissue were obtained from 18 CRC patients. Localization of GAL was evaluated using immunohistochemistry (IHC). Distribution of GALRs-immunoreactive (GALR1-Ir, GALR2-Ir and GALR3-Ir) was measured in myenteric plexuses of studied tissues and analyzed using Wilcoxon signed-rank test. Results were expressed as means of groups ± SEM ($p<0.05$).
RESULT: IHC revealed GALR1, GALR2 and GALR3 immunoreactivity within the cells of intestinal epithelium, intestinal stromal cells, cancer cells, myenteric plexuses and was predominantly identified in cell cytoplasm. Strong GALR1-Ir was found in CRC cells, intestinal epithelium and stromal cells distant from the tumor. In turn, GALR2-Ir was stronger in cancer cells and stromal cells than in epithelial cells. GALR3-Ir was weaker in stromal cells than in cancer and epithelium. Relative mean area of GALR1-Ir, GALR2-Ir and GALR3-Ir in intestinal wall close to the tumor was lower (0.79±0.05%, 0.21±0.04% and 0.51±0.06%, respectively), than that in distant section of colon wall (1.65±0.11%, 0.51±0.05% and 1.22±0.09%, respectively).
CONCLUSIONS: To the best of our knowledge, this study is the first to demonstrate GALRs immunoreactivity in epithelium and stromal cells of human colon and CRC tumor cells. In addition, lower relative mean area of GALRs-Ir in myenteric plexuses in the vicinity of CRC tumor than in the muscularis located distantly from the tumor may suggest the lower sensitivity of cancer cells to GAL. Different expression of particular GALRs in cancer cells may suggest that they play distinct roles in transduction of GAL signal in CRC tumor cells. However, the mechanisms of GAL action in CRC cancer need further studies.

Keywords: galanin, GALR1, GALR2, GALR3, colorectal cancer

10.5505/2017ichc.PP-134 [Cancer biology]

Effects of Abirateron Acetate and Docetaxel Therapy on Notch1, Jagged1 and Hes1 Expressions in Human Prostate Cancer Cell Lines

Hakan Soylu[1], Mustafa Kirca[2], Sema Avci[1], Leyla Kilinc[1], Ozlem Ozbey Unlu[1], Nuray Acar[1], Akin Yesilkaya[2], Ismail Ustunel[1]

[1]Department of Histology and Embriology, Faculty of Medicine, Akdeniz University, 07070 Antalya, TURKEY

[2]Department of Biochemistry, Faculty of Medicine, Akdeniz University, 07070 Antalya, TURKEY

Introduction & OBJECTIVES: In both Europe and the United States, prostate cancer remains the most commonly diagnosed non-cutaneous malignancy in men and the second most common cause of cancer death worldwide. Notch signaling pathway plays a crucial role in the development and homeostasis of tissues by regulating cell-fate decision, proliferation, differentiation, and apoptosis. So far, four Notch receptors (Notch 1–4) and five Notch ligands (Jagged 1–2; Delta 1, 3, 4) have been identified in mammals and the members of transcription factors (for example Hairy/Enhancer-of-Split family (HES) and Hairy/Enhancer-of-Split related with YRPW motif-like protein (HEY). Previous studies suggested that Notch1, Jagged-1 and Hes1 may play an important role in prostate cancer development, progression and metastasis. Abiraterone acetate is a cytochrome P450c17 (CYP17A1) inhibitor. Inhibition of CYP17A1 results in significant suppression of androgens. It is important for the treatment of men with castration-resistant prostate cancer (CRPC) progressing after docetaxel chemotherapy. Docetaxel has potent anti-tumor efficacy as a result of promoting microtubule assembly and microtubule bundling thereby impairing mitosis. The aim of this study was to investigate the effects of abiraterone acetate and docetaxel on NOTCH1, JAGGED1 and HES1 expressions in prostate cancer cell lines.
Materials & METHODS: Human PC cell lines, LNCaP (AR+) and PC3 (AR-) were purchased from American Type Culture Collection. LNCaP and PC3 cells were maintained in RPMI1640. Effective dose 50 of abiraterone acetat and docetaxel were determined by MTT assay in LNCaP and PC3. Cell lines were divided into 5 groups; control (only medium), DMSO control (<% 0,01), abiraterone acetate, docetaxel and abiraterone acetate+docetaxel. After these groups were incubated at 37 ºC for 72 h, the effects of abiraterone acetate and docetaxel on NOTCH1, JAGGED1 and HES1 expression were examined by immunoflourescence and western blot.
RESULTS: In PC3 and LNCaP cells, NOTCH1 and JAGGED1 expression were observed in all groups. In PC3, HES1 expression was the same among groups, but HES1 expression in abiraterone acetate, docetaxel and abiraterone acetate+docetaxel groups was increased compared to control in LNCaP.
CONCLUSIONS: Abirateone acetate- and docetaxel-induced HES1 expression may play a tumor suppressive role in AR+ LNCaP cells.

Keywords: Prostate cancer, Notch, Abiraterone acetate, Docetaxel

10.5505/2017ichc.PP-135 [Cancer biology]

The Investıgatıon of B-MYB and MALAT1 Gene Expressıons In Breast Cancer

Feridun Akkafa[1], Hasan Dağlı[2], Ebru Temiz[3], Kaifee Arman[3], Metin Kılınç[2]

[1]Department of Medical Biology, University of harran, Şanlıurfa, Turkey

[2]Department of Medical Biochemistry, University of kahramanmaraş sutcu Imam, Kahramanmaras, Turkey

[3]Department of Medical Biology, University of Gaziantep, Gaziantep, Turkey

Breast cancer is the most common cancer in women. It is prevalent among women both in developed and developing countries. One in ten of all new cancers diagnosed worldwide each year is a female breast cancer. It is also the principal cause of death from cancer among women globally. Drug resistance in the treatment of cancer still remains a major clinical concern. miRNAs play an important role in breast cancer. For this purpose, we wanted to find out the change in gen expression of B-MYB and MALAT1 after overexpressing three diffrent miRNAs targeting B-MYB and MALAT1. Breast cancer cell line (MCF-7) and epithelial breast cell line (hTERT-HME1 ATCC® CRL4010) were exposed to three different mimic miRNAs i.e. miR-503, miR-150 and miR-15a in cell culture medium. We used Real-Time PCR (qRT-PCR) to measure the expression level of B-MYB and MALAT1 in breast cancer cell line (MCF7) and epithelial breast cell line. The analysis was done using formala 2-ΔΔCt for fold change using t-test (Graph Pad Prism 5 Program). We found that there was significant increase in gene expression of MALAT1 and B-MYB in breast cancer cell line (MCF7) as compared to epithelial breast cell line (CRL4010) suggesting probable roles of these miRNAs in breast cancer by targeting B-MYB and MALAT1.

Keywords: MALAT1, B-MYB, MCF-7, Breast cancer

10.5505/2017ichc.PP-136 [Cancer biology]

Time Dependent Changes at the Mitochondria of Hepatocellular Carcinoma Cells During Hypothermia

Elif Buse Çalışkan[1], Hatice Isan[2], Aslı Camas[2], Ranan Gülhan Aktaş[2]

[1]Istanbul University, Cerrahpasa Faculty of Medicine, Istanbul, Turkey

[2]Maltepe University, School of Medicine, Cancer and Stem Cell Research Center, Istanbul, Turkey

INTRODUCTION: The effects of temperature changes on cancer cells reveals information about the development of cryopreservation methodologies and new chemotherapeutic agents.Effects of higher temperatures on cells are well defined.However, effects of hypothermia on cancer cells remain limited.Hypothermia affects the life span and proliferation rates; lowers metabolism rate; inhibits adhesion of cancer cells to endothelium.Mitochondria are one of the target organelles for chemotherapy since they are very important for apoptosis and cell division.It has been published that chemotherapeutic agents targeting mitochondria of cancer cells might not be toxic on normal cells.This study was designed to evaluate effects of mild hypothermia on mitochondria of HepG2 cells, a hepatocellular carcinoma cell line, at time dependent manner.
MATERIALS-METHODS: HepG2 cells were cultured in Dulbecco's modified Eagle's medium, supplemented with 1% fetal bovine serum. There were six experimental groups examined at 24th, 48th and 72nd hours in two incubators where temperature was set to 24°C or 37°C. MitoTracker has been used to investigate the behaviour of mitochondria *in vivo*.Cells were also labeled with antibodies specific for mitochondria.Sections were examined under light and confocal microscopes at 400X.Regions labeled with antimitochondrial antibody(AMA) were measured by ImageJ, Axiovision and Zen Image analysis systems.The results were compared statistically by using SPSS.
RESULTS: The mild loss of cytoplasmic and mitochondrial integrity at 24°C after 72 hours was apparent.Confocal microscopic examination revealed that there was no significant difference between morphology of mitochondria of cells in different groups.Live cell analysis exhibited a decrease in proliferation rate.There was striking difference at the mean intensity of the AMA-labeled cells between the groups cultured at 24 and 27°C.Statistical difference was also clear between the three groups at 24°C after 24th, 48th and 72nd hours.
CONCLUSIONS: The results support the hypothesis that the mitochondrial content of liver cancer cells significantly decrease under hypothermia.The results might explain why metabolism, oxygen consumption and proliferation rate decrease at cancer cells.The study also demonstrates the changes at those cells at room temperature.Further studies are underway to show physiological and biochemical changes. Hypothermia should be considered during therapy of liver cancer.
ACKNOWLEDGEMENTS:The study was supported by Turkish Liver Foundation(TKV) and TUBITAK.

Keywords: Liver cancer, Mitochondria, Hypothermia

10.5505/2017ichc.PP-137 [Cancer biology]

Three Dimensional Agarose Hydrogels as In Vitro Tumor Models for Cancer Drug Evaluation

Gokhan Duruksu, Yusufhan Yazır
Center for Stem Cell and Gene Therapies Research and Application, Kocaeli University, Kocaeli, Turkey

Introduction & Objectives.The traditional method for in vitro drug tests involves the use of two-dimensional cell culture settings, which raise many concerns in providing the biomimetic environment, in which the tumors reside. Unlike the monolayer culture, the cell culture in three-dimensional hydrogels might offer environmental conditions and oncogenic signals similar those in the tumor. The primary objective of this study was to determine the functionality of the agarose hydrogels, used as embedding matrix for the cancer cells, and to evaluate drug affectivity of this model.
Materials & Methods. To encapsulate and immobilize the cancer cells, agarose gel was used to create uniform disc-like structures. Molecular-grade agarose gel (0.8%) was mixed with prostate and breast cancer cell lines, DU145 and MCF7, and left to form a gel at room temperature. The hydrogels were incubated in RPMI1640 complete medium at 37°C. After morphological analysis, the viability of the cells in the hydrogels was evaluated by the Calcein A/Ethidium homodimer (EthD-1) staining; and the metabolically active cells by the WST-1 assay. The efficacy was assessed by addition of Paclitaxel in the medium containing the agarose hydrogels with cancer cell lines.
Results. In the agarose gel, the cells were distributed uniformly with the viability greater than 90%. The morphological analysis showed that the cell in agarose scaffold displayed a spherical form during the culture. After the incubation of both cell lines separately in the medium containing paclitaxel for 48 hrs, no significant difference in the lethality was observed compared to the monolayer cell cultures. The two and three-dimensional cultures didn't show a significant difference in the affectivity against the drug.
Conclusions. Although the diffusion was one of the serious problems usually encountered during the three-dimensional culture, the effect of the drug on the cells was quite similar. Beside the biocompatibility and the stability of the agarose, its tumor-similar stiffness indicates that this material might be a suitable matrix component in the in vitro tumor model. Although the heat-treatment remains to be the main disadvantage, this model could be successfully used as cell vehicle to engineering tumor.

Keywords: agarose, drug test, 3D culture, encapsulation, in vitro culture

Figure 1.

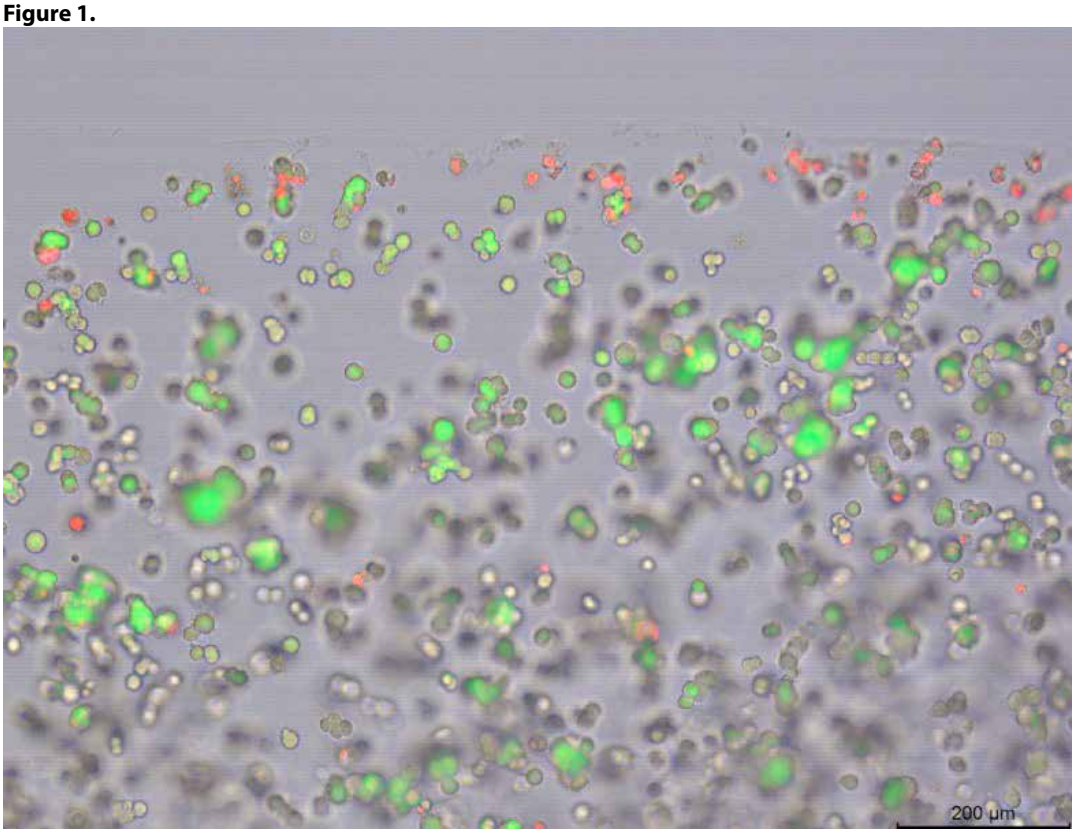

The encapsulated prostate cancer cells, DU145, in agarose hydrogel after staining with CalceinA/EthD-1. After 48 hrs of incubation in the medium with Paclitaxel, the viable cells were observed in green and death cells in red color.

10.5505/2017ichc.PP-139 [Cancer biology]

Anticancer effects of marine algae on breast and brain cancer

Oğuz Kurt[1], Feyzan Özdal Kurt[1], Mahmud Özkut[2], Ibrahim Tuğlu[2]

[1]Manisa Celal Bayar University, Faculty of Sciences & Letters, Department of Biology, Manisa, Turkey

[2]Manisa Celal Bayar University, School of Medicine, Department of Histology and Embryology, Manisa, Turkey

It has been known that marine algae has properties such as antiproliferative, apoptotic, cytotoxic, antitumoral and neurotoxic effects in vitro and in vivo conditions. Epidemiological studies reveal that high consumption of marine product related to algae caused low cancer incidence in some Asian countries. Therefore, marine algae were investigated for cancer chemopreventive agent. This study aimed to investigate the possibility of anticancer effects of extracts from algae samples in vitro in mouse neuroblastoma (NA2B) and breast cancer (MCF-7) cells and in vivo with clinical and histological methods.
The anticancer effects were studied of, Jania rubens (Linnaeus) J.V.Lamouroux and Codium fragile (Suringar) Hariot algae collected from the Aegean Sea coasts of Turkey. Cultured NA2B and MCF-7 cells were examined for antiproliferative effect by 3-[4,5-dimethylthiazol-2-yl]-2,5-diphenyltetrazolium bromide (MTT), antioxidant effect by endothelial nitric oxide synthase (eNOS) immunocytochemistry and antiapoptotic effect by Terminal deoxynucleotidyl transferase dUTP nick end labeling (TUNEL). The in vivo toxic effect study was done with Tarlov scoring. Jania rubens were found highly toxic to the NA2B and MCF-7 cells according to their IC50 values. H-score of e-NOS for oxidative stress and apoptotic index for cell death showed that Jania rubens more increased for these parameters compared to those of Codium fragile. Jania rubens extracts caused more clinical toxicity by Tarlov scoring whereas Codium fragile showed less toxicity. Histology of brain showed that there was similar morphology with more edama, bleeding and cell degeneration for Jania rubens.
Jania rubens showed clear anticancer effect in vitro for both brain and breast cancer cells with toxic effect of these cells in vivo. These toxic effects were found related to increase of oxidative stress and apoptosis. Anticancer effects of Jania rubens with these mechanisms are meaningful for cancer treatment and drug development.

Keywords: Marine algae, anticancer, NA2B, MCF-7, oxidative stress, apoptosis.

10.5505/2017ichc.PP-140 [Cancer biology]

The response of H-ras transformed tumour cell line to different acrylamide concentrations: A colorimetric assay

Sedat Kacar[1], Hatice Mehtap Kutlu[2], Varol Sahinturk[1]

[1]Department of Histology and Embryology, Faculty of Medicine, Eskisehir Osmangazi University, Eskisehir, Turkey

[2]Department of Biology, Faculty of Science, Anadolu University, Eskisehir, Turkey

Introduction & OBJECTIVES: Acrylamide is a chemical compound with the IUPAC name of prop-2-enamide and has been used in various industrial sectors since 1950s. After its discovery in 2002 that it forms in certain foods, it became one of the hot topics. Acrylamide was shown to cause toxic effects on many tissues and organs as well as on several cell lines in vivo/vitro studies. However, to our best knowledge, there are not any studies about the effect of acrylamide on the H-ras transformed tumour cell line (5RP7). Therefore, in this study our goal was to investigate how different concentrations of acrylamide affect 5RP7 cells.
Materials & METHODS: To attain our goal, we performed a MTT colorimetric assay. Filtered 100 mM stock solution of acrylamide was used. 5RP7 cells at a density of 3 × 103 cells per well were seeded in a 96-well microtiter plate and treated with different acrylamide concentrations ranging from 0.5 to 20 mM for 24 h at 37 °C. After the incubation period, 20 µL of MTT solution was added and, followed by 200 µL of DMSO after 4 h and then plates were read on an ELISA reader at 540 nm.
RESULTS: Between acrylamide concentrations of 0-1 mM, there was a cell proliferation; however, at the doses of higher than 1.5 mM, 5RP7 cell viability decreased in a dose-dependent manner. IC50 concentration of acrylamide against 5RP7 cells for 24 h was found to be 3.45±0.10.
CONCLUSIONS: To our best knowledge, we showed for the first time that acrylamide may exert a proliferative effect on 5RP7 cells at lower concentrations (<1.5 mM) and it exerts an obvious anti-proliferative and cytotoxic effect on 5RP7 cells dose-dependently at higher concentrations (>1.5mM).

Keywords: Acrylamide, MTT assay, 5RP7 cell line.

10.5505/2017ichc.PP-141 [Cancer biology]

A computational Analysis: Structural and Functional Concomitance of MicroRNAs involved in Colorectal Cancers

Rozhgar A. Khailany[1], Naser Gilani[1], Belan O. Kanabe[2], Khandakar A. S. M. Saadat[1], Muhamad Safdar[1], Ahmet Arslan[3], Yasmen Junejo[4]

[1]Department of Medical Biology, Faculty of Medicine, Gaziantep University, Gaziantep, Turkey

[2]Department of Biology, Gaziantep University, Gaziantep, Turkey

[3]Department of Medical Biology, Faculty of Medicine, Namık Kemal University, Tekirdag, Turkey

[4]National Center of Excellence in Analytical Chemistry, University of Sindh, Jamshoro, Pakistan

MicroRNAs (miRNAs) are small non-coding RNAs that function as guide molecules in mRNA silencing. They have a crucial role in post-transcriptional regulation of gene expression via mRNA degradation or translational repression. Currently, miRNAs are considered as indispensable players in several physiological and pathological conditions, particularly in various cancers due to their dysregulation. With the quick expanding number of biomolecule structures, a real challenge to molecular biologists will be with construing those capacity in view of their structural similarity. Instead of sequence, the structure of molecules could provide more conspicuous confirmation of functional part in biology. This study`s goal is to investigate whether the primary sequence similarity is expressed in structure similarity in phylogenetic contexts of miRNAs, which are responsible for colorectal cancers. In order to better understanding we compare the obtained trees using miRNA primary sequences and its secondary structures. The miRNA sequence sources is the miRBase 14.0, they were browsed and downloaded as a FASTA format. Sequence based analysis was performed using MUSCLE multiple alignment and MEGA 6.0 programs. Secondary structures were analyzed by Vienna RNA package. In the phylogenetic tree based on structural data it was clarified that has-mir-101-1 and has-mir-222 genes are closely related. However, in phylogenetic tree obtained from sequence data these miRNAs are noticeably distant from each other and closer to other miRNAs. Consequently, this approach could be very informative in predicting the concomitant function of new microRNAs whose function is yet to be known.

Keywords: MicroRNA, Phylogeny, Colorectal Cancer, Computing

10.5505/2017ichc.PP-143 [Cancer biology]

Expression pattern of miR-23b-3p and its target SETD2 in Renal Cell Carcinoma

Rozhgar A. Khailany[1], Naser Gilani[1], Belan O. Kanabe[2], Khandakar A. S. M. Saadat[1], Ahmet Arslan[3]

[1]Department of Medical Biology, Faculty of Medicine, Gaziantep University, Gaziantep, Turkey

[2]Department of Biology, Gaziantep University, Gaziantep, Turkey

[3]Department of Medical Biology, Faculty of Medicine, Namık Kemal University, Tekirdag, Turkey

Renal cell carcinoma (RCC) is the most common type of kidney cancer in adults. It composes around 3% of adult malignancies and 90-95% neoplasms of kidney. MicroRNA-23b-3p, a small non-coding RNA, is up-regulated in different cancers. Also it is predicted that tumor suppressor gene SET domain-containing protein 2 (SETD2) is a direct target of this miRNA. SETD2 encodes a histone methyltransferase, which is responsible for trimethylation of the lysine residue at position 36 of histone H3 and may play a role in suppressing tumor development. The aim of this work was to measure the expression level of miR-23b-3p and its target SETD2 in patients with renal cell carcinoma and normal control sample. Twenty one paired tumor and normal tissue samples that were grouped according to the sub-types of renal carcinoma and clinical characteristics of patients, including gender and average age were observed with gene expression analysis using quantitative real time polymerase chain reaction (qRT-PCR). The expression of SETD2 is quite lower as compared to miR-23b-3p expression in RCC. As a result, we conclude that miR-23b-3p may have an important role in suppressing the expression of SETD2. The aberrant expression in miR-23b-3p and its target SETD2 might be a risk factor for RCC. To our knowledge, it is the only study in which the expression levels of SETD2 and miR-23b-3p in RCC at the same time have been evaluated. Further analysis is required to determine the responsible miRNAs and their targets rather than miR-23b-3p and SETD2 in RCC.

Keywords: Renal Cell Carcinoma, miR-23b-3p, SETD2, qRT-PCR

10.5505/2017ichc.PP-144 [Correlating light and electronmicroscopy]

The protective effect of resveratrol in di(n-butyl) phthalate (DBP) induced nephrotoxicity. An immunohistochemical and ultrastructural studies

Cigdem Elmas[1], Cemile Merve Seymen[1], Dila Sener[2], Güleser Göktas[3], Tayfun Göktas[4], Ayten Türkkanı[5]

[1]Gazi University Faculty Of Medicine, Department of Histology and Embryology, Ankara, Turkey

[2]Okan University Faculty Of Medicine, Department of Histology and Embryology, İstanbul, Turkey

[3]Baskent University Faculty Of Medicine, Department of Histology and Embryology, Ankara, Turkey

[4]Gazi University Faculty Of Medicine, Department of Physiology, Ankara, Turkey

[5]TOBB University Faculty Of Medicine, Department of Histology and Embryology, Ankara, Turkey

Introduction and AIM: The purpose of present study to explore the renoprotective nature of resveratrol by assessing markers antioxidant competence in di(n-butyl) phthalate (DBP) injured rats kidneys with immunohistochemistry and electron microscopic techniques. In addition we examined the lipid peroxidation (measured as malondialdehyde, MDA) and total sulphydryl groups (RSH) levels.
METHODS: To generate an experimental condition reflecting possible renal damage caused from DBP, adult female 20-day-old Wistar albino rats were given a diet containing 500 mg/kg/day DBP (low dose group), 1000 mg/kg/day DBP (high dose group); dissolved in corn oil for 4 weeks. To see the possible protective effects of resveratrol and effects of solvent for resveratrol other groups were used as control and given solvent [Carboxymethyl cellulose (CMC), 10 ml/kg], 500 mg/kg/day DBP+20 mg/kg/day resveratrol, 1000 mg/kg/day DBP+20 mg/kg/day resveratrol. Total number of animals were 36 and each group had 6 rats (n=6).
RESULTS: The results showed that DBP and CMC treatment increased renal lipid peroxidation significantly and decreased the RSH level. In addition, TEM and SEM results showed degenerative changes such as deletion, folding and thickening of basement membrane, appearance of an electron dense intramembranous and mesangial deposits, deletion of foot processes in high dose DBP treated group. High dose DBP group was followed by solvent (CMC) and low dose DBP groups, respectively. Resveratrol treatment with low dose DBP significantly recovered degenerative changes however, compared to low dose group, resveratrol was found to have less protective effect while treated with high dose DBP. Treatment with resveratrol led to an improvement in both biochemical and histological alterations induced by DBP or CMC. Immunohistochemical results also supported our electron microscopic findings. Distal tubule and glomerular structures were considered as the most affected parts in kidney by DBP and CMC treatment.
CONCLUSION: These results indicated that DBP caused renal toxicity by inducing lipid peroxidation and morphological alterations. In conclusion, these results suggest that resveratrol protects against DBP-induced nephrotoxicity. This study could be important for further understanding of DBP toxicity in renal tissues and advancement of better treatments for people and/or animals exposed to DBP.

Keywords: DBP, Kidney, Caspase3, ET1, Resveratrol, TEM-SEM

Figure 1

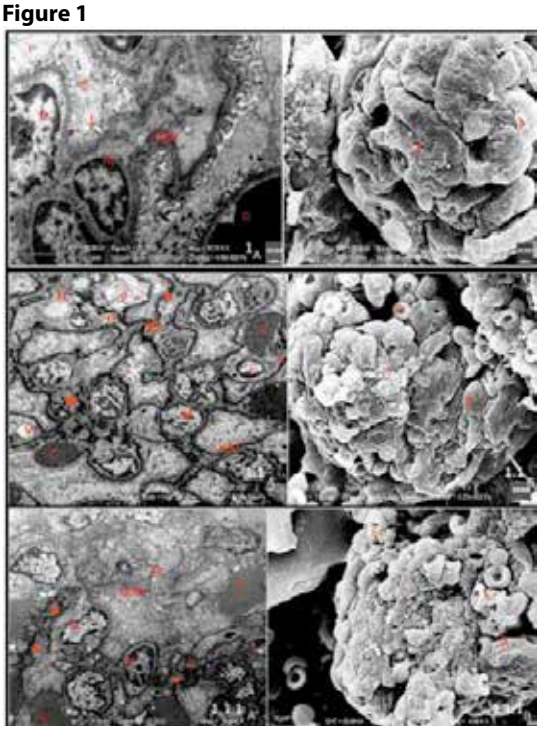

TEM analyses of control group (1A), low dose DBP group (1.1A), high dose DBP group (1.1.1A) and SEM analyses of control group (1B), low dose DBP group (1.1B), high dose DBP group (1.1.1B)

Figure 2

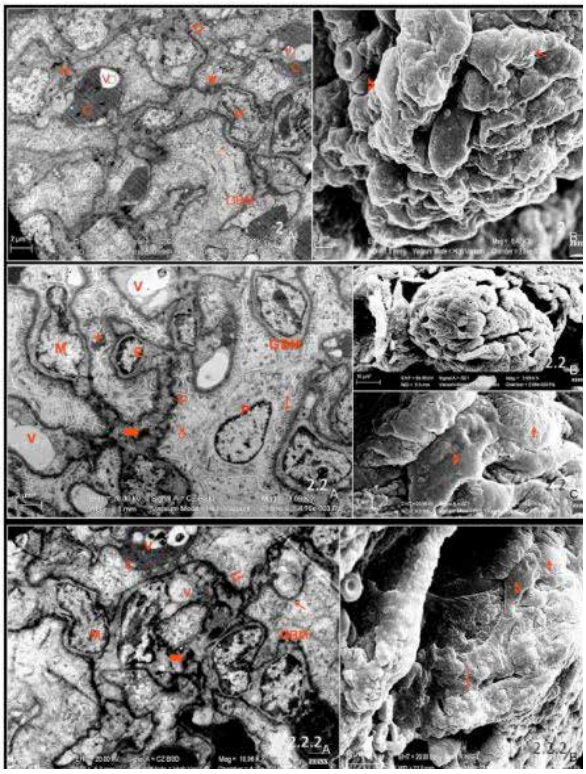

TEM analyses of carboxymethyl cellulose group (2A), low dose DBP+Resveratrol group (2.2A), high dose DBP+Resveratrol group (2.2.2A) and SEM analyses of carboxymethyl cellulose group (2B), low dose DBP+Resveratrol group (2.2B), high dose DBP+Resveratrol group (2.2.2B)

Figure 3

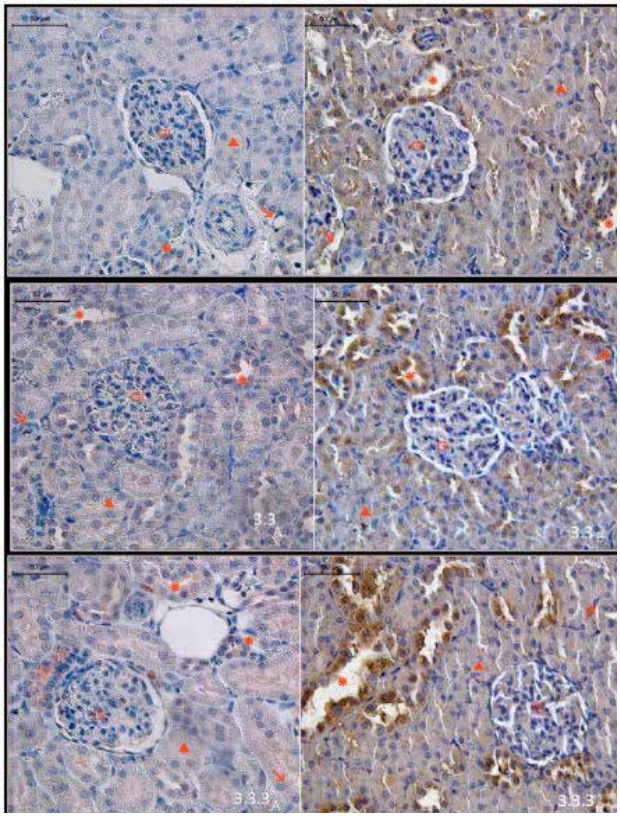

Caspase-3 immun stainings of control group (3A), low dose DBP group (3.3A), high dose DBP group (3.3.3A) and ET-1 immun stainings of control group (3B), low dose DBP group (3.3B), high dose DBP group (3.3.3B)

Figure 4

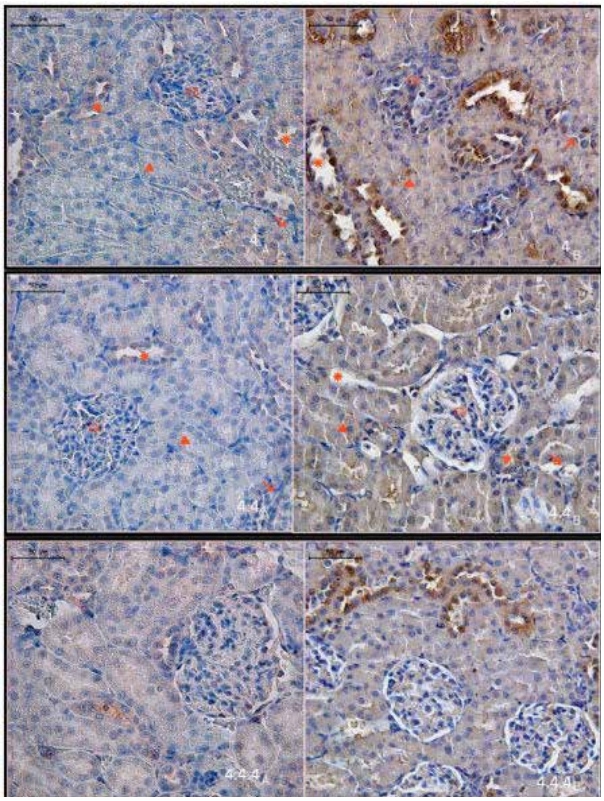

Caspase-3 immun stainings of carboxymethyl cellulose group (4A), low dose DBP+Resveratrol group (4.4A), high dose DBP+Resveratrol group (4.4.4A) and ET-1 immun stainings of carboxymethyl cellulose group (4B), low dose DBP+Resveratrol group (4.4B), high dose DBP+Resveratrol group (4.4.4B)

Graphic 1

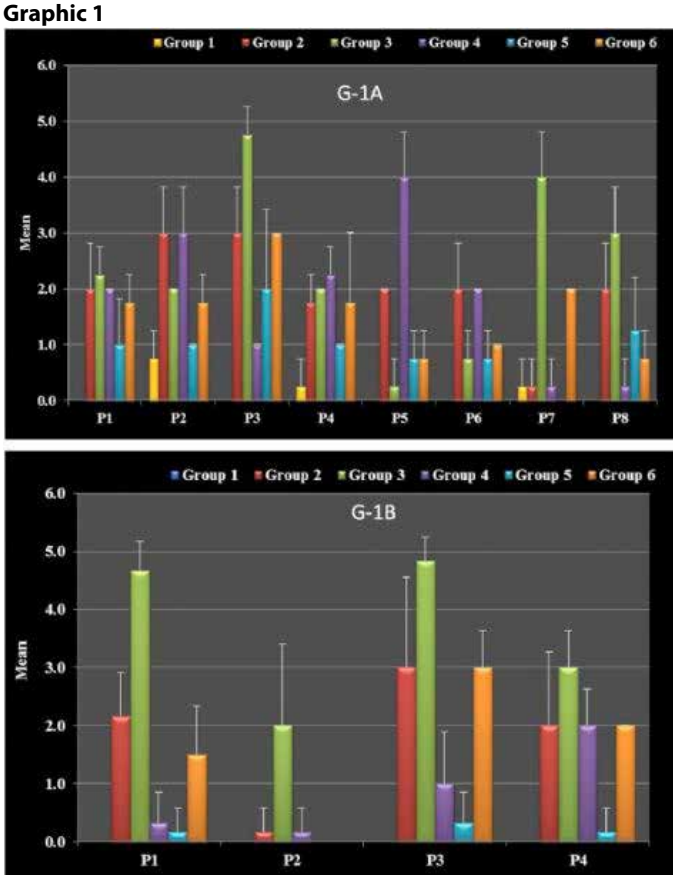

Mean of degeneration criteria in TEM (G-1A) and Degeneration criteria in SEM (G-1B).

Graphic 2

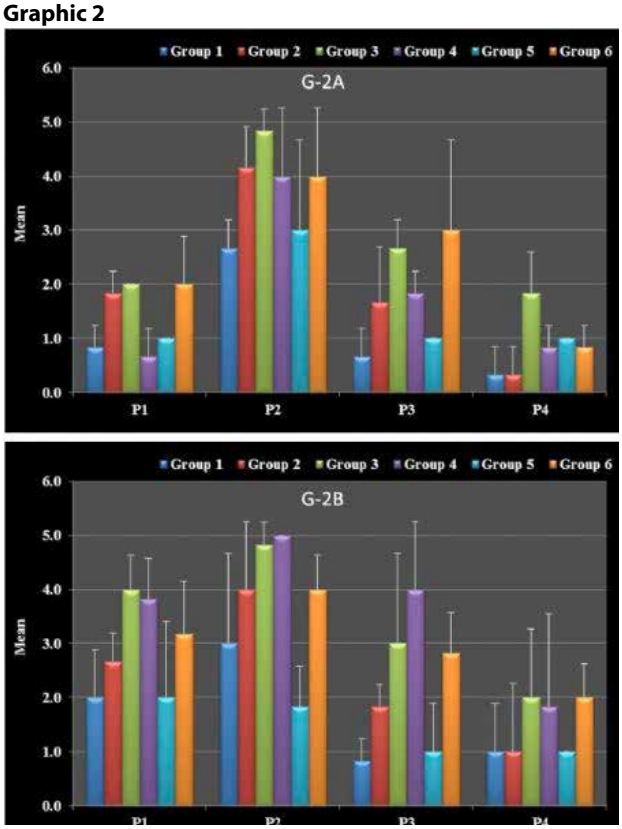

Evaluation of Caspase-3 primary antibody intensity between groups (G-2A) and Evaluation of ET-1 primary antibody intensity between groups (G-2B).

Graphic 3

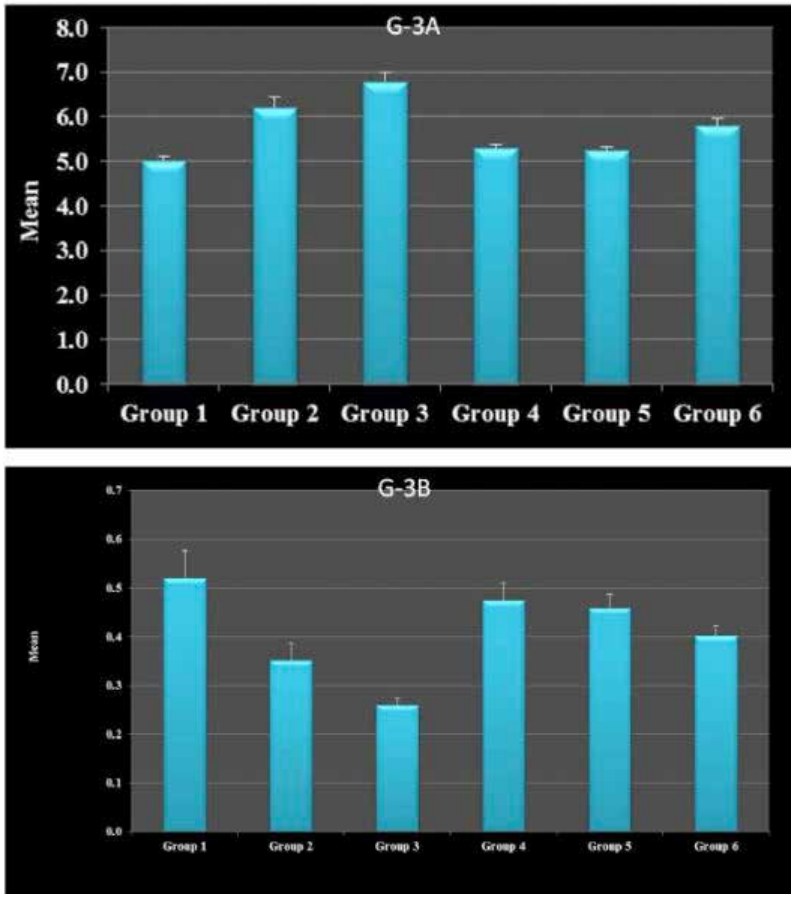

Mean of MDA levels (G-3A) and Mean of total sulphydryl groups (RSH) levels (G-3B).

10.5505/2017ichc.PP-145 [Correlating light and electronmicroscopy]

The Effect of Different Doses of Gallic Acid to Fatty Liver Disease in Rats

Tuğba Celik Samancı[1], Alpaslan Gökcimen[1], Tuncay Kuloglu[3], Murat Boyacıoglu[4], Yurdun Kuyucu[2], Sait Polat[2]

[1]Department of Histology and Embryology, Adnan Menderes University, Aydın, Turkey

[2]Department of Histology and Embryology, Cukurova University, Adana, Turkey

[3]Department of Histology and Embryology, Firat University, Elazıg, Turkey

[4]Department of Pharmacology and Toxicology, Adnan Menderes University, Aydın, Turkey

Back ground and Aıms: Fatty liver is increasingly widely. In our study, rats were lubricated with high fat diet which is assumed as lubricated agent in humans. Then the effects of different doses of gallic acid on fatty liver was investigated.
METHODS: 40 male Wistar albino rats (160+/-30 g) were used. Control group was fed with standart diet while steatosis group was fed with a high fat diet(HFD) for sixteen weeks. Other groups were fed with the HFD diet for ten weeks. At the end of ten weeks, gallic acid in the doses of 10,50 and 100 mg/kg/day were given by gavage for 6 weeks period. The effects of different doses of gallic acid on fatty liver were investigated with lightmicroscope, electron microscopy, determination of iNOS enzyme actvity, ALT, AST, SOD, CAT, GSH activities and MDA levels.
RESULTS: In the steatosis gruop iNOS enzyme activity, triglyceride content(TG), ALT, AST and MDA levels were found to increase while SOD activity was decreased. No differences was found between the groups for CAT and GSH activity. iNOS enzyme activity and TG content were decreased in the groups which were treated with 50 and 100 gallic acid. AST levels of the group which was treated with 50 gallic acid, and MDA levels of the group treated with 100 gallic acid were decreased. Histologically, 3 degree of steatosis was observed. in addition to balloning, granular and vacuolar degeneration,sinusoidal dilation, mononuclear cell infiltration in steatosis group. Gallic acid 100 is closest structurally normal group.
CONCLUSION: Third degree of fatty liver was observed in steatosis group. The group which was treated with 100 gallic acid was found to be closestto normal structure. Thr group of 50 gallic acid was found to be regulator of AST enzyme activity. And 100 gallic acid were found to decreased lipid peroxidation. It is possible to say that; structral and biochemical damage were decreased in the group of 100 gallic acid.

Keywords: fatty liver, gallic acid, antioxidant

10.5505/2017ichc.PP-146 [Correlating light and electronmicroscopy]

Protective Effects of Quercetin and Resveratrol Against Gentamicin-Induced Nephrotoxicity in Rats: Role of Nuclear Factor-Kappa B Pathway

Yesim Hulya Uz[1], Melike Sapmaz-Metin[2], Yeter Topcu-Tarladacalisir[1], Gulnur Kizilay[1], Turan Karaca[1], Enis Ulucam[3]

[1]Department of Histology and Embryology, Trakya University School of Medicine, Edirne, Turkey

[2]Vocational School of Health Services, Trakya University, Edirne, Turkey

[3]Department of Anatomy, Trakya University School of Medicine, Edirne, Turkey

BACKGROUND: Gentamicin (GM) is an aminoglycoside antibiotic widely used to treat gram-negative infections due to its efficacy and reasonable cost. However, its clinical use is limited by its nephrotoxicity. Studies have shown that nuclear factor-kappa B (NF-kB), are involved in nephrotoxicity induced by GM. The natural products, quercetin (QRC) and resveratrol (RSV), are established anti-inflammatory compounds that mediate their effects by inhibiting activation of NF-kB signaling.
OBJECTIVE: The aim of the present study was to investigate the protective effects of QRC and RSV against gentamicin-induced nephrotoxicity.
MATERIALS-METHODS: Twenty-four adult Wistar albino male rats were randomly divided into four groups, each consisting of six rats. The first group served as a control (C) and was gavaged with 60% dimethyl sulfoxide (DMSO, vehicle for QRC and RSV) for 12 days. The second (GM) group was injected with GM alone (100 mg/kg/day) intraperitoneally for the last 8 days. The third (GM+QRC) and fourth (GM+RSV) groups were gavaged with QRC (50 mg/kg/day) and RSV (10 mg/kg/day) for 12 days, respectively. They also were injected with GM (100 mg/kg/day) intraperitoneally for the last 8 days. All rats were sacrificed 24 hours after the last dose of drug application, and their kidneys were removed and fixed in 10% formalin solution. After routine tissue processing, sections were stained with hematoxylin-eosin (H&E) and periodic acid–Schiff (PAS) for histological examination, or with anti-NF-kB antibody for immunohistochemical assay. The data were analyzed statistically.
RESULTS: Kidneys of control group animals showed normal histological structure of the glomeruli and renal tubules. However, the kidneys of animals injected with GM revealed tubular dilatation, hyaline cast, tubular cell vacuolization, tubular cell flattening, debris material in tubular lumen, loss of brush border in proximal tubules, inflammatory cell infiltration, and tubular and glomerular degeneration. In addition, immunoreactivity of NF-kB was significantly increased in the GM group compared with the control group. Treatment with QRC and RSV exhibited significant protection against nephrotoxicity and markedly reduced immunoreactivity of GM-induced NF-kB.
CONCLUSION: Treatment with QRC and RSV may have protective effects against GM-induced nephrotoxicity through inhibition of the NF-kB signaling pathway.

Keywords: gentamicin, nephrotoxicity, nuclear factor-kappa B, quercetin, resveratrol

10.5505/2017ichc.PP-147 [Correlating light and electronmicroscopy]

Histology and Histochemistry of the Gastric Caecum in *Enoplops disciger* (Kolenati, 1845) (Heteroptera: Coreidae)

Selami Candan, Damla Amutkan, Nurcan Özyurt Koçakoğlu, Demet Çetin, Irmak Polat, Zekiye Suludere
Department of Biology, Faculty of Science, Gazi University, Ankara, Turkey

Stinkbugs (Hemiptera: Pentatomidae) are widely distributed around the globe and many species are considered as agricultural pests. A particular region of their hindgut, the gastric caecum in insects belonging to suborder Heteroptera, has been scrutinized due to its association with a community of bacteria. The structure of gastric caecum shows histological variation in different families of suborder Heteroptera. Therefore, in this study we histologically and histochemically were described the gastric caecum of *Enoplops disciger* (Kolenati, 1845) (Heteroptera: Coreidae). Adult females and males of *E. disciger* were collected from cultivated areas from Kazan, Ankara, Turkey in June-July 2016. For light microscopic examinations, the gastric caecum of adult males and females were dissected out and fixed in formaldehyde. After washing and the dehydration processes, samples were embedded in paraffin. Histological sections of 6 µm were cut and stained with Mallory's Trichrome stain. Sections were examined by Olympus BX51 microscope and photographed. As a result of our investigations, we observed that gastric caeca composed of four rows of plate like structures surrounding a tube in the digestive tract in *E. disciger*. They are connected to the hindgut and contain spesific bacteria that aid digestion in the lumen. Each caecum is surrounded monolayer epithelial cells.

Keywords: Insect, hindgut, microscopy

10.5505/2017ichc.PP-148 [Correlating light and electronmicroscopy]

Structure and Histochemistry of the Principal Salivary Glands in *Carpocoris purpureipennis* (De Geer, 1773) (Heteroptera: Pentatomidae)

Damla Amutkan, Nurcan Özyurt Koçakoğlu, Irmak Polat, Zekiye Suludere, Selami Candan
Department of Biology, Faculty of Science, Gazi University, Ankara, Turkey

Carpocoris purpureipennis (De Geer, 1773) is a species belonging to the family Pentatomidae (Heteroptera). This species lives in meadows, roadsides and gardens. Adults are found on plants of the Umbelliferae family and the weeds. They can form large groups sucking plant juice and damage to the crops. Therefore, this species has an economical importance. Consequently, determination of the morphological and the structural features of the principal salivary glands in this species has great importance. Accordingly, we aimed to identify the structure of the principal salivary glands which is the part of the digestive canal in *C. purpureipennis*.

Adult male and female specimens of *C. purpureipennis* were collected from different cultivated areas in Kazan, Kızılcahamam, Ankara in June and July 2016. Extracted salivary glands from collected adult males and females were fixed in Formaldehyde. After the washing and the dehydration process, the samples were embedded in paraffin. After that, the sections stained with Mallory›s trichrome stain. Sections which belong to the salivary glands were examined under an Olympus BX51 light microscope and were photographed with an Olympus E330 digital camera.

A pair of principal salivary glands, which lie dorso-laterally and close to the end of the proventriculus, occur on both sides of the foregut of *C. purpureipennis*. The salivary gland is formed of a single-layer of epithelium. There are microvilli on the apical region of cells. The lumen is filled with secretory vesicles. No differences found in the structure of the principal salivary glands between males and females.

Keywords: Histology, microscope, principal salivary glands

10.5505/2017ichc.PP-149 [Correlating light and electronmicroscopy]

Evaluation of Acute Toxicity of Marble Dust In Daphnia Magna

Yasin Ilgaz[1], Sedat Develi[2], Havva Ilgaz[3]

[1]Department of Medical Histology and Embryology, University of Health Sciences, Gulhane Faculty of Medicine, Ankara, Turkey

[2]Department of Anatomy, University of Health Sciences, Gulhane Faculty of Medicine, Ankara, Turkey

[3]Department of Undersea and Hyperbaric Medicine University of Health Sciences, Gulhane Faculty of Medicine, Ankara, Turkey

Introduction & OBJECTIVES: A nanoparticle is a microscopic small part of a matter which its size is less than 100 nm and widely used in many fields such as painting, cosmetics or medicine. But in time impacts of the nanoparticles on the ecosystem have become controversial. In this study, we aimed to evaluate the toxic effects of marble dust in Daphnia Magna. Because marble dust as a waste material of Marble industry has a possibility of reuse in the construction industry as well as food industry. It is widely used in animal feeds for acid neutralization or as a calcium supply in sucrose production. Due to its food chain relations, reproduction capabilities and adaption to environmental stress, Daphnia Magna is commonly used for ecotoxicity studies.
Materials & METHODS: Study was conducted with 4 groups which 5 adult animals were included in each group. Groups were divided by exposure time (12h, 24h, 48h and control) and incubated at 20°C. 2 gr/100 ml suspension of marble dust (Sivrihisar-Turkey) was used and it was filtered through a 0.1 µm disposable syringe filter. For cross-section TEM analyze animals fixed with glutaraldehyde and washed with PBS solution. After dehydration and embedding, sectioning of samples was done with an ultramicrotome.
RESULTS: All animals were survived except 2 of 48h group. In all samples, nanoparticles were observed within the digestive tract and uptake of particles into the gut cells near the lumen was shown, unlike the control group. Interestingly, in 24h and 48h groups, some nanoparticles were accumulated in nuclear part of the gut cells. Moreover, in 48h group, nanoparticles were also shown within the deeper tissues of the digestive system (Figure 1).
CONCLUSIONS: The effects of the marble dust to the ecosystem is not exactly known. It seems to be an important issue in terms of public health especially in countries such as Turkey which marble industry has been developed. We think that marble dust can affect human health directly by food intake due to animal feeds or sucrose, and indirectly toxic effects on watersheds.

Keywords: Daphnia magna, Transmission electron microscopy, Marble Dust, Nanoparticle Toxicity,

Figure 1

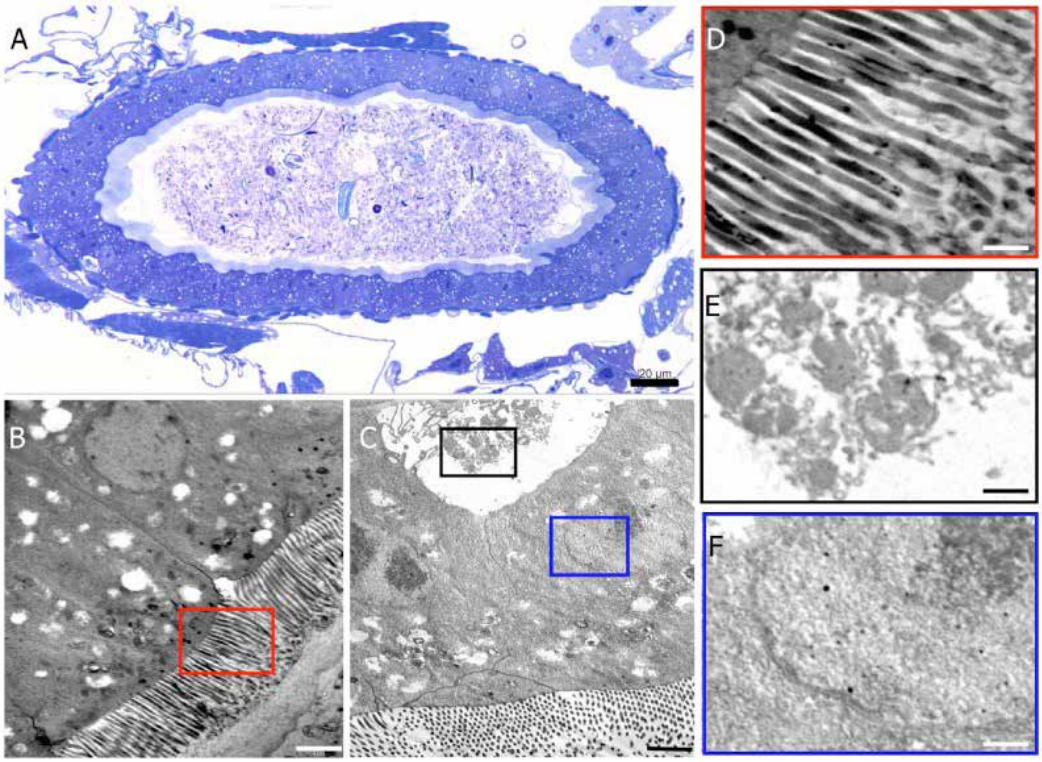

Representive histological images of Daphnia Magna. (A) Semi-thin section of alimentary canal, stained with toluidin blue (B) Nanoparticles in the lumen (C) Nanoparticles within the gut cell (D) Absorbtion of marble dust particles via microvilli of gut cell (E) Penetrated particles in capillary lumen (F) Particles in gut cell nucleus. Scale bars 20 µm (A), 2 µm (B,C), 500 nm (D,E,F).

10.5505/2017ichc.PP-150 [Correlating light and electronmicroscopy]

Protective role of curcumin in benzo(a)pyrene induced nephrotoxicity

Dila Şener[1], Çiğdem Elmas[2], Deniz Erdoğan[2], Gülnur Take Kaplanoğlu[2], Güleser Göktaş[2]

[1]Department of Histology and Embryology, Okan University, Istanbul, Turkey

[2]Department of Histology and Embryology, Gazi University, Ankara, Turkey

AIM: Polycyclic aromatic hydrocarbons are compounds classified as toxic environmental pollutants that occur during the industrial process and combustion period of organic materials. Benzo(a)pyrene (BAP) is a polycyclic hydrocarbon that exhibit DNA damaging and carcinogenic properties. Curcumin is derived from the root of Curcuma longa plant and major yellow pigment in turmeric which broadly includes biological and pharmacological activities in conjunction with its strong antioxidant competence. Our aim is to investigate the possible protective effects of curcumin against the benzo(a)pyrene damage in rat kidney tissue by using electron microscopic methods.
MATERIAL-METHODS: 36 male Wistar albino rats are divided into 6 groups (n=6) as follows control, corn oil, DMSO(curcumin solvent), BAP(10 mg/kg/day), curcumin(100 mg/kg/day), curcumin+BAP. Agents were daily and orally administered for six weeks. Kidney tissues were removed at the end of experimental period for both transmission and scanning electron microscopy sample preparation processes. Tissues were viewed with Carl Zeiss EVO LS 10 TEM-SEM microscope.
RESULTS: According to the results of control, corn oil and DMSO groups, the glomerular and tubular structures were exhibited normal ultrastructural features. Glomerular capillary dilation, thickening and folding of basement membrane and disruption of organelle contents were distinguished in the benzo(a)pyrene treated group. Deletion of the podocyte cell and pedicels also the sponge like appearance of glomerular surface were remarkable as degenerative findings in this group. The overall tissue components and the ultrastructural features were detected to protect in curcumin treated group. Podocyte cell process and the capillary interaction was similar to that of control, corn oil and DMSO groups. Heterochromatic appearance of the nucleus was still continuous in curcumin+BAP treated group however, glomerular basement membrane and proximal tubular structures were detected to have normal features similar with control.
CONCLUSION: In conclusion, administration of DMSO as a curcumin solvent resulted in no significant changes suggesting that the harmless content of these agent. The abnormalities that occur after benzo(a)pyrene administration strongly revealed the nephrotoxicity of this agent. Hence, there is a strong evidence that curcumin is an effective protective agent against benzo(a)pyrene nephrotoxicity.

Keywords: Benzo(a)pyrene, curcumin, kidney, ultrastructure

10.5505/2017ichc.PP-151 [Correlating light and electronmicroscopy]

Does the cigarette smoke exposure lead to histopathological alterations in olfactory epithelium? An electron microscopic study on a rat model

Elvan Şahin Özbek[1], Gürsel Ortuğ[2], Alpen Ortuğ[3]

[1]Department of Histology and Embryology, Medical School, Sakarya University, Korucuk, Sakarya, Turkey

[2]Department of Anatomy, Medical School, Bahçeşehir University, Istanbul, Turkey

[3]Department of Anatomy, Medical School, Medipol University, Istanbul, Turkey

INTRODUCTION & OBJECTIVES: It is known that certain inhalants, particularly cigarette smoke, may lead to irritation and consequent toxic and neoplastic changes in the respiratory system. As the exposure time increases, the tissue damage becomes more severe. In this study, the aim was to investigate the ultrastructure of olfactory epithelia in rats exposed to cigarette smoke for varying lengths of time.
MATERIALS & METHODS: 24 adult Wistar albino rats were randomly divided into four equal groups, and maintened under the standardized laboratory conditions, and fed with commercial rat diet and fresh tap-water for 2 months. Experimental rats (groups I, II, and III) were exposed to cigarette smoke by the same person who inhaled the smoke into his mouth for 2 seconds duration and immediately blew the smoke into a tube attached to a vent leading into a glass-cabin, five times consecutively (each puff contained approximately 35 ml of cigarette smoke). While control animals (group IV) were exposed only to fresh air, experimental animals of groups I, II, and III were exposed to the cigarette smoke either for 5, 10, or 15 minutes, respectively. This procedure was repeated 4 times daily during two months. After 2 months, the animals were sacrificed using a perfusion fixation of 2.5% glutaraldehyde under a deep anaesthesia, and the olfactory mucosa was carefully dissected away from the nasal bone. Following the post-fixation in osmium tetroxide, tissue samples were embedded in Araldite CY212. Semi-thin sections were stained with toluidine blue. Ultra-thin sections were stained with uranly acetate and lead citrate, and examined in a transmission electron microscope.
RESULTS.Prominent structural degenerations of olfactory epithelial cells were found in cigarette smoke-exposed rats as followings: Extensions of intercellular spaces, many apoptotic bodies between the cells, large cytoplasmic protrusions at the apical surface of supporting cells, deeply indented nuclear membrane of supporting cells, atrophy of the olfactory cilia, cytoplasmic edema, mitochondrial degeneration, numerous electron dense lysosome-like granular structures within the cells were seen.
CONCLUSION: Our findings suggested that cigarette smoke exposure may lead to toxic degenerative changes in the rat olfactory epithelium.

Keywords: olfactory epithelium, electron microscopy, cigarette smoke exposure, rat, histopathology, apoptosis

10.5505/2017ichc.PP-152 [Developmental and reproductive biology]

Is intrafollicular fertilization possible? Genetical analysis results of such embryos

Baris Baykal[1], Cem Korkmaz[1], Muhterem Bahçe[2], Cihangir Mutlu Ercan[1], Seyit Temel Ceyhan[1]

[1]ART Centre, Department of Obstetrics and Gynecology, Gulhane Training and Research Hospital, University of Health Sciences, Ankara, Turkey

[2]MBGENLAB Genetic Diseases Diagnosis Center, Ankara, Turkey

During the ICSI procedure of a 28 years old patient with unexplained infertility, we observed that one oocyte of the patient had two pronuclei (2PN) and 2 of the oocytes had 4 blastomeres. These two oocytes might either be embryos derived with intrafollicular fertilization or fragmented oocytes or parthenogenetic oocytes. We did not perform ICSI on these three suspicious oocytes and followed them up with a time-lapse embryo monitoring system. On day 1, the oocyte with 2PN initially had 2 blastomeres and 20% fragmentation. One of the initially 4 blastomere embryos was fragmented and the other one had 8 uneven blastomeres with 20% fragmentation. On day 2 and 3, the initially 2PN embryo had 4 blastomeres and on day 5 it had 6 blastomeres. The fragmented embryo had 12 blastomeres on day 2 and it progressed into blastocoel stage on day 5. The other one showed no progression.
On day 3 we performed blastomere biopsy to these 3 suspicious embryos. PGD was performed using FISH method with 5 probes (for chromosomes X, Y, 13, 18 and 21). The embryo that progressed into blastocoel stage and the one that was initially 2PN were haploidic and a PGD result could not be retrieved for the third one.
Nada ZM. (Fertility and Sterility 2005;83:457–61) and Terzic M. (Zentralbl Gynekol 2001;123:162–4) have reported the possibility of intrafollicular fertilization, which can be explained by the penetration of the ovarian tissue by the spermatozoa.
As a conclusion, zygotes (with 2 or more PNs) or embryos (with 2 or more blastomeres) can be encountered during ICSI procedure. These can be parthenogenetic (resulting with a haploidic embryo, which can progress further) or can be a result of intrafollicular fertilization.

Keywords: intrafollicular fertilization, two pronuclei, PGD

10.5505/2017ichc.PP-153 [Developmental and reproductive biology]

Structural and ultrastructural description of the ovarian wall in astacid crayfish, *Astacus leptodactylus*

Ana Maria Petrescu[1], Lucia Moldovan[2], Otilia Zarnescu[3]

[1]Department of Patrimony Research, "Grigore Antipa" National Museum of Natural History, Bucharest, Romania

[2]Department of Cellular and Molecular Biology, National Institute of Research and Development for Biological Sciences, Bucharest, Romania

[3]Laboratory of Histology and Developmental Biology, Faculty of Biology, University of Bucharest, Bucharest, Romania

Astacid crayfish reproductive cycle represents a current topic related to the basis of astaciculture. Astacid crayfishes have one reproductive cycle per year. The general structure of the ovary has a sac shape with three lobes, two anterior and one posterior, located dorsally to the hepatopancreas, common to all crayfish species. The ovarian wall is an important structure given the species characteristics, external fertilization and development. The purpose of this study is to identify significant correlations between structure and thickness of the ovarian wall during the reproductive cycle.
Several crayfish females were collected monthly from related localities in the southern part of Romania, tributaries of the Danube, ponds and as well the Danube River. The whole body and ovarian weight were obtained. The samples were fixed in Bouin solution and 6 µm histological sections were obtained. The general structure of the ovary was described using the hematoxylin-eosin-alcian blue staining (pH 2.5) and light microscopy. For transmission electron microscopy small fragments of ovary were fixed in glutaraldehyde, stained with uranyl acetate and lead citrate. Ovarian wall thickness was assessed for each reproductive period, from three sections and from 3 random points. During the reproductive cycle we have identified four distinct stages: immature, maturing, mature and spent. Its continuous structure with the oviduct ensures the cohesion of the three lobes and the expulsion to the oviduct of the mature egg and further to the gonopores.
The micrometric measurements revealed that the thickness of the ovarian wall decreased in a significant manner from the spent stage to the mature stage ($P<0.0001$). This structure, which is part of the somatic compartment of the ovary, includes two layers of spindle-shaped smooth-like muscle cells: an inner circular one and an outer longitudinal one, more rich in acidic mucopolyssacharides, haemocytes (abundancy variable with the reproductive stages), blood vessels and hemal sinuses. The ovarian wall is more thick close to the oviduct.
The present study underlines the importance of the ovarian wall during each stage of oogenesis and oviposition and it completes previous studies on crayfishes and lobsters.

Keywords: ovarian wall, crayfish, oogenesis, somatic cells.

10.5505/2017ichc.PP-154 [Developmental and reproductive biology]

The effects of di-n-butly phthalate on tuba uterina and possible protective effect of resveratrol

Nur Pakize Akkaya[1], Cigdem Elmas[1], Merve Cemile Seymen[1], Gülnur Take Kaplanoglu[1], Dila Sener[2]

[1]Gazi University Faculty of Medicine Department of Histology - Embryology, Ankara, Türkiye

[2]Okan University Faculty of Medicine Department of Histology - Embryology, İstanbul, Türkiye

Di-n-butyl phytalate (DBP) is an ester of phytalic acid that disturbs endocrine functions. It is used as a plasticizer in many substances such as dyes, enteric coatings of the drugs, toys and food packaging. It has many known adverse effects to the organism; particularly it can lead to infertility via its effects on the reproductive system. Resveratrol is a potent antioxidant that protects the organism against oxidative stress, it has been known and used for a long time. In our study, using histochemical and immunohistochemical methods we investigated the adverse effects of DBP on uterine tubes which are among the organs of female reproductive system, and the potential of Resveratrol as an antioxidant to reverse these adverse effects. For this purpose, we administered certain doses of DBP, solvent (carboxymethyl cellulose) and DBP+Resveratrol to 36 female rats aged 20 days which we divided into 6 groups during 30 days period. Data analysis was performed using Statistical Package for Social Sciences (SPSS) version 19.0 software and it was found statistically significant. Examination of the tissues using hematoxylin-eosin, Masson's trichrome stains and cytochrome-c primary antibodies revealed that DBP caused damage to uterine tubes in a dose dependent way, and that Resveratrol had the potential to reverse these damage; however it was less effective in the group that received high dose of DBP, therefore we concluded that its favorable effects could be enhanced by using it in dose-dependent way. Additionally MDA (Malondialdehyde) concentrations in tuba uterina were used as a measure of Lipid peroxidation (LPO). The results showed DBP and solvent (CMC) treatment increased tubal peroxidation significantly and decreased the total sulphydryl groups (RSH) level. Uterine tubes have very important functions as oosite transport, sperm maturation and fertilization. This study could be important for further understanding of DBP toxicity in uterine tubes as one of the causes of infertility.

Keywords: Di-n-butyl phthalate (DBP), Resveratrol, Tuba Uterina, Cytochrome-c

Cytochrome -c Antibody (IHC) (All groups)

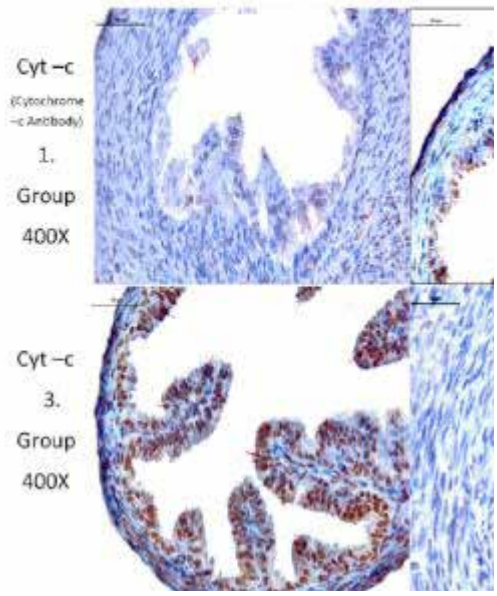

Hematoxylene - Eosin (1-2-3 Groups)

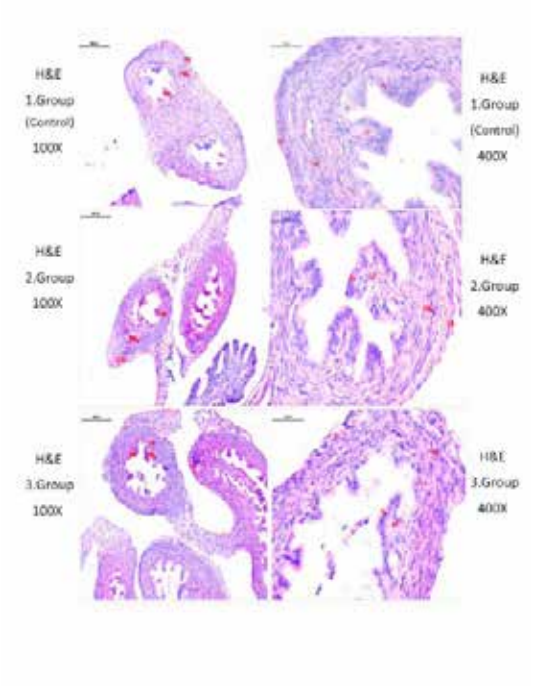

Hematoxylene - Eosin (4-5-6 Groups)

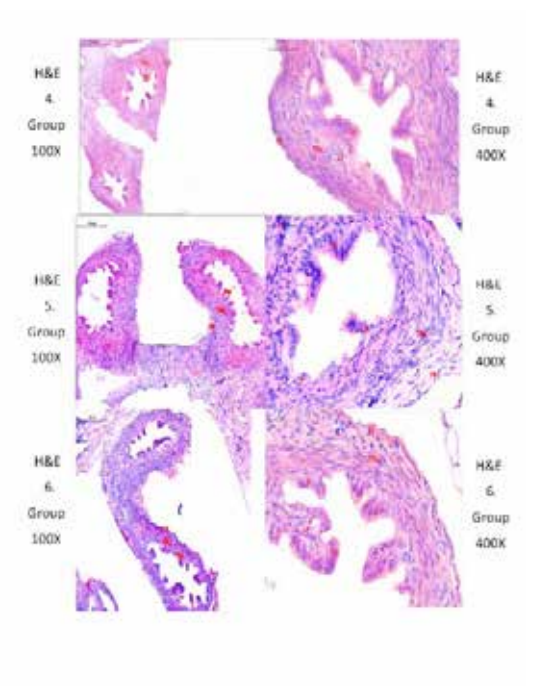

Masson's Trichrome (1-2-3 Groups)

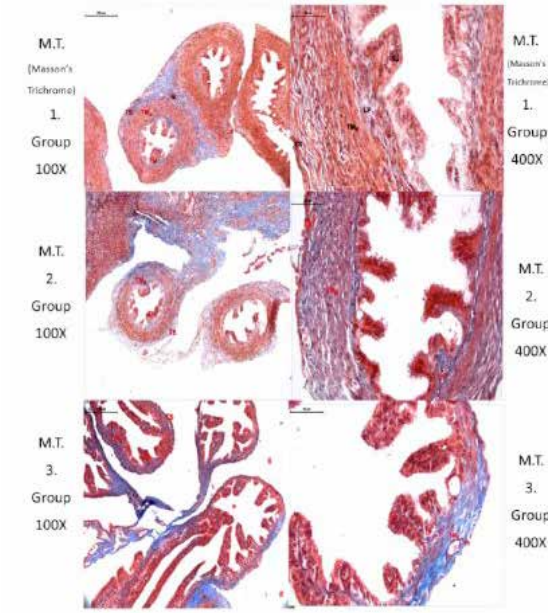

Masson's Trichrome (4-5-6 Groups)

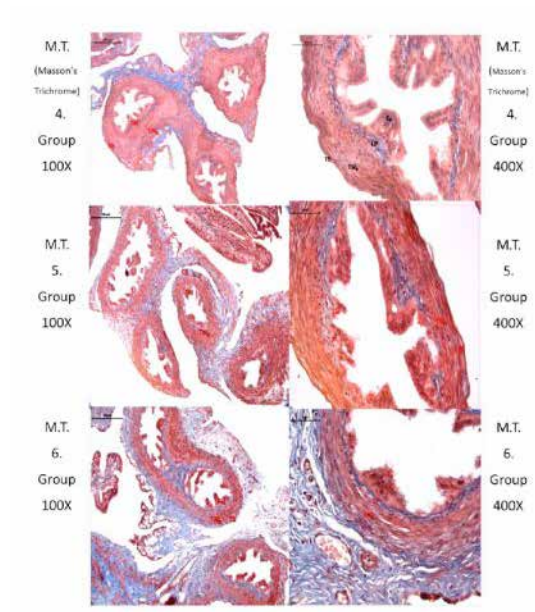

Statistics 1- Degeneration Criteria

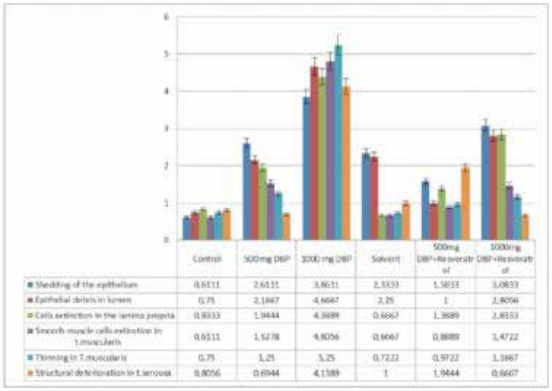

	Control	500 mg DBP	1000 mg DBP	Solvent	500mg DBP+Resveratrol	1000mg DBP+Resveratrol
Shedding of the epithelium	0,6111	2,6111	3,8611	2,3333	1,3833	3,0833
Epithelial debris in lumen	0,75	2,1667	4,6667	2,25	1	2,8056
Cells extinction in the lamina propria	0,8333	1,9444	4,3889	0,6667	1,3889	2,8333
Smooth muscle cells extinction in T.muscularis	0,6111	1,5278	4,8056	0,6667	0,8889	1,4722
Thinning in T.muscularis	0,75	1,25	5,25	0,7222	0,9722	1,3867
Structural deterioration in T.serrosa	0,8056	0,6944	4,1389	1	1,9444	0,6667

Figure 1: Mean of Degeneration Criteria.
(Histochemical Analysis under Light Microscopy)

Statistics 2- Immunreactivite (cyt -c primary antibody)

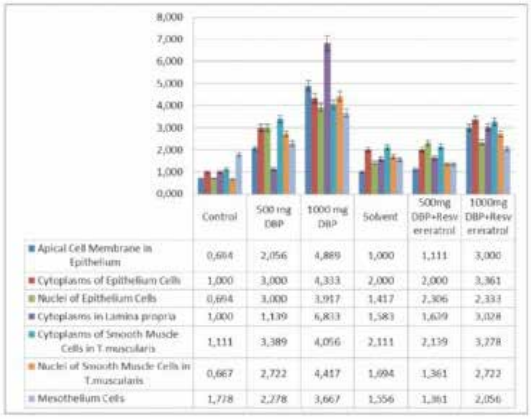

	Control	500 mg DBP	1000 mg DBP	Solvent	500mg DBP+Resveratrol	1000mg DBP+Resveratrol
Apical Cell Membrane in Epithelium	0,694	2,056	4,889	1,000	1,111	3,000
Cytoplasms of Epithelium Cells	1,000	3,000	4,333	2,000	2,000	3,361
Nuclei of Epithelium Cells	0,694	3,000	3,917	1,417	2,306	2,333
Cytoplasms in Lamina propria	1,000	1,139	6,833	1,583	1,639	3,028
Cytoplasms of Smooth Muscle Cells in T.muscularis	1,111	3,389	4,056	2,111	2,139	3,278
Nuclei of Smooth Muscle Cells in T.muscularis	0,667	2,722	4,417	1,694	1,361	2,722
Mesothelium Cells	1,778	2,278	3,667	1,556	1,361	2,056

Figure 2: Evaluation of Cytochrome –c primary antibody intensity between groups. (Immunohistochemical Analysis, under Light Microscopy)

Statistics 3- Mean of MDA and RSH Levels

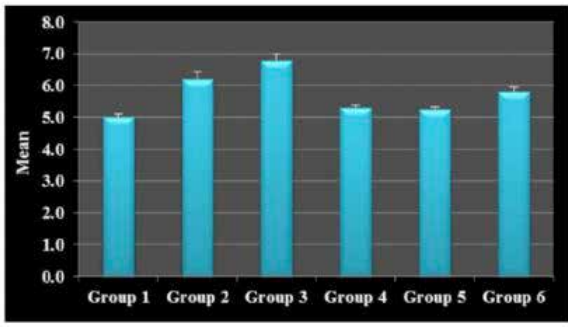

Figure 3: Mean of MDA levels.

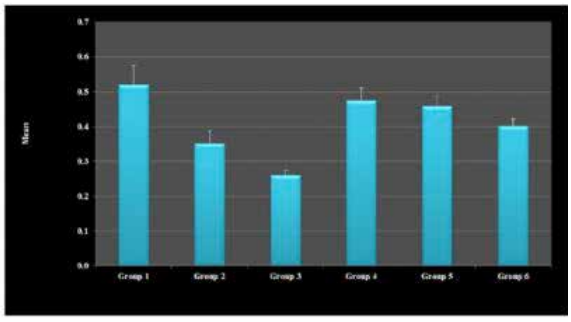

Figure 4: Mean of total sulphydryl groups (RSH) levels.

10.5505/2017ichc.PP-155 [Developmental and reproductive biology]

The role of miRNA's expressions during implantation

Sevtap Gökalp[1], Bunyamin Akgül[2], Tayfun Ozcakır[3], Hafize Seda Vatansever[4]

[1]Department of Histology and Embryology, Faculty of Medicine, Celal Bayar University, Manisa, Turkey

[2]Department of Molecular Biology and Genetics, Izmir Institute of Technology, Izmir, Turkey

[3]Department of Obstetrics and Gynecology, Faculty of Medicine, Celal Bayar University, Manisa, Turkey

[4]Department of Histology and Embryology, Faculty of Medicine, Celal Bayar University, Manisa, Turkey, Near East University, Experimental Health Sciences Research Center, Nicosia, North Cyprus.

Implantation process is controlled with endometrium, factors secreted by the embryos and in accordance with these factors embryo and/or endometrium via receptors on. The receptivity of the endometrium and embryos adhesiveness stands outs for implantation. MicroRNA (miRNAs) are small noncoding RNAs that control post-transcriptional gene expression. More than 700 human miRNAs have been identified and they were shown to play an important role in intracelluler cycle regulation in both normal and pathological conditions.
In this study we aim to identify miRNAs expression in different time period of endometrium in fertile and infertile cases, and also analyses of Dicer, Drosha, eIF2α and eIF2C's distributions in there.
The endometrial samples were taken from fertile and infertile patients in proliferation and early secretion periods for histological and miRNA analysis. For histological analyses, the samples are fixed in 10% formalin solution and stained them with hematoxylen-eosin for morphological analysis on paraffin sections. For immunohistochemical analysis, distribution of anti-dicer, anti-drosha, anti-eIf2α and anti-eIF2C were investigated. For the miRNA analyses, miR-17-5p, miR-23a, miR-23b, miR-542-3p, miR-21, miR-199a*, miR-705, miR-20a, miR-26a, miR-125b, miR-200a/b/c from all samples were were analyzed with qRT-PCR.
While Dicer immunoreactivity was detected weakly only proliferation phase of fertile group, this immunoreactivity were detected strongly in both proliferation and early secretory phases of infertile group. Drosha immunoreactivitiy was also weakly detected in the proliferation phase of fertile group, it was moderately detected in both proliferation and early secretory phases of infertile group. eIF2α immunoreactivitiy was similar in each groups but there were a few differences between fertile and infertile group. eIF2C immunoreactivitiy was negative in all groups.
miR-21, miR-199a* and miR-23a were highly expressed in proliferation phase of fertile group, miR-23a and miR-125b were highly expressed in early secretion phase of infertile group.
In conclusion, Dicer and Drosha immunoreactivities and different expression of miRNA's were detected in the infertile and fertile groups. Implantation problems may be reason for different miRNA expression which controlling with Dicer and Drosha in the infertile endometrium in both proliferation and early secretory phases. Therefore, miRNA biogenesis is important for understanding of implantation failure.

Keywords: Endometrium, infertility, implantation, miRNA

10.5505/2017ichc.PP-156 [Developmental and reproductive biology]

Effects of Di-n butyl phthalate and the possible protective potential of Resveratrol on uterus tissue

Dila Şener[1], Çiğdem Elmas[2], Deniz Erdoğan[2], Güleser Göktaş[2], Gülnur Take Kaplanoğlu[2]

[1]Department of Histology and Embryology, Okan University, Istanbul, Turkey

[2]Department of Histology and Embryology, Gazi University, Ankara, Turkey

AIM: Di-n-butyl phthalate (DBP) is endocrine disruptive chemical agent and phthalic acid ester used as a plasticizer. It was suggested that DBP leads to damage in many organs and reproductive system. DBP has adverse effects on uterine endometrial layer such as mimicking endogenous estrogen, reducing decidulization and increasing thickness of the endometrium. Resveratrol is a natural powerful antioxidant compound that exists high amounts in concord grape and its shell. Besides it possess many beneficial biological actions in organism, it was also reported that resveratrol has impacts on the uterine endometrial layer such as phytoestrogenic and anti-cancer effects. In this study, we aimed to determine positive protective effects of resveratrol against the damage caused by an endocrine disruptor DBP on uterine endometrial tissue with the immunohistochemistry and TUNEL methods.
MATERIAL-METHODS: 20 day old, 36 female Wistar-albino rats separated into six group (n=6) that are control, 500 mg/kg/day DBP, 1000 mg/kg/day DBP, solvent (carboxymethylcellulose (CMC), 10ml/kg), 500 mg/kg/day DBP+20 mg/kg/day Resveratrol and 1000 mg/kg/day DBP+20 mg/kg/day Resveratrol. All uterine tissues removed at the end of experimental period, prepared by using routine light microscopic methods. Immunohistochemistry was used to detect C-kit and Estrogen receptor- α (ER-α) antibody expressions and TUNEL method used for detection of apoptosis.
RESULTS: C-kit immunostaining was dense in endometrial surface and glandular epithelial cells of 500 mg/kg/day DBP group and expession was intense in subepithelial stroma of higher dose DBP group. C-kit immunoreactivity was significantly increased in CMC group however, decreased in resveratrol treated groups. Moderate staining occured in glandular epithelium, stromal cells in higher dose DBP+Resveratrol. Strong ER-α immunoreaction was observed in glands and functional layer in CMC group. In resveratrol treated groups ımmunostaining was remarkably similar with control. In 500 mg/kg/day DBP+Resveratrol, TUNEL positive cells were similar with control.
CONCLUSION: In conclusion, while DBP has distinct damaging effect with dose-dependent manner, resveratrol could have protective impact against damage in uterine tissue. Resveratrol was more effective in 500 mg/kg/day DBP+Resveratrol group, but insufficient with higher dose DBP combination. It was determined that according to the damage, using Resveratrol in dose dependent manner could enhance positive effects.

Keywords: Di-n-butyl phyhalate, Resveratrol, uterus

10.5505/2017ichc.PP-157 [Developmental and reproductive biology]

Chronic mobile phone radiation and the effect of melatonin which is applied for protection, on ovary tissue

Sinem Yücel[1], Gülnur Take Kaplanoglu[1], Iskender Kaplanoglu[2], Bahriye Sirav Aral[3], Cemile Merve Seymen[1]

[1]Gazi University Faculty Of Medicine, Department of Histology and Embryology, Ankara, Turkey

[2]Etlik Zubeyde Hanim Women's Health Teaching and Research Hospital IVF Center, Ankara, Turkey

[3]Gazi University Faculty Of Medicine, Department of Biophysics, Ankara, Turkey

AIM: To analyse the possible structural transformations in ovary tissue when being chronically exposed to electro-magnetic fields and we tried to figure out the preservative effect of melatonin to these transformations.
METHODS: 24 female Wistar albino rats were divided into 4 equal groups. Throughout in 90-day experiment, there has been no application to control group while subcutaneous daily melatonin was enjected to the 2nd group. 2100-MHz radiation for 30 minutes in every day applied to the 3rd group. Subcutaneous melatonin enjection was applied 40 minutes before radiation and then radiation was applied for 30 minutes to the 4th group. At the end of the experiment, ovary tissues were taken from subjects which was sacrificed under high-dose anesthesia. The sections that were grabbed for assessment has been applied with Hematoxylin-Eosin, TUNEL and PCNA paintings and they had been illustrated under light microscobe. Zona pellusida thickness were measured in the PAS paintings. Moreover, follicule counts were made from each sections. The data obtained were statistically analysed.
RESULTS: By the Hematoxylin-Eosin stainings, the increase in the number of follicles gone to atresia were noted in the third group, while zona pellusida had taken a somewhat bold and thin formation. In the fourth group, the number of follicles gone to atresia were lower when compared with the third group. With the TUNEL stainings, it had been reached that apoptotic device or cells were considerably low in the control group and the second group, whereas apoptotic device or cells were on the rise in the third group, depending on the density of follicles gone to atresia. In the PCNA stainings belonging to the third group; binding in the primordial, developing follicles and corpus luteum were much lower in comparison with the control group, while the binding levels in the fourth group were notably close to the control group.
CONCLUSION: It was concluded that melatonin implementation could partially avert structural degenerations caused by radiation, depending on the dosage or implementation length of melatonin.

Keywords: Mobile Phone, Radiation, Melatonin, Ovary

Figure 1



Experimental System

Figure 2

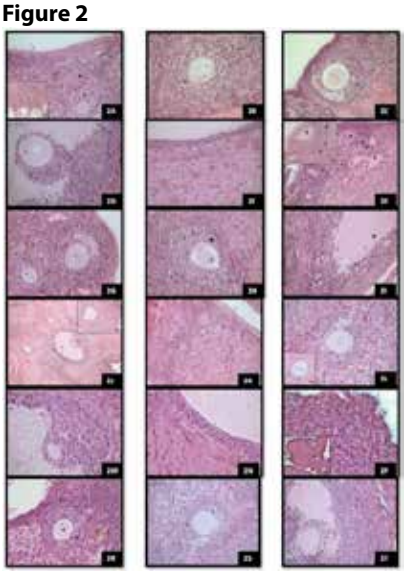

Hematoxylin Eosine stainings for all experimental groups

Figure 3

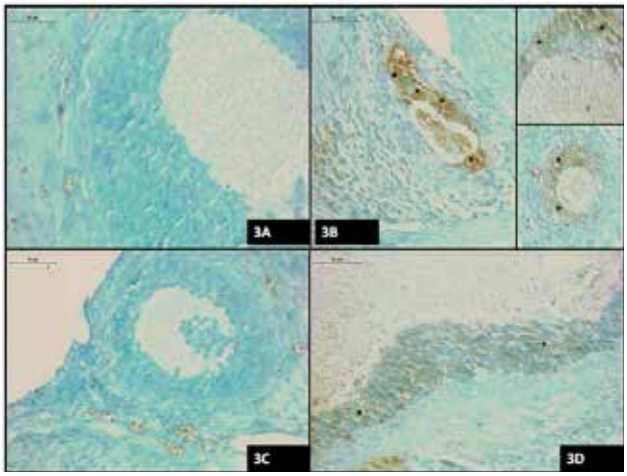

TUNEL stainings for all experimental groups

Figure 4

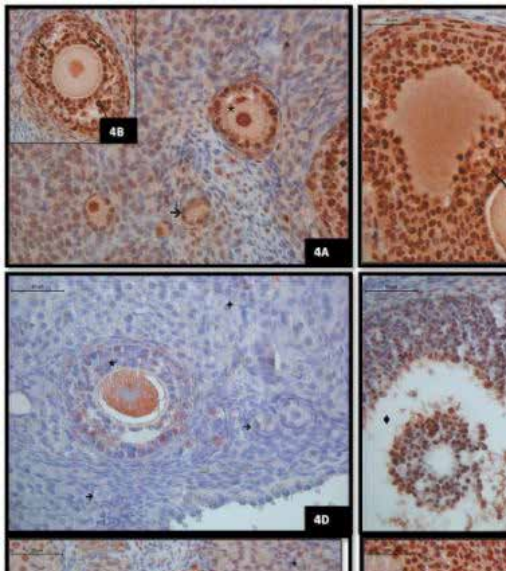

PCNA immun stainings for experimental groups

Figure 5

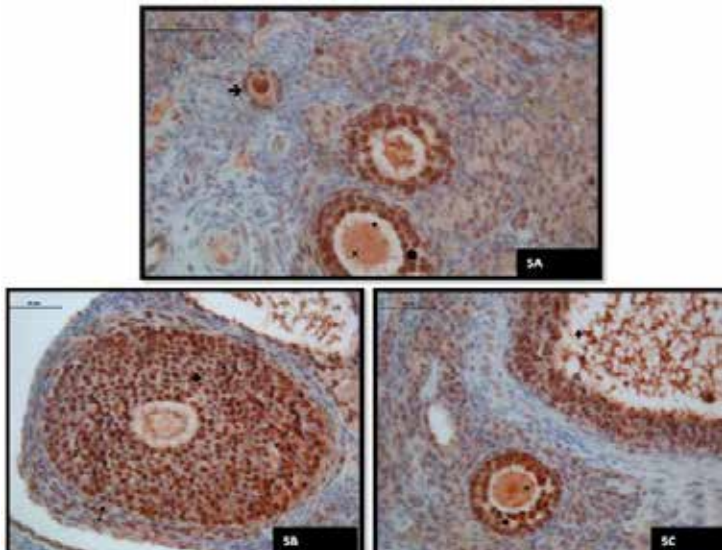

PCNA immun stainings for experimental groups

Graphic 1

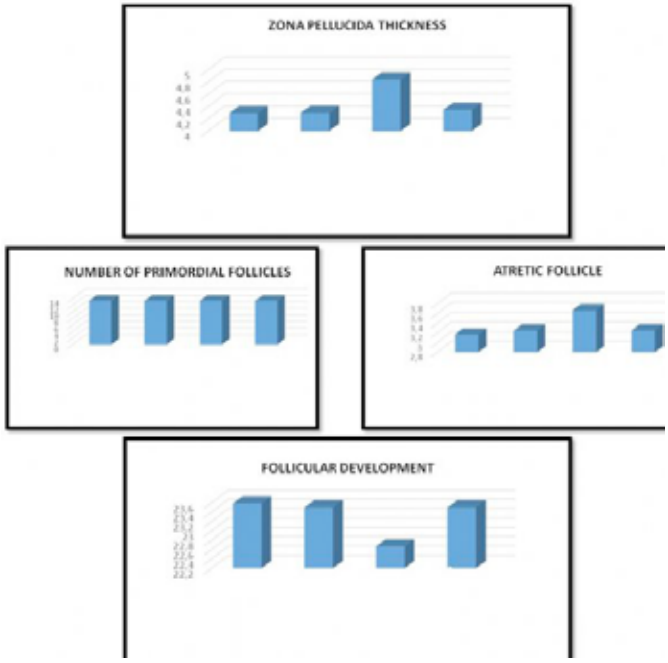

Statistical graphics for zona pellucida thickness, Number of primordial follicles, Atretic follicle and Follicular development.

10.5505/2017ichc.PP-158 [Developmental and reproductive biology]

The expression of Bcl-2, BAX and AR in ovary tissue of dehydroepiandrosterone-induced polycystic ovarian syndrome rats

Jinsong Zhou, Hong Tian, Xiaotian Zhang, Ming Lu, Lirong Wang
Department of Human Anatomy, Histology and Embryology, School of Basic Medical Sciences, Xi'an Jiaotong University Health Science Center. Xi'an, China

The polycystic ovarian syndrome <PCOS<is one of the frequently occurred endocrine diseases in fertile women, and the abnormal expression of apoptosis-related and sex genes are probably involved in the formation of PCOS. Bcl-2 and BAX are the important apoptosis-related regulatory proteins, and the androgen receptor (AR) gene polymorphism is also an influence factor in PCOS. In this study, the subcutaneous injection of dehydroepiandrosterone (6mg/100g) was carried on in 20 85-day old female rats at 20:00 for continuous 20 days, and the experiments of ovary morphology and serum hormone verified PCOS rat model. The Western-Blot and immunohistochemistry experiments were used to check the changes of distribution and amount of Bcl-2, BAX and AR in PCOS and control groups. The results showed that,1) In PCOS model, the Bcl-2 and BAX proteins are mainly expressed in the cytoplasm of granulosa cells of ovary follicles and granulosa lutein cells in corpus luteum, and the AR protein mainly locates in nuclei of granulosa cells of ovary follicles. 2<The expression of Bcl-2 and AR significantly decreased in PCOS rats<p<0.05<p<0.05<but the expression of BAX did not change. The results showed that the expression of Bcl-2 and AR decreases in PCOS rat, suggesting the apoptosis of ovary tissue and abnormal expression of AR may participate in the formation of PCOS, and why the expression of BAX did not change needs to be further studied.

Keywords: polycystic ovarian syndrome, apoptosis, Bcl-2, Bax, AR

10.5505/2017ichc.PP-159 [Developmental and reproductive biology]

Histopathologic Examination Of Possible Effects Of Melatonin Against The Alternation On Uterus Of Neonatal Exposure to Bispenol A In Female Rats

Damla Dernek[1], Suna Ömeroğlu[1], Neslihan Coşkun Akçay[2], Bahar Kartal[1], Saadet Özen Akarca Dizakar[1], Ismail Türkoğlu[1], Vildan Aydın[1]

[1]Department of Histology and Embryology, Gazi University, Ankara, Turkey

[2]Department of Obstetrics and Gynecology, Hacettepe University, Ankara, Turkey

The aim of this study was to investigate the possible effects of melatonin on rat on rat uterine tissue against exposure with BPA in the neonatal period.
Twenty-four female rats were divided into four groups, (n=6) per group. Group I was used as a control (sesame oil + ethanol), group II was injected daily with (100 mg/kg) BPA by subcutaneously (sc) daily postnatal days (PND0-PND10), group III were injected daily with (10 mg/kg) melatonin by sc for 10 days (PND20-PND30) and group IV were injected daily with (100 mg/kg) BPA (PND0-PND10) and (10 mg/kg) melatonin (PND20-PND30). All rats were sacrificed on the PND70. Histological analyses, immunostaining of Bcl-2 and cytochrome c and TUNEL assays were performed. According to our results neonatal exposure to BPA accelerates onset of puberty, causes degenerative and morphometric changes on rat uterus, increases apoptotic reaction rates. The immunoreactivity of Bcl-2 was decreased after BPA administration. In addition, immunoreactivity of Bcl-2 showed an increase after melatonin treatment. However, Cytochrome c immunoreactivity was decreased after melatonin administration. Our results suggest that melatonin may have positive effects against BPA-induced degenerative changes on rat uterus.

Keywords: Bisphenol A, Melatonin, histomorphologic, Bcl2, cytochrome c, apoptosis

Figure 1

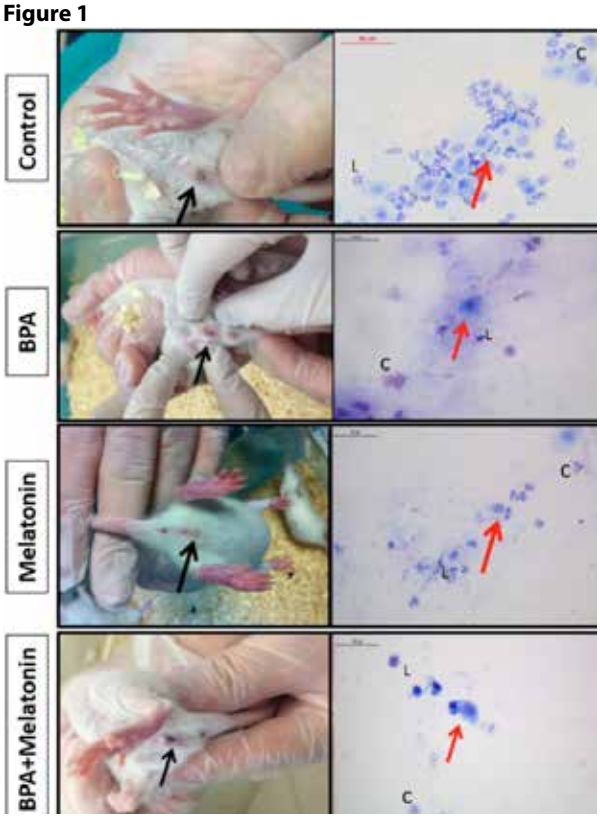

Determination of estrus cylce phase and on set of puberty 100mg/kg BPA treated rats during neonatal (PND0-10) period showed an earlier vaginal opening (PND24) and estrous cycle time (PND 31) as compared with all other groups. BPA administered rats showed earlier vaginal opening and estrous cycle time compared to other groups. Photograph showing vaginal opening (black arrow) and nucleated epithelial cells (red arrow), leukocytes (L) and anucleated cornified cells (C) in the in the vaginal smear samples of the female rats from each group (n=6 per group).

Figure 2

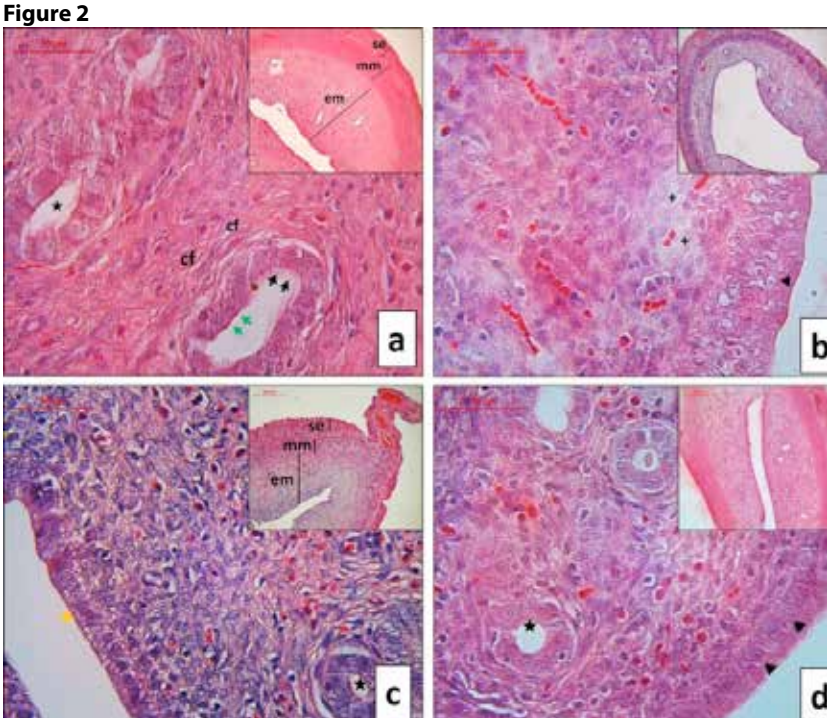

Histologic examination of all experimental groups. Normal microscopic appearance of the uterine, ciliated (black arrow) and secretory cells (green arrow), uterine gland (star), fibroblasts (fb) and collagen fibers (cf) in control (a). BPA group (b) showed edematous areas (+) and foamy-like formations with heterochromatic nucleus (arrowhead). Melatonin group (c) showed epithelium (yellow arrow), endometrium (em), myometrium (mm) and serosa (se) layers. In the BPA + melatonin group, the foamy like formations containing heterochromatic nucleus (arrowhead) was decreased in luminal epithelium of uterus of rats from in BPA+Melatonin group (d) compare to BPA group (b) (HE). (a, b, c and d Magnification x40, İnsets Magnification x10)

Figure 3

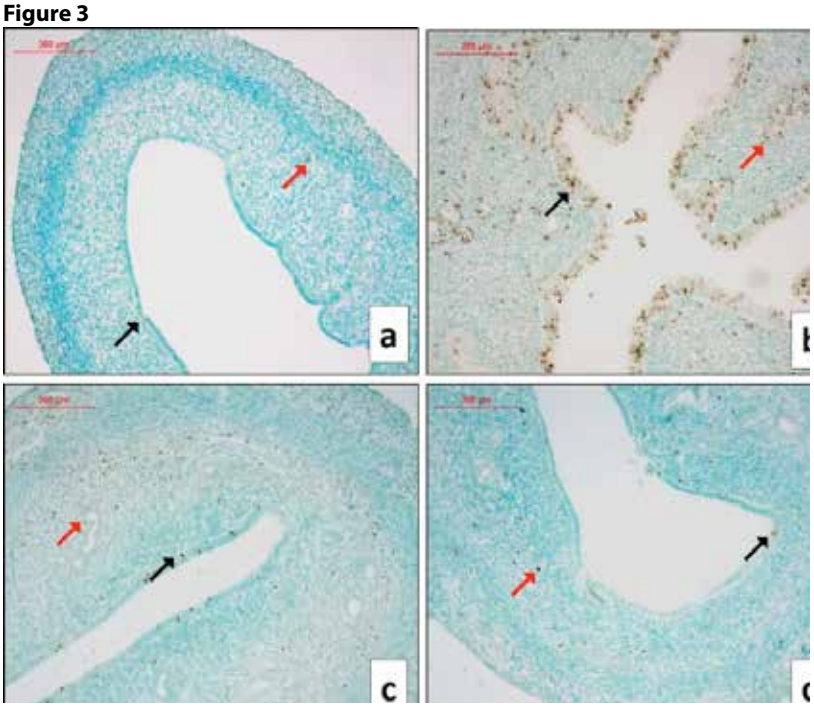

Apoptotic cells in the luminal and glandular epithelium. TUNEL-positive cells in the luminal (black arrow), and glandular epithelium (red arrow) of female rat uterus from control (a), BPA(b), Melatonin (c) and BPA+Melatonin (d). The number of TUNEL-positive cells in uterus luminal epithelium of BPA group rats, were significantly increased compare to those other groups. (DAB&Metilen green) (a, b, c, d: Magnification x10)

Figure 4

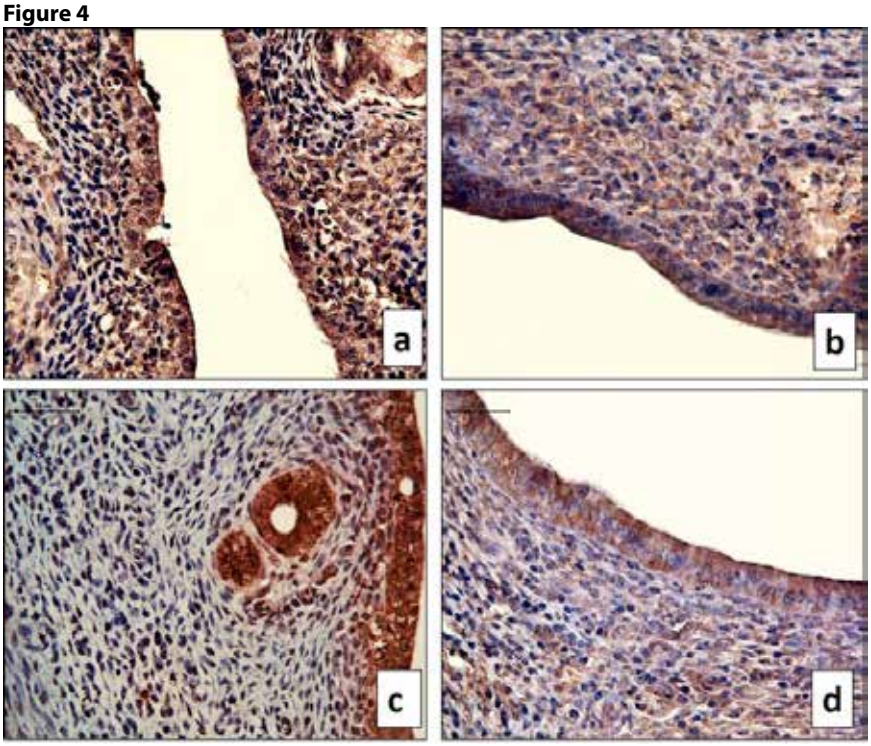

The immunoreactivity of anti- Bcl-2 in rat uterus from each group. Immunostaining of Anti-Bcl2 in endometrium and uterine glands of the rats from BPA and BPA+Melotonin group was lower than control group. Bcl2 immunoreactivity in endometrium and uterine glands of the rats from melatonin group was similar with control group. Control (a), BPA (b), Melatonin (c) and BPA+Melatonin (d). (a,b,c,d: Magnification x40)

Figure 5

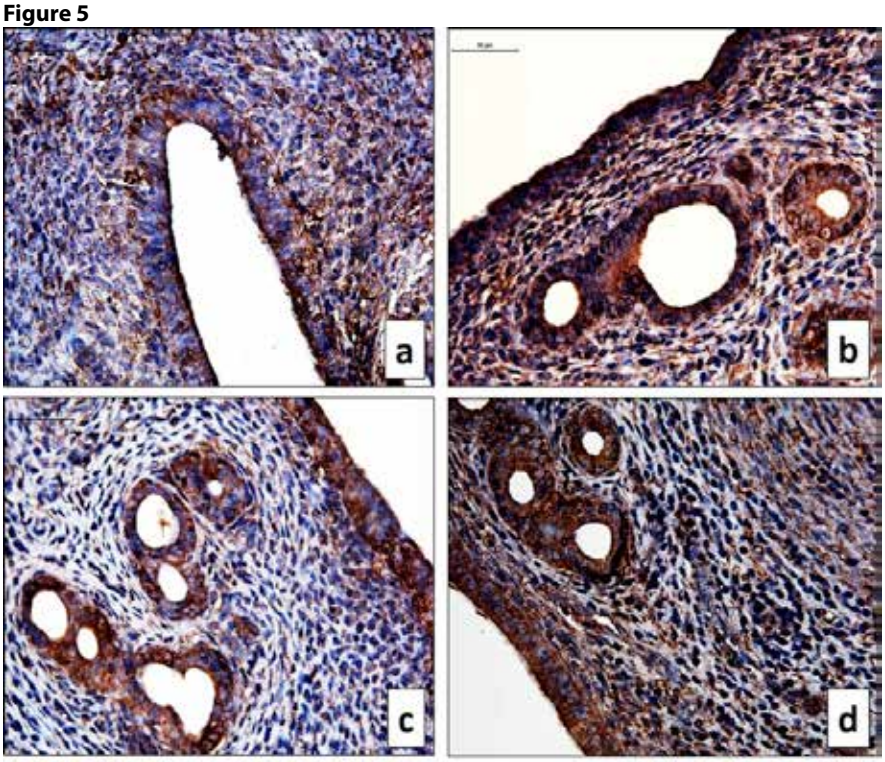

The immunoreactivity of cytochrome c in rat uterus from each group. Cytochrome c expression in endometrium and uterine glands of rats from BPA and BPA+Melatonin group was more intense than control group. The immunoreactivity of cytochrome c in endometrium and uterine glands of rats from melatonin group was similar with those of control. Control (a), BPA (b), Melatonin (c) and BPA+Melatonin (d). (a, b,c,d:Magnification x40)

10.5505/2017ichc.PP-160 [Developmental and reproductive biology]

The Role of Fas/FasL Signaling Pathway in Jnk-Inhibited Diabetic Testes Tissue

Gulnur Kizilay[1], Sinasi Bayram[1], Onur Ersoy[1], Yeliz Bozdemir Donmez[2]

[1]Trakya University, School of Medicine, Department of Histology and Embryology

[2]Trakya University, Technology Research and Development Application Research Center

BACKGROUND: Diabetic male subfertility and infertility have been topics of high interest in recent years. The apoptotic pathways have increasingly been important to these areas. Fas/FasL signaling pathway is known as apoptosis initiating pathway. c-Jun N-terminal kinases (JNKs) is regulate cell functions including proliferation, differentiation, cell survival and apoptosis. The aim of the study to reveal of the possible effect of JNK inhibitor (SP600125) on Fas/FasL signaling pathway in diabetic testicular apoptosis.
METHODS: Thirty *Sprague-Dawley* male rats, weighing 250–350g, were divided randomly into five groups; I.group; control (animals received only vehicle; n=6), II. group; (single dose 60 mg/kg streptozotocin i.p.,15 days; n=6), III. group; (60 mg/kg streptozotocin,30 days; n=6), IV. group; (60 mg/kg streptozotocin +15mg/kg SP600125 i.p.,15 days; n=6), V. group; (60 mg/kg streptozotocin+15 mg/kg SP600125,30 days; n=6). At the end of the experiment, rats were sacrificed, testes tissue samples were collected. Then, there were routinely processed and embedded in paraffin. Fas, FasL and caspase 8 were evaluated by using immunohistochemistry to examine the apoptosis in the diabetic testes. All data were analyzed using SPSS 20.0 for Windows software. Multiple comparisons were made among the different groups by Mann Whitney U test.
RESULTS: JNK inhibition have confirmed by histologic score (HSCORE) of JNK (unpublished data). Fas, FasL and caspase 8 immunoreactivities were scored as the number of immunopositive cells/1000 cells/slide. Fas and caspase 8 immunpositive cells were significantly increased in second, third, fourth and fifth groups compared with the first group ($P<0.05$; Table 1). FasL immunpositive cells count was significantly increased in all groups (except the fifth group) compared with first group ($P<0.05$; Table 1).
Interestingly, Fas, FasL and caspase 8 immunpositive cell counts were significantly decreased in the fourth and fifth groups compared with the second and third groups, respectively ($P<0.05$, $P<0.05$; Table 1).
CONCLUSION: We suggested that JNK inhibition may decrease apoptosis in diabetic testes with affected Fas/FasL signaling pathway.

Keywords: Diabetes mellitus, Testes, SP600125, Fas/FasL, Caspase 8

Fas, FasL and caspase 8 immunpositive cell counts

	I.group	II.group	III.group	IV.group	V.group
Fas	7,67 ± 2,42	22,83 ± 3,60a	39,83 ± 6,94a	14,17 ± 2,71a,b	12,33 ± 2,58a,c
FasL	11,67 ± 2,73	23,33 ± 3,27a	38,83 ± 3,92a	17,17 ± 2,14a,b	13,50 ± 2,59c
Caspase 8	4,83 ± 1,47	26,17 ± 2,99a	53,67 ± 6,89a	17,83 ± 2,32a,b	9,67 ± 1,63a,c

a: $P<0.05$, compared with first group; b: $P<0.05$, compared with second group; c: $P<0.05$, compared with third group.

10.5505/2017ichc.PP-161 [Developmental and reproductive biology]

Histological investigations on the thymus of male rats prenatally exposed to bisphenol A

Işıl Aydemir[1], Şadiye Kum[2], Mehmet Ibrahim Tuğlu[1]

[1]Celal Bayar University, Faculty Of Medicine, Histology And Embryology Department

[2]Adnan Menderes University, Faculty Of Veterinary Medicine, Histology And Embryology Department

Bisphenol A is called as a endocrine-distrupting chemical because of the its steroid-like activity and it used in the construction of plastic containing materials. It is indicated that bisphenol A can pass the human serum, urine, follicular fluid, placenta and umblical cord as a result of the use of substances containing this agent. In this study, we aimed to investigate the effects of bisphenol A on the development of the thymus, a primary lymphoid organ which plays an important role in the specific immunity. For this purpose, adult female rats were allowed to conceive and were divided into four groups, control, sham, low dose (300 µg/kg) and high dose (900 µg/kg). From the first day of pregnancy (during 21 days), BPA dissolved in 1 ml of corn oil was administered orally to the two groups (low dose and high dose), the sham group was given only 1 ml of corn oil whereas the control group was given nothing. Thymus samples from all groups were obtained on day 21, day 45 and day 90, were fixed in 10% buffered neutral formalin. After routine paraffin tissue protocol, the 6µm thick sections were taken and were applied hematoxylin-eosin and Mason's Trichrom staining to demonstrate the histological structure, immunohistochemistry staining for CD3, CD4, CD8 and CD79a and TUNEL method for the apoptotic cells. Evaluation of all groups, CD3, CD4, CD8 and CD79a staining were decreased in the experimental groups whereaas CD3, CD4, CD8 and CD79a staining were observed significant in the control group respectively. CD8 and CD79a staining were diminished in the test group low dose than the group high dose. The apoptotic cells were determined in the all groups on day 90 as a result of the thymus involution. It is noted that there was not any histological and morphological damages in the rats prenatally exposed the bisphenol A. It was seen changes in the CD markers and TUNEL staining, but bisphenol A did not affect the endocrine structure, quality of life significantly. The effect of the bisphenol A is unknown in the future, but there is no problem in the adult rats.

Keywords: Thymus, bisphenol-A, T lymphocyte

10.5505/2017ichc.PP-162 [Developmental and reproductive biology]

Assessment of Sperm DNA İntegrity From Normozoospermic İnfertile Men Selected by Different Selection Methods

Sevilay Erimşah[1], Süheyla Gonca[2], Aysel Kükner[1]

[1]Department of Histology and Embryology, Abant Izzet Baysal University, Bolu, Turkey

[2]Department of Histology and Embryology, Kocaeli University, Kocaeli, Turkey

INTRODUCTION: The male factor is responsible for about %50 of infertility cases and clinical parameters are not always enough for assessing the sperm quality of patients (1). The assessment of sperm DNA integrity was shown to be more significant than the standard semen analysis in determining the fertility potential. Density gradient and swim up methods are widely used classical methods for sperm selection at IVF treatment (2).
The microfluidic chip has been developed as a new sperm selection method which could be considered as a method of choice to achieve better results in IVF (3). The commonly used density gradient and swim up sperm selection methods require multiple centrifugation, washing or pipetting procedures that cause several sperm DNA damages. However, the microfluidic chip method does not require centrifugation and other common procedures to select good quality sperm (4). Although this microfluidic chip is an effective way to select good quality sperm, it is not clearly known whether it reduces sperm DNA fragmentation.
In this study density gradient and swim up which are classical selection techniques have been compared with microfluidic chip at the normozoospermic infertile patients.
MATERIALS-METHODS: Semen samples from twenty normozoospermic infertile men were separated into four groups and semen samples sorted using by microfluidic chip, swim-up and density gradient methods. Sperm samples were measured according to the WHO guidelines and stained with Aniline Blue (figure 1), Toluidine Blue (figure 2) and TUNEL (figure 3) to determine sperm chromatin condensation and DNA fragmentation. Subsequently, semen parameters, the percentages of sperm DNA fragmentation and chromatin condensation defects were measured and analyzed by variance and bonferroni test. We used the software of SPSS version 21 for statistical analysis.
ResultWhen the methods are compared, we found significantly different ($P<0.0001$) at DNA integrity. It was seen that the chromatin condensation defects and DNA fragmentation in sperms were the lowest after microfluidic chip and the highest after density gradient method. The results show that the microfluidic chip method is a more effective and physiological method than the density gradient and swim up methods in the IUI treatment of normozoospermik infertile patients.

Keywords: Normozoosperm, Sperm selection, Sperm DNA integrity.

figure 1



Aniline blue staining method, light blue sperm heads (black arrow) show normal chromatin condensation and dark blue sperm heads (red arrow) show abnormal chromatin condensation.

figure 2

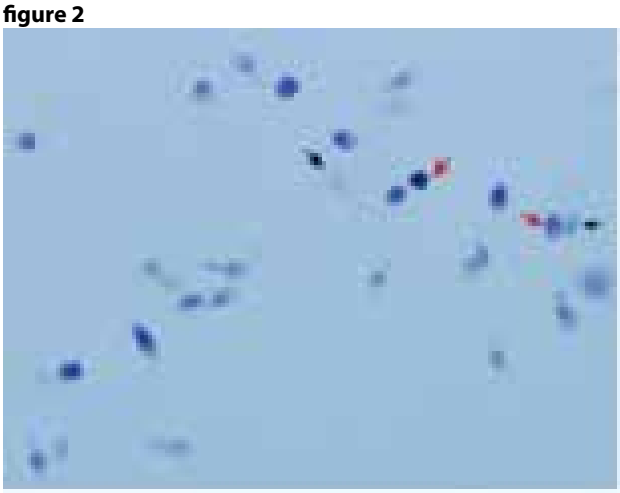

Toluidine blue staining method, pale blue sperm heads (black arrows) show normal and dark blue or violet or purple sperm heads (red arrows) show abnormal chromatin condensation.

figure 3

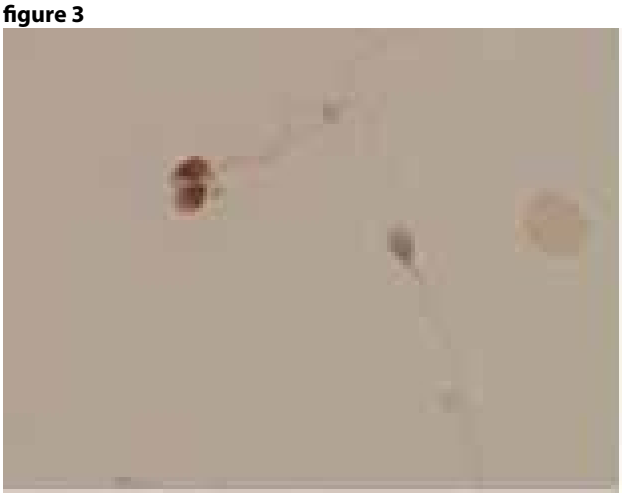

TUNEL staining method, brown stained sperm heads show fragmented DNA and green colored sperm heads show non-fragmented DNA.

10.5505/2017ichc.PP-163 [Developmental and reproductive biology]

The effects of melatonin on possible damage will be occur on adipocytokines and testis with the coadministration of fructose and bisphenol A

Ismail Türkoğlu[1], Suna Ömeroğlu[1], Mustafa Kavutçu[2], Saadet Özen Akarca Dizakar[1], Neslihan Coşkun Akçay[4], Meriç Arda Eşmekaya[3], Murat Kocabıyık[2]

[1]Department of Histology and Embryology, Gazi University, Ankara, Turkey

[2]Department of Medical Biochemistry, Gazi University, Ankara, Turkey

[3]Department of Biophysics, Gazi University, Ankara, Turkey

[4]Department of Obstetrics and Gynecology, Hacettepe University, Ankara, Turkey

Reproductive system includes complex biological processes that can be disrupted by exposure to environmental contaminants and affected by dietary habit. Bisphenol A (BPA) is one of the chemical contaminants produced in the highest quantity worldwide. BPA affects the normal development and function of the male reproductive system. Moreover, emerging evidence suggests that BPA may influence adipocytokines related male reproductive system. Furthermore, increasing daily dietary fructose consumption poses a threat to human health. Melatonin is a free radical scavenger and endogen antioxidant, in addition has important effects in the reproductive and metabolic regulation.
The aim of this study was to examine the effects of coadministration of fructose and bısphenol A on the testis tissue, adipocytokines in the this tissue and therapeutic effect of melatonin on possible damage.
For these purpose, forty-two pubertal male Wistar-albino rats were divided equally into seven groups. Groups are; Group 1:(n=6) Control (sesame oil+ethanol), Group 2: (n=6) Fructose Group (%10 D-Fructose), Group 3: (n=6) BPA Group (25mg/bw/day), Group 4: (n=6) F-BPA Group (%10 D-Fructose+BPA 25mg/bw/day), Group 5: (n=6) F-Melatonin Group (20 mg//bw/day), Group 6: (n=6) BPA-Melatonin Group, Group 7: (n=6) F-BPA-Melatonin Group. At the end of the experimental period, all rats were sacrificed and the testis tissue of rats were removed. Hematoxylin-eosin staining, Leptin and Adiponectin antibody immunohistochemical staining and TUNEL methods were performed. Fructose, BPA and Fructose+BPA cause testicular damage with decreased at diameter of the seminiferous tubule and seminiferous tubule epithelial thickness. The damage at Fructose+BPA group was much more than BPA while fructose group had minor damage than others. Mitochondrial membrane potential (Δψm) and Apoptosis (with Annexin V FITC apoptosis detection kit) at the testis were measured using Flow cytometry. The findings of apoptosis measurements support results of examination of the testis tissue using routine light microscope techniques.
Furthermore; In case of administration of Fructose, BPA and Fructose+BPA to rats, it is seen that the increases in lipid peroxidation levels in testis tissue depending on increased oxidative stress in this tissue. Melatonin has been found to induce testis tissue antioxidant enzyme activity at the positive direction and reduce the levels of lipid peroxidation.

Keywords: bisphenol A, fructose, melatonin, testis, adipocytokines, oxidative stress

Figure 2

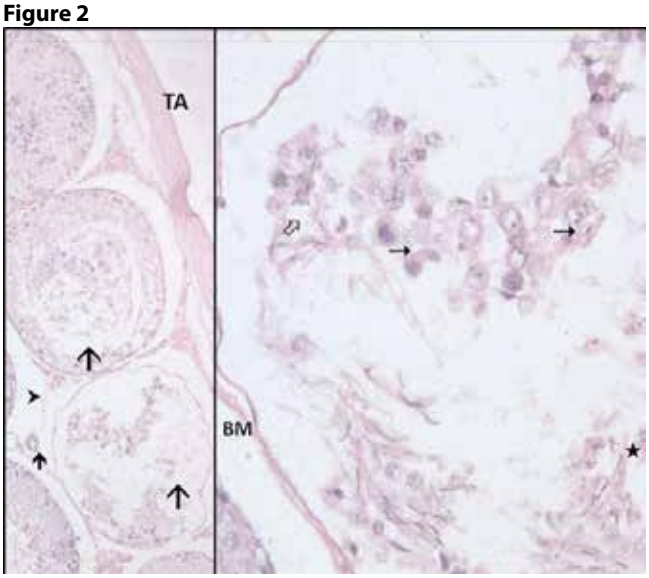

A-B: Fructose+BPA group, testis tissue H&E Tunica albuginea (TA), Seminiferous tubules (□), interstitial space (□), vascular structure (□), bazal menbrane (BM), germ cells (Ö), cell debris («), immature germ cells (□) ve interstitial space damage (t) (H&E x100, x400)

Figure 3

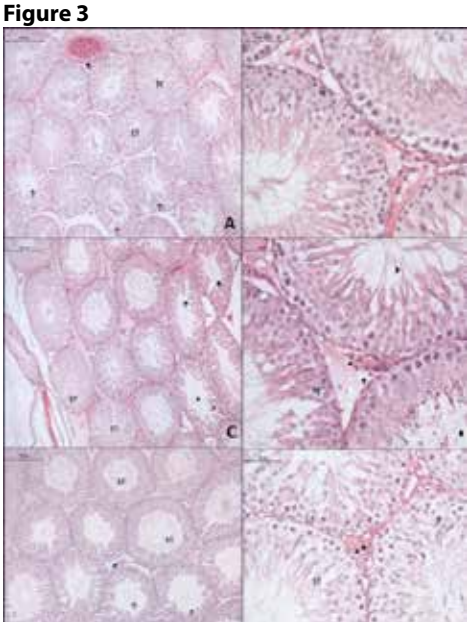

Figure 3: A.The testis of fructose+melatonin group (H&E, x100) B.The testis of fructose+melatonin group (H&E, x400) C. BPA+melatonin group (H&E, x100) D. BPA+melatonin group (H&E, x400) E. BPA group (H&E, x100) D. BPA group (H&E, x400) Seminiferous tubules (st), spermatogonia(sg), spermatozoa (ŧ), primer spermatocytes (¥), Sertoli cells (Ç) interstitial space(«), Leydig cells (<), myoid cells (M) vascular structure(<<) Tunica albuginea(TA), blood vessel (KD)

Figure 4

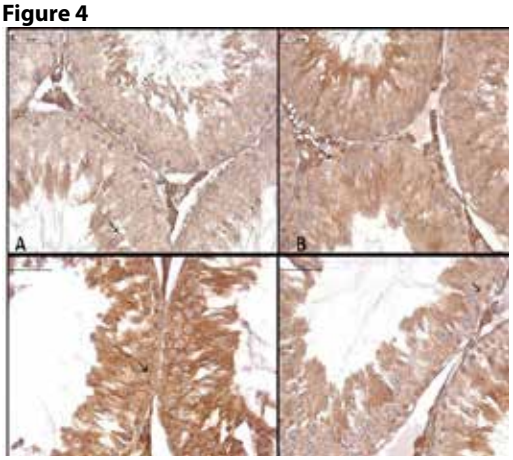

A:Control group, B: Fructose group, C: BPA group, D: Fructose-BPA group, ObR immunohistochemistry staining, Testis tissue (x400)

Figure 5

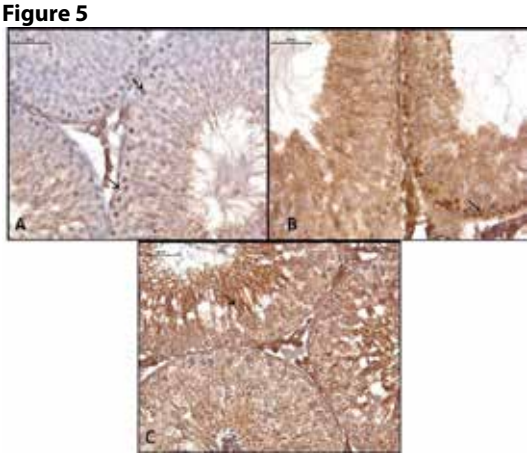

A:Fructose-Melatonin group, B: BPA-Melatonin group, C: Fructose-BPA Melatonin group, ObR immunohistochemistry staining, Testis tissue (x400)

Figure 6

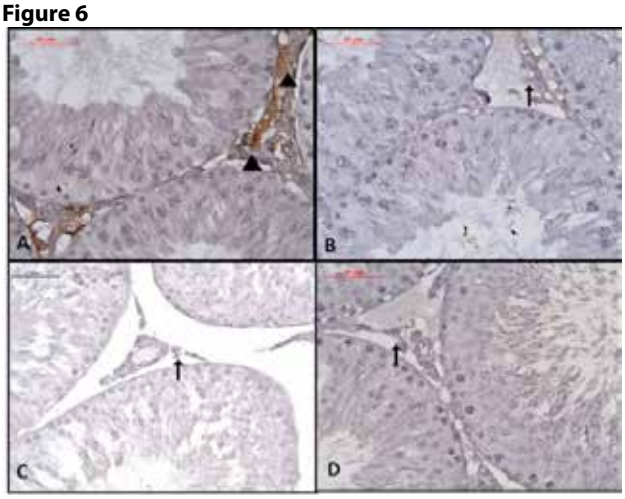

A:Control group, B: Fructose group, C: BPA group, D: Fructose-BPA group, AdR1 immunohistochemistry staining, Testis tissue (x400)

Figure 7

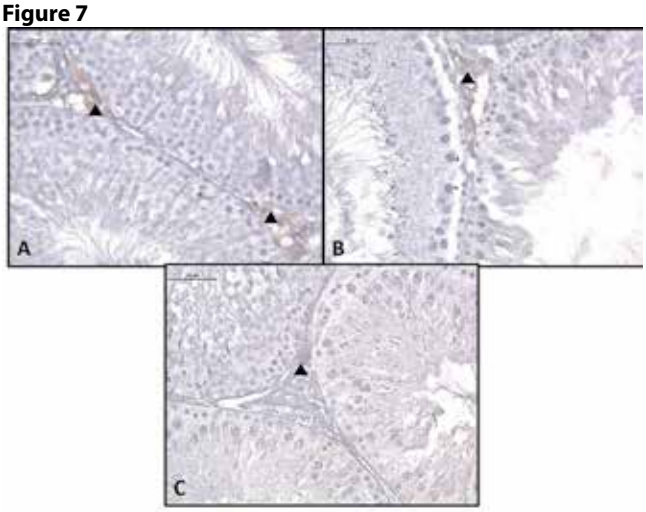

A:Fructose-Melatonin group, B: BPA-Melatonin group, C: Fructose-BPA Melatonin group, AdR1 immunohistochemistry staining, Testis tissue (x400)

Figure 1:

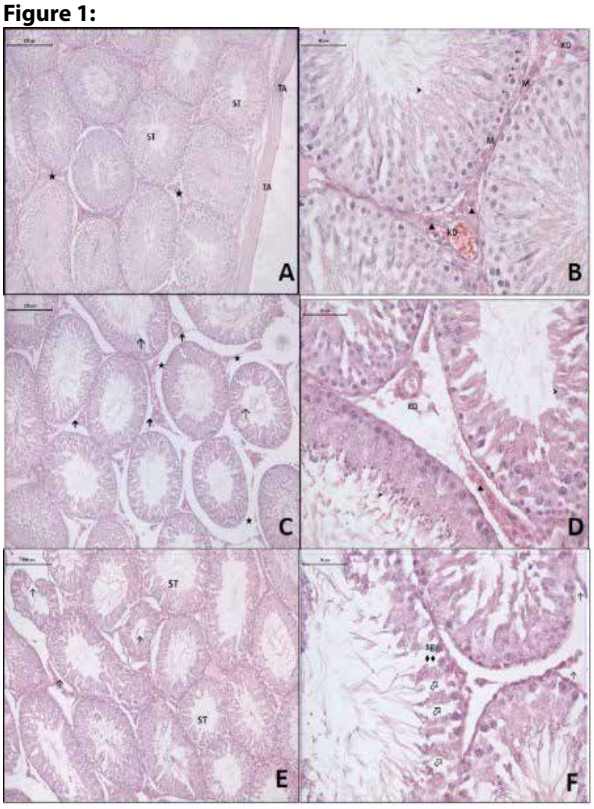

Figure 1: A.The testis of control group (H&E, x100) B.The testis of control group (H&E, x400) C. Fructose group (H&E, x100) D. Fructose group (H&E, x400) E. BPA group (H&E, x100) D. BPA group (H&E, x400) Seminiferous tubules (st), spermatogonia(sg), spermatozoa (ü), primer spermatocytes (¥), Sertoli cells (Ç) interstitial space(«), Leydig cells (<), myoid cells (M) vascular structure(<<) Tunica albuginea(TA), blood vessel (KD)

10.5505/2017ichc.PP-164 [Developmental and reproductive biology]

Morphological and Biochemical Evaluation of Protective Effects of Apocynin on Cisplatin-Induced Testicular Damage

M. Kutay Köroğlu[1], Özge Çevik[2], Göksel Şener[3], Feriha Ercan[1]

[1]Marmara University, School of Medicine, Department of Histology &Embryology, Istanbul, Turkey

[2]Cumhuriyet University, School of Pharmacy, Department of Biochemistry, Sivas, Turkey

[3]Marmara University, School of Pharmacy, Department of Pharmachology, İstanbul, Turkey

Cisplatin (CIS) is commonly used as a chemotherapeutic agent, however it is associated with numerous side effects such as reproductive cytotoxicity. It causes spermatogenic cell death and DNA damage in spermatozoa via formation of reactive oxygen species (ROS). NADPH-oxidase (NOX) is a major enzyme that uses NADPH to generate superoxide, initial ROS molecule, from oxygen. Apocynin (4-hydroxy-3methoxy-acetophenone, APO), naturally occurring methoxy substituted catechol, extracted from the roots of Apocynum cannabinum and Picrorhiza kurroa (Scrophulariaceae) is a well known inhibitor of NOX. The aim of this study is to investigate possible protective effects of apocynin in cisplatin induced testicular damage. Sprague Dawley rats were used in the study and experimental groups (n=7) were formed as: 1-control, 2-APO, 3-CIS and 4-CIS+APO groups. Following a single dose of CIS (7mg/kg i.p.), either dimethyl sulfoxide (DMSO) or APO (25mg/kg, orally) was administered for 5 days. After decapitation of rats, testes were removed for histopathological and biochemical evaluation. The testis tissue samples were prepared for light and electron microscopical investigation in order to evaluate general histopathology and ultrastructure, proliferative and apototic cells, and localization of NOX2. In order to examine oxidative tissue injury, 8-hydroxy-2-deoxyguanosine (8-OHdG), malondialdehyde (MDA), glutathione peroxidase (GSH), and superoxide dismutase (SOD) levels were analyzed biochemically. Data were analyzed statistically. Increased degenerated and atrophic tubules, apoptotic and NOX2 immunoreactive cells, numerous large vacuoles in the cytoplasm of spermatogonial and Sertoli cells and dilatation of intercellular tight junctions and decreased proliferative index were observed in CIS group compared to controls. Morphological parameters were ameliorated in CIS+APO group and smaller vacuoles in the cell cytoplasm and less dilatation of intercellular tight juctions were observed. While MDA and 8-OHDg levels and MPO activity were significantly increased, GSH and SOD levels were significantly decreased in CIS group compared to controls. All biochemical parameters were ameliorated in CIS+APO group when compared to CIS induced rats. In conclusion, cisplatin causes testis damage by decreasing spermatogenic cell line and increasing apoptosis and NOX2 activity via formation of oxidative stress, and apocynin prevents testis damage by its possible antioxidant effects.

Aknowledgement: This study was supported by Marmara University Research Fund (SAG-C-YLP-090414-0076).

Keywords: Cisplatin, Apocynin, Testis, Apoptosis, Cell Proliferation, NOX2

10.5505/2017ichc.PP-165 [Developmental and reproductive biology]

Ameliorative potentials of a combination of fenugreek and alpha-tocopherol on cadmium induced testicular toxicity: an ultrastructural study

Adel M. Hussein, Hesham N. Mustafa, Mohamed H. Badawoud
Anatomy Department, Faculty of Medicine, King Abdulaziz University, Jeddah, Saudi Arabia

BACKGROUND: The current study aimed to elucidate the protective role of combined fenugreek and a-tocopherol against cadmium induced histopathological changes in the testes.
MATERIALS-METHODS: Thirty adult male albino rats divided into three equal groups 10 rats each. Group I is the control group. Group II received 5 mg/kg/ day cadmium chloride. Group III received 5 mg/kg/day cadmium chloride and 150 mg/kg/day fenugreek and 100 mg/kg/ day of a-tocopherol. The treatment of all groups was done by oral gavage for 60 consecutive days. The testes were removed and subjected to histopathological and ultrastructure study.
RESULTS: Rats exposed to cadmium showed severe histopathological changes in the testicular spermatogenic series, many vacuoles and multinucleated giant cells. Treatment with fenugreek and a-tocopherol partially improved the morphological changes, reduced tissue damage and rebuilt of the spermatogonia layer.
CONCLUSIONS: Fenugreek and a-tocopherol might represent a promising medicinal combination to ameliorate the toxic effects of cadmium exposure.

Keywords: cadmium, fenugreek, ultrastructure

Figure 1

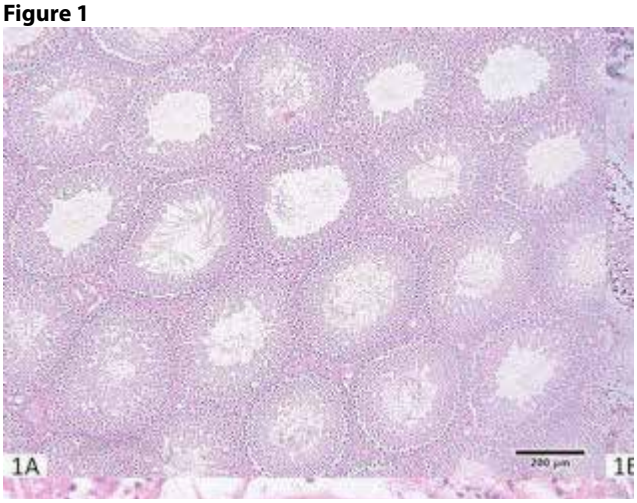

Fig. (1A): Photomicrograph of the control group. Fig. (1B): Group received CdCl2 showed vacuolation (V) with spermatogonia separated from the basal lamina (<) and a widening of the interstitial spaces (W). Fig. (1C): Higher magnification showed multinucleated giant cells (G) and congestion of the capillaries (C). Fig. (1D): Group received CdCl2 and combined fenugreek and α-tocopherol showed restoration of the spermatogonia near the basal lamina (<) and a decrease of the widening. (1A,B,D Scale bar, 200µm) (1C Scale bar, 50µm).

Figure 2

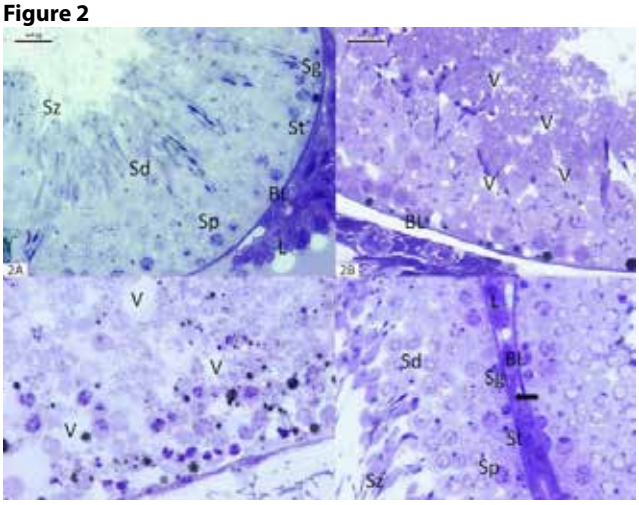

Fig. (2): Photomicrograph of a semithin section of a testis of a rat (2A). Control group. Note Sertoli cells (St), Spermatogonia (Sg), basal lamina (BL),

spermatocytes (Sp), spermatid (Sd), spermatozoa (Sz). (2B) Group received CdCl2 showed vacuolations (V). (2C) showed depletion, extensive vacuolization (V) of the germinal epithelium. (2D) Group received combined fenugreek and α-tocopherol with CdCl2 shows improvement of the epithelial layers. Note myoid cell (<), interstitial Leydig cells (L). (Scale bar, 20µm).

Figure 3

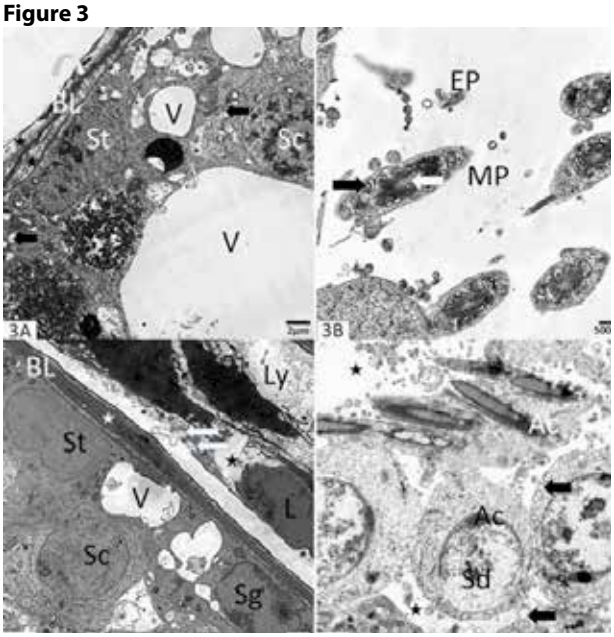

Fig. (3). An electron micrograph of a testis of the CdCl2 treated group. Fig. (3A). Sertoli cell (St) and primary spermatocyte (Sc) is separated by spaces (white star) and vacuolated mitochondria (black arrows). Vacuoles (V) and thickened basal lamina (BL) containing collagen (black star) and a myoid cell (curved arrow). Fig. (3B). Mid-piece of the sperm (MP) with swollen mitochondria (black arrow) surrounds the central axoneme (white arrow). End pieces (EP). Fig. (3C). Leydig cell (L), vacuoles (V), an empty space (black star), lymph vessels (Ly) and vacuolated mitochondria (white arrow). The spermatogonia (Sg) and the Sertoli cell (St) and thickened basal lamina (BL) with a myoid cell (star), primary spermatocyte (Sc). Fig. (3D). Spermatids (Sd) with mitochondria with lost cristae (black arrow) and acrosomal cap (Ac). Empty spaces (star) are all around (6A,C,D Scale bar, 2µm) (6B Scale bar,500nm).

Figure 4

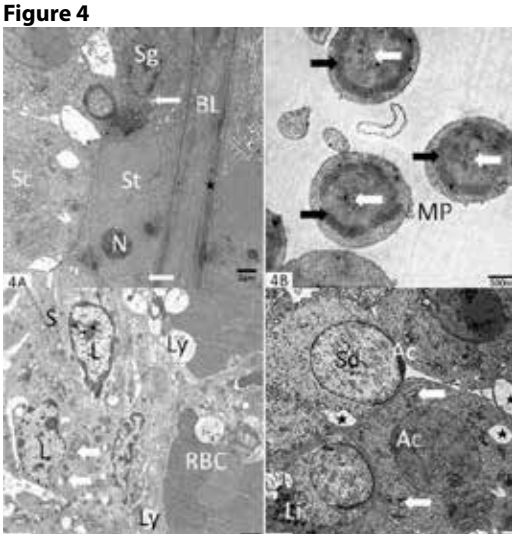

Fig. (4). An electron micrograph combined fenugreek and α-tocopherol and CdCl2 Fig. (4A). Sertoli cell (St) with a nucleolus (N) and the spermatogonia (Sg) on the thickened basal lamina (BL) with myoid cell (black star). Mitochondria (arrow) and primary spermatocyte (Sc) noticed. Fig. (4B). Mid-pieces (MP) with axoneme (white arrow) and a mitochondrial sheath (black arrow). Fig. (4C). Leydig cells (L), multiple lysosomes (S) and mitochondria (arrow) and Lymph vessels (Ly). Fig. (4D). The Spermatids (Sd) with mitochondria with preserved cristae (arrow) and acrosomal cap (Ac). Minimal empty spaces (star) in the affected intercellular bridge and lipid droplets (Li). (7A,C,D Scale bar, 2µm) (7B Scale bar,500nm).

Table 1. Mean testes weight and body weight

	Body weight [g]	Testis weight [g/100 g]
Control (n = 10)	210.40 ± 3.062	0.73 ± 0.036
CdCl 2 (n = 10)	199.5 ± 0.028* P < 0.001	0.61 ± 0.084* P < 0.001
Combined fenugreek and a-tocopherol with CdCl 2 (n = 10)	208.10 ± 0.994 P < 0.128	0.68 ± 0.030 P < 0.139

Values are expressed as a mean ± standard deviation. The analysis was conducted using one-way ANOVA followed by Tukey's post-hoc test.

Table 2. Mean diameter of seminiferous tubules (MSTD) and germinal epithelial height

	Control (n = 200)	CdCl 2 (n = 200)	Combined fenugreek and a-tocopherol (n = 200)
Tubular diameter (MSTD) [µm]	253.427 ± 17.536	240.256 ± 29.926 P < 0.0001*	246.223 ± 34.145 P < 0.029*
Seminiferous epithelium height [µm]	76.502 ± 5.549	70.066 ± 8.319 P < 0.0001*	73.333 ± 7.962 P < 0.0001*

*Values are expressed as a mean ± standard deviation. The analysis was conducted using one-way ANOVA followed by Tukey's post-hoc test.

Table 3. Mean area percentage of CD3, CD20, and CD68 immunostaining

Area %	Control (n = 10)	CdCl 2 (n = 10)	Combined fenugreek and a-tocopherol (n = 10)
CD3	0.031 ± 0.027	0.090 ± 0.049 P < 0.014*	0.056 ± 0.060 P < 0.553
CD20	0.050 ± 0.022	0.091 ± 0.040 P < 0.033*	0.060 ± 0.026 P < 0.692
CD68	0.058 ± 0.028	0.139 ± 0.080 P < 0.034*	0.106 ± 0.073 P < 0.213

*Values are expressed as a mean ± standard deviation. The analysis was conducted using one-way ANOVA followed by Dunnett's T3 test post-hoc test.

10.5505/2017ichc.PP-166 [Developmental and reproductive biology]

Expression of Interleukin 6 and Tumor Necrosis Factor Alpha in Endometriotic Tissues: An Immunohistochemical Study

Sait Polat[1], Nimet Fulya Furucu[1], Leman Sencar[1], Turan Çetin[2], Derya Gümürdülü[3], Ibrahim Ferhat Ürünsak[2]

[1]Department of Histology and Embryology

[2]Department of Obstetric and Gynecology

[3]Department of Pathology

Endometriosis occurs in about 10-15 % of women in reproductive age and incidence of the disease is up to 50 % in patients which suffers from chronic pelvic pain, dysmenorrhea and infertility. Although endometriosis is one of the most investigated disease of gynecology, its pathogenesis is still not clear completely. Tumor necrosis factor alpha (TNF-α) is the most effective proinflammatory cytokine produced in response to tissue injury and chronic inflammation. Interleukin 6 (IL-6) is another cytokine involved in the regulation of inflammation reactiones and immune system, cell differentiation, cell proliferation, hemopoiesis and tumorigenesis. Inspite of the studies done so far shows that TNF-α and IL-6 presence in patient with endometriosis, there was no comparative immunohistochemical studys hows the presence of these cytokines in normal and endometriotic tissue and the distribution in the cell types. In this study it is aimed to investigate TNF-α and IL-6 expressions of normal and endometriotic tissues in the human by immunohistochemical methods. Tissue sections that were examined in this study obtained from tissue biopsies of ectopic endometriums taken from 24 women between the ages of 20-40. Additionally, the tissue sections taken from the normal endometrium obtained from 10 patients without any endometrial dysfunction due to dilation or curettage are also evaluated as a control group. It was observed that TNF-α and IL-6 expressions are at varying levels from weak to moderate in the control groups in surface and glandular epithelium. However there is no evidence of a significant staining of the stromal cells. It is found that TNF-α and IL-6 immunoreactivity is significantly increased in the epithelial cells, stromal cells and macrophages which are in endometriotic tissues when these immunoreactivity rates in control endometrium are compared. Expression of TNF-α and IL-6 are both strong in ectopic endometrial tissues. This situation give rise to the tought of the two cytokines may have the same, parallel effects during the process of pathogenesis and development of the disease. When we evaluated the results together, we achieved the conclusion that bothTNF-α and IL-6 are important cytokines that involved in the pathogenesis of the endometriosis.

Keywords: Endometriosis, Immunohistochemistry, IL-6, TNF-α.

10.5505/2017ichc.PP-167 [Developmental and reproductive biology]

Pendrin and sodium / iodide symporter (NIS) protein expression in testicular tissue of diabetic rat*

Turan Karaca, Selim Demirtas, Duygu Uzun Gören
Department of Histology and Embryology, Trakya University, Edirne, Turkey

Introduction & OBJECTIVES: Pendrin (PDS) and sodium/iodide symport (NIS) is a transmembrane protein that found in many tissues, especially the thyroid follicular cells. These proteins are transmembrane proteins that attendant in the regulation of iodine in the thyroid follicular cells.
Materials & METHODS: In this study, prepubertal and adult rat testes tissue the PDS and NIS proteins, the apoptosis and proliferation were aimed to clarify in the diabetic rats. Fourty Wistar albino male rats (20 prepubertal and 20 adult) were divided into four groups; Group I: Control prepubertal group (30 days), Group II: Diabetic prebupertal group (30 days, 60 mg/kg streptozotocin (STZ, intraperitoneal (i.p.), group III: Control adult (8-10 weeks), and Group IV: Diabetic adult (60 mg/kg STZ, i.p.).
RESULTS: In prepubertal diabetic group (group I) testicular weight, testicular width and length significantly decreased compared with control diabetic group (Group II) ($P<0.05$). Adult testosterone levels in the diabetic group decreased significantly compared to the adult control group. Ki-67 immunoreactivity in prepubertal and adult both decreases in the diabetic groups, but apoptotic tubules index and the number of apoptotic cells increased in the diabetic groups compared to the controls. PDS immunoreactivity was detected in the seminiferous tubules and Leydig cells and decreased significantly in the diabetic group ($P<0.05$). The immunohistochemical analysis showed that NIS wes expressed only in Leydig cells of both control and diabaetic rat testis. The number of NIS positive cells were significantly decreased in prepubertal and adult diabetic groups compared with controls. ELISA analysis was performed that PDS and NIS expressions was significantly decreased in prepubertal diabetic group compared with prepubertal control rats, and adult diabetic group compared with adult control group rats.
CONCLUSIONS: These results suggest that PDS and NIS is expressed rat testis but expressed with lower in the diabetic individual.

*:This work was supported by Scientific and Technological Research Council of Turkey (TUBITAK-ARDEB-SBAG-115S689).

Keywords: Pendrin, sodyum/iodide symporter, diabetes mellitus, testis, rat

10.5505/2017ichc.PP-168 [Developmental and reproductive biology]

Effects of anti-Müllerian hormone expression on ovary morphology and folliculogenesis in different age groups of female rats

Gizem Söyler, Aysel Kükner
Department of Histology and Embryology, Abant Izzet Baysal University, Bolu, Turkey

INTRODUCTION: Ovarian follicles begin growing under the stimulation of Follicle Stimulation Hormone (FSH). Pregranulosa cells which produce primordial follicles, turn to granulosa cells and form primer follicles. Granulosa cells synthesize different types of hormones like estradiol, progesteron, inhibin-B, and anti-müllerian hormone (AMH) for development of oocytes (1).
Anti-Müllerian Hormon has an important role for recruitment of the follicles. AMH has been synthesised from primer follicles from birth, and provides growing of granulosa cells in order to increase the follicle size. Moreover, AMH repress the FSH activity and restricts entry early menopause. Therefore, AMH provide long life for follicles. AMH expression reaches the highest level in puberty and gets uncountable level in serum with menopause (2).
In this study, the effects of AMH expression was examined in ovarian morphology and folliculogenesis in different age grouped rat ovaries.
Material METHODS: Female Wistar Albino Rats were used for this experiment. Five different groups were detected according to animals age as 1, 2, 8, 15, 24 months. Each group consist of six individuals which were selected randomly. Rat oestrus cycle were detected by vaginal smear in reproductive 2, 8, 15 months rats and proestrus phase animals were anaesthetized with other individuals. Anaesthesia was made with xylasine and ketamine. Ovaries were collected into the neutral formaline.
After histological preparations, tissues were embedded in parafin blocks. Serial sections were taken in 5 microns. Hematoxylin and eosin staining were used for routine examination, and to observe AMH expression, immunohistochemical process was followed. Follicle count and AMH staining were evaluated under the light microscope.
RESULTS: According to age, significant differences were found in follicle count between the groups. Also, significant differences were found in AMH staining evaluation between the follicle types. However, we didn't see any difference in the amount of AMH expression between the same type of follicles depending on age.
References:1. Matsuda F, et al. Follicular growth and atresia in mammalian ovaries: Regulation by survival and death of granulosa cells. Journal of Reproduction and Development 2012; 58:44-50
2. Visser JA, Themmen APN. Anti-Müllerian hormone and folliculogenesis. Molecular and Cellular Endocrinology 2005; 234 81-86
This study is supported by Abant Izzet Baysal University, Scientific Research Projects. Project No.: 2016.08.03.1080

Keywords: Anti Müllerian Hormone, Ovary, Folliculogenesis

Figure 1

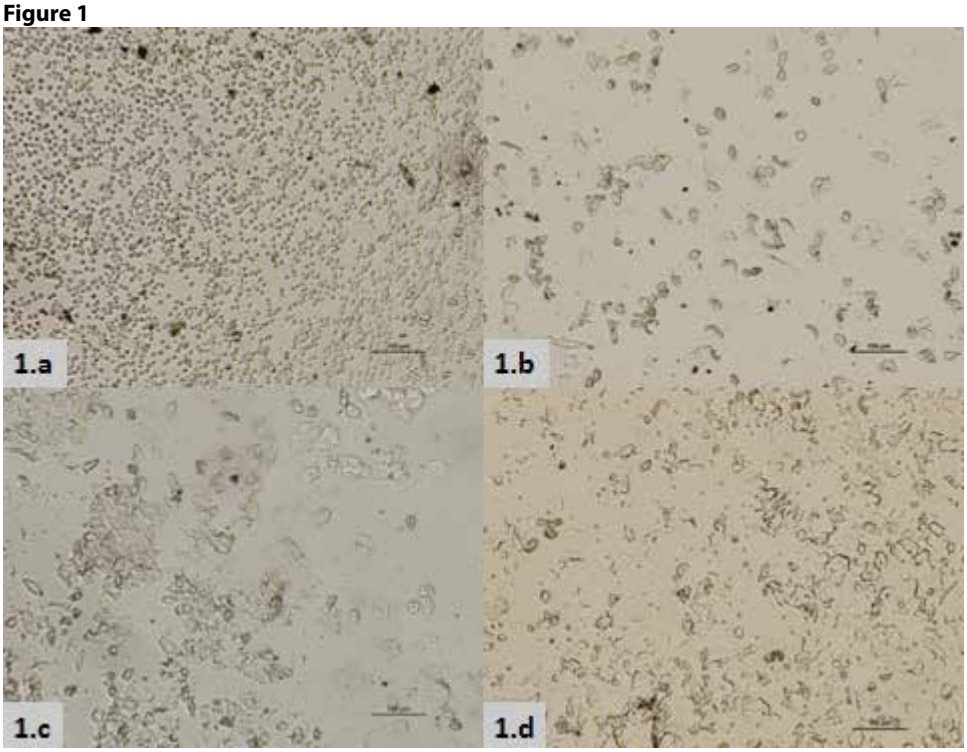

Vaginal smear to determine oestrus cycle phases under the light microscope, without any staining (10X). 1.a: Dioesturs Phase; highly amount of leukocyte cells. 1.b: Proestrus Phase; intensive amount of epithelial cells with cornified cells. 1.c: Oestrus Phase; highly amount of cornified cells. 1.d: Metoestrus Phase; almost equal amount of leukocyte, cornified and epithelial cells.

Figure 2

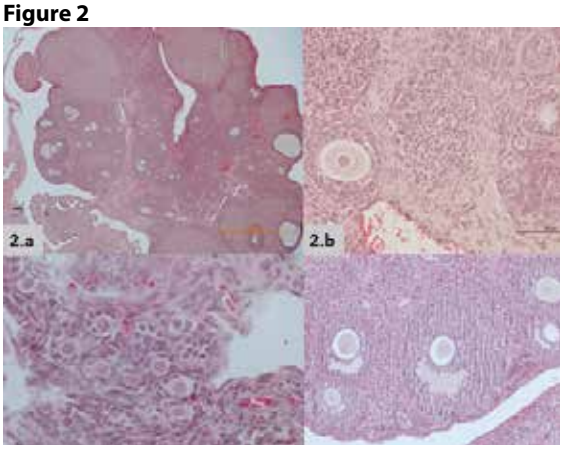

Hematoxyline and eosin staining of ovary. 2.a: 2 month rat ovary (2X) 2.b: 2 month rat ovary (20X) 2.c: 1 month rat ovary primordial follicle pool (40X) 2.d: 2 month rat ovary follicles (10X)

Figure 3

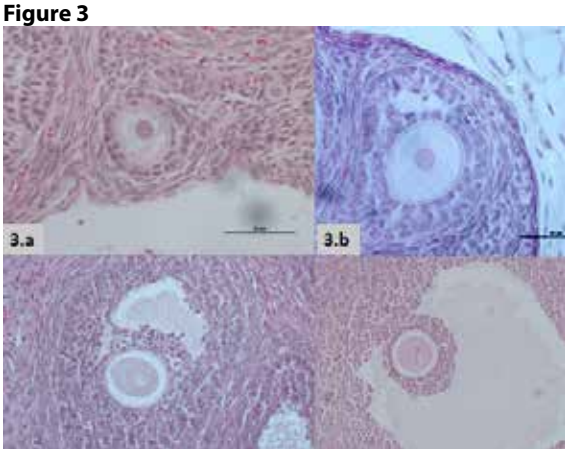

Hematoxyline and eosin staining. 3.a: 1 month rat ovary, primer follicle (20X). 3.b: 2 month rat ovary, preantral follicle (40X). 3.c: 2 month rat ovary, seconder follicle (20X). 3.d: 1 month rat ovary, tertiary follicle (20X).

Figure 4

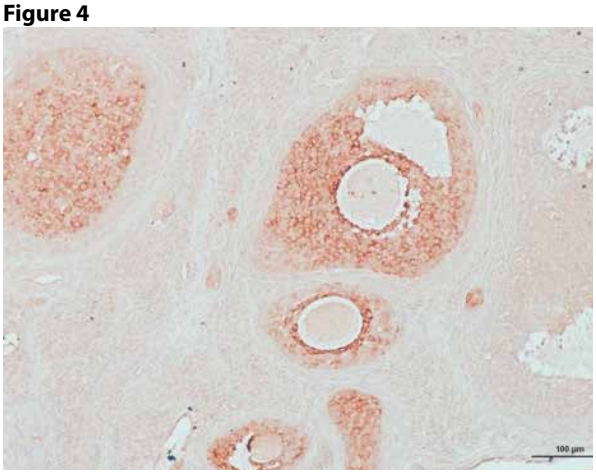

Immunohistochemical AMH staining on 2 month rat ovary (10X).

10.5505/2017ichc.PP-169 [Developmental and reproductive biology]

A histological map of neotenic and metamorphosed axolotl's tissues and organs

Berna Yildirim[1], Ayse Elif Ilhan[1], Ilknur Keskin[2], Turan Demircan[3]

[1]Regenerative and Restorative Medicine Research Center, REMER, Istanbul Medipol University, Istanbul, Turkey

[2]Department of Histology and Embryology, School of Medicine, Istanbul Medipol University, Istanbul, Turkey

[3]Department of Medical Biology, International School of Medicine, Istanbul Medipol University, Istanbul, Turkey

Axolotl (Ambystoma mexicanum) is a salamender species which has a unique regenerative capacity. It is normally a neotenic organism but has the ability to be induced to metamorphosis by the administration of thyroid hormones (THs). This opens the possibility of working with both neotenic and metamorphic stages of the same animal. Anatomical and morphological changes during metamorphosis are very crucial to expand our currenting understanding on adaptation to terrestrial life. Till now there was not any comphrensive histological studies regarding neotenic and metamorphic axolotl. Here, in this study, we aimed to exhibit the differences between neotenic and metamorphic axolotl tissues. Axolotls were maintained as one axolotl in each container and half of the axolots were induced to metamorphose using the T4 containing solution. Tissues and organs of metamorphic and neotenic axolotls were obtained by dissection. We carried out Hematoxylin & Eosin, Luxol-Fast Blue, Masson's Trichrome, Alcian Blue, Orcein and Weigart's staining to demonstrate the structural differences of all tissues and their cellular organization. We examined the specimens of brain, gallbladder,heart, intestine, liver, lung, muscle, skin, spleen, stomach, tail, tongue and vessel under the light microscopy. According to our data, mainly in tail, skin, gall bladder and spleen, but also in other tissues and organs structural changes were observed.

Keywords: Axolotl, Histological map, Thyroid hormone

10.5505/2017ichc.PP-170 [Developmental and reproductive biology]

Relationship Between Leptin Molecule and Effects of Cryopreservation on Sperm Motility and DNA Fragmentation

Tugce Onel[1], Şule Ayla[1], Ilknur Keskin[1], Cüneyd Parlayan[2], Türkan Yiğitbaşı[3], Bircan Kolbası[1], Tuba Varlı Yelke[4], Tuğba Şenel Ustabaş[4]

[1]Department of Histology and Embryology, REMER(Regenerative and Restorative Medicine Research Center), Istanbul Medipol University, Istanbul, Turkey

[2]Department of Biomedical Engineering, REMER, Istanbul Medipol University, Istanbul, Turkey

[3]Department of Medical Biochemistry, REMER, Istanbul Medipol University, Istanbul, Turkey

[4]In Vitro Fertilization Unit (IVF), Medipol International Health Center, Istanbul, Turkey

Radiotherapy, chemotherapy, various tumors and invasive surgery can result in ejaculatory dysfunction and testicular insufficiency. Sperm cryopreservation is the only method which can provide have a baby for couples. Cryopreservation freezes tissues and cells and allowing them to be stored for future use by stopping all biological activities. Cryopreservation can cause some harmful changes in the structure and function of the sperm. Leptin molecule plays many roles in most biological processes including the satiety and cell renewal, proliferation, angiogenesis, modulation of energy expenditure, regulation of the neuroendocrine system. Leptin was also reported to be assosiated with spermatogenesis in several studies. This study aims to use of leptin molecule as a for sperm motility and DNA fragmentation parameters before and after the cryopreservation. In this study, semen samples were taken from 30 normospermic male volunteers. Each semen sample is examined for the same paremeters before and after the cryopreservation. Samples were analyzed before and after cryopreservation in terms of sperm motility, morphological sperm analysis with spermac stain dye DNA fragmentation by TUNEL assay, ultrastructural analysis with transmission electron microscopy (TEM), seminal leptin levels by ELISA method, reactive oxygen species (ROS) levels by colorimetric method. Decreased sperm motility, distribution of sperm morphology and increased DNA fragmentation were determined after cryopreservation. Similarly, seminal ROS and leptin levels are also increased significantly. There was a negative correlation between seminal leptin and sperm motility. Additionally, there was a positive correlation between seminal leptin and DNA fragmentation. According to these results, leptin molecule can be used as a marker for sperm motility and DNA fragmentation before and after cryopreservation. We think that the results of this study can contribute to further studies in the clinical aspect.

Keywords: cryopreservation, DNA fragmentation, leptin, motility, sperm.

10.5505/2017ichc.PP-171 [Developmental and reproductive biology]

Investigation Of Protective Effect Of Caffeic Acid Phenethyl Ester On Testicular Damage Which Was Caused By Cisplatin

Tayfun Ceylan[1], Emin Kaymak[1], Betül Yalçın[1], Fazile Cantürk Tan[2], Birkan Yakan[1]

[1]Depatment of Hsitology and Embriyology, Erciyes University, Kayseri, Turkey

[2]Depatment of Biophysics, Erciyes University, Kayseri, Turkey

Cisplatin (CP), anticancer drug induces cytotoxicity in healthy tissues. Also cisplatin induces reactive oxygen species and induces apoptosis, inhibiting antioxidant enzymes. Gonadotoxicity is one of the side effects (1-4).
Caffeic acid phenethyl ester (CAPE) is Is a component of propolis, a honey bee product (5). Cape used in traditional medicine. CAPE has protective properties for many tissues, has antiviral, anti-inflammatory, immunomodulatory, and antioxidant proporties. CAPE inhibits lipid peroxidation, lipoxygenase and cyclooxygenase enzymes (6-10).
The aim of this study has been to evaluate the effects of caffeic acid phenethyl ester on testicular damage induced by cisplatin.
Experiment consisted of 40 adult Wistar albino rats, each weighing 200–250 g. Group I served as control and received no drug or agent. Group II received CP intraperitoneally at 7mg/kg for 7 th day. Group III received CAPE 10 µmol/kg /day for 10 days. Group IV received intraperitoneally at 7mg/kg for 7 th day plus CAPE 10 10 µmol/kg /day for 10 days. Testis tissues were processed histopathologically for evaluation of testis injury (testicular Johnsen scores). Anti-oxidant enzymes such as superoxide-dismutase, catalase and the level of malondialdehyde were studied in the testicular tissues of rats with enzyme-linked immunosorbent assay (ELISA). Serum levels of testosterone were studied using ELISA.
In the CP group, tubular biopsy score of Johnsen were decreased compared control group. Furthermore, the CAPE treated group showed an improved histological appearance in the CP group.
Activities of SOD and CAT in testicular tissues were increased by CP+CAPE and CAPE groups compared control group, but tissue MDA levels was higher than control group. MDA levels were decreased CAPE and CP+CAPE groups. Testosterone levels in CAPE and CP+CAPE groups increased when compared with control group.
Our results suggested that CAPE treatment provided protection against cisplatin toxicity. Following CAPE treatment with cisplatin-induced gonadotoxicity, SOD, CAT and testosterone levels increased, while MDA level and testis injury decreased in testis.

Keywords: Csiplatin, Caffeic Acid Phenethyl Ester, Gonadotoxicity

10.5505/2017ichc.PP-172 [Developmental and reproductive biology]

Altered expression of Ubiquitin proteasome pathway proteins in rat testis with metabolic syndrome

Sevil Cayli[1], Ayca Bilginoglu[2], Ebru Alimogullari[1], Ilkay Piskin[1], Hilal Nakkas[1]

[1]Department of Histology & Embryology, Ankara Yildirim Beyazit University, Ankara,Turkey

[2]Department of Biophysics, Ankara Yildirim Beyazit University, Ankara,Turkey

INTRODUCTION: Metabolic syndrome affects about 20–25% of worldwide population and is characterized by a combination of multiple alterations such as obesity, insulin resistance, dyslipidemia, and hypertension. In male, metabolic syndrome is associated with sexual dysfunction, hypogonadotropic hypogonadism and some infertility problems. However, the mechanisms and the metabolic features responsible for alterations of spermatogenesis and sperm characteristics are not fully disclosed. In particular, no studies have addressed the role of the Ubiquitin proteasome pathway's (UPP) proteins in metabolic syndrome.We aimed to investigate the relationship between metabolic sendrome features and expression of UPP proteins (p97/VCP and SVIP) in rat testis.
MATERIAL-METHODS: Male Wistar rats divided into two groups such as metabolic syndrome group and control group. Metabolic syndrome was induced by providing drinking water that was 32% sucrose, for 18 weeks. All of the animals were exposed to a 12 h light – 12 h dark cycle. Abdominal obesity and glucose intolerance had measured as a marker of metabolic syndrome (data not shown).
After sacrification of animals from each group, testicular tissues were snap-frozen in liquid nitrogen and stored at -80°C for Western blotting and embedded in paraffin for immunohistochemistry. H SCORE analysis was used to evaluate the immunohistochemistry results.
RESULTS: In the Metabolic syndrome group, high sucrose intake, as well as the normal daily diet, significantly increased body mass and blood glucose level of the rats, as compared with the non-treated control group. Compared with the control testis, the expression of p97/VCP and its interacting protein, SVIP were significantly increased in the rat testis with metabolic sendrome according to Western blotting and immunohistochemistry. Although the expression of UPP protein expression in rat testis were effected by metabolic sendrome, seminiferous tubules morphology showed no significant differences demonstrating the completion of spermatogenetic activity for both groups. According to immunohistochemistry results p97/VCP immunopositivity was mainly observed in Sertoli cells and spermatogenetic cells, while SVIP immunopositivity was only observed in spermatids in both groups.
CONCLUSION: Our results indicate that development of metabolic syndrome leads to alterations in the expression of UPP proteins in rat testis.

Keywords: metabolic syndrome, p97/VCP, rat, SVIP, testis

10.5505/2017ichc.PP-173 [Developmental and reproductive biology]

The Role of Curcumin as an Antioxidant on Ovary Tissue Changes of Benzo(a)Pyrene Applied Rats

Simge Celebi[1], Deniz Erdogan[1], Gulnur Take Kaplanoglu[1], Cigdem Elmas[1], Iskender Kaplanoglu[2], Cemile Merve Seymen[1]

[1]Department of Histology and Embryology, Gazi University, Ankara, Turkey

[2]Etlik Zübeyde Hanim Women's Health Teaching and Research Hospital, Center of Assisted Reproduction, Ankara, Turkey

Polycyclic aromatic hydrocarbons (PAH) are organic compunds that shaped on incomplete oxidation period of organic substances such as coal, petrol, gas, wood, cigarette smoke and barbecued meat. Benzo(a)Pyrene(BaP) is one of the polycyclic aromatic hydrocarbons and it has more than 100 varieties in the nature. We want to investigate, the protective effects of Curcumin as an antioxidanton on potential BaP damages on ovary.
36 female Wistar Albino rats were used and subjects were divided into 6 groups in test. Benzo (a) Pyrene (10mg/kg/days) was solved in maize oil but DMSO was used as a solvent for Curcumin (10mg/kg/days). Althougt we did not apply any chemicals to control group, other groups which are BaP, Curcumin, maize oil, BaP+Curcumin and DMSO, the chemicals were applied by gavage for 6 weeks. In daily basis experimental animals body weights were mesaured and saved. At the end of period the rats have been sacrificed under high dose anesthesia and their ovarian tissues were taken. Tissues weights were measured and saved and processed histological observation procedures. Cross sections taken for inspection hematoxyline-eosin dyes were applied. For immunohistochemical method apoptosis signal molecules Caspase-3 and Cytochrome c primary antibodies were used and cross sections images from light microscope were evaluated.
As results of test BaP application have an impact on the number of follicules noticeably Graaf follicle on ovary in a statistically significant decrease was detected. We saw that, the application of BaP, coused structural defects in ovarian tissue especially in zona pellucida, granulose and cumulus cells. In addition BaP application also caused to increase the number of atretic follicules. Beside this, the Curcumin which was used as a protective effects on ovary, we saw that; althougt it caused part of recovery on ovarian tissue, it has not completely protect the changes of some stromal degeneration to normal histological appears and we saw that it changes the strong immunreactivity of caspase 3 and sitocrom c in BaP groups to only mild reaction.
In conclusion, curcumin is an antioxidant that could be used potentially for inhibiting the effects of Benzo(a)pyrene, but it is not sufficient to prevent full protection.

Keywords: Benzo(a)pyrene, Curcumin, Ovary.

hematoxyline-eosin

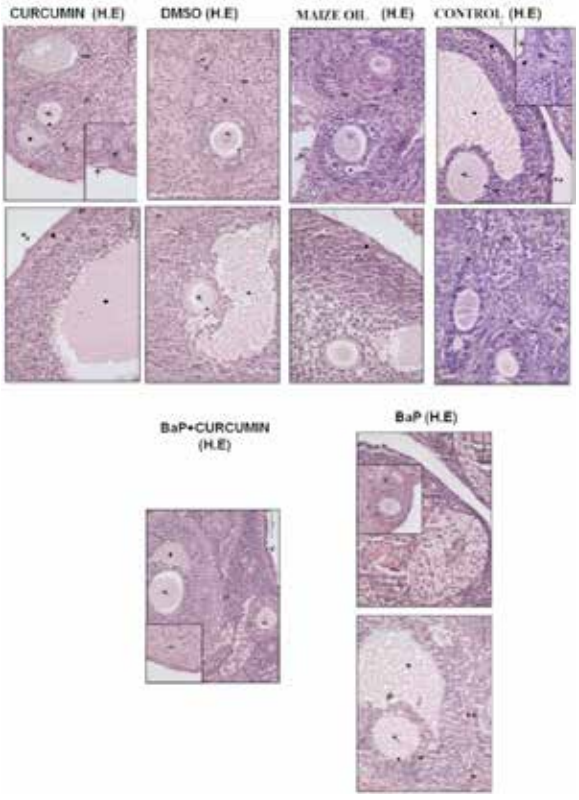

immunreactivity of caspase 3 and sitocrom c

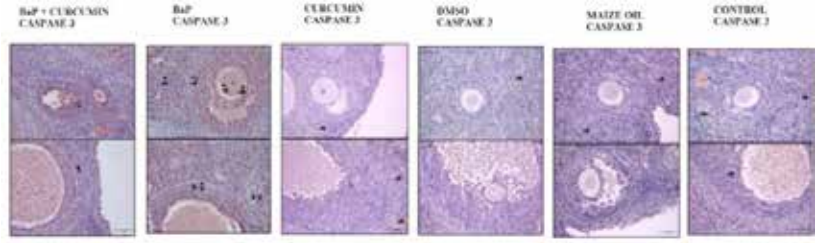

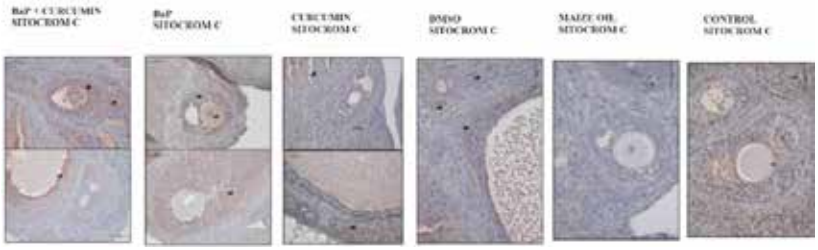

Statistical graphics of groups

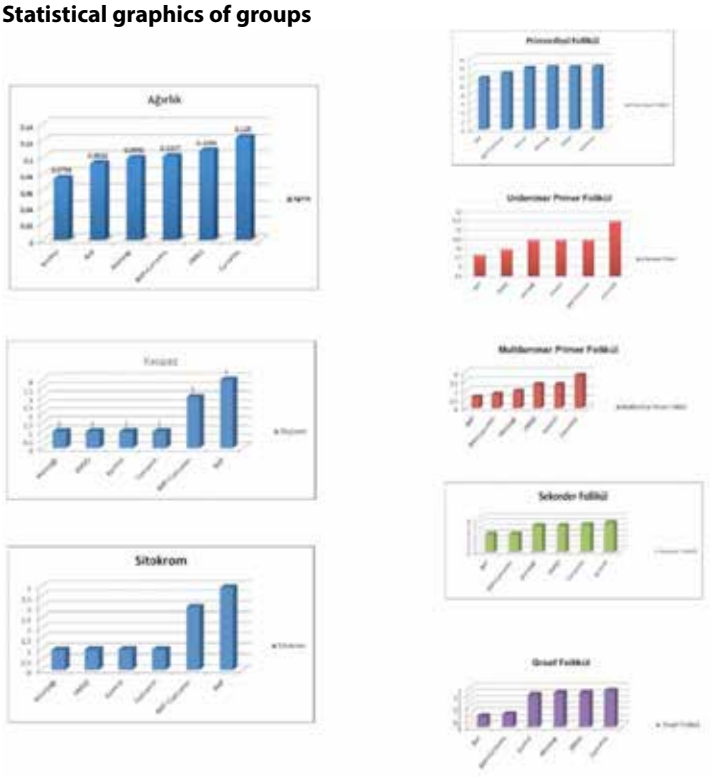

10.5505/2017ichc.PP-174 [Developmental and reproductive biology]

The effect of *Lycium barbarum* on testis tissue and sperm motility in experimentally diabetic male rats

Gizem Ilter Aktaş, Tülin Fırat
Department of Histology and Embryology, Abant Izzet Baysal University, Bolu, Turkey

INTRODUCTION & OBJECTIVES: In this study, we aimed to investigate the possibility of treatment with *Lycium barbarum* polysaccharides (LBP) for male reproductive system damages of diabetes.
MATERIALS & METHODS: Wistar albino male rats (3-4 months old) were randomly placed into 4 groups; negative control (n=6), positive control (only LBP) (n=6), Diabetic (STZ) group (n=9) and treatment (STZ+LBP) group (n=10). To generate experimentally diabetic rats, single dose of 55 mg/kg STZ was injected intraperitoneally. Rats were accepted as diabetic according to their blood glucose levels (at least 250 mg/dl). In the treatment group (STZ+LBP), the diabetic rats were administered with 200mg/kg of LBP by gastric gavage, once a day for 15 consecutive days. We have prepared *Lycium barbarum* polysaccharides from the fruit bodies. Sperm samples were obtained from epididymis by cutting the tissue gently in PBS solution. Makler counting chamber was used for semen analysis.
RESULTS: According to the routine histological stainings and light microscopic investigations, it can be seen that intertubular connective tissue was stained more specifically with Masson's trichrome stain in diabetic (STZ) testis. Furthermore, congestion was clear on blood vessels. The treatment (STZ+LBP) group was almost similar to negative control group (Fig. 1). Additionally, there were vacuole-like structures in diabetic group's testes (Fig. 2). Also sperm samples stained with Aniline blue can be seen (Fig. 3).
To evaluate the results of semen analysis, Kruskal Wallis and Mann-Whitney U tests were applied on SPSS Statistics programme, Version 21. Sperm motility frequencies were compared and $p<0.005$ was considered statistically significant. There was a significant difference between 4 groups (Table 1). The motility frequency in diabetic group was significantly decreased when compared to negative control (Table 2). In addition, the motility frequency was significantly increased in treatment group when compared to diabetic group (Table 3).
CONCLUSIONS: In conclusion, there was a significant increase for sperm motility in the treatment group, therefore *Lycium barbarum* polysaccharides (LBP) can be effective treatment for male reproductive system damages on diabetic patients.

Keywords: testis, sperm, diabetes, Lycium barbarum polysaccharides

Figure 1

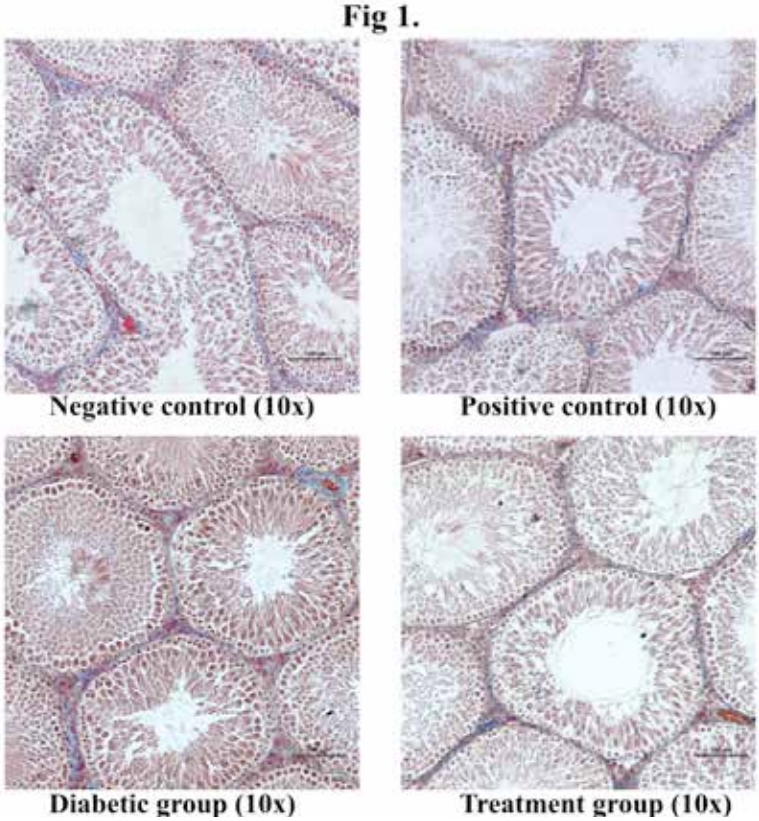

Intertubular connective tissue was stained more specifically with Masson's trichrome stain in diabetic (STZ) testis. Also, the treatment (STZ+LBP) group was almost similar to negative control group

Figure 2

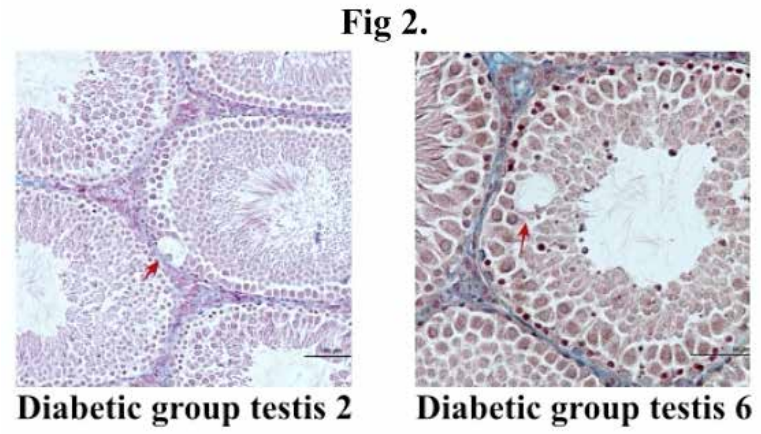

Vacuole-like structures in diabetic group's testes

Figure 3



Sperm samples stained with Aniline blue

Table 1. Comparing all groups for sperm motility frequencies

Groups	Mean Rank
Negative control	19,67
Positive control	16,33
Diabetic group	6,5
Treatment group	22,15

Kruskal Wallis test was applied. Asymp. significance: 0,001. (p<0,005)

Table 2. Comparison between diabetic and negative control group for sperm motility frequencies

Groups	Mean Rank
Negative control	12,5
Diabetic group	5

Mann-Whitney U test was applied. Asymp. significance: 0,000. (p<0,005)

Table 3. Comparison between diabetic and treatment group for sperm motility frequencies

Groups	Mean Rank
Diabetic group	5,5
Treatment group	14,05

Mann-Whitney U test was applied. Asymp. significance: 0,000. (p<0,005)

10.5505/2017ichc.PP-175 [Developmental and reproductive biology]

Investigation of Ameloriate Effect of Fulvic Acid on the Testicular Tissue of Rats Exposed to Water Avoidance Stress

Cansu Bahçıvan, Ibrahim Söğüt, Türkan Sarıoğlu, Canan Hürdağ, Esra Çikler Dülger
Department of Histology and Embryology, Istanbul Bilim University, Istanbul, Turkey

Introduction and OBJECTIVES: Stress-related infertility in the formation of oxidative stress, apoptosis and inflammation play an important role in organisms. Stress is the the body's automatic response given to various internal and external stimuli. The body of hypothalamic-pituitary- adrenal (HPA) axis is a relationship between the regulation of hormones. In response to stress, the activity of HPA axis and secretion of ACTH increases, whereas LH level decreases. Decreased LH level has an indirect effect on both testis seminiferous tubulles' Sertoli cells and germ cells. Chronic water avoidance stress is known to cause oxidative damage to testicular tissue. Oxidative damage is caused by reduced levels of antioxidants and reactive oxygen species (ROS) in the body.
Fulvic acid has antioxidant, antiapoptotic and antiinflammatory action by binding to regions bound by reactive oxygen species. This is the first study where the healing effect of fulvic acid on testicular tissue damage is examined.
MATERIALS-METHODS: 18 Sprague-Dawley (250-300 gr) male rats were used. In each experimetal group (3) with 6 animals. Control (K), Chronic Stress (KS) and Chronic Stress + Fulvic Acid (KS + FA). Histological sections obtained from testicular tissues of animals were stained with Hematoxylin & Eosin and Toluidine blue. Immunohistochemical marker of iNOS were performed. TAS / TOS, CAT, GPx and SOD levels were measured biochemically.
RESULTS: Histopathological examinations in the testis tissue sections revealed irregularity in the basal membrane and widenings between germinal epithelium in the seminiferous tubules in KS group. In the KS + FA group, improvement was observed in both the basal membrane and germinal epithelium. iNOS reactivity was primarily observed in spermatids. Biochemical findings supported our histological findings.
CONCLUSIONS: The therapeutic effect of fulvic acid was observed but not at a sufficient dosage. The use of higher doses of fulvic acid should reveal a more prevelant antioxidant effect.

Keywords: Antioxidant, Infertility, Spermatogenesis, Fulvic Acid, Water Avoidance Stress, Oxidatif Stress

10.5505/2017ichc.PP-176 [Developmental and reproductive biology]

Oxıdatıve Damage Of Chronıc Water Avoıdance And The Effect Of Fulvıc Acıd In Male Rat Tıssues Wıth Erectıle Dysfunctıon

Ezgi Yaprak, Ibrahim Söğüt, Türkan Sarıoğlu, Esra Çikler Dülger, Canan Hürdağ
Department of Hıstology and Embryology, İstanbul Bilim University, Istanbul, Turkey

Introduction and OBJECTIVES: Long-term stress exposure is defined as chronic stress and toxicity caused by the increase in reactive oxygen species (ROS) in tissues. Oxidative damage causes inflammation in the penile tissue. Decreased NO stimulates penile blood flow in the veins, a decrease in blood flow may result in erectile dysfunction. Fulvic acid is an organic molecule known to have antioxidant activity.
We aimed to utilize the antioxidant property of fulvic acid in our study to prevent penile tissue damage associated with erectile dysfunction. This study is the first research to be conducted in our country and in the world where fulvic acid is used in the treatment of erectile dysfunction, an important social problem, which is increasing as a vital stress condition affecting everybody today.
MATERIALS-METHODS: 18 Sprague-Dawley (250-300 gr) male rats were used in our study. Six animals in each group, in 3 groups: Control (K), Chronic Stress (KS) and Chronic Stress + Fulvic Acid (KS + FA). The penile tissues obtained from the experimental rats were examined by histochemical staining (Hematoxylin & Eosin, Masson-Trichrome and Toluidine blue), immunohistochemical (eNOS, nNOS and caveolin-1) were conducted and biochemical methods (TAS / TOS, CAT, GPx and SOD) amounts were measured.
RESULTS: Cavernous tissue specimens taken from KS group were examined, it was observed that trabecular endothelial cells are lost, collagen fibers had shrunk, connective tissue and smooth muscle distributions were unevenly distributed compared to the control group. When KS + FA group were examined, damage in the KS group showed considerable recovery in tissues that were treated. In KS group both eNOS and nNOS reactivity had decreased compare to the control group whereas caveolin-1 reactivity had increased. Furthermore the biochemical findings supports our end-point histochemical data.
CONCLUSION: The fulvic acid used was found to have therapeutic effects but the dosage used for treatment was not sufficient. In summary, we suggest to work at different but higher dosages to ensure that the therapeutic effect is achieved.

Keywords: Erectile dysfunction, water avoidance stress, oxidative stress, infertility, fulvic acid

10.5505/2017ichc.PP-177 [Developmental and reproductive biology]

Comparative Investigation of Structure of Male Genital System of Ductus Deferens Ligation in Rats

Hazal Demir Yarar
Department of histology,Çukurova University,Adana,Turkey

OBJECTIVE: Vasectomy is reliable and popular male contraception method, applied widely in the world and in recent years vasectomies has been increasing interest. Many studies are carried out to examine the damage and the changes that occurred after vasectomy.In our study, pre-pubertal and pubertal period in rats with unilateral ligation of the ductus deferens later, testis and ductus deferens, structural and morphological changes occurring in the tissues was aimed to investigate.
MATERIAL-METHODS: In the experimental study, 6 male pre-pubertal and 6 male pubertal Wistar albino rats were used and the subjects were divided into four groups. Animals with unilateral ligation of the ductus deferens was performed. Untreated side was considered as a control group. Following ligation in the second month, high doses were sacrificed under the anesthesia on expiry of the subjects were testis and ductus deferens tissues. Tissues were blocked passage of the histological tracking method. Hematoxylin-eosin staining and Vascular endothelial growth factor (VEGF) immunohistochemical staining were applied.
RESULTS: Testicular tissue and the seminiferous tubule diameter of seminiferous tubule epithelial thickness was analyzed statistically using Mann-Whitney U test with Bonferroni. In our study, unilateral ligation of the ductus deferens, both in pre-pubertal period and pubertal period, testis and ductus deferens tissues of rats lead to structural changes, morphological and statistically affect on spermatogenesis process has been, after ligation the seminiferous epithelium and the seminiferous tubule diameter were thickness, and ductus deferens epithelial structure and muscles in the structure of muscle fibers forming the base degenerative changes were observed. After ligation, in pre-pubertal period and pubertal period, VEGF immunoreactivity was not observed in seminiferous tubule.
CONCLUSION: During prepubertal and pubertal period in rats with unilateral ligation causes damage on the ductus deferens and testis. Because of this damaged effects may be result in man infertility.

Keywords: Vasectomy, testis, ductus deferens, puberty, prepuberty, vascular endothelial growth factor

Histologic examination of testis in all groups

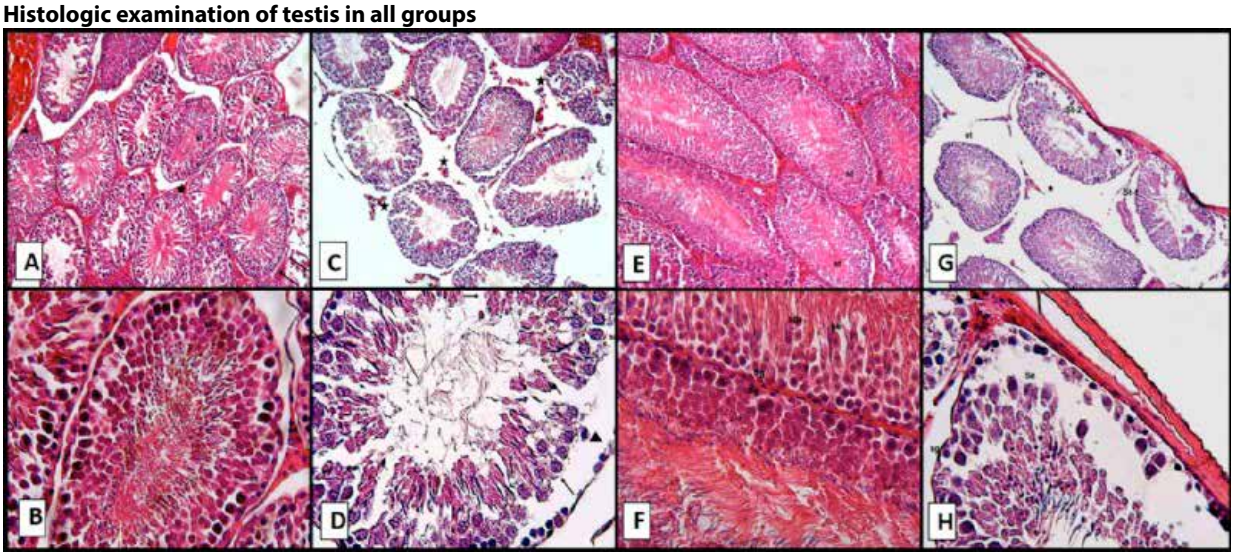

(A-B)Pre- pubertal control group: Normal histologic structure for prepubertal period apperance in testis (C-D) Pre-Pubertal ligation group: dejeneration and irregular boundaries of seminiferous tubules and cells were observed (E-F) Pubertal control group: Testicular section showing normal histological apperarance, (G-H) Pubertal ligation group: Testicular section shows severe degeneration and loss of the developing spermatogenic cell series. Seminiferous tubules (st), spermatogonia (<), interstisium (‹‹), Leydig Cells (L), sertoli cell (s), vascular structures (ĵĵ), cells of Spermatogenic series (ĵ).(A,C,E,G HE, Magnificatin x10, B, D, F, H HE, Magnification x40)

Histologic examination of vas deferens in all groups

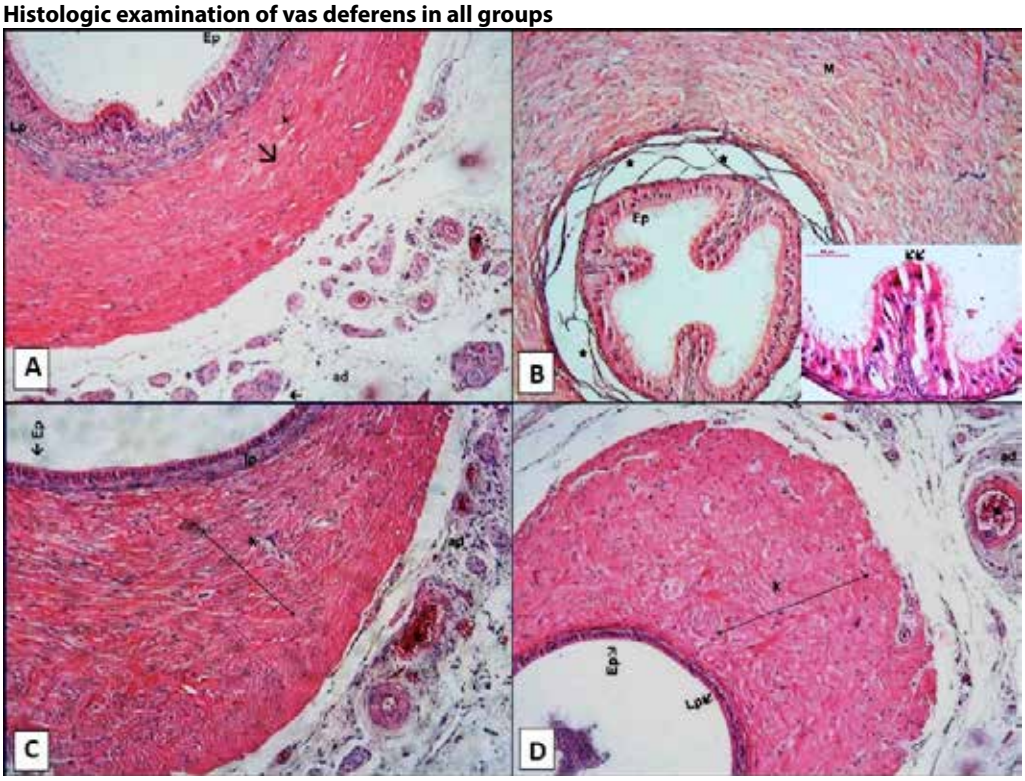

(A) Vas deferens section of pre-pubertal control group.: pseudostratified columnar epithelium and lamina propria appeared normal. (B) Pre-pubertal ligation group: degenerative changes in pseudostratified columnar epithelial and muscular layer. (C) Pubertal control group showed that normal histologic structure. (D) Pubertal ligation group: irregular morphology for stereosilium, muscle fiber of muscular layer and thinned lamina propria. pseudostratified columnar epithelium (Ep), Lamina propria (Lp), muscular layer (m,k), blood vessels (↞), degenerative changes (,,ß) and tunica adventitia (ad) (A-D; H.E, Magnification x10)

VEGF immunostaining in testicular tissue

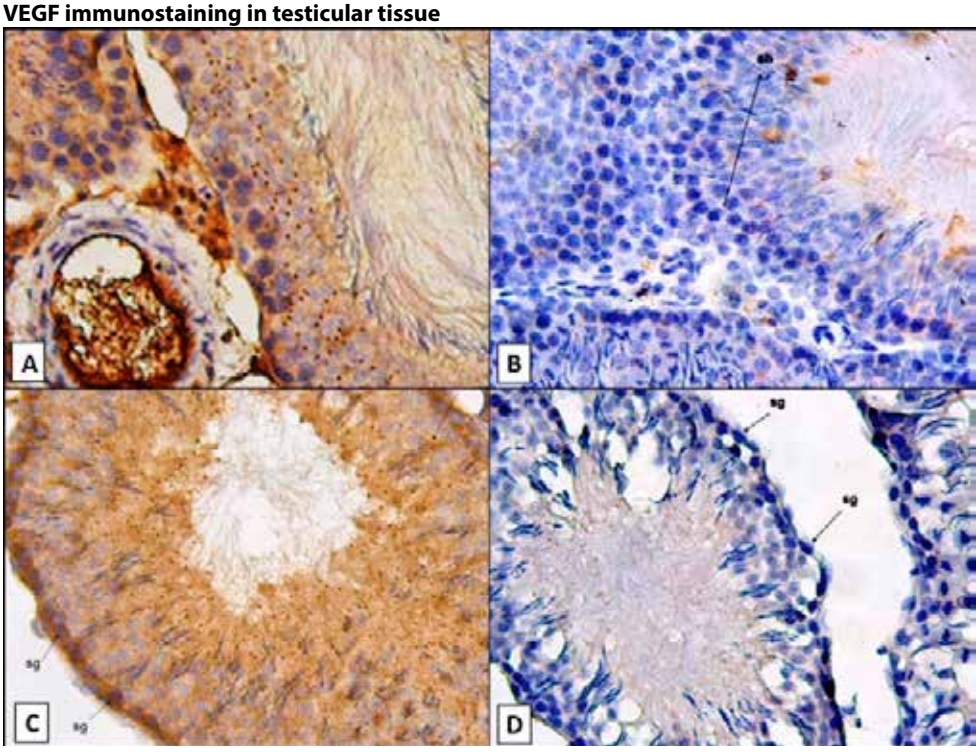

A) Pre-pubertal control group, B) Pre-Pubertal ligation group, C) Pubertal control group, D) Pubertal ligation group (A-D, Magnification, x40)

10.5505/2017ichc.PP-178 [Developmental and reproductive biology]

Distribution of Epidermal Growth Factor Receptors in the Rat Uterus during Anestrus

Uğur Topaloğlu[1], M. Erdem Akbalık[1], Berna Güney Saruhan[1], M. Aydın Ketani[1], Mehmet Kılınç[2], Hakan Sağsöz[1]

[1]Department of Histology & Embryology, Faculty of Veterinary Medicine, University of Dicle 21280-Campus- Diyarbakır, TURKEY

[2]Department of Anatomy, Faculty of Veterinary Medicine, University of Dicle 21280-Campus- Diyarbakır, TURKEY

The epidermal growth factor receptors (EGFR/erbB/HER) play a crucial role in the control of uterine cell proliferation, growth and differentiation. This study was designed to investigate the expression and localization of the ErbB/HER receptors during the anestrus of rat uterine by using immunohistochemistry. In this study, ten rats were used. In the different layers of the uterus, the changes of expressions of ErbB /HER receptors were demonstrated. In particular, luminal and glandular epithelial cells of the uterus showed more intense expression of ErbB/HER than those of smooth muscle cells and connective tissue. In addition, ErbB3/HER3 was found more intense in the apical cytoplasms of luminal and glandular epithelial cells. As a result, these findings revealed that EGFR system played important roles in the physiological changes of uterus.

Keywords: EGFR, endometrium, estrus cycle

10.5505/2017ichc.PP-179 [Developmental and reproductive biology]

The Role of Apoptosis and Notch2 in The First Trimester Spontaneous Abortions

Fatma Kaya Dagistanli[1], Tugan Bese[2], Fazile Akyuz Golgeci[2], Gamze Tanriverdi[4], Matem Tuncdemir[1], Sennur Ilvan[3], Sera Kayacan[1], Melek Ozturk[1]

[1]Department of Medical Biology, Cerrahpasa Medical Faculty, Istanbul University, Istanbul, Turkey

[2]Department of Obstetrics and Gynecology, Cerrahpasa Medical Faculty, Istanbul University, Istanbul, Turkey

[3]Department of Pathology, Cerrahpasa Medical Faculty, Istanbul University, Istanbul, Turkey

[4]Department of Histology and Embryology, Cerrahpasa Medical Faculty, Istanbul University, Istanbul, Turkey

The Notch signalling pathway regulates cell fate under the control of internal and external developmental signals. It is involved in the process of differentiation, proliferation and apoptosis. Notch pathway is essential for the placental functions. The aim was to investigate the relations between Notch2 and apoptosis or cell cycle regulator proteins (bcl-2, c-myc, p53, p21/waf-1) in placental tissues of spontaneous abortus during the first trimester.

In this study, the first trimester placental tissues were obtained from spontaneous abortions (missed abortion (n:18) and incompleted abortion (n:14)) and legal (elective) terminations of normal pregnancy (n:14) by curettage. None of the abortions was pharmacologically induced. Patients with clinically acute infection, autoimmune, or other systemic diseases were excluded. Immunohistochemistry for p53, bcl-2, c-myc, p21/waf-1 and notch2 and TUNEL method for apoptosis were performed to placental tissue sections.

There was no statistical difference for age, gestational age and abortion rates between two groups. We observed an increase of p21/waf-1 and p53 expression in the chorionic villi and decidua of placentas of the spontaneous abortions compared to the the elective abortion. More intense immunopositivity for p53 and Notch2 were seen in the cells of chorionic villus and decidua of missed abortion with respect to incomplete abortion. Whereas p21/waf-1 expression was higher in incomplete abortion compared to the missed abortion. TUNEL positive cells increased in the chorionic villi and decidua in the spontaneous abortions group compare to the elective abortion group ($p<0.001$). There was a positive correlation with apoptosis between increased expression of p53 and p21/waf-1. Notch2 immunopositive cells decreased in the spontaneous abortion cases. There was no significant difference between the numbers of c-myc immunopositive cells in both spontaneous abortion and elective termination cases, while bcl-2 and Notch2 have seen the strong immunopositivity especially in choronic villi and decidua of the elective abortion group.

Our study demostrated that p21/waf-1, p53 may contribute to spontaneous abortions involving excessive apoptosis causing the downregulation of Notch2 in the placenta. Notch2 and bcl-2 may be one of the major preventing factors from cell death for the maintenance of normal pregnancy.

Keywords: Apoptosis, Notch signaling, spontaneous abortions

10.5505/2017ichc.PP-180 [Developmental and reproductive biology]

Histological and Biochemical Investigation of the Effects of Apocynin on the Testes in Methotrexate-Induced Rats

Kübra Kavram[1], Melda Yardimoglu[1], Yusufhan Yazir[1], Ceyla Eraldemir[2], Esra Acar[2]

[1]Department of Histology and Embryology

[2]Department of Medical Biochemistry, Kocaeli University, Kocaeli, Turkey

INTRODUCTION & OBJECTIVES: Methotrexate, widely used drug in cancer or many diseases therapy, has many adverse effects on tissues. Apocynin, NADPH oxidase inhibitor, has many antioxidant properties. We aim to demonstrate the adverse effects of Methotrexate on testicular tissue and evaluate the protective effects of apocynin on methotrexateinduced testis injury and male fertility.
MATERIALS & METHODS: A total of 50 male Wistar albino rats (eight weeks old) were divided into five groups: Control (n=10), DMSO (n=10), Methotrexate (n=10), Apocynin(20mg)+ Methotrexate (n=10), and Apocynin(50mg)+ Methotrexate (n=10) groups. Control group received 1.25 ml, %0.9NaCl. DMSO group received 0,2 ml DMSO(Apocynin solvent) everyday.
The experimental groups; Methotrexate, Apocynin(20mg/kg) and Apocynin(50mg/kg), received 20 mg/kg Methotrexate as a single dose on day 24, while Apocynin (20mg/kg) and Apocynin (50mg/kg) received Apocynin everyday. All injections were performed intraperitoneally. At the end of day 28, all rats were sacrified under anesthesia. Testes were evaluated histologically and blood samples were analysed biochemically.
RESULTS: Testicular tissue and biochemical parameters of rats were normal in control groups. Methotrexate group displayed vacuolization in seminiferous tubules, immature germ cells in lumens, basal lamina ondulation and congestion in interstitial tissue (Figure 1). Apoptotic cells were significantly higher in methotrexate group compared with the other groups (Figure 2). Tissue and blood MDA and MPO levels were increased while the GSH and testosterone levels were decreased in methotrexate group. Apoptotic index were significantly decreased in apocynin treatment groups compared with the methotrexate group (Table 1). Apocynin treatment groups exhibited more better testis morphology against methotrexate induced damage and biochemical abnormalities.
CONCLUSIONS: Our results suggest that methotrexate induces structural defects on testis morphology via oxidative stress and apocynin ameliorates these effects with its antioxidant properties.

Keywords: Testis, Methotrexate, Apocynin, Apoptosis, Testosterone

Figure 1

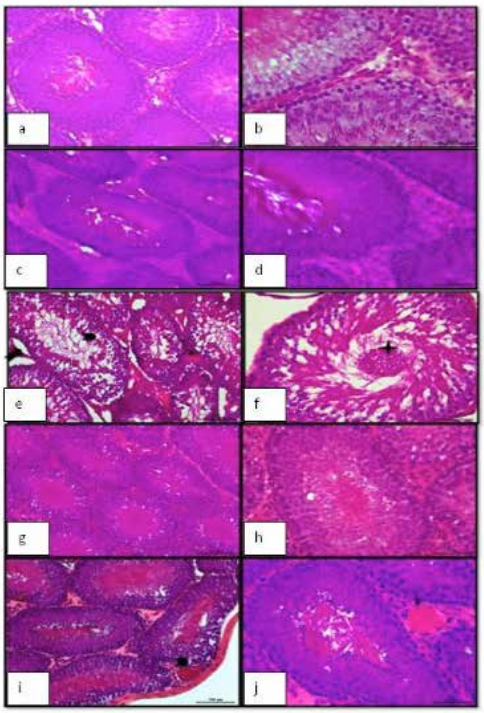

Photomicrographs of testis sections stained with H&E. Control group (a, b); DMSO group (c, d); methotrexate group (e, f); apocynin (20 mg)+methotrexate group (g, h); apocynin (50 mg) +methotrexate group (i, j). Note intact normal testis histology in the control group (a, b). Note congestion (thin arrow) in DMSO, methotrexate, apocynin (50 mg) + methotrexate groups; vacuolization ( ), basal lamina ondulation (thick arrow) and desqume cells in seminiferous tubules (*) in the methotrexate group. Note congestion (thin arrow) and vacuolization ( ) in apocynin (50 mg)+ methotrexate group; apocynin (20 mg) +methotrexate group had better histological morphology. Magnification, X200 in left column and and X400 in right column.

Figure 2

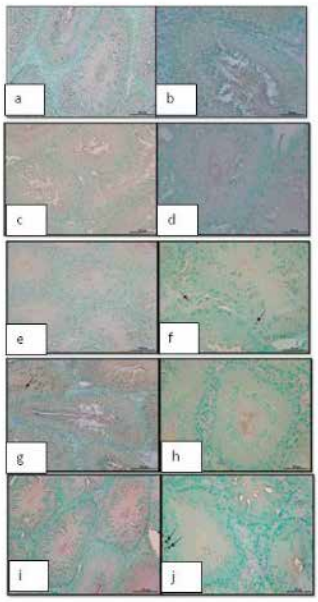

Photomicrographs of testis sections stained with TUNEL. Control group (a, b); DMSO group (c, d); methotrexate group (e, f); apocynin (20 mg) +methotrexate group (g, h); apocynin (50 mg) +methotrexate group (i, j). Note apoptotic cells as dark brown spots (arrow). The number of TUNELpositive cells increased in the methotrexate group (e, f), and decreased following treatment with apocynin (g-j). Magnification, X200 in left column and and X400 in right column.

Table 1

Groups	Apoptotic index
Control	0.000 (0.0000.023)
DMSO	0.008 (0.0000.035)
Methotrexate	0.161 (0.1190.200)
Apocynin (20 mg) +Methotrexate	0.000 (0.0000.005)
Apocynin (50 mg) +Methotrexate	0.009 (0.0000.015)

Methotrexate injury and apocynin effect on germ cell apoptosis index in adult rat testis (P=0.002).

10.5505/2017ichc.PP-181 [Developmental and reproductive biology]

The First Part of the Ductus Deferens in Bull and Ram:Morphological, Histological and Histochemical Aspects

Berna Güney Saruhan, Uğur Topaloğlu, M. Erdem Akbalık, Muzaffer Aydın Ketani, Hakan Sağsöz
Department of Histology and Embryology, Faculty of Veterinary Medicine, Dicle University, Diyarbakir, Turkey,

The aim of this study was to investigate the histomorphological and histochemical structure of the Ductus Deferens (DD) in bull and ram examined by light microscope. In this study, tissue samples taken from 8 of the healthy and mature male bull and ram were used as material. The collected samples were, organs grossly examined measured for length and processed for histology. The lumen of ductus deferens of ram and bull was appeared irregular in shape with many spiral mucosal folds. Each ductus deferens specimen consisted of mucosa, muscularis, and adventitia. The lining epithelium was pseudostratified columnar type with stereocilia. The lamina propria was formed from fibroelastic dense connective tissue layer. The muscular coat was formed from intermingled smooth muscle fibers arranged mainly as circular bundles, then appeared as longitudinal and spiral bundles. The neutral mucins appeared as PAS-positive (Periyodik Asit Schift) substances in the cytoplasm of the principal cells of the lining epithelium. The weak sulphated mucins showed up Aldehyde Fuchsin and Alcian Blue staining in the apical mucoza.

Keywords: Bull, ductus deferens, histochemistry, histomorphology, ram

10.5505/2017ichc.PP-182 [Developmental and reproductive biology]

Histological Effects of the Cress Seeds Added Broiler Ration

Hatice Erdost[1], Tuncay Ilhan[1], Ümit Polat[2], Deniz Belenli[2]

[1]Department of Histology and Embriyology, Faculty of Veterinary Medicine, Uludag University, 16059 Bursa, Turkey

[2]Department of Biochemistry, Faculty of Veterinary Medicine, Uludag University, 16059 Bursa, Turkey

INTRODUCTION & OBJECTIVES: Cress seed is a plant species belonging to Brassicacae family. In this study, it is aimed to evaluate the use of cress seed added broiler ration as an alternative natural and economical food additive to antimicrobials.
MATERIALS & METHODS: The chicks were fed and nursed from day 0 until they were slaughtered on the 42nd day of the study. The chicks were divided into four groups, consisting of one control and three treatment groups. Cress seed added to diet at the following dosages: 0.05% for the first treatment group; 0.10% for the second treatment group; 0.15% for the third treatment group. On the 21 and 45th days of the treatments, tissue samples were taken from duedonum, M. Femoralis and M. Pektoralis; then tissues were fixed in Bouin's solution for 24-48 h. After routine histology technique, the specimens were embedded in paraffin wax and 5-7 µm sections were cut and stained with Crossman's triple staining method. Goblet cell number, crypt depth and villus length of the four groups were compared using the Univariate Analysis of Variance.
RESULTS: In the all experimental groups, it was observed that villus intestinalis were morfologically longer, thinner and more regular than the control group. The surface epithelial cells in the experimental group were observed to have simple columnar epithelium with a very distinctive cell bounders whereas the control group surface epithelial cells were observed to have pseudostratified epithelium. As a result of the examinations, goblet cells as considered more numerous in the experimental groups. Lymphocyte infiltration was found fewer. At the same time, villus length and crypt depth was statistically significant.
When the cross sections prepared from M. Femoralis and M. Pectoralis by triple staining were examined, histopathological result was not observed in the experimental groups.
CONCLUSIONS: In conclusion, that supplementation broiler diets with cress seed may help prolong the shelf-life of the commercial broiler meat by reducing lymphocyte infiltration and Carcass quality can be affected positively.

Keywords: Broiler chicken, Cress seed, Duedonum, Muscle, Histology.

10.5505/2017ichc.PP-183 [Developmental and reproductive biology]

Ovarian tissue cryopreservation in prepubertal girls before chemotherapy seems to be efficient to preserve primordial follicle reserve as shown in a mouse model of vitrification and re-transplantation

Soner Celik[1], Sinan Ozkavukcu[2], Dileyra Adiguzel[1], Ciler Celik Ozenci[1]

[1]Department of Histology and Embryology, School of Medicine, Akdeniz University

[2]Department of Obstetrics and Gynecology, Centre for Assisted Reproduction, School of Medicine, Ankara University

Introduction & OBJECTIVES: Cyclophosphamide (CTX) is an alkylating agent that is commonly used in many chemotherapy protocols and it is reported to cause irreversible loss of primordial follicles (PmF) in cancer survivals. Especially in prepubertal girls, ovarian tissue cryopreservation (OTC) is the only option for fertility preservation and more than 80 live births have been reported after OTC and auto-transplantation so far. In this study, utilizing an animal model, we aim to investigate whether OTC before CTX therapy is efficient to preserve fertility in prepubertal females.
Materials & METHODS: Control group (n=12): Whole ovaries from 8-weeks-old female mice were removed and fixed. CTX group (n=12): Single dose of CTX was injected (200 mg/kg/I.P.) on postnatal day (PD) of 21. When these mice grew 8-weeks-old, their ovaries were also removed and fixed. VIT+CTX+TR group (n=10): Ovaries were removed on PD18 (before puberty) and cryopreserved by vitrification. CTX injection was applied on PD21 and ovaries were thawed and re-transplanted into the back muscle when mice grew 6-weeks-old. Grafts were removed after 2 weeks. All tissues were fixed in Bouin's solution and embedded into paraffin. Normal and atretic follicle counts were done in serial sections from whole ovaries that were stained with HE.
RESULTS: Mean number of normal PmF count was 764.3±39.2, 14.5±4.8 and 325.2±39.1 in control, CTX, and VIT+CTX+TR groups, respectively. The mean number of PmFs decreased significantly in CTX group when compared to control group. On the other hand, mean number of PmFs was significantly higher in VIT+CTX+TR group when compared to CTX group ($p<0.001$)(Fig.1). Mean number of growing follicles in CTX and VIT+CTX+TR groups were significantly lower than control group($p<=0.001$) (Fig.2). No significant differences were detected between any of the groups regarding atretic follicle numbers of PmFs and growing follicles(Fig.2). Representative images of HE stained ovarian sections of each group are given in Fig.3.
CONCLUSIONS: Our findings indicate that PmF reserve was better protected by OTC before CTX treatment in mice. On contrary, number of growing follicles was not affected. This model presents evidence for the first time that OTC in prepubertal girls before chemotherapy seems to be efficient to preserve PmF pool.

Keywords: vitrification, transplantation, ovarian tissue, mouse,fertility preservation, follicle counting

Figure 1

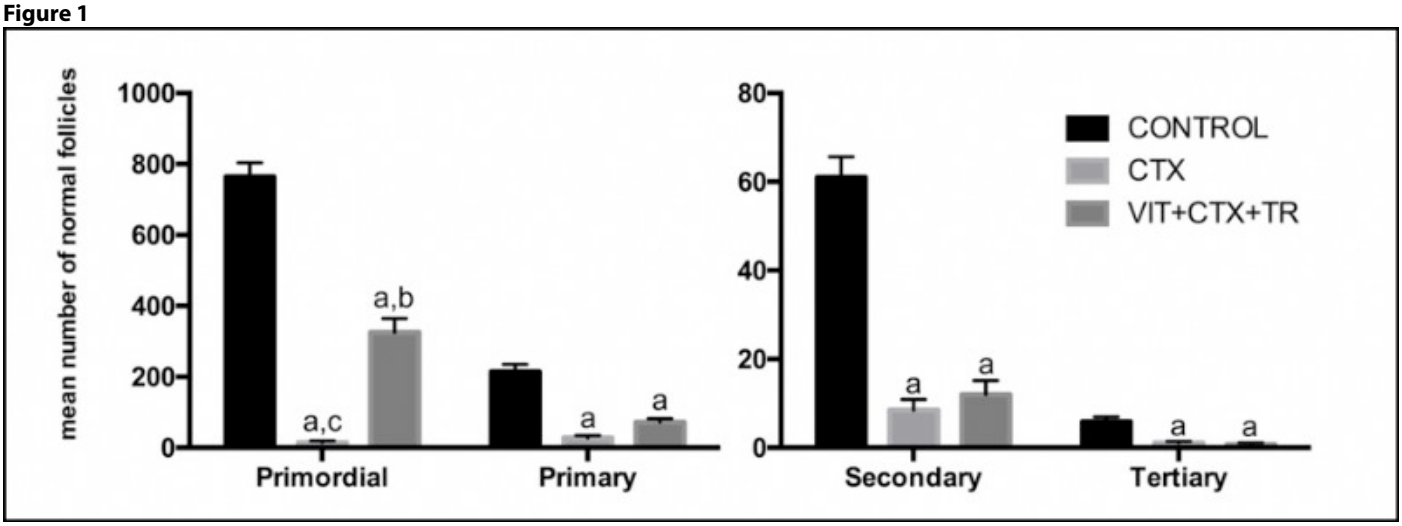

Mean number of normal follicles. a: Statistically significant from control group ($p<=0.001$), b: Statistically significant from CTX group ($p<=0.001$). c: Statistically significant from VIT+CTX+TR group ($p<=0.001$).

Figure 2

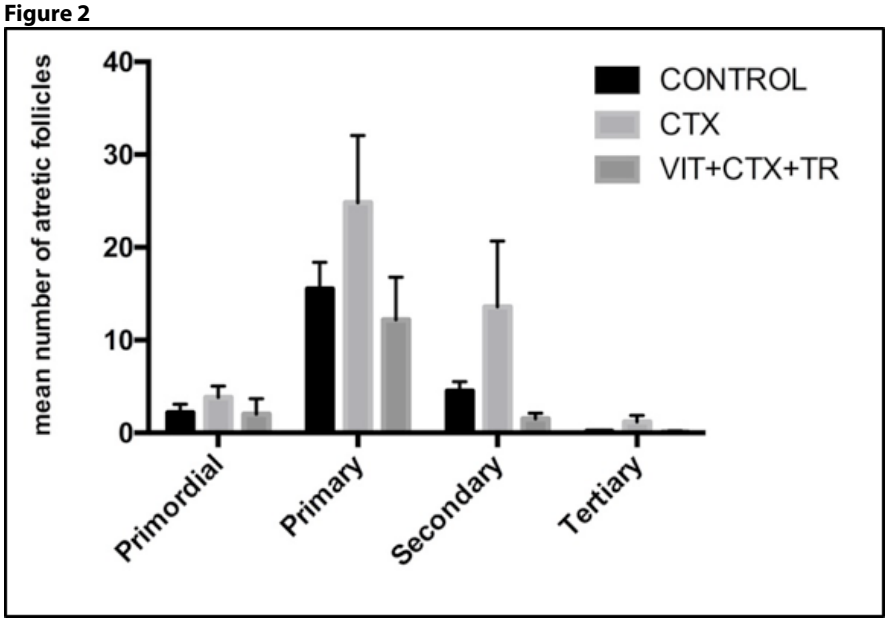

Mean number of atretic follicles. No significant differences were present between any of the groups regarding follicle numbers.

Figure 3

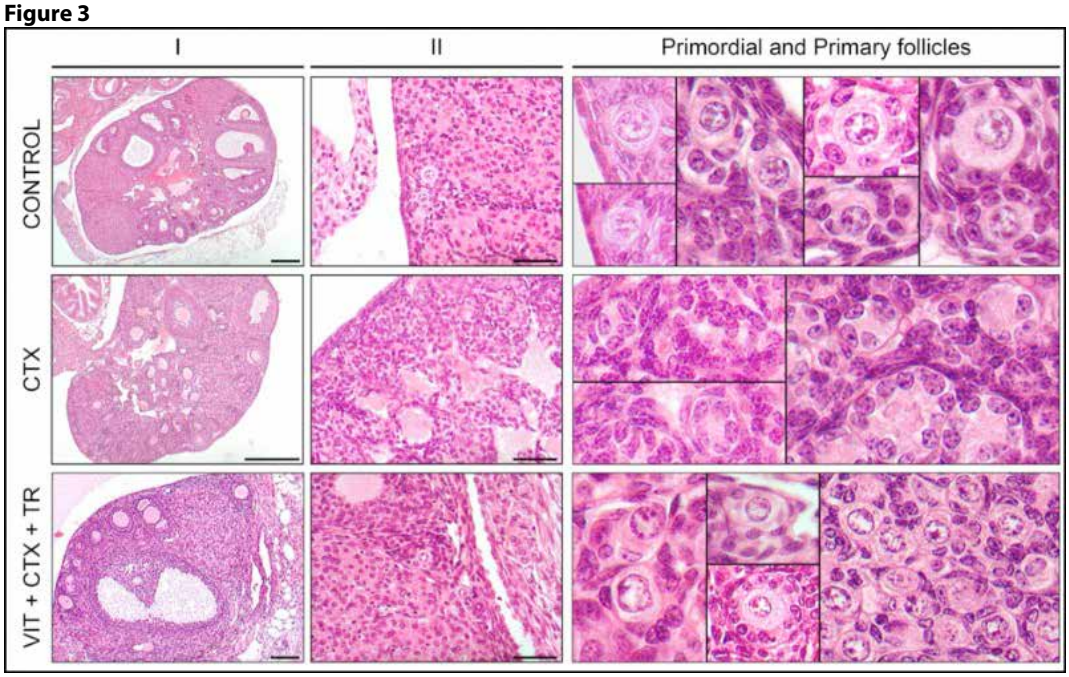

Histological sections of ovaries stained with hematoxylin and eosin (H&E). Scale bars of columns I and II represent 250m and 50m, respectively. Primordial and primary follicles column show digital magnifications of primordial and primary follicles in each group.

10.5505/2017ichc.PP-184 [Developmental and reproductive biology]

Expression of circadian clock proteins during peri-implantation period in mice

Dileyra Adıgüzel[1], Merve Gürsoy[2], Soner Çelik[1], Pınar Şahin[1], Çiler Çelik Özenci[1]

[1]Faculty of Medicine Department of Histology and Embryology, Akdeniz University, Antalya, Turkey

[2]Faculty of Medicine, Akdeniz University, Antalya, Turkey

OBJECTIVE: Embryo implantation is a complex process that requires the spatiotemporal hormonal orchestration and reciprocal interactions between implantation-competent blastocyst and the receptive uterus. Internally synchronized circadian clock contains 4 genes/proteins at molecular level: CLOCK, BMAL1, Cry (1-2) and Per (1-3). Additionally, NPAS-2 is a compansator protein for BMAL1. The cellular clock regulates various processes including cell cycle control, DNA damage responses and hormone oscillations. The aim of this study was to investigate the expression of circadian clock proteins in mouse uterus during early pregnancy and also in pseudopregnancy and artificial decidualization models.
MATERIALS-METHOD: From 6 weeks old BALB/C female mice; estrous phase and pregnancy days of 1–8 uteri sections were obtained. In addition, pseudopregnancy and artificial decidualization models were established to understand whether expressions of circadian clock proteins are blastocyst and/or ovarian steroid hormone dependent or not (Figure1). Immunohistochemical analyses were performed for CLOCK, BMAL1, and NPAS-2 in all groups (n=6 in each group).
RESULTS: At the time of implantation on day 5 of pregnancy, NPAS-2 expression was strong in stromal cell nuclei at implantation sites while its expression was weak at inter-implantation sites where no embryo was present. This was true for day 6 as well (Figure 2). BMAL1 expression was nuclear in endometrial luminal epithelium and glands at implantation sites while its expression was almost absent at inter-implantation sites. This was true for day 6 as well (Figure 3). There was an extensive but day independent expression of CLOCK protein during peri-implantation period (Figure 4). When expressions of these proteins in pseudopregnancy and artificial decidualization models were evaluated, we found that their expressions seem to be regulated by steroid hormones, except for CLOCK protein (Figure2-4).
CONCLUSION: Disruption of the circadian system, due to irregular lifestyle such as rotating shift work, frequent travel across time-zones, or chronic stress, is correlated with several diseases such as infertility, cancer, and neurological disorders. Our findings indicate for the first time that Clock proteins are differentially expressed throughout early pregnancy and they may have important roles in mouse embryo implantation, uterus receptivity and decidualization processes.
This project was supported by TÜBİTAK (project number:215S868)

Keywords: mouse, peri-implantation, clock proteins, NPAS-2, BMAL1, CLOCK

Figure 1



Artificial decidualization was induced by intraluminally infusing 25 µl of sesame oil into one horn of the uterine on day 4 of pseudopregnancy, while the contralateral uninjected horn used as a control. Following artificially induced decidualization, the uterus was collected on day 5, 6, and 8 of pseudopregnancy.

Figure 2

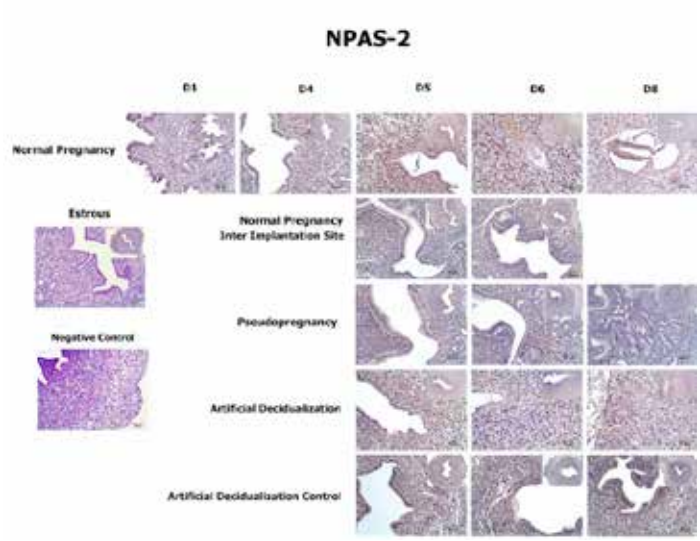

Immunlocalization of NPAS-2 at pregnancy days of 1–8, estrous phase, pseudopregnancy, and artificial decidualization model in mice

Figure 3

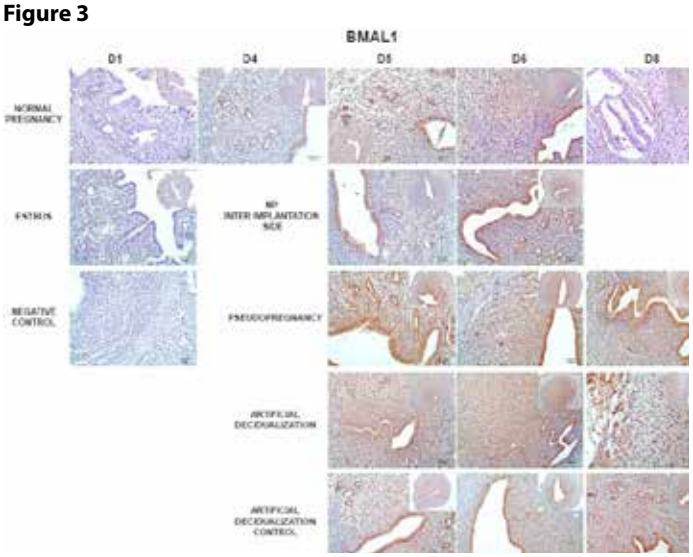

Immunlocalization of BMAL1 at pregnancy days of 1–8, estrous phase, pseudopregnancy, and artificial decidualization model in mice

Figure 4

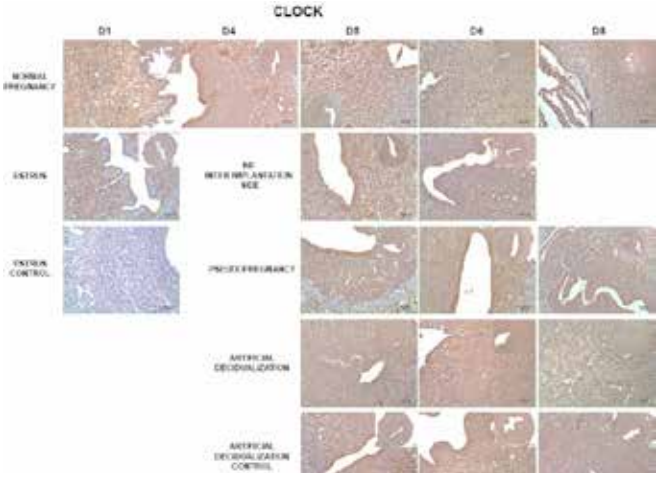

Immunlocalization of CLOCK at pregnancy days of 1–8, estrous phase, pseudopregnancy, and artificial decidualization model in mice

10.5505/2017ichc.PP-185 [Developmental and reproductive biology]

Testicular torsion-induced tubular injury and disturbed spermatogenesis in rats were improved with an estrogen receptor-beta agonist

Sevil Arabacı Tamer[1], Şule Arabacı[2], Selin Çiftci[2], Sena Akın[2], Elif Sarı[2], Hakim Ahmetoğlu[2], M. Kutay Köroğlu[3], Feriha Ercan[3], Özge Dağdeviren Çevik[4], Meral Yüksel[5], Alper Yıldırım[1], Berrak Ç.yeğen[1]

[1]Departments of Physiology, School of Medicine, Marmara University, Istanbul, Turkey

[2]School of Medicine, Marmara University, Istanbul, Turkey

[3]Departments of Histology and Embryology, School of Medicine, Marmara University, Istanbul, Turkey

[4]Departments of Biochemistry, Faculty of Pharmacy, Cumhuriyet University, Sivas, Turkey

[5]Vocational School of Health Service, Marmara University, Istanbul, Turkey

Introduction & OBJECTIVES: Testicular torsion, caused by twisted spermatic cord, disrupts blood flow and leads to ischemia and reperfusion injury in testis tissue. Estrogen and estrogen receptor (ER) agonists have an important role in regulating the development and function of testis. In a testicular ischemia-reperfusion injury in rats, it was aimed to examine the role of ERß agonist diarylpropionitrile (DPN), ERα agonist propylpyrazol-triol (PPT) and 17ß Estradiol (E2) on testicular histopathology.
Materials & METHODS: Under anesthesia, 6-8-week-old male Sprague-Dawley rats underwent sham-operation (n=8) with a left scrotal incision or testicular torsion (n=32) by fixing left testis rotated at 720° for 2 h. Following detorsion, E2, DPN, PPT (each 1ml/kg/day) or vehicle was given subcutaneously for 3 days until they were decapitated. Blood flow was monitored by laser Doppler flowmeter before and after torsion, and on 3rd day of torsion. Morphology and motility of epididymal spermatozoa were microscopically evaluated. In each hematoxylin-eosin stained section, at least 20 seminiferous tubules were scored microscopically by using modified Johnsen scoring method for evaluation of spermatogenesis. Statistical analyses were made using ANOVA and Student's t-test.
RESULTS: Blunted blood flow by torsion was recovered on 3rd day, while E2 or ER agonists further facilitated blood flow. Compared to sham group, vehicle-treated torsion group revealed a higher percentage of sperm neck defect, while defect percentage was lower in DPN- or E2-treated rats ($p<0.05$-0.001). Although total sperm count was decreased in all torsion groups, DPN increased the number of motile sperm count ($p<0.01$). In vehicle-treated or PPT-treated torsion groups, most of the seminiferous tubules were degenerative with vacuole formation in spermatogenic cells, decreased spermatogenic germ cells, immature cells in the lumen, while some of the seminiferous tubules did not have spermatozoa or spermatids. However, in DPN- or E2-treated rats, most of the seminiferous tubules demonstrated quite regular germinal epithelium with spermatogonia, spermatocytes, spermatids and spermatozoa.
CONCLUSION: Treatment with an ERß receptor agonist in the early period of detorsion improved torsion-induced tubular injury and supported disturbed spermatogenesis, implicating that use of ERß receptor agonists could be of therapeutic value in ameliorating ischemic testicular injury and in maintaining fertility.

Keywords: Testis torsion, DPN, PPT, E2, estrogen.

10.5505/2017ichc.PP-186 [Developmental and reproductive biology]

Immunohistochemical evaluation of endoplasmic reticulum stress-related protein expressions in streptozotocin-induced diabetic mouse ovary

Aslı Okan, Berna Sözen, Necdet Demir
Department of Histology And Embryology, Akdeniz University, Antalya, Turkey

Introduction & Objectives: Various factors result in the onset of accumulating the unfolded and/or misfolded proteins in the endoplasmic reticulum (ER) lumen which causes to ER stress. Unfolded protein response (UPR) is activated against to ER stress to retain cellular homeostasis. The UPR can eventually trigger cell death if ER dysfunction is severe or prolonged. Previous studies showed that there is a relationship between the UPR and ovarian development and function. Additionally, the UPR is also related with pathophysiology of various diseases, including diabetes. Our hypothesis in here is that hyperglycaemic microenvironment activates UPR signaling pathway as a result of triggered ER-stress within the ovarian tissue. To this end, we aim to determine localization and expression levels of transmembrane receptor proteins of UPR in STZ-induced diabetic mouse ovaries.
Materials & Methods: In this study, 24-days-old Balb/C female mice (N=31) were used and designed as three groups: Control (N=10, no treatment), Vehicle (N=6, The single injection of 100µl sodium citrate buffer i.p.), Diabetic (N=15, The single injection of STZ, 90mg/kg body weight in 100µl sodium citrate buffer i.p.). Blood glucose level was measured following the injection days on 2nd, 7th and 14th. Mice whose blood sugar was over 300 mg/dl were accepted as the diabetic. The day of 14th, mice were sacrificed and ovary samples were collected, then embedded in paraffin and the localization and the expression levels of GRP78, DDIT3, Caspase 12 and p-PERK examined by immunohistochemical staining.
Results:GRP78 was detected in the cytoplasm of granulosa cells and oocytes of all groups in the developing follicles within the ovary. Caspase 12 protein was observed in cytoplasm of seconder follicles, antral follicles and luteal cells of corpus luteum within ovaries of all experimental groups. Expression of p-PERK and DDIT3 were significantly increased in diabetic ovaries, especially in atretic follicles, apoptotic granulosa cells and degenerated oocytes. Additionally, p-PERK was observed as nuclear staining in primer oocytes of primordial follicles in diabetic ovaries.
Conclusions: According to our findings, the UPR may play a key role in the regulation of follicular development and selection of atretic follicles in mice ovaries under hyperglycaemic conditions.

Keywords: Endoplasmic Reticulum Stress, Diabetes, Streptozotocin, Ovary, Mouse

Figure 2

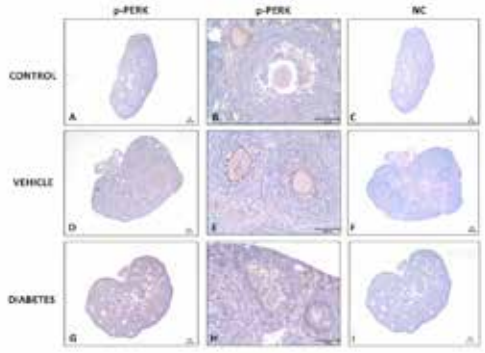

Expression of p-PERK in mice ovaries. p-PERK signal was detected in the cytoplasm of atretic follicles degenerated oocytes and apoptotic granulosa cells in the control ovaries (A,B) and in the vehicle ovaries (D,E); increased expression of p-PERK in early follicular stages of the diabetic ovaries (G,H); negative control sections (C,F,I); bars=50µm.

Figure 3

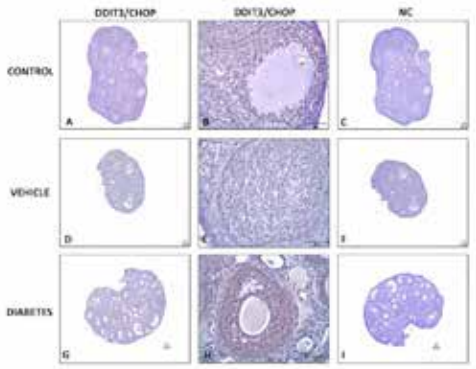

Expression of DDIT3 in mice ovaries. Signal of DDIT3 was observed in the cytoplasm and the nucleus of apoptotic granulosa cells in the control ovaries (A,B) and the vehicle ovaries (D,E); Nuclear expression of DDIT3 in follicles of the diabetic ovaries (G,H); negative control sections (C,F,I); bars=50µm.

Figure 4

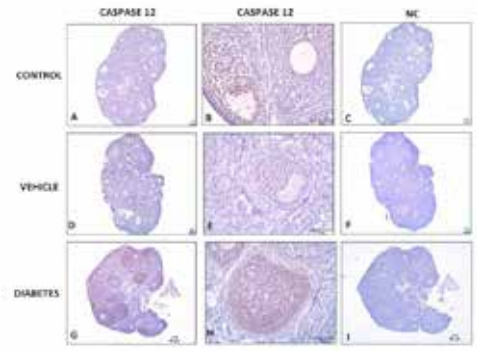

Expression of Caspase 12 was detected in the cytoplasm of seconder follicles, antral follicles and luteal cells of corpus luteum in the ovaries of all the subjects. (A. B) The control group, (D, E) the vehicle group, (G, H) the diabetes group, (C, F,I) negative control sections; bars=50µm.

Figure 5

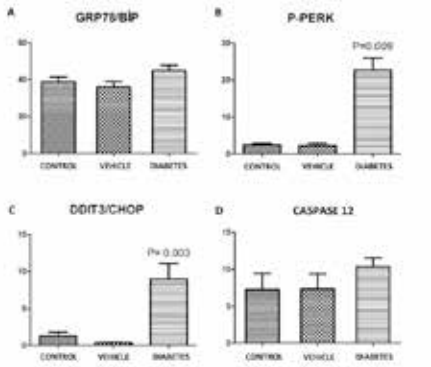

Image J evaluations of (A) GRP78/BiP, (B) p-PERK, (C) Caspase 12 in experimental groups (*P<0.05).

Figure1

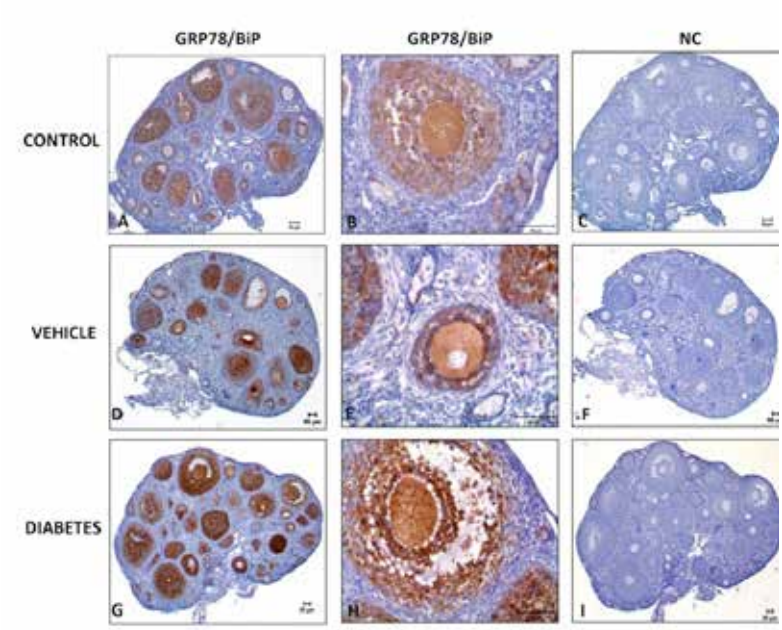

Expression of GRP78/BiP was detected in the cytoplasm of granulosa cells and oocytes of all groups in mice ovaries. (A,B) The control group, (D,E) the vehicle group, (G,H) the diabetes group, (C,F,H) negative control sections; Bars=50µm.

10.5505/2017ichc.PP-187 [Developmental and reproductive biology]

Development of the Fetal Membranes in Chicken Embryo

Yasin Ilgaz[1], Havva Ilgaz[2], Esra Erdogan[1], Barış Baykal[1]

[1]Department of Medical Histology and Embryology, University of Health Sciences, Gulhane Faculty of Medicine, Ankara, Turkey

[2]Department of Undersea and Hyperbaric Medicine University of Health Sciences, Gulhane Faculty of Medicine, Ankara, Turkey

The chick embryo is being used in experimental investigations because of the easy accessibility of fetal membranes. Especially chorioallantoic membrane (CAM) which is formed by the fusion of chorion and allantois is routinely used in biological and biomedical research to investigate development, angiogenesis, tumors, chemotherapeutic agents and to propagate and investigate viruses or helminths. The formation of membranes is a dynamic process like embryonic tissues in fetal period. Therefore, a researcher planning to study the fetal membranes should be aware of the developmental stages of these membranes. This will simplify the timing of applications to egg and the selection of safe locations.
Chick development takes place in 21 days. During this process, four extraembryonic membranes (Vitelline-yolk sac, amnion, allantois, serosa-chorion) develop and they have a lot of functions such as;
Nutrition:Vitelline substance which is transferred to the embriyo via vitelline vessels from the yolk sac provides embryo development.
Respiration:The exchange of O2 and CO2 initially occurs in the vitellus cutaneous capillary network. After embryonic growth and shrinkage of the vitelline sac, the chorioallantoic membrane takes over this task.
Urination:Metabolic wastes cannot be thrown out of the egg. Allantois that the cloaca forms outwardly outside the embryo is the collection point of the metabolic wastes like urea and uric acid.
Liquid media formation:A suitable fluid medium for providing morphogenic movements is created through amniotic sac.
The bilayer CAM in a dense vascular network that is connected to the embryo via allantoic arteries and venules. Thus, the chorionic epithelium and allantoic vascular network provide O2-CO2 exchange between the external environment and the embryo. After eight days of incubation, CAM occupies 75% of the inner surface of the egg, and it occupies 100% on the 12th day. It's proximity to the egg shell makes respiration function easy.
The chick embryo is a quick, technically simple, and inexpensive experimental model. However, a major drawback is that it is labor intensive due to the large number of eggs that are required to obtain consistent results. Because of that, the researcher who wants to optimize the study has to learn the development of the membranes.

Keywords: Fetal Membranes, Chorioallantoic Membrane Assay, Development of Chick Embryo

Figure 1

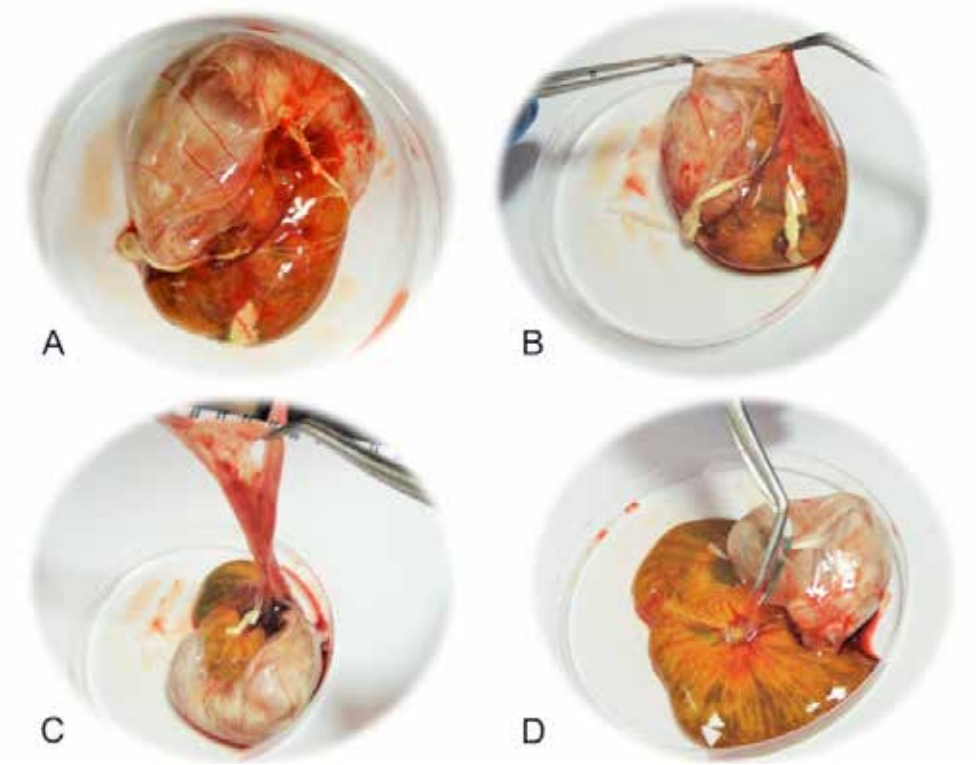

19th day of chick development. (A) Appearance of the incubated egg with no eggshell. (B) Chorioallantoic membrane is held with pliers. (C) Chorioallantoic membrane is peeling off. (D) Showing amnion's membrane with the help of pliers.

Figure 2

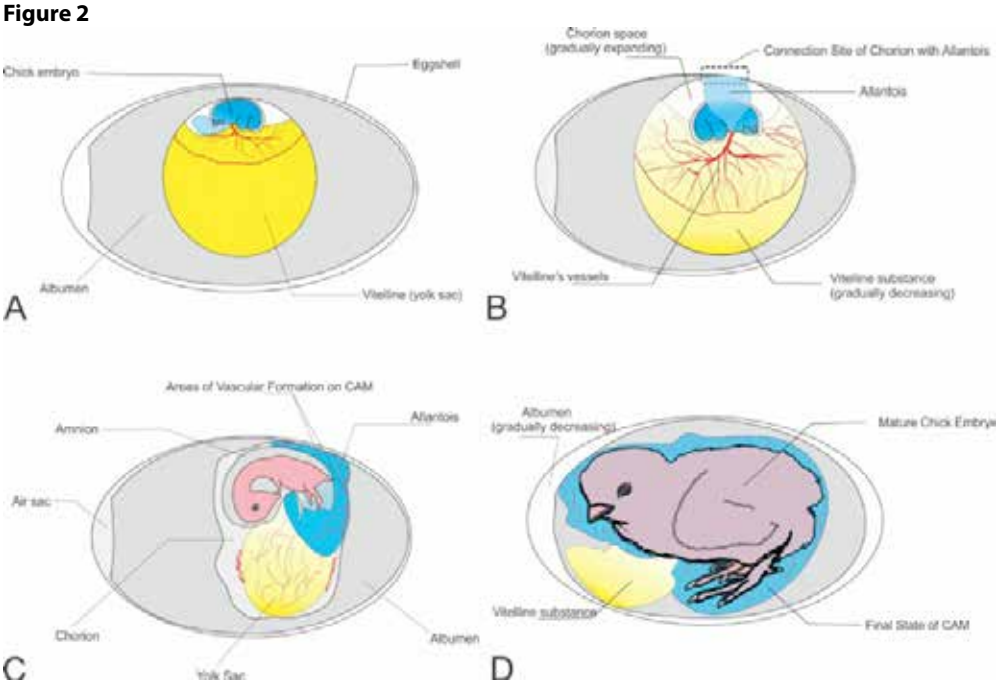

Different stages of chicken embryo. (A) 4th day of incubation (B) 5,5th day of incubation (C) 8th day of incubation (D) Embryonic state just before the hatching.

10.5505/2017ichc.PP-188 [Developmental and reproductive biology]

The effects of 2100 MHz radio frequency radiation on ductus epididymis in hypertensive and normal rats

Gökçe Nur Yücel[1], Dilek Kuzay[2], Cemile Merve Seymen[1], Çiğdem Özer[3], Tayfun Göktaş[3], Bahriye Sirav Aral[4], Fatih Şentürk[4], Gülnur Take Kaplanoğlu[1]

[1]Gazi University Faculty of Medicine, Department of Histology and Embryology, Ankara, Turkey

[2]Ahi Evran University Faculty of Medicine, Department of Physiology, Kırşehir, Turkey

[3]Gazi University Faculty of Medicine, Department of Physiology, Ankara, Turkey

[4]Gazi University Faculty of Medicine, Department of Biophysics, Ankara, Turkey

AIM: Hypertension is an important disease that affects nearly one million people and threatens the health negatively, today. Studies in radiofrequency radiation have shown that radiofrequency exposure increases blood and plasma viscosities and causes to rise reactive oxygen species in tissues. In our study, we aimed to investigate the effects of radiofrequency radiation, which we are exposed to increasingly nowadays, on ductus epididymis in hypertensive individuals at light microscopic level.
MATERIALS-METHODS: 250 ± 20 gr, 24 Wistar albino male rats were divided into 4 groups. Sham control group (Group 1) was given 1 ml/day tap water for 1 month by gavage. The experimental group (Group 2) of hypertension model was given 1 mg of L-NAME which dissolved in 1 ml of tap water for 1 month by gavage. The radiofrequency radiation group (Group 3) was exposed to 60 minutes/5 days/2100 MHz radiofrequency radiation for 2 months. The group which an experimental hypertension model was established and radiofrequency radiation applied (Group 4), was administered with a dose of 60 mg/kg L-NAME which dissolved in 1 ml of tap water, for 1 month by gavage and was exposed to 60 minutes/5 days/2100 MHz radiofrequency radiation for 2 months. At the end of the experiment, ductus epididymis tissues were taken and Masson's Trichrom and Androgen Receptor (AR) stainings were performed.
RESULTS: It was observed that junctional complexes of ductus epididymis tubular epithelial cells opened, also stereocilium structures deleted and the amount of spermium decreased by Masson's trichrome staining through hypertensive rats. In addition to opening the junctional complexes with application of radiation, it was also detected that stereociliums showed pinopod-like shape. In the fourth group, intense degeneration in tubular epithelial cells were observed and also it was seen that spermiums showed head/tail abnormalities. In AR immunohistochemical stainings, the intensive immunreactivity was seen in hypertensive rats but also weak immunreactivity was seen in the fourth group.
RESULT: Taken together, exposure to radiofrequency radiation in combination with experimental hypertension model affects the ductus epididymis structure negatively and causes to change of AR distribution.
Keywords: Hypertension, Radiation, Ductus Epididymis, Androgen Receptor

Figure 1

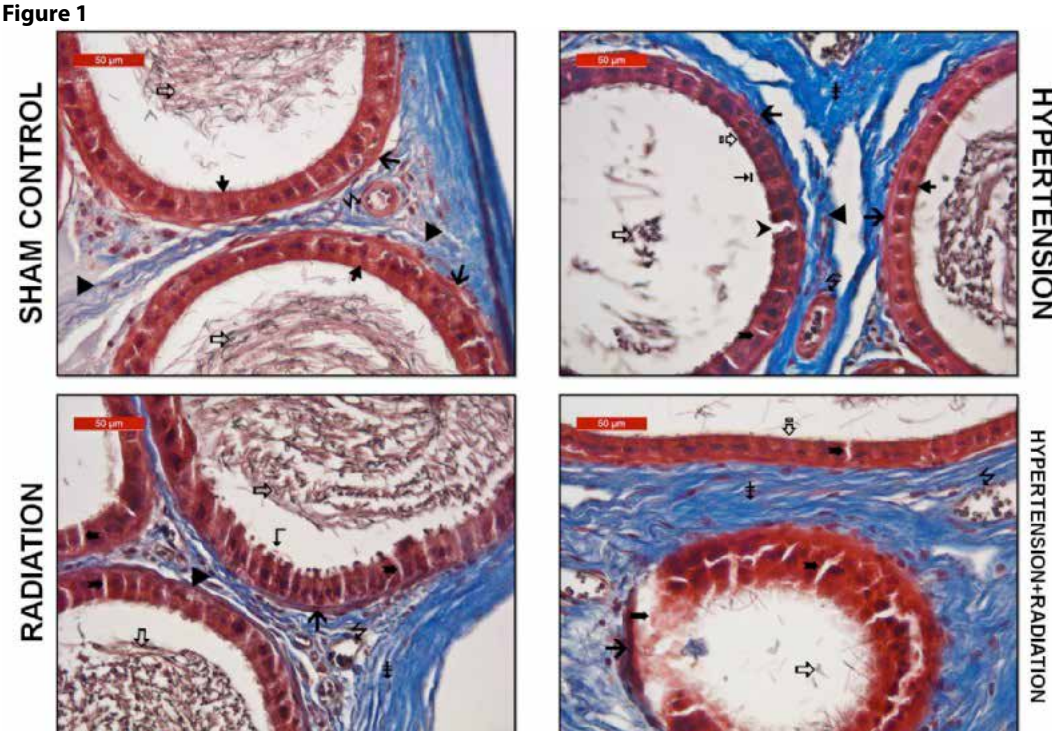

Figure 2

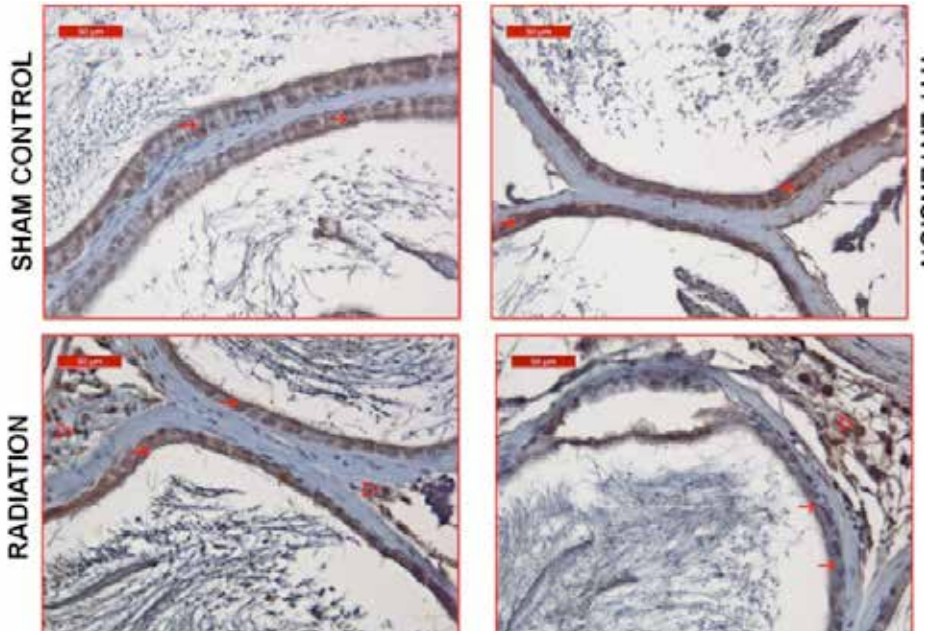

10.5505/2017ichc.PP-189 [Developmental and reproductive biology]

The Biochemical and Histopathological Evaluation of Cytotoxic Effects of Acetamipride, a Neonicotinoid Insecticide, on Rat Testis

Yağmur Emre Arıcan[1], Damla Kayalı[2], Feriha Ercan[2], Gül Özhan[1]

[1]Department of Pharmaceutical Toxicology,Istanbul University, Faculty of Pharmacy

[2]Department of Histology & Embryology, School of Medicine, Marmara University, Istanbul, Turkey

INTRODUCTION: The fact about industrialization and advanced technology is that they have cumulative harmful effects on human health and environment while making the life easy, fast and modern. Recently it was reporeted that, many xenobiotics has developmental, reproductive and endocrin system-related toxic effects. Organophosphate and carbamate pesticides were replaced with neonicotinoids, which have sun-light resistance and higher toxicity to pests than mammals. Acetamipride is one of the most preffered and widely used neonicotinoids, act as a selective agonist on acetylcholine receptor. There are some information about effects of acetamipride on male reproductive system in both agriculture laborers and food consumers, however, its toxic effects and mechanism of action have not been clarified exactly yet. The aim of the study investigate possible cytotoxic effects of Acetamipride on testis.
MATERIAL-METHODS: Male Sprague-Dawley rats were used in this study. Acetamipride solved in methylselulose were applied to the animals orally, in 12.5, 25 ve 35 mg/kg bw doses for 90 days. In control rats only methylselulose were applied to the animals. Under ether anesthesia blood and testes removed from the animals and prepared for biochemical and histological analysis. Cholesterol, FSH, LH, Inhibin, Gonadotropin-Releasing Hormone (GnRH), testosterone were analysed in blood serum. Oxidative demage parameters as Glutathion (GSH), Malondialdehyde (MDA), Total Antioxidant Status (TAS) and Total Oxidant Status (TOS) were analysed in testes biochemically. Sperm parameters, testis morphology and apoptotic cells were analysed microscopically. Data were analyzed statistically.
RESULTS: All the hormone, GSH and TOS levels, the percentage of normal spermatozoa were decreased, MDA and TAS level, the number of atrophic seminiferous tubules and apototic cells were increased in a high dose acetamipride administration comparing to the control rats.
DISCUSSION: According to our biochemical and histopathological results oral administration of acetamipride at 35mg/kg bw dose causes testis damage by decreasing spermatogenic cell line and increasing apoptosis via the formation of oxidative stress.

Keywords: Acetamipride, oxidative stress, apoptosis, testis

10.5505/2017ichc.PP-190 [Developmental and reproductive biology]

Protective Effect of Resveratrol on Cisplatin Induced Testicular Cytotoxicity and Ultrastructural Damage

Nagehan Özyilmaz Yay[1], Göksel Şener[2], Feriha Ercan[1]

[1]Departmant of Histology and Embryology, School of Medicine, Marmara University, Istanbul, Turkey

[2]Department of Pharmacology, School of Pharmacy, Marmara University, Istanbul, Turkey

INTRODUCTION: In this study, we aimed to investigate the possible protective role of resveratrol (RES) on cisplatin (CIS)-induced testicular toxicity in rats using histological, histochemical, ultrastructural and biochemical methods.
MATERIALS-METHOD: Sprague-Dawley rats (n= 7) were divided into four groups. 1) Control, 2) RES, 3) CIS, 4) CIS+RES. We applied either saline or 10 mg/kg RES orally for 5 days after a single dose of 7 mg/kg i.p. cisplatin to the CIS groups. Only saline or RES was applied to the control groups. After 5 days, rats were decapitated under ether anesthesia and testis tissues were removed. After routine histological preparation, the diameter and area of seminiferous tubules were measured. Proliferative and apoptotic cells were evaluated quantitatively. Ultrastructural alterations were evaluated by using electron microscopical technics. Malondialdehyde (MDA) and glutathione (GSH) levels and myeloperoxidase (MPO) activity were measured in the tissues.
RESULTS: The area and diameter of the seminiferous tubules were significantly decreased in CIS group and increased in CIS+RES group. Apoptotic index was increased in CIS group and decreased in CIS+RES group. Proliferative index was decreased in CIS group and increased in CIS+RES group. Numerous large vacuoles in the cytoplasm of spermatogonial and Sertoli cells and dilatation of intercellular tight junctions were observed in CIS group. A decreased number of small vacuoles in the cell cytoplasm was observed and dilatation of intercellular tight juctions was decreased in CIS+RES group. While MDA level and MPO activity were significantly increased, GSH level was significantly decreased in CIS group. All biochemical parameters were ameliorated in CIS+RES group.
CONCLUSION: Cisplatin causes testis damage by decreasing spermatogenic cell line and increasing apoptosis, via the formation of oxidative stress, and resveratrol prevents testis damage by its possible antioxidant effects.

Acknowledgement: This study was supported by Marmara University Research Fund (SAG-C-YLP-090414-0076).

Keywords: Cisplatin, Resveratrol, Testis, Apoptosis, Cell Proliferation

10.5505/2017ichc.PP-191 [Developmental and reproductive biology]

The investigation of potential protective effects of ellagic acid against reproductive damage induced by irinotecan in male rats

Cemile Ceren Gül[1], Aslı Taslidere[1], Nese Basak Türkmen[2], Osman Ciftci[3], Muhterem Aydın[4]

[1]Inonu University Faculty of Medicine, Department of Histology and Embryology, Malatya, Turkey

[2]Inonu University Faculty of Pharmacy, Department of Pharmaceutic Toxicology, Malatya, Turkey.

[3]Inonu University Faculty of Medicine, Department of Medical Pharmacology, Malatya, Turkey.

[4]Fırat University Faculty of Veterinary Medicine, Department of Obstetrics and Gynecology, Elazıg, Turkey.

AIM: Irinotecan(CPT-11) is an anticancer agent derived from camptothecin and has a wide anticancer spectrum including colorectal, pulmonary, cervical, and ovarian cancer. The active metabolite, SN-38, induces irreversible deoxyribose nucleic acid(DNA) damage in tumor cells, and its accumulation in the intestinal mucosa is thought to be responsible for enterotoxicity. The wide distribution of CPT-11 and SN-38 in tissues enhanced the potential risk of tissue toxicity. Testes were a well-recognized target toxic tissue of CPT-11. Ellagic acid (EA) is a natural phenol antioxidant found in numerous fruits and vegetables. The antiproliferative and antioxidant properties of ellagic acid have prompted research into its potential health benefits. This study was planned to investigation of potential protective effects of Ellagic acid againts reproductive damage induced by IR in male rats.
MATERIAL-METHOD: In our study 40 Sprauge-Dawley rats were used. Rat were divided into 4 groups randomly selected(n=10). Groups:
1.Group: Control
2.Group: IR
3.Group: IR+EA
4.Group: EA
At the end of the study testis tissue samples were taken from rats. The testes samples were processed by routine tissue techniques and embedded in paraffin. 5 µm thick sections of tissues were cut, mounted on slides, stained with Hematoxylin-Eosin(H-E). For immunohistochemical investigation, sections were stained with Caspase-3 and examined under a Leica DFC280 light microscope by Leica Qwin and Image Analysis System.
RESULTS: In Control and EA groups, testis showed a normal histological appearance with H-E procedure. In IR group, testis tissue showed some histological alterations such as:congestion in tunica albuginea layer, congestion between tubules, oedema, vacuolisation in interstitial area, reduction in germ line cells in seminiferous tubules, apoptotic cells, squamotion in lumen and arrested spermatocytes in different stage in division were observed. These findings were significantly decreased in IR+EA group. In biochemical analysis, IR lead to a significant increased in TBARS levels and significant decrease in GSH, SOD, GPxand CAT levels in testis tissue compared with other groups. Besides, in the IR+EA group there was an attenuated increased inTBARS levels and an increase in GSH, SOD, GPx and CAT activities.
CONCLUSION: As a result of Ellagic acid have protective effects againts the reproductive damage which created with Irinotecan.

Keywords: Irinotecan, Testis, Ellagic acid, Rat, Caspase-3.

10.5505/2017ichc.PP-192 [Developmental and reproductive biology]

Testicular Effects of Prenatal and Lactational Exposure to Bisphenol A and/or Di-2-Ethylhexyl Phthalate in the Rat Offsprings

Aylin Balcı[1], Naciye Dilara Zeybek[2], Nilgün Yersal[2], Kübra Gizem Yıldıztekin[3], Pınar Erkekoğlu[1], Belma Koçer Gümüşel[1]

[1]Department of Toxicology, Hacettepe University, Faculty of Pharmacy, Ankara, Turkey

[2]Department of Histology and Embriology, Hacettepe University, Faculty of Medicine, Ankara, Turkey

[3]Department of Toxicology, Erzincan University, Faculty of Pharmacy, Erzincan, Turkey

Bisphenol A(BPA) and di-(2-ethylhexyl)phthalate (DEHP) are widely used in the production of various consumer products in industry and they are abundant endocrine disrupting chemicals(EDC). Exposure to these chemicals during prenatal and early postnatal period (specifically in lactation) can cause anomalies in the development of organs, problems in reproduction as well as metabolic and hormonal defects. The present study aimed to evaluate the effects of prenatal and lactational exposure to BPA and/or DEHP on testis of rat offsprings. Pregnant Sprague-Dawley rats were divided randomly to four groups (n=3/group):Controls received corn oil; DEHP group received 30 mg/kg/day DEHP;BPA group received 50 mg/kg/day BPA and DEHP-BPA group received 30 mg/kg/day DEHP and 50 mg/kg/day BPA through 6-21 gestational days by intra-gastric lavage. Dams continued to receive EDCs during the lactation period as well (for21 days). After 21st postnatal day, male offsprings (n=6/group) from each mother were fed until the end of the tenth postnatal week and were then euthanized. Testis was weighed and fixed. Paraffin sections were stained with hematoxylin and eosin and apoptosis was assessed by TUNEL assay. DEHP-exposed dams gained less weight during the gestation period. Mean testis weights were not different than control in BPA, DEHP and DEHP-BPA groups. However, relative testis weights were markedly lower in BPA group vs. DEHP group ($p=0.01$). DEHP exposure caused significant decreases in the pup body weights vs. control ($p<0.01$). There were few primary spermatocytes in DEHP, BPA and DEHP-BPA groups compared to control. The nuclei of differentiating cells of the seminiferous epithelium was lacking in some animals belonging to DEPH group. In addition, vacuoles were observed in-between the Sertoli cells and germ cells of the DEHP group. In BPA group lipid droplets were observed in the cytoplasm of Sertoli cells. In DEPH-BPA group, the spermatogonium was missing at the basal compartment. Big vacuoles and lipid droplets were observed in Sertoli cells. Besides, apoptosis was altered in DEHP, BPA and DEHP-BPA groups as evidenced by TUNEL assay.
The results indicate that BPA and DEHP can lead to altered structure and apoptosis in the testis of rats exposed to these compounds prenatally or postnatally.

Keywords: Bisphenol, di-(2-ethylhexyl)phthalate, testis, rat

10.5505/2017ichc.PP-193 [Developmental and reproductive biology]

Evaluation of ultrastructural changes in the rat ovary after internal iliac artery ligation

Servet Hacıvelioğlu[1], Işık Ünal[2], Mert Çalış[3], Lale Karakoç Sökmensüer[2], Figen Kaymaz[2]

[1]Department of Obstetrics and Gynecology, Osmangazi University, Eskişehir, Turkey

[2]Department of Histology and Embryology, Hacettepe University, Ankara, Turkey

[3]Department of Plastic Reconstructive and Aesthetic Surgery, Hacettepe University, Ankara, Turkey

INTRODUCTION: Obstetric hemorrhage remains the leading cause of maternal death and severe morbidity worldwide. Uterine atony is the most common cause of hemorrhage. Other risk factors are abnormal placentation, coagulation disorders and trauma that can also lead significant morbidity and mortality. Internal iliac artery ligation (IIAL) is one of the treatment methods used to treat obstetric hemorrhage. However, efficiency of the collateral circulation in patient after IIAL is still unclear. The aim of this study is to evaluate the effect of IIAL on ovarian blood supply and ovarian reserve by electron microscopy.

MATERIALS AND METHODS: Fifteen female Sprague Dawley rats were randomly divided into two groups.The sham group (n=8) had a lower abdominal incision without any further surgery. In ligation group (n=7), both iliac arteries were dissected and ligated with hemoclip. Then the abdominal incision was sutured. After 15 days, laparotomy was performed and ovaries were removed. Ovarian tissues were quickly separated into 1 mm3. They were fixed with glutaraldehyde and osmium tetroxide. One micrometer semi-thin sections were obtained and 70 nm ultrathin sections were cut. Ultrathin sections were double stained with uranyl acetate and lead citrate. These sections were examined in electron microscope and photographed by a CCD camera.

RESULTS: In the electron microscopic evaluation of the ovaries in sham group, oocytes and the granulosa cells were observed with normal structure, penetrating microvilli from both sides through zona pellucida.The theca interna cells were seen in normal structure with lipid droplets in the cytoplasm.

In ligation group, oocytes had normal structure with numerous mitochondria. In some areas fewer penetrating microvilli were observed from both oocyte and granulosa cells. In some of the follicles, few granulosa cells were observed with apoptotic changes including chromatin condensation, increase in cellular electron density and cell shrinkage.Theca interna cells have more numerous lipid droplets than the sham goup. In some arteriols the endothelial cells were seen bulging towards the lumen due to vasoconstriction.

CONCLUSION: As a treatment method used for obstetric hemorrhage, internal iliac artery ligation can effect the ovarian reserve by changing the blood supply. The long-term effects of IIAL on ovarian function remain unknown.

Keywords: internal iliac artery ligation, ovarian reserve, ovarian follicle ultrastructure

Figure-1

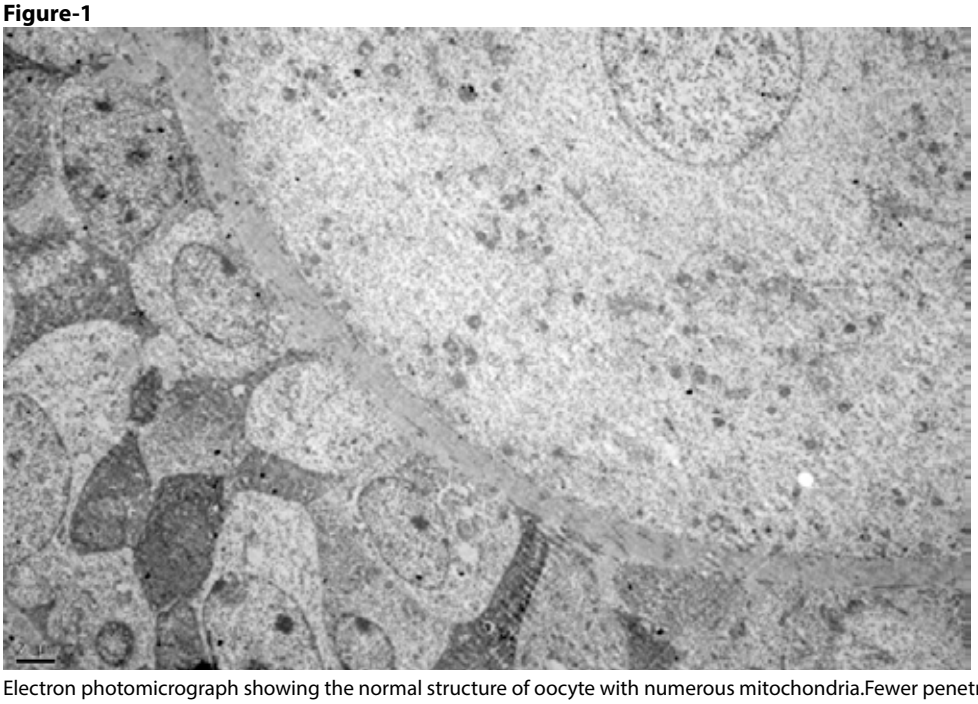

Electron photomicrograph showing the normal structure of oocyte with numerous mitochondria.Fewer penetrating microvilli were observed from both oocyte and granulosa cells.The granulosa cells were observed with chromatin condensation, increase in cellular electron density and cell shrinkage; Ligation group, X 4000 magnification

Figure-2

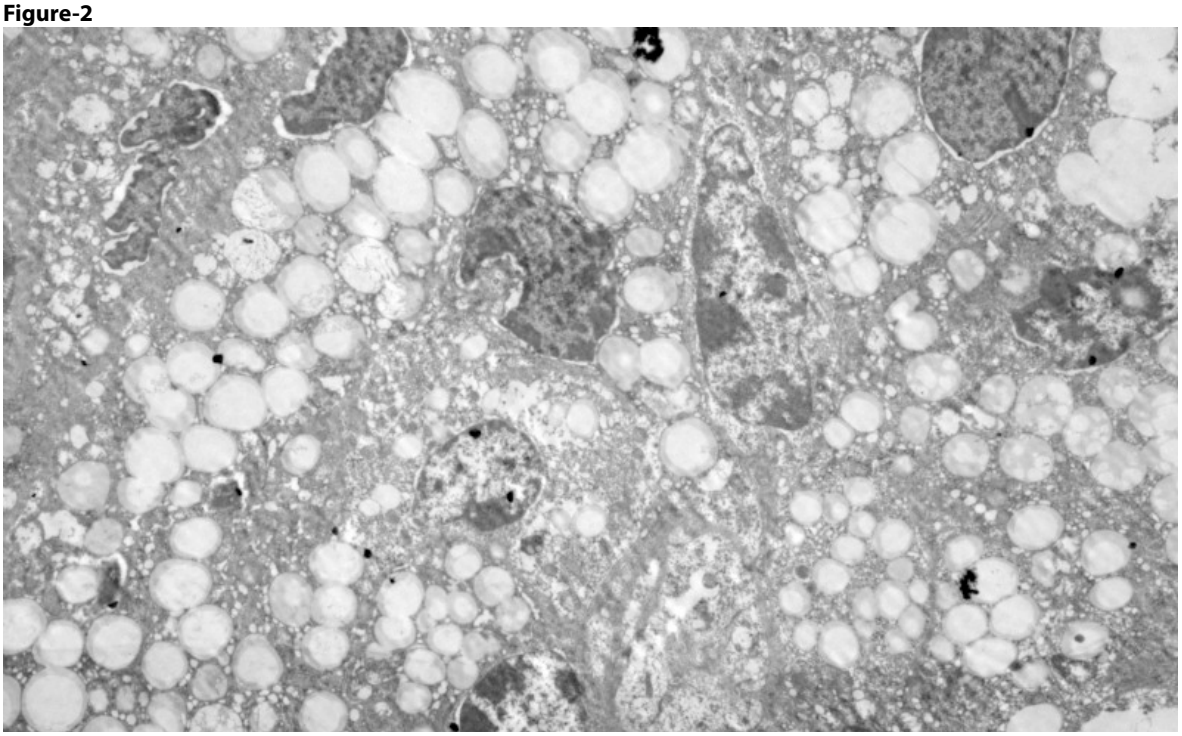

Electron photomicrograph showing the theca cells with numerous lipid droplets in the cytoplasm, ligation group, X 6000 magnification

Figure-3

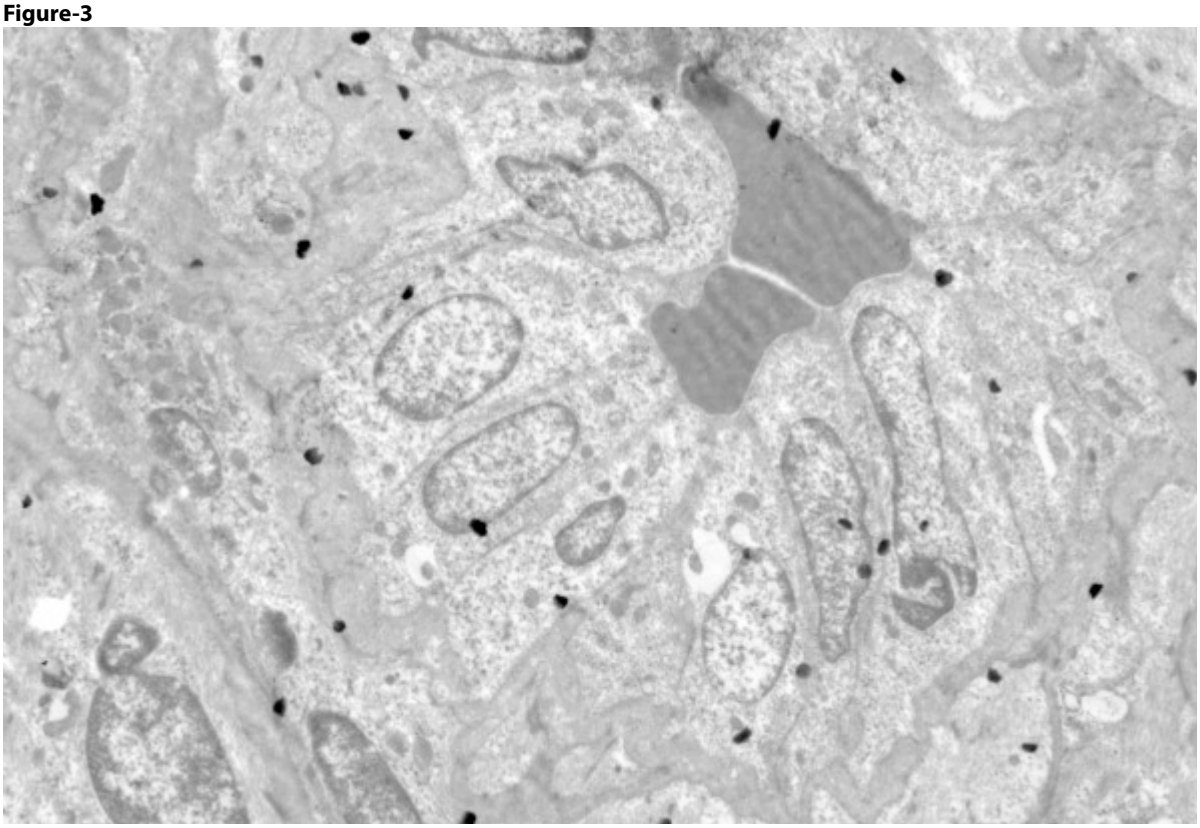

The endothelial cells were seen bulging towards the lumen due to vasoconstriction, ligation group, X 8000 magnification

10.5505/2017ichc.PP-194 [Developmental and reproductive biology]

'The investigation of paricalcitol effects on testicular tissue exposed to subchronic 1800 MHz electromagnetic field

Burcu Demirbağ[1], Savaş Aktaş[1], Metin Yıldırım[2], Ülkü Çömelekoğlu[3], Didem Derici Yıldırım[4], Kezban Kibar[1]

[1]Department of Histology and Embryology, Mersin University, Mersin, Turkey

[2]Department of Biochemistry, Mersin University, Mersin, Turkey

[3]Department of Biophysics, Mersin University, Mersin, Turkey

[4]Department of Biostatistics and Medical Informatics, Mersin University, Mersin, Turkey

INTRODUCTION: It is well-known that exposure to electromagnetic field (EMF) may lead to male in fertility by causing changes in the testicular tissue. The present study aimed to investigate the effect of paricalcitol on the testicular morphology and function after exposure to 1800 MHz EMF.
MATERIALS-METHODS: In our study we used 28 male Wistar rats (8 to 10 weeks of age) and they were divided into four groups; as control (C), paricalcitol (P), electromagnetic field (EMF) and electromagnetic field+paricalcitol (EMF+P). No treatment was applied to control group (n=7). In P group animals were injected with 0,2 µg/kg paricalcitol (3 times/week for 30 days) subcutaneously (sc). EMF group was exposed to EMF of 1800 MHz (1 h/day for 30 days). EMF+P group was both exposed to EMF of 1800 MHz (1 h/day for 30 days) and injected with 0,2 µg/kg paricalcitol sc (3 times/week for 30 days). At the end of the experiment, tissues were evaluated by histological and biochemical analysis.
RESULTS: Johnsen score EMF+P group and C group were similar but EMF+P group showed a significant increase compared to EMF group (Figure 1). Ki67 and p63 immunoreactivity scores (IRS) showed a significant decrease in EMF+P group compared to C group. Ki67 and p63 IRS increased significantly in EMF+P group compared to EMF group (Figure 2, 3, 4). There was no significant difference in malondialdehyde (MDA) levels between EMF+P and C groups. However EMF group was significantly lower than EMF+P group (Figure 5). The superoxide dismutase (SOD) level of EMF+P group didn't show a significant increase compared to EMF group but significantly decreased compared to C group (Figure 6). Catalase (CAT) activity of EMF+P group did show significant increase compared to EMF group whereas it didn't show any significant difference compared to C group (Figure 6).
CONCLUSION: It was concluded that paricalcitol may have protective properties against the adverse effects of EMF on spermatogenesis. We suggests that paricalcitol may have regulatory effects on apoptosis and proliferation of germ cells by altering the antioxidant mechanism.

"This study was supported by the Research Fund of Mersin University in Turkey (2016-1-TP2-1406)".

Keywords: Antioxidan capacite, electromagnetic fields, testis, Ki67, p63, paricalcitol.

Figure 1

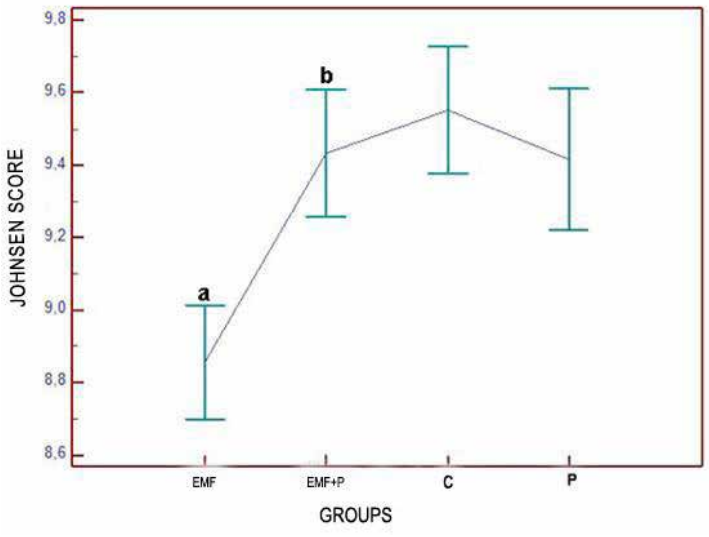

Comparison of Johnsen scores between groups. aEMF group score was significantly lower than EMF+P and C scores ($p<0.05$ and $p<0.05$). bEMF+P group score did not significant difference from C group ($p=1.000$) but was significantly higher than from EMF group ($p<0.05$).

Figure 2

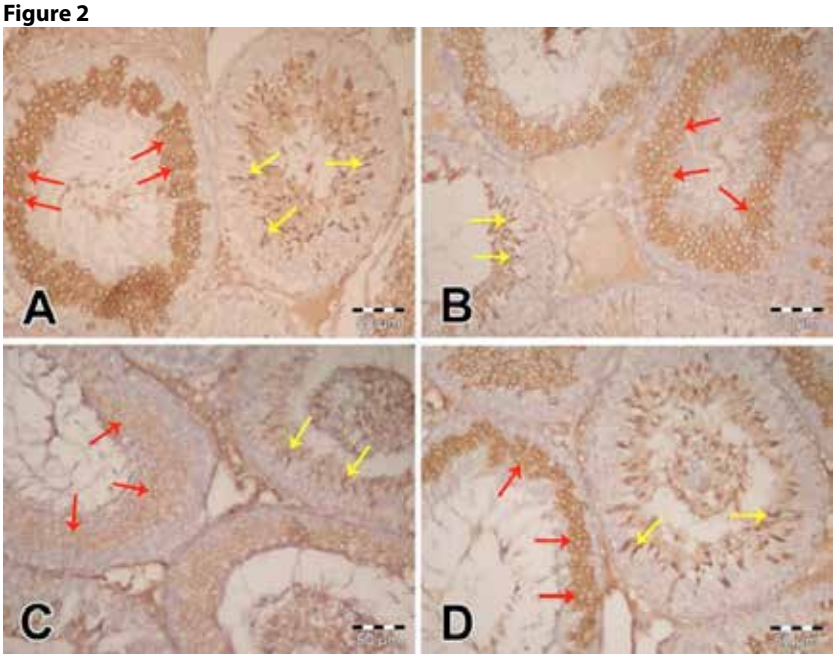

In seminiferous tubule, p63 immunostaining in early (red polar) and late spermatids (yellow arrows). A. C group, B. P group, C. EMF group, D. EMF+P group (Indirect peroxidase X600).

Figure 3

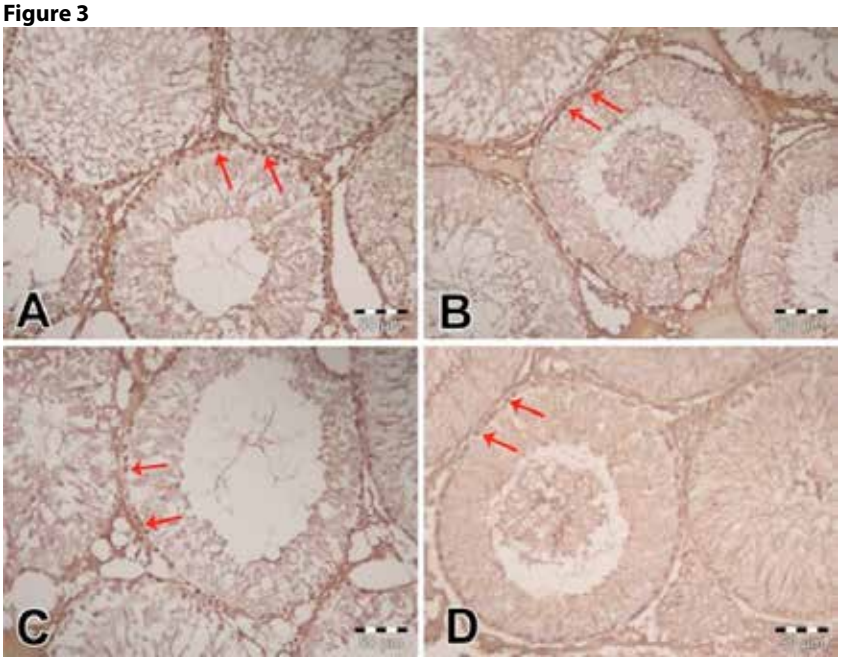

In seminiferous tubules, Ki67 immunostaining of spermatogonium (red arrows). A. C group, B. P group, C. EMF group, D. EMF+C group (Indirect peroxidase X600).

Figure 4

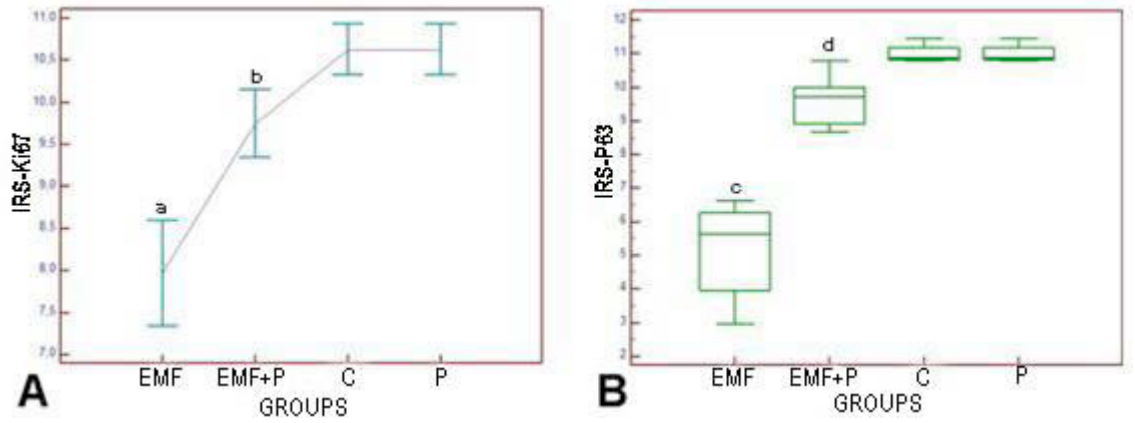

Comparison of Ki67 IRS (A) and p63 IRS (B) in groups. aThe Ki67 IRS of EMF group was significantly lower than the EMF+P and C groups ($p<0.05$ and $p<0.05$) (A). b The Ki67 IRS of EMF+P group was significantly lower than C group ($p<0.05$) but it was significantly higher than the EMF group ($p<0.05$) (A). cEMF group p63 IRS was significantly lower than the EMF+P and C groups ($p<0.05$ and $p<0.05$) (B). dThe p63 IRS of EMF+P group was significantly lower than of C group ($p<0.05$) but It was significantly higher than the EMF group ($p<0.05$) (B).

Figure 5

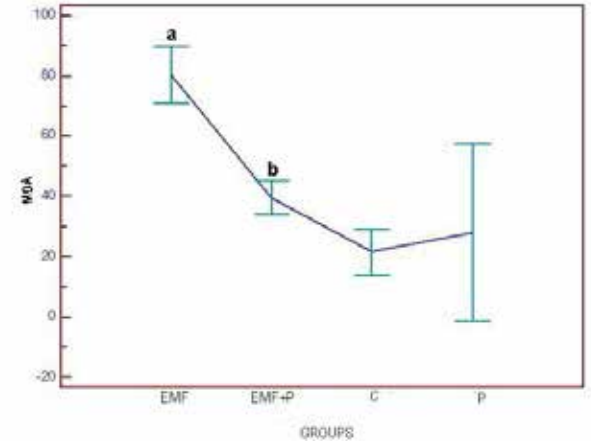

Comparison of MDA levels of groups. aMDA level of EMF group was significantly higher than MDA levels of EMF+P and C groups ($p<0.05$ and $p<0.05$). bMDA level of EMF+P group did not significantly difference from group C ($p=0.227$) but It was significantly lower than group EMF ($p<0.05$).

Figure 6

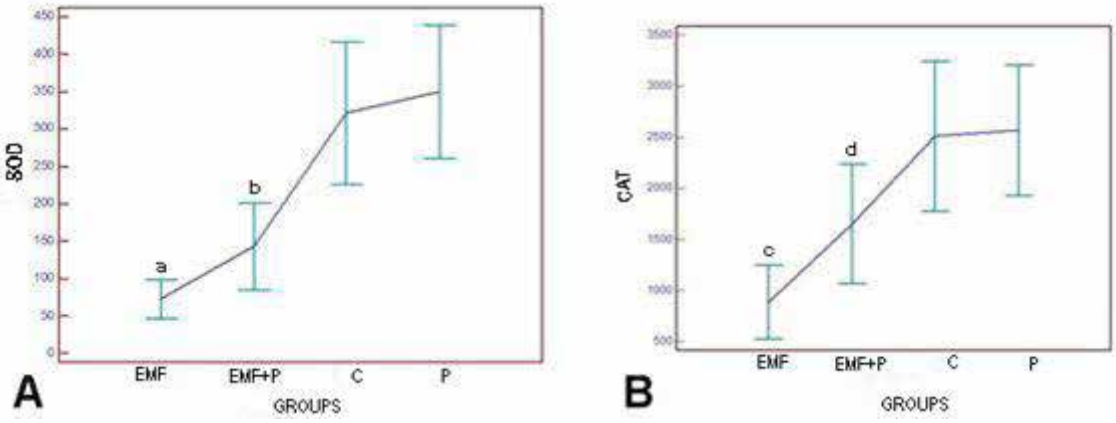

Comparison of testicular SOD (A) and CAT (B) levels in groups. aThe SOD level of the EMF group did not significantly difference from EMF+P group ($p=0.104$), but It was significantly lower than C group ($p<0.05$). (A). bThe SOD level of the EMF+P group didn't show a significant increase compared to the EMF group ($p=0,104$) but significantly decreased compared to the C group ($p<0.05$) (A). cThe CAT level of the EMF group was significantly lower than EMF+P and C groups ($p<0.05$ and $p<0.05$) (B). dThe CAT activity of the EMF+P group did show a significant increase ($p<0.05$) compared to the EMF group whereas it didn't show any significant difference compared to C group ($p=0,208$) (B).

10.5505/2017ichc.PP-195 [Developmental and reproductive biology]

Immunohistochemical investigation of TLR4 in rat testis and epididymis during postnatal development

Mehmet Özbek[1], Emel Ergün[2], Feyzullah Beyaz[3], Levent Ergün[2], Nuh Yıldırım[2], Özge Özgenç[2], Füsun Erhan[2]

[1]Mehmet Akif Ersoy University, Faculty of Veterinary Medicine, Department of Histology and Embryology, Burdur, Turkey

[2]Ankara University, Faculty of Veterinary Medicine, Department of Histology and Embryology, Ankara, Turkey

[3]Erciyes University, Erciyes University, Faculty of Veterinary Medicine, Department of Histology and Embryology, Kayseri, Turkey

Introduction: The testis exemplifies an immune privileged organ where both allo- and auto-antigens can be tolerated without evoking immune rejection. The testis can be infected by various microbial pathogens derived from circulating blood or that ascend the genitourinary tract. To elicit an appropriate and effective local reaction against invading pathogens, testicular cells have to cope with immune privilege. The role of the pattern recognition receptors in the initiation of testicular natural immunological responses has begun to emerge.
This study was conducted to demonstrate expression of TLR4 in the testis and epididymis in the postnatal period in rats.
Materials & Methods: The material of the study consisted of testis and epididymis tissues taken from the wistar albino rats. Each of the four groups composed of six rats were designed as prepubertal (5 days), pubertal (20 days), postpubertal (50 days) and mature (70 days). Immunohistochemical staining was performed with the primary antibody to TLR4 by using StreptAvidin Biotin (Strep-ABC) method.
Results
A remarkable immunological reaction was not observed in the seminiferous tubules of rats aged 5 days. At 20 old day rats, 50 day old rats and 70 old day rats, a large proportion of seminiferous tubules and peritubular myoid cells show weak immun reaction, while a more severe reaction was observed in some interstitial cells and some cells in some spermatogenic series facing the lumen of the seminiferous tubules. İn the epididymis, a weak reaction was observed in epithelial cells and smooth muscle at 5 old day rats. At 20 old day rats, the intense reaction was observed on the apical faces of the epithelial cells and in the smooth muscles around the epithelial cells. In the epididymis of 50 and 70 day old rats, a very intense reaction was observed in some epithelial cells, some pyramidal epithelial cells whose apical faces reached the lumen, and smooth muscles around the epithelial cells.
Conclusion : The increase of TLR4 expression after puberty in both the seminiferous tubule and the epididymis suggests that TLR4 may be responsible for the continuity of spermatogenesis and protection of spermatozoa against pathogens.

Keywords: TLR-4, testis, epididymis, rat, immunohistochemistry

10.5505/2017ichc.PP-196 [Neuroscience]

PML nuclear bodies are differentially expressed among various neuronal subtypes of the mouse cerebellum

Iwona Czaban[1], Malgorzata Broszkiewicz[1], Andrzej Szczepankiewicz[1], Satyam Patel[2], Agnieszka Walczak[1], Robert Pawlak[2], Adriana Magalska[1], Grzegorz Marek Wilczyński[1]

[1]Nencki Institute of Experimental Biology, Warsaw, Poland

[2]University of Leicester, Leicester, United Kingdom

PML is a tumor-suppresor protein involved in the pathogenesis of promyelocytic leukemia. In proliferating mammalian cells, PML is a principal component of characteristic nuclear bodies, which also contain multiple other proteins. Typically there are several PML bodies per nucleus; they form round sub-micrometer foci scattered throughout the interchromatin space, and do not contain nucleic acids. The molecular function of PML protein is unclear, yet the majority of data points to its involvement in regulation of gene-expression and/or intranuclear protein storage and degradation. In brain, PML has been implicated in the pathogenesis of neurodegenerative disorders, glioma and, very recently, in the control of embryonic neurogenesis. However, it is not clear whether the protein is expressed, and has a function, in the normal adult brain. Therefore we have investigated the expression and localization of PML at the cellular and subcellular levels, in the adult mouse brain, focusing on the cerebellum. By immunofluorescence, PML bodies were found in a subset of neurons in the cerebellar cortex. Particularly strong and rather diffuse PML immunoreactivity was found in the nuclei of Purkinje cells. Our study indicates that PML protein and the PML bodies can play a role in the cerebellar function.

Keywords: PML bodies, PML protein, cerebellar cortex, Purkinje cells

10.5505/2017ichc.PP-197 [Neuroscience]

The Ultrastructural And Molecular Changes In Motor Cortex And Spinal Cord Ventral Horn Motor Neurons Of Rats Exposed To Chronic High Intensity-Intermittent Running Exercise

Zelal Keleş[1], Güleser Göktaş[2], Deniz Erbaş[1], Haydar Ali Demirel[3], Saadet Özen Akarca Dizakar[4], Çiğdem Elmas[4]

[1]Department of Physiology, Gazi University, Ankara, Turkey

[2]Department of Histology and Embryology, Başkent University, Ankara, Turkey

[3]Department of Exercise and Sport Physiology, Hacettepe University, Ankara, Turkey

[4]Department of Histology and Embryology, Gazi University, Ankara, Turkey

OBJECTIVE: Scientific data on the type of ultrastructural and molecular responses at motor neuron level brought about by long term high intensity exercise or intensive physical activity is scarce. The aim of this study was to evaluate the ultrastructural morphological and molecular changes in the motor neurons at the motor cortex and in ventral horn motor neurons at the cervical and lumbar spinal cord in rats following chronic high intensity-intermittent running exercise.
MATERIAL-METHODS: 30 Wistar albino male rats were distributed into three groups: A: a sedentary control group, B: a group which received moderate intensity-continuous exercise (MICE) 5 days/ week for 13-15 weeks and C: a group which received high intensity-intermittent exercise (HIIE) 5 days/ week for 13-15 weeks. At the end of the observational and experimental period of 13-15 weeks, all the animals were sacrificed and spinal cord was removed. Early apoptotic markers cytochrome c and Bcl-2 were evaluated by immunohistochemical method for investigating mitochondrial dysfunction in motor neurons and glial cells. Ultrastructural morphologic evaluations were carried out by electrone microscope.
RESULTS: Unlike other groups a tendency of reduction in antiapoptotic Bcl-2 immunoreactivity and a tendency of rise of proapoptotic cytochrome c immunoreactivity were observed at all three anatomic levels in the HIIE group, but these changes were not pronounced. Sporadic apoptotic cell changes were observed by electron microscopic evaluation in the HIIE group.
CONCLUSION: Although chronic high intensity-intermittent running exercise did not lead to a pathologic apoptotic process or to degeneration in rat motor neurons the non-significant changes in cytochrome c and Bcl-2 immunoreactivities can be considered as a mitochondrial dysfunction trend failing to activate caspases.

Keywords: Chronic high intense-intermittant exercise, motor cortex, cytochrome c, Bcl-2

Figure 1

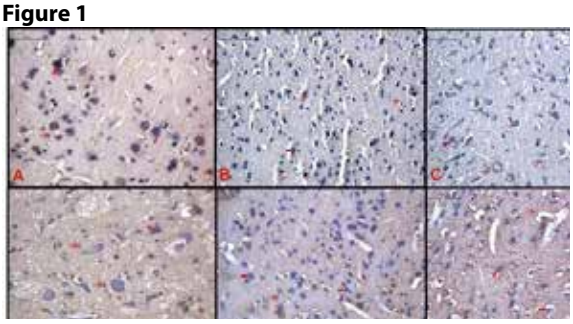

Bcl-2 immunostaining in motor cortex of the control (A), moderate intensity-continuous exercise (B), high intensity –intermittent exercise (C) groups and cytochrome c immunostaining of the control (D), moderate intensity-continuous exercise (E), high intensity –intermittent exercise (F) Neurons (□) and glial cells (ȃ). (immunoperoxidase-Hematoxylin magnification 400x)

Figure 2

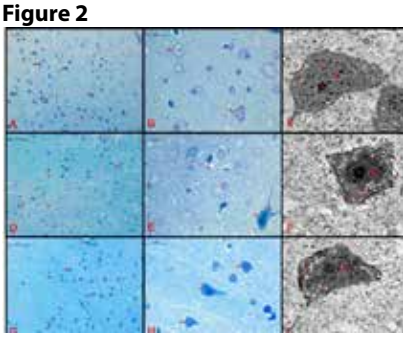

Motor cortex, of control group (A,B,C), moderate intensity-continuous exercise group (D,E,F) and high intensity –intermittent exercise group (G,H,I); neuron (□), glial cells (ȃ), vessel (ȉ), Nissl body(∅), edema(ȍ), nucleus (ȣ), nucleolus (ˑ), granular endoplasmic reticulum(ȹ) and mitochondrion (ˋ). Toluidine blue-stained semi-thin cross sections and Uranyl acetate and lead citrate stained thin section (C, F, I).

Figure 3

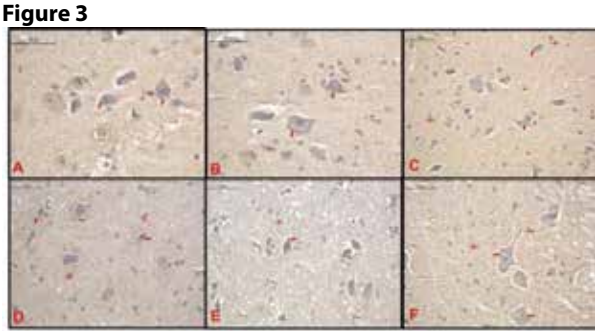

Bcl-2 immunostaining in spinal cord cervical region of the control (A), moderate intensity-continuous exercise (B), high intensity –intermittent exercise (C) groups and cytochrome c immunostaining of the control (D), moderate intensity-continuous exercise (E), high intensity –intermittent exercise (F) Neurons (□) and glial cells (∂). (immunoperoxidase-Hematoxylin magnification 400X)

Figure 4

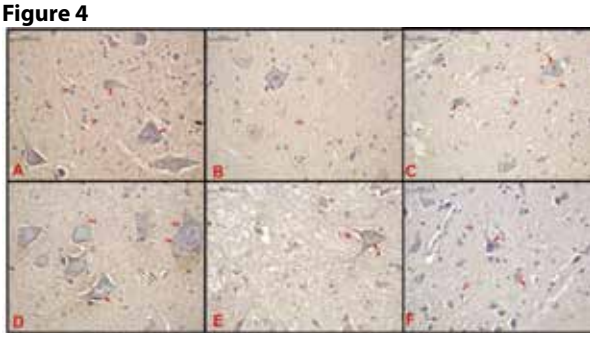

Bcl-2 immunostaining in spinal cord lumbar region of the control (A), moderate intensity-continuous exercise (B), high intensity –intermittent exercise (C) groups and cytochrome c immunostaining of the control (D), moderate intensity-continuous exercise (E), high intensity –intermittent exercise (F) Neurons (□) and glial cells (∂). (immunoperoxidase-Hematoxylin magnification 400X)

Figure 5

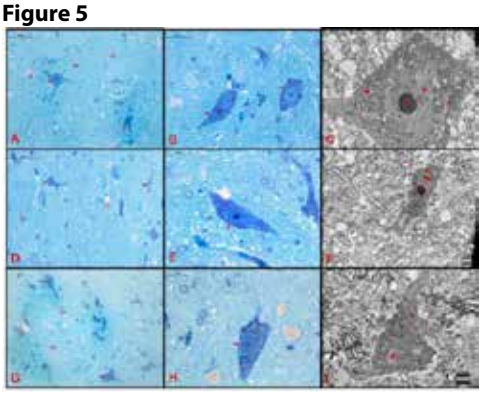

Spinal cord cervical region of control group (A,B,C), moderate intensity-continuous exercise group (D,E,F) and high intensity –intermittent exercise group (G,H,I); neuron (□), glial cells (∂), vessel (/), Nissl body(∅), nucleus (β), nucleolus (·), granular endoplasmic reticulum(¢) and mitochondrion (ˆ). Toluidine blue-stained semi-thin cross sections (A,D,G magnification 400x, B,E,H magnification 100x and Uranyl acetate and lead citrate stained thin section (C, F, I).

Figure 6

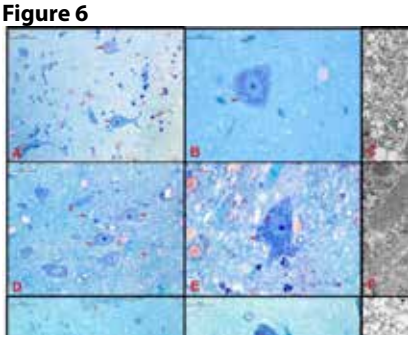

Spinal cord lumbar region of control group (A,B,C), moderate intensity-continuous exercise group (D,E,F) and high intensity –intermittent exercise group (G,H,I); neuron (□), glial cells (∂), vessel (/), Nissl body(∅), nucleus (β), nucleolus (·), granular endoplasmic reticulum(¢) and mitochondrion (ˆ). Toluidine blue-stained semi-thin cross sections (A,D,G magnification 400x, B,E,H magnification 1000x and Uranyl acetate and lead citrate stained thin section (C, F, I).

10.5505/2017ichc.PP-198 [Neuroscience]

Nesfatin-1 improves seizure-induced neuronal damage and memory dysfunction in rats

Turkan Koyuncuoglu[1], Sevil Arabaci Tamer[1], Ayca Karagoz[2], Dilek Akakin[2], Meral Yuksel[3], Berrak C. Yegen[1]

[1]Marmara University School of Medicine, Department of Physiology, Istanbul, Turkey

[2]Marmara University School of Medicine, Department of Histology and Embryology, Istanbul, Turkey

[3]Marmara University Vocational School of Health Related Services, Istanbul, Turkey

INTRODUCTION: Epilepsy is characterized by recurrent seizures that occur by sudden abnormal electrical discharges of neurons. The anorexigenic peptide nesfatin-1 was shown to exert protective effects in several inflammatory models. We aimed to investigate the putative neuroprotective effects of nesfatin-1 in a rat model of seizure-induced neuronal injury.
MATERIALS-METHODS: Following an initial passive avoidance test (PAT), male Wistar rats (n=60) were divided into control and pentylenetetrazole (PTZ)-induced seizure groups. Thirty minutes prior to PTZ (45 mg/kg; intraperitoneal, ip) injection, saline or nesfatin-1 (0.3 µg/kg, 1 µg/kg, 3 µg/kg) was administered ip, and injections were repeated at 24th and 48th hours of seizures. Control rats were injected with saline, but not with PTZ. Seizures were scored based on Racine's scale. At the 72nd hour, PAT was repeated to evaluate memory function, and then rats were perfused with 4% paraformaldehyde. Paraffin blocks were stained with hematoxylene and eosin, and examined immunohistochemically using glial fibrillary acidic protein (GFAP) antibody (astrocyte marker). Apoptotic cells were determined by TUNEL. Statistical analysis was performed by ANOVA and Student's t tests.
RESULTS: Percentage of rats that had tonic-clonic seizures and their average seizure-scores were reduced in nesfatin-1-treated PTZ group (1µg/kg; $p<0.05$). While the control rats avoided entrance to dark-chamber in 300 sec (cut-off) where they have received electrical shock, rats in saline-treated PTZ group entered in 93.3±45.5 sec, indicating memory dysfunction. Nesfatin-1 treatment at 0.3, 1 and 3 µg/kg doses increased the delay in entrance (228.8±46.7, 206.5±46.0 and 264.9±35.1 sec, respectively). Neuronal cell degeneration in cerebral cortex and hippocampal CA3 and dentate gyrus (DG) areas of saline-treated PTZ group ($p<0.001$) was ameliorated in nesfatin-1 (0.3 µg/kg and 1 µg/kg)-treated rats ($p<0.05$). Increased TUNEL-positive (apoptotic) cells were determined only in the cortices of PTZ-administered rats compared to control rats, but no significant differences were observed by nesfatin-treatment. Increased GFAP immunolabelling, determined in the hippocampus and cortices of PTZ-administered group as compared to controls, was reduced in nesfatin-1 (0.3 µg/kg) treated group.
CONCLUSION: Nesfatin-1 exerted neuroprotection on seizure-induced brain injury and improved memory dysfunction by a dose-dependent manner.

Keywords: Epilepsy, pentylenetetrazole, nesfatin-1, hippocampus

10.5505/2017ichc.PP-199 [Neuroscience]

Synaptic Alterations in the Rat Hippocampus After Irradiation and Hyperthermia

Gözde Erkanlı Şentürk[1], Ozlem Tugce Kaya[2], Serap Şirvancı[2], Cenk Umay[4], Filiz Onat[3], Çiğdem Özkara[5], Mustafa Uzan[6], Feriha Ercan[2]

[1]Bahcesehir University, School of Medicine, Department of Histology and Embryology, Istanbul, Turkiye

[2]Marmara University, School of Medicine, Department of Histology and Embryology, Istanbul, Turkiye

[3]Marmara University, School of Medicine, Department of Pharmacology and Clinical Pharmacology, Istanbul, Turkiye

[4]Istanbul University, Cerrahpasa Medical Faculty, Department of Radiation Oncology, Istanbul, Turkiye

[5]Istanbul University, Cerrahpasa Medical Faculty, Department of Neurology, Istanbul, Turkiye

[6]Istanbul University, Cerrahpasa Medical Faculty, Department of Neurosurgery, Istanbul, Turkiye

INTRODUCTION: In utero irradiated rat model shares clinical and histopathological features with cortical developmental malformation in human, characterized by widespread neuronal degeneration. Experimental studies showed that seizures induced by hyperthermia (HT) led mortality due to neuronal loss. The aim of this study was to investigate ultrastructural synaptic alterations in rat hippocampus after in utero exposure to irradiation (IR) and postnatal exposure to HT.
MATERIALS-METHOD: There were four groups: 1) IR group: Pregnant rats were exposed to 100 cGy radiation in 17th gestational day. 2) HT group: Hyperthermia was applied to the rat pups on postnatal 10th day. 3) IR+HT group: Both IR and HT were applied at the same time-period. 4) Control group: No IR or HT was applied. All experimental groups were perfused with 4% paraformaldehyde 3 or 6 months later. Thin sections from CA3 and dentate gyrus regions of the dorsal hippocampus were evaluated by transmission electron microscope for synapse counts. In each section, at least five micrographs were taken blindly at x20k magnification. Synapses were counted, divided by the area of the micrograph, and statistical analysis was performed.
RESULTS: In all experimental groups, disruption in myelin sheath, decrease in vesicles in mossy terminals, and vacuolization in neuropil were observed in both CA3 and DG regions. In CA3 region; synaptic count was significantly increased in IR 3 months, IR 6 months, and IR+HT 3 months groups, compared to the control group. The number of synapses was significantly increased in HT 3 months group, compared to the control group in DG region. A tendency for increased number of synapses was seen in the other experimental groups in CA3 and DG regions compared to the control groups; however, the differences were not statistically significant.
CONCLUSION: The results of the present study suggest that the increased number of synapses in the rat hippocampus may be due to mossy fiber sprouting, possibly caused by in utero irradiation and/or postnatal hyperthermia.
Acknowledgement:
This study was supported by Marmara University Scientific Research Commission (SAG-BGS-150107-0015).

Keywords: Radiation, hyperthermia, hippocampus, synapse

Figures: Immunohistochemical staining results of the kidney tissue sections.

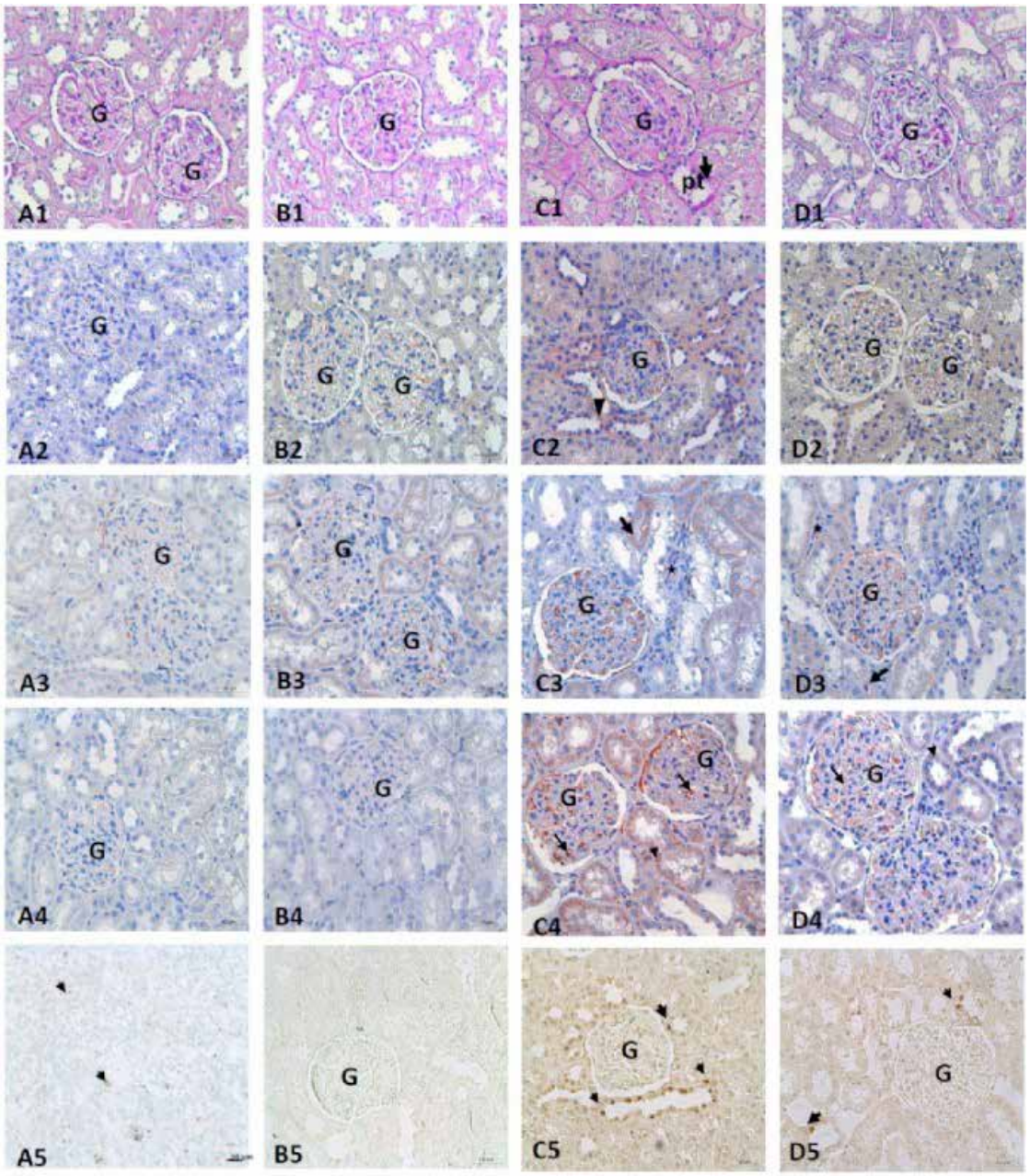

Kidney sections of non-diabetic control (A), quercetin control (B), untreated diabetic (C), quercetin treated diabetic group (D). (1) PAS staining, (2) Immunoreactivity of caspase-3, (3) bcl-2, (4) bax and (5) TUNEL staining. (pt: proximal tubuli; G: glomeruli; <: immunopositivity; *, interstitial area <: apoptotic cell nucleus). Bar: 40 µm, Counterstain: Haematoxylin, methyl green (for TUNEL staining).

Table: Evaluation of apoptotic cell counts in the kidney tubules.

Groups	Apoptotic cell count
Non-diabetic Control	1,65±0,25
Quercetin Control	1,71±0,27
Untreated diabetic	13,79±3,12 a
Quercetin treated diabetic	6,41±1,66 b,c

Values are mean ± SD. a,b P < 0.001 vs. controls, c P < 0.001 vs.untreated diabetic group.

10.5505/2017ichc.PP-200 [Neuroscience]

GABA Immunocytochemistry and Evaluation of Synaptic Length in the Somatosensory Cortex of Absence Epileptic Rats Receiving Kindling Stimulations

Furkan Bölükbaşı[1], Özlem Tuğçe Kaya[1], Tuğba Karamahmutoğlu[2], Filiz Onat[2], Serap Şirvancı[1]

[1]Department of Histology and Embryology, Faculty of Medicine, Marmara University, Istanbul, Turkey

[2]Department of Medical Pharmacology, Faculty of Medicine, Marmara University, Istanbul, Turkey

AIM: GABA has been investigated widely in the studies for enlightening the mechanisms of epilepsy. Alterations in GABA levels were demonstrated in epileptic conditions. GAERS is a genetic model of absence epilepsy and has been used in studies comparing temporal lobe and absence epilepsies. The present study aimed to examine GABA density and synaptic length in the somatosensory cortex of GAERS after electrical kindling stimulations at the ultrastructural level.
MATERIALS-METHOD: A total of 6 stimulations were applied to Wistar rats and GAERS for electrical kindling. Animals were sacrificed by perfusion fixation 1 hour after the last stimulation. Cortical tissues were routinely processed for transmission electron microscopy, and thin sections were obtained. Immunogold method was applied by using anti-GABA primary antibody and secondary IgG antibody conjugated to 10 nm gold particles. Ten micrographs were taken from each animal. GABA density and synaptic length in the GABAergic terminals were calculated by using NIH Image Analysis (Image J) program. Statistical analysis was performed using One-Way ANOVA and Tukey multiple comparison tests.
RESULTS: It was found that the GABA density was significantly decreased, and the synaptic length was significantly increased in the Wistar kindling group, compared to the sham-operated Wistar control group. GABA density showed a tendency to decrease, and synaptic length to increase, in GAERS kindling group, compared to the sham-operated GAERS control group; however, the differences were not statistically significant.
DISCUSSION: The reduction in GABA density in Wistar kindling group in the present study is in line with the previous studies demonstrating inhibitory cell loss in temporal lobe epilepsy. Decreased GABA in this group may have resulted in a compensatory increase in the synaptic length. On the other hand, a lack of significant reduction of GABA in the cortex of GAERS kindling group may be related to the resistance of this strain to kindling stimulations.

Keywords: Absence epilepsy, GAERS, kindling, GABA, cortex

10.5505/2017ichc.PP-201 [Neuroscience]

Hypothyroidism Changes the Immunoreactivity of MAP-2 in the Adult Rat Cerebral Cortex

Ayşegül Burçin Yıldırım[1], Saim Özdamar[2], Betül Yalçın[2], Arzu Yay[2]

[1]Department of Histology and Embriyology, Kahramanmaraş Sütçü İmam Üniversitesi, Kahramanmaraş,Turkey

[2]Department of Histology and Embriyology, Erciyes Üniversitesi, Kayseri,Turkey

The microtubule-associated protein (MAP-2) is an essential part of the cytoskeleton and plays an important role in neural morphogenesis. This protein is an indispensable component of the dendritic cytoskeleton, especially in the adult brain, and its expression can be altered under experimental or pathological conditions (1). Thyroid hormone plays a very important role in the development of the central nervous system (2). Hypothyroidism disrupts brain function in both humans and rats (3, 4). The aim of this study is to evaluate immunohistochemically the effect of hypothyroidism on MAP-2 expression in the rat cerebral cortex.
12 Wistar-albino adult female rats were divided into two groups, namely hypothyroidism (H) and control (C) groups. Hypothyroidism was induced by adding %0.01 of propylthiouracil (PTU). Group H were given PTU for 42 days. Group C (control) were only given water.
At the end of the treatment period, hypothyroidism and control group rats brain tissues were removed by decapitating and to determine distribution of MAP-2 and cell structure at cortex in coronal sections of brain tissue, immunohistochemical staining method was performed in the brain tissues. MAP-2 immunreactivity was measured in the cerebral cortex by Image J program. Blood samples of rats in groups H and C were taken. T3, T4 and TSH values were measured by ELISA method. All data were statistically analysed.
In hypothyroid group, statistically significant decrease in MAP-2 expression was observed. It was noted that in some neuronal bodies and dendrites decreased expression of MAP-2. In control group, dendritic extensions were uninterrupted, but it was determined in hypothyroid group, dendritic extensions with the dendritic organization disorder were interrupted. In addition, the decrease in T3 and T4 values of the hypothyroid group and statistically significant increase in TSH values showed that hypothyroidism was realized.
According to the obtained data, it was observed that in adult rat cerebral cortex hypothyroidism caused disruption in neuronal cytoskeleton structure and dendritic organization and decrease in MAP-2 expression.

Keywords: Hypothyroidism, MAP-2, Cerebral Cortex, Immunohistochemistry

10.5505/2017ichc.PP-202 [Neuroscience]

Stereologic and ultrastructural analysis of amniotic membrane covering for sciatic nerve repair

Oya Evirgen[1], Emine Nazli Hayirli[1], Erdal Resit Yilmaz[2], Askin Esen Hasturk[3]

[1]Department of Histology and Embryology, Ankara University School of Medicine, Ankara, Turkey

[2]Department of Neurosurgery, Diskapi Yildirim Beyazit Training and Research Hospital, Ankara, Turkey

[3]Department of Neurosurgery, Abdurrahman Yurtaslan Oncology Training and Research Hospital, Ankara, Turkey

OBJECTIVES: Amniotic membrane has been widely used in ocular surgery and skin injury because of its anti-fibrotic,anti-inflammatory, anti-adhesive and low antigenicity properties. In literature amniotic membrane is also applied in peripheral nerve repair. Wrapping the anastomosis site with amniotic membrane connective tissue matrix sheets after removal of epithelial cells forms an isolated microenvironment that reducing fibrosis and inflammatory cell infiltration. In this study we aimed to evaluate the effects of human(hAM) and rat amniotic membrane(rAM) which was a biological material wrapped around primary epineurial anastomosis(PEA) region on nerve regeneration.
METHODS: Rats were randomly divided into 4 groups as control,PEA after transection,PEA with hAM wrapping and PEA with rAM wrapping. 12 weeks after surgery tissue samples were collected from anastomosis site and fixed with 2.5% glutaraldehyde. After routine tissue processing the samples embedded in araldite. Semi-thin sections(1µm) stained with toluidine-blue and StereoInvestigator(MBF Bioscience) software was used for all stereological analysis. Fractionator probe was used to obtain an estimation of myelinated axon number in an unbiased manner. And a two-dimensional isotropic uniform random nucleator probe was used for estimation of axonal area,axon diameter,fiber diameter and the thickness of myelin sheath using an oil objective(100x). The g ratio values were calculated. Ultra-thin sections were observed under LEO 906 E transmission electron microscope.
RESULTS: The myelinated axon number of the transection injury groups were lower than control group. There were no differences in mean axonal area of myelinated fibers between transection injury groups revealed that there is very little change in the fiber morphology with surgical repair model. A comparison of control and transection injury groups indicated that control group had a thicker myelin sheeth (1,79µm vs 1,29µm; 1,13µm; 1,11 µm). The transection injury groups compared to control showed larger g-ratio(axonal diameter to the total fiber diameter) which corralates to diminished and damaged myelin sheaths of regenerating axons (0,50 vs 0,53; 0,55; 0,56).
CONCLUSION: In conclusion the morphometric analysis suggested that the surcigal treatment of sciatic nerve with hAM and rAM which wrapped around the repair site have similar supportive effects to overall quality of nerve regeneration by providing an appropriate microenviroment.

Keywords: Amniotic membrane, Nerve regeneration, Stereology, Rat

Table 1. Morphometric parameters of sciatic nerve

Groups	Mean Myelinated Axon Number	Mean Axonal Area (µm2)	Mean Fiber Diameter (µm)	Mean Axon Diameter (µm)	Mean Myelin Thickness(µm)	g Ratio
Control	5775± 1617	14.35±2.5	3,6±0,37	1,8±0,16	1.79±0.21	0.50
PEA	3994± 159	9.64±0.9	2,7±0,86	1,45±0,08	1.29±0.78	0.53
PEA+hAM	4823±1986	9.02±4.88	2,5±0,84	1,41±0,39	1.13±0.48	0.55
PEA+rAM	4256±468	9.08±3.47	2,5±0,55	1,41±0,39	1.11±0.31	0.56

10.5505/2017ichc.PP-203 [Neuroscience]

Immunohistochemical Assessment of Direct Communication between Orexin and Nesfatin Neurons

Duygu Gok Yurtseven[1], Zehra Minbay[2], Ozhan Eyigor[2]

[1]Department of Medical Histology and Embryology, Uludag University Institute of Health Science, Bursa, Turkey.

[2]Department of Histology and Embryology, Uludag University Faculty of Medicine, Bursa, Turkey.

INTRODUCTION & OBJECTIVES: In controlling the food intake nesfatin and orexin act in opposite manners, where nesfatin is the suppressing peptide. These peptides are synthesized by neurons located in the hypothalamus. We aimed to assess direct effects of these peptides on each other by using immunohistochemistry. We first analyzed the possibility of direct innervations of peptides on respective neurons. Secondly activation of orexin neurons after nesfatin injection and nesfatin neurons following orexin injection was examined. Expression of c-Fos, phosphorylated-CREB or phosphorylated-STAT5 was used as the activation marker. Male and female animals were included in the studies.
MATERIALS & METHODS: For the first experiment, dual-immunohistochemistry for nesfatin (DAB) and orexin (Ni-DAB) was used. In second experiment, animals were injected with nesfatin or orexin and sections were dual-labeled for respectibe peptide and either of the activation markers.
RESULTS: In the first experiment, nesfatin neurons possess orexin-positive terminals juxta-positioned to the cell bodies. Similar synaptic contacts were not observed for nesfatin neuronal endings on orexin neurons. In second experiment, following orexin injection, c-Fos expression was not detected in nesfatin neurons while all nesfatin neurons were positive for pCREB. c-Fos expression was detected in orexin neurons following nesfatin injection. Although the number of activated orexin neurons were higher in experimental group when compared to control group, the increase was not statistically significant. pCREB expression was detected in about 60% of orexin neurons in both experimental and control animals. pSTAT expression was absent in orexin or nesfatin neurons following respective injections. In all experiments gender differences were not detected.
CONCLUSION: These results suggested that orexin or nesfatin does not possess a direct control mechanism on each other at the level of respective neurons. Although results revealed the possibility of synaptic contact between orexin-positive axonal endings and nesfatin neurons, this needs to be confirmed at the ultrastructural level. Studies also determined that in nesfatin neurons an intracellular pathway involving CREB phosphorylation is active even in basal conditions. In conclusion, it is suggested that the activation of nesfatin or orexin neurons does not involve direct effects of these peptides on each other. (Supported by TUBITAK-113S377).

Keywords: orexin, nesfatin, c-FOS, pCREB, pSTAT, immunohistochemistry

10.5505/2017ichc.PP-204 [Neuroscience]

The Role of Glutamatergic System in the Activation of Neuronostatin Neurons Induced by Refeeding

Sema Serter Kocoglu[1], Cihan Cakir[1], Zehra Minbay[2], Ozhan Eyigor[2]

[1]Department of Medical Histology and Embryology, Uludag University Institute of Health Science, Bursa, Turkey.

[2]Department of Histology and Embryology, Uludag University Faculty of Medicine, Bursa, Turkey.

INTRODUCTION & OBJECTIVES: Neuronostatin, is encoded by the somatostatin gene and involved in the regulation of feeding behavior by suppressing the food intake. Majority of the neuronostatin neurons is localized in the anterior hypothalamic periventricular nucleus. It is well-known that glutamate plays an effective role in the regulation of most of the hypothalamic neurons. The present study investigates whether refeeding after fasting activates neuronostatin neurons and assesess the possible regulatory role of the glutamatergic system on the activation of these neurons.
MATERIALS & METHODS: To determine the effect of refeeding and glutamatergic system on the neuronostatin neurons, three experimental groups consisting of 3-month-old Sprague Dawley rats were designed. After 48 h of fasting; group-1 (refeeding) was allowed to eat ad-libitum for 2 hours, group-2 (fasting) was unfed and group-3 (antagonist+refeeding) was injected intraperitoneal glutamate antagonist (CNQX) before refeeding. In order to assess the activation of the neuronostatin neurons, pSTAT5 expression was used as a marker of neuronal activation. For all groups, the activation of the neuronostatin neurons was assessed by dual immunohistochemical staining for neuronostatin and pSTAT5 on 40-micrometer-thick floating sections. The ratio of pSTAT5-immunoreactive neuronostatin neurons to all neuronostatin neurons was statistically compared between groups.
RESULTS: In the refeeding group, approximately 40.31% of neuronostatin neurons that are localized in periventricular zone were pSTAT5-positive, while this ratio was 14.96% in fasting group. The number of activated neurons was reduced to 17.33% after CNQX injection. The ratio of activated neuronostatin neurons in refeeding group was significantly higher when compared to fasting group. The reduction in the number of activated neurons after the application of CNQX in antagonist+refeeding group was statistically significant when compared to refeeding group.
CONCLUSION: This study showed that the neuronostatin neurons were activated by refeeding through the intracellular JAK/STAT signaling pathway. The application of a glutamate antagonist partially reduced the number of activated neurons which indicates the involvement of glutamatergic system in this mechanism. It is suggested that neuronostatin neurons take part in the regulation of feeding behavior by neuronal activation in order to suppress the food intake and this process is under the control of glutamatergic neurotransmission.

Keywords: Neuronostatin, pSTAT, glutamate, food intake, immunohistochemistry

10.5505/2017ichc.PP-205 [Neuroscience]

Histopathological Evaluation of Hippocampal Astrocytes in Pre-pubertal and Pubertal Pups of Mothers with Hypothyroidism

Ayşegül Burçin Yıldırım[1], Saim Özdamar[2], Betül Yalçın[2]

[1]Department of Histology-Embriyology, Kahramanmaraş Sütçü İmam University, Kahramanmaraş, Turkey

[2]Department of Histology-Embriyology, Erciyes University, Kayseri, Turkey

Absence of TH causes delay in the maturation of glial cells and neurons along with decrease in the number of cells in hippocampus. Glial fibrillary acidic protein(GFAP) is one of the intermediate filament proteins. The aim of this study is to investigate the histopathological changes in the GFAP and the astrocytes in the hippocampus in pups during the pre-pubertal and pubertal periods in cases of hypothyroidism.
A number of 12 pregnant Wistar Albino rats were divided into two groups as A and K (control). Hypothyroidism was achieved by adding PTU(0.01%) into the rats' drinking water. PTU was given to the rats in group A during pregnancy for 21 days. The control group received only water. The newborns from the mother rats in the control group and those with hypothyroidism were sacrificed at day 15 and day 60 after which their brain tissues were extracted and GFAP immunohistochemistry was performed to determine the GFAP+ cell expression and number in the coronal section of the brain tissues and assess the expression density. The GFAP-expressing cells in the hippocampus were considered in cornu ammonis(CA1) and dentate gyrus(DG) using the Image J software. The data were analyzed statistically.
GFAP+ cell numbers of 15 and 60 day old groups were evaluated separately. There was no significant difference in both areas(CA1 and DG) between the A15 and K15 groups. However, there was a statistically significant decrement in the GFAP+ cell numbers in both areas in the A60 group compared with the K60 group(Figure 1). The GFAP expression density in the A-15 group was similar to that in the control group, whereas the expression decreased in the A-60 group(Figure 2). Furthermore, it was worthy of attention that the expression was lower in the astrocytic extensions.
Based on the collected data, it was determined that while there was no change in the CA1 and DG areas of pups at early ages due to maternal hypothyroidism, it decreases astrocyte survival and GFAP+ cell expression during the later ages. These deficiencies in the hippocampal astrocyte functions could play a role in the pathophysiology of the neurological dysfunctions hypothyroidism.

Keywords: Hippocampus, Hypothyroidism, GFAP, Astrocytes

Figure 1

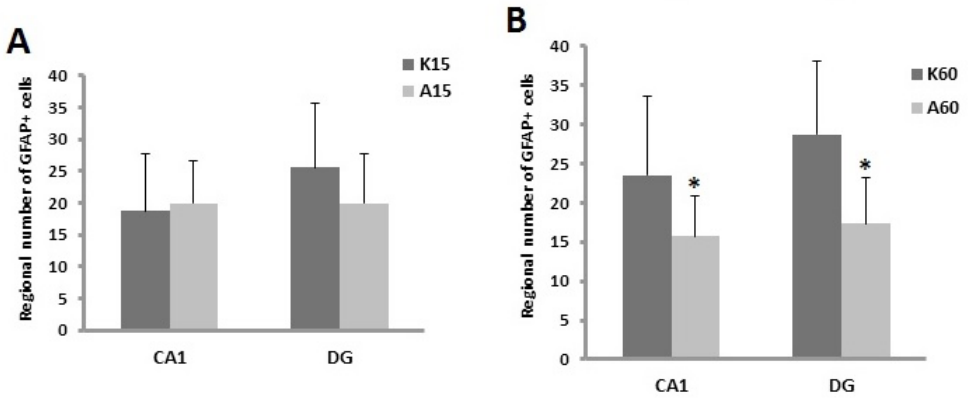

GFAP+ cell number change in CA1 and DG for all groups (different from the control group at the level of *p<.05)

Figure 2

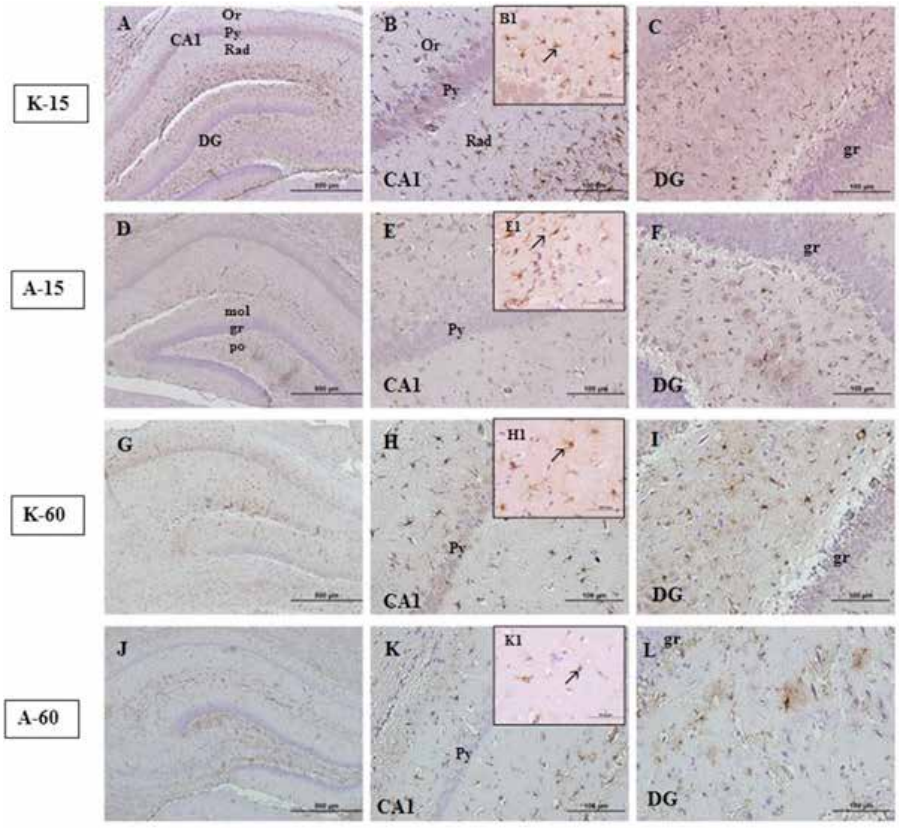

overall (A), CA1 (B,B1), DG (C) in the C-15 group; overall (D), CA1 (E, E1), DG (F) in the A-15 group; overall (G), CA1 (H,H1), DG (I) in the C-60 group; and in the A-60 group: overall (J), CA1 (K, K1), DG (L) GFAP expression (arrow). GFAP immunohistochemistry. Or(stratum oriens), Py(stratum pyramidalis) and Rad(stratum radiatum)

10.5505/2017ichc.PP-206 [Neuroscience]

The protective role of epigallocatechin-3- gallate in aluminum induced neurotoxicity in rats: Focus on apoptosis

Saziye Sezin Palabiyik[1], Naciye Dilara Zeybek[2], Erol Akpınar[3], Elham Bahador Zırh[2], Hande Sipahi[4], Zekai Halici[3]

[1]Ataturk University, Faculty of Pharmacy, Department of Pharmaceutical Toxicology, Erzurum, Turkey

[2]Hacettepe University, Faculty of Medicine, Department of Histology and Embryology, Ankara, Turkey

[3]Ataturk University, Faculty of Medicine, Department of Pharmacology, Erzurum, Turkey

[4]Yeditepe University, Faculty of Pharmacy, Department of Pharmaceutical Toxicology, Istanbul, Turkey

Introduction & OBJECTIVES: Aluminum is a neurotoxic metal(1). Prolonged aluminum exposure induces oxidative stress and apoptosis in brain. Epigallocatechin gallate(EGCG) is a well-known antioxidant(2, 3). The aim of our study is to investigate the effect of chronic aluminum toxicity in the rat hippocampus and the neuroprotective role of EGCG.
Materials & METHODS: A hundred and twenty male Sprague-Dawley rats were divided into 10 groups(n=12, per group). Control(C) was given 1 mL/day saline orally; 100mg/kg aluminum chloride ($AlCl_3$) was administrated for 8 weeks to $AlCl_3$ group; 10 and 20mg/kg EGCG was given for 4 or 8 weeks as EGCG C group. $AlCl_3$ was administered with 2 different doses of EGCG and 0.15mmol/kg deferoxamine. For the other two groups after 4 weeks pre-administration of $AlCl_3$, 2 different doses of EGCG was added to the administration. After decapitation, apoptotic cell death was assessed in the samples of hippocampus by using TUNEL assay and real time PCR(mRNA levels of caspase 3 and 9). Serum caspase 3 and 9 levels were also determined.
RESULTS: Serum and hippocampus mRNA levels of caspase 3 and 9 were significantly increased in $AlCl_3$ group when compared to control($p<0.001$). EGCG caused a dose dependent significant decrease in the serum and mRNA levels of caspase 3 and 9 in $AlCl_3$+10 or 20mg/kg EGCG when compared to $AlCl_3$ group($p<0.01$,$p<0.001$ respectively). Serum and mRNA levels of caspase 3 and 9 were decreased in deferoxamin+$AlCl_3$ group when compared to $AlCl_3$ and this was statistically significant only for serum levels. There was no difference in the serum and mRNA levels of caspase 3 and 9 in deferoxamine group, 10 or 20mg/kg EGCG groups compared to control. TUNEL positive cells were detected in CA1, CA2 and CA3 areas of hippocampus in $AlCl_3$ group. The number of apoptotic cells was decreased in CA1 and CA2 areas of $AlCl_3$+20mg/kg EGCG group. In the last 4 weeks of $AlCl_3$ exposure, both doses of EGCG decreased the number of apoptotic cells in hippocampus when compared to $AlCl_3$ group.
CONCLUSIONS: EGCG showed a potential protective role in aluminum neurotoxicity as deferoxamine.

This work was supported by TUBITAK research fund(project no: 115S533)

Keywords: epigallocatechin-3-gallate, aluminum, neurotoxicity, apoptosis

10.5505/2017ichc.PP-207 [Neuroscience]

Effect of Chondroitinase ABC and platelet rich plasma combination on sciatic nerve regeneration

Emine Nazli Hayirli[1], Oya Evirgen[1], Erdal Resit Yilmaz[2]

[1]Department of Histology and Embryology, Ankara University School of Medicine, Ankara, Turkey

[2]Department of Neurosurgery, Diskapi Yildirim Beyazit Training and Research Hospital, Ankara, Turkey

The peripheral nerves has an intrinsic capacity for regeneration after injury. For regeneration the most important factors are Schwann cells, trophic factors and extracellular matrix(ECM) molecules. The common treatment method for transection injuries is to directly suture the injured nerve ends together. In this study to achieve a good functional and morphological recovery, the chondroitinase ABC(ChABC) enzyme which reduces the inhibitory effects of the some ECM components on nerve regeneration and platelet-rich plasma(PRP) which including axon growth stimulating growth factors(IGF-1, PDGF etc.) one by one and in combination were used after surgical repair.
A total of 40 Wistar rats were randomly seperated into 5 groups. The transection injury was formed by transverse incision from the 1cm proximal of the branching point on the left side in all groups. Right sciatic nerves were used as control. Untreated group have no treatment with primary epineural anatomosis(PEA). After PEA 0.125ml saline, 2U/0.125ml ChABC, 0,125 ml PRP and combined 2U ChABC+0.125ml PRP were applied onto the repair site in treated groups (saline,ChABC,PRP and ChABC+PRP). For the preperation of PRP, blood was collected by cardiac puncture in a tube containing anticoagulant. After centrifugation the pellet was diluted with supernatant and activated by 10%CaCl2. After 12 weeks the nerves were removed and fixed with 10%formalin and processed as routinely. Paraffin sections from distal stump stained with hematoxylin and eosin, luxol fast blue and Mallory's azan. For immunohistochemical examination the sections were stained with anti-S100 and anti-GAP43 antibodies for visualization of Schwann cells and regenerating axons under Leica DM500 microscope and images were captured with Leica ICC50HD camera.
Untreated group demonstrated the greatest axonal degeneration and myelin loss when compared with the treated groups and misdirected regenerating sprouts were seen in the epineurium. Macrophages that were fagosite myelin debris and mast cells around blood vessels and in endoneurium were seen in all groups. The nerve fibers in fasicles of ChABC+PRP group were more compactly arranged and have thicker myelin sheaths than ChABC and PRP groups.
These result suggested that combined ChABC and PRP treatment after PEA enhanced nerve regeneration and myelinization when compared with their single usage.

Keywords: ChABC, PRP, Rat, Regeneration, Sciatic Nerve

10.5505/2017ichc.PP-208 [Neuroscience]

Rasmussen's Encephalitis: A Case Report

İrsel Tezer Filik[1], Ayşegül Fırat[2], Işık Ünal[3], Burçak Bilginer[4], Figen Kaymaz[3], Figen Söylemezoğlu[5], Serap Saygı[1]

[1]Department of Neurology, Faculty of Medicine, Hacettepe University, Ankara, Turkey

[2]Department of Anatomy, Faculty of Medicine, Hacettepe University, Ankara, Turkey

[3]Department of Histology and Embryology, Faculty of Medicine, Hacettepe University, Ankara, Turkey

[4]Department of Neurosurgery, Faculty of Medicine, Hacettepe University, Ankara, Turkey

[5]Department of Pathology, Faculty of Medicine, Hacettepe University, Ankara, Turkey

Introduction & Objectives: Rasmussen's encephalitis is a progressive disease characterised by drug-resistant focal epilepsy, progressive hemiplegia, and cognitive decline with unihemispheric brain atrophy. It is a rare disease and affects children and young adults. The characteristic histopathological findings of Rasmussen's encephalitis are cortical inflammation, neuronal loss, and gliosis located in one cerebral hemisphere. Microglial and lymphocytic nodules, perivascular infiltration and neuronal death are the most common pathological features. End-stage features include cortical cavitation, marked astrogliosis, and neuronal cell loss. There is a growing interest to the immunological and inflammatory mechanisms of the neurological diseases. Our aim in this study was to evaluate some antibody related immunohistological parameters of a Rasmussen's encephalitis case.
Materials & Methods: Our study was composed of a pathologically proven case of Rasmussen's encephalitis treated and followed in our neurology clinic. The diagnosis of the case was confirmed with magnetic resonance imaging and ictal-interictal electroencephalographic findings. The patient was pharmacoresistant to the seizures and therefore surgically operated by left hemispherectomy. Pathological examinations confirmed encephalitis and hippocampal sclerosis. Postsurgically, frozen brain tissue was prepared to be stained with anti-NMDA antibody, anti-VKGC antibody, anti-GAD antibody, anti-NeuN antibody, anti-GFAP antibody and anti CD-3 and anti CD-8 antibodies to evaluate the immunological parameters semi-quantitatively.
Results: In the sections perivascular inflammatory cells and lymphocyte infiltration were prominent in temporal lobe, hippocampus and frontal lobe sections. Neuronal atrophy was also prominent in all regions. Especially GFAP (+) gliosis was a common finding.
Conclusions: Immunotherapies of patients with neurological diseases has been changing very rapidly. Such descriptive studies with immunohistochemistry will help to evaluate the clinical outcome and improve the treatment of the cases.

Keywords: Rasmussen's encephalitis, epilepsy, autoimmunity, immunohistochemistry

Figure-1

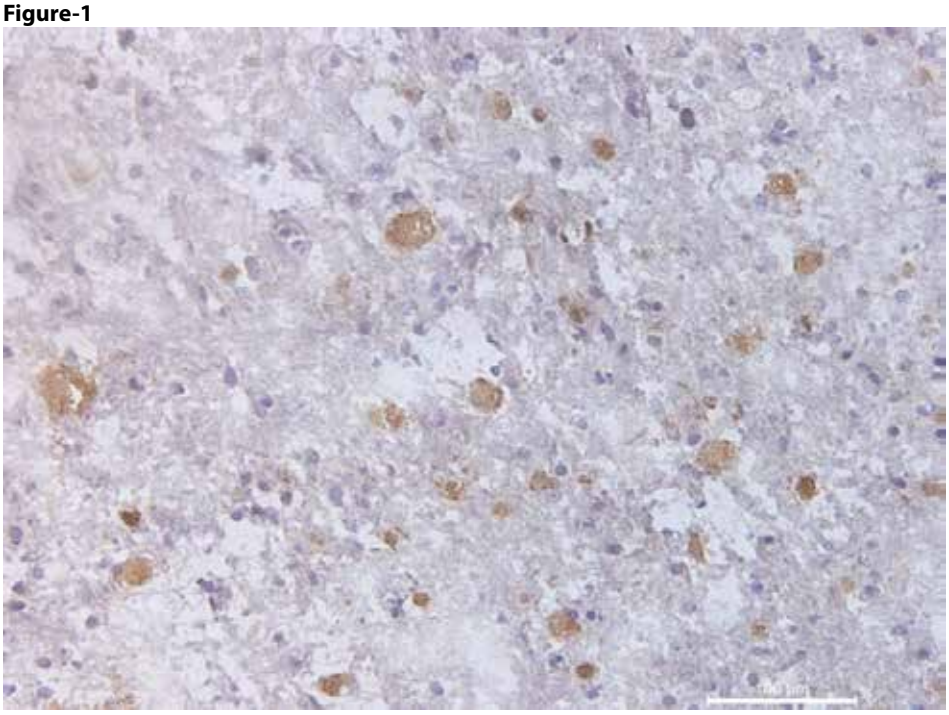

Hippocampal neurons, anti-NeuN antibody, X200.

Figure-2

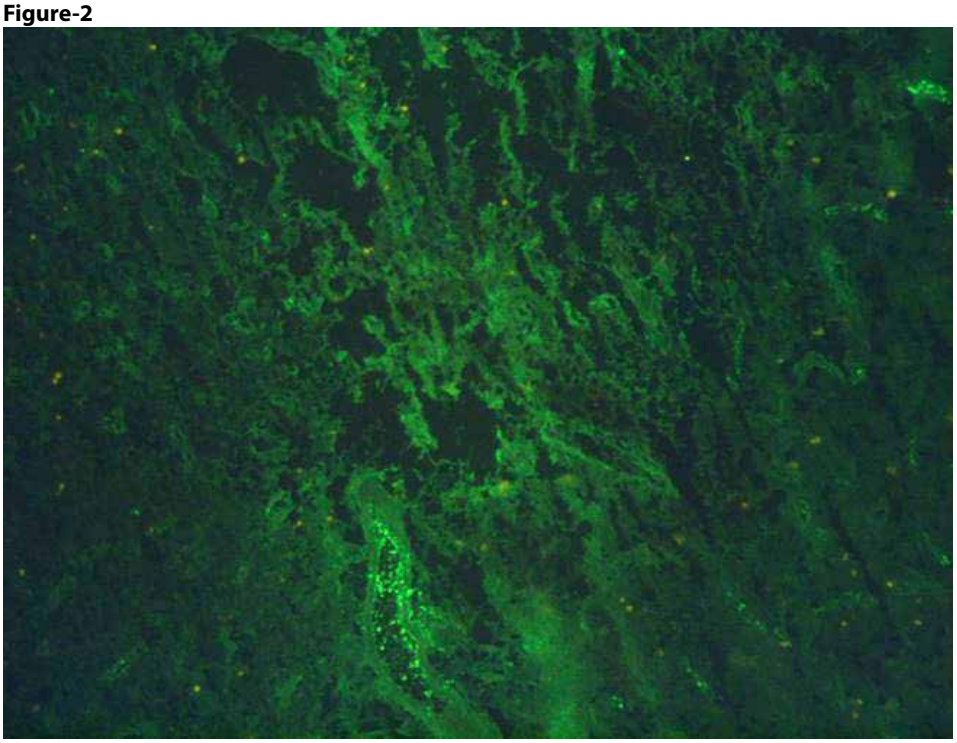

Temporal lobe, anti human IgG, x 100

10.5505/2017ichc.PP-209 [Neuroscience]

Determination of GABA density in the substansia nigra of genetic absence epileptic rats receiving kindling stimulations

Zehra Nur Turgan[1], Ozlem Tugce Kaya[2], Tuğba Karamahmutoğlu[1], Medine Gülçebi Idrizoglu[1], Dilek Akakın[2], Serap Şirvancı[2], Filiz Onat[1]

[1]Department of Pharmacology and Clinical Pharmacology, Marmara University School of Medicine, Istanbul, Turkey

[2]Department of Histology and Embryology, Marmara University Faculty of Medicine, Istanbul, Turkey

Genetic Absence Epilepsy Rats from Strasbourg (GAERS), which is a well-known animal model of absence epilepsy, show resistance to kindling stimulations. The aim of the present study was to examine whether there was a difference in gamma-aminobutyric acid (GABA) levels in the substantia nigra pars reticulata (SNR) between control or stimulated GAERS and Wistar rats.
Animals in the kindling group received 6 stimulations in the basolateral amygdala region. Rats were decapitated one hour after the last stimulation. In the SNR regions of the brains obtained by intracardiac perfusion fixation, GABA immunoreactivity in the nerve terminals was detected by postembedding immunogold method at the ultrastructural level. Labeled sections were observed and photographed by SIS Morada CCD camera system attached to a JEOL 1200 EXII transmission electron microscope and analyzed quantitatively by NIH Image Analysis (Image J) software.
Basal GABA levels showed a tendency to increase in GAERS compared to Wistar rats. Although the GABA density in Wistar kindling group showed a tendency to increase, GAERS kindling group showed a tendency to decrease, compared to their respective controls. However, the quantitative results did not reach statistical significance.
The findings of the present study suggests that SNR may have a role in resistance of GAERS to kindling stimulations. The results might be a basis for further studies.

Keywords: GAERS, kindling, substansia nigra, GABA, immunogold method

10.5505/2017ichc.PP-210 [Neuroscience]

Ultrastructural GABA immunocytochemistry in the hippocampal mossy terminals of GAERS receiving kindling stimulations

Nükhet Dağbaşı[1], Ozlem Tugce Kaya[1], Zehra Nur Turgan[2], Tuğba Karamahmutoğlu[2], Medine Gülçebi Idrizoğlu[2], Dilek Akakın[1], Filiz Onat[2], Serap Şirvancı[1]

[1]Department of Histology and Embryology, Marmara University Faculty of Medicine, Istanbul, Turkey

[2]Department of Pharmacology and Clinical Pharmacology, Marmara University School of Medicine, Istanbul, Turkey

Epileptic mechanisms are thought to be based on excitation-inhibition imbalance in the central nervous system. GAERS (Genetic Absence Epilepsy Rats from Strasbourg) is an animal model of absence epilepsy, and has a resistance to develop stage 3-5 seizures after kindling stimulations. In this study, we aimed to determine the level of GABA immunoreactivity and possible morphological changes in GAERS hippocampus after electrical kindling stimulations.
All animals in the kindling groups received 6 stimulations in the basolateral amygdala and were decapitated 1 hour after the last stimulation. Brain tissues were obtained by intracardiac perfusion fixation method. For the evaluation of quantitative GABA density in mossy terminals of hippocampal CA3 region, ultrastructural postembedding immunogold labelling method was used. Micrographs were taken by using SIS Morada CCD camera system attached to a JEOL 1200 EXII transmission electron microscope. NIH Image Analysis (Image J) software was used for quantitative analyses.
GABA levels were decreased in kindling groups compared to their controls, and in GAERS groups compared to Wistar groups; although the quantitative results did not reach statistical significance. Depletion of synaptic vesicles was evident in the mossy terminals of kindling groups.
The results of the present study, indicating different mechanisms of absence epilepsy and temporal lobe epilepsy, might be a basis for further experimental studies.

Keywords: GAERS, kindling, hippocampus, GABA, immunogold method.

10.5505/2017ichc.PP-211 [Neuroscience]

Role of the store-operated calcium entry in the optic nerve damage occurred following acute retinal ischemia-reperfusion injury

Tuba Demirci[1], Nuray Bilge[2], Metin Uçar[3], Özlem Özgül Abuç[1], Hilal Atilay[1]

[1]Department of Histology and Embryology, Faculty of Medicine, Ataturk University, Erzurum, Turkey

[2]Department of Neurology, Regional Training and Research Hospital, Erzurum, Turkey

[3]Department of Ophthalmology, Regional Training and Research Hospital, Erzurum, Turkey

Introduction & OBJECTIVES: The aim of our study is to investigate the relationship between the optic nerve damage occurring as a result of acute retinal ischemia-reperfusion (ARIR) injury and store-operated calcium entry (SOCE), and also to examine the effect of 2-aminoethoxydiphenyl borate (2-APB) as a SOCE blocker, administered in relation to reperfusion duration, depend on the expression level of Orai1 and STIM1 on a rat model.
Materials & METHODS: Wistar-Albino rats were randomly divided into 3 groups as sham group (n=10), ARIR group (n=10) and ARIR10 group (n=10). In the ischemia-reperfusion groups, right eyes were cannulated with a 30-gauge needle and the intraocular pressure was elevated to 120 mmHg and an hour later reperfusion was realized. In the rats of sham group, the intraocular pressure was not elevated; just needle was applied and removed. 4 mg/kg 2-APB was given to the ARIR10 group as i.p 10 minutes before reperfusion. The third day of the experiment, the rats were sacrificed under anesthesia and optic nerves were removed. After histological procedure, the sections were stained with H-E and toluidine blue. Immunohistochemical staining was performed to show the Orai1 and STIM1 proteins.
RESULTS: When compare with the sham group, in the H-E stained sections of the ARIR group; there was a disruption in the arrangement of axons; and axonal degeneration was prominent. There were swelling and vacuolar degeneration in the myelin sheath of the axons. An increase in glial cells was observed extensively. Also, in the toluidine blue stained sections, intensive demyelination areas were remarkable. In the treatment group given 2-ABP, these findings were seen less. However, immunostaining of Orai1 and STIM1 in the optic nerve sections was more evident in the ARIR group than sham group. In the ARIR10 group, immunostaining of Orai1 and STIM1 was observed, but the intensity of the staining was less than that of the ARIR group.
CONCLUSIONS: In the light of our findings, we conclude that store-operated calcium entry (SOCE) in the cell has an important role in the optic nerve damage occurred following acute retinal ischemia-reperfusion injury, and 2-ABP can use in the treatment.

Keywords: optic nerve, SOCE, STIM1, Orai1, 2-ABP

10.5505/2017ichc.PP-212 [Neuroscience]

The Effect of Docosahexaenoic Acid on TNF-α Level and Mast Cell Number in the Stomach of Mice in 1-Methyl-4-Phenyl-1.2.3.6.-Tetrahydropyridine-induced Parkinson's Disease

Sema Avci[1], Ilknur Birsen[2], Ayşe Ozkan[2], Hande Parlak[2], Hakan Soylu[1], Leyla Kilinc[1], Aysel Agar[2], V.nimet Izgut Uysal[2], Ismail Ustunel[1]

[1]Department of Histology and Embryology, Akdeniz University, Faculty of Medicine, Antalya,Turkey

[2]Department of Physiology, Akdeniz University, Faculty of Medicine, Antalya,Turkey

Parkinson's disease (PD) is a degenerative disorder of the peripheral and enteric nervous systems in the human. The cause of impaired gastrointestinal function in PD is still unknown. Recent findings suggest that inflammation may be a pathogenic factor in the onset and progression of PD. Mast cells play an important role in inflammation (1). DHA (docosahexaenoic acid) is known to have anti-inflammatory effects (2).
The aim of this study was to investigate the effect of the number of mast cells and TNF- α level in the MPTP-induced Parkinson mouse model with DHA treatment.
In the study; male C57BL/6 mice were randomly divided into four experimental groups as follows (for each group n:30): 1) Control; 2) DHA-treated (DHA); 3) MPTP-injected (Parkinson); 4) DHA treated+MPTP injected (DHA+Parkinson). All groups of animals were dissected after 30 days and stomach tissues were taken for physiological, histological and immunohistochemical examinations.
For immunohistochemical studies, formaline-fixed gastric tissues embedded in paraffin, cut into 5 µm thick sections. After, sections were incubated with TNF- antibody. İmmunoreactivity in samples from groups were evaluated using image-J analysis. Sections were stained with a mixture of 1% toluidine blue and the number of mast cells was determined at each microscope site. The data were analyzed statistically by student-t test. Significance levels were set at $p<0.05$.
In the parkinson group, the number of mast cells (fig.1) and the expression of TNF-α protein (fig.2) significantly increased in the submucosal layer of the stomach wall. Serum gastric TNF-α levels were higher in the elisa measure (fig.3). According to our findings; the TNF-α levels in serum/tissue and the number of mast cells decreased in the DHA+Parkinson group.
In summary, the mast cells may play an important role in the inflammatory process associated with stomach/gut disorders in PD. This study suggests that DHA may reduce the symptoms of digestive disorders in PD and may be used as a preventive.
References:
1. Pellegrini C. et al. Alteration of colonic excitatory tachykininergic motility and enteric inflammation following dopaminergic nigrostriatal neurodegeneration. J Neuroinflammation. 2016; 13: 146.
2. Calder PC. Omega-3 Fatty Acids and Inflammatory Processes. Nutrients; 2; 355-374; 2010

Keywords: Parkinson's disease, mast cell, gastric TNF-α

The number of mast cells



In the parkinson group, the number of mast cells significantly increased in the submucosal layer of the stomach wall. arrow head: mast cell.

TNF-α immunohistochemical evaluation

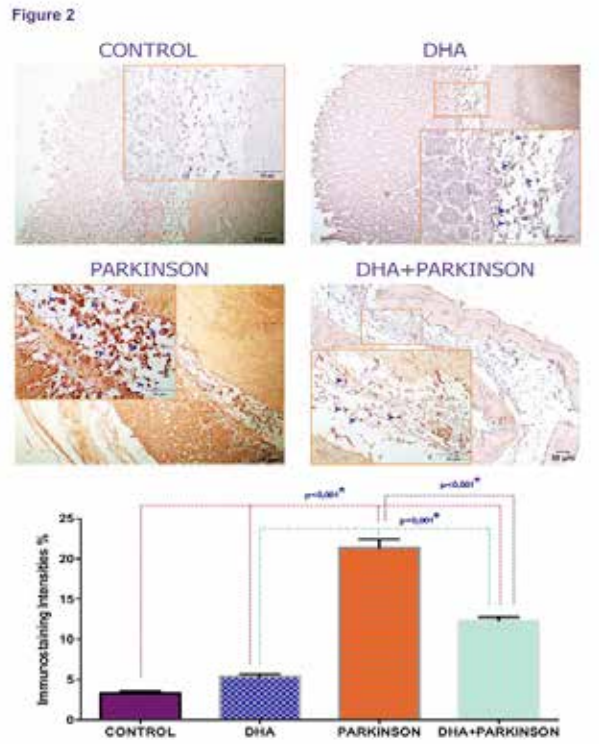

TNF-α immunohistochemically intensively stained in the parkinson group. arrow heads: immunohistochemically positive connective tissue cells.

Serum gastric TNF-α level

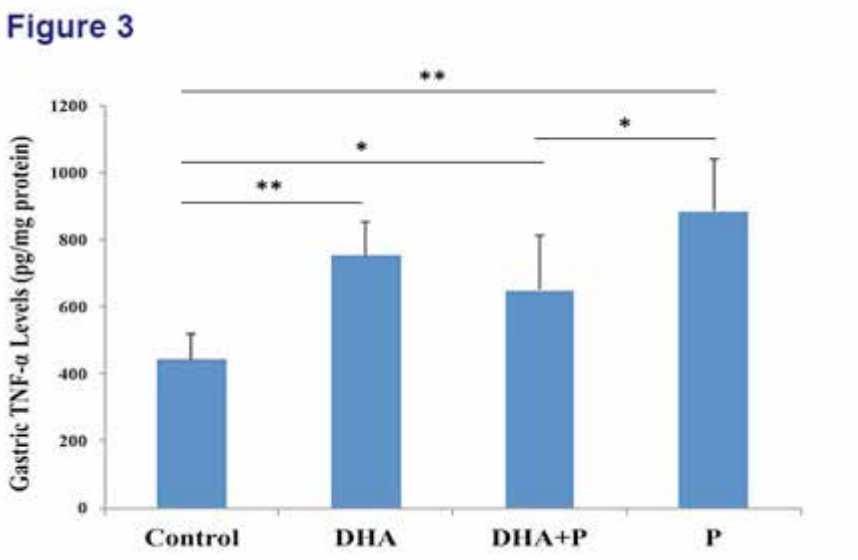

Serum gastric TNF-α levels were significantly lower in the group treated with DHA than in the Parkinson group.

AuthorToEditor: Distinguished Scientific Committee Members; Thank you firstly for bringing an international congress to Antalya. I am truly grateful for the opportunity to present our work as a Ph.D. student. Best regards.

10.5505/2017ichc.PP-213 [Neuroscience]

Investigation of effect of alpha lipoic acid on neurofilament expression in cerebellum tissue of experimental diabetic rat model

Semir Gül[1], Kevser Tanbek[2], Emrah Zayman[1], Elif Özerol[2], Mehmet Gül[1]

[1]İnönü University, Faculty of Medicine, Department of Histology and Embryology

[2]İnönü University, Faculty of Medicine, Department of Medical Biochemistry

Introduction: Neuropathy due to diabetic complications causes structural and functional impairments in cerebellum tissue. Streptozotosin (STZ) is the most suitable diabetogenic agent in diabetic studies. Alpha lipoic acid (ALA) is an important molecule in biological systems and has antioxidant activity. In this study, we aimed to investigate the pathological effects in cerebellum of STZ-induced diabetic rats and to show ameliorative effects of ALA by demonstrating the neurofilament distrubution.
Materials and Methods: 40 Wistar albino male rats were divided into four groups. Control (n=10); applied nothing. ALA (n=10); ALA was orally administered for six weeks at the dose of 100 mg/kg/day. Rats with blood glucose levels of 200 mg/dl and above were grouped as STZ (n=10) and STZ+ALA (n=10) after 72 hours of STZ injection (50mg/kg). STZ+ALA group; 100 mg/kg/day ALA was given by gg. for 6 weeks. After six weeks, cerebellum tissues were taken and processed with routine histological procedures after formalin fixation and embedded to paraffin blocks. 5µm thickness of sections were taken and stained with Neurofilament Ab1. Stained sections were analyzed with Nikon Eclipse NiU microscope, Ds-Fi2 camera and the DS-L3 image analysis system.
Results: General organization and distrubution of neurons in the three layers of cerebellar cortex were similar to each other in control and ALA groups (A1-A3, B1-B3). However, neurofilament content and density in medulla and cortex were seen as more abundant in ALA group compared to control group. Neurofilaments around the purkinje cells were the most intensive in ALA group (B1-B3). In diabetic STZ group, neurofilament pattern was decreased in respect of general contribution. Especially, neurofilament density at the around of purkinje cells were considerably deminished. Furthermore, the number of purkinje cells decreased and proper sequence of ganglionic layer was disturbed in this group (C1-C3). On the other hand, these malformations disappeared in STZ+ALA group. In this group, number of purkinje cells, neurofilament pattern were similar to control and ALA groups (D1-D3). In summary, this study showed that ALA play a protective and ameliorative role over the neurofilament lose in cerebellum of experimental diabetic rats.

Keywords: Neurofilament, alpha lipoic acid, cerebellum, diabetes

10.5505/2017ichc.PP-214 [Neuroscience]

Resveratrol exhibits antidepressant-like behavior in the rat chronic unpredictable mild stress model through reducing serum corticosterone, peripheral inflammation and neuroinflammation and also maintaining hippocampal BDNF levels

Yusufhan Yazir[1], Selenay Furat Rençber[1], Gülçin Gacar[2], Ayşegül Aytekin[1], Selen Önder[2], Tijen Utkan[3]

[1]Department of Histology and Embryology, Kocaeli University Faculty of Medicine, Kocaeli, Turkey

[2]Stem Cell and Gene Therapies Research and Application Center, Kocaeli University, Kocaeli, Turkey

[3]Department of Pharmacology, Kocaeli University Faculty of Medicine, Kocaeli, Turkey

It is well known that major depressive disorder (MDD) is the most common neuropsychiatric disorders and has been associated with inflammation. Resveratrol (trans 3,5,4-trihydoxystilbene) possesses antidepressant-like effects and antiinflammatory properties. The aim of this study is to examine possible effect of resveratrol on HPA axis function, peripheral inflammation, neuroinflammation and neurogenesis, and associated depressive–like behaviours in rats.

Male Wistar albino rats were randomly divided into four groups (n=10): Animals not exposed to CUMS (control), animals exposed to CUMS, and animals treated with resveratrol while exposed to CUMS. Resveratrol was administrated intraperitoneally, 20 mg/kg/day for 12 weeks to the animals being exposed to the CUMS protocol. CUMS and CUMS+resveratrol groups were subjected to different types of stressors. These stressors were randomly applied for 12 weeks. After 12 weeks, Forced swimming test (FST) and the sucrose consumption test (SCT) were used to evaluate the depressive-like behavior of animals. BDNF expression was assessed by immunohistochemically. Plasma corticosterone, proinflammatory (TNF-alpha, IL-1 beta, IL-6) and inflammatory (CRP, MCP-1) cytokines levels and hippocampal proinflammatory cytokines (TNF-alpha, IL-1 beta) levels were assessed with an ELISA kit according to the manufacturer's instructions. Significant differences were determined using one-way ANOVA followed by Tukey post hoc tests. The immunoreactivity scores were compared by the Kruskal-Wallis test following Dunn's multiple comparison test. $P<0.05$ was considered significant.

In the FST, CUMS-exposed rats exhibited more immobility than control rats ($p<0.05$). There were no difference between resveratrol-treated CUMS rats and control rats. In the SCT, CUMS-exposed rats consumed less sucrose solution than controls ($p<0.05$). However, resveratrol treated stressed rats, the sucrose consumption did not differ significantly from nonstressed controls. Additionally, the results showed a decrease in the hippocampal BDNF immunoreactivity ($p<0.05$), an increase in plasma corticosterone ($p<0.05$), TNF-alpha ($p<0.05$), IL-1 Beta ($p<0.05$), IL-6 ($p<0.05$), CRP ($p<0.05$), MCP-1($p<0.05$) levels and an increase in hippocampal TNF-alpha ($p<0.05$) and IL-1 beta levels ($p<0.05$). Chronic treatment with resveratrol restored hippocampal BDNF immunoreactivity and reduced plasma and also hippocampal cytokine levels.

Our study demonstrated that resveratrol exhibited antidepressant-like behavior in CUMS rats through normalizing serum cortosterone levels, peripheral inflammation and neuroinflammation while also maintaining BDNF levels in the hippocampus.

Keywords: Resveratrol, Hippocampus, BDNF, Inflammation

10.5505/2017ichc.PP-215 [Neuroscience]

Effects of DBP on medial prefrontal cortex and hippocampus. Can resveratrol prevent the damage?

Süheyla Esra Özkoçer[1], Çiğdem Elmas[1], Deniz Irem Bulut[1], Cemile Merve Seymen[1], Gülnur Take Kaplanoğlu[1], Dila Şener[2], Deniz Erdoğan[1]

[1]Department of Histology and Embryology, Gazi University, Ankara, Turkey

[2]Department of Histology and Embryology, Okan University, Istanbul, Turkey

INTRODUCTION & OBJECTIVES: Di-n-butyl phthalate (DBP) is a chemical substance which used for personal care products. Unfortunately, adolescent girls are vulnerable to DBP effects. In this study, we aim to show DBP effects on hippocampal CA1 region and medial prefrontal cortex (mPFC) degeneration. Estrogen receptor β (ERβ) which regulates hippocampal plasticity and improves learning. Dopaminergic system hypofunction and increase dopamine 2 receptor (D2DR) on medial prefrontal cortex (mPFC) related inattention and impulsivity. Resveratrol which is antioxidant found in grapes and wine can prevent those DBP's harmful effects.
MATERIALS & METHODS: 36 pubertal female Wistar Albino rats divided six groups. Groups had received substances daily by oral gavage for 4 weeks. Group 1: Control group- saline. Group 2: 500 mg/kg DBP. Group 3: 1000 mg/kg DBP. Group 4: CMC (resveratrol's solvent 10mg/kg). Group 5: 500 mg/kg DBP + resveratrol (20 mg/kg). Group 6: 1000 mg/kg DBP + resveratrol (20 mg/kg). Toluidine blue and immunohistochemical staining with D2DR and ERβ antibodies performed to sagittal sections from paraffin embedded tissue.
RESULTS: DBP caused tissue degeneration even 500mg/kg DBP on mPFC and hippocampus. Degeneration increased with higher dosage. CMC group showed minimal degeneration. Resveratrol diminished 500 mg/kg DBP effect but less effective against 1000mg/kg DBP. DBP down-regulated ERβ on CA1 pyramidal and granular neurons. Resveratrol up-regulated ERβ according to DBP only groups. DBP up-regulated D2DR on pyramidal and granular neurons throughout the mPFC. CMC had minimal effect. Resveratrol down- regulated D2DR. Resveratrol was less effective against high dosage DBP.
CONCLUSIONS: Pubertal female rats' hippocampal plasticity and mPFC dopaminergic pathways are affected by DBP. Resveratrol can prevent those effects depends on DBP dosage.

Keywords: di-n-butyl phthalate, DBP, resveratrol, hippocampus, medial prefrontal cortex

mPFChippocampus



Figure numbers indicate group numbers. Left column (Letter A) shows Dopamine 2 receptor (D2DR) on medial prefrontal cortex (mPFC). Right column (Letter B) shows Estrogen receptor β (ERβ) on CA1 region of hippocampus. e.g. 5A: group 5 D2DR

10.5505/2017ichc.PP-216 [Neuroscience]

Estrogen receptor agonists improved seizure-induced memory dysfunction and increased immunoreactivity for GABA(A)α1 in rats

Sevil Arabacı Tamer[1], Türkan Koyuncuoğlu[1], Ayça Karagöz[2], Dilek Akakın[2], Can Erzik[3], Meral Yüksel[4], Berrak Ç. Yeğen[1]

[1]Departments of Physiology, School of Medicine, Marmara University, Istanbul, Turkey

[2]Departments of Histology and Embryology, School of Medicine,Marmara University, Istanbul, Turkey

[3]Department of Medical Biology, School of Medicine, Marmara University, Istanbul, Turkey

[4]Vocational School of Health Service, Marmara University, Istanbul, Turkey

Introduction & OBJECTIVES: It is well-known that susceptibility to epilepsy varies by sex and by monthly fluctuations in estrogen levels, while estrogens may have proconvulsant or anticonvulsant effects. It is aimed to elucidate effects of estrogen receptor (ER) agonists, in comparison to phenytoin and 17β-estradiol (E2), on occurrence of epileptic seizures, seizure-induced memory dysfunction and GABA(A) α1 receptor subunit expression.
Materials & METHODS: Wistar albino male rats initially had a learning session for passive avoidance test (PAT) and were then randomly separated as control (n=8) and pentylene tetrazole-induced (PTZ) seizure (n=60) groups. Before the PTZ injection, either E2 (1mg/kg/day) or phenytoin (40 mg/kg/day) was given in drinking water for 28 days or ER-α receptor agonist (PPT; 10μg/kg/day), ER-β receptor agonist (DPN; 10μg/kg/day) or vehicle (oil) was injected subcutaneously for 28 days. Seizures induced by a single-dose PTZ (45mg/kg; intraperitoneally) were video-taped and scored by Racine's scale. Treatments were continued for the following 3 days and PAT was repeated to assess memory. At the 72nd hour of PTZ, rats were perfused transcardially with 4% paraformaldehyde. GABA(A)α1 immunohistochemical staining procedure was performed in sections cut from frozen tissues. Statistical analysis was performed by ANOVA and Student's t tests.
RESULTS: Averages of seizure stage scores and number of rats having seizures were similar in all PTZ groups, except for the phenytoin group that demonstrated a reduction in seizure score ($p<0.05$). As compared to control rats, PAT revealed memory dysfunction in vehicle-treated PTZ group ($p<0.001$), while phenytoin-, DPN- or PPT-treated rats, but not E2, showed an enhanced memory performance ($p<0.05$- 0.001). GABA(A)α1 immunoreactivity in the brain sections of vehicle-treated PTZ rats was decreased with respect to control group. However, GABA(A)α1 immunoreactivity was elevated in the brain tissues of 17 β-estradiol-, DPN- or PPT- treated PTZ-seizure groups as compared to vehicle-treated PTZ group.
CONCLUSION: Estrogen receptor agonists exerted no significant effect on the occurrence or severity of epileptic seizures, but both ER-α and ER-β agonists improved memory dysfunction and increased immunoreactivity for GABA(A)α1 subunit, suggesting that either agonists could be beneficial in ameliorating seizure-induced cognitive impairment via the regulation of GABA(A)α1 receptors.

Keywords: Estrogen, DPN, PPT, epileptic seizure, memory dysfunction

10.5505/2017ichc.PP-217 [Neuroscience]

A point mutation detection of MT-ATP6 gene in Leigh syndrome: A case report

Naser Gilani[1], Rozhgar A. Khailany[1], Javad Homayounvash[2], Mehri Igci[1], Ihsan Al Shamari[3], Amir Ariamand[2], Amir Monfaredan[2], Khandakar A. S. M. Saadat[1], Ahmet Arslan[4]

[1]Department of Medical Biology, Faculty of Medicine, Gaziantep University, Gaziantep, Turkey

[2]Farabi Medical Laboratory, Erbil, Iraq

[3]College of Medicine, Erbil Medical University, Erbil, Iraq

[4]Department of Medical Biology, Faculty of Medicine, Namık Kemal University, Tekirdag, Turkey

Leigh Syndrome (LS) is an uncommon progressive neurodegenerative, mitochondrial disorder. The condition is characterized by a progressive mental and developmental disabilities (psychomotor regression) and commonly brings about death inside a few years of diagnosis, more often due to respiratory failure. A little number of patients do not create manifestations until adulthood. The principal indications of Leigh syndrome found in early stages are typically diarrhea, vomiting and difficulty swallowing (dysphagia), which disturbs eating. These problems usually result in a powerlessness to develop and put on weight under the normal rate (failure to thrive). Serious movement and muscle problems are basic in Leigh syndrome. In this case report, we introduce the molecular and clinical features of a 19-year-old female as proband and also we study other members of the family consequently. The m.9176T> G heteroplasmic mutation in MT-ATP6 gene was detected by high resolution melt (HRM) and DNA sequencing techniques. Similarly, the m.9176T> G was heteroplasmic in the mother. In conclusion, this report in compliance with previous studies, underlines the necessity of further research on prenatal distinguishing proof of the responsible mutations and avoidance of the disease in families with known cases.

Keywords: Mitochondrial DNA, MT-ATP6, Leigh Syndrome, Clinical Feature, Mutation Screening

10.5505/2017ichc.PP-218 [Pathology and clinical medicine]

Immunohistochemical method in differential diagnostics of pre tumor and tumor processes

Sergey Arkadievich Sukhanov[1], Egor Aleksandrovich Lozhkin[1], Anna Sergeevna Sherbina[1], Nikolay Aleksandrovich Kiryanov[2]

[1]Republican oncologic center, Izhevsk, Russia

[2]Izhevsk State medical academy, Izhevsk, Russia

Differential diagnostics of tumors and tumor-like formations is a topical issue of modern oncology. In this regard issues relating to early tumor detection are of great importance both theoretically and practically. Histological diagnosis of precancerous lesions is challenging, especially in biopsy specimens. For this reason new distinct differential diagnostic criteria need to be considered for morphological diagnostics of tumor and pre tumor processes. And practical application of new diagnostic methods is of special significance. Tumor growth starts with gene regulation disorder and intense cell clone proliferation. It leads to DNA content changes in the nucleus. Increased ploidy may reflect abnormal cell proliferative activity and indicate neoplastic proliferation. In many tumors the p53 anti-oncogene which prevents proliferation and accumulation of abnormal cells can be pointed out as biomarkers of tumor growth. Another factor providing cell population stability is the apoptosis system. Bcl-2 has the ability to inhibit the apoptotic process. One of the most important characteristics of a neoplasm is its growth potential determined by the Ki-67 antigen proliferation marker. Thus, detection of different nucleus ploidy can be used as an objective criterion for the differential diagnostics of hyperplastic processes, premalignant conditions and tumors. The results of the expression of proliferation and apoptosis biomarkers obtained under immunohistochemical analysis will reflect the intensity of molecular changes in cells in hyperplastic processes, precancerous conditions and tumors. The presence or absence of p53, Bcl-2, Ki-67 expression and their intensity can be considered as additional diagnostic criteria in the analysis of biopsy specimens. At that high aneuploidy of tumor cells and p53, Ki-67, Bcl-2 hyperexpression will be considered as adverse prognostic factors for tumor processes.

Keywords: differential diagnosis, pretumours, tumors, immunohistochemistry

10.5505/2017ichc.PP-219 [Pathology and clinical medicine]

The Relationship Between Serum S100B Levels And Microglial Activation In Rat Hipocampus After Lithium-pilocarpine Induced Status Epilepticus And The Effect Of Liraglutide, A GLP-1 Analogue On These Changes

Murat Kiziltas[1], Sureyya Barun[1], Ilhan Yetkin[2], Sahin Hanalioglu[3], Firat Narin[4], Burçak Bilginer[3], Önder Aydemir[5], Pergin Atilla[6], Sevda Muftuoglu[6], Turan Turhan[7], Murat Oktem[8]

[1]Department of Pharmacology, Gazi University Faculty of Medicine, Ankara, Turkey

[2]Department of Endocrinology, Gazi University Faculty of Medicine, Ankara, Turkey

[3]Department of Neurosurgery, Hacettepe University Faculty of Medicine, Ankara, Turkey

[4]Institute of Neurological Sciences and Psychiatry, Hacettepe University, Ankara, Turkey

[5]Department of Public Health, Gazi University Faculty of Medicine, Ankara, Turkey

[6]Department of Histology and Embryology, Hacettepe University Faculty of Medicine, Ankara, Turkey

[7]Department of Biochemistry, Ankara Numune Education and Research Hospital, Ankara, Turkey

[8]Duzen Laboratories Group, Ankara, Turkey

The aim of this study was to investigate probable correlation between serum S100B levels and microglial activation in rat hipocampus after lithium-pilocarpine-induced-status epilepticus (SE) and investigation of liraglutide effect on these changes.
MATERIAL-METHOD: Twenty-four rats (male, 200-250gr, Spraque-Dawley) were assigned into 4 groups. 1: Control group; No operation, 2: Sham group; 1stday, instead of lithium-chloride SF(127mg/kg i.p.) was administered. 2ndday, with 30min intervals, respectively methylscopolamine-bromide (1mg/kg ip), instead of pilocarpine SF(30mg/kg ip), instead of pilocarpine-SF(10mg/kg ip) and diazepam (10mg/kg i.p) were administered. 3rd-4th-5th-6th-7thdays not implemented any action. 3: SE group; Lithium-pilocarpine induced SE animals group. 24h before pilocarpine, lithium-chloride (127mg/kg ip) were administered. Pilocarpine with interval of 30min(30mg/kg ip), (10mg/kg ip) in two doses were administered. Also, to eliminate cholinergic side-effects of pilocarpin, 30min before methylscopolaminebromide (1mg/kg ip) was administered. SE were terminated by diazepam(10mg/kg ip). SF-TPN were given to reduce mortality rate on 3rd-4th-5th-6th-7thdays. 4: SE+Liraglutide group; SEgroup protocol was repeated in presence of liraglutide.
On 8thday, for determination of S100B bloods were drawn from all animals in 4 groups and hippocampi were removed for determination of GFAP and OX-42 immunoreactivity. Indirect ABC method was used for GFAP and OX-42 immunostaining.
RESULTS AND DISCUSSION: High levels of S100B in SE+Liraglutide group compared to control group may result of neuroprotective properties of liraglutide as stated in literature. Besides, high level positive correlation between OX-42(+) microglia number in CA1area, blood S100B levels was found in SE group. Our S100B findings may reflect microglial activation at relevant pathological focus. OX-42 expression in DG wasn't different statistically between each groups. Moreover, OX-42 ekspression in CA1 in SE and SE+Liraglutide groups were statistically higher than control supporting the idea that CA1 is taking place at forefront of neuroinflammatory pathological processes. There was no effect of liraglutide on OX-42 ekspression which occured in SE group. But, there was high level of correlation between CA1 and DG GFAP(+) cell numbers suggesting that liraglutide may trigger neuroinflammatory processes.
Keywords: Epilepsy, Microglia, S100, liraglutide, GFAp, OX42

GFAP immunoreactivity in SE+Liraglutid group

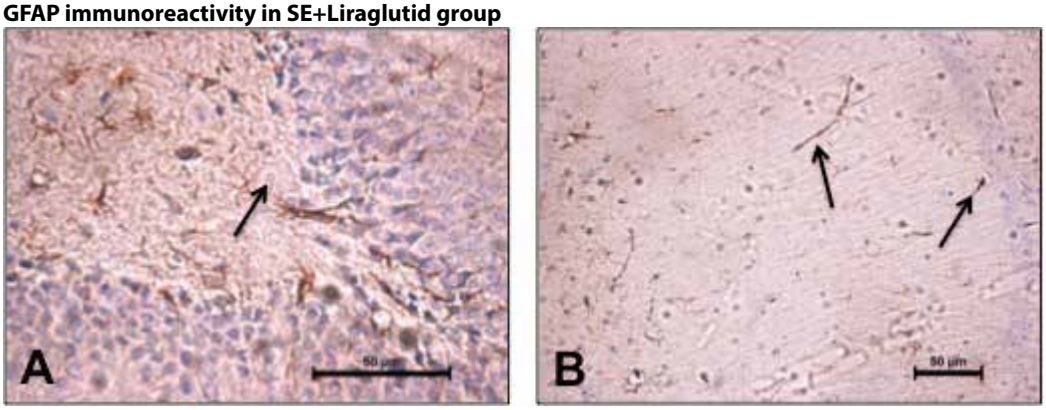

A: GAFP immunoreactive cells in DG, B: GAFP immunoreactive cells in CA1.

OX-42 immunoreactivity in SE+Liraglutid group

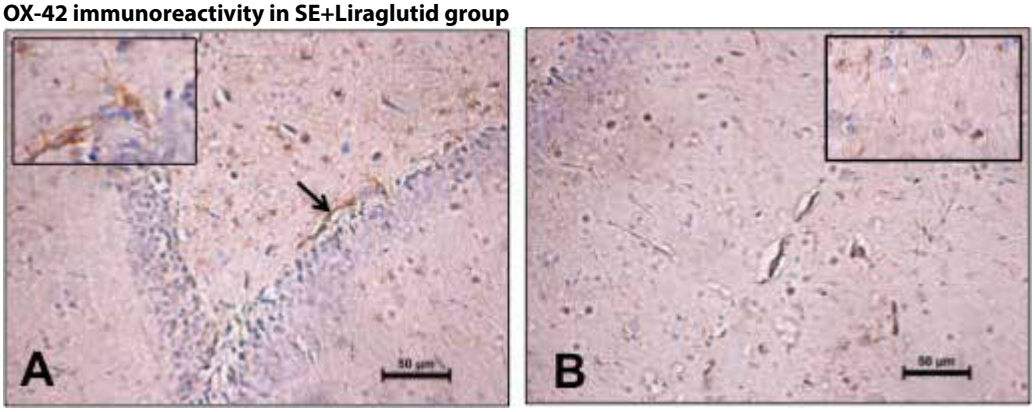

A: OX-42(+) microglial cells in DG, B: OX-42(+) microglial cells in CA1 located at the side of blood vessels. Inset: OX-42(+) microglial cells at high magnification.

s100B blood levels

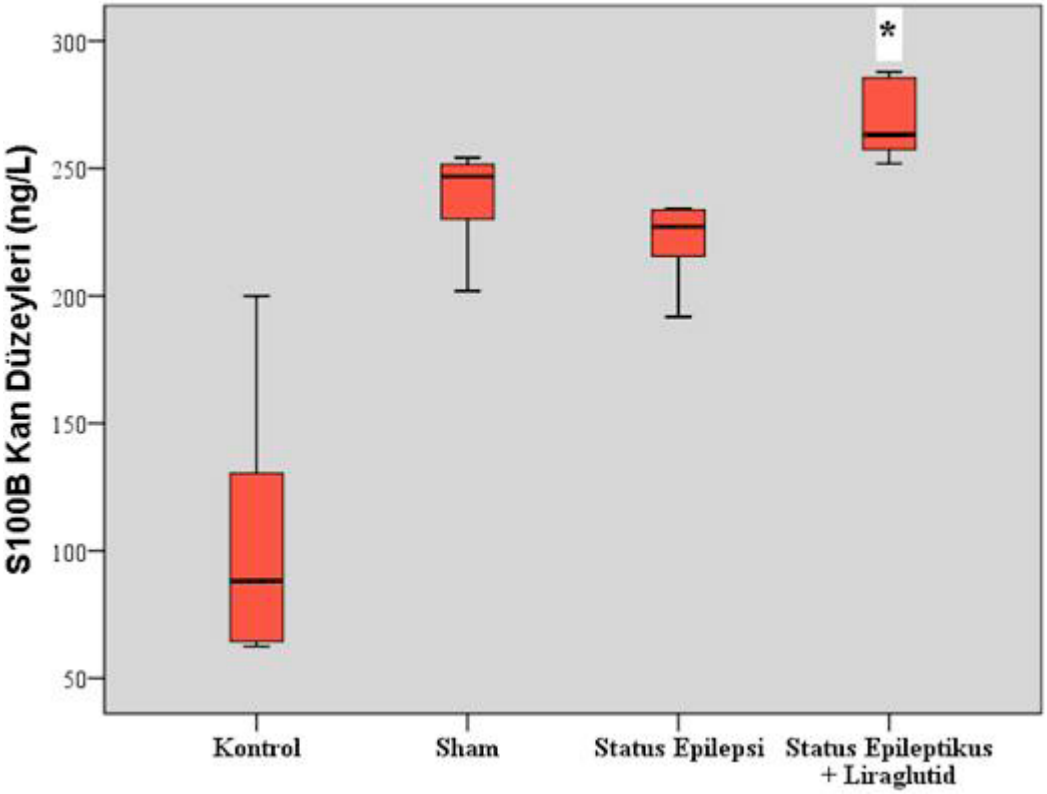

Difference between control group and SE+Liraglutid group was statistically significant. p<0,00.1

10.5505/2017ichc.PP-220 [Pathology and clinical medicine]

Reductions in Protein Levels of Lysyl Oxidases Led to Pulmonary Emphysema in Chronic Obstructive Lung Disease

Fusun Oztay[1], Neziha Besiktepe[1], Ezel Ersen[2]

[1]Department of Biology, Faculty of Science, Istanbul University, Istanbul, Turkey

[2]Department of Thoracic Surgery, Faculty of Cerrahpasa Medical, Istanbul University, Istanbul, Turkey

Introduction & OBJECTIVES: Pulmonary emphysema (PF) is characterized by enlargement alveoli, the destruction of alveolar wall and abnormalities in the accumulation and digestion of elastic fiber. The copper-dependent lysyl oxidases regulate the production of elastic fibers and their accumulation in the connective tissue, thereby installing cross-linking of each tropoelastin monomers. The present study focused on the relationship between lysyl oxidases (LOX, LOXL1, LOXL2) and PF pathogenesis.
Materilas & METHODS: The lung samples with emphysema (n = 10) and without emphysema (n = 6) removed from chronic obstructive lung disease patients who have lung cancer diagnosis were used in the present study. Protein levels of elastin, LOX, LOXL1, LOXL2, hypoxia-inducible factor-1 alpha (HIF-1α), COMMD1 (an effective protein in copper metabolism) and phosphotase and tensin homolog (PTEN) were assayed microscopic and biochemical methods in the tissue samples.
RESULTS: Enlargement alveoli, thinning and disruptions in alveolar wall, a lot of accumulated macrophages in alveolar lumen and increased HIF-1α immunoreactivity were observed in emphysematous areas. Furthermore, in these tissues, it was detected a significant decrease in elastin, LOX, LOXL1, LOXL2, HIF-1α, COMMD1 and PTEN protein levels when compared with control tissues.
CONCLUSIONS: We think that reductions of HIF-1α levels in PF led to decreases in protein levels of activated LOX, LOXL1 and LOXL2 and this decrease caused abnormalities in elastic fiber biology. In emphysematous lung samples, HIF-1α activation induced by decreased COMMD1 protein and protease activation induced by decreased PTEN protein levels can contribute to the generation of disease pathogenesis. As a result, approaches made to increase activated LOXs, COMMD1 and PTEN protein levels can be effective for the regression of PF.

Keywords: Pulmonary Emphysema, LOX, HIF1, COMMD1, PTEN

10.5505/2017ichc.PP-221 [Pathology and clinical medicine]

The Effects of Minocycline On Hippocampus In Lithium-pilocarpine Induced Status Epilepticus In Rat: Relations With Microglial/astrocytic Activation And Serum S100B Level

Erkut Baha Bulduk[1], Gokhan Kurt[1], Sureyya Barun[2], Sahin Hanalioglu[3], Fırat Narin[4], Onder Aydemir[5], Murat Kiziltas[2], Murat Oktem[6], Turan Turan[7], Pergin Atilla[8], Sevda Muftuoglu[8]

[1]Department of Neurosurgery, Gazi University Faculty of Medicine, Ankara, Turkey

[2]Department of Pharmacology, Gazi University Faculty of Medicine, Ankara, Turkey

[3]Department of Neurosurgery, Hacettepe University Faculty of Medicine, Ankara, Turkey

[4]Institute of Neurological Sciences and Psychiatry, Hacettepe University, Ankara, Turkey

[5]Department of Public Health, Gazi University Faculty of Medicine, Ankara, Turkey

[6]Duzen Laboratories Group, Ankara, Turkey

[7]Department of Biochemistry, Ankara Numune Education and Research Hospital, Ankara, Turkey

[8]Department of Histology and Embryology, Hacettepe University Faculty of Medicine, Ankara, Turkey

Seizures are associated with neuroinflammation and neuronal loss. S100B is a protein released from astrocytes and stimulates microglia during seizure. In this study, the possible correlations were investigated between serum S100B levels and astrocytic/microglial activation in rat hippocampus exposed to lithium-pilocarpine to induce status epilepticus (SE). The aim was to determine whether S100B in serum may refelect neuroinflammation linearly. Additionally, the effects of minocycline (M), an inhibitor of neuroinflammation, has been tested on these parameters.
MATERIAL-METHOD: Rats were divided into 4 groups, each including 6 animal. Groups were defined as control (C), sham (S), SE and SE+M. Animals were exposed to lithium-pilocarpine to induce SE in SE and SE+M groups. Cardiac blood was collected to measure S100B levels and coronal brain sections including hippocampus were obtained for the examination of microglial/astrocytic activation to evaluate the neuroinflammation at the 7th day of SE. OX-42 and GFAP immunoreactivities were detected by indirect ABC method for demonstration of microglial and astrocytic activation respectively.
RESULTS AND DISCUSSION: As a result, OX42 (+) microglia in CA1 and GFAP (+) astrocytes in both CA1 and dentate gyrus (DG) were found to be higher as well as S100B levels compared with C. Most importantly, highly positive correlations were found between S100B levels and microglial activation in CA1 in addition to astrocytic activation in CA1 and DG (r=0.82, r=0.94, r=0.8,3 respectively). Unexpectedly, microglial activation in CA1 and astrocytic activation in DG were also enhanced in SE+M group compared with C. Moreover, M reversed the neuronal loss observed in SE in DG. S100B level was also found to be higher in SE+M compared with C. However, correlations were not observed between the parameters mentioned above in M applied group. These results suggest that S100B in serum may be a candidate biomarker to monitor neuroinflamation. It may also contribute to the prediction of diagnosis and prognosis. In addition, evaluation of the inhibitory effecs of drugs on neuroinflammation and experimental animal models used needs further investigation.

Keywords: S100B, astrocyte, microglia, minocycline, seizure, lithium-pilocarpine

GFAP M+SE group

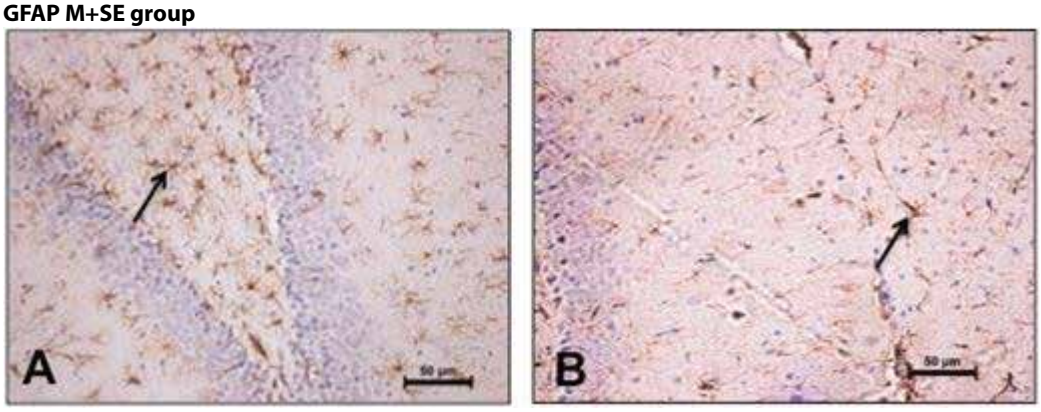

GFAP (+) astroglia predominating in DG (A) and in CA1 (B).

OX42 M+SE group

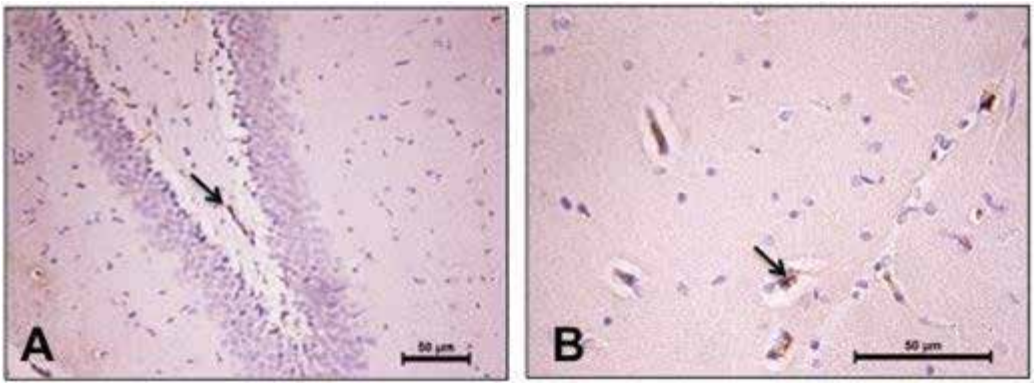

OX42 (+) microglial cells in DG (A) and CA1 (B).

10.5505/2017ichc.PP-222 [Pathology and clinical medicine]

Effect of different aerobic exercise frequency on type 2 diabetes in rat

Nuray Alaca[1], Serap Uslu[2], Umit Ince[3], Mustafa Serteser[4], Guldal Suyen[5], Hızır Kurtel[6]

[1]Acibadem University, School of Physiotherapy and Rehabilitation, Istanbul, Turkey

[2]Istanbul Medeniyet University, Medical School, Department of Histology and Embriyology, Istanbul, Turkey

[3]Acibadem University, Medical School, Department of Pathology, Istanbul, Turkey

[4]Acibadem University, Medical School, Department of Biochemistry, Istanbul, Turkey

[5]Acibadem University, Medical School, Department of Physiology Istanbul, Turkey

[6]Marmara University, Medical School, Department of Physiology Istanbul, Turkey.

OBJECTIVE: Recommendations for exercise and physical activity by professional organizations and government agencies advise that moderate-intensity physical activity may be accumulated in bouts of >10 min each to attain the daily goal of >30 min/day. Although accumulated approach is useful increasing adhesion of an individual to exercise program, benefits in diabetic conditions are not studied. Thus, the objectives of this study is to compare the alterations induced by long-moderate exercise pattern with short bouts of exercise for a given duration and volume on the histopathological structure of skeletal muscle in an experimental model of type 2 diabetes mellitus (T2DM).
MATERIALS-METHODS: T2DM was induced by using nicotinamide (NAD-110mg/kg) and streptozotocin (STZ-65mg/kg) in Sprague Dawley rats (n:35) and diabetic rats were allocated into the groups of sedentary control (SC), sedentary diabetes (SD), diabetes and continuous exercise (DcE; swimming for 30 minutes/day and 5 days/week) and diabetes and short bout of exercise (DsbE, swimming, 3x10 minutes/day, 5 days/week). After 6 weeks of exercise, biochemical tests were performed to measure insulin and glucose. Histologic analyses consisting of modified gomori's trichrome, hematoxylin-eosin stains, periodic Acid-Schiff and oil red o stains were performed. Additionally, muscle oxidative enzyme activities including cytochrome C oxidase (COX), succinate dehydrogenase (SDH) and Ragged Red Fibers (RRF) were analyzed.
RESULTS: In the SD group, increased blood glucose were accompanied by interfibriller connective tissue accumulation (CTA) and vacuolization, increased RRF levels and atrophy (slow and fast twitch fibers). In addition, insulin levels and SDH positive fiber density were found to be decreased in SD group compared to SC ($p<0,05$). When compared to the SD group, significant improvements were observed in all training groups regardless of the exercise type. Blood glucose levels, CTA, vacuolization, muscle atrophy, content of muscle oxidative enzyme activities were all significantly improved in both DcE and DsbE groups compared to SD ($p<0,05$).
CONCLUSION: The results of this study underlined the effect of exercise on myopathy and mitochondrial damage in the rat model of T2DM, while training frequency did not make any significant difference indicating the potential benefits of the accumulated approach.

Keywords: Streptozotocin-Nicotinamide, Type 2 Diabetes Mellitus, Continuous Aerobic Exercise, Short bouth Aerobic Exercise, Weekend Warrior

10.5505/2017ichc.PP-223 [Pathology and clinical medicine]

Conventional vs rapid processing of mamma needle biopsies focusing on morphology, immunohistochemistry and fluorescens in situ hybridization

Lone Bojesen, Anne Roslind, Karen Nørgaard, Kamilla Lund Berthelsen, Reema Butt, Haidar Khalil, Linda Thyregod, Hanne Bjørn
Department of Pathology, Herlev Hospital, University of Copenhagen, Denmark

Conventional tissue processing overnight is still the most commonly used preparation method in Denmark. In the past 10 years rapid processing has been introduced in most pathology laboratories, but there are still various types of tissue where it is not used because it has a negative influence on the analyses. Rapid processing could yield faster results for clinicians and thereby faster initialization of treatment
The aim of this study is to compare the influence of different processing methods on morphology, immunohistochemistry (IHC) and Fluorescence in situ hybridization (FISH) on mamma needle biopsies, to reduce turnaround time (TAT). The treatment of patients with mamma cancer is largely dependent on the results of the IHC and FISH analyses; therefore it is important to test how the rapid processing affects these analyses.
Samples: Mamma tumor is cut into needle biopsies (approx. 1x1x10 mm) fixed for 4 and 6 hours in 4% neutrally buffered formaldehyde (NBF) and processed on both Tissue Tek® VIP® 5 and Tissue Tek® Xpress®.
Stains: H&E, Immunhistochemical stains: ER, Ki67, HER2, FISH stain: FISH-HER2. Morphology, immunohistochemical and FISH stains were evaluated with a score from 0-3, where 3 is optimal and 0 is poor. HER2 and FISH-HER2 diagnostic score was not evaluated
We found no discernable difference between processing methods or fixation time for the HE stain, the IHC stain for ER and Ki67. IHC HER2 shows a very weak tendency towards better results in 6 hours fixation, but no or very little difference between processing methods. FISH-HER2 shows better results at 6 hours fixation and preparation on VIP. The tissue processed on Xpress shows diffuse fluorescent precipitate which influences reading of the results.
The conclusion is that rapid processing on the Xpress can be used for morphology and IHC analyses on mamma needle biopsies, but it is not optimal for FISH analyses. Therefore rapid processing on the Xpress can't be recommended for mamma needle biopsies as long as the HER2 amplification is analyzed by FISH.

Keywords: processing, morphology, immunohistochemistry, FISH, rapid processing, conventional processing

10.5505/2017ichc.PP-224 [Pathology and clinical medicine]

Macrophages role in uterus remodeling in adenomyosis associated with pelvic pain

Oksana Sulaieva, Mekan Orazov, Oksana Slavcheva, Sergey Bondarenko
Department of Pathology, Ukrainian Research and Practical Centre of Endocrine Surgery, Kyiv, Ukraine

Background. Pain syndrome in adenomyosis is associated with growth of nerves and angiogenesis through stimulation of NGF and VEGF expression. In addition to ovarian steroids, immune-mediated stimulation of vessels and nerves growth is discussed. The aim of this study was to estimate the relationship between nerves, vessels and macrophages in adenomyosis.
Material and methods. The immunohistochemical investigation was conducted after hysterectomy among 6 patients with diffuse adenomyosis associated with pelvic pain. Nerves (visualized with monoclonal antibodies to neurofilaments proteins), vessels (CD131), and macrophages (CD68) were counted. In addition, we estimated distribution of expression of VEGF and estrogen receptors (ER). Data were compared with 6 patients with asymptomic leiomyoma.
Results. Increased nerves number and active angiogenesis were detected in myometrium of patients with adenomyosis. Most of nerves were located around vessels in myometrium remodeling zones, less nerves were found around ectopic endometrium. Assessment of sensitivity to estrogens demonstrated high ER expression in epithelium of glands and stromal cells, whereas myometrium and vessels wall were with moderate or low expression. High expression of VEGF was detected in eutopic and ectopic glands, and in addition in perivascular stromal cells in myometrium at sites of remodeling. This fact confirms the data about estrogen-dependent induction of VEGF expression in glandular epithelium and stromal cells. Interestingly that increased angiogenesis in the myometrium was associated with enhanced macrophages density (P=0.007 comparing with leiomyoma patients). Macrophages number in perivascular zone of myometrium under adenomyosis was significantly higher than those around ectopic endometrium (P=0.0023). Since location of macrophages was the similar to VEGF expression we propose that myometrium remodeling including vessels and nerves growth could be promoted by macrophages. In addition, collocation of CD68 and VEGF expression could reflect the prevalence of M2 type of macrophages in the myometrium under adenomyosis.
Conclusion. This study demonstrates that in adenomyosis activated macrophages are a major source of VEGF promoting vessels and the consequent nerves growth in myometrium, and this events are regulated directly by ovarian steroids.

Keywords: adenomyosis, angiogenesis, macrophages, VEGF.

10.5505/2017ichc.PP-225 [Pathology and clinical medicine]

Review of the histological structure of veins

Yasin Ilgaz[1], Sedat Develi[2], Esra Erdogan[1]

[1]Departmant of Histology and Embryology, Gulhane Military Medical Academy, Ankara, Turkey

[2]Departman of Anatomy, Gulhane Military Medical Academy, Ankara, Turkey

Venous system is responsible of carrying blood from organs to the heart. This system begins from post capillary venules and ends with inferior and superior caval veins at the right atrium. Veins are classified as large-sized veins such as caval veins, medium-sized veins such as saphenous vein, and small-sized veins. In this presentation we aimed to review histological structure of the veins.
As in the arteries, walls of the veins are composed of three layers. Tunica intima is the innermost layer and it consists of a thin layer of endothelium, basal membrane and subendothelial connective tissue. Tunica media is the middle layer and it is composed of circularly arranged smooth muscle fibers between collagen and elastic fibers. The tunica adventitia is the outer layer of loose connective tissue containing collagen, fibroblasts and vaso vasorum.
Tunica adventitia is the thickest layer of the veins. It is well developed in large-sized veins and three zones are distinguishable. The outer zone composed of dense connective tissue of collagen and elastic fibers. Vaso vasorum are mostly seen here but they can be found in all layers. Middle zone mainly consists of smooth muscle fibers. They are longitudinally arranged and this zone is most-developed in inferior vena cava. It consists of numerous smooth muscle fibers and distinguishes inferior vena cava from superior vena cava.
Tunica intima is similar in small, medium or large-sized veins. Femoral and mesenteric veins have specialized tunica intima that is subendothelial connective tissue contains longitudinal smooth muscle fibers.
Tunica media is thinner and it is not well developed as in the arteries. Due to the relative amount of the muscle fibers, veins cannot hold the shape of the lumen and they are seen irregularly according to the arteries. Large veins consists of a few layers circular smooth muscle fibers in tunica media but superior vena cava have more than 10 layers of circularly arranged smooth muscle fibers. Maternal veins of placenta and retinal veins doesn't have any smooth muscle in tunica media layer on the contrary, thickening of tunica media is well observed in umbilical vein.

Keywords: Tunica intima, Tunica adventitia, Tunica media

Reprehensive figures of specified structure of vena cava superior, femoral and umblical veins.

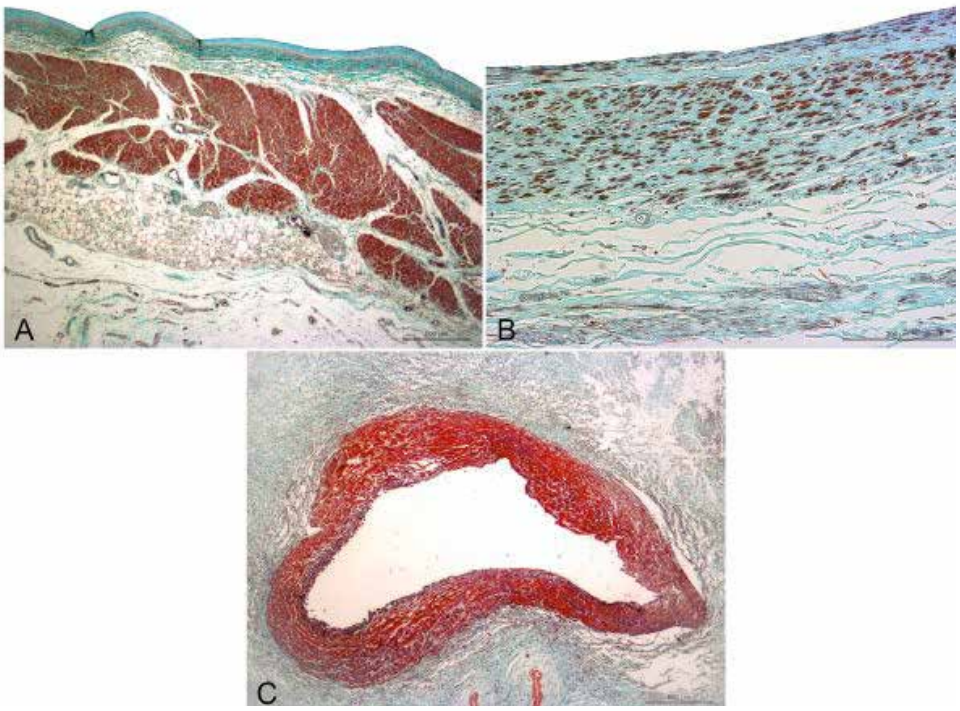

Figure 1: (A) The superior vena cava contains abundant smooth muscle fibers in the thick tunica adventitia layer. (B) The femoral vein has longitudinal smooth muscle fibers as subendothelial connective tissue in tunica intima. (C) The umbilical vein contains thickened tunica media layer consist of smooth muscle fibers (Masson trichrome, Scale bar 500-200-500 µm).

10.5505/2017ichc.PP-226 [Pathology and clinical medicine]

Review of the histological features of tendon sheath and vinculum

Seda Develi[1], Yasin Ilgaz[2]

[1]Departmant of Anatomy, Gulhane Military Medical Academy, Ankara, Turkey

[2]Departmant of Histology and Embryology, Gulhane Military Medical Academy, Ankara, Turkey

Tendon is a dense cord of fibrous connective tissue. Tendons connect muscle with the bones. They are composed of collagen fibers which forming dense regular connective tissue. They are covered by irregular connective tissue sheaths called peritendineum or synovial sheet. Synovial sheet is composed of collagenous fibers which are mainly composed of type I and type III collagen fibrils. The inner layer of synovial sheath is called vagina synovialis or stratum synoviale. This layer forms a closed space and produces peritendinous fluid which reduces the friction and provides gliding of the tendon. The outer layer of synovial sheet is called vagina fibrosa or stratum fibrosum which confines the tendon to osseous groove. Histological specimen of tendon sheath of flexor digitorum profundus muscle (fourth digit on the middle phalanx) is seen in Figure 1. As seen in Figure 1; vessels supplying the tendon sheath are mainly located in the midsection of the sheath. This area is the attachment site of vinculum (pl. vincula). Vinculum also known as mesotendineum is a band of connective tissue which lies between palmar surface of the phalanxes and dorsal surface of the tendon sheaths. Main function of the vinculum is to carry vessels which are supplying the tendon sheath and tendon. In anatomic terminology; there are two types of vinculum- vincula longi and breve. These ligamentous structures are mainly found in digits of hand foot and they are located between phalanxes and tendon sheath on the median plane. In terms of vascularization of tendon and tendon sheath, their location should be kept in mind in procedures such as rupture repair, transection of digital pulley systems or local anesthesia.

Keywords: Mesotendineum, tendon sheath, vinculum

Representative photographs of the blood vessels in the tendon sheath stained with Masson trichrome.

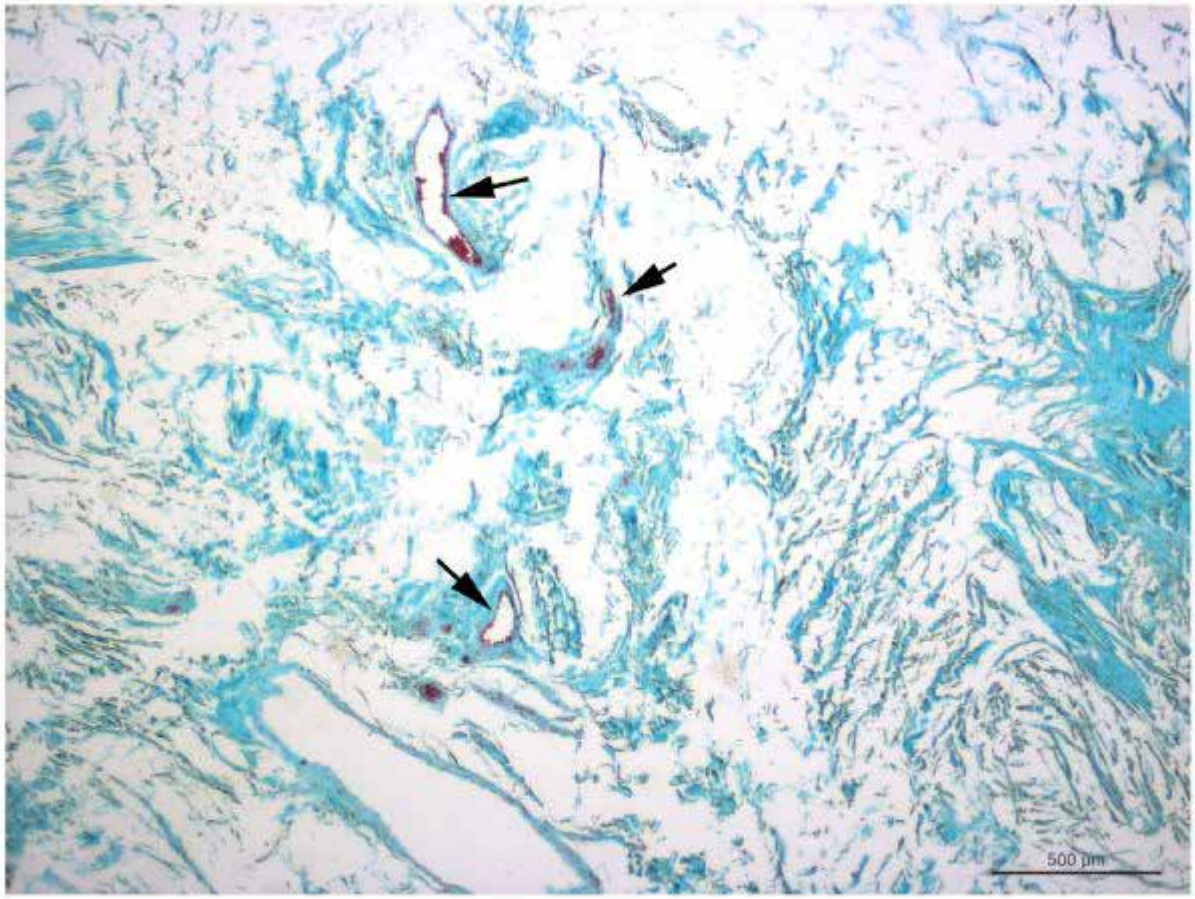

Figure: Vascular structures (arrows) of the tendon sheath are mostly located in the midsection of the sheath, Scale bar 500 µm.

10.5505/2017ichc.PP-227 [Pathology and clinical medicine]

Can Urine Alkalinisation Be A Treatment Option On Colistin Induced Nephrotoxicity: An Ultrastructural And Histochemical Study In Rats

Berfu Korucu[1], Işık Ünal[2], Mert Pekcan[3], Mehmet Alper Çetinkaya[4], Fevziye Figen Kaymaz[2], Kadir Mutlu Hayran[5], Mustafa Tuğrul Demir[6], Ahmet Çağkan Inkaya[7], Murat Akova[7], Serhat Ünal[7], Yunus Erdem[8]

[1]Hacettepe University Faculty of Medicine, Department of Internal Medicine, Ankara,Turkey

[2]Hacettepe University Faculty of Medicine, Department of Histology and Embryology,Ankara,Turkey

[3]Ankara University Faculty of Veterinary Medicine, Department of Biyochemistry,Ankara,Turkey

[4]Hacettepe University Laboratory Animal Research Center, Ankara,Turkey

[5]Hacettepe University Faculty of Medicine, Department of Preventive Oncology, Ankara,Turkey

[6]Hacettepe University Faculty of Medicine, Medical Student, Ankara,Turkey

[7]Hacettepe University Faculty of Medicine, Department of Infectious Diseases, Ankara,Turkey

[8]Hacettepe UniversityFaculty of Medicine, Department of Nephrology, Ankara,Turkey

Colistin is a vital antibiotic that is used in drug-resistant nosocomial infections. The most important side effect is nephrotoxicity (Acute tubular necrosis). Colistin is a weak acid. The aim of this study is to evauate the possible protection of urine alkalinisation that is used in toxicities of weak acids. Sprauge Dawley rats were divided into four groups. Group-I (control) were injected intramuscular distilated water. Group-II (colistin) were injected 750000 IU/kg/day of colistin. Group-III (colistin-bicarbonate) were injected same dose of colistin, after they reach urinary pH >7 by addition of bicarbonate in their drinking water. Group-IV (colistin-NaCl) were injected the same dose of colistin after reaching Group-III's urine density by adding NaCl in their drinking water. Serum urea levels showed borderline statistical difference (p=0,046) but, it was not clinically correlated when compared histopathologically. Serum creatinine values showed no statistical difference (p=0,131). According to histological tubular degeneration average scores evaluated by light microscopy (scored 0-5,Table-1) and electron microscopy; Group-I scored "0", Group-II scored "4,25±0,89", Grup-III scored "2±1,26", and Grup-IV scored "1,5±0,55". In Group-III and Group-IV, protection was achieved against nephrotoxic agent (p<0,001).
Normal renal tubule epithelium were observed in the control group.
Mild-marked tubuler degeneration was detected in colistin-treated rats, the tubules had pyknotic nuclei, vacuolation in the cytoplasm and sloughed cells were seen within tubular lumina (protein casts) (Figure-1).
In colistin-bicarbonate group, less tubules were affected, and a small number of protein casts, vacuolization and necrosis were detected (Grade1-4 tubuler degeneration). In some areas pale basophilic accumulations were seen in tubule lumen, and basal membrane separation were detected.
In colistin-NaCl group there were a few dilatated tubules with separated epithelial cells. Interstitial edema and pyknotic nuclei of the spilled cells were observed in some of the tubule's lumen (Figure-2).
Bicarbonate group was not superior to NaCl group(p=0,601). Urine densities and tubular degeneration scores were statistically correlated independent of the groups. The lower the urine density was, the
lower the tubular score(p=0.001). Bicarbonate hydration is not superior to NaCl hydration, and both are effective similarly. Decrease in urine density is correlated with tubular protection.

Keywords: colistin, nephrotoxicity, urine alkalinisation, hydration, urine density

Figure 2

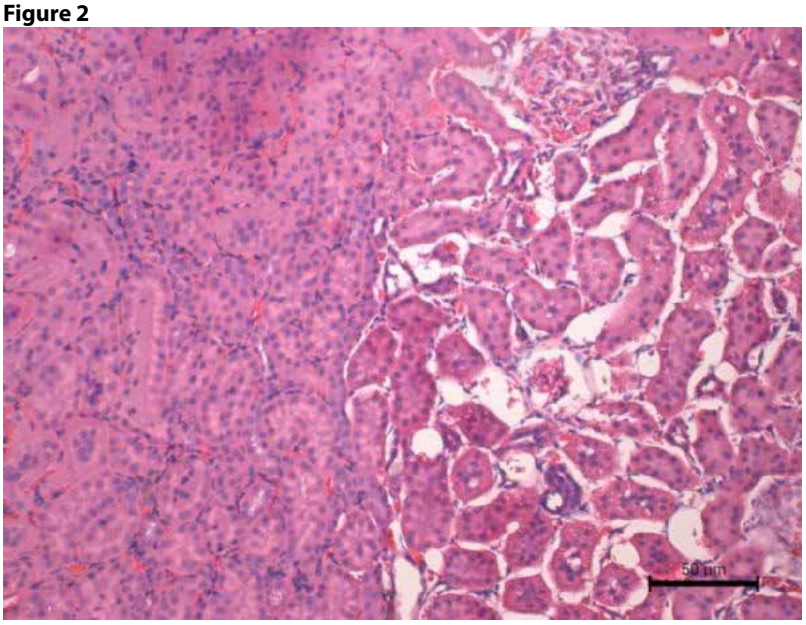

Significant interstitial edema in the right, kidney biopsy ×20 objective H&E

Figure-1

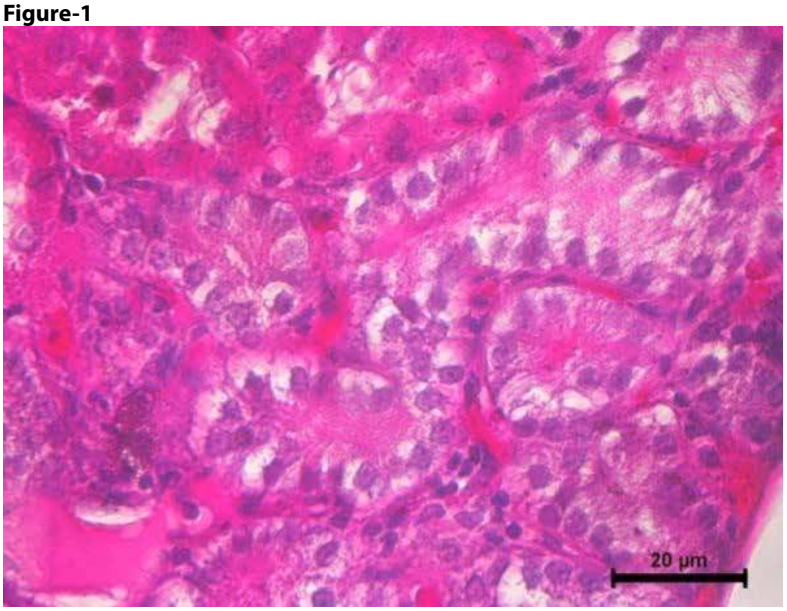

Vacuolation of the cytoplasm, renal cortex. Original magnification×63 H&E

Table-1.

Score	Tubuler Degenaration Grade	Histopathological Findings
0	Normal	Normal renal tubuler epitelial cells
1	Minimal	Tubuler cells with brightly eosinophilic cytoplasm and pyknotic nuclei;
2	Slight	Occasional degenerate cells with pyknotic to karyorrhectic nuclei and sloughed cells within tubular lumina (protein casts)
3	Mild	Small clusters of 2–4 degenerate cells with pyknotic nuclei and protein casts
4	Moderate	Larger clusters and chains of degenerate cells, some with complete loss of chromatin, affecting numerous tubules
5	Marked	Majority of tubules affected by chains of degenerate cells, or entire tubular segments affected by degeneration.

The histopathological grading scheme for tubuler degeneration, Keirstead et all.

10.5505/2017ichc.PP-228 [Pathology and clinical medicine]

Increased number of macrophages are associated with the lower expression of p16INK4a in the atherosclerotic lesions of carotid stenosis patients

Burcu Bayoglu[1], Fatma Kaya Dagistanli[1], Caner Arslan[2], Mujgan Cengiz[1]

[1]Department of Medical Biology, Cerrahpasa Medical Faculty, Istanbul University, Istanbul, Turkey

[2]Department of Cardiovascular Surgery, Cerrahpasa Medical Faculty, Istanbul University, Istanbul, Turkey

Carotid atherosclerosis (CA) is the stenosis of the proximal bulbous internal carotid artery (ICA). CA is the main cause of stroke. Atherosclerosis is characterized by plaques composed of inflammatory cells, lipid deposition, fibrosis, smooth muscle cell (SMC) proliferation, calcification, and necrosis. INK4/ARF locus was shown to have an important role in cardiovascular diseases. p16INK4a arrests the cell cycle progression via inhibiting CDK4/6 activity. In this study, we aimed to determine the number of macrophages, cell proliferation levels and the p16INK4a expression in carotid plaques and saphenous tissue samples of both symptomatic and asymptomatic CA patients. Patients with 70% stenosis of ICA who experienced cerebrovascular events such as stroke, transient ischemic attacks or amaurosis fugax were classified as symptomatic. Patients with 70% stenosis of ICA but lack of clinical symptoms were classified as asymptomatic. Immunohistochemistry (IHC) was used to analyze CD68, PCNA, and p16INK4a protein levels in the carotid artery plaques and saphenous tissue specimens of 50 CA patients. CD68 immune (+) cells were significantly higher especially in the atherosclerotic lesions of the carotid plaques compared with saphenous veins indicating significantly increased number of macrophages in the atherosclerotic lesions of CA patients ($p<0.05$). Increased number of macrophages were also negatively correlated with attenuated p16INK4a expression in the plaque specimens. Besides, CD68 immune (+) cells were significantly increased in symptomatic group of the carotid plaques of CA patients compared with asymptomatic ones ($p<0.05$). p16INK4a immune (+) cells were higher in carotid plaques of symptomatic patients compared with asymptomatics. Cell proliferation index was also significantly increased in carotid plaques compared with saphenous tissues ($p=0.001$). Increased macrophage number accompanied with the decreased expression of p16INK4a especially in the atherosclerotic lesions may indicate the functional importance of the relation between cell cycle regulators and the inflammatory processes in the development of atherosclerosis.

Keywords: Carotid atherosclerosis, macrophage, CD68, cell cycle, p16INK4a, PCNA

10.5505/2017ichc.PP-229 [Pathology and clinical medicine]

A comparison between three different method of bone tissue decalcification in terms of tissue and cellular integrity

Semir Gül, Mehmet Gül, Birgül Yiğitcan, Salih Yahya Aksanyar
İnönü Üniversitesi, Tıp Fakültesi, Histoloji Embriyoloji Anabilim Dalı

Bone decalcification is the removal of calcium ions from the bone through histological process thereby making the bone flexible and easy for pathological investigation. Due to being a time consuming process, it is crucial for especially clinical applications to decalcify the bone tissue in a short time without structural and cellular disruption for proper diagnosis. The aim of this study was to investigate and compare differences of three different decalcification methods (10% formic acid, RDO-GOLD decalcifier solution (EMS, USA) and electrolysis (SAKURA TDETM 30 Decalcifier System, Netherlands)) to find out which method gives the best result for cellular integrity in respect of immunohistochemistry with least time consumption. Six healthy Wistar Albino rats were used in the study. Femurs of the rats were taken under ketamine/xylazine anesthesia and fixed with 10% formaldehyde. Firstly, two femur tissues were placed into 10% formic acid solution which refreshed properly for 6 weeks. Second group of femurs were incubated in RDO-GOLD solution for 5 hours. Finally, last two femurs were treated with electrolysis for 3 hours. After decalcification, each femur was processed with routine histological tissue processing procedure, embedded to paraffin, sectioned by microtome and stained. Osteopontin (OPN) and osteocalcin (OC) antibodies were used for immunohistochemical staining.
In RDO and electrolysis groups, bone tissue nucleus heterochromozisis, periosteum and connective tissue staining properties and cellular structure of endosteum were normal. Bone marrow hematopoietic cells had normal chromatin staining. There were increased heterochromozisis in bone marrow cells in RDO group. In formic acid group, nuclear chromotolyzis appearance was common and widespread. The contrast of appearance was very weak. There were disruptions in cellular structure of bone marrow. OPN and OC staining of RDO and electrolysis group was very clear and strong, whereas there was very weak staining in formic acid group. H score for OPN of RDO and electrolysis group was similar to each other (60.0 and 58.3, respectively) and significantly greater than the formic acid group (25.0) ($p<0.05$). Similarly, H score for OC of RDO and electrolysis group was close to each other (43.3 and 51.7, respectively) and significantly greater than formic acid group (23.3) ($p<0.05$).

Keywords: Decalcification, immunohistochemistry, cellular integrity

10.5505/2017ichc.PP-230 [Pathology and clinical medicine]

The Effect of Apelin on Podocytes in Doxorubicin Induced Nephrotic Syndrome

Naziye Özkan[1], Ahmet Özer Şehirli[2], Meral Yüksel[3], Özlem Tuğçe Çilingir[4], Olgu Enis Tok[5], Sezgin Aydemir[1], Mehmet Koç[6], Şule Çetinel[4]

[1]Department of Pathology Laboratory Techniques, Vocational School of Health Services, Marmara University, Istanbul, Turkey

[2]Department of Pharmacology, Faculty of Dentistry, Near East University, Nicosia, North Cyprus

[3]Department of Medical Laboratory Techniques, Vocational School of Health Services, Marmara University, Istanbul, Turkey

[4]Department of Histology&Embryology, School of Medicine, Marmara University, Istanbul, Turkey

[5]Department of Histology&Embryology, School of Medicine, Bezmialem Vakif University, Istanbul, Turkey

[6]Department of Nephrology, School of Medicine, Marmara University, Istanbul, Turkey

Introduction & OBJECTIVES: Nephrotic syndrome (NS) is a disease which may progress to renal failure. The anthracycline antibiotic doxorubicin (DXR) is widely used for the treatment of a variety of neoplastic diseases such as leukemias. However, one of the major side effects of anthracycline antibiotics is nephrotoxicity. Doxorubicin causes to increased glomerular capillary permeability through mechanisms of free radical formation and lipid peroxidation. Podocytes are a key component of the kidney's filtration barrier. During NS, podocyte injury results in structural alterations in the foot processes and slit diaphragm proteins such as nephrin. Apelin (AP), is a vasoactive peptide, shows its effect by binding the apelin receptor (APJ). Apelin, presents in endothelial and vascular smooth muscle cells of glomerular arterioles and has effects on the pre- and post- microvascularization through regulating renal hemodynamics. The purpose of this study is to investigate the effects of apelin on the podocyte injury at light microscopic levels in rats.
Materials & METHODS: Male Sprague-Dawley rats were used in the study. Rats were randomly divided into 4 groups (n=6); Control (C; i.p. physiological saline solution (PS)); Apelin+Control (APC; PS and 50 mcg/kg/day apelin-13 i.p.); Nephrotic Syndrome (NS; i.p. 10 mg/kg DXR) and Nephrotic Syndrome+Apelin (NSAP; i.p. 10 mg/kg DXR+50 mcg/kg/day apelin-13). Kidney tissues were collected at the 22st day for light microscopic investigations. Tissues were fixed in 10% neutral buffered formalin, embedded in paraffin, and stained with Haematoxylin and Eosin (H&E), PAS and Gomori One Step Trichrome. Immunoexpression of Nephrin was performed using the HRP-polymer based immunohistochemical staining method.
RESULTS: Light microscopy investigations shows that NS group revealed adhesion between the tuft and Bowman's capsule, mesangial matrix accumulation in glomeruli. In NSAP group minimal regression in glomerular damage was observed. Immunexpression of nephrin decreased in NS group. Compared to NS group, expression of nephrin was not changed significantly in NSAP group.
CONCLUSION: Apelin has limited therapeutic effects on podocyte damage in experimental model of nephrotic syndrome induced by doxorubucin.

Keywords: Nephrotic syndrome, podocyte, doxorubicin, apelin

10.5505/2017ichc.PP-231 [Pathology and clinical medicine]

Renal histopathological changes, cellular organization alterations and apoptosis caused by Aroclor 1254 in rats with different selenium status

Naciye Dilara Zeybek[1], Ofcan Oflaz[2], Aylin Balcı[3], Ünzile Yaman[4], Pınar Erkekoğlu[3], Kübra Gizem Yıldıztekin[5], Ali Aşçı[4], Belma Koçer Gümüşel[3]

[1]Department of Histology and Embriology, Hacettepe University, Faculty of Medicine, Ankara, Turkey

[2]Department of Biology, Hacettepe University, Faculty of Science, Ankara, Turkey

[3]Department of Toxicology, Hacettepe University, Faculty of Pharmacy, Ankara, Turkey

[4]Department of Toxicology, Atatürk University, Faculty of Pharmacy, Erzurum, Turkey

[5]Department of Toxicology, Erzincan University, Faculty of Pharmacy, Erzincan, Turkey

Aroclor 1254 (A1254) is a commercial mixture of polychlorinated biphenyls (PCBs) that are highly toxic environmental contaminants. A1254 shows hepatic, renal and reproductive toxicity in laboratory animals. Some of these effects were suggested to be related to oxidative stress. Selenium (Se) is an important component of cellular antioxidant defense. The present study aimed to evaluate the renal histopathological changes, cell organization alterations, and apoptosis caused by A1254 in Se-supplemented and Se-deficient in male Sprague-Dawley rats, which were randomly divided into 6 groups, six animals in each. Control group (C), fed regular diet (0.15 mg/kg Se); (ii) Se-supplemented group (SeS), fed Se-supplemented diet (1 mg/kg Se); (iii) Se-deficient group (SeD), fed Se- deficient diet (≤0.05 mg/kg Se); (iv) A1254-treated group (A), fed regular diet (0.15 mg/kg Se) and received 10 mg/kg Aroclor1254 during the last 15 days of feeding period; (v) Se-supplemented A1254 group (ASeS), fed Se-supplemented diet (1 mg/kg Se) and received 10 mg/kg A1254 during the last 15 days; (vi) Se- deficient A1254 group (ASeD), fed Se-deficient diet (≤0.05 mg/kg Se) and received 10 mg/kg A1254 during the last 15 days. After decapitation, the kidney samples were fixed and processed for light and electron microscopic examination. Apoptotic cell death was assessed by using TUNEL assay. Absolute and relative kidney weights significantly decreased and renal atrophic changes were observed in both A and ASeD groups. Se supplementation was found to ameliorate the decrease in renal weight caused by A1254. Normal renal morphology was observed in C, SeS and SeD groups. A1254 caused decrease in the Bowman's space, renal corpuscular atrophy, peritubular vascular congestion and edema. The number of apoptotic cells was increased in the renal cortex and medulla of both A and ASeD groups. Besides, examination of kidney samples by electron microscopy also supported our results. In conclusion, A1254 was found to induce both histopathological alterations and cell death in renal tissue of rats, particularly in rats with selenium deficiency. Selenium supplementation with A1254 exposure may have partial protective effects against the renal toxicity induced by A1254.
This work was supported by TUBITAK research fund (project no.:1919B011301522)

Keywords: Selenium, Aroclor1254, kidney, apoptosis

10.5505/2017ichc.PP-232 [Pathology and clinical medicine]

Melatonin And Alendronate Synergistically Preserved Bone Matrix And Increased Trabecular Thickness In Rats With Overiectomy

Esra Bihter Gürler[1], Irem Peker[2], Özlem Tuğçe Kaya[3], Mustafa Akkirpik[2], Feriha Ercan[3], Berrak Ç. Yeğen[1]

[1]Marmara University, School of Medicine, Department of Physiology, Istanbul, Turkey

[2]Marmara University, School of Medicine, Department of Medical Biology, Istanbul, Turkey

[3]Marmara University, School of Medicine, Department of Histology and Embryology, Istanbul, Turkey

Post-menopausal osteoporosis is frequently treated by biphosphonates (e.g. alendronate) to maintain bone mass. Anti-inflammatory agent melatonin was suggested to have a regulatory role in bone physiology. The aim was to evaluate the possible anti-osteoporotic effect of melatonin. Under anesthesia female Sprague-Dawley rats (n=56) underwent bilateral ovariectomy (OVX), while control group had sham-surgery (n=8). Four weeks after the surgery, OVX rats were treated with saline, alendronate (70 µg/kg/week, subcutaneously), melatonin (25 mg/kg/day, orally), melatonin+alendronate, melatonin+melatonin receptor antagonist (luzindole, 10 µg/kg/day, intraperitoneally) or alendronate+melatonin+luzindole for 8 weeks. Rats were euthanized at the end of 12th week, while an additional saline-treated OVX group (n=8) was euthanized at the end of 4th week. Runx2 expression in bone marrow was determined using real-time polymerase chain reaction. Excised tibiae, fixed in formalin, were treated with commercial de-calcifier. Paraffin sections were stained with TUNEL kit for evaluation of apoptotic cells and with Masson's trichrome to evaluate bone matrix, mineralization and trabecular thickness. Statistical analysis was performed using Kruskal-Wallis and ANOVA tests. Runx2 expression was depressed in all OVX groups. Serum estrogen level in the saline-treated groups was decreased at both the 4th and 12th weeks following OVX ($p<0.05$), while melatonin abolished this reduction. At the 12th week, saline-treated OVX group presented an extreme decrease in calcified area along with increased un-mineralized area and reduced thickness of the trabecular bone with separation of lamellae, while these alterations were milder at 4th week. In melatonin- or alendronate-treated groups, trabecular bones were mostly calcified, with new bone formation in some regions and less separated lamellae. In alendronate+melatonin-treated group, quite regular, mostly calcified trabecular bones were present, while trabecular thickness was similar to sham-operated group. Moderate decreases in calcified areas and in trabecular thickness, increased decalcified areas with severe separation of lamellae in trabecular bones were observed in melatonin+luzindole-treated group, while these histopathological alterations were milder in melatonin+luzindole+alendronate-treated group. Quantiative TUNEL analysis also revealed significant decreases in both alendronate-treated and melatonin-treated groups. Similar to alendronate, melatonin has additive anti-apoptotic and bone-mass-preserving effects and its stimulatory effect on trabecular thickness is reversed by luzindole, suggesting its receptor-mediated action.

Keywords: Ovariectomy, Osteoporosis, Alendronate, Melatonin, Luzindole, Apoptosis

10.5505/2017ichc.PP-233 [Pathology and clinical medicine]

Caustic Esophageal Burn Injury in Rats is Alleviated by the Antifibrotic Drug Halofuginone

Kıvılcım Karadeniz Cerit[1], Berna Karakoyun[2], Elif Bahadır[3], Meral Yüksel[4], Nurdan Bülbül[5], Feriha Ercan[5], Tolga E. Dağlı[1], Berrak Ç. Yeğen[3]

[1]Marmara University, School of Medicine, Department of Pediatric Surgery, İstanbul, Turkey.

[2]Marmara University, Faculty of Health Sciences, Department of Basic Health Sciences, Istanbul, Turkey.

[3]Marmara University, School of Medicine, Department of Physiology, Istanbul, Turkey.

[4]Marmara University, Vocational School of Health Related Professions, Department of Medical Laboratory, Istanbul, Turkey.

[5]Marmara University, School of Medicine, Department of Histology and Embryology, Istanbul, Turkey.

BACKGROUND: Accidental ingestion of corrosive substances in children, leading to esophageal strictures, is still an important health issue in developing countries. We have previously shown that halofuginone, a specific inhibitor of collagen type 1 synthesis, is beneficial in ameliorating oxidative damage in different rat models. The aim of this study is to evaluate the anti-inflammatory and antifibrotic effects of halofuginone in caustic esophageal burn injury in rats.
MATERIALS-METHODS: Under anesthesia, caustic esophageal burn injury (EBI) was produced in male Wistar albino rats by the application of 37.5% NaOH onto the distal esophagus (n=40), while only 0.09% NaCl solution was instilled in the control group (n=8). Until the rats were decapitated on the 3rd day (early group) or on the 28th day (late group) of EBI induction, rats were treated intraperitoneally with saline or halofuginone (100 µg/kg/day) on each day (early group) or on alternate days (late group). Nitric oxide (NO), peroxynitrite (ONOO-), nuclear factor (NF)-κB, caspase-3 and luminol- and lucigenin-enhanced chemiluminescence (CL) levels were measured in the esophageal tissues. Tissue samples were prepared for histopathological evaluation. Statistical analysis was performed by ANOVA and Student's t-tests.
RESULTS: NFκB and caspase-3 levels were not different among groups. Microscopic damage scores were elevated in both early and late EBI groups ($p<0.001$), while halofuginone treatment reduced the microscopic damage scores in both groups. NO, ONOO- and CL levels, which were elevated in the saline-treated early EBI group ($p<0.05$-0.001), were suppressed by halofuginone treatment ($p<0.05$). EBI-induced elevations in NO and ONOO- levels were reduced in the late period of saline-treated group, while these levels were increased by halofuginone ($p<0.001$). EBI-induced high CL levels were not changed in the late groups treated with either saline or halofuginone.
CONCLUSION: In the early period, halofuginone alleviated injury of the caustic esophagus by reducing the release of oxygen/nitrogen-derived free radicals. Although halofuginone was still efficient in reducing EBI in the chronic phase, its oxidant scavenging effect was replaced by enhanced production of nitrogen radicals, suggesting the contribution of other anti-inflammatory mechanisms.

Keywords: Caustic, eusophagus, halofuginone,

10.5505/2017ichc.PP-234 [Pathology and clinical medicine]

The effect of phosphodiesterase-5 inhibitor tadalafil on the severity of joint injury in rats with adjuvant arthritis

Elif Bahadır[1], M. Kutay Köroğlu[2], Feriha Ercan[2], Inci Alican[1]

[1]Department of Physiology, School of Medicine, Marmara University, Istanbul, Turkey

[2]Department of Histology & Embryology, School of Medicine, Marmara University, Istanbul, Turkey

INTRODUCTION: Rheumatoid arthritis (RA) is a systemic inflammatory and autoimmune disease, characterized by chronic, symmetric and erosive synovitis, mainly of peripheral joints. Although etiology of RA is not clearly described, recent research efforts have been focused on oxidative stress. Tadalafil is a selective and potent inhibitor of phosphodiesterase (PDE)-5 for the cure of sexual dysfunction. PDE-5 inhibitors have been proved to reduce oxidative stress to decrease inflammatory events in various experimental models. This study aimed to investigate whether tadalafil has a protective effect on the severity of joint damage using an experimental RA model.
METHODS: Male Sprague-Dawley rats (300-450 g) were inoculated intradermally into the plantar surface of right hand paw with 0.1 ml of complete Freund' adjuvant (CFA) containing 10 mg/ml of heat-killed Mycobacterium tuberculosis. Control group received paraffin oil. Treatment groups, after being injected with CFA, were treated with tadalafil (10 mg/kg; per oral) alone or along with the guanyly cyclase inhibitor ODQ (10 mg/kg; intraperitoneally), the non-selective nitric oxide synthase inhibitor L-NAME (25 mg/kg; subcutaneously) or the non-selective cycloxygenase inhibitor indomethacin (10 mg/kg; intraperitoneally) through days 5-15. After decapitation on day-16, metatarsophalangeal joints were sampled, fixed in formalin, prepared routinely for paraffin embedding. Paraffin sections were stained with hematoxylin & eosin and Masson's trichrome for histopathological evaluation in terms of inflammatory cell infiltration, pannus formation, cartilage and bone damage. Statistical analysis was performed by ANOVA and Student's t-tests.
RESULTS: On day-15, there was increased paw edema in arthritis group compared to control (34.76±0.93 mm2, 31.28±0.14 mm2, respectively; $p<0.01$). Tadalafil did not show a beneficial effect on the extent of paw edema due to arthritis (37.79±0.60 mm2). High microscopic score of the arthritis group (4.17±0.79; $p<0.001$) in comparison to control (0.02±0.01) was attenuated by tadalafil (1.17±0.31; $p<0.01$); however, ODQ, L-NAME or indomethacin did not seem to change the effect of tadalafil on this parameter.
CONCLUSION: The results of the present study suggest that inhibition of phosphodiesterase-5 enzyme by tadalafil decreases the extent of the histopathological damage in metatarsophalangeal joints in a rat model of experimental RA.

Keywords: Adjuvant arthritis, tadalafil, phosphodiesterase-5, histology, rat

10.5505/2017ichc.PP-235 [Pathology and clinical medicine]

The effects of sunitinib on immunoreactivities of vimentin, E-cadherin and S100 in kidneys of the experimental Streptozotocin -induced mouse model

Saadet Özen Akarca Dizakar[1], Hüseyin Aktuğ[2], Fatih Oltulu[2], Gülperi Öktem[2], Altuğ Yavaşoğlu[2], Eda Açıkgöz[2], Gürkan Yiğittürk[2], Kenan Demir[2], Ayşegül Uysal[2]

[1]Department of Histology and Embryology, Gazi University Medical Faculty, Ankara, TURKEY

[2]Department of Histology and Embryology, Ege University Medical Faculty, İzmir, TURKEY

Diabetes mellitus (DM) is a chronic disease and has negative effects on most of system and organs including kidney. Sunitinib is an oral inhibitor of tyrosine kinase that cause sunitinib-induced hypoglycemia. The aim of this study was to investigate the possible effects of tyrosine kinase inhibitor sunitinib on the kidney of Streptozotocin (STZ) -induced type 1 diabetic mice.
In this study, twenty- eight CD 1 type male mice were used and equally divided into four groups (n=7). Type I diabetes was induced by intraperitoneal (i.p.) administration STZ. Fourteen mice with normal blood glucose levels were included in control group (Group 1) and control treated sunitinib group (Group 2). Mice with ≥250 mg/dL blood glucose levels were considered as diabetic with saline group (Group 3) and sunitinib- treatment group (Group 4). After 8 week kidneys were removed. The immunoreactivities of vimentin, E-cadherin and S100 and were evaluated by using immunohistochemical procedure. Immunostaining of vimentin, E-cadherin and S100 were situated in both of the glomeruli and tubules of the kidney. Our results showed that the number of vimentin and E-cadherin positive glomeruli and tubules were increased after sunitinib treatment, compared to saline-treated diabetic mice. However, vimentin labeled tubules, were decreased in the sunitinib treatment group compared to diabetic+saline groups. There were no statistically significant differences the number of S100 positive tubules and glomeruli in the between group 3 and 4. In this study, we can conclude that the effect of sunitinib on the experimental diabetic mouse model are related to immunostaining of vimentin, E-cadherin and S100 in glomeruli and tubulus of kidney and sunitinib may have positive effect for treatment of renal damage from diabetic process.

Keywords: Sunitinib, S100, vimentin, E-cadherin and diabetes mellitus

figure

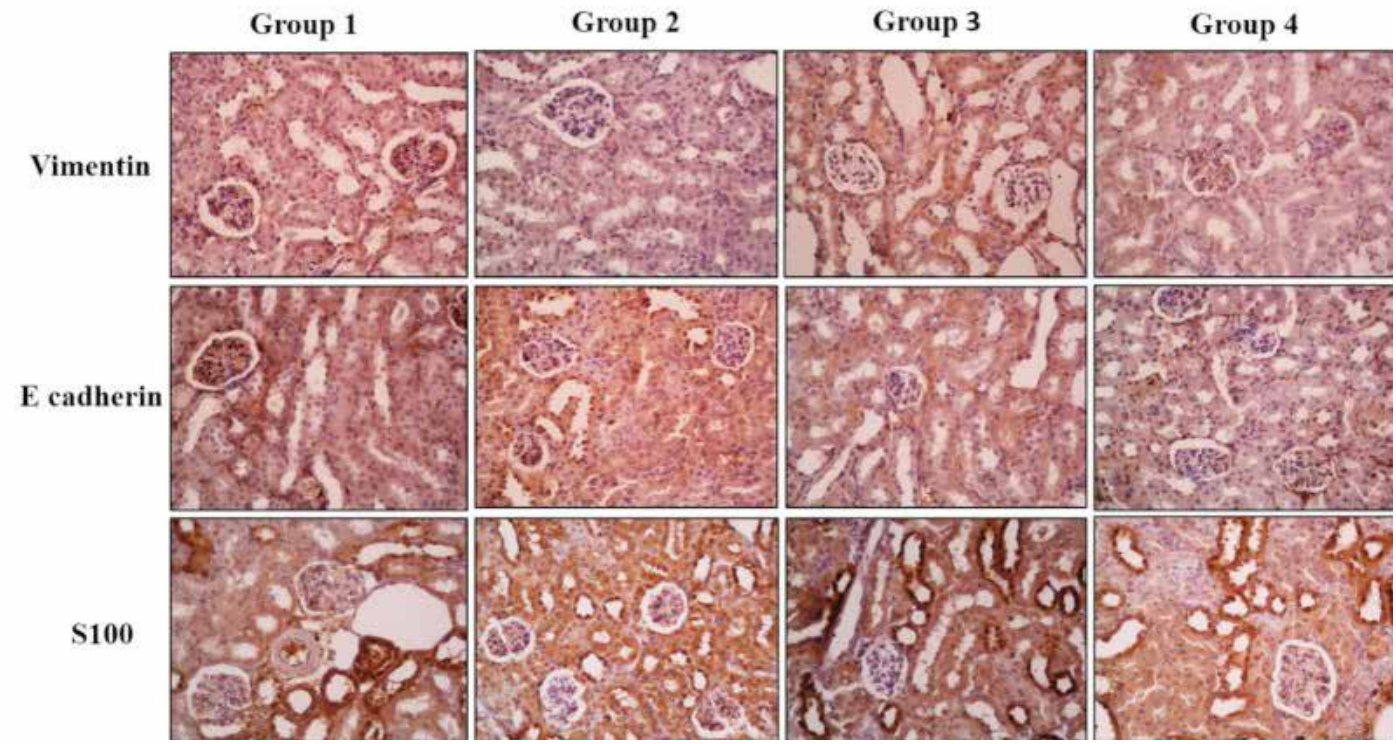

Vimentin, E-cadherin and S100 immunostaining in renal tissue. Magnification x400

10.5505/2017ichc.PP-236 [Pathology and clinical medicine]

The Effects of Atorvastatin on Renal Injury That Occurs Associated with Pulmonary Fibrosis

Ayse Karatug Kacar, Merve Yildirim, Sehnaz Bolkent, Fusun Oztay
Department of Biology, Faculty of Science, Istanbul University, Istanbul, Turkey

Introduction & OBJECTIVES: Idiopathic pulmonary fibrosis is a fatal fibrotic lung disorder. It is known that pulmonary fibrosis induced renal inflammation. The protective effects of atorvastatin on lung diseases and acute kidney injury were shown by several studies. The present study was designed to investigate the effects of atorvastatin on renal injury that occurs associated with pulmonary fibrosis (PF).
Materials & METHODS: PF in mice was induced by bleomycin. Adult mice were divided into four groups: mice dissected 21days after the bleomycin instillation (0.08 mg/kg in 200 µl) (I) and their controls (II), and mice treated with atorvastatin (20 mg/kg in 400 µl, intraperitoneally) for 10 days 7 days after bleomycin instillation and dissected 21 days after instillation (III) and their controls (IV). After the mice were killed, the kidneys of mice were harvested for microscopic and immunoblotting analyses.
RESULTS: It was detected the induced TGF-beta signaling, decreased pSMAD-2 level and some degenerative alterations, such as mononuclear cell infiltration, increased interstitial tissue and injured proximal tubule epithelium in the kidney tissue of mice with PF. The treatments of atorvastatin to mice with PF resulted in a significant increase in the activation of TGF-beta and degree of the present tissue damage, decrease in the activation pSMAD-2, but not change pSMAD-3 activation, in the kidneys of these mice.
CONCLUSIONS: Pulmonary fibrosis induced kidney damage. However, atorvastatin used as a therapeutic agent in the present study contributes to kidney injury as well. Atorvastatin, using as an antifibrotic agent in PF, is not effective agent on the regression of kidney damage in mice with PF. Moreover, it can induce kidney injury due to it's toxic effect. SMAD signaling seems not to be related to the kidney damage induced by PF.

Keywords: Atorvastatin, Bleomycin, Kidney, p-SMAD-2,3, TGF-beta

10.5505/2017ichc.PP-237 [Pathology and clinical medicine]

Effect of different aerobic exercise frequency on type 2 diabetes in rats

Nuray Alaca[1], Serap Uslu[2], Umit Ince[3], Mustafa Serteser[4], Guldal Suyen[5], Hızır Kurtel[6]

[1]School of Physiotherapy and Rehabilitation, Acibadem University, Istanbul, Turkey

[2]Histology and Embryology, School of Medicine, Istanbul Medeniyet University, Istanbul, Turkey

[3]Pathology, Acibadem University, School of Medicine, Istanbul, Turkey

[4]Biochemistry, Acibadem University, School of Medicine, Istanbul, Turkey

[5]Physiology, Acibadem University, School of Medicine, Istanbul, Turkey

[6]Physiology, Marmara University School of Medicine, Istanbul, Turkey

INTRODUCTION: Recommendations for exercise and physical activity by professional organizations and government agencies advise that moderate-intensity physical activity may be accumulated in bouts of >10 min each to attain the daily goal of >30 min/day. Although accumulated approach is useful increasing adhesion of an individual to exercise program, benefits in diabetic conditions are not studied. Thus, the objectives of this study is to compare the alterations induced by long-moderate exercise pattern with short bouts of exercise for a given duration and volume on the histopathological structure of skeletal muscle in an experimental model of type 2 diabetes mellitus (T2DM).
MATERIALS-METHODS: T2DM was induced by using nicotinamide (NAD-110mg/kg) and streptozotocin (STZ-65mg/kg) in Sprague Dawley rats (n:35) and diabetic rats were allocated into the groups of sedentary control (SC), sedentary diabetes (SD), diabetes and continuous exercise (DcE; swimming for 30 minutes/day and 5 days/week) and diabetes and short bout of exercise (DsbE, swimming, 3x10 minutes/day, 5 days/week). After 6 weeks of exercise, biochemical tests were performed to measure insulin and glucose. Hematoxylin-eosin, Modified Gomori's Trichrome, Periodic Acid-Schiff and Oil Red O stains were performed for histologic evaluation. Additionally, muscle oxidative enzyme activities including Cytochrome C oxidase (COX), Succinate Dehydrogenase (SDH) and Ragged Red Fibers (RRF) were analyzed.
RESULTS: In the SD group, increased blood glucose were accompanied by interfibriller connective tissue accumulation (CTA) and vacuolization, increased RRF levels and atrophy (slow and fast twitch fibers). In addition, insulin levels and SDH positive fiber density were found to be decreased in SD group compared to SC ($p < 0.05$). When compared to the SD group, significant improvements were observed in all training groups regardless of the exercise type. Blood glucose levels, CTA, vacuolization, muscle atrophy, content of muscle oxidative enzyme activities were all significantly improved in both DcE and DsbE groups compared to SD ($p < 0.05$).
CONCLUSION: The results of this study underlined the effect of exercise on myopathy and mitochondrial damage in the rat model of T2DM, while training frequency did not make any significant difference indicating the potential benefits of the accumulated approach.

Keywords: streptozotocin-nicotinamide, type 2 diabetes mellitus, continuous aerobicExercise, short bouth aerobic exercise, weekend warrior

10.5505/2017ichc.PP-238 [Pathology and clinical medicine]

The Effect Of Systemic And Local Minocycline On The Fat Graft Survival And The Inhibition Of Apoptotic Pathway

Kırdar Güney[1], Serhan Tuncer[1], Bora Özel[1], Çiğdem Elmas[2], Cemile Merve Seymen[2], Seyhan Çenetoğlu[1]

[1]Department of Plastic and Reconstructive Surgery, Medical School, Gazi University, Ankara, Turkey

[2]Department of Histology and Embryology, Medical School, Gazi University, Ankara, Turkey

INTRODUCTION: Recently use of fat grafting has been popularized in plastic surgery. Because it is good soft tissue filler, cheap and easily obtained and has no side effects so these are the main reasons for popularized using. But the survival rate of fat grafts is unknown.
AIM: The purpose of this study to increase fat graft survival rate and to inhibit early stage apoptosis that cause fat cell death after ischemia by using minocycline.
METHODS: 48 Wistar Albino rats were divided into 8 groups. Group 1 and 5 are control groups. Group 2 and 6 are systemic minocycline groups. Group 3 and 7 are local minocycline groups. Group 4 and 8 are local and systemic minocycline groups. In every group, inguinal fat pads were got and after systemic, local or both minocycline application, fat pads transplanted animal's back. Group 1, 2, 3 and 4 were sacrifice after 90 days later. Group 5, 6, 7 and 8 were sacrifice after 9 days later and all fat pads determined by Hematoxylin Eosine, 90. days groups stained by Oil Red O and 9. days groups examined by TUNEL stainings for all groups. Results also analysed using statistical methods.
RESULTS: Grafts treated with local and systemic minocycline group, changes in volume values are very low, the amount of size in all areas and lipid contents in intact fat cells was very high ($p<0.05$). It was followed by systemic drug administiration, local drug administiration and the control group. The maximum number of cells going into apoptosis were observed in control group, the minimum numbers were observed in the systemic and local drug administiration group ($p <0.05$).
CONCLUSION: In conclusion; degenerative histological changes and "brite adipocyte" formation were seen in 90.days groups due to the stress and the morphological features of white adipose cells were mostly protected by systemic minocyclin administration. Using systemic or local drug administiration is prevent apoptosis in early stages and they increase the number of living fat cells with intact lipid contents. By combining using systemic and local minocycline are potentiated and they effects the retention of fat volume.

Keywords: Fat pads, Minocycline, Oil red O, TUNEL

Figure 1

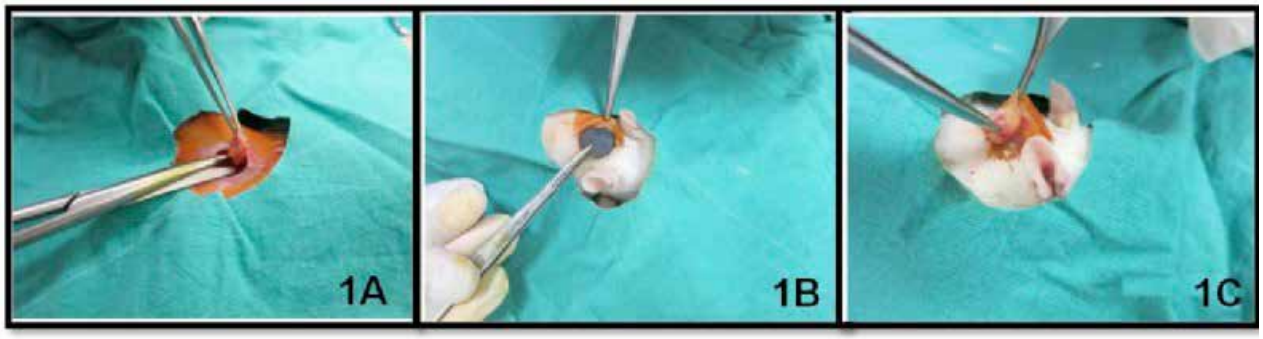

Figure 2

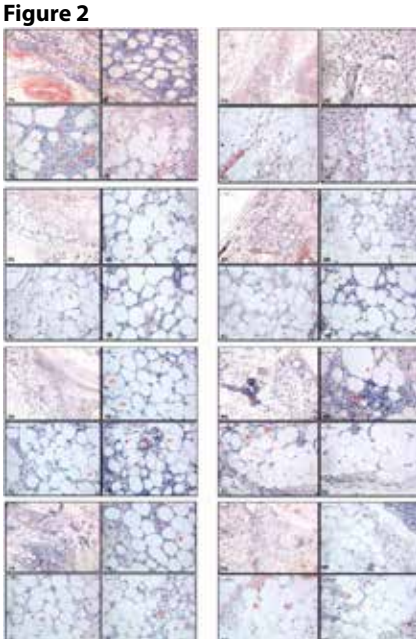

Figure 3

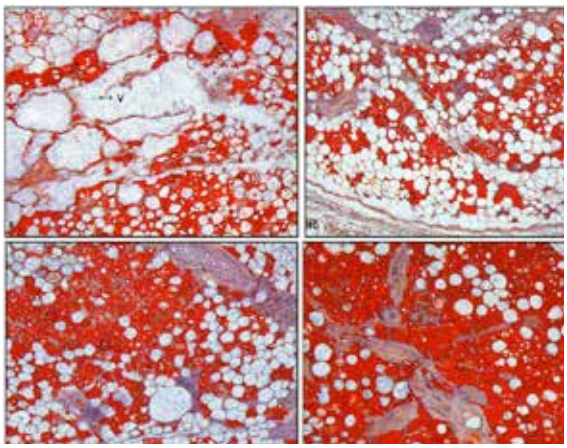

Figure 4

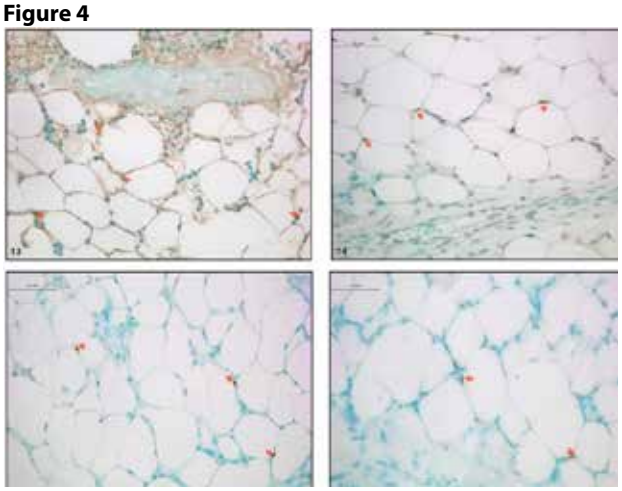

Graphic 1

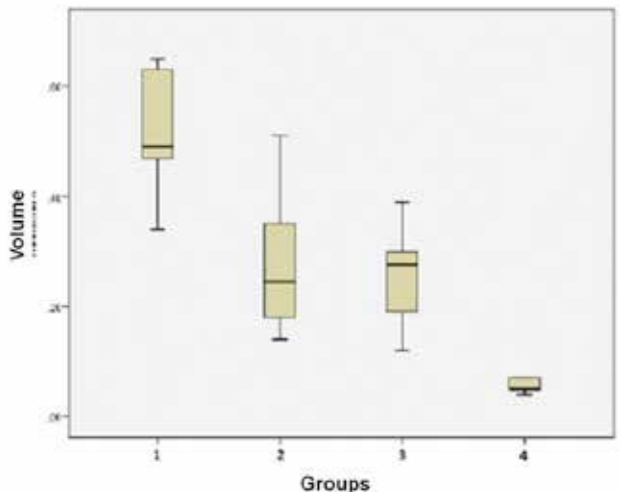

Graphic 2

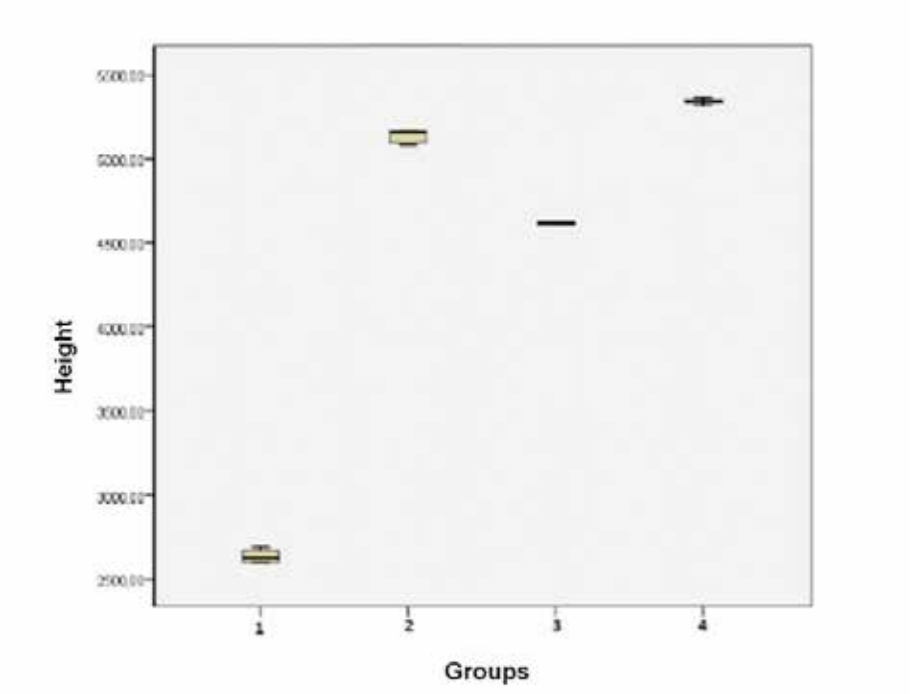

Graphic 3

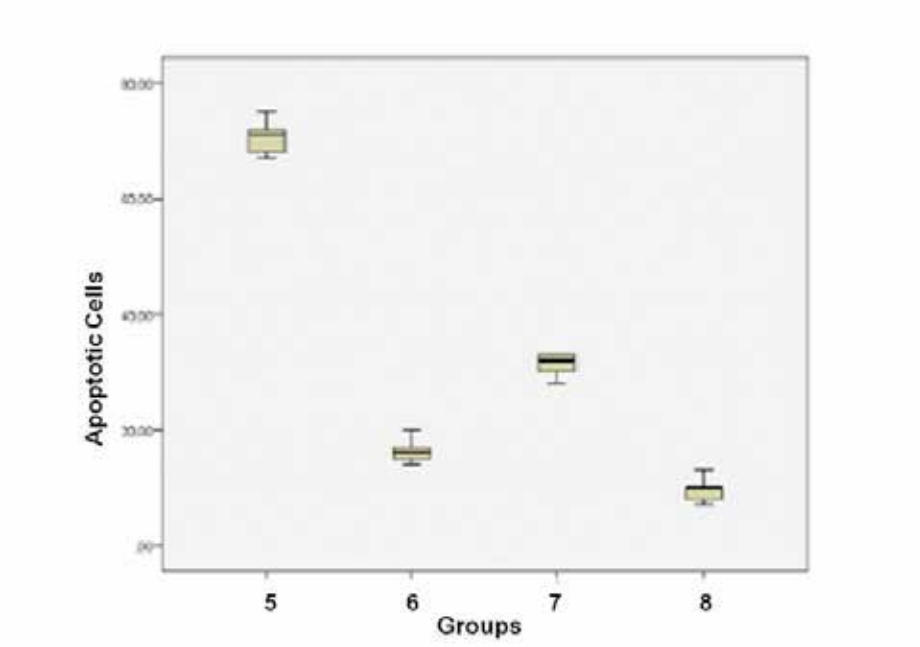

10.5505/2017ichc.PP-239 [Pathology and clinical medicine]

Protective effect of Caffeic acid phenethyl ester against cisplatin-induced nephrotoxicity in rats

Tayfun Ceylan, Emin Kaymak, Betül Yalçın, Birkan Yakan
Depatment of Hsitology and Embriyology, Erciyes University, Kayseri, Turkey

Cisplatin (CP), an antineoplastic drug made in the end of the 19th century (1). Cisplatin may cause ototoxicity, nephrotoxicity, myelosuppression, and peripheral neuropathy (2). Also cisplatin leads to Inflammation, oxidative stress, and apoptosis in nephrotoxicity (3,4).
Caffeic acid phenethyl ester (CAPE) is a component of propolis, a honey bee product (5). CAPE is used in traditional medicine. CAPE has protective properties for many tissues, has antiviral, anti-inflammatory, immunomodulatory, and antioxidant proporties. CAPE inhibits lipid peroxidation, lipoxygenase and cyclooxygenase enzymes (6-10).
The aim of this study is to evaluate the effects of caffeic acid phenethyl ester on nephrotoxicity induced by cisplatin.
A total of 40 male rats were equally divided into four study groups namely, control, CP (7mg/kg for 7 th day), CAPE (10 µmol/kg /day for 10 days) and CP+CAPE (7mg/kg for 7 th +10 µmol/kg /day for 10 days). The rats were decapitated under ketamine anesthesia and their kidney tissues were removed. Tissue superoxide-dismutase (SOD), catalase (CAT) and the level of malondialdehyde (MDA) and histopathological damage scores were then compared.
İn CAPE group, tissue CAT and SOD levels were higher than control group. When SOD and CAT levels were measured, no significant difference was observed between CAPE and CP+CAPE groups. İn CP group, tissue MDA levels were higher than control group, but interestingly, the dose of CAPE we administered increased the level of MDA in the kidney. İn CP group, tubules observed dilated with thin denuded lining epithelium, atrophy when compared with control group. CAPE treated group showed showed an decreased histological appearance in the CP group.
Our results suggested that CAPE increases antioxidant activity, while it causes lipid damage as dose-dependent in kidney tissues. CAPE can be protective effect against tubular damage.

Keywords: Cisplatin, nephrotoxicity, Caffeic acid phenethyl ester

10.5505/2017ichc.PP-240 [Pathology and clinical medicine]

Protective Effect of Origanum majorana Against Nephrotoxicity Induced by gentamicin

Abdullah Özdaşçı[1], Emin Kaymak[1], Ali Tuğrul Akin[2], Birkan Yakan[1]

[1]Depatment of Hsitology and Embriyology, Erciyes University, Kayseri, Turkey

[2]Depatment of Biology, Erciyes University, Kayseri, Turkey

Gentamicin (GM) is an important aminoglycoside antibiotic against life threatening bacterial infections. İt causes nephrotoxicity and ototoxicity and major problems for its effective long term clinical use [1]. GM nephrotoxicity leads to accumulation in the renal proximal convoluted tubules and tubular necrosis [2].

Origanum majorana L. (OM) belonging to Lamiaceae family has antiviral, antibacterial, antiseptic ve antifungal effects [3-4]
The aim of this study is to investigate protective effects of Origanum majorana on gentamicin induced nephrotoxicity in rats.
In this study, 48 adult Wistar albino rats, each weigthing 200–250 g were used. They were equally divided into 6 groups: group I (control, only olive oil for 28 days), group II (0,32 ml/kg OM for 28 days), group III (0,64 ml/kg OM for 28 days), group IV (gentamicin 100 mg/kg/d for 8 days as of 21th day), group V (0,32 OM for 28 days and GM as of 21th day) and group VI (0,64 OM for 28 days and GM as of 21th day). Kidney tissues were evaluated histopathologically for determining gentamicin induced renal tubule damages and also evaluated apopitosis by TUNNEL assay. Anti-oxidant enzymes such as superoxide-dismutase (SOD), catalase (CAT) and the level of malondialdehyde (MDA) were studied in the kidney tissues of rats with enzyme-linked immunosorbent assay (ELISA).
Glomerular damages, tubular dilations and tubular atrophy were observed in GM groups compared to control group. OM treated GV (0,32 OM+GM) showed that OM decreased kidney damage induced by GM. Apopitosis increased statistically in GIV (GM) compared to control group and decreased statistically in OM treated GV (0,32 OM+GM) compared to GIV.
MDA levels in GIV increased compared to control group and decreased in GVI compared to control group. It is observed that SOD and CAT enzyme activities decreased in GV and GVI while OM in G2 and G3 increased SOD and CAT enzyme activities.
Our results showed that 0,32 mg/kg dose of OM may have protective effects on kidney damage and apoptosis induced by GM. Therefore, we suggested that OM can use as an effective antioxidant in further studies

Keywords: Gentamicin, Nephrotoxicity, Origanum majorana

10.5505/2017ichc.PP-241 [Pathology and clinical medicine]

Natural anti-oxidant for skeletal muscle death prevention

Sara Salucci, Francesco Maria Giordano, Davide Curzi, Michela Battistelli, Debora Burini, Elisabetta Falcieri, Sabrina Burattini
Department of Biomolecular Sciences, University of Urbino Carlo Bo, Urbino, Italy

Introduction & OBJECTIVES: Tyrosol (4-(2-hydroxyethyl) phenol) (Tyr) is a well-known phenolic compound present in extra-virgin olive oil. Some papers in literature already reported the antioxidant, antimicrobial and anti-inflammatory properties of this molecule which seems to have also scavenging effects on peroxynitrite and superoxide anion [1]. Moreover, Tyr exhibits anticancer, anti-depressant, anti-stress, cardioprotective, anti-osteoporosis, anti-inflammatory and neural protective effects [2]. Here Tyr effect has been investigated in C2C12 muscle cell line exposed to known oxidative stress inducers [3, 4].
Materials & METHODS: Tyr protection against oxidative stress and cell death has been investigated through ultrastructural and confocal microscopy functional analyses, focusing our attention on the mitochondrial behavior.
RESULTS: all techniques confirmed that Tyr is able to prevent skeletal muscle damage and to preserve the mitochondrial membrane integrity and functionality.
CONCLUSIONS: all together, these findings demonstrate that Tyr has antioxidant properties in this skeletal muscle cell model, and suggest, for this molecule, a potential protective role against muscle diseases related to ROS production and accumulation.
References
[1] Vlachogianni et al. (2015) In vitro assessment of antioxidant activity of tyrosol, resveratrol and their acetylated derivatives. Food Chemistry 177, 165.
[2] Chandramohan et al. (2015) Tyrosol, a phenolic compound, ameliorates hyperglycemia by regulating key enzymes of carbohydrate metabolism in streptozotocin induced diabetic rats. Chem Biol Interact 229, 44.
[3] Salucci et al. (2014) Melatonin prevents chemical-induced haemopoietic cell death. Int J Mol Sci 15, 6625.
[4] Burattini et al. (2013) Anti-apoptotic activity of hydroxytyrosol and hydroxytyrosyl laurate. Food Chem Toxicol 55, 248.

Keywords: Tyrosol, C2C12 cells, oxidative stress

Figure

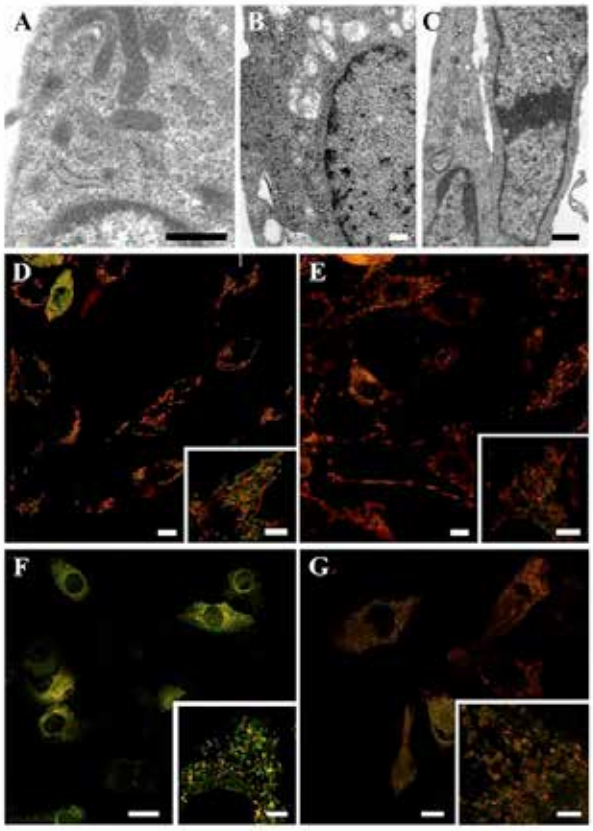

C2C12 cell line at TEM (A-C) and CLSM after JC-1 staining (D-G). Control (A, D), Tyr alone (E), H2O2 (B, F), H2O2 +Tyr (C, G). A, bar= 10 µm; B, bar= 0.25 µm; C, inset D, inset E, inset F, inset G, bar= 0.5 µm; D, E, G, bar= 10 µm; F, bar= 25 µm.

10.5505/2017ichc.PP-242 [Pathology and clinical medicine]

Effect of Pioglitazone on the expression of Ubiquitin proteasome system (UPS) proteins in rat pancreas with metabolic syndrome

Sevil Cayli[1], Ayca Bilginoglu[2], Ilkay Piskin[1], Ebru Alimogullari[1], Hilal Nakkas[1]

[1]Department of Histology & Embryology, Ankara Yildirim Beyazit University, Ankara, Turkey

[2]Department of Biophysics, Ankara Yildirim Beyazit University, Ankara, Turkey

INTRODUCTION: The metabolic syndrome (MS) and pathologies associated with metabolic dysregulations became a worldwide spreading and growing problem.It was recently shown that modulation or restoration of Ubiquitin proteasome system (UPS) function may be an effective approach preventing MS detrimental consequences.However, the mechanisms mediating the according cellular changes is still at the beginning. For this reason, we hypothesed that MS-related pathological changes effect on UPS.In this study, our first aim is to detect whether MS effects on the expression of UPS proteins (p97/VCP, SVIP and ubiquitin) in rat pancreas and our second aim is to test whether treatment with pioglitazone (antidiabetic drug) has impact on the UPS.
MATERIAL-METHODS: Male Wistar rats divided into three groups such as control group, metabolic syndrome group, and metabolic syndrome + Pioglitazone (PGZ) group.Metabolic syndrome was induced by providing drinking water that was 32% sucrose, for 18 weeks. In order to detect the effect of Pioglitazone, rats were given intragastric Pioglitazone for 8 weeks. All of the animals were exposed to a 12h light – 12h dark cycle. Abdominal obesity and glucose intolerance had measured as a marker of metabolic syndrome.At the end of the treatment period, animals from each group were sacrifed and pancreatic tissues were snap-frozen in liquid nitrogen and stored at -80 °C for Western blotting and embedded in paraffin for immunohistochemistry. H SCORE analysis was used to evaluate the immunohistochemistry results.
RESULTS: MS rats had altered body weight, abdominal obesity and glucose intolerance indicating successful establishment of our MS model. In control group, moderate to strong p97/VCP expression was observed in langerhans islet of rat pancreas, however SVIP expression was barely detected. In MS group,SVIP expression was significantly increased while decreased p97/VCP expression was seen.Treatment with PGZ,reduced the expression of SVIP in MS rats. SVIP expression was only seen in the beta and alpha cells of islet, howeverp97/VCP immunoreactivity observed not only in the islet but also in the exocrine part of rat pancreas.
CONCLUSION: MS in rat pancreas appears to play important role in disruption of the ubiquitin-proteasome system.PGZ has an effect on UPS and may direct to therapeutic approaches.

Keywords: Metabolic syndrome, pancreas, pioglitazone, rat, ubiquitin proteasome system

10.5505/2017ichc.PP-243 [Pathology and clinical medicine]

Investigation of the Effect and Damage of Fulvic Acid in the Stomach and Intestinal Mucosa Under Chronic Water Avoidance Stress

Sezen Gizem Gürel[1], Ibrahim Söğüt[2], Türkan Sarıoğlu[3], Canan Hürdağ[4], Esra Çikler Dülger[5]

[1]Department of Histology and Embryology TC İstanbul Bilim University Sezen Gizem GÜREL, Istanbul, Turkey

[2]Department of Medical Services and Techniques, Vocational School of Health Services, Istanbul Bilim University, İbrahim Söğüt, Istanbul, Turkey

[3]Department of Histology and Embryology TC İstanbul Bilim University Türkan Sarıoğlu, Istanbul, Turkey

[4]Department of Histology and Embryology TC İstanbul Bilim University Canan Hürdağ, Istanbul, Turkey

[5]Department of Histology and Embryology TC İstanbul Bilim University Esra Çikler Dülger, Istanbul, Turkey

Choronic stress model which created by the water avoidance stress,increases the progress of gastric diseases.Oxidative stress occurs under these conditions where antioxidant defense systems which control the formation of free radicals in the tissues are inadequate.Many drugs available for the treatment of gasrointestinal system disease,these drugs sometimes cannot succeed.Fulvic acids (FA) are completely natural and do not show toxic effects so they are a light of hope as a therapeutic agents.Fulvic acid exhibits an organic and stable atomic structure and provides an antioxidant and antiinflammatory effect by forming a bond instead of reactive oxygen species.This is the first study of fulvic acid to be used as a histologically therapeutic agent in the recovery of gastrointestinal damage in our country.Three experimental groups were established (18 Sprague-Dawley male rats,300gr):Control(C),Chronic Stres(CS) and Chronic Stres+Fulvic Acid(CS+FA).Rats in the stress group were exposed to WAS(1 hr/day) for 10 days.Histological sections obtained from stomach and small intestines of animals were histochemically stained with Hematoxylen-Eosin and Periodic Acid Schiff (PAS) and Toluidine blue.For immunohistochemical markers eNOS and iNOS were examined along with biochemical markers.Tissues were evaluated also biochemically to determine TAS,TOS,SOD,GPx and CAT parameters.150 mg/kg dose of FA injected to the group of CS+FA and compared with the C and CS.Histological findings of CS that mucosal damage,cellular losses, connective tissue inflammation,thinning of mucus layer,activation in mucous surface cells,activation and increase in mast cell number.In CS+FA showed improvement in the epithelial cell structure forming the mucosa and thickening of the superficial mucus layer.Inflammation on connective tissue which increased in stress conditions was not seen in CS+FA and also mast cell numbers decreased in terms of both numerical and activity when the compare with the control group.As a biochemically analyzes the levels of antioxidants parameters were increased in CS+FA when compared with the C and CS groups.In addition,FA decreased the levels of the oxidant parameters in the stomach and intestinal tissues of the rats when the compared to CS group.Concluted that the FA has antioxidant and antiinflammatory effects on the stomach and small intestines tissues.However, It is necessary to study at higher doses so that FA can fully heal.

Keywords: Antioxidant, Inflammation, Fulvic Acid, Water Avoidance Stress, Oxidative Stress

10.5505/2017ichc.PP-244 [Pathology and clinical medicine]

Histological Examination of the Effect of *Lycium Barbarum* (Goji Berry) Extract on Testis and Epididymis of Acrylamide Treated Young Male Rats

Havva Imran Özdemir, Aysel Kükner
Department of Histology and Embriyology, Abant İzzet Baysal University, Bolu, Turkey

Introduction and Objectives: In this study, it is aimed to contribute to alternative mediciene by reducing oxidative stress which is resulted from the toxic effect of acrylamide and causes infertility.
Material and Method: 2-3 months old wistar albino male rats are categorized into 4 groups which each of all consists of 6 rats as random. The groups are as follows: Acrylamide (ACR) group (n=6), ACR+ Goji berry (treatment) group (n=6), negative control group (n=6), positive control group (only goji berry treated) (n=6). ACR group is treated with 50 mg/kg ACR via gavage one time per day for 5 consecutive days. For treatment group,ACR is applied as former. Additionally, the group is treated with 200 mg/kg goji berry extract via gavage one time per day for 5 consecutive days. Positive control group is treated with 200 mg/kg goji berry extract one time per day via gavage for 5 consecutive days.
Results: According to routine histological stainings (H&E, Masson's Trichrome, and PAS) there is no big difference in testis tissues of 4 groups. (Fig. 1). In epididymises of ACR group sperm reserves are decreased compared to other groups (Fig. 2).The difference is seen at immunohistochemical staining (TUNEL). The number of apoptotic cells is very high in ACR and positive control group compared to other groups (Fig. 3).

Keywords: Acrylamide, testis, goji berry, infertility

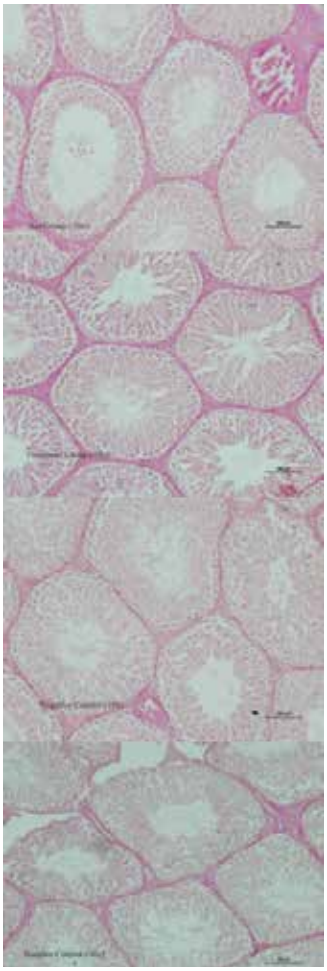

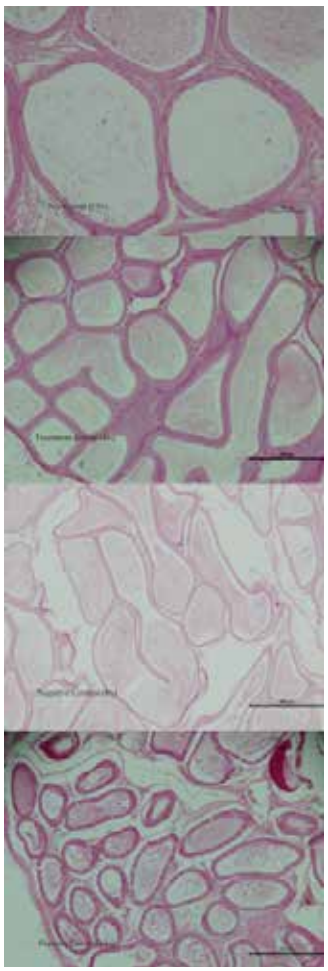

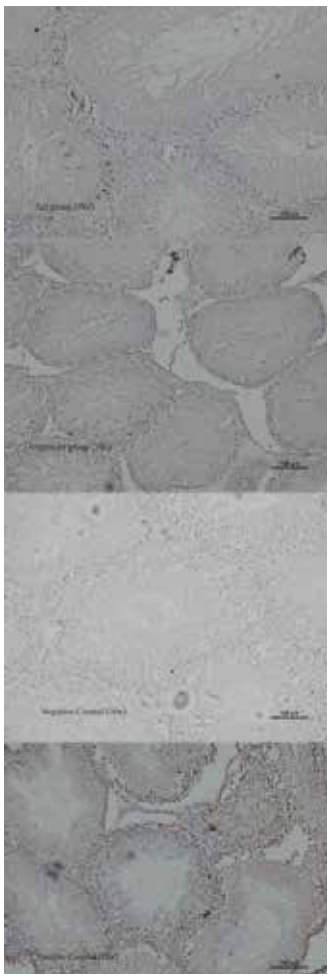

Fig 1 It shows the differences in the testis tissues between four groups
Fig 2 It shows the differences in the epididymis tissues between four groups.
Fig 3 It shows TUNEL staining differences between four groups.

10.5505/2017ichc.PP-245 [Pathology and clinical medicine]

Custodiol versus Blood Cardioplegia; Comparision of Myocardial Tissue Effects in Adult Cardiac Surgery

Ünal Aydın[1], Onur Şen[1], Ersin Kadiroğulları[1], Süheyla Gonca[2], Alev Cumbul[3], Burak Onan[1], Korhan Erkanlı[1]

[1]Department of Cardiovascular Surgery, Istanbul Mehmet Akif Ersoy Thoracic and Cardiovascular Surgery Training Hospital, Istanbul, Turkey,

[2]Department of Histology and Embryology, Kocaeli University Faculty of Medicine, Kocaeli, Turkey

[3]Department of Histology and Embryology, Yeditepe University Faculty of Medicine, Istanbul, Turkey

Introduction & OBJECTIVES: During heart surgeries worldwide, substantially as a method of providing cardiac arrest "Blood cardioplegia" is used. In some centers in long-awaited procedures, cardiac arrest is achieved using "custadiol" solution. In our study, during aortic clamping between blood cardioplegia and custadiol groups of patients, we plan to investigate whether there is a difference in cell level of the two methods determined by immunoexpression.
Materials & METHODS: Ethics committee approval was received for this study. Our study carried out at Mehmet Akif Ersoy Thoracic and Cardiovascular Surgery Training Research Hospital consisted of 24 cases of patients. The study was planned as 2 groups (Group I:Custodiol, Group II:Blood cardioplegia) and each group contained 12 cases. Demographic datas and risk factors were analyzed and both groups were similar to each others. Cardioplegia was performed via antegrad in both groups and complete cardiac arrest was achieved. Before declamping atrial tissue sample was taken and kept in formalin until histopathological evaluation. Immunohistochemistry was performed(Formalin/PFA-fixed paraffin-embedded sections) using an avidin–biotin–peroxidase method. (Zymed, San Francisco, CA)
RESULTS: According to immunohistochemistry, in the Blood cardioplegia group, strong eNOS staining(+++), mild VEGF and iNOS staining(+++/++) and weak Bcl-2 and annexin staining(++) were seen. In Custadiol group, very strong eNOS staining(++++), mild VEGF and iNOS staining(+++) and weak Bcl-2 and annexin staining(++) were seen (Figure 1A).
CONCLUSIONS: Increased expression of NO derived from especially eNOS may contributes to myocardial protection of the Custadiol group. There is no significant difference showed by immunoexpression of VEGF, iNOS, Bcl-2 and annexin in atrial myocardium between Custadiol and Blood cardioplegia groups. Immunocytochemical analysis revealed that especially eNOS were well preserved in the atrial tissue with the custadiol group and blood cardioplegia group, and especially increased in Custadiol group. However, no significant difference was identified in our study that compared Custodiol solution and Blood cardioplegia groups. Large randomised trials are required.

Keywords: Cardiac surgery, custadiol solution, myocardial protection, immunohistochemistry

Figure 1A

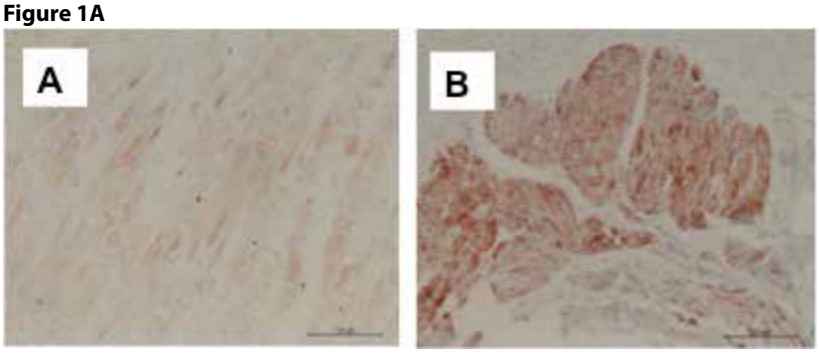

Control group. According to eNOS immunostaining well preserved immunoexpression of the atrial section. B. Custadiol group. According to eNOS immunostaining strong immunoexpression of the atrial section. Bar:120 µm

10.5505/2017ichc.PP-246 [Pathology and clinical medicine]

Role of Indomethacin in Corneal Neovascularization in Acid Burn of Rabbits

Semih Altan[1], Feray Altan[2], Hakan Sağsöz[3], Zeki Oğurtan[4]

[1]Department of Surgery, Faculty of Veterinary Medicine, Dicle University, 21280 Diyarbakir, Turkey

[2]Department of Pharmacology and Toxicology, Faculty of Veterinary Medicine, Dicle University, 21280 Diyarbakir, Turkey

[3]Department of Histology and Embryology, Faculty of Veterinary Medicine, Dicle University, 21280 Diyarbakir, Turkey

[4]Department of Surgery, Faculty of Veterinary Medicine, Selçuk University, 42030 Konya, Turkey

Owing to the presence of antiangiogenic factors and stromal barriers that prevent the production of angiogenic factors, the cornea is an avascular tissue. However, in the event of pathological conditions including infections, chemical burns, inflammation, graft rejection, and thermal injuries, the balance between these factors is disrupted. As a result, corneal neovascularization (CNV) develops, which leads to the loss of vision and blindness. CNV results from the disruption of the balance between angiogenic and antiangiogenic factors. In the study, in the corneal damage remodeled whether VEGI, VEGF and receptors expressions and topical drug treatments play a critical role in regulating corneal neovascularization was aimed to find out immunohistochemically. 36 mature male New Zealand rabbits were used. Under general anesthesia, after a corneal burn was formed by hydrofluoric acid, drug treatments of Indomethacin were administered. Rabbits were euthanized on the 2nd, 7th and 14th days of the experiment and each cornea was fixed in 10% neutral formol solution. Generally, it was ascertained that in Control and Indomethacin groups, on day 7, the epithelial and stromal cells, and in Indomethacin group, on days 7 and 14, the inflammatory cells displayed a stronger VEGF expression. It was observed that VEGI expression was weak in the stromal and inflammatory cells on days 7 and 14 in Indomethacin group. The NV areas were particularly larger in Indomethacin group, and the blood vessels showed a dense ramification. In conclusion, the presence of VEGI expression in the damaged cornea suggested that VEGI could be effective in maintaining in the inhibition of CNV. However, it was claimed that the topical administration of Indomethacin alone was inefficient in the inhibition of CNV.

Keywords: corneal burn, Indomethacin, anti-inflammatory, neovascularization

10.5505/2017ichc.PP-247 [Pathology and clinical medicine]

Dimethyl Sulfoxide Suppresses Corneal Neovascularization in Acid Burn of Rabbits

Semih Altan[1], Feray Altan[2], Hakan Sağsöz[3], Zeki Oğurtan[4]

[1]Department of Surgery, Faculty of Veterinary Medicine, Dicle University, 21280 Diyarbakir, Turkey

[2]Department of Pharmacology and Toxicology, Faculty of Veterinary Medicine, Dicle University, 21280 Diyarbakir, Turkey

[3]Department of Histology and Embryology, Faculty of Veterinary Medicine, Dicle University, 21280 Diyarbakir, Turkey

[4]Department of Surgery, Faculty of Veterinary Medicine, Selçuk University, 42030 Konya, Turkey

Corneal neovascularization (CNV) is characterized by the invasion of new blood vessels into the cornea from the limbus. It is caused by a disruption of the balance between angiogenic and antiangiogenic factors that preserves corneal transparency. Under inflammatory conditions, corneal epithelial and endothelial cells, macrophages, and inflammatory cells produce angiogenic factors such as vascular endothelial growth factor (VEGF) and fibroblast growth factors. In the study, in the corneal damage remodeled whether VEGI, VEGF and receptors expressions and topical drug treatments play a critical role in regulating corneal neovascularization was aimed to find out immunohistochemically. 36 mature male New Zealand rabbits were used. Under general anesthesia, after a corneal burn was formed by hydrofluoric acid, drug treatments of DMSO were performed. The animals were euthanized on the 2nd, 7th and 14th days of the experiment and each cornea was fixed in 10% neutral formol solution. On the 2nd, 7th and 14th days of experiments, VEGF, flk1/KDR and flt1/fms were strongly expressed in epithelium, stromal and inflammation cells rather than corneal endothelium cells ($p<0.05$). Especially, VEGI expression was stronger in the stromal and inflammatory cells. On the 7th day, it was observed that newly blood vessels were improving toward the center of cornea. The number of the newly formed blood vessels was greater in Control group compared to DMSO group ($p<0.05$). On day 14, in the NV areas, the new blood vessels were observed in the deep of the stroma and the number of blood vessels DMSO group were lower. In conclusion, it was determined that these angiogenic cytokines stimulated CNV by enabling the growth of new blood and lymph vessels in the inflamed cornea. It was ascertained that the topical administration of DMSO was more effective in the inhibition of CNV.

Keywords: burn, cornea, DMSO, hydrofluoric acid, neovascularization

10.5505/2017ichc.PP-248 [Pathology and clinical medicine]

Histopathological Evaluation of Desferrioxamine Effect on Fat Graft Viability

Bahadır Çelik[1], Deniz Billur[2], Pınar Bayram[2], Hilal Nakkaş[3], Şule Kızıl[2], Belgin Can[2], Kutlu Sevin[1]

[1]Department of Plastic and Reconstructive Surgery, Faculty of Medicine, Ankara University, Ankara Turkey

[2]Department of Histology and Embryology, Faculty of Medicine, Ankara University, Ankara Turkey

[3]Department of Histology and Embryology, Faculty of Medicine, Ankara Yildirim Beyazit University, Ankara Turkey

INTRODUCTION: Fat grafting is used for many important purposes and disadvantage of this surgery is that viability of graft cannot be foreseen.Tissue hypoxia is the most important stimulus for neovascularization.Hypoxia induced factor(HIF) increases at hypoxic tissue. Consequently vascular endothelial growth factor(VEGF) increases and leads to vascularization.Iron is cofactor of enzymes which eliminate HIF. Desferrioxamine is an iron chelation agent and can be used for increasing HIF levels and vascularization.Our aim was to see the effect of Desferrioxamine on graft viability.

Materials-METHODS: Rats seperated into 6 groups (n=8) randomly and fat grafts taken from inguinal area were placed under scalp skin. Group 1,2 and 3 were used to investigate fat viability whereas Group 4,5 and 6 were used for vascularisation evaluation.To Group 1 and 4(control) saline solution and Group 2 and 5(local treatment) desferrioxamine enjected to the graft area.To Group 3 and 6(systemic treatment) desferrioxamine was given by intramusculer injection.Group 1,2 and 3 were sacrified after 8 weeks and Group 4,5 and 6 were sacrified after 1 week.After fixation and preparation steps tissues were stained with Hematoxylene-Eosin(H-E) and VEGF Ab as immunohistochemically. Specimen was scored for viability of adipocytes, necrosis, cysts, fibrosis, inflammation and integrity.Vascularization is evaluated by a point counting method.

RESULT: At Group 2 and 3 adipocytes which contain nucleus and have a normal view were more than Group 1but it was statistically meaningless.Fibrotic areas were narrower and capillaries were more than control group. Inflammation, integrity and vascularization differences between groups (1,2 and 3) were statistically significant.Especially mononuclear cells at tissue were anti-VEGF(+).Comparement of group 4,5 and 6 showed that vascularization and positivity of VEGF is more at local and systemic desferrioxamine groups than control group and this difference was statistically significant.

DISCUSSION: Recent studies showed that VEGF increases vascularization and viability of graft. Also it is proved that desferrioxamine applications to different tissues increased tolerance to ischemia and reduced ischemia-reperfusion injury. In our study we found desferrioxamine contributes to graft viability by increasing integrity and vascularization and decreasing necrosis, fibrosis, cyst formation, inflammation.With further studies researchers can optimize application way, time, dosage and can develop a method for desferrioxamine usage on fat grafts.

Keywords: Fat graft, desferrioxamine, "vascular endothelial growth factor", graft viability, neovascularization

10.5505/2017ichc.PP-249 [Pathology and clinical medicine]

Histological evaluation of ozone combined collagen cross-linking (CXL) treatment on keratoconus

Aysun Sanal Dogan[1], Canan Gurdal[1], Sinan Caliskan[1], Evrim Onder[2], Fevziye Figen Kaymaz[3], Elif Bilgic[3]

[1]Department of Ophtalmology, Diskapi Yildirim Beyazit Training and Research Hospital, 06330 Ankara, Turkey.

[2]Department of Pathology, Diskapi Yildirim Beyazit Training and Researach Hospital, 06330 Ankara, Turkey

[3]Department of Histology and Embryology, Hacettepe University Faculty of Medicine, 06100 Ankara, Turkey

Keratoconus (KC) is a non-inflammatory ectatic disorder of the cornea that is characterized by the progressively bulging with abnormal corneal elevation and thinning in the central or paracentral area. Pathological changes in the stroma of cornea such keratocyte apoptosis and dysregulation of collagen fiber arrangements are observed in the course of the disease. Although there are classical treatment methods of keratoconus, nowadays corneal collagen cross-linking (CXL) is favored (1). CXL is a photopolymerisation reaction on cornea that is achieved by a photosensitizer (riboflavin) is excited by UVA leading to oxygen radicals end up with the corneal collagen cross-linking. Also ozone is an unstable trioxygene molecule that is a powerful oxidizing agent and theoretically may augment this reaction by the oxygen radicals released. Though, clinical effects of ozone treatment besides CXL protocol is not clear yet we hypothesized that ozone application with/without CXL treatment could be beneficial to correct the pathophysiological changes that were caused by keratokonus in the corneal stroma. The study was designed as composing from enucleated cadaver yearling lamp eyes (n= 28). Eyes were divided into groups: control (K, n:6), sham (A, n:6), ozone (B, n:6), CXL (C, n:5), Ozone+CXL (D, n:5). Individual cornea was dissected from the globe and specimens were taken for light and electron microscopic evaluation. Corneal stromal oxygen levels were higher in ozonated groups (B and D). There were increased tissue reflectivity in stroma, in groups B, C and D. Straight lines of collagen bundles were prominent especially in group D.
To figure out the effects of ozone treated groups samples were examined by caspase-3 activity for apoptosis of keratocytes. Caspase activity was higher in cross-linked groups (C and D).In toluidine blue-stained semi-thin sections Group D showed more regular, tight and parallel located less undulating collagen fibers compared to the other groups. In electron microscopic examination, we observed more regularly arrangement of fibers and extracellular matrix in group D. And both light microscopic and electron microscopic micrographs were compatible with these findings.
In conclusion, these findings hint the potential augmentative effect of ozon on the cross-linking capacity of the conventional CXL technique.

Keywords: Keratoconus, CXL, apoptosis, ozone, caspase-3, electron microscopy

Figure 1

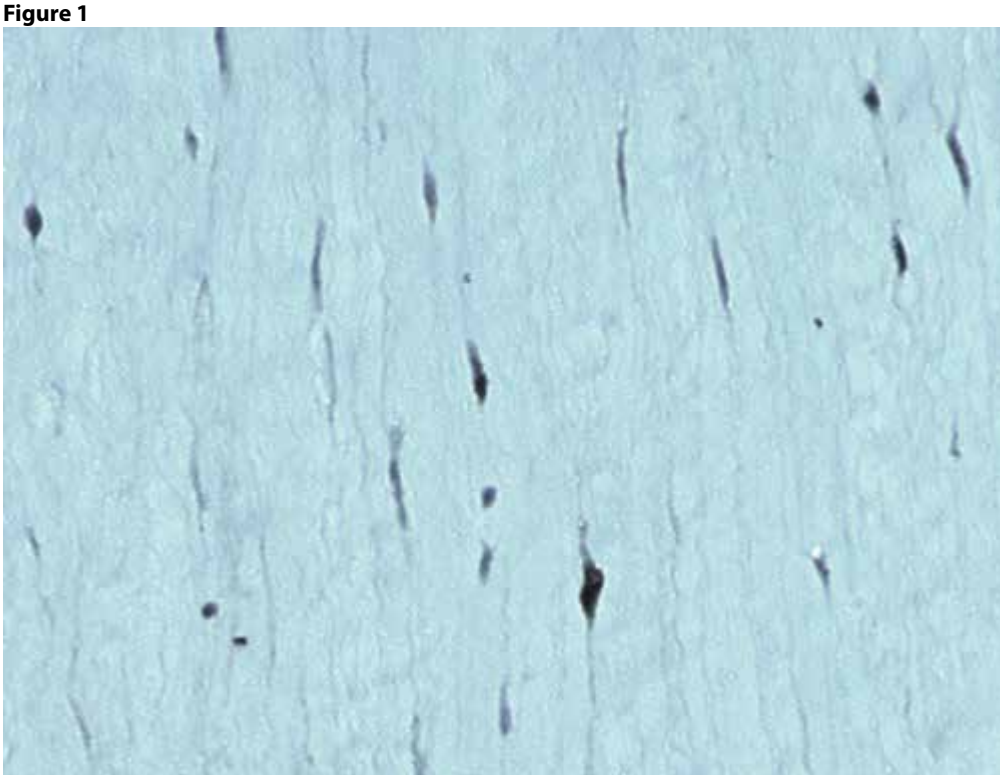

Caspase-3 immunopositivity in stromal cells of corneal section from D group. This positivity was scored as 4% (Methyl green) (X 400)

Figure 2

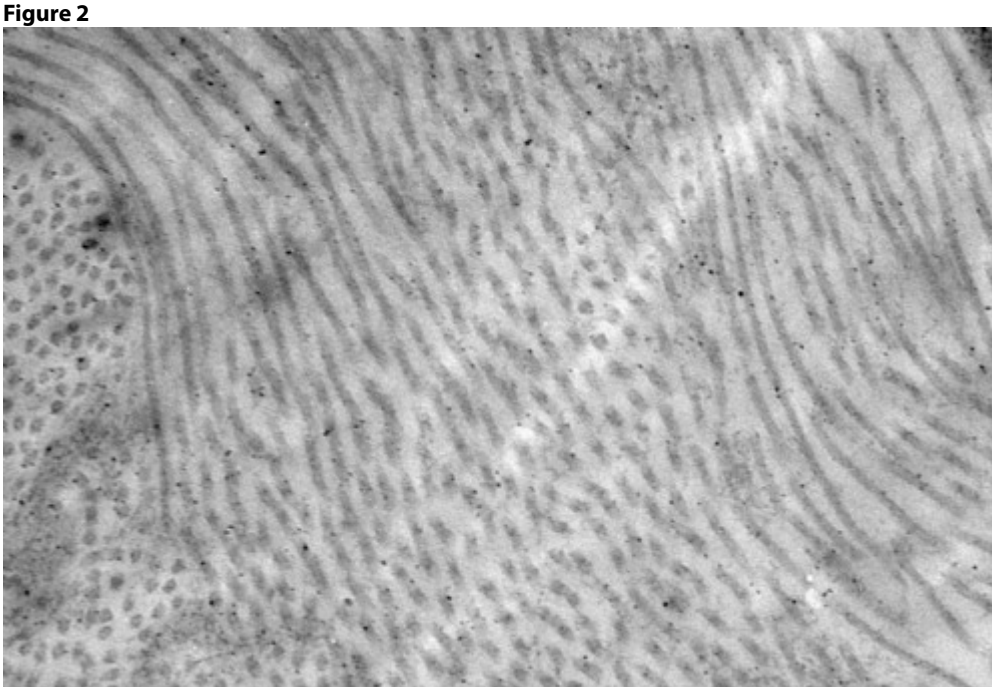

Electron micrograph of group 3 that shows the collagen fiber arrangement with extracellular matrix (50K)

Figure 3

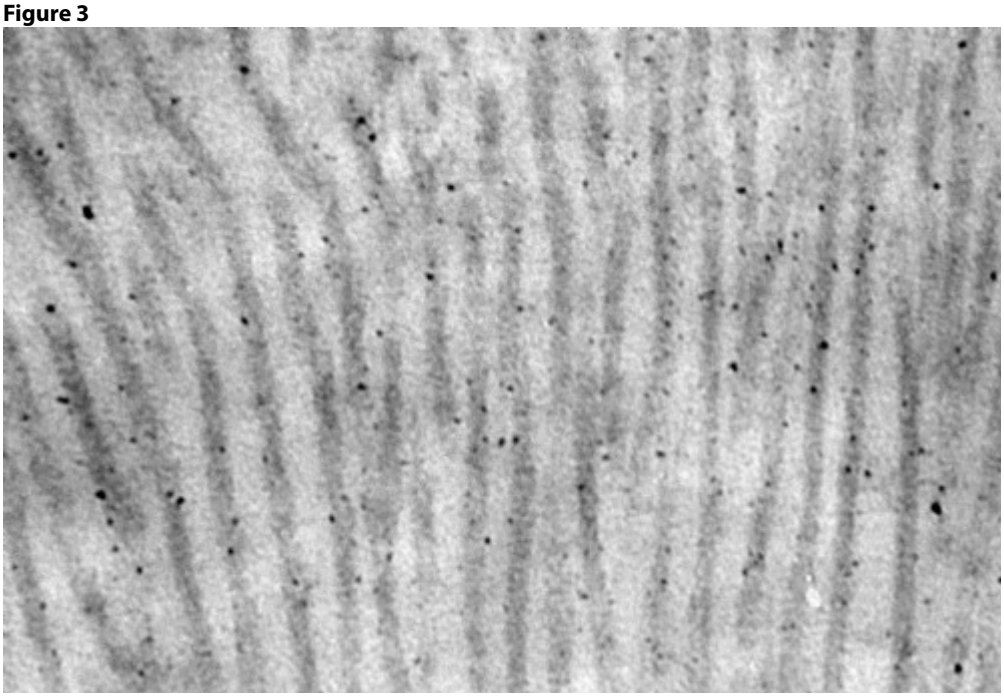

Higher magnification of collagen bundles and extracellular matrix of Group D (X100k)

The study was supported by TUBITAK. And the other colleagues presented the clinical part of the study in XXII Biennial Meeting of the International Society for Eye ResearchSeptember 25-29, 2016 | Tokyo, Japan as poster presentation.

10.5505/2017ichc.PP-250 [Pathology and clinical medicine]

Instant And Early Stage Post-Operative Histological Results Of Suturing And Stapler Techniques In Wedge Lung Resection

Sabire Güler[1], Nesrin Özfiliz[1], Hakan Salcı[2], Ahmet Sami Bayram[3]

[1]Department of Histology, Uludag University, Faculty of Veterinary Medicine, Bursa, Turkey

[2]Department of Surgery, Uludag University, Faculty of Veterinary Medicine, Bursa, Turkey

[3]Department of Thoracic Surgery, Uludag University, Faculty of Medicine, Bursa, Turkey

Introductıon and OBJECTIVES: The aim of this study was to evaluate instant and early post-operative stage histological results of suturing and stapler techniques in goat model lung wedge resection.
MATERIAL-METHODS: Totally 3 Saanen breed, male, about 3 year-old goats included the material of the study. After general anesthesia and endotracheal intubation of the goats, surgical preparations were made on left lateral thoracic wall. Left thoracotomy was performed and double row suturing was applied with 2 pieces of hand-suture (verlapping) (polyglactin 910; Vicryl®, Ethicon, US) and 2 pieces of stapler (Endopath® ETS, Ethicon, US) on the left lung lobes. Wedge resection was carried out with the bistoury from the mid-point of the double row suturing. While a part of tissue samples applied hand-suture and stapler was removing (Group A) the other suturing lung parts were placed into the thorax (Group B). After routine thoracic closure, the experiments were waited for tissue healing during 2 months of period post-operatively. At the end of 2nd month, the experiments were decapitated and lung tissues applied hand-suture and stapler were taken out or sampling. The samples were fixed in 10% formalin solution. The routine histological methods were applied to the fixed samples and embedded in paraffin. Five µm thick sections were cut from paraffin blocks, mounted on slides, and dried overnight. The sections were stained by the Crossman's triple stain for morphological examination.
RESULTS: Histologically, in the investigations of the samples taken group A; irregular, fragmented and separated wound edges due to hand suturing were observed. Integrity of the lung tissues on the stapler-applied parts was much more protected than hand-suture application. In the group B, because of the hand suture application, angiogenesis and common connective tissue existence was determined. Angiogenesis and minimal connective tissue cells were determined at the resected sites with stapler. CONCLUSION: As a Conclusion, in the wedge lung resection, it has been observed that stapler, which is an alternative to hand-suture, is a safely and effective technique in terms of tissue healing.

Keywords: hand-suture, stapler, histology, wedge lung resection

10.5505/2017ichc.PP-251 [Pathology and clinical medicine]

Effect of Folic acid Against Cisplatin-Induced Ototoxicity: A Functional and morphological study

Talip Talha Tanyeli[1], Hatice Karadaş[1], Ilker Akyıldız[1], Ozan Gökdoğan[2], Çiğdem Sönmez[3], Naciye Dilara Zeybek[4]

[1]Department of Otorhinolaryngology - Head and Neck Surgery, Ministry of Health, Ankara Training and Research Hospital, Ankara, Turkey.

[2]Department of Otorhinolaryngology, Memorial Health Group Ankara Hospital, Ankara, Turkey

[3]Department of Biochemistry, Ministry of Health Abdurrahman Yurtaslan Ankara Oncology Training and Research Hospital, Ankara, Turkey

[4]Department of Histology and Embriology, Hacettepe University, Faculty of Medicine, Ankara, Turkey

INTRODUCTION & OBJECTIVES: Cisplatin causes cochlea damage, leading to excessive production of free oxygen radicals in the organ of Corti, stria vascularis and spiral ganglion cells. The cytotoxicity is associated with the generation of reactive oxygen species (ROS). In this study, we aimed to investigate the potential protective effect of folic acid against cisplatin-induced ototoxicity.
MATERIALS & METHODS: Thirty male Wistar rats were randomly divided into 5 groups, six animals in each. Intraperitoneal cisplatin (CDDP) (10mg/kg/day) was administrated on day 2 and 3 to all groups except Group V. Besides CDDP, Group I was administrated intraperitoneal 10mg/kg/day folic acid (FA), Group II was administrated intraperitoneal saline, Group III was administrated intratympanic 0,15 ml/day FA, Group IV was administrated intratympanic saline on day 1, 2, 3, 4. Group V was administrated only intratympanic 0,15 ml/day FA on day 1, 2, 3, 4. Prior and after drug administration, plasma homocysteine, folic acid levels and auditory brainstem evoked responses were measured. The rats were then sacrificed and the inner ears were processed for electron microscopy.
RESULTS Biochemical results supported our experimental groups. There were statistically significant less hearing loss at low frequencies in group I compared to group II. Statistically significant less hearing loss was detected in group III (CDDP+ IT FA) compared to group IV (CDDP+ IT saline) at 12 kHz.
Cisplatin treatment resulted with degeneration in the cells of the organ of Corti, stria vascularis and spiral ganglion. Normal ultrastructural morphology was detected in intra-tympanic folic acid administrated group. The outer and inner hairs cells of the organ of Corti were examined in both intra-tympanic and intra-peritonel folic acid administrated after cisplatin treatment groups.
CONCLUSION: Folic acid is an agent, which has a partial preventive effect to cisplatin-induced ototoxicity.

Keywords: Cisplatin, folic acid, ototoxicity

10.5505/2017ichc.PP-252 [Pathology and clinical medicine]

Histochemical and Ultrastructural Findings of Isolated Aortitis: a case report

Ozge Kockara[1], Sebnem Ataman[2], Figen Kaymaz[3]

[1]Department of Histology and Embryology, Faculty of Medicine, Hacettepe University, Department of Physical Medicine and Rehabilitation, Faculty of Medicine, Ankara University, Ankara, Republic of Turkey

[2]Department of Physical Medicine and Rehabilitation Rheumatology Division, Faculty of Medicine, Ankara University, Ankara, Republic of Turkey

[3]Department of Histology and Embryology, Faculty of Medicine, Hacettepe University, Ankara, Republic of Turkey

INTRODUCTION: Isolated aortitis is a rare type of large vessel vasculitis that occurs an inflammation in aorta and major branches. İnflammation can cause aneurysm which lead to rupture in aorta. There is no histopathologic criteria to diagnose isolated aortitis and also ultrastructural findings. Histochemical and ultrastructural evaluation of an aorta of a patient diagnosed clinically as isolated aortitis and large vessel vasculitis pathologically after thoracic aortic aneurysm and aortic dissection surgery was reported in this study.
MATERIALS METHODS: 55 years old patient who has a cerebral hemorrhage, elevated erytrocyte sedimentation rate (ESH) and C-reactive protein (CRP) levels, unintentional weight loss, anemia, an aortic dissection with thrombosis (diameter: 14 mm) between descending aorta and orifice of renal artery, abdominal aortic aneurysm (69x57 mm) was complaining about the side effects of high dose glucocorticoids (Figure 1). Methotrexate, azathioprine, golimumab were ineffective. After surgery the segment of the thrombotic dissection and aneurysmal aorta was taken and examined by histochemical (Hematoxylin & Eosin, Verhoff van Gieson) and ultrastructural techniques (electron microscope). Patient was treated with tocilizumab (interleukin 6 monoclonal antibody).
RESULTS: We have seen a disruption of medial elastic fibrils and external elastic lamina, pseudolumen formation, extention of vasa vasorum into the tunica media, increase in size and number of vessels in adventitia and intimal thickening of small vessels (Figure 2), fibrosis in all layers of aortic wall, intimal thickening and necrosis (Figure 3), infiltration of lymphocyte, plasma cells, macrophages, monocytes, eosinophils, neutrophils in tunica media and adventitia predominantly around vasa vasorum and vascular regions. Regeneration areas in tunica media after aortic dissection was also observed (Figure 4). There was no inflammatory cells in tunica intima also there was no internal elastic lamina, granuloma and giant cell in all layers of aortic wall.
CONCLUSION: In this case report histochemical and ultrastructural findings of a patient diagnosed as isolated aortitis was reported.

Keywords: isolated aortitis, vasculitis, ultrastructure, microscopy

1



Dissection and aneurysm in aorta. CT image.

2

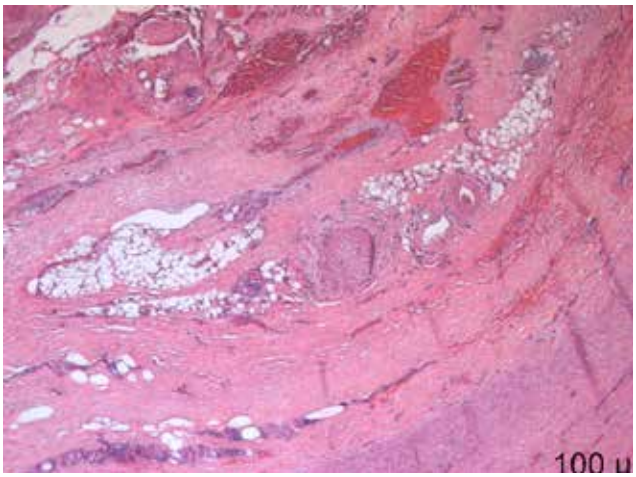

Tunica media and adventitia of an isolated aortitis. H&E, x25.

3



Tunica intima and media of isolated aortitis. Verhoff van Gieson, x50.

4

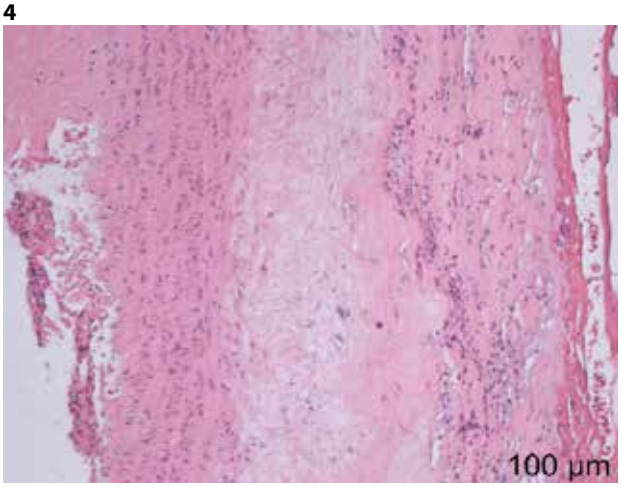

Tunica media of isolated aortitis. H&E, 100.

10.5505/2017ichc.PP-253 [Pathology and clinical medicine]

Protective effect of ticagrelor on liver damage induced by ischemia-reperfusion

Yusufhan Yazir[1], Melda Yardımoğlu Yılmaz[1], Selenay Furat Rencber[1], Kübra Kavram[1], Göktuğ Şirin[2]

[1]Department of Histology and Embryology, Kocaeli University Faculty of Medicine, Turkey

[2]Department of Gastroenterology, Kocaeli University Faculty of Medicine, Turkey

Introduction & OBJECTIVES: Ischemia-reperfusion injury (IRI) occurs after different surgical treatments and may have an effect in remote organs, causing multiple organ dysfunction syndrome and death. The aim of this study is to evaluate the protective effect of ticagrelor on liver histology in ischemia-reperfusion model.
Materials & METHODS: Thirty-five Sprague-Dawley rats were divided into 5 groups: In group 1, only laparatomy was performed. In all groups except for the sham group (group 1), IRI was induced by clamping the aorta with atraumatic vascular clamp infrarenally for two hours, followed by 4 hours of reperfusion. In group 2-5, animals were treated with 0.1 ml saline, dose of 7.5 mg/kg, 15 mg/kg and 25 mg/kg ticagrelor, respectively. At the end of the experiment, livers were removed, processed and embedded in paraffin blocks and cut into 4-5 µm sections. Histologic evaluation was performed H&E-stained sections. Liver injury was scored from 'mild' to 'severe. Hepatic IRI were classified as follows: Grade 0, no damage; Grade 1, mild damage with cytoplasmic vacuolization and nuclear pycnosis; Grade 2, moderate damage with expanded nuclear pycnosis, increase of cytoplasmic eosinophilia and loss of intercellular borders; Grade 3, severe damage with hemorrhage, neutrophil infiltration and severe necrosis. TUNEL protocol was applied and apoptotic index was calculated. All sections were examined by light microscope.
RESULTS: In sham group (group 1), microscopic architecture and cellular arrangement of liver were normal. Grade 3 injury was seen in group 2 and 3. Cytoplasmic vacuoles in hepatocytes, numerous leucocytes in sinusoids, vena centralis and portal area, hemorrhage, and necrosis were observed in these groups. In group 4 and 5, grade 1 and grade 2 injuries were seen such as moderate leucocytes and sinusoidal dilatation. The number of apoptotic cells in group 2 was more than group 4 and 5. There was a significant difference between group 1 and 2, group 1 and 3, group 2 and 3.
CONCLUSIONS: Our results suggest that ticagrelor plays a protective role against ischemia-reperfusion induced histological impairments and apoptosis. Although future clinical trials are required, the effective dose of ticagrelor may be used in ischemica-reperfusion induced liver damage.

Keywords: Ischemia-reperfusion, ticagrelor, liver, apoptosis.

TUNEL staining photomicrographs of all groups

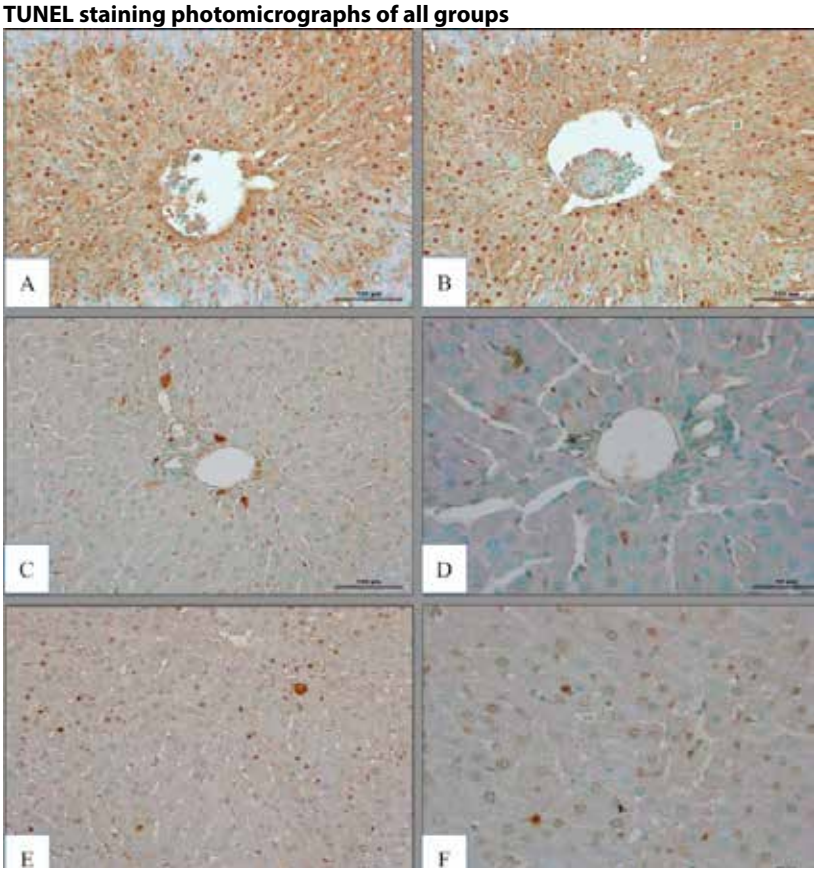

TUNEL staining photomicrographs are seen of the liver in dose of 7.5 mg/kg (A, B), 15 mg/kg (C, D) and 25 mg/kg (E, F) of treatment groups, respectively.

10.5505/2017ichc.PP-254 [Pathology and clinical medicine]

Effects of Atorvastatin on the Renal Tissue in Streptozotocin-Induced Diabetic Rats

Melda Yardimoglu[1], Liridona Adili Osmani[1], Ayşegül Albayrak Aytekin[1], Ceyla Eraldemir[2], Esra Acar[2], Kürşat Yıldız[3], Canan Baydemir[4]

[1]Department of Histology and Embryology, Kocaeli University, Kocaeli, Turkey

[2]Department of Biochemistry, Kocaeli University, Kocaeli, Turkey

[3]Department of Pathology, Kocaeli University, Kocaeli, Turkey

[4]Department of Biostatistics, Kocaeli University, Kocaeli, Turkey

INTRODUCTION & OBJECTIVES: Turkey is the country with the biggest increase in diabetes in Europe. This study was planned to investigate the possible protective effect of Atorvastatin on renal morfology and oxidative stress in STZ-induced diabetic rats.
MATERIALS & METHODS: Wistar albino female rats (200-220 g) were divided into six groups: non-diabetic control (C); Diabetic control (DM); Non-diabetic rats administered 10 mg/kg Atorvastatin (C-A 10); Non-diabetic rats administered 20 mg/kg Atorvastatin (C-A 20); Diabetic rats administered 10 mg/kg Atorvastatin (DM-A10); Diabetic rats administered 20 mg/kg Atorvastatin (DM-A20). The experimental diabetes model was administered as single-dose of STZ (40 mg/kg in sodium citrate buffer 0,1 M pH 4, i.p.). A week after the establishment of DM, the groups of C-A and DM-A received daily treatment of Atorvastatin (10 mg/kg and 20 mg/kg) via oral gavage for 3 weeks. At the end of the experiment all rats were sacrificed and the kidneys were removed and processed for histological and biochemical studies. Paraffin serial sections stained with H&E and TGF-β immunocytochemistry method. Glomerular diameters were quantified and evaluated by light microcopy. MDA levels was measured spectrophotometrically by biochemical methods
RESULTS: There was a statistical difference of the body weights between the groups. Body weights in DM group, were significantly decreased compared to control group ($p < 0.01$) (Graphic 1). There was a significant difference in the size of the glomeruls between the internal and external zones of the renal cortex. There was a significant difference between the glomerul size in internal and external cortical zones of the groups. The glomeruls of diabetic rats administered Atorvastatin were significantly larger compared with the Group C (Graphic 2, Table 1). Group DM displayed tubular and vascular dilatation, fibrotic changes and glomerular space reduction (Fig.1). TGF-β (+) cells were seen in DM group compared with the other groups (Fig.2). These histological changes were less prominent in groups treated with Atorvastatin.
CONCLUSIONS: Our findings suggest that DM induces histopathological changes on renal morphology. Atorvastatin treated groups indicate healthier histological structure but showed incresed of glomerular hypertrophy compared with other groups.

Keywords: Kidney, Streptozotocin-induced diatbetic rats, Atorvastatin, TGF-β.

Graphic 1

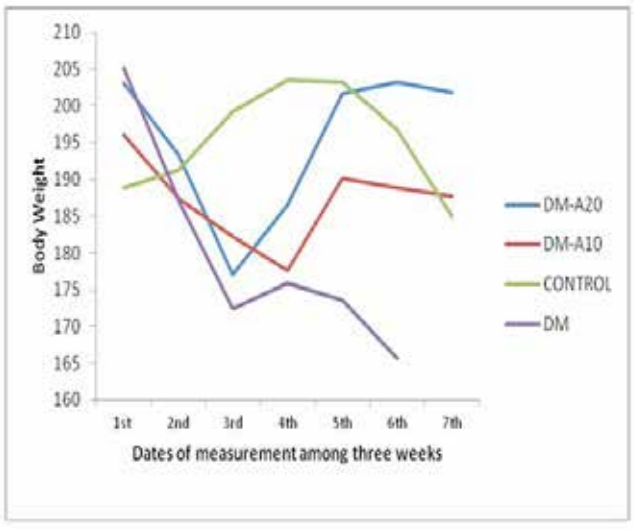

The differences of body weights during three weeks. Body weights in DM group were decreased compared to the control group ($p < 0.001$).

Graphic 2.

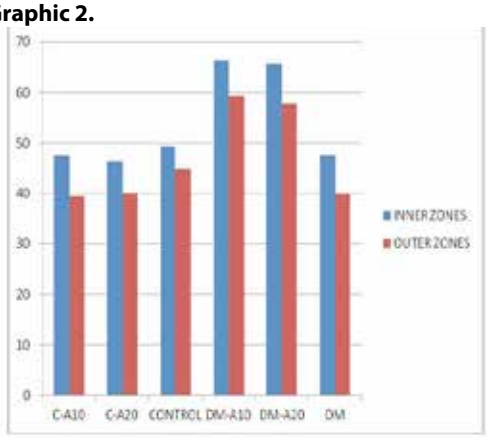

Glomerul size in internal and external cortical zones between the groups ($p < 0.001$).

Table 1

Groups	Control (mean±SD)	DM (mean±SD)	C-A 10) (mean±SD)	C-A 20 (mean±SD)	DM-A 10 (mean±SD)	DM-A 20 (mean±SD)
Internal zone of cortex	49,32±13,08	47,41±7.05	47,47±9,25	46,21±8,10	66,41±9,84	65,83±10,13
Externalzone of cortex	44,86±8,71	39,76±4,69	39,35±7,49	39,91±4,83	59,32±9,19	57,92±6,82

Glomerul diameters of renal cortex in internal and external zones in non-diabetic control (C), diabetic control (DM), non-diabetic rats administered 10 mg/kg Atorvastatin (C-A 10), non-diabetic rats administered 20 mg/kg Atorvastatin (C-A 20),diabetic rats administered 10 mg/kg Atorvastatin (DM-A10), diabetic rats administered 20 mg/kg Atorvastatin (DM-A20) groups. Values are means± SD from animals. The significance level is P< 0.05.

Figure 1.

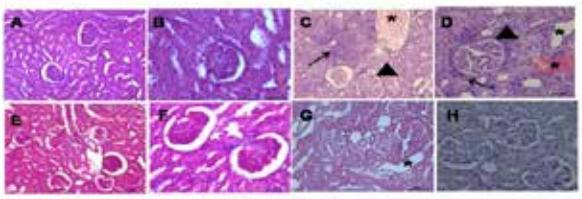

Figure 1. Photomicrographs of the Control (A, B); DM (C, D); C-A 10(E, F); DM-A10 (G,H) groups in kidney sections stained with H&E, tubular & vascular dilatation (*), fibrosis (arrow), glomerular space reduction (arrowhead) were prominent in DM group compared to other groups.

Photomicrographs of the Control (A, B); DM (C, D); C-A 10(E, F); DM-A10 (G,H) groups in kidney sections stained with H&E; tubular & vascular dilatation (*), fibrosis (arrow), glomerular space reduction (arrowhead) were prominent in DM group compared to other groups.

Figure 2.

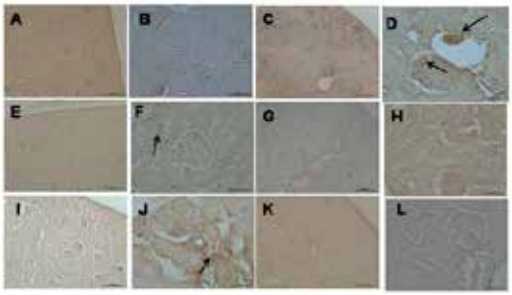

Figure 2. Photomicrographs of TGF-β immunohistochemistry of the Control (A, B); DM (C, D); C-A 10(E, F); C-A 20 (G,H); DM-A10 (I, J); DM-A20 (K, L) groups in kidney sections. TGF-β (+) immunostaining (arrow) is prominent in DM (C, D) compared control (A,B) and other groups (E-L).

Photomicrographs of TGF-β immunohistochemistry of the Control (A, B); DM (C, D); C-A 10(E, F); C-A 20 (G,H); DM-A10 (I, J); DM-A20 (K, L) groups in kidney sections. TGF-β (+) immunostaining (arrow) is prominent in DM (C, D) compared control (A,B) and other groups (E-L).

10.5505/2017ichc.PP-255 [Pathology and clinical medicine]

Minoxidil Effects Angiogenesis In-vivo and In-vitro Settings

Yasin Ilgaz[1], Barıs Baykal[1], Esra Erdogan[1], Tugba Fatsa[2]

[1]Department of Medical Histology and Embryology, University of Health Sciences, Gulhane Faculty of Medicine, Ankara, Turkey

[2]Stem Cell Laboratory, Gulhane Research Institute, University of Health Sciences, Ankara, Turkey

Introduction&OBJECTIVES: Angiogenesis a process initiated in preexisting vessels. Many researches regarding cancer, diabetic retinopathy, psoriasis and some inflammatory diseases interrelated with angiogenesis have been performed to date. Angiogenesis is regulated by expression of VEGF which is a dynamic process and effected by many molecules such as; IL-6, IL-1β, TGF-β and PDGF-β. However, this mechanism is not well-characterized and it is likely that other molecules may also stimulate the expression of VEGF.
Minoxidil is a well-known hypertrichotic agent used for the treatment of androgenic alopecia. Minoxidil is reported to be involved in the development of dermal papilla vascularization via stimulation of VEGF expression. The purpose of this study was to evaluate the effect of minoxidil on angiogenesis using in vitro and in vivo model systems.
Materials&METHODS: Lohmann LSL classical type fertilized eggs were used for in vivo CAM assay and they were kept at 37 °C and 65–75% relative humidity in an incubator. The CAMs were treated with different concentrations of Minoxidil (10μM, 50μM, 100μM, 200μM). At the 24th hour of the administration the CAMs were visualized by a digital camera.
For tube formation assay; Matrigel matrix was plated in 96-well (ibidi Cat.No:89646) μ-plates. After incubation for 30 min, 40 μL HUVEC (10,000 cells/well) and 40 μL of Minoxidil (50μM - 100μM - 200μM) in a conditioned medium were placed on Matrigel and incubated at 37°C for 24 h. Following incubation, the plated wells were photographed, and the results were evaluated with "Angiosys and Wimasis" software. The proliferation inducing activity of Minoxidil was also determined through MTT assay on HUVECs. Control and vehicle groups were prepared by following the same procedure as mentioned previously except Minoxidil solution for all assays.
RESULTS: In CAM assay, minoxidil had no significant angiogenic effect compared to vehicle groups (Figure 1). Minoxidil had a statistically significant ($p<0.05$) proliferative effect on HUVECs. Results of tube formation assay are presented in Figure 2.
CONCLUSIONS: Although minoxidil had a slight angiogenic effect of on CAM vessels, it significantly induces angiogenesis on in-vitro assays.

Keywords: Minoxidil, Angiogenesis, Chorioallantoic Membrane Assay, Tube Formation Assay

Figure 1

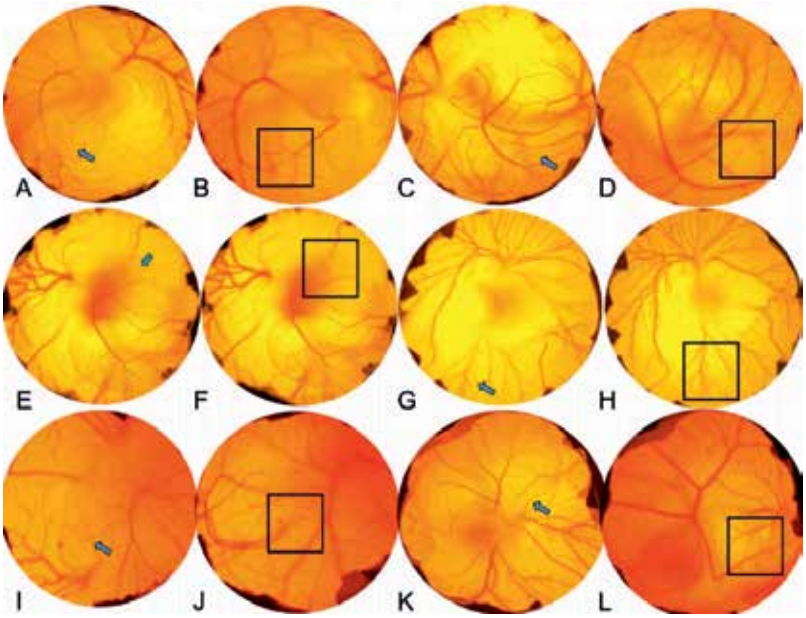

Stereomicroscopic observation of CAM assay. (A-B) Control (C-D) Vehicle (E-F)10 μM (G-H) 50 μM (I-J) 100 μM (K-L) 200 μM. The blue arrows indicate drug treated sites. The black squares point out application areas after 24h. There was no difference in vascular branching when compared to vehicle and control groups. Minoxidil has a dosage-independent and statistically insignificant stimulation effect on vascular bridging.

Figure 2

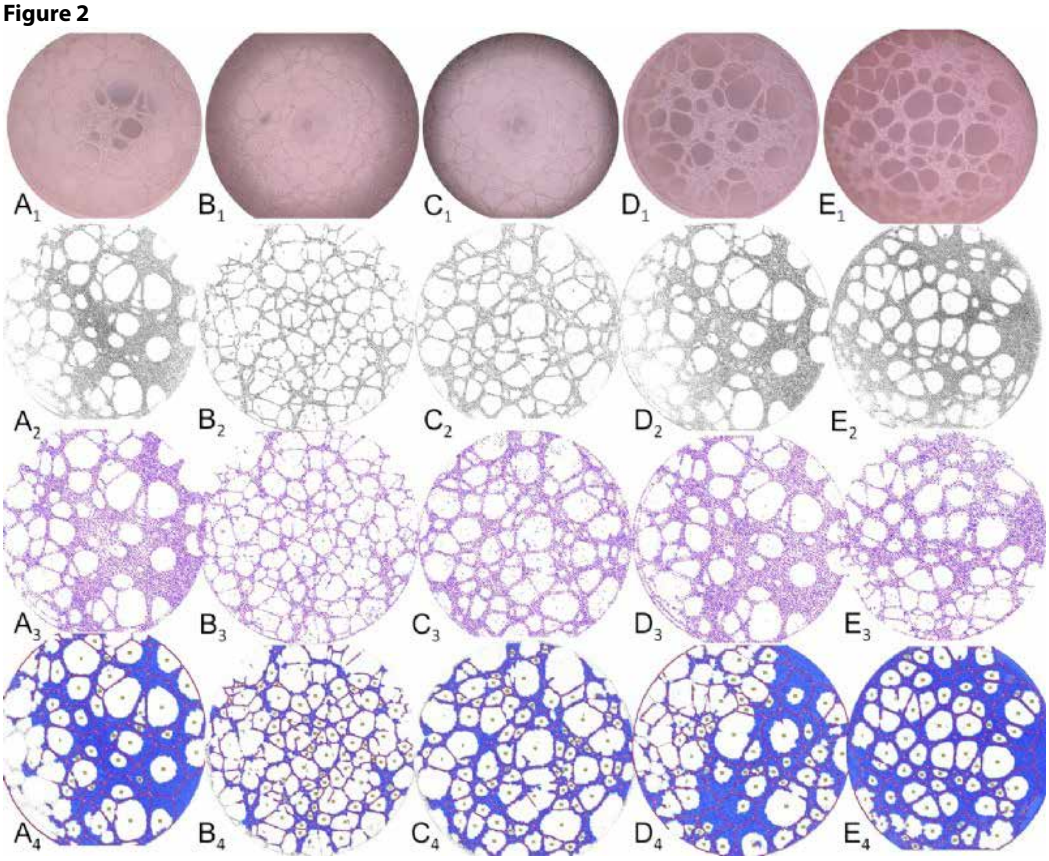

Representive images of tube formation assay. The first line is the original phase-contrast images at 24th h, the second line shows the images used for analysis, the third line shows the resulting images of Wimasis-WimTube software, the fourth line shows the resulting images of Angiosys software. (A) Control (B) 50 µM (C) 100 µM (D) 200 µM (E) Vehicle (40 X). Comparing the number of tubules and junctions, areas of loops, branch sites and mean tubule length, there was a statistically significant dose-dependent increase in the minoxidil groups compared to the control and vehicle groups ($p<0.05$).

10.5505/2017ichc.PP-256 [Pathology and clinical medicine]

Effect of Botulinum Toxin A on The Development of Neointimal Hyperplasia in Arterial Grafts in An Experimental Rat Model

Serhat Atalay Evis[1], Muharrem Cicek[2], Seyhun Solakoglu[2], Ufuk Emekli[1]

[1]Department of Plastic Reconstructive and Aesthetic Surgery, Istanbul University Istanbul Medical Faculty, Istanbul, Turkey

[2]Department of Histology and Embryology, Istanbul University Istanbul Medical Faculty, Istanbul, Turkey

INTRODUCTION: Because of the physical trauma of surgery and secondary hemodynamic stress, activation and migration of smooth muscle cells from the media into the intima may play an important role in development of neointimal hyperplasia which is a common cause of vessels graft failure resulting from luminal narrowing and occlusion. Botulinum toxin inhibits the release of neurotransmitters such as norepinephrine and Substance P, which cause neointimal hyperplasia, while increasing neurotransmitters that suppress neointimal hyperplasia, such as NO and CGRP. In addition, botulinum toxin inhibits the release of the neurotransmitter acetylcholine causing muscle paralysis.
AIM: The aim of our study was to evaluate the effect of botulinum toxin A on the development of neointimal hyperplasia in arterial grafts used in arterial defect repair in an experimental rat model.
METHODS: Four experimental and four control Sprague Dawley rats underwent interposition saphenous artery grafting into the femoral artery and, followed by a single topical dose (5 IU) of botulinum toxin type A (Botox® Allergan, Inc., Irvine, California) applied around the artery graft, and a single dose (5 IU) was injected into the inguinal fat pad, covering the anastomosis lines and the graft. Grafts were harvested and underwent histologic staining of axial sections to visualize intima thickness after 28 days. The intima-to-media (I/M) and the intima-to–sum of intima and media (I/I+M) ratios were determined to control for discrepancies in overall graft size. Distances of intima and media were quantified with ImageJ software (https://imagej.nih.gov/ij/docs/guide/146.html). The study was approved by Istanbul University Animal Experiments Local Ethical Committee, permit no. 2016/74.
RESULTS: Average intima size of the botulinum toxin -treated group was reduced by 48% compared with the control group (24,34 ±6,27 versus 47,11 ±7,10 µm; $p < 0.05$). Respectively, average I/M and I/I+M ratios of the treatment group were statistically reduced by 36% (0,45±0,12 vs 0,7±0,07; $p < 0.05$) and 16% (0,36±0,04 vs 0,43±0,02; $p < 0.05$) compared with the control group.
CONCLUSIONS: A single local intraoperative dose of botulinum toxin may be helpful in reducing intima size and preventing vessels graft failure resulting from luminal narrowing and occlusion in the first four weeks.

Keywords: Botulinum toxin, neointimal hyperplasia, arterial grafts, rat model.

10.5505/2017ichc.PP-257 [Pathology and clinical medicine]

Effect of ozone on apelin and APJ expressions in rats peritonitis-constituted with colon anastomosis

Leyla Kilinc[1], Sema Avci[1], Hakan Soylu[1], Tugrul Cakir[2], Arif Aslaner[2], Ismail Ustunel[1]

[1]Akdeniz Univeristy, Faculty of Medicine, Department of Histology and Embryology, Antalya

[2]Health Sciences University, Antalya Training and Research Hospital, Department of General Surgery, Antalya

Introduction&OBJECTIVES: Anastomosis is one the performed surgical procedures in gastrointestinal system including peritonitis model (1). Ozone theraphy has been found useful in the treatment of various diseases including gastroduodenal ulcers, peritonitis and colitis (2). Apelin, the endogenous ligand of APJ which it was first isolate from bovine stomach extracts. The apelin expression is known regulate with factors as hypoxia, fasting and feeding (3). In the present study, we aim to analize effect of ozone theraphy on Apelin and APJ expressions in peritonitis constituted colon anastomosis.
Materials&METHODS: Eighteen Wistar albino rats of male gender of weighing 250-300 g were used in this study. The rats were randomly assigned into three equal groups; 1) Control group was receiving only physiological saline; 2) The cecal punctuation and colonic anastomoses group; 3) Cecal punctuation and colonic anastomoses treated with medical ozone group receiving at dose of 1mg/kg/d medical ozone intraperitoneally for three weeks. At the end of the three weekly ozone treatment the rats were sacrified and colonic tissues samples were obtained. In the colonic tissue samples was carried out the Hematoxylen-Eosin staining (HE) and the Apelin and APJ immuno-staining. Also, Apelin and APJ protein levels which between groups was determined with Western-Blot method.
RESULTS: Control group samples have normal view with HE staining while in anastomosis group has rather break down of normal structure. Ozone thraphy group appearance a normal view in comparison with anastomosis group. Concordantly in anastomosis group was increased immuno-density of Apelin and APJ in comparison with control group. In ozone theraphy group it was decreased in comparison with anastomosis group and approached to control group. The protein levels of Apelin and APJ according to Western-Blot analysis are correspondent with immunostaining. The levels of Apelin/APJ in anastomosis group were high in comparison with control group, but in ozone theraphy group were determined to decrease in comparison with control group.
CONCLUSIONS: As a result increasing of the levels of Apelin and APJ in cecal punctution and colonic anastomosis process can be deduced and said to contribute worsening of tissue while it may be involved in return to normal of with treatment.

Keywords: Colon, Anastomosis, Surgical, Peritonitis, Apelin, APJ

10.5505/2017ichc.PP-258 [Pathology and clinical medicine]

The Effect of Thermal Energy on The Neovascularızatıon After The Saphenofemoral Compound Lıgatıon and Saphenous Veın Strıppıng

Leyla Bahar[1], Mehmet Gül[2], Nehir Sucu[3], Semir Gül[2], Emrah Zayman[2], Sema Erden Ertürk[1]

[1]Vocational School of Health Services, Mersin University, Mersin, Turkey

[2]Department of Histology and Embryology, Faculty of Medicine, Inönü University, Malatya, Turkey

[3]Department of Cardiovascular Surgery, Faculty of Medicine, Mersin University, Mersin,Turkey

Introduction & OBJECTIVES: It is known that the two most important factors in the recurrence of varicose veins after varicose vein surgery are stump and neovascularization in the saphenous femoral junction (SFJ). The aim of this experimental study is to contribute to the elucidation of the etiopathogenesis of recurrence and to investigate the effect of thermal energy on neovascularization in SFJ divisions in rats.

Materials & METHODS: Seven adult wistar rats have been used for each group in the study. The rats were named Group 1(surgical) and Group 2 (thermal energy- laser), respectively, after right femoral venous binding with prolene, then with scissor divide and directly with cotter divide. The left legs of the same rats without any attemp were accepted as the control group. After routine light microscopic tissue processing; rat tissue samples were stained by Hemotoxylin-Eosin and VEGF and also with S100 for neovascularization determination. In light microscopic sections, capillaries were counted with 10 different field x20 lens magnification and the average was taken and H-Scores were determined. For the statistics analysis was applied the Spousal T Test and Kolmogorov-Simirnov Test.

RESULTS: In light microscopic examinations, capillary counts were made for neovascularization and H-Ssors were detected. As a result of statistical analysis; It was observed that each group applied the Kolmogorov-Simirnov test was normally distributed separately (p> 0,05). In VEGF immunostaining; while there was statistically significant difference between Control and Group 1 (p: 0,001), between Group 1 and Group 2 (p: 0,039), there was no statistically significant difference between Control and Group 2 (P: 0,199). When S100 staining was compared, there was a statistically significant difference in H-score between Control-Group1 (p: 0.001), between Group1 and Group2 (p: 0.003) and between Control-Group2 (P: 0.006).

CONCLUSIONS: In our study, it was observed that the use of thermal ablation in divisions of varicose vein surgeon in SFJ reduced neovascularization emerging in varicose vein recurrence. In our study, results that supporting endovenous thermal treatments have been reached. Thermal energy applications may be an easily applicable, minimally invasive and alternative way of preventing varicose venous recurrences.

Keywords: Thermal Energy, Neovascularızatıon, Saphenofemoral Compound, Saphenous Veın

Fig. A

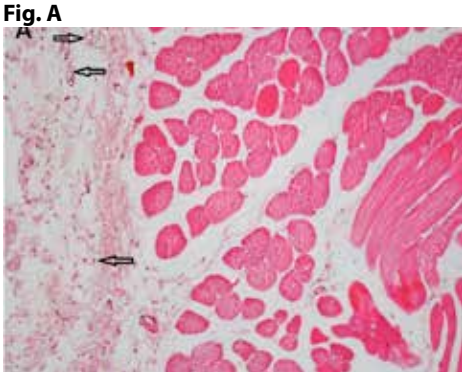

Fig. B

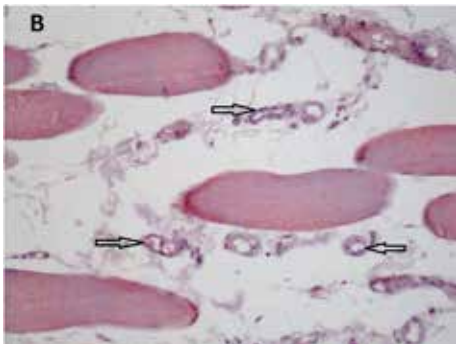

Fig. C

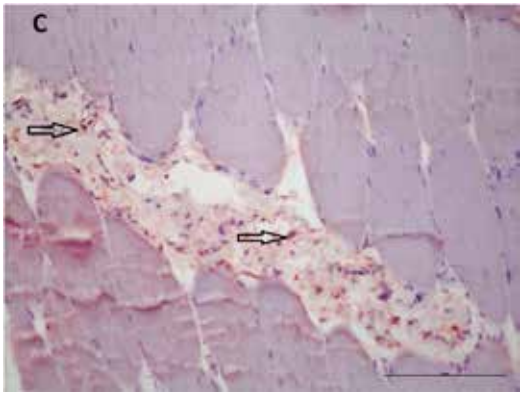

Fig. D

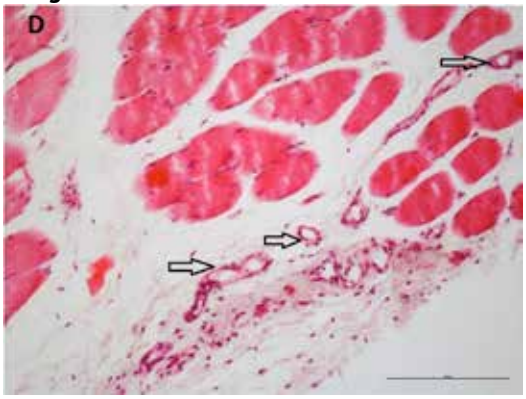

Fig. E

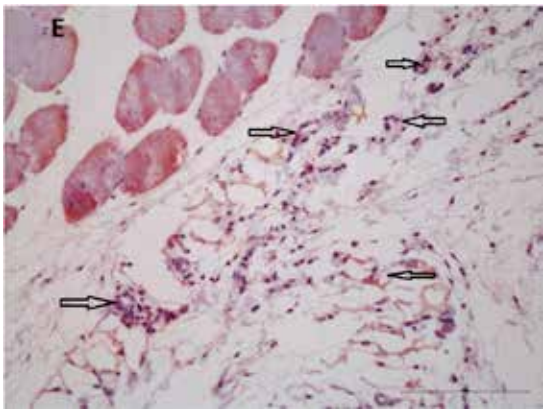

Fig. F

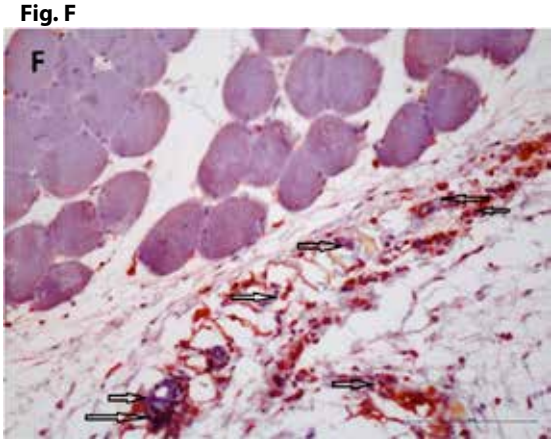

Fig. G

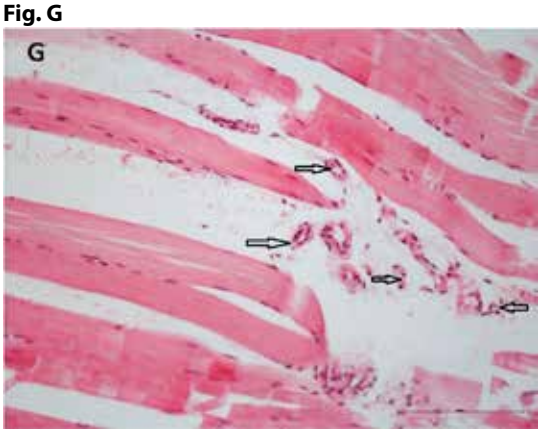

Fig. H

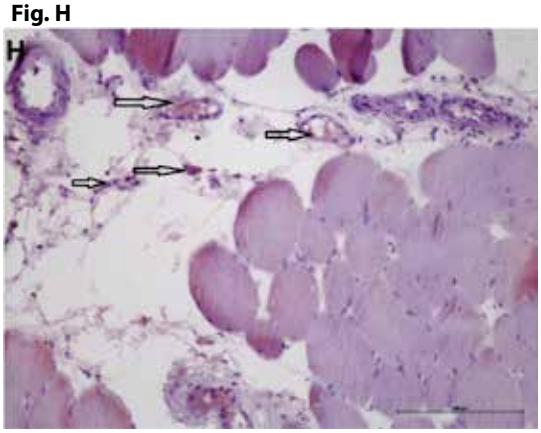

Fig. I

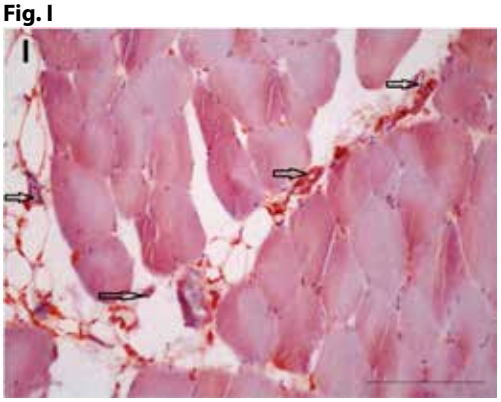

Table 1

	Control (n=7)	Group1 (Surgical group, n=7)	Group2(laser group n=7)
	mean±SD	mean±SD	mean±SD
VEGF	31,428 ± 8,997	88,571 ± 24,784	47,142 ± 24,299
S100	41,428 ± 14,638	92,857 ± 21,380	71,428 ± 22,677

Table 1. Comparison of baseline characteristics between the controls and other groups

10.5505/2017ichc.PP-259 [Pathology and clinical medicine]

Structure of collagen and blood vessels of ovarium, in teens and old, in diabetic and normal pregnant rats

Perihan Yalçınkaya, Ciğdem Elmas, Deniz Erdoğan, Güleser Göktaş
Department of Histology & Embryology, Gazi University, Faculty of Medicine, Ankara/Turkey

INTRODUCTION: Diabetes is a metabolic disorder resulted from rising of blood glucose level extremely. Pregnancy and diabetes are cases affecting each other negatively. It includes aging that is deterioration process affecting cell, tissue, organ and systems and many changes in biochemical and structural level. In experiment models created in our study, it was aimed to be examined the collagen content belonging to ovary that is known underwent various changes in pregnancy, diabetes and senility and effects to be created by every three cases together in vein structures, histological changes and damage that are probable to develop immunohistochemically and comparatively by using collagen type III, IV, VI and alpha actin primary markers.
MATERIALS-METHODS: In our study, total 48 Sprague Dawley species female rats were used; 24 rats are 2 months old (young) and 24 rats are 8 months old (old). Totally 8 groups were created. Experimental diabetes was created by applying one dose 50 mg/kg STZ with intraperitonal injection. In subjects determined that they had diabates after 2 months' follow-up period following the implementation. pregnancy was provided. In 14th day of pregnancy, ovaries were removed. Immunohistochemical results were evaluated in light microscope level.
RESULT: A clear reduction in immunoreactivity of all collagen types in diabetic groups were found in our study. Similarly, reduction in immunoreactivity was monitored in all collagen types in pregnant groups also. It was seen that old and diabetic group ovary tissues of said markers had the least expressions. Contrary to this, an increase was observed in expression of type IV collagen and alpha actin expression in vein structures of diabetic, pregnant and old groups. At the same time, degenerations such as increase in atretic follicle number, deterioration in zona pellusida structure, perivascular edema, thinning in theca internal and external layers, deformities in granulized cell and core structures and decrease in primary follicle number pointed out. In conclusion, it was concluded that this study would be important clinically and fulfill the deficiency in resources largely in line with histopathological findings that we observed in old and pregnant groups in addition to the said immunohistochemical findings.

Keywords: Diabetes, Pregnancy, Ovary, Collagen, α-Actin

Figure 1: In ovarium tissues belonging to young group (3 months) stained with Type VI collagen antibody;

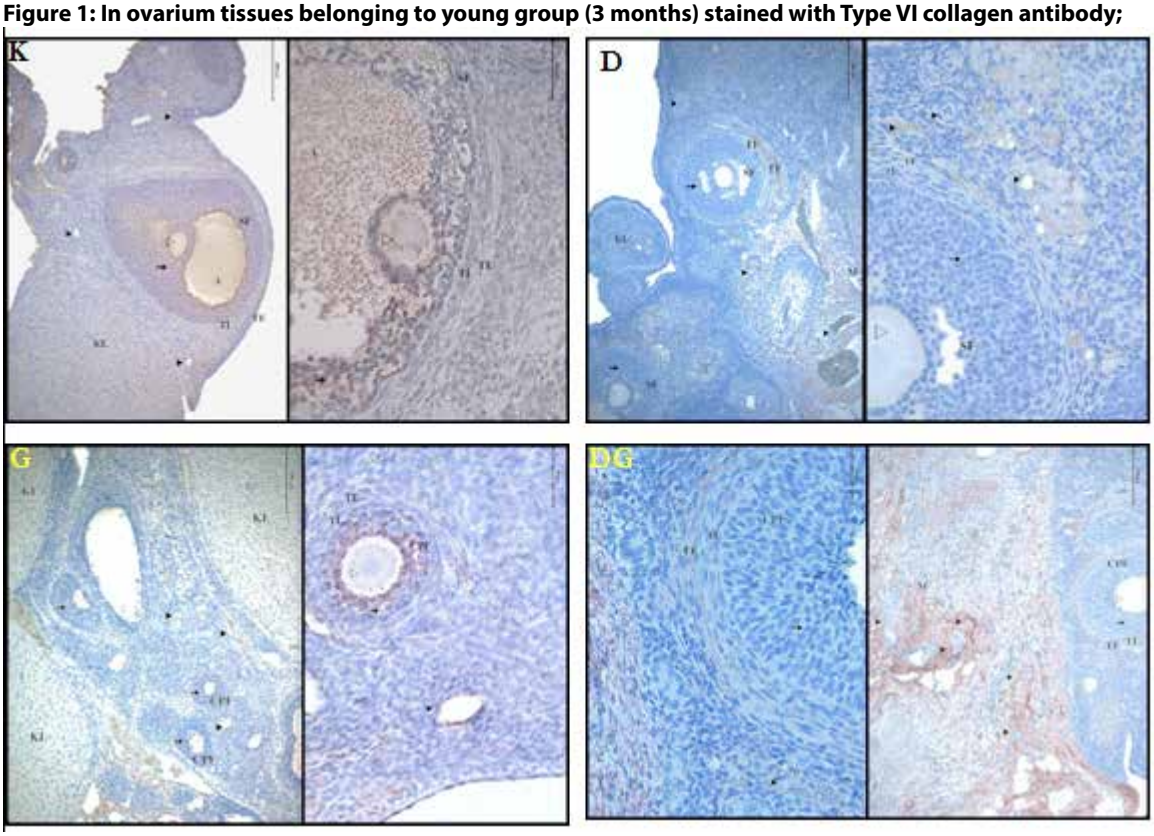

Secondary follicle (SF) Atretic follicle (AF), Multilayer primary follicle (MPF), Granulosa cell (), Teka interna (TI), Teka externa (TE), Corpus luteum (KL), Graaf follicle (GF), Antrum(A), oocyte cytoplasm, medulla (M), deformations in nucleus and cytoplasm in granulosa cells (†) (Immunoperoxidase - Hematoxylin) C: CONTROL D: DIABETIC, P: PREGNANT, PG: PREGNANT AND DIABETIC.

Figure 2: In ovarium tissues belonging to old group (8 months) stained with Type VI collagen antibody;

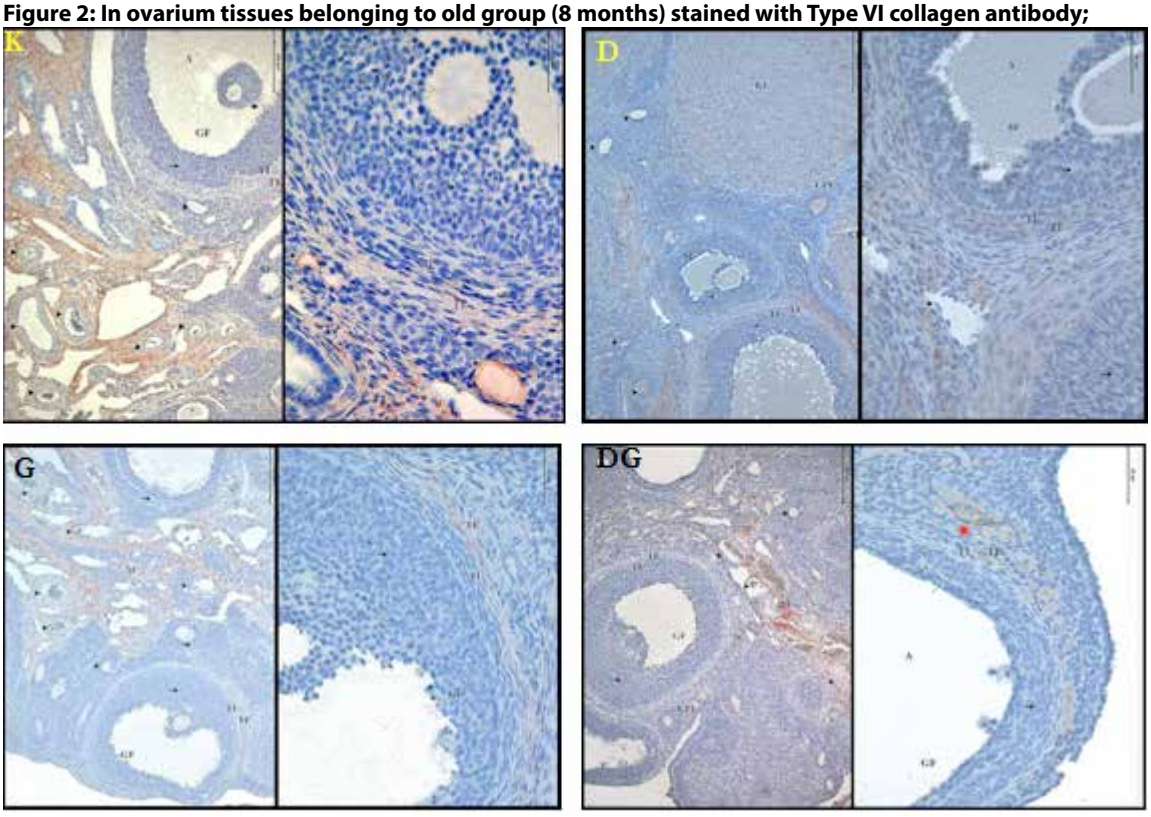

Secondary follicle (SF) Atretic follicle (AF), Granulosa cell (), Teka interna (TI), Teka externa (TE), Corpus luteum (CL), Graaf follicle (GF) Antrum (A), oocyte cytoplasm, medulla (M), deformations in nucleus and cytoplasm in granulosa cells (†) (Immunoperoxidase - Hematoxylin) C: CONTROL D: DIABETIC, P: PREGNANT, PG: PREGNANT AND DIABETIC.

10.5505/2017ichc.PP-260 [Pathology and clinical medicine]

Histopathological evaluation of mechanorecepters in the metatarsophalangeal joint capsule in hallux valgus cases

Barış Yılmaz[1], Cansu Kandemir[2], Evrim Şirin[1], Güzelali Özdemir[3], Dursun Ak[4], Nazım Karahan[1], Dilek Akakın[2], Hasan Hilmi Muratlı[5]

[1]Department of Orthopedic Surgery and Traumatology, Fatih Sultan Mehmet Education and Research Hospital, Istanbul, Turkey

[2]Department of Histology and Embryology, Marmara University School of Medicine, Istanbul, Turkey

[3]Department of Orthopedic Surgery and Traumatology, Ankara Numune Education and Research Hospital, Ankara, Turkey

[4]Department of Orthopedic Surgery and Traumatology, Çerkezköy State Hospital, Tekirdag, Turkey

[5]Department of Orthopedic Surgery and Traumatology, Trakya University School of Medicine, Edirne, Turkey

INTRODUCTION and OBJECTIVES: Hallux valgus (HV) deformity is a lateral subluxation of the first metatarsophalangeal (MTP) joint of the big toe because of medial deviation of the first metatarsal bone. The aim of this study was to evaluate the presence of mechanoreceptors in samples obtained from the first MTP joint capsule of patients with HV deformity and thereby contribute to the clinical and histopathological clarification of HV deformity.
MATERIALS-METHODS: Samples were taken from the 1st MTP joint capsule of 29 patients diagnosed with HV during surgery. In the same way, 13 samples were obtained from the 1st MTP joint capsule of fresh frozen cadavers with normal anatomy. For light microscopic investigations, excised joint capsule specimens were fixed in 10% formaldehyde solution and processed for routine histopathological investigation. All samples were dehydrated in a series of ethanol, cleared in xylene and then embedded in parafin. Sections (5 µm) taken by rotary microtome were stained with Masson's trichrome stain and processed immunohistochemically with antibody against S-100 protein. Orientation of collagen fibers was determined on Masson's trichrome stained sections under a photomicroscope and for immunohistochemical analysis, free nerve endings were counted in the photographs taken from three different areas. Finally, statistical analysis was performed.
RESULTS: In the sections stained with Masson's trichrome stain, regular arrangement of collagen fiber orientation was observed in the control group. On the contrary, coarse collagen bundles which were disoriented were observed in the diseased group ($p<0.05$). S100 immunostaining was positive in the sections of both cadaver and patients as evidenced by brown staining. Free nerve endings (FNE) were found to be more abundant in the samples obtained from patients when compared to control capsules ($p<0.05$).
CONCLUSIONS: In conclusion, increase in the number of FNE in the first metatarsophalangeal joint capsule of feet with HV deformity is thought to have a potential role in the development of clinically relevant joint pain.

Keywords: Hallux valgus, mechanoreceptor, joint capsule, Masson's trichrome stain, S-100 protein

10.5505/2017ichc.PP-261 [Pathology and clinical medicine]

Histological and Immunochemical Investigation of the Effect of Acute Fenthion Toxicity on Kidneys

Orhan Baş[1], Yasemin Kaya[2], Hatice Hancı[3], Soner Çankaya[4], Ismail Nalbant[5], Ersan Odacı[6], Hüseyin Avni Uydu[7], Ali Aslan[8]

[1]Orhan Bas Ordu, Department of Anatomy, Faculty of Medicine, Ordu University, Ordu, Turkey

[2]Yasemin Kaya, Department of Internal Medicine, Faculty of Medicine, Ordu University, Ordu, Turkey

[3]Hatice Hancı, Faculty of Medicine, Department of Histology and Embryology, Karadeniz Technical University, Trabzon, Turkey

[4]Soner Çankaya, Department of Biostatistics, Faculty of Medicine, Ordu University, Ordu, Turkey

[5]İsmail Nalbant, Department of Urology, Faculty of Medicine, Ordu University, Ordu, Turkey

[6]Ersan Odacı, Faculty of Medicine, Department of Histology and Embryology, Karadeniz Technical University, Trabzon, Turkey

[7]Hüseyin Avni Uydu,Department of Medical Biochemistry, Faculty of Medicine, Recep Tayyip Erdogan University, Rize, Turkey

[8]Ali Aslan, Department of Physiology, Faculty of Medicine, Ordu University, Ordu, Turkey

Introduction & Objectives: Organophosphate derivative intoxication has formed one of the most significant public health problems globally in the last sixty years. The effect mechanism of organophosphate compounds is inhibition of the acetylcholinesterase enzyme causing accumulation of acetylcholine in the body. A variety of studies have reported that partial exposure to cholinesterase may disrupt renal functions like both renal circulation and electrolyte excretion.
As a result, in this study we decided to histopathologically investigate the possible effect of acute toxicity due to fenthion, on the kidneys.
Materials & Methods: Weighing 250-300 g, 21 female Wistar albino rats were randomly divided into three groups in the study as experimental, control and sham. The following procedures were applied.
Rats in the experimental group were each administered intraperitoneal 0.8 g/kg fenthion within 1 ml saline. Rats in the sham group were only administered intraperitoneal 1 ml saline. Rats in the control group continued normal nutrition with no procedure performed.
Twenty-four hours after the procedure rats in all groups were sacrificed with cervical dislocation and kidney tissue were obtained and blocked. Sections of 7 micron thickness were obtained from the blocks. Hematoxylin-eosin and periodic acid Schiff reactions were applied. The preparates were examined under a light microscope.
Results : At the end of the study, the cortex and medulla distinction could be observed in control group rats, with kidney tissue with normal structure glomerules and tubules observed and no histopathological findings encountered.
Rats in the experimental group were observed to have epithelial cell disorganization in tubules, moderate epithelial cell loss and degeneration. Again, expansion of tubules, vacuolization of tubular epithelial cells and tubular structure approaching atrophy were observed, with cells approaching apoptosis and common hemorrhage noted.
Though rats in the sham group were observed to have mild tubular degeneration, kidney tissue with generally normal histological structure and similar to the control group was observed.
Conclusions: In conclusion, it should not be forgotten that one of the causes of systemic complaints linked to acute toxicity in people exposed to the organophosphate compound of fenthion may be cellular injury to glomerular and tubular structures in the kidneys.

Keywords: Fenthion, Kidney, Rat

10.5505/2017ichc.PP-262 [Pathology and clinical medicine]

The investigation of potential protective effects of curcumin and capsaicin against kidney damage induced by cyclophosphamide in female rats

Osman Ciftci[1], Aslı Taslidere[2], Cemile Ceren Gül[2], Nese Basak Türkmen[3]

[1]Inonu University Faculty of Medicine, Department of Medical Pharmacology, Malatya, Turkey.

[2]Inonu University Faculty of Medicine, Department of Histology and Embryology, Malatya, Turkey.

[3]Inonu University Faculty of Pharmacy, Department of Pharmaceutic Toxicology, Malatya, Turkey.

AIM: Cyclophosphamide (CP) is a widely accepted chemotherapeutic agent used in the treatment of several malignancies and also as a prophylactic to metastatic tumours. However, the severe adverse reactions including immunosuppression, cardiotoxicity, liver and kidney toxicity observed in CP treatment pose great challenges. Capsaicin is an active component of chili peppers, which are plants belonging to the genus Capsicum. It is an irritant for mammals, including humans, and produces a sensation of burning in any tissue with which it comes into contact. Curcumin, is a lipophilic molecule that rapidly permeates cell membrane.In fact, it has scientifically proven that curcumin is indeed antioxidant, anti-inflammatory and antibacterial.This study was planned to observe the protective effects of Curcumin and Capsaicin on Cyclophosphamide induced kidney damage in rats.
MATERIALS-METHODS: In this study, forty Sprauge-Dawley female rats were randomly divided into four equal groups. Groups:
1.Group: Control group
2.Group:Cyclophosphamide group
3.Group:Cyclophosphamide+ Curcumin group
4.Group:Cyclophosphamide + Capsaicin group
At the end of the study, rats were sacrified under ketamine/xylazine anesthesia. For light microscopic evaluation, kidney samples were fixed in 10% formalin. Tissue samples were processed by routine tissue techniques and were embedded in paraffin. Paraffin-embedded specimens were cut into 5µm thick sections, mounted on slides and sections were stained with Hematoxylen- Eosin, Periodic acid-schiff for histological investigation. For immunohistochemical investigation, sections were stained with Caspase-3. Sections examined under a Leica DFC280 light microscope by Leica QWin and Image Analysis System (Leica Micros Imaging Solutions Ltd.; Cambridge, U.K). TBARS, SOD, CAT, GPx, GSH levels were determined for biochemical analysis.
RESULTS: In the sections stained in control groups, kidney showed normal histological appearence. We detected some histopathological changes in Cyclophosphamide group. These changes were narrowing of Bowman's space, hemorrhage in peritubular spaces, epithelial atrophy, cell desquamation in tubules, inflammatory cell infiltration, hydropic degeneration, casts in tubular lumen, oedema, tubuler dilatation and vacuolisation. In Cyclophosphamide+Curcumin and Cyclophosphamide+Capsaicin groups, histopathological damages were significantly decreased compared with Cyclophosphamide group.
CONCLUSION: The results of this study suggest that Cyclophosphamide induced kidney damage could be significantly reduced by Curcumin and Capsaicin administration.

Keywords: Cyclophosphamide,Curcumin, Capsaicin, Kidney.

10.5505/2017ichc.PP-263 [Pathology and clinical medicine]

Electron Microscopic Features of Skin in Neuronal Ceroid Lipofuscinosis Cases

Fatma Nur Karakus[1], Emel Usta[1], Ozge Hurdogan[2], Muharrem Cicek[1], Edibe Pembegul Yildiz[3], Gozde Yesil[4], Seyhun Solakoglu[1]

[1]Department of Histology and Embryology, Istanbul University Istanbul Medical Faculty, Istanbul, Turkey

[2]Department of Pathology, Istanbul University Istanbul Medical Faculty, Istanbul, Turkey

[3]Department of Pediatric Neurology, Istanbul University Istanbul Medical Faculty, Istanbul, Turkey

[4]Department of Medical Genetics, Bezmialem University Medical Faculty, Istanbul, Turkey

INTRODUCTION: Neuronal ceroid lipofuscinoses (NCLs) are a group of genetic lysosomal storage disorders and characterized by progressive cognitive and motor deficits, retinopathy resulting in blindness, progressive cerebellar atrophy, epileptic seizures and short life span. Along with many underlying biochemical etiologies, NCLs are caused by excessive accumulation of neuronal and extraneuronal lipopigments (ceroid lipofuscin). Diagnosis of NCLs is based on assay of enzyme activity, genetic testing, electron microscopy (EM) of tissue biopsies. <[8]
AIM: In our retrospective study, we aimed to evaluate electron microscopic findings in skin biopsies[6] of NCL-suspected cases.
METHODS: Among patients referred to our electron microscopy laboratory between April 2014 and December 2016, we retrospectively evaluated demographic data and ultrastructural findings in skin biopsies of patients, aged between 0-75 years.
RESULTS: Skin biopsies were obtained from 30 patients; granular osmiophilic deposits (GROD) were seen in 23 patients (76,7%), rectilinear inclusions in 11 (36,7%), fingerprint profiles in 6 (20%) and curvilinear bodies in 2 (6,7%). GROD inclusions were the most common and were seen in 76,7% of cases.
CONCLUSIONS: Electron microscopy researchers should be supported by clinical history, because small inclusions may be overlooked. Ultrastructural analysis of skin biopsy is a good screening test for NCL although assay of enzyme activity and genetic testing are necessary for diagnosis.

Keywords: neuronal ceroid lipofuscinoses, electron microscopy, skin.

10.5505/2017ichc.PP-264 [Pathology and clinical medicine]

The Protective Effects of Dapaglifozin on Experimental Sepsis Induced Kidney Damage in Rats

Zehra Betül Kıngır[1], Zarife Nigar Ozdemir Kumral[2], Ozlem Bingol Özakpınar[3], Ozlem Tugce Kaya[4], Derya Özsavcı[3], Turgut Şekerler[3], Muhammed Emin Çam[5], Feriha Ercan[4], Betul Okuyan[1]

[1]Department of Clinical Pharmacy, Marmara University, Faculty of Pharmacy, Istanbul, Turkey

[2]Department of Physiology, Marmara University Faculty of Medicine, Istanbul, Turkey

[3]Department of Biochemistry, Marmara University, Faculty of Pharmacy, Istanbul, Turkey

[4]Department of Histology and Embryology, Marmara University Faculty of Medicine, Istanbul, Turkey

[5]Department of Pharmacology, Marmara University, Faculty of Pharmacy, Istanbul, Turkey

INTRODUCTION: As a result of damage in multiple organ systems, sepsis is a severe clinical condition possibly due to imbalance between oxidant/antioxidant systems. Dapagliflozin is a new class of therapeutic agent used in type-2-diebetes acting independently of insulin or glucose metabolism. We aimed to show the possible protective effects of dapagliflozin on experimental sepsis induced kidney damage.
METHODS: Male Sprague-Dawley rats received saline (1 ml/kg, i.p) or dapagliflozin (10 mg/kg, i.p) for 5 days prior to surgical procedures. Under ketamine/xylazine anesthesia, sepsis (n=16) was induced by ligation and punction of the cecum, while sham groups (n=16) had only laparotomy. Rats were decapitated 24 hours after surgery to obtain blood, and kidney tissues. Serum BUN, creatinine and glucose levels were measured while the levels of malondialdehyde (MDA) and glutathione (GSH) were determined in kidney tissues. For histological evaluation, renal tissues were fixed with 10% neutral formalin and processed for routine parafine embedding and the parafine sections were stained by hematoxylin and eosin and periodic acid Schiff. Data were analyzed by ANOVA and Tukey multiple comparison tests.
RESULTS: Sepsis resulted in increased BUN and creatinine levels as compared to control group ($p<0.01$-0.001) but a decrease was observed in the glucose levels ($p<0.05$). In the dapagliflozin-treated sepsis group this decrease was abolished. Renal MDA levels were increased by sepsis as compared to control group but were not different among dapagliflozin-treated sepsis group in kidney tissues. GSH levels were exhausted in sepsis group ($p<0.05$) but increased in dapagliflozin-treated sepsis group ($p<0.001$). Histologically, sepsis group showed glomerular congestion, dilatation in Bowman space, interstitial bleeding and tubular damage with luminal debris. These histopathological results were moderately decreased in renal tissues of dapagliflozin-treated sepsis group.
CONCLUSION: The findings of the present study showed the possibility that treatment of dapagliflozin reduces sepsis-induced kidney damage by improving the balance between oxidative mechanisms.

Keywords: Dapagliflozin, Sepsis, glutathione, malondialdehyde, antioxidant

10.5505/2017ichc.PP-265 [Pathology and clinical medicine]

The Protective Effects Of Carvacrol On Cardiac Damages Caused By Global Cerebral Ischemia

Aslı Taslidere[1], Cemile Ceren Gül[1], Osman Ciftci[2], Nese Basak Türkmen[3]

[1]Inonu University Faculty of Medicine, Department of Histology and Embryology, Malatya, Turkey.

[2]Inonu University Faculty of Medicine, Department of Medical Pharmacology, Malatya, Turkey.

[3]Inonu University Faculty of Pharmacy, Department of Pharmaceutic Toxicology, Malatya, Turkey.

AIM: Cerebral ischemia or brain ischemia, is a condition that occurs when there isn't enough blood flow to the brain to meet metabolic demand. This leads to limited oxygen supply or cerebral hypoxia and leads to the death of brain tissue, cerebral infarction, or ischemic stroke. It is a sub-type of stroke along with subarachnoid hemorrhage and intracerebral hemorrhage. There are two kinds of ischemia: focal ischemia; confined to a specific region of the brain, global ischemia; encompasses wide areas of brain tissue. This study aimed that the determination of protective effects of carvacrol on heart damage caused by Global cerebral ischemia.
MATERIAL-METHOD: In our study 28 Sprauge-Dawley rats were used. Rat were divided into 4 groups randomly selected (n=7). Groups:
1.Group: Control (CMC %0,01)
2.Group: Ischemia reperfusion (CMC %0,01)
3.Group: Carvacrol (gavage 100 mg/kg)
4.Group: Ischemia reperfusion +Carvacrol
At the end of the study heart tissue samples were taken from rats. The heart samples were processed by routine tissue techniques and embedded in paraffin. 5 µm thick sections of tissues were cut, mounted on slides, stained with Hematoxylin-Eosin (H-E). For immunohistochemical investigation, sections were stained with Caspase-3 and examined under a Leica DFC280 light microscope by Leica Qwin and Image Analysis System.
RESULTS: In Control group, heart tissue showed a normal histological appearance with H-E procedure. In IR group, heart tissue showed some histological alterations such as: vascular congestion, oedema, vacuolisation in interstitial area, eosinophilic stained and pyknotic nuclei cells, mononuclear cell infiltration and ischemic areas. These findings were significantly decreased in IR+Carvacrol group. In biochemical analysis, IR lead to a significant increased in TBARS levels and significant decrease in GSH, SOD, GPx and CAT levels in testis tissue compared with other groups. Besides, in the IR+EA group there was an attenuated increased in TBARS levels and an increase in GSH, SOD, GPx and CAT activities.
CONCLUSION: As a result, we observed that carvacrol have protective effects on heart tissue damage. The results of this study suggest that ischemia-reperfusion could be significantly reduced by carvacrol administration.

Keywords: Rat, Cerebral ischemia, Heart, Caspase-3.

10.5505/2017ichc.PP-266 [Pathology and clinical medicine]

Investigation of the correlation between serum leptin levels and leptin gene -2548 G>A polymorphism in patients with Alzheimer's disease

Ibrahim Seyfettin Çelik[1], Ramazan Güneşaçar[2], Fatma Inanç Tolun[1], Buket Tuğan Yildiz[3], Bekir Mehmet Kelleci[2], Ferit Can Yazdiç[4], Deniz Tuncel[5], Muhammet Üremiş[1]

[1]Department of medical Bıochemsıtry Universty of Kahramanmaraş Sutçu Imam, Kahramanmaras, Turkey

[2]Department of medical Biology Universty of Kahramanmaraş Sutçu Imam, Kahramanmaras, Turkey

[3]Department of Clinical Neurology NFK Hospital Kahramanmaras, Turkey

[4]Department of Zootechnical, Universty of Kahramanmaraş Sutçu Imam, Kahramanmaras, Turkey

[5]Department of Clinical Neurology Universty of Kahramanmaraş Sutçu Imam, Kahramanmaras, Turkey

Alzheimer's disease is a neurodegenerative disorder characterized by impairment in memory and cognitive functions. Blood fat values were investigated in this study due to the known relationship between leptin hormone to blood lipid values in correlation to Alzheimer's disease. In this study, we aimed to determine whether serum leptin level and blood lipid parameters were statistically evaluated in promoter region c.2548 G> A polymorphism of leptin gene in healthy individuals and Alzheimer patients. The study included 61 Alzheimer patients and 60 healthy individuals within the same age group without any kinship relationship or other neurodegenerative disease. To determine the c.2548 G> A polymorphism in the LEP promotor region, PCR-RFLP technique applied by Gotoda et al. was modified and applied according to laboratory conditions. Serum leptin levels were statistically significant between the patient and control groups (p = 0.0001). When the serum leptin levels of patients and control groups participating in the study were compared in terms of genotype and allele gene, the serum leptin levels of patients with homozygous AA allele were statistically significant (p = 0.001). Serum leptin levels in patients who have G (GG + GA) alleles and controls were found to be statistically significant (p = 0.006). Serum leptin levels of polymorphic A (AA + GA) alleles in the patient and control groups were statistically significant (p = 0.001). Patients and control group participating in the study were found to be statistically significant with blood lipid levels of individuals with LDL p = 0,024, triglyceride p = 0,013, TOTAL cholesterol p = 0,034 and VLDL p = 0,012. In this study, there was no statistical significance between the patient and control groups in terms of genotype and alleles. In conclusion, serum leptin levels and blood lipid values show significants between patient and control group parameters which can be used in the diagnosis of Alzheimer's disease.

Keywords: Leptin, Alzheimer's Disease, Polymorphism.

10.5505/2017ichc.PP-267 [Pathology and clinical medicine]

The effect of intravesicale hyaluronic acid application on distribution of CD3, CD4, CD19, CD56 and IL-6 immunopositive cells in the experimental model of interstitial cystitis in mouse bladder

Ilker Fatih Sahiner[1], Hakan Soylu[2], Sema Avcı[2], Leyla Kılınc[2], Ahmet Danısman[1], Ozlem Ozbey[2], Nuray Acar[2], Ismail Ustunel[2]

[1]Akdeniz University, Faculty of Medicine, Department of Urology, Antalya, TURKEY

[2]Akdeniz University, Faculty of Medicine, Department of Histology and Embryology, Antalya, TURKEY

There is a great importance of Interstitial Cystitis (IC)/ Painful Bladder Syndrome (PBS) which is a bladder disease in urology. İnfection, autoimmunity, genetic, the presence of toxic substances in the urine, smoking, diet, psychiatric reasons can cause to interstitial cystitis. According to data of previous studies, there is a great importance of inflammation in the pathogenesis of this disease. Intravesical hyaluronic acid administration is one of the most effective treatment methods in the treatment of interstitial cystitis. According to our literature review, the effect of hyaluronic acid administration on CD3, CD14, CD19, CD56 and IL-6 immunopositive cell distributions in the bladder for the treatment of interstitial cystitis induced by intravesical hydrochloric acid application in rats has not yet been fully understood and it needs to be studied.This study was planned for this aim.
In the study, rats were sacrified after 2 to 4 days of HA treatment of interstitial cystitis and their bladder was removediIn the HCl group, it was determined that CD3, CD14, CD19, CD56 and IL6 immunopositive cells were significantly increased in the bladder tissue compared to the control group and in the HA treated group it was significantly lower than the HCl group and closer to the control.
As a result, it can be said that the treatment of interstitial cystitis HA reduces the number of CD3, CD14, CD19, CD56 and IL6 immunopositive cells and that the bladder tissue has a normal appearance.

Keywords: Bladder, Interstitial cystitis, HCl, Hyaluronic acid, Inflammation, Immunohistochemistry

10.5505/2017ichc.PP-268 [Pathology and clinical medicine]

Riboflavin Treatment Reduces Apoptosis and Oxidative DNA Damage in a Ischemia/Reperfusion Induced Renal Damage in Rats

Betül Ayaz Adakul[1], Büşra Ertaş[1], Dilek Özbeyli[2], Cansu Kandemir[3], Özge Çevik[4], Feriha Ercan[3], Göksel Şener[1]

[1]Department of Pharmacology, School of Pharmacy, Marmara University, İstanbul, Turkey

[2]Department of Physiology, School of Medicine, Marmara University, İstanbul, Turkey

[3]Department of Histology and Embryology, School of Medicine, Marmara University, İstanbul, Turkey

[4]Department of Biochemistry, School of Pharmacy, Cumhuriyet University, Sivas, Turkey.

INTRODUCTION: Oxygen free radicals are important components involved in the pathophysiological processes observed duringi schemia/reperfusion (I/R). Riboflavin is an easily absorbed micronutrient that plays an important role in maintaining health in humans and animals. This study was designed to determine the possible protective effect of riboflavin (RIBO) on renal I/R injury.
MATERIAL-METHODS: Wistar albino rats weighing 200-300 gr were divided into 3 groups of 7 animals per group. Riboflavin (25 mg/kg, orally) or vehicle was administered for one week as pretreatment and then to induce I/R injury, rats were unilaterally nephrectomized and subjected to 45 minutes of renal pedicle occlusion followed by 6 hours of reperfusion. At the end of the treatment period, all rats were decapitated. Kidney samples were taken for histological examination or determination of the renal malondialdehyde (MDA), glutathione (GSH) and 8-hydroxy-2<-deoxyguanosine (8-OHdG) levels and myeloperoxidase (MPO) and caspase-3 activities. Data were analyzed statistically.
RESULTS: I/R caused a significant decrease in tissue GSH level, which were accompanied by significant increases in MDA and 8-OHdG levels and MPO and caspase-3 activities. However, riboflavin treatment reversed these parameters. I/R group showed degenerated renal corpuscles with dilated Bowman space and cellular debris, atrophic glomeruli, degeneration in tubular cells with luminal debris and severe interstitial bleeding in renal parenchyma. However, RIBO+I/R group showed moderately decreased kidney damage.
CONCLUSION: Findings of the present study suggest that riboflavin exerts renoprotective effects via its radical scavenging, antioxidant and antiapoptotic activities, which appear to involve the inhibition of tissue neutrophil infiltration.

Keywords: Ischemia/reperfusion, riboflavin, oxidative damage

10.5505/2017ichc.PP-269 [Pathology and clinical medicine]

Immunohistochemical study of Osteopontin and Bcl-2 gene expression in kidney tissue in histidine-tryptophan-ketoglutarate (HTK) solution prepared with N-acetyl-L-carnitine

Candan Özoğul[1], Ilkay Başer Demircan[1], Süreyya Barun[2], Mustafa Kavutçu[3], Mustafa Ilhan[4], Seda Nur Akyol[1], Ibrahim Murat Hirfanoğlu[5], Mustafa Bilgi[3], Gülistan Sanem Sarıbaş[1], Pınar Kaçamak[1], Asiye Aslı Emniyet[1]

[1]Gazi University, Faculty of Medicine, Division of Basic Medical Sciences, Department of Histology and Embriology, Ankara, Turkey

[2]Gazi University, Faculty of Medicine, Division of Basic Medical Sciences, Department of Medical Pharmacology, Ankara, Turkey

[3]Gazi University, Faculty of Medicine, Division of Basic Medical Sciences, Department of Medical Biocemistry, Ankara, Turkey

[4]Gazi University, Faculty of Medicine, Division of Basic Medical Sciences, Department of Public Health, Ankara, Turkey

[5]Gazi University, Faculty of Medicine, Division of Internal Medical Sciences, Department of Pediatric Health and Illnesses, Ankara, Turkey

In this study we aimed to determine Osteopontin and Bcl-2 expression levels in kidney tissue in histidine-tryptophan-ketoglutarate (HTK) solution prepared with Acetyl L-Carnitine as immunohistochemistrical.
Organ transplantion is main solution for organ failure. Transplant organ must be protected from hypoxia to avoid ischemia.Ischemia is a restriction in blood flows to tissues, trigger to produce of reactive oxygen species (ROS), proinflammatory cytokine production and caused activation of apoptotic pathway. To prevent these damages, preservation solution is used include HTK that a protective agent, plays an important role in mitochondrial functions. Osteopontin (OPN) is an extracellular matrix cell adhesion phosphoglycoprotein. It is generally produced by osteoblasts and also produced by brain and kidney. OPN has some renoprotective actions in renal injury, such as increasing tolerance to acute ischemia, decreasing cell apoptosis and participating in the regeneration of cells. Bcl-2 is an antiapoptotic proteins are responsible to supress otophagy and apoptosis and allow the cell to survive.
MATERIAL-METHODS: We used 24 female rats equally divided into four groups: group1 had the uterus stored in HTK solution at +4°C cold storage for 4hours. Group2, the uterine tissue was stored in HTK solution combined with Acetyl L-carnitine for 4hours at +4°C. The same procedure with group1/2 were repeated for 24hours for groups3/4 respectively. Histological investigation and immunohistochemical analysis were performed.
RESULTS: Glomerular sclerosis was found to be mild in short-term HTK and HTK+L-Car groups but it was found widely in long term HTK and HTK+L-Car groups on histologic evaluation and widely in long term HTL+L-Car. Tubuler cell vacuolization and cellular desquamation were observed in the proximal tubules in the long-term HTK group. According to immunohistochemical evaluation, in short and long term HTK+L-Car groups acetyl L-Carnitine prevented the antiapoptotic mechanisms to be activated and the intense expression of Bcl-2 has not occurred. In short- and long-term HTK groups, Osteopontin showed more immunopositive result, as a marker of tissue damage.
CONCLUSIONS: It was determined that the modified HTK solution prevented the increase of the activation of the expected oxidant mechanisms resulting in ischemia. This contribution of acetyl L-carnitine was also found in long-term group findings.

Keywords: Ischemia, Histidine Tryptophane Ketoglutarate (HTK), Acetyl L-carnitine, Osteopontin, Bcl-2

Histological and immunohistochemical examination of all the groups.

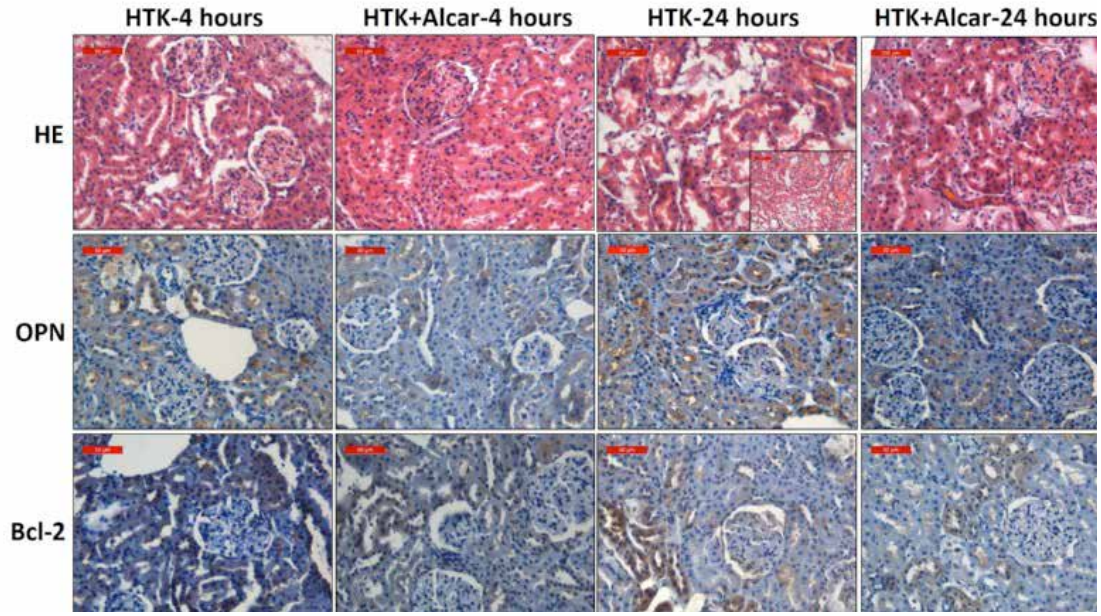

10.5505/2017ichc.PP-270 [Pathology and clinical medicine]

The effects of iloprost and ischemic pre-conditioning on mesenteric perfusion and ischemia-reperfusion injury of jejunal flaps

Fatma Betül Tuncer[1], Sevil Arabacı Tamer[2], Alper Yıldırım[2], Leyla Cinel[3], Hülya Şahin[3], Fatma Nihal Durmuş Kocaaslan[1], Özhan Çelebiler[1]

[1]Department of Plastic, Reconstructive and Aesthetic Surgery, School of Medicine, Marmara University, Istanbul, Turkey.

[2]Department of Physiology, School of Medicine, Marmara University, Istanbul, Turkey

[3]Department of Pathology, School of Medicine, Marmara University, Istanbul, Turkey

Introduction & OBJECTIVES: Free jejunal flap is one of the most commonly used flaps for esophageal reconstruction. However, ischemia-reperfusion (I/R) injury seen during the warm ischemia limits its use, since jejunum is extremely sensitive to ischemia. Iloprost, a prostacyclin analogue, was shown to be a promising agent in reducing I/R injury in both animal and clinical studies of liver transplantation. The goal of this study was to evaluate the effects of iloprost (ILO) and ischemic pre-conditioning (IPC) on intestinal I/R injury and to compare the effectiveness of these two modalities.

Materials & METHODS: Thirty-four Sprague-Dawley rats were randomized into 5 groups: Sham, I/R only (control), ischemic preconditioning (IPC), iloprost(ILO) and IPC+ILO. A 5-7 cm long jejunal segment was isolated with its supplying vessels under the microscope. Jejunal flaps in all groups, except sham group, underwent ischemia for 60 min and reperfusion for 2 hours by occluding the flap pedicle. Before the ischemia, 1 mcg/kg normal saline or iloprost was injected as an intravenous bolus in each group. Ischemic preconditioning was done by 3 cycles of 3 min ischemia and 3 min reperfusion. Flap perfusion was assessed by laser Doppler flowmetry throughout the study. The histologic sections were scored using Chiu scoring system. Superoxide dismutase (SOD) and myeloperoxidase (MPO) levels were measured via spectrophotometry.

RESULTS: Animals administered iloprost or underwent IPC had significantly better post-ischemic recovery of mesenteric perfusion and histologic scores compared with control group. In accordance with these results, SOD levels were increased and MPO levels were reduced in ILO and IPC groups. Iloprost group had improved perfusion and histology than IPC group following I/R injury ($p<0.05$).

CONCLUSION: We showed that iloprost and ischemic preconditioning increased the mucosal perfusion and reduced the mucosal injury of jejunal flap following I/R injury. Particularly iloprost might be considered as a novel treatment agent in the future to reduce the I/R injury of jejunal flaps.

Keywords: Jejunal flap, ischemic preconditioning, chiu score, prostacyclin, ischemia-reperfusion injury

10.5505/2017ichc.PP-271 [Pathology and clinical medicine]

Protective Effects of Exercise on Cardiovascular System in High-Fat Diet Induced Obese Rats

Merve Acikel Elmas[1], Seyit Enes Cakıcı[2], Ismail Rahmi Dur[2], Ibrahim Kozluca[2], Melih Arınc[2], Berkant Binbuga[2], Ozlem Bingol Ozakpinar[3], Meltem Kolgazi[4], Goksel Sener[5], Feriha Ercan[2]

[1]Department of Histology and Embryology, Acibadem University School of Medicine, Istanbul, Turkey

[2]Department of Histology and Embryology, Marmara University School of Medicine, Istanbul, Turkey

[3]Department of Biochemistry, Marmara University Faculty of Pharmacy, Istanbul, Turkey

[4]Department of Physiology, Acibadem University School of Medicine, Istanbul, Turkey

[5]Department of Pharmacology, Marmara University Faculty of Pharmacy, Istanbul, Turkey

INTRODUCTION: Obesity is a global epidemic health problem and it is an important risk factor that cause the pathogenesis of cardiovascular system organs. Oxidative stress, remarkable by excessive production of reactive oxygen species (ROS) is thought to be elevated in obese individuals with vascular diseases, particularly in males. On the other hand, exercise training is known to protect against cardiovascular disease and obesity. The aim of this study was to investigate the protective effects of swimming exercise on high fat diet induced obese male rats.
MATERIAL-METHODS: Sprague Dawley male rats fed either standart chow (STD group; 6% fat) or high fat diet (HFD group; 45% fat) for 18 weeks and half of these animals were trained by daily swimming sessions (1h per day, 5 days/week) the last 6 weeks (STD+EXC group and HFD+EXC group respectively). After 18 weeks, the animals were sacrificed under anesthesia, then blood, heart and aorta tissues were collected and prepared for both routine light and electron microscoical evaluations. In order to determine eNOS and iNOS distribution, the tissue samples were examined by immunohistochemistry. For biochemical examinations, malondialdehyde (MDA), glutathione (GSH) levels, and myeloperoxidase (MPO) activity were measured. All data were analysed statistically.
RESULTS: Normal morphology of aorta and cardiac tissues were observed in STD and STD+EXC group. In HFD group, inflammatory cell infiltration, mast cell activation, disorganisation of cardiac muscle cells were seen in the heart tissue. While quite regular cardiac muscle cells, granulated mast cells were seen in HFD+EXC group. Immunohistochemical results showed that eNOS-immunoreactivity (ir) was decreased and iNOS-ir increased in endothelium of aorta of HFD group compared to STD and STD+EXC groups. Biochemical results were parallel with the histological results.
CONCLUSION: This study revealed that obesity caused iNOS activation, inflammatory cell activation and increase oxidative stress parameters in cardiac and aorta tissues. Exercise protected the cardiac and aortic tissue damage from HFD induced obesity via inhibiting the formation of ROS and iNOS dependent nitric oxide metabolites.

Acknokledgement: This study was financially supported by Marmara Scientific Research Project Committee (SAG-B-110117-0003).

Keywords: Obesity, exercise, heart, reactive oxygen species (ROS), eNOS, iNOS

10.5505/2017ichc.PP-275 [Pathology and clinical medicine]

The role of aging and ER stress related proteins on testicular disturbances in STZ-diabetic rats

Fatma Kaya Dagistanli[1], Alp Aytekin[2], Nevin Erensoy[3], Selma Yilmazer[1]

[1]Cerrahpasa Faculty of Medicine,Istanbul University, Istanbul,Turkey

[2]Faculty of Medicine, University of Szeged,Szeged, Hungary

[3]Faculty of Medicine, Balıkesir University, Balikesir, Turkey

Diabetes mellitus (DM) causes severe complications and deleterious effects on various organs in the body. Sexual disturbances in diabetic patients are well known. The cause of fertility problems in diabetes is largely unknown. The aim of this study was to investigate the effects of streptozotocin (STZ) induced diabetes on testicular spermatogenic disturbances and expression of apoptosis, proliferation, aging and ER stress related proteins.

Seven male Wistar albino rats received intraperitoneal injection of STZ (65 mg/kg) and seven normal rats received vehicle and served as control. During the experimental period, blood glucose levels and body weights were measured. 30 days later, all the animals were sacrified and their testes were removed and prepared for light and electron microscopic examinations. The tissue sections were stained with hematoxylin and eosin, periodic acid shiff reaction for evaluation of testicular histopathological changes. Caspase 3, Caspase 8, ER chaperone GRP78, senescence and ageing protein p16 and proliferating cell nuclear antigen (PCNA) expressions were evaluated using immunohistochemical staining. TUNEL assays were performed to evaluate apoptosis.

Various morphological changes were observed in the testes of STZ induced diabetic rats including; disorganisation of germinal cells, spermatogenesis arrest in different stages, desquamation of immature germ cells and thickening of basement membranes of the seminiferous tubules.Diabetes induced increase in testicular TUNEL positive cells, and decrease in PCNA positive cells but did not change the expression of caspase-3 and caspase-8. Diabetic rat seminiferous tubules showed increased expression of p16 and GRP78. These results suggest that accelerated senescence of seminiferous epithelial cells and ER stress related mechanisms may contribute to diabetes induced testicular disturbances.

Keywords: Diabetic testes, Immunohistochemistry, Apoptosis, PCNA, p16, GRP78

Sponsoring Societies & Journals

European Microscopy Society

European Microscopy Society

International Cell Death Society

THE INTERNATIONAL CELL DEATH SOCIETY

Journal of Functional Morphology and Kinesiology

Journal of *Functional Morphology and Kinesiology*

Sponsoring Companies



FIGUR CONGRESS & ORGANIZATION

19 Mayıs Mah. 19 Mayıs Cad. Nova Baran Center No:4 34360 Şişli / İstanbul – Türkiye
Phone : +90 212 381 46 00 • Fax: +90 212 258 60 78
E-mail : ichc2017@figur.net

www.ichc2017.com