ISSN: 1220-3173; E-ISSN: 2457-7618

FUNCTIONAL MORPHOLOGY OF THE FOREARM MUSCLES IN THE BROWN BEAR (*URSUS ARCTOS*): ADAPTATIONS TO PLANTIGRADE LOCOMOTION

MORFOLOGIA FUNCȚIONALĂ A MUȘCHILOR ANTEBRAȚULUI LA URSUL BRUN (*URSUS ARCTOS*): ADAPTĂRI LA LOCOMOȚIA PLANTIGRADĂ

Alexandra-Andreea CHERȘUNARU[1),*)], T.D. HRIȚCU[1)], C. SPATARU[1)], T. SZARA[2)], O. MELNYK[3)], O. GÜNDEMIR[4)], Mihaela Claudia SPATARU[1)]

ABSTRACT | REZUMAT

The forearm of the brown bear (*Ursus arctos, Ursidae, Carnivora*) serves as a useful anatomical model for studying muscular adaptations in a large plantigrade carnivore whose behavior combines terrestrial locomotion, grasping, digging, and, in young individuals, limited climbing. This paper systematically describes the musculature of the forearm in *Ursus arctos* based on macroscopic dissection, with an emphasis on the morphology, architecture, and functional role of the main groups of muscles: digital and carpal flexors, digital and carpal extensors, pronators, and supinators. The results spotlight a deep flexor muscle (*m. flexor digitorum profundus*) with a pinnate appearance, involved in the powerful flexion of the claws, essential for digging or handling prey. The superficial flexor muscle (*m. flexor digitorum superficialis)* has a bipartite configuration, with a superficial pentadigital portion and a deep portion selectively inserted on the central fingers II–IV. The carpal flexors (*m. flexor carpi radialis* and *m. flexor carpi ulnaris*) contribute to the dynamic stabilization of the carpal joint under conditions of asymmetric mechanical stress, while the well-developed accessory carpal bone (*Os carpi accesorium*) amplifies the lever arm of the *flexor carpi ulnaris* muscle. The extensor group of muscles, comprising the digital and carpal extensor muscles (*m. extensor digitorum communis, m. extensor digitorum lateralis, m. extensor carpi radialis, m. extensor carpi ulnaris*), predominates on the craniolateral aspect of the antebrachium. These muscles play a critical role in stabilizing the forelimb during the stance phase of locomotion and facilitate active extension of the digits following forceful flexion. The *pronator teres* and *pronator quadratus* muscles are solely responsible for pronation, while the supinator muscles (*m. supinator, m. biceps brachii*) provide the forearm rotation necessary for grasping and, in juveniles, for climbing. Overall, the forearm musculature of *Ursus arctos* represents an evolutionary compromise between the retained arboreal capabilities characteristic of the *Ursidae* and the functional demands for strength, stability, and mechanical endurance associated with a large plantigrade carnivore exhibiting diverse locomotor and feeding behaviors. The findings presented here provide not only a detailed anatomical description of the zeugopodial musculature but also an integrated functional interpretation, demonstrating how muscular morphology reflects the ecological adaptations and behavioral repertoire of the species.

Keywords: *Ursus arctos*, Carnivora, myology, forearm, plantigrade

Antebrațul ursului brun (*Ursus arctos, Ursidae, Carnivora*) constituie un model anatomic util pentru studierea adaptărilor musculare la un carnivor plantigrad de talie mare, al cărui comportament îmbină locomoția terestră, prinderea obiectelor, săpatul și, la exemplarele tinere, o capacitate limitată de cățărare. Această lucrare descrie sistematic musculatura antebrațului la *Ursus arctos* pe baza disecției macroscopice, cu accent pe morfologia, arhitectura și rolul funcțional al principalelor grupe musculare: flexorii digitali și carpieni, extensorii digitali și carpieni, pronatorii și supinatorii. Rezultatele evidențiază un mușchi flexor profund (*m. flexor digitorum profundus*) cu aspect penat, implicat în flexia puternică a ghearelor, esențială pentru săpat sau pentru manipularea prăzii. Mușchiul flexor digital superficial (*m. flexor digitorum superficialis)* prezintă o configurație bipartită, cu o porțiune superficială pentadigitală și o porțiune profundă, inserată selectiv pe degetele centrale II–IV. Flexorii carpieni (*m. flexor carpi radialis* și *m. flexor carpi ulnaris*) contribuie la stabilizarea dinamică a articulației carpiene în condiții de solicitare mecanică asimetrică,în timp ce osul carpian accesoriu (*Os carpi accesorium*), bine dezvoltat, amplifică brațul de pârghie al mușchiului *flexor carpi ulnaris*. Grupul de mușchi extensori, alcătuit din mușchii extensori digitali și carpieni (*m. extensor digitorum communis, m. extensor digitorum lateralis, m. extensor carpi radialis, m. extensor carpi ulnaris*), predomină pe fața craniolaterală a antebrațului. Acești mușchi joacă un rol esențial în stabilizarea membrului toracic în timpul fazei de sprijin a locomoției și facilitează extensia activă a degetelor după o flexie pronunțată. Mușchii *pronator teres* și *pronator quadratus* sunt singurii responsabili de pronație, în timp ce mușchii supinatori (*m. supinator*, *m. biceps brachii*) asigură rotația antebrațului necesară pentru prindere și, la pui, pentru cățărare. Musculatura antebrațului la *Ursus arctos* reprezintă un compromis evolutiv între capacitățile arboreale păstrate, caracteristice familiei *Ursidae*, și cerințele funcționale de forță, stabilitate și rezistență mecanică asociate unui carnivor plantigrad de talie mare, care manifestă comportamente diverse de locomoție și hrănire. Rezultatele prezentate oferă nu numai o descriere anatomică detaliată a musculaturii zeugopodiale, ci și o interpretare funcțională, demonstrând modul în care morfologia musculară reflectă adaptările ecologice și repertoriul comportamental al speciei.

Cuvinte cheie: *Ursus arctos*, Carnivora, miologie, antebraț, plantigrad

1) "Ion Ionescu de la Brad" University of Life Science, Faculty of Veterinary Medicine, Iasi, Romania
2) Warsaw University of Life Sciences - SGGW, Institute of Veterinary Medicine, Warsaw, Poland
3) National University of Life and Environmental Sciences of Ukraine, Kyiv, Ukraine
4) Istanbul University- Cerrahpasa, Faculty of Veterinary Medicine, Istanbul, Türkiye
*) *Corresponding author: alexandra.chersunaru@iuls.ro*

The *Ursidae* family is a striking example of plantigrade posture among large mammals (33, 36). Although this ancestral conformation entails higher energy costs during terrestrial locomotion compared to digitigrade or unguligrade postures, offering significant biomechanical advantages,such as increased stability, support for a large body mass, and a high degree of dexterity in manipulative activities (33). In this context, the forelimb of the brown bear

(*Ursus arctos*) may be regarded as a functional phenotype that integrates seemingly contrasting biomechanical demands, combining the capacity to generate substantial traction forces with the degree of mobility required for climbing, object manipulation, and diverse foraging behaviors (30, 43). The brown bear (*Ursus arctos* Linnaeus, 1758) is one of the largest extant representatives of the order *Carnivora*, with adult body masses ranging from approximately 102 to 324 kg. It has a broad circumpolar distribution, occupying habitats ranging from tundra to temperate forests, exhibiting high ecological flexibility and a remarkably varied behavioral repertoire, enabling the species to exploit a wide spectrum of environmental conditions and food resources (8). Although the brown bear exhibits an omnivorous feeding strategy, its diet consists predominantly of plants, supplemented by the active predation of a wide range of vertebrate prey, including cervids, chamois, birds, and rodents, as well as the opportunistic scavenging of carrion (32). Despite its dietary plasticity, the species retains morphological characteristics typical of carnivorans. These include a dentition and gastrointestinal tract that closely resemble those of other members of the order *Carnivora*, along with well-developed grasping and food-manipulation abilities. Collectively, these anatomical and behavioral traits support its taxonomic placement within this order (21).

Unlike most large carnivores, *Ursus arctos* uses its forelimbs for a wide range of activities: digging hibernation dens and burrows, overturning rocks and logs in search of food, grasping food, marking territory by scratching tree bark, and also for fighting; and, in young individuals, for climbing trees (19, 27, 37). For cubs, trees provide a vital refuge from predators such as adult bears or other large predators (2, 19). Vertical climbing imposes substantial biomechanical demands on the forelimb, requiring coordinated activation of the supinator and digital flexor muscles to generate the forces necessary to maintain secure substrate attachment and to overcome gravitational loading (35). This ontogenetic shift in locomotor behavior is accompanied by a progressive reduction in the maximum range of forearm pronation and supination as body mass increases, reflecting a gradual decline in radioulnar mobility with skeletal and musculoskeletal maturation (2).

The adult brown bear exhibits relatively less supinator musculature and considerably more massive and robust forelimbs (21,22). This bony robustness and pronounced muscular development represent a clear evolutionary specialization aimed at optimizing digging force and resistance to impact with hard ground (2, 3, 21).

In *Ursus arctos*, the *pronator teres* and *pronator quadratus* muscles are solely responsible for pronation (35).

The forearm flexor muscles of the brown bear are characterized by robust muscle bellies and relatively short tendons, a morphological configuration that favors force production over contraction velocity. This architectural arrangement reflects the functional demands imposed by powerful digging, weight-bearing, and terrestrial locomotion across heterogeneous substrates, emphasizing mechanical strength and stability rather than rapid limb movements (1). Forearm rotation in *Ursus arctos* is achieved through the complex interaction between the radius and ulna and the pronator and supinator muscles (35). Supination and pronation are essential for orienting the palm relative to the substrate or prey (24, 38).

This study aims to provide a systematic morphofunctional description of the forearm musculature in *Ursus arctos*, based on direct anatomical dissection of the specimens examined. The research was structured around three complementary objectives: the identification and detailed characterization of the origins, insertions, and topographic relationships of the forearm muscles; analysis of muscle architecture in relation to the biomechanical requirements of locomotion; and integrating the authors' own dissection data into a comparative framework with the published literature, with an emphasis on the functional interpretation of the morphological characteristics identified in this species.

MATERIALS AND METHODS

The forelimbs of three brown bears (*Ursus arctos*), a juvenile female and two adult males from Bacău County (eastern Romania), euthanized for medical reasons, were dissected to identify and describe the range of motion of the joints, in relation to the morphology of the articular surfaces, ligament types, and muscle action. The specimens belonged to the collections of the Department of Anatomy at the Faculty of Veterinary Medicine in Iași. The limbs were preserved by freezing at −20 °C and subsequently dissected after thawing. Photographic documentation was taken at each stage of the dissection. The anatomical nomenclature used conforms to the *Nomina Anatomica Veterinaria*.

RESULTS AND DISCUSSION

General Muscular Architecture

The muscles of the forearm can be organized into four main functional compartments: (*1*) digital and carpal extensors (dorsal/extensor compartment), (*2*) digital and carpal flexors (palmar/flexor compartment), (*3*) pronator muscles, and (*4*) supinator muscles (12, 15, 18, 39, 41). In *Ursidae*, the flexor muscles are well developed and predominant, supporting their functional roles in digging and grasping (1, 15, 35).

Extensor Muscles — Adaptations for Stability and Propulsion

The craniolateral aspect of the forearm in brown bears is occupied by the extensor muscle group, which is functionally organized into two distinct subdivisions: the digital extensors (*m. extensor digitorum communis* and *m. extensor digitorum lateralis*) and the carpal extensors (*m. extensor carpi radialis* and *m. extensor carpi ulnaris*). These muscles are responsible for active extension of the carpus and digits and contribute to stabilization of the thoracic limb during the stance phase of locomotion by resisting flexion under load (35).

Within the craniolateral compartment, the *extensor carpi radialis* muscle originates from the lateral epicondylar crest. In the brown bear, unlike in the dog—where the two portions are partially fused into a common muscle mass and separate predominantly distally— the *extensor carpi radialis* muscle exhibits a complete division into the *longus* and *brevis* portions already at the level of origin, an aspect comparable to that described in the cat (35). The complete separation of the two segments in the brown bear suggests, by analogy with humans and cats, greater independence of carpal extension and abduction

(11, 35). In the dog, the two segments remain partly fused proximally, and experimental dissection at their origin increases elbow hyperextension, indicating that the proximal fusion contributes to passive stabilization of the elbow joint (9, 26). In the brown bear, the architecture differs; the two portions are independent from their origin. Therefore, this separation may redistribute the mechanical load at the elbow: the *longus* portion could retain a role in flexion and stabilization, analogous to its role during flexion, as documented in humans (6, 17). Furthermore, the anatomical separation of the *brevis* and *longus* components in the brown bear suggests that the *brevis* portion may contribute less, or in a functionally distinct manner, to passive stabilization of the elbow joint. However, this interpretation remains hypothetical for *Ursidae* and is based solely on comparative anatomical evidence, as no species-specific experimental studies have yet validated this proposed functional relationship.

Distally, the muscle's tendon passes under the abductor pollicis longus muscle (*M. abductor digiti primi (pollicis) longus*), through the synovial sheath shared by the two muscles. The *longus* portion inserts at the base of the second metacarpal bone, and the *brevis* portion at the base of the third metacarpal bone, thereby contributing to the extension and abduction of the carpal joint (35).

The *extensor digitorum communis* muscle originates from the humeral lateral epicondyle and runs along the dorsal aspect of the forearm. In the carpal region, its four tendons are distributed to the second, the third, the fourth, and the fifth fingers (Fig.1), allowing the simultaneous or independent extension of the fingers, and is additionally involved in paw retraction and limb repositioning during locomotion (18). The lateral digital extensor muscle (*M. extensor digitorum lateralis*) originates from the lateral collateral ligament and the lateral epicondyle of the humerus. It passes through the carpal retinaculum extensorum, then it trifurcates, distributing tendons to the third, the fourth, and the fifth digits (Fig. 1).

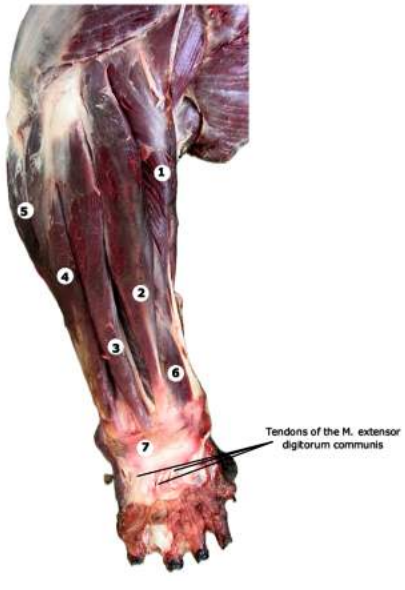

Fig. 1. Dorsal aspect of the forearm in *Ursus arctos.* 1- *M.* brachioradialis*,* 2- *M. extensor carpi radialis,* 3- *M. extensor digitorum communis*, 4- *M. extensor digitorum lateralis,* 5- *M. extensor carpi ulnaris,* 6- *M. abductor digiti primi longus,* 7- *Retinaculum extensorum*

The *abductor digiti I (pollicis) longus* muscle is well developed in the brown bear, exhibiting a triangular muscular aspect and an oblique course along the distal portion of the antebrachium, before inserting on the base of the first metacarpal. Its pronounced development suggests a multifunctional biomechanical role. In addition to facilitating abduction and extension of the first digit, the muscle may contribute to forearm supination through its oblique position. Similarly, it assists in stabilizing the carpal joint during grasping, manipulation, and substrate interaction. However, these proposed functions should be regarded as functional inferences based on anatomical morphology and require experimental validation (35).

In plantigrade carnivores,the extensor muscular complex plays an important role in stabilizing the forelimb during the stance phase of locomotion by counteracting the flexion moments generated at the carpal and digital joints, as well as by maintaining the segmental alignment of the limb during increased mechanical loads (7, 37, 42, 45). In addition, the digital extensor muscles facilitate active extension of the digits following flexion, thereby restoring digital alignment and preparing the limb for subsequent contact with the substrate. This functional pattern is consistent with the repetitive flexion–extension cycles associated with digging and other force-generating forelimb activities (42, 45). Morphological and functional studies of various carnivores (procyonids, mustelids, felids) confirm a relatively pronounced development of the extensor muscles as an adaptation to the increased mechanical demands on the forelimb, both during support and while handling prey (42, 45).

Pronator and Supinator Muscles

The osteomuscular architecture of the brown bear zeugopodium includes specialized structures that enable forearm rotation. Thus, the *supinator* muscle and, to some extent, the *biceps brachii* muscle provide pronation/supination mobility; these rotational movements enhance forelimb versatility and are functionally important for substrate interaction, limb stabilization, and the manipulation of food and objects (44). From a biomechanical perspective, studies show that, at different speeds, the forearm functions in the frontal plane as a support structure, illustrating a robust forelimb adapted to withstand repeated loads during terrestrial locomotion, rather than a fine specialization for rotation or propulsion (2, 37).

In *Ursus arctos*, the *supinator* muscle is well developed, with a broad origin on the humeral lateral epicondyle and on the collateral ligament (13). The *biceps brachii* muscle originates from the supraglenoid tubercle and courses through the intertubercular (bicipital) groove by means of a short proximal tendon. Distally, toward the radial insertion, it thickens and then inserts onto the bicipital tuberosity of the radius through a short tendon (Fig.2).

Pronator teres and *pronator quadratus* muscles achieve forearm pronation. In bears, the *pronator teres* muscle has a short body and a long tendon inserting on the medial border of the radius in its distal third; it primarily performs flexion of the elbow joint, similar to that in dogs (10, 18, 35). *M. pronator quadratus* occupies the deep layer of the antebrachium, lying on the interosseous membrane between the distal parts of the radius and ulna. Based on the present observations, the muscle is quadrilateral in shape, measuring approximately 6–7 cm in width, with transversely oriented muscle fibers. It origi-

nates from the caudomedial border of the ulna and inserts onto the opposing palmar surface of the distal part of the radius. The location and fiber orientation are consistent with its primary role in forearm pronation while also contributing to stabilization of the distal radioulnar joint (Fig.3). The transverse orientation of fibers provides the muscle with an optimal mechanical advantage for pronation, acting as a direct rotator of the radius related to the ulna (18, 35).

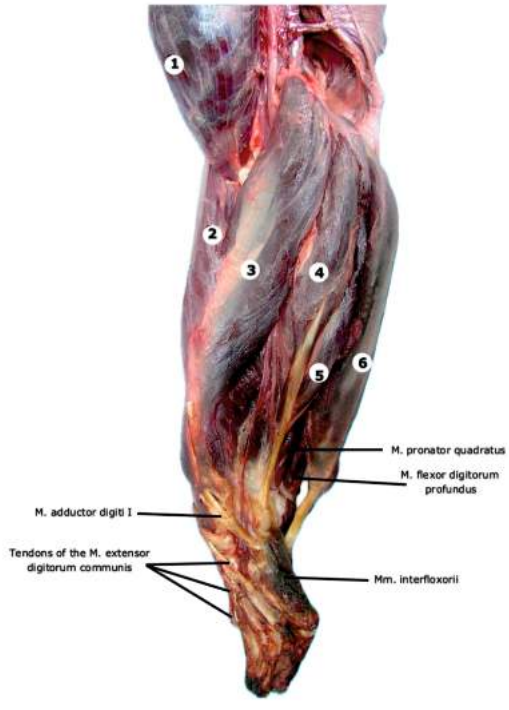

Fig. 2. Cranio-medial aspect of the forearm in *Ursus arctos.* 1- *M. biceps brachii,* 2- *M. extensor carpi radialis,* 3-*M. extensor digitorum communis,* 4- *M. extensor carpi ulnaris,* 5- *M. supinator,* 6- *M. flexor digitorum superficialis*

From a functional standpoint, the *pronator quadratus* muscle rotates the radius around the ulna, bringing the palmar surface toward the ground and preparing the forelimb for supporting and grasping, a functional aspect more closely resembling that of felines than dogs (20). The muscle acts throughout the entire range of forearm pronation, irrespective of the degree of elbow flexion or extension. Its distal location, between the radius and ulna, enables it to maintain close apposition of these bones at the distal radioulnar joint, thereby providing dynamic stabilization during rotational movements. In addition to its role in pronation, the muscle contributes to forearm stability during grasping and load-bearing activities by facilitating the distribution of mechanical forces between the radius and ulna. This stabilizing function is particularly important during substrate support, object manipulation, and weight-bearing tasks and is consistent with the biomechanical role attributed to the *m. pronator quadratus* in humans (35, 46).

Data on the magnitude of this rotation was determined by Amaike et al. (2021) through direct measurements, the average ranges of rotation of the radius relative to the ulna being of 78.0° ± 1.9° in subadult Asian black bears and 76.9° ± 2.1° in adult bears, compared to 72.7° ± 2.9° in subadult brown bears and only 45.8° ± 5.2° in adult brown bears, showing a significant reduction in mobility with skeletal maturation. In the only adult polar bear examined, the pronation-supination range of motion was only 39.3°, the lowest value reported within the family *Ursidae*. This trend toward reduced radioulnar mobility, correlated with the degree of dietary specialization, is also supported by behavioral observations: species with a predominantly omnivorous diet appear to use their forelimbs with greater manipulative dexterity than strictly carnivorous species (20).

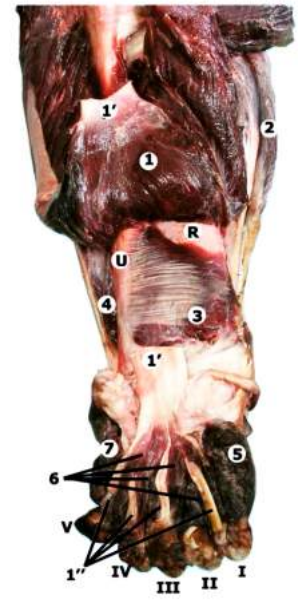

Fig. 3. Palmar muscles of the *Ursus arctos*. I-V- *Digits*, U-*Ulna*, R- *Radius*, 1, 1', 1''- *M. flexor digitorum profundus*, 2-*M. extensor carpi radialis*, 3 - *M. pronator quadratus*, 4- *M. extensor digitorum lateralis*, 5- *M. extensor digiti I*, 6- *Mm. interflexorii*, 7- M. *extensor digiti minimi (V)*

Carpal Flexors

Flexor carpi radialis and *flexor carpi ulnaris* contribute to both flexion of the antebrachio-carpal-metacarpal joint and its stabilization during the asymmetric forces involved in digging. In some plantigrade mammals, including bears, the *flexor carpi ulnaris* muscle is associated with a well-developed pisiform bone, which contributes to the increasing of the muscle's lever arm (1, 10, 23). *M. flexor carpi radialis* originates from the medial epicondyle of the humerus, immediately caudal to the origin of the *m. pronator teres*. The muscle possesses a well-defined fusiform belly that continues distally as a long, distinct tendon from the middle of the antebrachium. Regarding the distal course of the muscle, the data presented indicate insertion on the first and second metacarpals, which supports carpal adduction and flexion (1).

The flexor carpi ulnaris muscle consists of two portions with distinct origins that converge toward a common distal insertion. The humeral portion attaches to the epitrochlear tubercle, while the ulnar portion, triangular in shape, originates on the caudo-medial aspect of the olecranon, gradually fusing with the former as it descends along the forearm. Distally, both portions insert onto the pisiform bone, whose presence considerably increases the muscle's lever arm, thereby amplifying the force avai-

lable for ulnar flexion and stabilization of the carpal joint (1, 15). Through their combined action, the two mentioned flexors contribute to the flexion and stabilization of the carpal joint, especially during the intense mechanical stresses generated by digging (28, 37).

Superficial digital flexor muscle of *Ursus arctos*

In *Ursidae*, the superficial digital flexor muscle consists of two muscular bellies: a superficial portion, associated with the *palmaris longus muscle* (21, 40), and a deep portion, with different morphological characteristics and a different course, but which converge into a common tendon (10, 15, 40). The superficial portion, which is more developed, originates from the humeral epitrochlear crest running along the entire length of the caudo-medial aspect of the forearm. Upon reaching the carpal region, the tendon crosses the *flexor retinaculum (manica flexoria),* where the *palmaris longus* muscle also inserts. It contributes to stabilization of the carpal joint and provides tension to the palmar fascial structures, thereby indirectly helping grasping and support on the ground. In the brown bear, the palmar fascia is particularly well developed, forming a robust connective tissue framework that reinforces the carpal joint and enhances the mechanical stability of the palmar aspect of the manus during locomotion and substrate interaction. From the deep surface, the common tendon of the *flexor digitorum brevis* muscle arises; however, its presence is variable in *Ursus arctos*, in contrast to the consistent presence described in some felids (3). Distal to the carpus, the main tendon of the superficial portion branches into four insertion tendons, serving digits I–IV in all specimens examined and allowing for independent flexion of each digit (Fig.4).

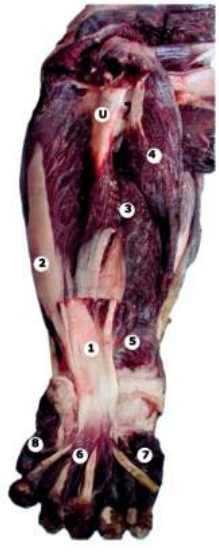

Fig. 4. Caudal view of the deep antebrachial muscles in *Ursus arctos*. *U- ulna; 1- M. flexor digitorum superficialis; 2- M. flexor digitorum profundus, caput ulnare; 3- M. flexor digitorum profundus, caput humerale; 4- M. pronator teres; 5- M. pronator quadratus; 6-M. interflexorii; 7- M. adductor digiti I; 8- M. adductor digiti V*

The deep portion shares a common humeral origin with the humeral portion of the deep digital flexor, to which it is closely attached. It is not until the distal third of the forearm that the two structures separate, with the deep portion of the superficial flexor becoming a distinct entity. At this level, three tendons branch off, passing through the large carpal tunnel. Distally, these tendons attach to the tendons of the superficial portion corresponding to digits II, III, and IV (Fig. 4). In carnivores, this bipartite architecture—two muscle bellies—confers remarkable functional versatility on the superficial flexor: the ability to generate global flexion of the paw while finely modulating the pressure exerted on digits II–IV, which is essential for grasping and manipulating prey and for stabilizing contact with the substrate (38).

Flexor digitorum profundus muscle of *Ursus arctos*

The flexor digitorum profundus muscle is one of the most important muscles of the forelimb in the brown bear in terms of the force it generates. It features pennate muscle bundles, a configuration that maximizes the physiological cross-sectional area and, consequently, the contraction force generated per unit of muscle volume (5). The ulnar portion is the most voluminous component of the muscle; it attaches using an extensive insertion along the entire caudomedial margin of the ulna, from the olecranon to the distal end of the bone (Fig. 4).

The force generated at this level is transmitted through a robust tendon, which transitions into the tendon of the humeral portion. The radial portion, which is triangular (fan-shaped), originates from the proximal two -thirds of the caudomedial surface of the radius; then it fuses along its entire length with the ulnar portion, contributing to the homogenization of force transmission to the common tendon (15).

At the carpus, the common tendon widens considerably (3–4 cm) as it passes through the large carpal tunnel. Distally, the tendon branches into five cylindrical tendons, one for each finger, each anchoring to the flexor tubercle of the distal phalanx—the insertion point where force is applied directly to the claw (5).

The distal flexor system is complemented by the interflexor muscles (*mm. interflexorii*), accessory structures originating from the branches of the deep flexor tendon, which attach to the tendons and insert onto the medial sesamoid bones (Fig.4). Perdomo-Cárdenas et al. (2021) described the interflexor muscles in procyonids as structures with marked interspecific variability, absent or rudimentary in cursorial carnivores and better represented in species with manipulative behaviors. Their presence in *Ursus arctos* fits this pattern, supporting the hypothesis of a distal flexor system adapted for precision under variable load conditions. Far from being passive elements, these muscles modulate and guide the force generated by the main muscle groups, ensuring precision and stability of flexion under conditions of maximum exertion—such as when the bear digs its claws into the ground or forcefully seizes prey (14, 40).

Comparative studies of *Carnivora* indicate relatively high muscle mass and a moderately oblique orientation of muscle bundles relative to the tendon axis, parameters associated with high force production (25, 29). Although these data come from studies of burrowing mustelids, the architectural parameters are comparable across *Carnivora* in the context of convergent adaptations for digging (7, 14). In bears, the *flexor digitorum profundus* muscle provides the primary force for powerful flexion of the claws, an essential aspect for digging and grasping food resources (1).

In *Ursus arctos*, the forearm musculature represents a generalist functional phenotype, capable of supporting both behaviours requiring brute force (digging) and behaviours requiring mobility and coordination (climbing, manipulation) (4, 21, 28, 40).

Pagano et al. (2018) spotlighted that, although plantigrade locomotion in bears is energetically more demanding than digitigrade locomotion at higher speeds, it provides significant functional advantages in non-locomotor activities, including digging, grasping, and object manipulation. This versatility is directly reflected in the muscular architecture of the forearm, which is not optimized for a single function but rather for a wide range of mechanical demands (4, 37).

In the comparative literature on carnivores, forearm musculature evolves convergently in arboreal species, with stronger and more massive wrist rotators and elbow flexors, indicating a combination of strength and fine control of the forelimb (2, 21, 40, 42). Based on a large sample of carnivores, Böhmer et al. (2019) observed that the relative mass of the digital flexors and forearm rotators is significantly correlated with the degree of arboreality, independent of phylogeny.

In *Ursus arctos*, although arboreal behaviour is limited in adults, the presence of these muscular features can be interpreted as structures that were originally selected for climbing and later functionally repurposed for manipulation and digging (3, 21, 42). According to observations of Tarquini et al. (2023), the carpal and digital extensors stabilize the limb and re-extend the digits after a strong flexion. In the brown bear, pronation and supination are produced by *pronator teres* and *pronator quadratus* muscles, as well as by the well-developed *supinator* and *biceps brachii* muscles, allowing for substantial rotation of the forearm (35). Amaike et al. (2021) demonstrated that radio-ulnar mobility in *Ursus arctos* is not fixed at the species level but varies with age: non-adult brown bears, which retain climbing ability, showed pronation/supination angles comparable to those of the more arboreal *U. thibetanus*, whereas adult brown bears, which lose this ability, showed reduced angles similar to those of the strictly terrestrial *U. maritimus*. This ontogenetic shift supports the conclusion that the range of pronation and supination reflects arboreal activity within *Ursidae*, rather than representing a stable, species-level ecological trait.

Digging is used by *Ursidae* to prepare hibernation dens, extract roots and tubers, access colonies of social insects, and to hunt subterranean rodents (27). The brown bear's digging efficiency is supported not only by the described muscular architecture but also by the skeletal configuration of the forearm: an elongated olecranon, a robust radius, and compact carpal bones, aspects that maximize the transmission of forces generated by the proximal musculature to the distal end of the limb (21, 35, 36). Estimates of digging force in the brown bear significantly exceed those recorded in carnivores of similar size, which is consistent with the described muscular architecture (16). Climbing behaviour is indeed more common in young individuals (under 3–4 years of age); they use trees as refuge against predators (19). Adults occasionally climb to access food resources such as fruit or honey, or to mark the territory. Climbing movements heavily engage the supinators and digital flexors to maintain grip (2).

Compared to American black bears (*Ursus americanus*), which are considered more frequent and agile climbers, adult brown bears have relatively less developed supinator muscles and more massive forelimbs, reflecting an evolutionary trade-off toward specialization in digging (3, 22). Although direct comparative data on the mass of the supinators in *U. arctos* and *U. americanus* are limited, the available morphological pattern suggests a functional differentiation between the two species (22, 28).

The present study is based on a limited number of specimens, which calls for caution in generalizing-conclusions; future studies on larger samples, supplemented with quantitative data on muscle architecture—mass, fascicle length, and physiological cross-sectional area—would allow for a more rigorous biomechanical characterization. The data presented may serve as a reference point for comparative studies within the *Ursidae* family, with potential applications in providing a scientific basis for habitat management plans for brown bear populations in Europe.

CONCLUSIONS

Dissection of the forelimbs of three specimens of *Ursus arctos* revealed a complex forearm musculature, with morphofunctional adaptations consistent with the species' omnivorous lifestyle and plantigrade locomotion. The deep digital flexors, well-developed supinator and pronator muscles, and massive carpal extensors reflect the forelimb's ability to combine the strength required for digging and food manipulation with limb stabilization during weight-bearing phases. The nomenclature and morphological descriptions obtained are consistent with *Nomina Anatomica Veterinaria* and with the available comparative literature on *Carnivora*. The data presented may serve as a reference point for future studies in comparative anatomy, biomechanics, or wildlife medicine and rehabilitation.

REFERENCES

1. *Adrian B., Barton M., Tang S., Fisher R.,* (2010), The functional and comparative anatomy of the forelimb muscles in the sun bear (*Helarctos malayanus*). The FASEB Journal, 24:448.4-448.4
2. *Amaike H., Sasaki M., Tsuzuki N., Kayano M., Oishi M., Yamada K., Kitamura N.,* (2021), Mobility of the forearm skeleton in the Asiatic black (*Ursus thibetanus*), brown (*U. arctos*) and polar (*U. maritimus*) bears. Journal of Veterinary Medical Science, 83(8): 1284–1289
3. *Argot C.,* (2001), Functional-adaptive anatomy of the forelimb in the Didelphidae, and the paleobiology of the Paleocene marsupials Mayulestes ferox and Pucadelphys andinus. Journal of Morphology, 247(1):51–79
4. *Argot C.,* (2010), Morphofunctional analysis of the postcranium of *Amphicyon major* (*Mammalia, Carnivora, Amphicyonidae*) from the Miocene of Sansan (Gers, France) compared to three extant carnivores: Ursus arctos, Panthera leo, and Canis lupus. Geodiversitas, 32(1):65–106
5. *Ari H.H., Yurdakul İ., Aksoy G.,* (2019), A macroscopic study on the muscles and tendons of forepaws in the anatolian bobcat (*Lynx lynx*). Slovenian Veterinary Research, 56(4):153–162
6. *Bernholt D. L., Rosenber S. I., Brady A. W., Storaci H. W., Viola R. W., Hackett T. R.,* (2020), Quantitative

and qualitative analyses of the lateral ligamentous complex and extensor tendon origins of the elbow: an anatomic study. Orthopaedic Journal of Sports Medicine, 8(10):2325967120961373
7. *Böhmer C., Fabre A.C., Taverne M., Herbin M., Peigné S., Herrel A.,* (2019), Functional relationship between myology and ecology in carnivores: do forelimb muscles reflect adaptations to prehension?. Biological Journal of the Linnean Society, 127(3):661–680
8. *Bojarska K., Selva N.,* (2012), Spatial patterns in brown bear *Ursus arctos* diet: the role of geographical and environmental factors. Mammal Review, 42(2): 120–143
9. *Chong T. E., Davies H. M.,* (2018), Investigating canine elbow joint stabilisation through mechanical constraints of the deep fascia and other soft tissues. Journal of Anatomy, 232(3):407-421
10. *Constantinescu Gh.M.,* (2018), Illustrated veterinary Anatomicał Nomenclature. 4th Edition, Georg Thieme Verlag
11. *Cossu F., Guintard C.,* (2000), Anatomical and descriptive study of the radial extensor muscle (M. extensor carpi radialis). Anatomia, Histologia, Embryologia, 29(6):337-343
12. *Coțofan V., Palicica R., Hrițcu V., Enciu V.,* (1999), Anatomy of domestic animals, Vol. I. [in Romanian], (Ed.) Didactică și Pedagogică, Bucharest, Romania
13. *Davis D.D.,* (1964), The giant panda: A morphological study of evolutionary mechanisms. Fieldiana Zoology Memoirs, 3:1–339
14. *de Souza Junior P., de Souza Pahim A.B., Viotto-Souza W., Pellenz J., Bernardes F.C.S., Abidu-Figueiredo M., Santos A.L.Q.,* (2021), Evolutionary history or function? Which preponderates in the expression of the muscle mass of the thoracic limb in wild carnivorans?. Anatomical Record, 304(6):1344–1356
15. *Endo H., Sasaki M., Narushima E., Komiya T., Hayashida A., Hayashi Y., Stafford B.J.,* (2003), Macroscopic study of the functional significance of the forearm muscles in the giant panda. Journal of Veterinary Medical Science, 65(8):839–843
16. *Ercoli M.D., Prevosti F.J., Alvarez A.,* (2014), Form and function within a phylogenetic framework: Locomotory habits of extant predators and some Pliocene carnivorans. Annales Zoologici Fennici, 51(4):348–362
17. *Ettema G. J. C., Styles G., Kippers V.,* (1998), The moment arms of 23 muscle segments of the upper limb with varying elbow and forearm positions: implications for motor control. Human Movement Science, 17(2):201-220
18. *Evans H.E., de Lahunta A.,* (2013), Miller's Anatomy of the Dog. 4th ED., (Ed.) Elsevier Saunders, Philadelphia, USA
19. *Herrero S.,* (2018), Bear attacks: their causes and avoidance, (Ed.) Simon and Schuster, New York, USA
20. *Iwaniuk A.N., Whishaw I.Q.,* (1999), How skilled are the skilled limb movements of the raccoon (*Procyon lotor*)?. Behav. Brain Res., 99:35–44
21. *Iwaniuk A.N., Pellis S.M., Whishaw I.Q.,* (1999), The relationship between forelimb morphology and behaviour in North American carnivores (*Carnivora*). Canadian Journal of Zoology, 77(7):1064–1074
22. *Iwaniuk A.N., Pellis S.M., Whishaw I.Q.,* (2000), The relative importance of body size, phylogeny, locomotion, and diet in the evolution of forelimb dexterity in fissiped carnivores (*Carnivora*). Canadian Journal of Zoology, 78(7):1110–1125
23. *Jenkins P.A., Weijs W.A.,* (1979), The functional anatomy of the shoulder in the Virginia opossum (*Didelphis virginiana*). Journal of Zoology, 188:379–410
24. *Junior P.D.S., dos Santos L.M., Nogueira D.M., Abidu-Figueiredo M., Santos A.L.,* (2015), Occurrence and morphometrics of the brachioradialis muscle in wild carnivorans (Carnivora: Caniformia, Feliformia). Zoologia (Curitiba), 32:23–32
25. *Jurestovsky D.J., Blob R.W., Butcher M.T.,* (2017), Forelimb muscle architecture in the American badger (*Taxidea taxus*): Functional implications for digging. Journal of Morphology, 278(11):1507–1521
26. *Kamali Y., Almasi R., Moradi H. R., Fathollahi S.,* (2023), Intraspecific anatomical variations of the extensor tendons of the carpus and digits with a reexamination of their insertion sites in the domestic dog (*Canis lupus familiaris*): a cadaveric study. BMC Veterinary Research, 19(1):197
27. *Mattson D.J., Blanchard B.M., Knight R.R.,* (1991), Food habits of Yellowstone grizzly bears, 1977–1987. Canadian Journal of Zoology, 69(6):1619–1629
28. *Meloro C., de Oliveira A.M.,* (2019), Elbow joint geometry in bears (*Ursidae, Carnivora*): a tool to infer paleobiology and functional adaptations of Quaternary fossils. Journal of Mammalian Evolution, 26:133–146
29. *Moore A.L., Butcher M.,* (2011), Functional specialization in the forelimb of two digging mammals: the American badger (*Taxidea taxus*) and groundhog (*Marmota monax*). (unpublished).
30. *Morlo M., Friscia A., Miller E.R., Locke E., Nengo I.,* (2021), Systematics and paleobiology of Carnivora and Hyaenodonta from the lower Miocene of Buluk, Kenya. Acta Palaeontologica Polonica, 66(2):465–484
31. *Nomina Anatomica Veterinaria (NAV),* (2017), The international committee on veterinary gross anatomical nomenclature, 6th ed, WAVA, Hannover, Germany
32. *Nowak R.M.,* (1999), Walker's mammals of the world, Vol. 1., (Ed.) JHU Press, Baltimore, USA
33. *Pagano A.M., Carnahan A.M., Robbins C.T., Owen M.A., Batson T., Wagner N., Williams T.M.,* (2018), Energetic costs of locomotion in bears: is plantigrade locomotion energetically economical?. Journal of Experimental Biology, 221(12):jeb175372
34. *Perdomo-Cárdenas V., Patiño-Holguín C., Vélez-García J.F.,* (2021), Evolutionary and terminological analysis of the flexor digitorum superficialis, interflexorii and palmaris longus muscles in kinkajou (*Potos flavus*) and crab-eating racoon (*Procyon cancrivorus*). Anatomia Histologia Embryologia, 50:520–533
35. *Ruzhanova-Gospodinova I., Georgiev G.I.,* (2024), Anatomical features related to the locomotion of the brown bear (*Ursus arctos*) zeugopodium. Acta Morphologica et Anthropologica, 31(1-2)
36. *Shine C.L.,* (2016), Ursidae locomotion: Right down to the "bear bones". Doctoral dissertation, University of Idaho, USA
37. *Shine C.L., Robbins C.T., Nelson O.L., McGowan C.P.,* (2017), Grizzly bear (*Ursus arctos horribilis*) locomotion: forelimb joint mechanics across speed in the sa-

gittal and frontal planes. Journal of Experimental Biology, 220(7):1322–1329
38. *Smith H.F., Adrian B., Koshy R., Alwiel R., Grossman A.,* (2020), Adaptations to cursoriality and digit reduction in the forelimb of the African wild dog (*Lycaon pic*tus). PeerJ, 8:e9866
39. *Spătaru C., Spătaru M.,* (2003), Practical manual of veterinary anatomy — The locomotor system [in Romanian], (Ed.) Tehnopress, Iași, Romania
40. *Spoor C. F., Badoux D. M.,* (1986), Nomenclatural review of long digital forelimb flexors in carnivores. The Anatomical Record, 216(4):471-473
41. *Ștefănescu S., Predoi G., Belu C., Georgescu B., Dumitrescu I., Bițoiu C., Șeicaru A.,* (2012), Morpho-functional correlations of the forearm muscle at sheep and dog. Scientific Works — University of Agronomical Sciences and Veterinary Medicine Bucharest, Series C, Veterinary Medicine
42. *Tarquini J., Mosto M.C., Ercoli M.D.,* (2023), Functional and phylogenetic interpretation of the forelimb myology of two South American carnivorans, the ring-tailed coati (*Nasua nasua*) and crab-eating raccoon (Procyon cancrivorus). Journal of Morphology, 284 (6):e21587
43. *Tarquini J., Toledo N., Morgan C.C., Soibelzon L.H.,* (2015), The forelimb of †Cyonasua sp. (*Procyonidae, Carnivora*): ecomorphological interpretation in the context of carnivorans. Earth and Environmental Science Transactions of the Royal Society of Edinburgh, 106(4):325–335
44. *Tochigi K., Masaki T., Nakajima A., Yamazaki K., Inagaki A., Koike S.,* (2018), Detection of arboreal feeding signs by Asiatic black bears: effects of hard mast production at individual tree and regional scales. Journal of Zoology, 305(4):223–231
45. *Vélez-García J.F., Marín-González L., Monroy-Cendales M.J., Miglino M.A.,* (2022), Craniolateral forearm muscles of the crab-eating raccoon (*Procyon cancrivorus*) and a comparative review with other carnivorans.Iheringia—Série Zoologia, 112:e2022012
46. *Zeybek N., Gayretli Ö., Şanlıtürk Y. N., Kale A.,* (2025), Morphometric and anatomic characteristics of pronator quadratus muscle. Chinese Journal of Traumatology, 28(4):252-256.