Diagnostic Performance of Superb Microvascular Imaging and Other Sonographic Modalities in the Assessment of Lateral Epicondylosis

Serdar Arslan, MD, Ali Yavuz Karahan, MD, Fatih Oncu, MD, Suleyman Bakdik, MD, Mehmet Sedat Durmaz, MD, Ismet Tolu, MD

Objectives—The aim of this study was to compare the diagnostic performance of different sonographic modalities for diagnosing lateral epicondylosis.

Methods—A total of 50 symptomatic and 50 asymptomatic common extensor tendons in 44 patients with lateral epicondylosis, and 25 healthy participants were prospectively examined by B-mode sonography, color Doppler imaging, power Doppler imaging, Superb Microvascular Imaging (SMI; Toshiba Medical Systems Corporation, Tokyo, Japan), and strain elastography. We evaluated blood flow in common extensor tendons by using a grading system with color Doppler imaging, power Doppler imaging, and SMI. The diagnostic performance of the modalities was compared.

Results—When a cutoff value of hypoechogenicity was used for the mean strain ratio, the sensitivity, specificity, positive predictive value (PPV), negative predictive value (NPV), and accuracy rates were 92.0%, 94%.0, 93.9%, 92.2%, and 93.0%, respectively. When a cutoff point of grade 1 was used, the sensitivity, specificity, PPV, NPV, and accuracy rates were 26.0%, 10.0%, 10.0%, 57.5%, and 63.0, for color Doppler imaging; 40.0%, 10.0%, 10.0%, 62.5%, and 70.0% for power Doppler imaging; and 84.0%, 94.0%, 93.0%, 85.5%, and 89.0% for SMI. When a cutoff value of 3.94 was used for the mean strain ratio, the sensitivity, specificity, PPV, NPV, and accuracy rates were 78.0%, 92.0%, 90.7%, 80.7%, and 85.0%, respectively. A statistically significant correlation was detected between SMI, strain elastography, and visual analog scale scores ($P < .001$).

Conclusions—The combination of SMI and B-mode sonography was found to have excellent diagnostic performance for lateral epicondylosis. Neovascularzation in patients' tendons with lateral epicondylosis was identified much better with SMI compared to color or power Doppler imaging.

Key Words—Doppler; elastography; extremities; high-frequency imaging; lateral epicondylosis; musculoskeletal; sonography; Superb Microvascular Imaging

Received March 13, 2017, from the Department of Radiology, University of Health Sciences, Konya Training and Research Hospital, Konya, Turkey (S.A., F.O., M.S.D., I.T.); Department of Physical Therapy and Rehabilitation, Usak University School of Medicine, Usak, Turkey (A.Y.K.); and Department of Radiology, Necmettin Erbakan University School of Medicine, Konya, Turkey (S.B.). Manuscript accepted for publication May 30, 2017.

Address correspondence to Serdar Arslan, MD, Department of Radiology, University of Health Sciences, Konya Training and Research Hospital, Haci Saban Mah, Meram Yeniyol Caddesi 97, 42090 Meram, Konya, Turkey.

E-mail: arslanserdar10@gmail.com

Abbreviations

NPV, negative predictive value; PPV, positive predictive value; ROI, region of interest; SMI, Superb Microvascular Imaging; VAS, visual analog scale

doi:10.1002/jum.14369

Lateral epicondylosis is a disorder that usually causes lateral elbow pain and has an estimated prevalence between 1% and 3%.[1] The condition is diagnosed clinically on the basis of history and physical examination results.[2] Imaging modalities, such as sonography and magnetic resonance imaging, are also useful in confirming the diagnosis and excluding other causes with similar symptoms.[3,4] Studies revealed that the presence of neovessels and

© 2017 by the American Institute of Ultrasound in Medicine

accompanying nerves in areas of tendinopathy leads to increased tendon pain, and this neovascularity can be detected by vascular sonographic modalities, such as conventional Doppler sonography.[5,6]

Superb Microvascular Imaging (SMI; Toshiba Medical Systems Corporation, Tokyo, Japan) is a new vascular imaging technique used to detect subtle low-flow components. Blood flow and tissue motion, called clutter, produce ultrasonic Doppler signals.[7] Conventional Doppler sonographic techniques use a wall filter to remove clutter, causing loss of subtle low-flow components. However, SMI can differentiate flow signals from underlying clutter by using an adaptive algorithm.[8]

Strain elastography is another imaging technique based on sonography, providing information on the mechanical traits of tissues and reflecting their condition. Strain elastography is based on the principle that tissue compression produces strain within the tissue, and the strain is less in hard tissues than in soft ones.[9] Strain elastography can also be used to evaluate lateral epicondylosis.[10] The aim of this study was to compare the diagnostic performance of sonographic modalities used to diagnose lateral epicondylosis.

Materials and Methods

Participants

After the study was approved by the local Ethics Committee, informed oral and written consent was obtained from all patients and healthy volunteers. Between February and December 2016, we used B-mode sonography, color Doppler imaging, power Doppler imaging, SMI, and compression-based strain elastography to prospectively examine 50 common extensor tendons of 44 patients with a clinical diagnosis of lateral epicondylosis and in both elbows of 25 healthy participants. The patients had been referred to a physiatrist with 7 years of experience in shoulders and elbows. Among the 44 patients with lateral epicondylosis, 38 had unilateral epicondylosis, and 6 had bilateral epicondylosis. The inclusion criteria for lateral epicondylosis were local tenderness during palpation of the common extensor origin and pain with resisted wrist extension.[11] Subjective pain was recorded by using a visual analog scale (VAS; score, 0–100). The exclusion criteria were previous elbow surgery, fracture, or a history of systemic inflammatory ailments, such as rheumatoid arthritis. The healthy volunteers underwent clinical examinations to exclude the possibility of lateral epicondylosis. The inclusion criteria for the healthy participants were asymptomatic elbows, no previous trauma or surgery on elbows, and no history of systemic inflammatory disorders.

Imaging Analysis

All participants were examined by B-mode sonography, strain elastography, color Doppler imaging, power Doppler imaging (frame rate, 10–15 Hz), and SMI (frame rate $>$ 50 Hz) with a Toshiba Aplio 500 ultrasound system and a high-frequency (14-MHz) linear array transducer. Blinded to the findings of the clinical examination, 2 radiologists with 5 years of experience in musculoskeletal sonography performed the examinations separately.

All participants were examined while seated with both arms on the examination table and elbows in the semiflexion position. The transducer was placed in the longitudinal plane over the lateral epicondyle along the common extensor tendon. Scanning included the entire tendon origin from the anterior margin to the posterior margin.

B-mode sonography was used to assess whether swelling, a hypoechoic change, a tear, and calcifications were present in the common extensor tendon. Swelling was defined as an outward convexity of the tendon origin and compared to the contralateral side in cases of unilateral epicondylosis. A hypoechoic change was defined as the loss of the normal fibrillar pattern by focal areas of hypoechogenicity, and a tear was detected as an anechoic area with no fibers intact.

For abnormal findings on sonography, we used strain elastography by focusing on the areas. During the examination, the grayscale and elastographic images were monitored side by side on the screen. The force applied to the tendon was properly adjusted according to the compression and relaxation curves below the baseline on the elastographic screen, showing optimal strain at the area of interest. The elastographic scanning was sustained through several cycles of mild compression and relaxation. To obtain a still image for the diagnosis with a correct elastographic map, the process was reiterated until a stable image was obtained. Two regions of interest (ROIs) were selected for the strain ratio measurements. A circular sample was placed at the tendon origin to avoid violating the tendon margin superiorly and inferiorly and not to extend below the epicondyle for the target

area. Another circular sample was placed at the adjacent subcutis as a reference area. Strain ratios were then automatically calculated by the software (Figure 1C).

Then, color Doppler imaging, power Doppler imaging, and SMI were performed to evaluate intratendinous hyperemia in the origin of the common extensor tendon. Vascular blood flow images on color Doppler imaging, power Doppler imaging, and SMI were obtained by taking the same imaging area (Figure 2). The images were evaluated by 2 radiologists using a grading system. A 4-stage evaluation system was used for grading as follows:

Figure 1. Images from a 51-year-old woman with lateral epicondylosis. **A** and **B**, Monochromatic and color SMI images showing grade 3 vascular flow (arrows). **C**, Strain elastographic image showing wide heterogeneous soft tissue areas in the common extensor tendon. Two ROIs were selected on the elastographic image. The reference ROI is at the subcutis above the common extensor tendon, and the target ROI is at the tendon origin. The strain ratio was calculated to be 1.47.

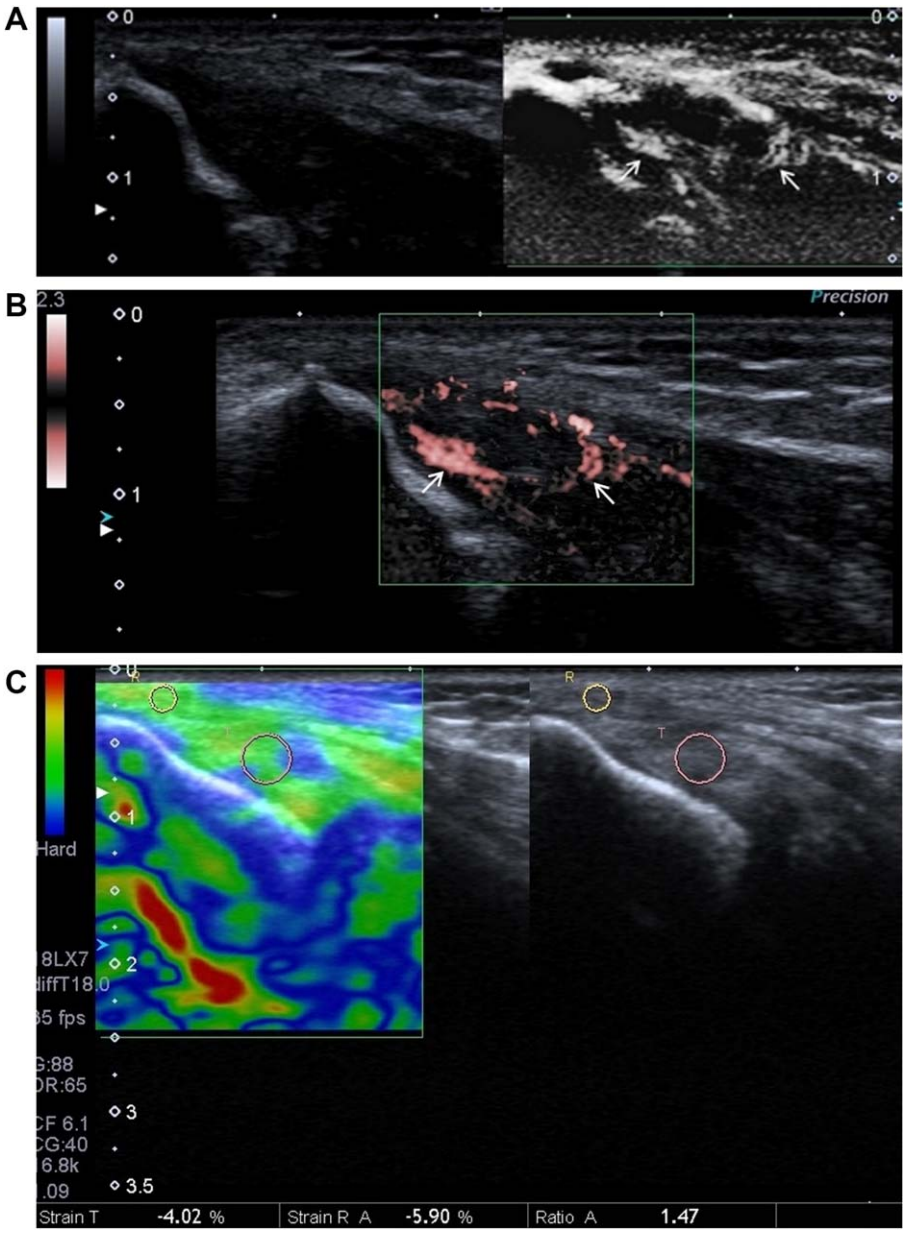

Figure 2. Images from a 43-year-old woman with lateral epicondylosis. **A** and **B**, Monochromatic and color SMI images showing grade 3 vascular flow (arrows). **C**, Power Doppler image showing no vascularity. Artifactual unreal color enhancements are shown. **D**, Color Doppler image showing no vascularity.

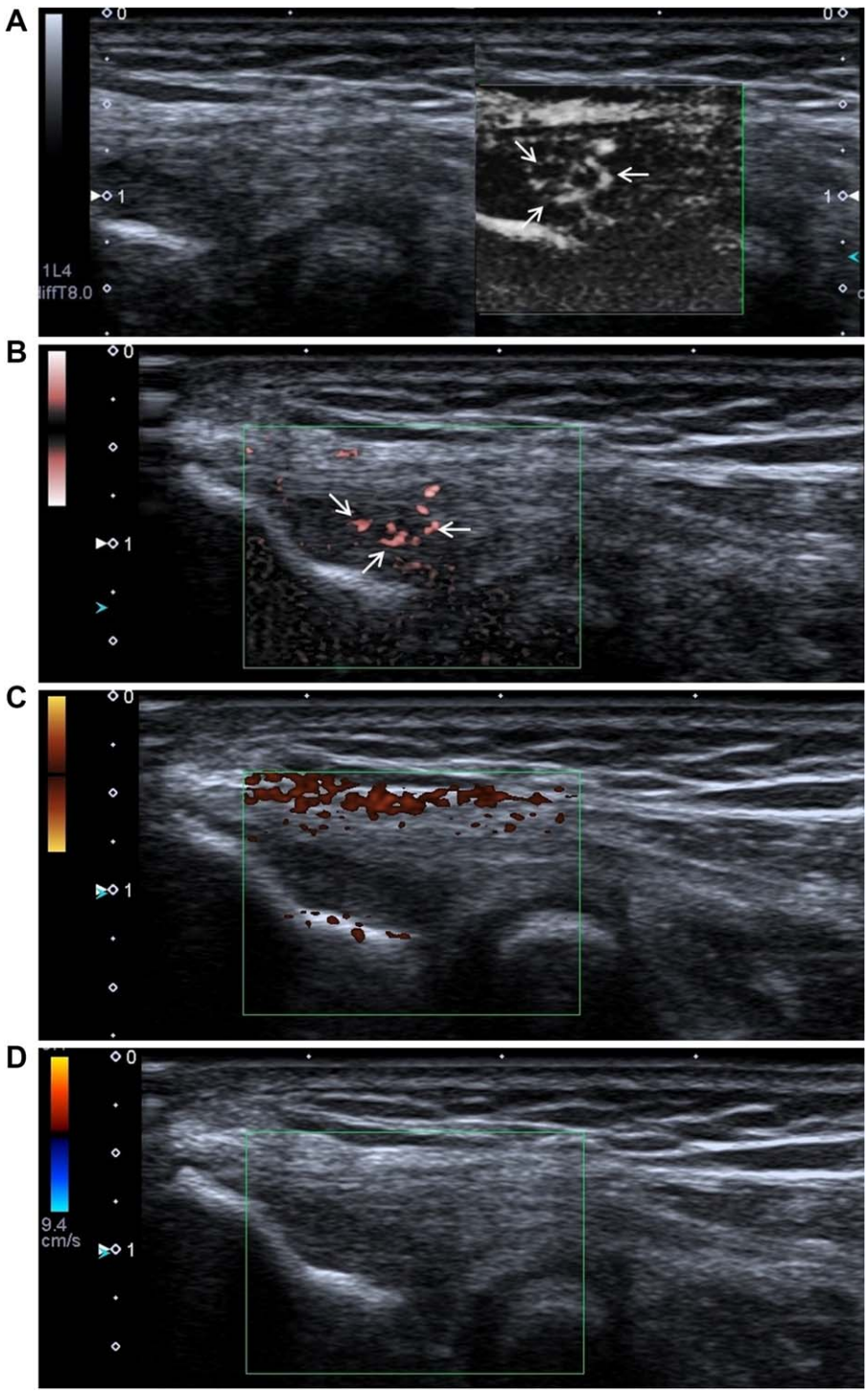

grade 0, no vascularity; grade 1, 1 or 2 color-encoded focal spots; grade 2, 1 linear or more than 2 color-encoded focal spots; and grade 3, more than 1 color-encoded linear spots. We used monochromatic SMI images that only revealed the vasculature by subtracting the background signals for analysis. According to this system of grading, those with grade 1, 2, or 3 flow were accepted as having positive results for lateral epicondylosis, and those with grade 0 were accepted as having negative results (Figure 1, A and B). In addition, reach the highest sensitivity, specificity, and accuracy rates for diagnosis of lateral epicondylosis, SMI and strain elastographic methods were combined with B-mode sonography.

Statistical Analyses

All statistical analyses were performed with SAS version 9.4 software (SAS Institute Inc, Cary, NC). Categorical variables were presented in terms of frequencies and percentages. A χ^2 tests was used to compare the categorical features of the healthy and diseased groups. Continuous variables were presented as means and standard deviations. An independent-sample t test or analysis of variance was used to compare differences between groups. A receiver operating characteristic curve analysis was performed to evaluate the predictive abilities of the strain ratio, SMI, color Doppler imaging, and power Doppler imaging. Area under the receiver operating characteristic curve values were calculated by using the optimal cutoff points. The sensitivity, specificity, positive predictive value (PPV), negative predictive value (NPV), and accuracy were calculated by using the cutoff points. The κ statistic or intraclass correlation coefficient was used to evaluate the inter-rater agreement for SMI, color Doppler imaging, power Doppler imaging, and the strain ratio. $P < .05$ was considered statistically significant.

Results

The 44 patients with a clinical diagnosis of lateral epicondylosis included 16 men and 28 women aged 24 to 66 years, and the 25 healthy participants included 11 men and 14 women aged 19 to 30 years. The mean duration of patients' symptoms was 20.5 ± 11.7 days (range, 3–48 days). The mean pain strength VAS score was 72.7 ± 15.7 (range, 39–97). In the healthy volunteers, no symptomatic common extensor tendon origin was seen. Table 1 shows the characteristics of the participants.

The most common findings for symptomatic tendons on B-mode sonography were intratendinous hypoechogenicity and swelling, followed by calcifications and tearing. The frequencies of tendon swelling, intratendinous hypoechogenicity, calcifications, and hyperemia were significantly different between symptomatic and asymptomatic tendons ($P < .001$). Intratendinous grade 1, 2, or 3 flow was detected in 42 (84%), 20 (40%), and 13 (26%) of SMI, power Doppler imaging, and color Doppler imaging cases in the symptomatic group, respectively. No grade 1, 2, or 3 flow was detected in any of the participants in the asymptomatic group as a result of power and color Doppler examinations, but grade 1 flow was detected only in 3 (6%) patients ($P < .001$).

The mean strain ratio was significantly lower in the symptomatic tendons (2.85 ± 1.99) than the asymptomatic tendons (7.41 ± 2.24; $P < .001$), indicating that the symptomatic tendons were softer. Table 2 shows the imaging findings. To obtain the highest sensitivity and specificity, the cutoff values for SMI, power Doppler imaging, and color Doppler imaging were determined to be grade 1; in this way, the sensitivity, specificity, PPV, NPV, and accuracy rates were calculated to be 84.0%, 94.0%, 93.0%, 85.5% and 89.0% for SMI and 40.0%, 10.0%, 10.0%, 62.5%, and 63.0% for color Doppler imaging, respectively. The cutoff value of the strain ratio between the symptomatic and asymptomatic tendons was 3.94. The area under the receiver operating characteristic curve or the strain ratio was 0.918, and the sensitivity, specificity, PPV, NPV, and accuracy rates were

Table 1. Basic Characteristics of Symptomatic and Asymptomatic Tendons

Characteristic	Symptomatic (n = 50)	Asymptomatic (n = 50)
Symptom duration, d	20.5 ± 11.7	NA
VAS score	72.7 ± 15.7	NA
Tendons by sex, n (%)		
Male	20 (40)	22 (44)
Female	30 (60)	28 (56)
Age, y	42.3 ± 9.5	24 ± 3.7
Tendons by side, n (%)		
Right	33 (66)	25 (50)
Left	17 (34)	25 (50)

Data are presented as mean ± SD where applicable. NA indicates not applicable.

calculated to be 78.0%, 92.0%, 90.7%, 80.7%, and 85.0%. The Doppler methods, strain elastography, and combined diagnostic performance are summarized in Table 3.

The mean strain ratio of each SMI subgroup (3–0) showed an inverse relationship with the sonographic score, and this relationship was found to be statistically significant ($P < .001$). There was no correlation between the duration of symptoms and the strain ratio. However, SMI was significantly correlated with the duration of symptoms ($P = .0023$). These data are summarized in Table 4. In addition, SMI was found to be significantly correlated with the VAS score ($P < .001$).

The inter-rater agreement rates were $\kappa = 0.71$ ($P < .001$) for SMI, $\kappa = 0.71$ ($P < .001$) for power Doppler imaging, $\kappa = 0.60$ ($P < .001$) for color Doppler imaging, and intraclass correlation coefficient = 0.58 ($P < .001$) for the strain ratio.

Discussion

Lateral epicondylosis is a common disorder of the elbow that causes pain and functional impairment.[12] Imaging is often necessary for evaluation of epicondylosis when there are refractory or confounding symptoms[4,12]; magnetic resonance imaging and sonography are the most widely used techniques. Sonography is a practical and noninvasive method. Additionally, the advent of high-frequency transducers has resulted in improved resolution, which enables application to soft tissues.[12] New modalities developed in the field of sonography in recent years have increased the effectiveness of sonography and widened the areas of use further. B-mode sonography and strain elastography are two screening techniques with high accuracy rates, and their reliability tested well. B-mode sonography is especially quite successful for determination of hypoechoic areas, tears, swelling, and calcifications in tendons with the help of high-frequency transducers.[3,4] However, conventional vascular sonographic modalities have yet to reach the desired accuracy rates in showing the development of neovascularization in tendons.[3] Superb Microvascular Imaging is a newly developed vascular sonographic screening modality that can show quite tiny capillaries and very low flow rates successfully. In this study, we

Table 2. Imaging Findings of Symptomatic and Asymptomatic Tendons

Finding	Symptomatic (n = 50)	Asymptomatic (n = 50)	*P*
Tendons on B-mode sonography, n (%)			
Swelling	44 (88)	0 (0)	<.001
Hypoechogenicity	46 (92)	3 (6)	<.001
Calcifications	8 (16)	4 (8)	.2184
Tear	4 (8)	0 (0)	.0587
Grade 1–3 flow-positive tendons, n (%)			
SMI	42 (84)	3 (6)	<.001
Power Doppler	20 (40)	0 (0)	<.001
Color Doppler	13 (26)	0 (0)	.0001
Strain ratio	2.85 ± 1.99	7.41 ± 2.24	<.001

Data are presented as mean ± SD where applicable.

Table 3. Diagnostic Performance of Sonographic Modalities and Their Combinations for Lateral Epicondylosis

Group	Cutoff	AUROC	SEN, %	SPE, %	PPV, %	NPV, %	ACC, %
Sonography	Hypoechogenicity	0.93	92.0	94.0	93.9	92.2	93.0
Strain elastography	3.94	0.91	78.0	92.0	90.7	80.7	85.0
SME	Grade 1	0.90	84.0	94.0	93.0	85.5	89.0
Power Doppler	Grade 1	0.70	40.0	10.0	10.0	62.5	70.0
Color Doppler	Grade 1	0.63	26.0	10.0	10.0	57.5	63.0
Sonography + strain elastography		0.94	92.0	96.0	95.8	92.3	94.0
Sonography + SMI		0.96	94.0	98.0	97.9	94.2	96.0
Sonography + SMI + strain elastography		0.96	94.0	98.0	97.9	94.2	96.0

ACC indicates accuracy; AUROC, area under the receiver operating characteristic curve; SEN, sensitivity; and SPE, specificity.

performed SMI and other sonographic modalities and aimed at obtaining the highest sensitivity, specificity, and accuracy rates by evaluating different sonographic tests for diagnosing lateral epicondylosis. Additionally, we also tried to show whether SMI was superior to power and color Doppler imaging for detecting the development of neovascularization in tendons.

Various studies showed that conventional sonography has yet to achieve the desired sensitivity and specificity rates for diagnosing lateral epicondylosis. In a study by Miller et al,[13] the sensitivity of sonography for detection of both lateral and medial epicondylosis was found to range from 64% to 82%, whereas that of magnetic resonance imaging ranged from 90% to 100%. Levin et al[4] found that the sensitivities of sonography for detection of symptomatic lateral epicondylosis ranged from 72% to 88%, whereas the specificities ranged from 36% to 48.5%. In this study, in which we used a high-frequency transducer, we obtained high accuracy rates for diagnosis of lateral epicondylosis by B-mode sonography. However, SMI, power Doppler imaging, color Doppler imaging, and the strain ratio were used individually to increase the sensitivity, specificity, and accuracy values for diagnosing lateral epicondylosis, as well as B-mode sonography. Of these techniques, power and color Doppler imaging failed to make a significant contribution to the diagnosis of lateral epicondylosis, consistent with findings reported in similar studies.[6,10,14]

Lateral epicondylosis is considered to be caused by recurrent mechanical overloading of the lateral elbow, reducing the ability of the tendons to repair themselves. Subsequently, this disorder leads to microscopic tears of the tendons and an abnormal reparative response.[3,15] Such changes developing in the common extensor tendon can now be detected with higher accuracy by using high-frequency transducers. In one study, Connell et al[3] found that the most common appearance of lateral epicondylosis was a focal hypoechoic area. In another study, Ahn et al[12] also revealed that the most common grayscale findings in lateral epicondylitis were hypoechogenicity (87 of 97) and swelling (86 of 97). In our study, hypoechogenicity (46 of 50) and swelling (44 of 50) were the most commonly detected findings on sonography, and there was a significant difference between symptomatic and asymptomatic tendons ($P < .001$).

Table 4. Association Between SMI Grades, Strain Ratio, and Symptom Duration

Parameter	Value	*P*
Strain ratio		<.001
Grade 0	6.88 ± 2.5	
Grade 1	4.49 ± 2.73	
Grade 2	2.04 ± 1.25	
Grade 3	1.53 ± 0.82	
Symptom duration, d		.0023
Grade 0	29.0 ± 14.2	
Grade 1	24.5 ± 10.5	
Grade 2	17.7 ± 9.5	
Grade 3	12.0 ± 7.9	

Data are presented as mean ± SD.

Histologic changes in lateral epicondylosis were described as angiofibroblastic proliferation, collagen fibrillar degeneration, and tissue necrosis with myxoid and hyaline degeneration not involving a histologic inflammatory process, and some previous studies failed to demonstrate neovascularization in the common extensor tendon.[3,16] Color Doppler imaging methods have several technical limitations in terms of visualizing subtle vessels and blood flow. Power Doppler imaging is based on the integrated Doppler power spectrum, which has lower angle dependence and higher sensitivity to low-velocity blood flow.[7] Connell et al[3] suggested that power Doppler imaging remained inefficient in showing vascularization in epicondylosis, and Zanetti et al[17] found a limited role of power Doppler imaging in the evaluation of tendon vascularization. To avoid these limitations, SMI was developed by using unique Doppler technologies, high-density beam former architecture, and a real-time application platform. The modality uses a special filtering technique to display the slow blood flow not depicted on conventional Doppler sonography, unless contrast agents are used.[18] Our study demonstrated the utility of SMI for evaluation of common extensor tendon neovascularization in lateral epicondylosis with high accuracy rates. Additionally, a significant correlation was found between SMI and the symptom duration in our study. We also found that SMI grading decreased as the condition progressed from the acute to the subacute phase. Accordingly, the increase in vascularization that occurred in the acute period of lateral epicondylosis was higher. In addition, by depending on increasing vascularization in the tendon, the VAS score also increased. From this point of view, we think that neovascularization is higher in periods when more pain is felt.

In strain elastography, a compressive force is applied to the surface of the tissue, leading to tissue

displacement and determined by comparing the echo signal sets acquired before and after the compression.[19] In a study conducted by using strain elastography in patients with lateral epicondylosis and healthy volunteers, Ahn et al[12] found that the mean strain ratios were 1.45 ± 0.45 for symptomatic tendons and 2.07 ± 0.70 for asymptomatic tendons. The mean strain ratio was significantly lower for the symptomatic tendons than the asymptomatic tendons. In another study conducted by De Zordo et al[10] in patients with lateral epicondylosis, strain elastography was used and gave sensitivity of 100%, specificity of 89%, and accuracy of 94%. In our study, the mean strain ratios were 2.85 ± 1.99 for symptomatic tendons and 7.41 ± 2.24 for asymptomatic tendons. There was a statistically significant difference between the groups ($P < .001$). We determined that the strain elastographic and SMI techniques had similar sensitivity and specificity rates for diagnosis of lateral epicondylosis and were obviously superior to color and power Doppler imaging. However, when we used B-mode sonography in combination with strain elastography, we obtained a significant increase in the sensitivity and accuracy rates, but we reached the highest sensitivity, specificity, and accuracy rates with the combined use of B-mode sonography and SMI. When strain elastography was combined with the B-mode sonographic and SMI methods, we observed no increase in diagnostic performance. Therefore, we concluded that the combined use of B-mode sonography and SMI is sufficient for achieving the highest diagnostic performance, and that strain elastography technique no additional contributions to those two.

In a study performed by Kocyigit et al,[1] strain elastographic and color Doppler techniques were reported to show similar findings in the common extensor tendon. In our study, we detected a significant correlation between SMI grading and the strain ratio. Accordingly, as the grade increased on SMI, the strain ratio was found to be statistically lower. Therefore, as tissue softness increases in patients with lateral epicondylosis, neovascularization in the tendon increases in a similar way.

The fact that strain elastography has an operator-dependent nature is one of its disadvantages. Different imaging planes may be obtained on the tendon by different operators, and the sizes and locations of the selected ROIs may also be inconsistent. As a result of these disadvantages, the value of interobserver κ correlations was lower in our study compared to other sonographic vascular modalities.

Our study had several limitations. First, the number of patients examined was relatively limited. In addition, patients with lateral epicondylosis in the chronic period were not included in the study. Therefore, the diagnostic performance of SMI in these patients could not be evaluated. Finally, another limitation was that our study was deprived of an intraobserver agreement evaluation.

In conclusion, the combination of SMI and B-mode sonography was found to have excellent diagnostic performance as easy and practical techniques for evaluation of the common extensor tendon in patients with lateral epicondylosis. Superb Microvascular Imaging was found to be much more sensitive than color and power Doppler imaging for detecting tendon abnormalities in lateral epicondylosis.

References

1. Kocyigit F, Kuyucu E, Kocyigit A, et al. Association of real-time sonoelastography findings with clinical parameters in lateral epicondylitis. *Rheumatol Int* 2016; 36:91–100.
2. Tosti R, Jennings J, Sewards JM. Lateral epicondylitis of the elbow. *Am J Med* 2013; 126:357.e1–357.e6.
3. Connell D, Burke F, Coombes P, et al. Sonographic examination of lateral epicondylitis. *AJR Am J Roentgenol* 2001; 176:777–782.
4. Levin D, Nazarian LN, Miller TT, et al. Lateral epicondylitis of the elbow: US findings. *Radiology* 2005; 237:230–234.
5. Alfredson H, Ohberg L, Forsgren S. Is vasculo-neural ingrowth the cause of pain in chronic Achilles tendinosis? An investigation using ultrasonography and colour Doppler, immunohistochemistry, and diagnostic injections. *Knee Surg Sports Traumatol Arthrosc* 2003; 11: 334–338.
6. du Toit C, Stieler M, Saunders R, Bisset L, Vicenzino B. Diagnostic accuracy of power Doppler ultrasound in patients with chronic tennis elbow. *Br J Sports Med* 2008; 42:872–876.
7. Zhan J, Diao XH, Jin JM, Chen L, Chen Y. Superb Microvascular Imaging—a new vascular detecting ultrasonographic technique for avascular breast masses: a preliminary study. *Eur J Radiol* 2016; 85: 915–921.
8. Lee YS, Kim MJ, Han SW, et al. Superb Microvascular Imaging for the detection of parenchymal perfusion in normal and undescended testes in young children. *Eur J Radiol* 2016; 85:649–656.
9. Ooi CC, Malliaras P, Schneider ME, Connell DA. "Soft, hard, or just right?" Applications and limitations of axial-strain sonoelastography and shear-wave elastography in the assessment of tendon injuries. *Skeletal Radiol* 2014; 43:1–12.

10. De Zordo T, Lill SR, Fink C, et al. Real-time sonoelastography of lateral epicondylitis: comparison of findings between patients and healthy volunteers. *AJR Am J Roentgenol* 2009; 193:180–185.
11. Kotnis NA, Chiavaras MM, Harish S. Lateral epicondylitis and beyond: imaging of lateral elbow pain with clinical-radiologic correlation. *Skeletal Radiol* 2012; 41:369–386.
12. Ahn KS, Kang CH, Hong SJ, Jeong WK. Ultrasound elastography of lateral epicondylosis: clinical feasibility of quantitative elastographic measurements. *AJR Am J Roentgenol* 2014; 202:1094–1099.
13. Miller TT, Shapiro MA, Schultz E, Kalish PE. Comparison of sonography and MRI for diagnosing epicondylitis. *J Clin Ultrasound* 2002; 30:193–202.
14. Obradov M, Anderson PG. Ultrasonographic findings for chronic lateral epicondylitis. *JBR-BTR* 2012; 95:66–70.
15. Nirschl RP, Pettrone FA. Tennis elbow: the surgical treatment of lateral epicondylitis. *J Bone Joint Surg Am* 1979; 61:832–839.
16. Regan W, Wold LE, Coonrad R, Morrey BF. Microscopic histopathology of chronic refractory lateral epicondylitis. *Am J Sports Med* 1992; 20:746–749.
17. Zanetti M, Metzdorf A, Kundert HP, et al. Achilles tendons: clinical relevance of neovascularization diagnosed with power Doppler US. *Radiology* 2003; 227:556–560.
18. Lee DH, Lee JY, Han JK. Superb Microvascular Imaging technology for ultrasound examinations: initial experiences for hepatic tumors. *Eur J Radiol* 2016; 85:2090–1095.
19. Li Y, Snedeker JG. Elastography: modality-specific approaches, clinical applications, and research horizons. *Skeletal Radiol* 2011; 40:389–397.