Indian Journal of Surgery
https://doi.org/10.1007/s12262-023-03880-3

SURGICAL TECHNIQUES AND INNOVATIONS

Rectus Sheath Block for Pain Management in Subxiphoid Single-Incision Thoracoscopic Surgery

İsmail Sarbay[1] · Havva Süheyla Akın Uzan[2] · Lale Yüceyar[2] · Akif Turna[1]

Received: 20 May 2022 / Accepted: 17 July 2023
© Association of Surgeons of India 2023

Abstract
Subxiphoid video-assisted thoracoscopic surgery (VATS) procedures have been shown to cause less postoperative pain compared to that caused by intercostal VATS. New approaches have been investigated to prevent surgery or chest tube pain. We performed a middle lobe wedge resection for a solitary pulmonary nodule via a uniportal subxiphoid VATS approach. An ultrasound-guided rectus sheath block (US-RSB) was performed after the procedure. The patient recovered well with a numeric pain score of 1/10 and was discharged on the postoperative first day without complications. There was no need for opioid agents perioperatively. This report is the first to use a rectus sheath block to prevent postoperative pain in subxiphoid VATS.

Keywords Rectus sheath block · Video-assisted thoracic surgery · Subxiphoid VATS · Pain management · Minimally invasive surgery

Case

A 63-year-old man diagnosed with non-Hodgkin lymphoma received three cycles of chemotherapy and 16 fractions of radiotherapy in 2016. A 1 cm pulmonary nodule was located in the middle lobe, disclosed on his follow-up computed tomography (Fig. 1). He had a cigarette smoking history for a short period and quit smoking 45 years ago. A positron emission tomography–computed tomography (PET-CT) showed progression in diameter and increased fluorodeoxyglucose (FDG) uptake with a standard uptake value (SUV) of 6.7 which was indicated as a possible malignancy. Due to the lesion's close location to the pericardium, needle biopsy was not considered safe. The decision was a diagnostic wedge resection. The patient's written consent was obtained prior to the surgery.

✉ İsmail Sarbay
issarbay@gmail.com

[1] Department of Thoracic Surgery, Istanbul University-Cerrahpasa Cerrahpasa Medical Faculty, Fatih, Istanbul, Turkey

[2] Department of Anesthesiology and Reanimation, Istanbul University Cerrahpasa Cerrahpasa Medical Faculty, Fatih, Istanbul, Turkey

Surgical Technique

Under general anesthesia with double-lumen intubation, the patient was positioned in a semi-supine position with his right side up approximately 30 degrees. A single 3cm subxiphoid incision was made on the midline. Careful dissection was done, sparing the rectus muscle and avoiding any breach of the diaphragm or confrontation with abdominal structures. The right pleural space was opened by blunt dissection. A wound protector was placed. A retractor was used to elevate the xiphoid process and expand the exposure (Fig. 2).

A 30-degree video-thoracoscope was inserted for visualization. The thoracoscopic instruments were advanced through the same incision. In exploration of the right lung, a 1 cm lesion was observed in the middle lob. An endoscopic stapling device was used for the wedge resection of the nodule. The material was removed via an endoscopic specimen retrieval bag. A 28F chest drain was placed through the same incision, and the wound was sutured (Fig. 2).

Pain Management and RSB

Analgesia was provided with intravenously administered 100 mg tramadol and 1 g of paracetamol throughout the surgery. After the surgical procedure, an

Published online: 22 July 2023

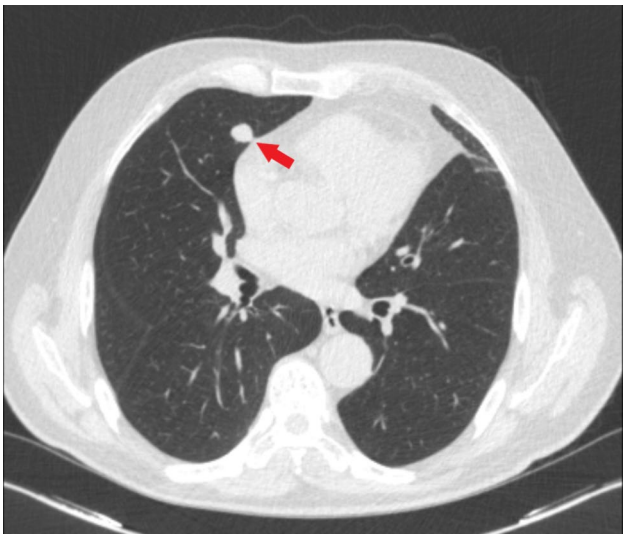

Fig. 1 The right-sided pulmonary nodule located close to pericardium was observed in this computed tomography section

ultrasound-guided rectus sheath block was performed. The rectus sheath was visualized via a linear ultrasound probe bilaterally, and a drug combination was injected into the upper first segment on each side using a 22G 100mm needle (Figs. 3, 4). The drug combination of 15 mL 0.5% bupivacaine together with 0.2 µg adrenaline and 1 mg dexamethasone. The patient was extubated in the operating room and transferred to the ward.

Postoperative Course

The patient managed to mobilize 2 h after recovery. He received 1 g of intravenous paracetamol at the sixth postoperative hour as a clinical routine. The maximal numeric pain score was 1/10 during the postoperative pain follow-up, and no other analgesia was needed.

A chest X-ray showed a re-expanded right lung. The chest drain was removed at the 18th hour, and the patient was discharged at the 21st hour of the operation with no complications. The pathology report suggested no malignancy. The patient described no pain on the incision site during the follow-ups.

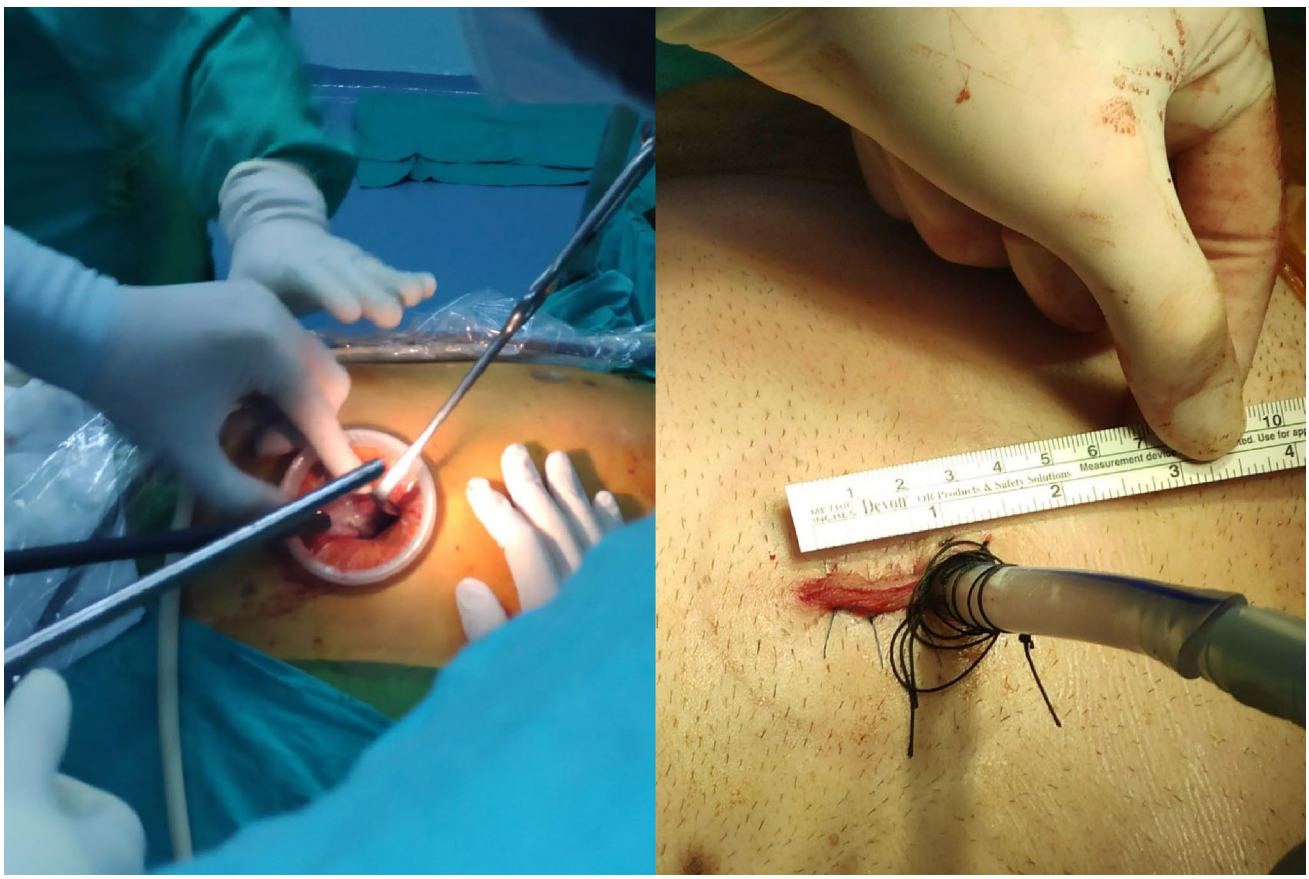

Fig. 2 The video-thoracoscopic operation was performed through a single 3cm subxiphoid incision

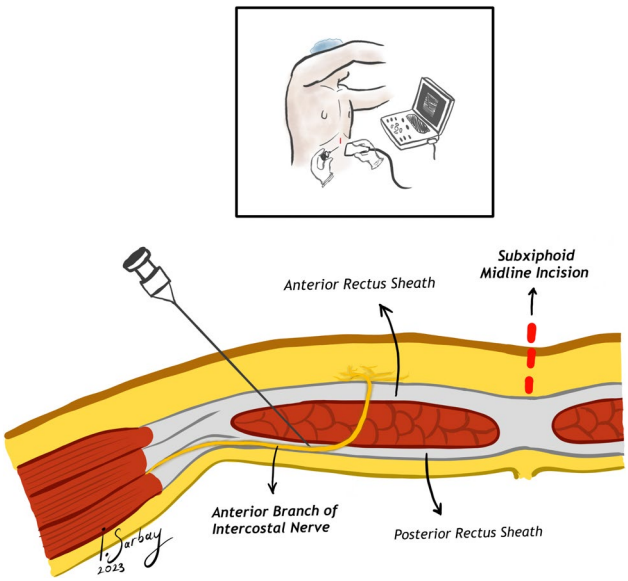

Fig. 3 The illustration of the anatomy and application of ultrasound-guided rectus sheath block

Discussion

The minimally invasive approach in thoracic surgery has expanded over the past few decades. Minimally invasive techniques benefit patient comfort, lower pain, and shorter hospital length of stay. A meta-analysis suggested that the subxiphoid approach causes less pain and a lower incidence of paresthesia than standard intercostal VATS [1].

An epidural anesthesia can be performed for better analgesia, and the serratus anterior plane and pectoral nerves can be blocked using an erector spinae plane block [2, 3]. US-RSB has been well known for postoperative pain relief after abdominal surgeries with different drug combinations [4]. US-RSB after cardiac surgery was found to reduce the pain related to sternotomy incision and subxiphoid placements of chest tubes [5]. Our intraoperative and postoperative pain management did not require opioid agents which is important to improve postoperative recovery [6]. No report was published on using US-RSB for pain management after subxiphoid or any VATS procedures.

In conclusion, subxiphoid single-incision video-thoracoscopic pulmonary resections are safe and feasible.

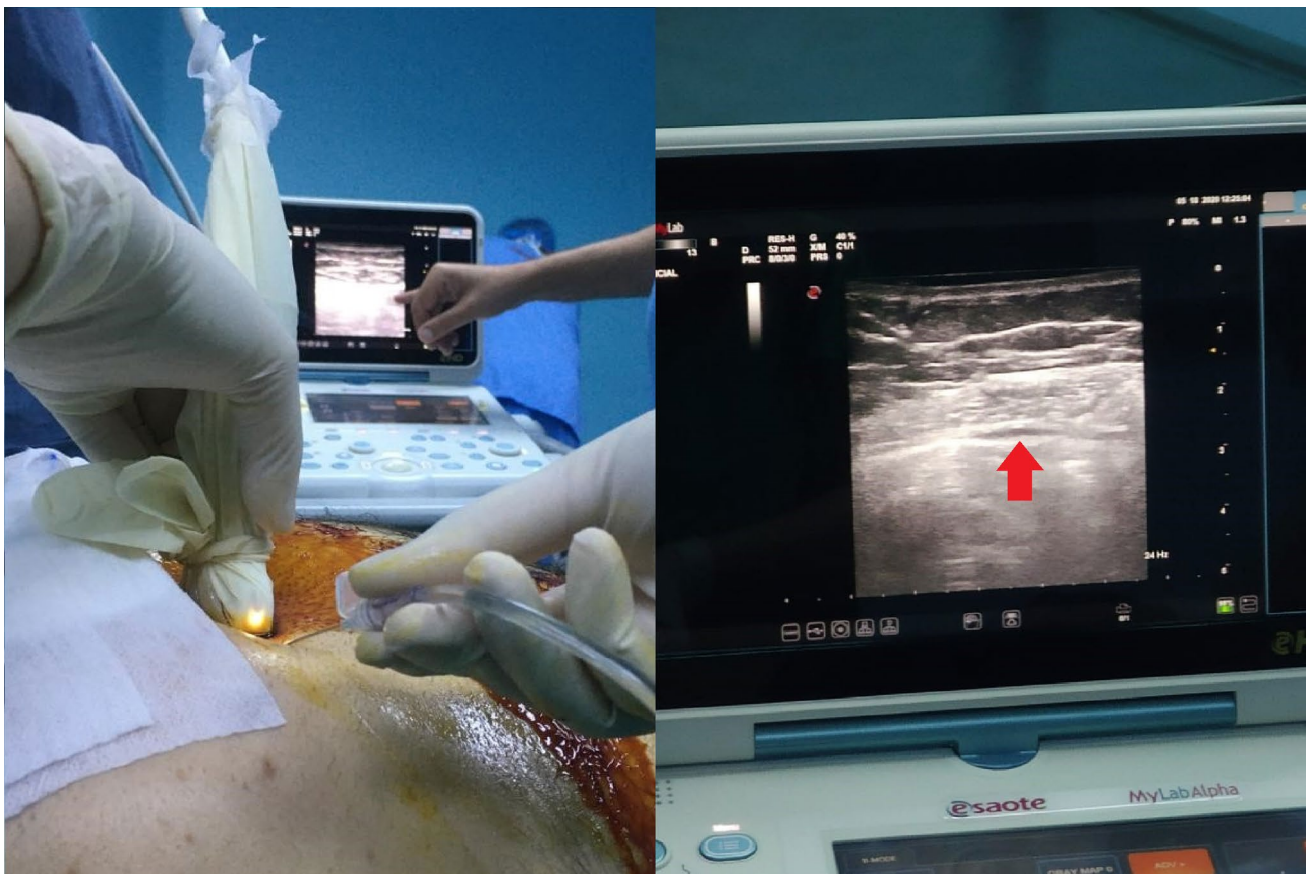

Fig. 4 The application of ultrasound-guided rectus sheath block by the anesthesiologists. Red arrow indicates the administered fluid within the posterior rectus sheath

Although reports suggested that the subxiphoid approach was associated with lower pain, patients may benefit from additional measures by receiving US-RSB to reduce the pain and hospital stay, accomplishing the fast-track protocols. Our patient described minimal pain and could be discharged within 24 h after the procedure. There is a need for further studies and randomized controlled trials to compare other pain management procedures better to understand the advantage of US-RSB for subxiphoid thoracic surgeries.

Declarations

Conflict of Interest The authors declare no competing interests.

References

1. Mei L-X, Wang Y-Y, Chen Y et al (2020) Subxiphoid versus intercostal video-assisted thoracic surgery for lung resection: a meta-analysis. Minim Invasive Ther Allied Technol 31:359–369
2. Jack JM, McLellan E, Versyck B et al (2020) The role of serratus anterior plane and pectoral nerves blocks in cardiac surgery, thoracic surgery and trauma: a qualitative systematic review. Anaesthesia 75:1372–1385
3. Shim J-G, Ryu K-H, Kim PO et al (2020) Evaluation of ultrasound-guided erector spinae plane block for postoperative management of video-assisted thoracoscopic surgery: a prospective, randomized, controlled clinical trial. J Thorac Dis 12:4174–4182
4. Wilkinson KM, Krige A, Brearley SG et al (2014) Thoracic epidural analgesia versus rectus sheath catheters for open midline incisions in major abdominal surgery within an enhanced recovery programme (TERSC): study protocol for a randomised controlled trial. Trials 15:400
5. Sepolvere G, Tedesco M, Fusco P et al (2020) Subxiphoid cardiac drainage pain management: could ultrasound rectus sheath block be the answer? Minerva Anestesiol 86:994–996
6. Qiu Y, Lu X, Liu Y, Chen X, Wu J (2022) Efficacy of the intraoperative opioid-sparing anesthesia on quality of patients' recovery in video-assisted thoracoscopic surgery: a randomized trial. J Thorac Dis 14(7):2544–2555

Publisher's Note Springer Nature remains neutral with regard to jurisdictional claims in published maps and institutional affiliations.

Springer Nature or its licensor (e.g. a society or other partner) holds exclusive rights to this article under a publishing agreement with the author(s) or other rightsholder(s); author self-archiving of the accepted manuscript version of this article is solely governed by the terms of such publishing agreement and applicable law.