Superb Microvascular Imaging of the Median Nerve in Carpal Tunnel Syndrome

An Electrodiagnostic and Ultrasonographic Study

Ali Yavuz Karahan, MD, Serdar Arslan, MD, Banu Ordahan, MD, Suleyman Bakdik, MD, Timur Ekiz, MD

Objective—To evaluate intraneural blood flow of the median nerve using superb microvascular imaging (SMI) and power Doppler ultrasonography (PDUS), and to examine their correlation with electroneuromyography in patients with carpal tunnel syndrome (CTS).

Methods—A cross-sectional survey was used, and the study was conducted in the research unit of a training and research hospital. Patients diagnosed with CTS according to electroneuromyography studies were included in the study. Ultrasound measurements were taken using an Aplio-500 (Toshiba Medical System Corporation, Tokyo, Japan) device and a linear multifrequency 14-MHz probe. The cross-sectional area of the median nerve at the carpal tunnel level was measured by the direct tracing method using electronic calipers. The power Doppler ultrasonography and superb microvascular imaging scores were recorded by grading the vascularity between 0 and 3.

Results—Evaluation was made of a total of 113 hands of 80 patients (18 men, 62 women) with a mean age of 34.67 ± 12.82 years. The mean duration of symptoms was 12.34 ± 6.66 months. When the patients were grouped as mild, moderate, and severe CTS, there was a statistically significant difference between the SMI and PDUS grades ($P < .05$). As the severity of CTS increased, an increase in SMI and PDUS scores was observed. There was a strong correlation between SMI scores and motor distal latency ($r = .71/P = .026$), amplitude of sensory action potential ($r = -.77/P = .029$), and sensory neurotransmission rate ($r = .77/P = .029$).

Conclusion—SMI seems to be more sensitive than PDUS for evaluating the vascularity of the median nerve in patients with CTS, and SMI grading is correlated with the ENMG results.

Key Words—entrapment neuropathy; musculoskeletal ultrasound; peripheral nerve; superb microvascular imaging; ultrasonography

Received January 22, 2018, from the Department of Physical and Rehabilitation Medicine, Medical Faculty of Usak University, Usak, Turkey (A.Y.K.); Department of Radiology (S.A., S.B.) and Department of Physical and Rehabilitation Medicine (B.O.), Konya Training and Research Hospital, Konya, Turkey; and Department of Physical and Rehabilitation Medicine, Dermancan Medical Center, Adana, Turkey (T.E.). Manuscript accepted for publication February 26, 2018.

Address correspondence to Ali Yavuz Karahan, MD, Kemalözmah. Dördüncüyöre sk. Akasya SitesiNo:8 Uşak/Turkey.

E-mail: ayk222@hotmail.com

Abbreviations

CDUS, color Doppler ultrasonography; CSA, cross-sectional area; CTS, carpal tunnel syndrome; ENMG, electroneuromyography; MN, median nerve; PDUS, power Doppler ultrasonography; SMI, superb microvascular imaging

doi:10.1002/jum.14645

Sonography is a well-established imaging modality for visualizing the peripheral nerves because of several advantages, such as being cost-effective, portable, readily available, well-tolerated, and patient friendly; it provides guidance for interventions, has high spatial resolution, and is noninvasive.[1] In this context, sonography is widely preferred for the examination of carpal tunnel syndrome (CTS). The median nerve (MN) can be imaged throughout with sonography, and it provides not only morphologic features but also

ascertains the underlying/triggering causes such as structural changes, anatomic variations, ganglion cysts, or tumors in the case of entrapment.[1–4] Interventional procedures can also be administered under ultrasound guidance. Sono-Tinel or sonopalpation techniques, that is, placing the probe on the location indicated by the patient as the painful area, make sonography the most sensitive and specific imaging modality for entrapment neuropathies.[1,2] Distal flattening and enlargement of the nerve just proximal to the flexor retinaculum is the typical imaging of CTS. Enlargement of the MN is very sensitive and specific in the diagnosis of CTS, although different cutoff values for the cross-sectional area (CSA) have been reported.[1] The CSA of the MN is substantially greater in patients with CTS, and it shows a considerable correlation with electrodiagnostic findings (eg, sensory nerve conduction velocity and distal motor latency).

Because sonography enhances the diagnostic accuracy by the detection of the epineural or intraneuronal blood flow, 3 different techniques of Doppler sonography (color, power, and spectral Doppler techniques) are currently preferred for the diagnosis of CTS.[5–8] Power Doppler ultrasonography (PDUS) in CTS has been previously studied and shown to be valid and reliable for grading the intraneural flow.[7,8] However, superb microvascular imaging (SMI) represents a new era in diagnostic sonography, and this new technology enables accurate visualization of vascular structures with intensive clutter suppression to provide flow signals for large to small vessels, and it presents these data at high frame rates.[9–11] The 2 SMI modes, color SMI and monochrome SMI, allow visualization of lower-velocity blood flows and smaller vessels without the use of contrast medium.[9–11] To the best of our knowledge, there is only one study that has evaluated the use of SMI in the diagnosis of CTS. Chen et al[11] compared the value of SMI with color Doppler ultrasonography (CDUS) and PDUS and reported that SMI is more sensitive in demonstrating blood flow in the diagnosis of CTS compared with CDUS and PDUS.

Therefore, the objective of this study was to evaluate intraneural blood flow of the MN using SMI and PDUS, and to examine their correlation with electroneuromyography (ENMG) findings in patients with CTS.

Materials and Methods

Study Design and Participants

This study was conducted in the departments of physical and rehabilitation medicine and radiology of Konya Training and Research Hospital between June 2016 and December 2016. The study was approved by the Local Research Ethics Committee (the Ethics Committee of the University of Selcuk, approval number 276/2016) and registered (ClinicalTrials.gov Identifier: NCT03213847). Participants were given a clear description of the purpose of the research and the testing procedures during the initial contact. Written informed consent was obtained from all patients before enrollment in the study.

The study included 80 consecutive patients, aged 18 to 45 years, diagnosed with CTS. All patients had a history of paralysis, pain, and/or vasomotor symptoms, with symptoms in the MN distribution, symptoms ongoing for longer than 6 weeks, and a positive response to Phalen, Tinel, or inverse Phalen tests. The American Academy of Neurology diagnostic criteria for CTS, which include history, clinical symptoms, and evidence of slowing in MN conduction, were used for the diagnosis of CTS.[12] Patients were excluded if they had any of the predisposing factors for CTS such as trauma, diabetes mellitus, pregnancy, neurologic or rheumatic diseases, or hypothyroidism. Patients with polyneuropathy, cervical radiculopathy, or proximal median or ulnar neuropathy were also excluded. Clinical and demographic features, including age, weight, height, body mass index, sex, occupation, medication history, and hand dominance, were registered.

Electrodiagnostic Testing

Nerve conduction studies were performed using an ENMG device (Nihon Kohden Neuropak M1-MEB-9200; Nihon Kohden Corporation, Tokyo, Japan). The room and hand temperature was standardized for each study participant. For the sensory conduction study of the MN, active electrodes were placed on the proximal phalanx of the first to fourth digits, and the reference electrodes were fixed 4 cm distal to each active electrode. Stimulation was applied at 10 cm proximal for the first digit and 14 cm proximal for the other digits. For every evaluated sensory nerve action potential, the onset latency, peak latency, baseline to peak amplitude, and conduction velocity were measured. An active electrode was fixed at the middle portion of the abductor pollicis brevis muscle for the motor conduction study of the MN. Stimulation was applied at the wrist level 8 cm proximal from the active electrode. Onset latency, amplitude, and conduction velocity were obtained. The ulnar

sensory nerve action potential was measured to exclude any possible disorders.

The patients were subdivided into 3 groups according to the severity of CTS according to the Stevens classification as follows: early or mild (abnormal median sensory studies, peak latency $\geq$3.5 ms), moderate (prolonged median distal motor latency, abnormal median sensory studies, peak latency $\geq$4.5 ms), or severe (absence of median sensory or motor response and/or low amplitude or other evidence of axonal loss, such as positive fibrillations).

Ultrasound Examinations

Sonographic examinations were conducted by 2 radiologists experienced in musculoskeletal sonography. Both sonographers were unaware of the ENMG results. The sonographers used an ultrasound device (Aplio 500; Toshiba Medical System Corporation, Tokyo, Japan) with a multifrequency linear-array transducer (14 Hz). All participants were examined in the sitting position with both hands in a horizontal supine position on the examination table with the fingers semiflexed. A frequency of 14.0 MHz was used for the B-mode sonography. Gray scale sonography was used for transverse imaging of the MN. The CSA of the MN was determined at the carpal tunnel level. On the axial view of the MN, the inner hyperechoic rim was determined by tracing a continuous line, and the CSA was measured using electronic calipers. The largest CSA of the MN between the carpal tunnel inlet and outlet was recorded. Vascular blood flow images of the MN were obtained from longitudinal images, using PDUS and monochrome SMI at the same level where the CSA measurements were taken. All participants were examined by power Doppler imaging (the scale was set at 5 cm/s, the mechanical index at 1.5, the wall filter at 50–100 Hz, and the frame rate at 10–25 frames/s), and SMI (the scale was set at 1.5–2.5 cm/s, the mechanical index at 1.5, the wall filter at 50–100 Hz, and the frame rate at >50 Hz.). Flow gain was increased until noise emerged. When microvessels were detected in SMI, the imaging mode was switched to Doppler imaging to determine whether PDUS could detect these microvessels. Without extra pressure, the depth of imaging was set at 3 cm and the position of focus point was adjusted to the nerve depth, and pulse repetition frequency was placed at 470 to

Figure 1. Ultrasound grading of the median nerve. **A**, Grade 0, no vascularity in the median nerve. **B**, Grade 1, one or 2 focal color-encoded spots in the median nerve (white arrow). **C**, Grade 2, one linear color-encoded line, and more than 2 focal color-encoded spots in the median nerve (white arrows). **D**, Grade 3, more than one linear color-encoded line in the median nerve (white arrows).

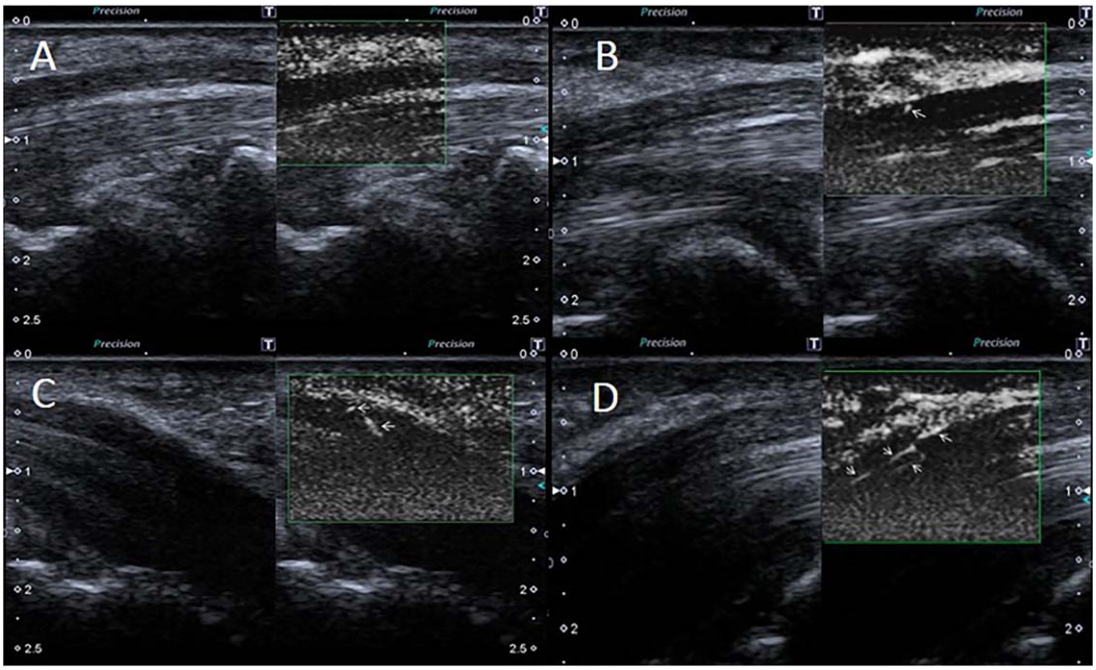

480 Hz in PDUS mode and 190 Hz in SMI mode. A 4-stage classification system was used for grading these images (for both monochrome SMI and PDUS modes) as follows: grade 0 (no vascularity in MN); grade 1 (1 or 2 focal color-encoded spots in the MN); grade 2 (1 linear color-encoded line or >2 focal color-encoded spots in the MN); or grade 3 (>1 linear color-encoded line in the MN (Figure 1).

Statistical Analysis

Commercially available software (SPSS version 16; SPSS Inc., Chicago, IL) was used for the statistical analyses. Data were expressed as mean ± standard deviation or number (n) and percentage. The χ^2 test was applied in the comparison of categorical variables. One-way analysis of variance was used to determine whether there were any substantial differences between the means of the groups. Correlations between clinical parameters, ENMG, Doppler, and SMI findings were analyzed using Pearson correlation coefficients. A value of $P < .05$ was defined as statistically significant.

Results

In this study, analysis was made of 113 wrists of 80 patients (18 men, 62 women) with a mean age of 34.6 years (range, 18–45 years). Both wrists were studied in 33 patients. The clinical characteristics of the patients are summarized in Table 1.

The comparison of the ENMG findings and CSA measurements according to the severity of CTS is shown in Table 2. A substantial difference was observed between the groups in terms of motor distal latency, sensory distal latency, sensory nerve action potential, sensory nerve velocity, and compound motor action potential values (all $P < .05$). No substantial difference was observed between the groups in respect of the CSA measurements ($P = .864$).

The power Doppler and SMI gradings according to the severity of CTS are shown in Table 3 and Figure 2. There was a substantial difference between the groups ($P < .05$). CSA and PDUS values had a mild to moderate correlation with the ENMG parameters, but not of a statistically significant level ($P > .05$). The SMI values showed a strong correlation with motor nerve distal latency ($r = .71$, $P = .026$), sensory nerve action potential amplitude ($r = -.77$, $P = .029$), and sensory nerve velocity ($r = .77$, $P = .029$) (Table 4).

Table 1. Clinical Features of Patients With Carpal Tunnel Syndrome

Age, y	34.67 ± 12.82
Duration of symptoms (months)	12.34 ± 6.66
Female/Male (n)	62/18
Laterality (n)	
Unilateral	
Right	21
Left	26
Bilateral	33
BMI (kg/m^2)	29.19 ± 7.45
CSA of MN (mm^2)	13.54 ± 2.69

The data are shown as the mean and standard deviation or n.
BMI, body mass index; CSA, cross-sectional area; MN, median nerve.

Discussion

In this study, we aimed to evaluate the intraneural blood flow of the MN using SMI and PDUS and to examine their correlation with ENMG findings. The study revealed 2 main findings. First, SMI is more sensitive for quantifying intraneural blood compared with PDUS. Second, although the SMI findings were strongly correlated with the ENMG findings, there was no substantial correlation with the PDUS findings.

The diagnosis of CTS relies on nerve conduction studies, and ENMG has traditionally been used as the gold-standard tool for evaluating CTS.[5] Although ENMG provides electrophysiologic features and indirect localization of the entrapment side, it cannot uncover the underlying pathology and morphologic view. In addition, ENG has some technical difficulties during the evaluation, such as surfacing the electrodes and inserting

Table 2. Electrophysiologic Parameters and Cross-Sectional Area of the Median Nerve

Median nerve	Mild CTS	Moderate CTS	Severe CTS	*P*
MDL	3.7 ± 0.89	4.6 ± 0.68	5.7 ± 0.96	.001[a]
CMAP	17.8 ± 2.90	10.3 ± 3.50	3.6 ± 2.85	.001[a]
SDL	2.4 ± 1.07	3.5 ± 0.81	—	.024[a]
SNAP	24 ± 15.53	17 ± 15.53	—	.019[a]
SNV	35 ± 5.53	29.1 ± 6.29	—	.026[a]
CSA (mm^2)	13.24 ± 2.46	13.76 ± 2.96	13.64 ± 3.09	.864

The data are shown as the mean and standard deviation.
[a]$P < .05$ statically significant differences obtained between mild, moderate, and severe CTS groups.
CMAP, compound muscle action potential; CSA, cross-sectional area; CTS, carpal tunnel syndrome; MDL, motor nerve distal latency; SD, standard deviation; SDL, sensory nerve distal latency; SNAP, sensory nerve action potential; SNV, sensory nerve velocity.

the needle.[13] In this context, since the 1990s, the American Academy of Neurology has recommended ultrasound examination of the MN for the diagnosis of CTS.[14] Ultrasound evaluation easily provides a morphologic view, can reveal the underlying pathology (anatomic variations, schwannoma/fibrolipomatous hamartoma), and be a guide for injections.[3,4,13] Cross-sectional and longitudinal views of the MN nerve in the forearm, wrist, and palm in classical gray scale ultrasound examination give important information about local anatomic structures.[1,2,13] Any entrapment of the MN in the carpal tunnel, such as compression of the transverse carpal ligament, is easily detectable. Furthermore, an irregular shape and vague border of the MN would be associated with CTS.[1,2] However, distal flattening and enlargement of the nerve just proximal to the entrapment side is the classical sonography finding of CTS.[14,15] This enlargement is seen due to increased pressure arising from venous congestion and the limited axoplasmic flow in the compressed nerve. Whereas some studies have highlighted the threshold measurements of CSA for the diagnostic accuracy of CTS, others have suggested that sonography could be used only complementary to ENMG, but not alone.[5,15] The correlation between CSA and ENMG results has been studied, and results of these have also been conflicting. Bayrak et al[16] emphasized that there was a negative correlation between increasing CSA of the MN and a decreasing number of motor units in the abductor pollicis brevis muscles. Kwon et al[17] used 3-dimensional sonography to determine the CSA, and reported a low correlation between the CSA and the compound muscle action potential amplitude ($r = -.323$, $P < .01$) or the sensory nerve action potential amplitude of the MN ($r = .335$, $P < .01$). The findings in the patients with CTS in the current study did not indicate any correlation between the severity of CTS and either power Doppler or SMI scores ($P > .05$). This observation is consistent with the results reported by Moran et al.[18] and Mohammadi et al.[19] This fact could be attributed to the lack of a control group comprising healthy subjects. In the current study, the mean CSA measurement was approximately 13 mm^2 and higher than the thresholds previously defined. If this study had included a control group, the CSA measurements of the healthy subjects might have differed from those of the patients with CTS.

The superiority of Doppler sonographic examination lies in its ability to scan the blood flow signal. The density of the microvessels increases because of enhanced proliferation of Schwann cells. Vascular endothelial growth factor is responsible for regeneration of the entrapped MN.[8,20] The diagnostic value of the Doppler sonographic technique in CTS has been studied previously, but the results of those studies have not been consistent. Ghasemi-Esfe et al[21] and Joy et al[20] reported that the intraneural vascularity seen with CDUS had higher sensitivity values when compared with the CSA of the MN. However, Dejaco et al[22]

Figure 2. Correlation of power Doppler and superb microvascular imaging values with mild, moderate, and severe carpal tunnel syndrome. PD, Power Doppler; SMI, superb microvascular imaging.

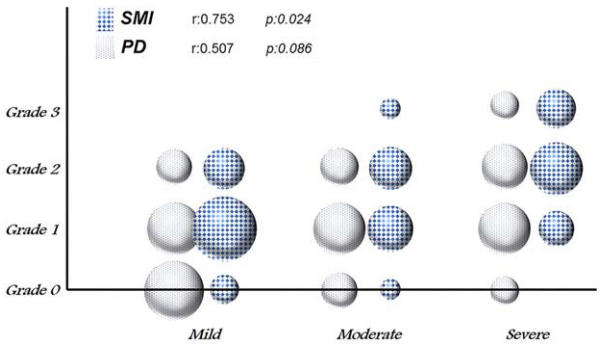

Table 3. Compression of Superb Microvacular Imaging and Power Doppler Ultrasonography Values According to Severity of Carpal Tunnel Syndrome

	SMI					PDUS			
	Grade 0	Grade 1	Grade 2	Grade 3	SMI and PDUS, *P*	Grade 0	Grade 1	Grade 2	Grade 3
Mild CTS (n = 45)	5	29	11	0	.003[a]	21	17	7	0
Moderate CTS (n = 31)	3	14	12	2	.003[a]	7	16	8	0
Severe CTS (n = 37)	0	8	19	10	.001[a]	5	16	12	4

[a]P < .05 statistically significant differences obtained between SMI and Doppler sonography values.
CTS, carpal tunnel syndrome; PDUS, power Doppler ultrasound; SMI, superb microvascular imaging.

concluded that CSA of the MN had high diagnostic value and excellent reliability with both sensitivity and specificity of 92%, but the Doppler sensitivity (47.4%) was lower.[22] PDUS is considered to be more sensitive than CDUS for displaying blood flow signals within any tissue, and researchers using PDUS to diagnose CTS have reported lower sensitivity than that reported by researchers using CDUS.[4,13–15] Mohammadi et al[19] and Kutlar et al[8] found a substantial correlation between hypervascularization of the MN and the severity of CTS and reported that the severity of CTS correlated with CDUS. According to the current study results, the PDUS grading had a correlation with the motor nerve distal latency and sensory nerve velocity of the MN ($r = .548$ and $r = -.498$, respectively), but the correlation of the PDUS grading and the severity of CTS was not statistically significant ($r = .507$, $P = .086$).

To the best of our knowledge, there has been only 1 clinical study of SMI technology in patients with CTS. Chen et al[11] compared the SMI value in patients with CTS with that of CDUS and PDUS. It was reported that the blood flow display ratio for SMI in patients with CTS was substantially higher than that of CDUS and PDUS. SMI technology was developed by Toshiba, and it is available as the Toshiba premium ultrasound system Aplio 500. This technique is an innovative vascular imaging method that can visualize lower-velocity blood flows and smaller vessels without the use of contrast medium.[9,23] The ability of SMI to sweep at high frame rates is important, and when compared with conventional CDUS and PDUS, the detail of the microvessels that can be visualized with this new technology appears to be considerably better. This technique is expected to be of great value for early diagnosis and treatment planning in different diseases, such as cancer; rheumatoid arthritis; and liver, thyroid, and testicular diseases.[9–11] According to the results of the current study, the vascular blood flow images obtained from the MN using monochrome SMI correlated substantially with the severity of CTS. There was a particularly high correlation between the SMI and the distal motor latency of the MN. In addition, there was a considerable correlation between the SMI and the CSA of the MN.

Table 4. The Correlation of Cross-Sectional Area, Power Doppler Ultrasonography and Superb Microvascular Imaging With the Nerve Conduction Studies

n nerve	CSA	PDUS	SMI
MDL			
Pearson correlation	0.457	0.548	0.711
Sig.(2-tailed)	0.184	0.066	0.026[a]
CMAP			
Pearson correlation	−0.493	−0.488	−0.642
Sig.(2-tailed)	0.093	0.109	0.864
SDL			
Pearson correlation	0.475	0.462	0.621
Sig.(2-tailed)	0.112	0.187	0.749
SNAP			
Pearson correlation	−0.414	−0.477	−0.780
Sig.(2-tailed)	0.201	0.256	0.022[a]
SNV			
Pearson correlation	−0.481	−0.498	−0.773
Sig.(2-tailed)	0.354	0.357	0.029[a]
CSA			
Pearson correlation	1	0.557	0.521
Sig.(2-tailed)	.	0.123	0.986

[a] $P < .05$ statistically significant differences obtained in correlation analyses.

CSA, cross-sectional area; CMAP, compound muscle action potential; MDL, motor nerve distal latency; SD, standard deviation; SDL, sensory nerve distal latency; SNAP, sensory nerve action potential; SNV, sensory nerve velocity.

There were some important drawbacks to this study. The lack of a control group is the main limitation. Second, 2 radiologists performed the measurements and provided a common decision, but interobserver reliability was not assessed. Finally, the SMI is a new vascular imaging technique used to detect subtle low-flow components (Toshiba Medical Systems Corporation, Tokyo, Japan). Therefore a brand-dependent mode of sonography was used in this study.

Conclusion

In the light of these results, SMI seems to be more sensitive for the diagnosis of CTS compared with PDUS, and the SMI results were strongly correlated with the ENMG findings. These results indicate that SMI is a useful imaging tool for evaluating the severity of CTS. There is a need for further imaging studies using SMI technology to assess the relationship between increased blood flow of the nerves in other entrapment syndromes.

References

1. Özçakar L, Kara M, Chang KV, et al. Nineteen reasons why physiatrists should do musculoskeletal ultrasound: EURO-MUSCULUS/USPRM recommendations. *Am J Phys Med Rehabil* 2015; 94:45–94.

2. Kara M, Özçakar L, De Muynck M, Tok F, Vanderstraeten G. Musculoskeletal ultrasound for peripheral nerve lesions. *Eur J Phys Rehabil Med* 2012; 48:665–674; quiz 708.
3. Ekiz T, Onat ŞŞ, Yalçin S, Atik Ç, Özçakar L. Ultrasound imaging of persistent median artery and veins in an asymptomatic patient with a bifid median nerve. *Am J Phys Med Rehabil* 2016;95:e127–e128.
4. Kara M, Ozçakar L, Ekiz T, Yalçın E, Tiftik T, Akyüz M. Fibrolipomatous hamartoma of the median nerve: comparison of magnetic resonance imaging and ultrasound. *PM R* 2013; 5:805–806.
5. Vanderschueren GA, Meys VE, Beekman R. Doppler sonography for the diagnosis of carpal tunnel syndrome: a critical review. *Muscle Nerve* 2014; 50:159–163.
6. Inui A, Nishimoto H, Mifune Y, Kokubu T, Sakata R, Kurosaka M. Ultrasound measurement of median nerve cross-sectional area at the inlet and outlet of carpal tunnel after carpal tunnel release compared to electrodiagnostic findings. *Arch Orthop Trauma Surg* 2016; 136: 1325–1330. doi: 10.1007/s00402-016-2514-9. 8.
7. Ooi CC, Wong SK, Tan AB, et al. Diagnostic criteria of carpal tunnel syndrome using high-resolution ultrasonography: correlation with nerve conduction studies. *Skeletal Radiol* 2014; 43:1387–1394.
8. Kutlar N, Bayrak AO, Bayrak IK, Canbaz S, Turker H. Diagnosing carpal tunnel syndrome with Doppler ultrasonography: a comparison of ultrasonographic measurements and electrophysiological severity. *Neurol Res* 2017; 39:126–132.
9. Ishikawa M, Ota Y, Nagai M, Kusaka G, Tanaka Y, Naritaka H. Ultrasonography monitoring with superb microvascular imaging technique in brain tumor surgery. *World Neurosurg* 2017; 97:749.e11–e20.
10. Ohno Y, Fujimoto T, Shibata Y. A new era in diagnostic ultrasound, superb microvascular imaging: preliminary results in pediatric hepato-gastrointestinal disorders. *Eur J Pediatr Surg* 2017; 27: 20–25.
11. Chen J, Chen L, Wu L, et al. Value of superb microvascular imaging ultrasonography in the diagnosis of carpal tunnel syndrome: compared with color Doppler and power Doppler. *Medicine* 2017; 96: e6862.
12. Jablecki CK, Andary MT, Floeter MK, et al. Practice parameter: electrodiagnostic studies in carpal tunnel syndrome. Report of the American Association of Electrodiagnostic Medicine, American Academy of Neurology, American Academy of Physical Medicine and Rehabilitation. *Neurology* 2002; 58:1589.
13. Ozturk GT, Malas FU, Yildizgoren MT, et al. Ultrasonographic assessment of the femoral cartilage thickness in patients with pes planus: a multicenter study by TURK-MUSCULUS. *Am J Phys Med Rehabil* 2015; 94:568–572.
14. Cartwright MS, Hobson-Webb LD, Boon AJ, et al. Evidence-based guideline: Neuromuscular ultrasound for the diagnosis of carpal tunnel syndrome. *Muscle Nerve* 2012; 46:287–293.
15. Yoshii Y, Tanaka T, Ishii T. Correlations of median nerve area, strain, and nerve conduction in carpal tunnel syndrome patients. *Hand* 2016; 11:161–67.
16. Bayrak IK, Bayrak AO, Tilki HE, Nural MS, Sunter T. Ultrasonography in carpal tunnel syndrome: comparison with electrophysiological stage and motor unit number estimate. *Muscle Nerve* 2007; 35:344–348.
17. Kwon HK, Kang HJ, Byun CW, Yoon JS, Kang, CH, Pyun SB. Correlation between ultrasonography findings and electrodiagnostic severity in carpal tunnel syndrome: 3D ultrasonography. *J Clin Neurol* 2014; 10, 348–353.
18. Moran L, Perez M, Esteban A, Bellon J, Arranz B, del Cerro M. Sonographic measurement of cross-sectional area of the median nerve in the diagnosis of carpal tunnel syndrome: correlation with nerve conduction studies. *J Clin Ultrasound* 2009; 37:125–131.
19. Mohammadi A, Ghasemi-Rad M, Mladkova-Suchy N, Ansari S. Correlation between the severity of carpal tunnel syndrome and color Doppler sonography findings. *AJR Am J Roentgenol* 2012; 198:W181–W184.
20. Joy V, Therimadasamy AK, Chan YC, Wilder-Smith EP. Combined Doppler and B-mode sonography in carpal tunnel syndrome. *J Neurol Sci* 2011; 308:16–20.
21. Ghasemi-Esfe AR, Khalilzadeh O, Vaziri-Bozorg SM, et al. Color and power Doppler US for diagnosing carpal tunnel syndrome and determining its severity: a quantitative image processing method. *Radiology* 2011; 261:499–506.
22. Dejaco C, Stradner M, Zauner D, et al. Ultrasound for diagnosis of carpal tunnel syndrome: comparison of different methods to determine median nerve volume and value of power Doppler sonography. *Ann Rheum Dis* 2013; 72:1934–1939.
23. Arslan S, Karahan AY, Oncu F, Bakdik S, Durmaz MS, Tolu I. Diagnostic performance of superb microvascular imaging and other sonographic modalities in the assessment of lateral epicondylosis [published online ahead of print August 29, 2017]. *J Ultrasound Med*. doi: 10.1002/jum.14369.