Journal of Cardiology Cases (2011) 4, e8—e12

available at www.sciencedirect.com

ScienceDirect

journal homepage: www.elsevier.com/locate/jccase

Case Report

Acute myocardial infarction due to antiphospholipid antibody syndrome in a young pregnant woman

Huseyin Altug Cakmak (MD)*, Serkan Aslan (MD), Eser Durmaz (MD), Bilgehan Karadag (MD), Rasim Enar (MD)

Istanbul University Cerrahpasa School of Medicine, Department of Cardiology, Istanbul, Turkey

Received 25 January 2011; received in revised form 14 April 2011; accepted 25 April 2011

KEYWORDS
Antiphospholipid antibody syndrome;
Acute myocardial infarction;
Pregnant;
Bleeding complications

Summary Myocardial infarction (MI) in pregnant patients confer additional risks and unique problems related to necessity of concomitant obstetric interventions and coexistence of disorders as hypercoagulability. Therefore, patients usually have a more complicated course which demands prompt diagnosis and appropriate treatment. Here we report a 22 year old pregnant woman with an acute anterior myocardial infarction and the complicated course of the management. Although the patient underwent a successful percutaneous coronary intervention at the first presentation with MI, one week later she suffered a stent thrombosis presumably due to cessation of clopidogrel in order to prevent bleeding before the termination of pregnancy. Later, a detailed examination of the patient has led to diagnosis of antiphospholipid antibody syndrome.
© 2011 Japanese College of Cardiology. Published by Elsevier Ltd. All rights reserved.

Introduction

Acute coronary syndromes in pregnant patients confer additional risks and unique problem associated with, limitations of management alternatives, necessity of concomitant obstetric interventions and coexistence of disorders as antiphospholipid antibody syndrome. The antiphospholipid antibody syndrome (APAS), a systemic autoimmune disease characterized by recurrent arterial and venous thrombosis and/or pregnancy loss in association with circulating antiphospholipid antibody, is the most common acquired thrombophilia. The incidence of antiphospholipid antibody syndrome is 2—4% [1—3] in general population and its usually associated with in venous thrombophilia [4,5] and systemic lupus erythematosus (30%) [6]. Coronary thrombosis as a manifestation of the antiphospholipid antibody syndrome is occasionally rare. The cardiac manifestations of this disease include valvular abnormalities (thrombotic vegetations or thickening), myocardial infarction, intracardiac thrombi and myocardial microthrombosis.

* Corresponding author at: Istanbul University Cerrahpasa School of Medicine, Department of Cardiology, Kocamustafapasa Street, 34098 Fatih, Istanbul, Turkey. Tel.: +90 533 328 6329.
E-mail address: altugcakmak@hotmail.com (H.A. Cakmak).

1878-5409/$ — see front matter © 2011 Japanese College of Cardiology. Published by Elsevier Ltd. All rights reserved.
doi:10.1016/j.jccase.2011.04.006

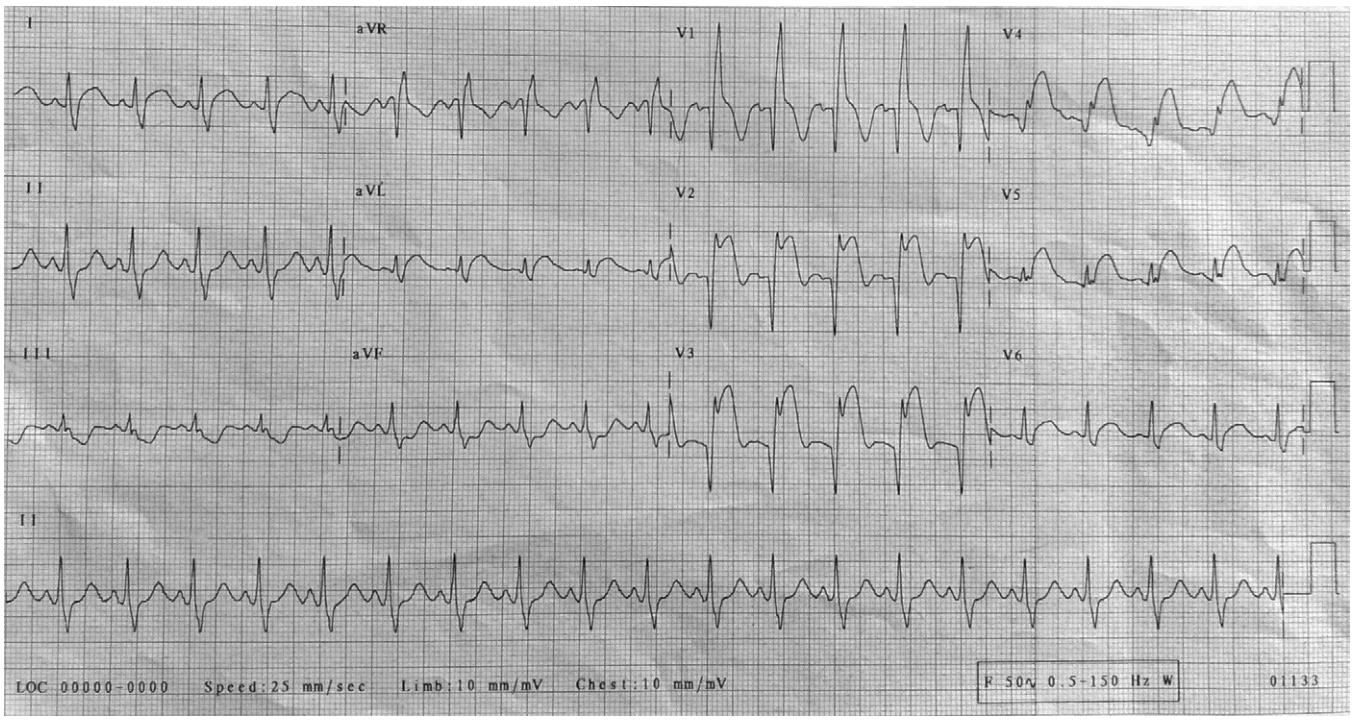

Figure 1 Twelve-lead electrocardiography during chest pain showing ST segment elevation in leads I, aVL, V1—V6, and reciprocal ST segment depression in leads II, III, and aVF.

Here in, we report the complicated course and management of an acute myocardial infarction due to antiphospholipid antibody syndrome in a pregnant patient.

Case report

Twenty two year-old, twelve week pregnant woman was admitted with retrosternal chest pain radiating to left arm with a duration of 12 h. Her past medical history was unrelevant except one spontaneous abortus 2 years ago and a family history for coronary artery disease. Her physical examination revealed a blood pressure of 112/78 mmHg, and a pulse rate of 81 min. Auscultatory findings were normal except the presence of S4. Twelve-lead electrocardiography recorded during chest pain showed ST segment elevation in leads I, aVL, V1—V6 and reciprocal ST segment depression in leads II, III and aVF (Fig. 1). The initial laboratory findings at admission were as follows: CK: 3151 U/L, CK-MB: 474 U/L, Troponin: >100 ng/mL and echocardiography showed anteroapical, anteroseptal akinesia and midseptal hypokinesia with an ejection fraction of 35—40%. The patient was transferred to the catheterization laboratory immediately with an intention for primary percutaneous coronary intervention (PCI). Three hundred milligrams acetylsalicylic acid with 600 mg loading dose clopidogrel was orally administered and 0.75 mg/kg intravenous enoxaparine was given before procedure. An immediate coronary angiography showed a subtotal occlusion of mid left anterior descending artery (LAD) (Fig. 2A). The circumflex and right coronary arteries were disease free. The lesion was dilated with a balloon. Although the initial strategy was balloon recanalization only in order to avoid stent implantation which will lead to necessity of long term clopidogrel use. However, the distal perfusion of the vessel was suboptimal after balloon recanalization, therefore 3.5×16 mm bare metal stent was implanted with 18 atmosphere (Fig. 2B). A slow flow was observed in LAD following stent implantation and the flow was restored after administration of 1 mg (0.5 + 0.5 mg) of intracoronary verapamil. Finally, TIMI III flow was established, pain was relieved and complete ST resolution was observed in anterior derivations. The transthoracic echocardiography showed left ventricular apical dyskinesis, and aneursym formation with a trombus inside. The ejection fraction was 20%. The patient stayed in cardiology department for 7 days and then referred to obstetrics department for termination of pregnancy in accordance with the obstetricians suggestions. Clopidogrel was stopped 5 days prior to abortion, aspirin continued and subcutaneous enoxaparine was started. Termination of pregnancy was performed with potassium hydrochloride injection to fetal heart and no bleeding complication was seen during the procedure. Two days after the abortus the patient has experienced chest pain resembling the previous event. Therefore the patient was transferred to catheterization laboratory for immediate PCI with a diagnosis of presumed stent thrombosis due to discontinuation of clopidogrel. Angiography showed a totally occluded LAD due to stent thrombosis. Tirofiban infusion was started, 10,000 units of unfractional heparin, 300 mg acetylsalicylic acid and 600 mg clopidogrel was administered immediately. The stent was crossed with a soft wire and several thrombus aspirations and balloon dilatation were performed. Unfortunately thrombus

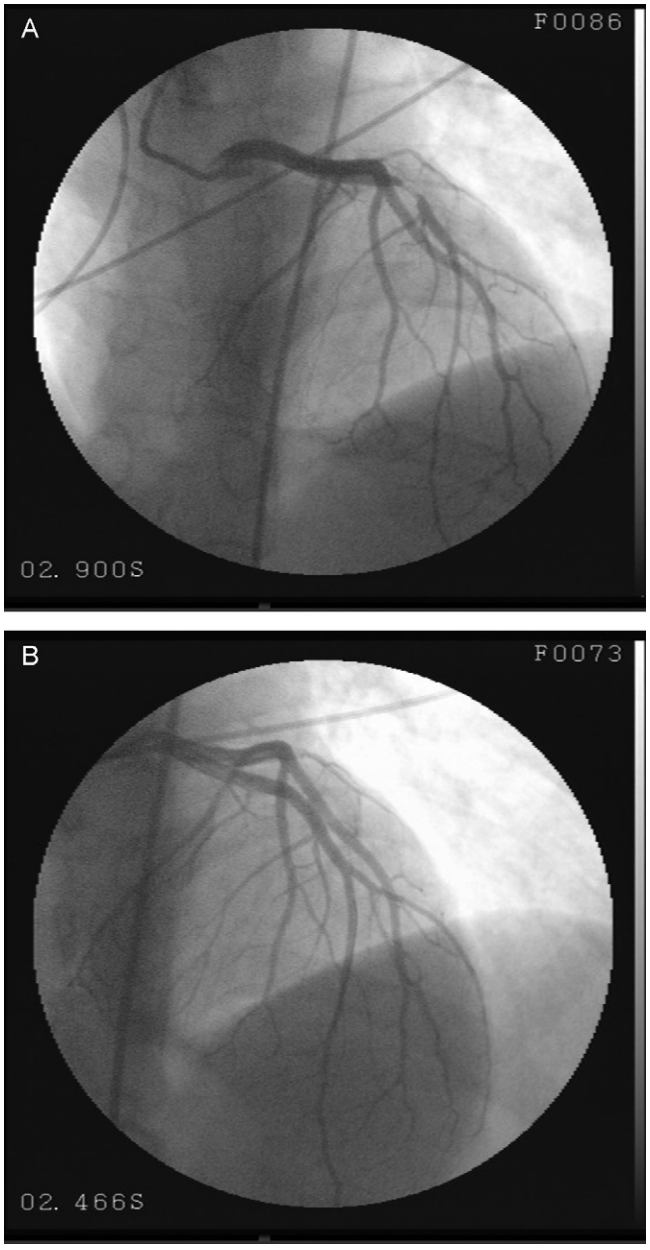

Figure 2 (A) The coronary angiography showed a subtotal occlusion of mid left anterior descending artery. (B) The coronary angiography showed 3.5×16 mm bare metal stent implantation at 18 atmospheres to the mid left anterior descending artery for suboptimal distal perfusion of the vessel following balloon recanalization.

aspirations and balloon recanalization attempts failed and all recanalizations were followed by reocclusion due to heavy thrombus burden. As a last attempt 250.000 units of streptokinase was infused with an infusion catheter into the LAD selectively for 3 min. Intracoronary thrombolytic infusion also failed. During her coronary care unit follow up she developed complete atrioventricular block which responded intravenous atropine administration. The control echocardiography revealed an ejection fraction of 20% with an aneursymatic left ventricle with thrombus. Two days later curettage was performed due to incomplete abortion. Rheumatologic and hematologic tests were as follows: free T3 (sT3): 2.74 pg/mL (1.8—4.2), free T4 (sT4): 1.06 ng/dL (0.7—1.9), thyroid-stimulating hormone (TSH): 14.06 mIU/L (0.4—4.20), anti-thyroid peroxidase autoantibody (TPO): 3.04 IU/mL (0—35), anti-thyroglobulin (TG): 3.45 IU/mL (0—40), low density lipoprotein (LDL): 116 mg/dL, triglyceride (TG): 152 mg/dL, high density lipoprotein (HDL): 43 mg/dL, HbA1C: 6.9%, compleman 3C (C3C): 1.44 g/L (0.9—1.8), compleman 4C (C4C): 0.55 g/L (0.1—0.4), protein C: 131% (70—140%), protein S: 44% (60—123%), anti-thrombin III activity: 103.1% (75—125%), homocysteine: 11.7 μmol/L (0—15 μmol/L), anti-Sjogren Syndrome A (SSA): 0.277 (<1), anti-Sjogren Syndrome B (SSB): 0.321 (<1), beta-2 glycoprotein IgM: 116 (>20 positive), beta-2 glycoprotein IgG: <2.0 (>20 positive), anti-cardiolipin IgM: 3.545 MPLU/mL (0—7 MPLU/mL), anti-cardiolipin IgG: 7.089 GPLU/mL (0—10 GPLU/mL), lupus anticoagulant: medium positive, antinuclear antibody (ANA): strong positive, anti-double strand DNA(ds-DNA): 1.28 (>1.1 positive). Levothyroxine 50 mcg was started for her subclinical hypothyroidia. She was given systemic lupus erythematosus prophylaxis with hydroxychlorochine and warfarin was administered with the indication of antiphospholipid antibody syndrome with left ventricular thrombus. After achieving target INR values, she was discharged and referred to rheumatology and cardiology outpatient clinics for further follow-up.

Discussion

Acute myocardial infarction (AMI), which carries a high risk of maternal and perinatal mortality, complicates approximately 1 in 10,000 pregnancy. Although patients presenting with AMI during pregnancy tend to be younger and have less co-morbidities, the maternal mortality from AMI is high up to 21% [7]. Identified risk factors for coronary artery disease in young women include diabetes mellitus, smoking, dyslipidemia, family history, and previous use of oral contraceptives [8]. The underlying precipitating factors of AMI in pregnancy are thought to be multifactorial and attributable to the physiological events that occur during pregnancy. The increased myocardial oxygen demand due to marked increases in blood volume, stroke volume, and heart rate, profound alterations in the coagulation and fibrinolytic system that lead to increased risk of thrombosis, the physiological anemia and decreased diastolic blood pressure that may reduce myocardial oxygen supply are the most important mechanisms leading to AMI in peripartal women [9]. In contrast to the general population, underlying atherosclerotic disease is documented in less than half (43%) [8] of the acute coronary syndrome cases seen in pregnant patients. Normal coronary arteries were found in 29% [8] of reported cases in which the coronary artery anatomy was defined. In general terms it appears that pregnant women are at 3—4 times greater risk of AMI than age matched non-pregnant women, although the incidence in absolute terms is very small. Independent predisposing factors that have been associated with an increased risk of infarction in a pregnant women are age over 30 years, third trimester of pregnancy, multiparity, hypertension, eclampsia, pre-eclampsia, diabetes, smoking, thrombophilia, need

for blood transfusion, and appearance of infection following delivery [9]. Non-atherosclerotic etiologies likely to be responsible from MI in pregnant patients include thrombosis, coronary artery spasm, spontaneous coronary artery dissection, collagen vascular disease, aortic valvular stenosis, prosthetic valve thrombosis, sickle cell disease, and thrombophilic disorders like antiphospholipid syndrome as in our case [9]. The pathogenic mechanisms of the antiphospholipid antibody syndrome that lead to in vivo injury and vessel thrombosis are unknown. APAS are found in 15—30% of patients presenting with venous thromboembolism [4,5], in about 25% of patients presenting with first ischemic stroke [10], and in approximately 2.8% of young people presenting with first myocardial infarction [11]. Their prevalence in the unselected population is unknown. About 30% of individuals with systemic lupus erythematosus have an APAS [12]. Myocardial infarction (MI) in pregnant patients confer additional risks and unique problems related to necessity of concomitant obstetric interventions and coexistence of disorders as hypercoagulability. The most important points relevant to the management of patients with AMI during pregnancy are the timing of the delivery and drug treatment. A number of cases reporting successful PCI as a treatment of STEMI during pregnancy have been published [13,14]. Evidence-based treatment of these patients is difficult due to the lack of data from randomized controlled trials. Trombolysis agents are not recommended due to risk of hemorrhagic complications as spontaneous abortion, minor vaginal bleeding, spontaneous hematoma in the inguinal and axillary region requiring blood transfusion, fatal abruptio with fetal death, uterine bleeding necessitating emergency cesarean section, and postpartum hemorrhage requiring transfusion. The optimal management approach for NSTEMI or USAP have also not yet been defined. In the presence of ongoing myocardial ischemia, the recommendations are to administer aspirin, unfractionated heparin, B-blockers, and nitroglycerin, and to perform immediate coronary angiography. Depending on the patient's coronary anatomy and response to medical management, therapy options range from a conservative approach to percutaneous coronary intervention or coronary artery bypass surgery. Since percutaneous and surgical revascularizations may be very challenging in the setting of pregnancy, medical management should be considered as the first line treatment in the absence of ongoing ischemia. It is best to avoid stent implantation and rather prefer plain balloon angioplasty in these patients because of the detrimental effects of clopidogrel discontinuation for abortus or delivery. In case of stent implantation, as in our experience, cessation of clopidogrel may cause catastrophic outcomes [9]. Therefore, in patients who underwent percutaneous coronary interventions and stenting, clopidogrel could be discontinued only in the presence of compelling contraindications to antiplatelet agents. An alternative strategy can be switching from clopidogrel 5 days before surgery to a reversible antiplatelet agent with a short half-life as a glycoprotein IIb/IIIa or eptifibatide and stopping the infusion 4 h before the surgery or abortion. Following the surgery, resumption of clopidogrel as soon as possible after the establishment of hemostasis is strongly recommended. The substitution of dual antiplatelet treatment with low molecular weight heparin or unfractionated heparin is not effective. In other scenarios which necessitate long term anticoagulation as presence of atrium fibrillation or prosthetic valves, unfractionated heparin (UFH) and low molecular weight heparin (LMWH) are considered as the anticoagulation of choice during pregnancy because their large molecular weights prevent them from crossing the placenta and therefore precludes teratogenic effects. The safety of higher doses of aspirin and aspirin ingestion during the first trimester remains uncertain. The use of newer antiplatelet agents during pregnancy, such as glycoprotein IIb/IIIa antagonists, ticlopidine, and clopidogrel have been reported in the literature; however, very little data exist for their use in management of pregnant patients [9].

In conclusion, despite a prompt and appropriate diagnosis and management, acute MI in pregnant patients who have antiphospholipid antibody syndrome may follow a complicated course and lead to a poor outcome. Therefore optimal treatment strategy for this situation requires further investigation.

References

[1] Eschwège V, Peynaud-Debayle E, Wolf M, Amiral J, Vissac AM, Bridey F, Dreyfus M, Boyer-Neumann C, Meyer D. Prevalence of antiphospholipid-related antibodies in unselected patients with history of venous thrombosis. Blood Coagul Fibrinolysis 1998;9:429—34.

[2] Zanon E, Prandoni P, Vianello F, Saggiorato G, Carraro G, Bagatella P, Girolami A. Anti-beta2-glycoprotein I antibodies in patients with acute venous thromboembolism: prevalence and association with recurrent thromboembolism. Thromb Res 1999;96:269—74.

[3] Zielinska J, Ryglewicz D, Wierzchowska E, Lechowicz W, Hier DB, Czlonkowska A. Anticardiolipin antibodies are an independent risk factor for ischemic stroke. Neurol Res 1999;21: 653—7.

[4] Cervera R, Piette JC, Font J, Khamashta MA, Shoenfeld Y, Camps MT, Jacobsen S, Lakos G, Tincani A, Kontopoulou-Griva I, Galeazzi M, Meroni PL, Derksen RH, de Groot PG, Gromnica-Ihle E, et al. Antiphospholipid syndrome: clinical and immunologic manifestations and patterns of disease expression in a cohort of 1000 patients. Arthritis Rheum 2002;46: 1019—27.

[5] Love PE, Santoro SA. Antiphospholipid antibodies, anticardiolipin and the lupus anticoagulant in systemic lupus erythematosus (SLE) and in non-SLE disorders. Ann Intern Med 1990;112:682—9.

[6] Lockwood CJ, Romero R, Feinberg RF, Clyne LP, Coster BS, Hobbins JC. The prevalence and biologic significance of lupus anticoagulant and anticardiolipin antibodies in a general obstetric population. Am J Obstet Gynecol 1989;161: 369—73.

[7] Shi W, Krilis SA, Chong BH, Gordon S, Chesterman CN. Prevalence of lupus anticoagulant and anticardiolipin antibodies in a healthy population. Aust NZ J Med 1990;20:231—6.

[8] Infante-Rivard C, David M, Gauthier R, Rivard GE. Lupus anticoagulants, anticardiolipin antibodies, and fetal loss. A case—control study. N Engl J Med 1991;325:1063—6.

[9] Petri M. Clinical and management aspects of the antiphospholipid syndrome. In: Wallace DJ, Hahn BH, editors. Dubois' lupus erythematosus. 5th ed. Baltimore: Williams & Wilkins; 1997. p. 57.

[10] Hankins GD, Wendel Jr GD, Leveno KJ, Stoneham J. Myocardial infarction during pregnancy: a review. Obstet Gynecol 1985;65:139—46.

[11] Roth A, Elkayam U. Acute myocardial infarction associated with pregnancy. Ann Intern Med 1996;125:751—62.
[12] Poh C-L, Lee C-H. AMI in pregnancy. Review. Ann Acad Med Singapore 2010;39:247—53.
[13] Ascarelli MH, Grider AR, Hsu HW. Acute myocardial infarction during pregnancy managed with immediate percutaneous transluminal coronary angioplasty. Obstet Gynecol 1996;88:655—7.
[14] Balmain S, McCullough CT, Love C, Hughes R, Heidemann B, Bloomfield P. Acute myocardial infarction during pregnancy successfully treated with primary percutaneous coronary intervention. Int J Cardiol 2007;116:e85—7.