ACTA ORTHOPAEDICA et TRAUMATOLOGICA TURCICA
www.aott.org.tr

Research Article

Dose-dependent effects of estrogen-enriched bone cement on membrane quality in the Masquelet technique: experimental rat model

Mehmet Utku Çiftçi[1], Merjem Purelku[2], Furkan Özönder[3], Nezih Ziroğlu[4], Bülent Tanrıverdi[3], Gamze Tanrıverdi[5], Mustafa Gökhan Bilgili[3]

[1]*Department of Orthopeadic and Travmatology, Sultan 2. Abdulhamid Han Training and Research Hospital, University of Health Sciences, İstanbul, Türkiye*
[2]*Department of Histology and Embryology, Bahçeşehir University School of Medicine, İstanbul, Türkiye*
[3]*Department of Orthopeadic and Travmatology, Bakırkoy Dr. Sadi Konuk Training and Research Hospital, University of Health Sciences, İstanbul, Türkiye*
[4]*Department of Orthopeadic and Traumatology, Acıbadem Atakent Hospital, Acıbadem University, İstanbul, Türkiye*
[5]*Department of Histology and Embryology, İstanbul University-Cerrhpaşa Cerrahpaşa School of Medicine, İstanbul, Türkiye*

ARTICLE INFO

Article history:
Submitted March 29, 2025
Received in revised form
April 22, 2025
Last revision received form
September 23, 2025
Accepted September 24, 2025
Publication Date
February 23, 2026

Keywords
Bone defect
Estrogen
Induced membrane
Masquelet technique
PMMA

ORCID iDs of the authors:
M.U.C. 0000-0001-5594-4138;
M.P. 0000-0003-2219-0231;
F.O. 0000-0001-8075-8919;
N.Z. 0000-0002-2595-9459;
B.T. 0000-0001-8931-9189;
G.T. 0000 0002 8646 0336;
M.G.B. 0000-0002-5301-6407.

Corresponding author:
Nezih Ziroğlu,
nezih.ziroglu@yahoo.com

Content of this journal is licensed under a Creative Commons Attribution-NonCommercial 4.0 International License.

ABSTRACT

Objective: The Masquelet technique is a 2-stage surgical method used for the reconstruction of critically sized bone defects due to various etiologies. Estrogen is known to have anabolic effects on bone metabolism. In this study, based on literature data, the aim is to systematically evaluate the histological and immunohistochemical effects of adding different doses of estrogen to polymethylmethacrylate cement on induced membrane tissue.

Methods: Twenty-eight male rats were included in the study and divided into 4 groups. Three experimental groups received different doses of estradiol, a subtype of estrogen mixed with bone cement, while a control group received only bone cement. Approximately 10 mm defects were created in single femurs of all rats. Bone cement appropriate for each experimental group was placed in these defects, and bone fixation was performed with mini plates and screws. Tissue samples taken from all animals at the end of the sixth week were evaluated by histological and immunohistochemical methods.

Results: Histological and immunohistochemical evaluations of the induced membranes obtained at the end of the experiment revealed signs of bone formation in all subgroups. A significant increase in bone formation was observed with increasing doses in groups E1, E2, and E3 compared to the control group ($P < .05$). The histological scores of the study groups were found to increase statistically significantly with increasing estrogen dose ($P < .05$). Furthermore, immunohistochemical analyses revealed that the immuno-reactive scores for bone morphogenetic protein-4 and insulin-like growth factor-1 expression were significantly higher in the E3 group compared to the other groups ($P < .05$).

Conclusion: In this study, it was found that enriching the cement content with estrogen during bone cement placement, the first step of the Masquelet technique, improved the quality of the formed membrane. This improvement in membrane quality is promising for increasing treatment efficacy and shortening the treatment duration.

Level of Evidence: Level V, Therapeutic Study.

Introduction

In orthopedics practice, the term critical bone defect, which may occur due to trauma, infection, or malignancy, refers to bone cavities that the body cannot heal and are also defined as segmental defects larger than 6 cm.[1] Many different treatment options can be used in the treatment of bone defects, depending on the size of the defect.[2] Induced membrane technique (IMT), free vascularized fibula graft, and distraction osteogenesis are the preferred treatment methods for large segmental bone defects.[3]

In the first stage of the Masquelet technique (MT) described by Masquelet in 1986, debridement and bone cement (polymethylmethacrylate (PMMA)) are applied. In the second stage, the reconstruction is completed by opening the membrane without damaging it, removing the PMMA, and filling the space with a bone graft.[4] It has been shown in many studies that the induced membrane that develops after a foreign body reaction around PMMA placed in the defect area prevents resorption by storing bone grafts and provides osteoinductive growth factors for bone healing.[5] In the Masquelet technique, which is a popular method on which research continues in Orthopedics and Traumatology practice, studies continue under headings such as improving membrane quality, reducing membrane formation time, reducing refracture rates and post-treatment deformity development, and combating complications such as infection more effectively.[6] In a recent study, it has been shown that the addition of estrogen molecules, which are known to have osteoproductive effects, to the PMMA used in the Masquelet technique improves membrane quality.[7] In addition, it has also been shown that estrogen weakens osteoblast and osteocyte apoptosis and reduces osteoclast formation and bone resorption.[8] However, questions regarding the doses at which it acts optimally or the relationship between the increase in membrane quality and the dose remain unanswered.

Cite this article as: *Çiftçi MU, Purelku M, Özönder F, et al. Dose-dependent effects of estrogen-enriched bone cement on membrane quality in the masquelet technique: experimental rat model. Acta Orthop Traumatol Turc., 2026; 60(1), 0355, doi: 10.5152/j.aott.2026.25355.*

In this study, it was investigated whether the addition of different doses of estrogen to PMMA bone cement improves the histological and immunohistochemical quality of the induced membrane formed by the Masquelet technique. It was hypothesized that incorporating estrogen molecules, known for their osteoproductive effects, into the bone cement would enhance membrane quality in a dose-dependent manner, enabling the formation of a more effective membrane in a shorter time.

The aim of the study is to demonstrate histologically and immunohistochemically how estrogen molecules, which have been shown to improve membrane quality, affect the quality of induced membrane when applied at different doses.

Material and methods

Power analysis

Power analysis was performed using the G*Power (v3.1.7) program to determine the sample size. The power of the study is expressed as 1-β (β=probability of type 2 error), and in general, studies should have 80% power. In the histopathologic scoring measurements, at least an average of 3.72 units difference was calculated for the clinical difference between the groups, and the effect size was found to be $d=3.067$. It was calculated that there should be at least 6 rats in total in the groups to obtain 99% power at $\alpha = 0.05$ level.

Study groups

In the study, 3 groups in which estradiol, a subtype of estrogen, was administered at different doses and 1 control group were formed. The study was performed on Wistar Hannover rats in which bone defects were created in the laboratory and the results were evaluated histologically and immunohistochemically. An experimental model was prepared with a total of 28 rats consisting of 4 groups and 7 male Wistar Hannover rats, each group consisting of 7 rats aged 5-7 months and weighing 300-350 grams.[7] Female rodents experience significant fluctuations in gonadal hormone levels throughout their approximately 4-day estrous cycles, which are considered equivalent to the human menstrual cycle (Becker et al., 2005). These hormonal changes can, in some cases, influence behavior, neuroanatomy, and physiology. In this study, only male rats were used to minimize biological variability and eliminate the potential effects of the estrous cycle on hormonal balance. This choice was made to ensure hormonal stability throughout the experiment and to maintain methodological consistency with previous studies evaluating local hormone-based interventions.[9]

Ethical committee approval was received from the Ethics Committee of Bezmialem Vakıf University (Approval no: 2021/157, Date: 21.06.2021). Experimental groups were formed by planning to place PMMA without any additive in the control (K) group, PMMA with 1 mg estrogen added in the E1 group, PMMA with 2 mg estrogen added in the E2 group, and PMMA with 4 mg estrogen added in the E3 group in the bone defect created in rats.[7]

HIGHLIGHTS

- In this study, the impact of varying estrogen doses on the Masquelet technique (MT) for bone defect treatment was investigated.
- Histopathologic and immunohistochemical evaluations showed that estrogen enhanced new bone formation and shortened the formation time.
- Increased estrogen doses led to greater expression of bone morphogenetic protein-4 and insulin-like growth factor-1, promoting osteogenic activity.
- Histological scoring revealed significant improvements in membrane quality and new bone formation in the E3 group compared to lower-dose groups.
- These findings suggest that estrogen could potentially expedite MT's effectiveness, though further research is needed to optimize dosage and assess systemic effects.

Animal care

Rats were kept in a separate cage at 21°C with adequate ventilation and lighting (12 hours during the day and 12 hours at night). During the recovery period, rats were observed daily for complications of discomfort, difficulty, and pain.[10]

Preparation and surgery

After anesthesia, the surgical field was shaved, sterile stained, and covered. Following the incision made in the right thigh for each animal, the femur bone was reached by bluntly passing between the rectus femoris and vastus lateralis heads of the quadriceps muscle. After the femur bone was exposed, a 6-hole plate was implanted into the rat femur with 2 proximal and 2 distal screws. Approximately a 10 mm femoral diaphyseal defect was created by osteotomy with the help of micro reamers through 2 holes in the center of the plate.

Bone cement was mixed and placed in the defect area under sterile conditions to the previously determined extent for each group, 1 for each rat. After washing, subcutaneous tissues, muscles, and skin were repaired with polypropylene suture material.

Preparation and application of bone cement to the defect

The cement contents to be applied to the defect area were prepared separately for each rat in the laboratory environment using a precision laboratory scale under sterile conditions. To account for the potential material loss during the mixing and application of small volumes, bone cement was individually prepared according to predetermined ratios of solid polymer, liquid monomer, and bio-agent components.

For the PMMA (Control) group, plain cement was prepared by adding 1-2 cc of liquid monomer (VERSABOND: Smith & Nephew / USA) to 0.2-0.3 g of PMAA and combining it with the powdered PMMA.

Although some studies report that teicoplanin up to 2 g per 40 g of cement increases mechanical fatigue strength, amounts above 800 mg may significantly reduce it.[11,12] Many authors have examined antibiotic-loaded bone cement, yet there is no consensus on the optimal antibiotic or dosage. In the study by Ziroglu et al, 2 mg of estrogen was added to the estrogen-supplemented cement formulation to investigate its effect on the membrane.[6] There is only 1 study in the literature on estrogen-enriched bone cement, in which a dose of 2 mg was used. Therefore, based on the limited available data and considering dose ranges that do not excessively compromise mechanical strength, 1 mg, 2 mg, and 4 mg estradiol were selected as the study groups. For experimental groups (E1, E2, and E3), 1 mg, 2 mg and 4 mg estradiol (Estrofem® 2 mg tablet - estradiol hemihydrate) tablets were finely ground using a sterile mortar and pestle for incorporation into powdered PMMA, indicating low normal and high dose ratios, respectively. The resulting powder was thoroughly mixed with the solid polymer component before the liquid monomer was added. This dry-mixing approach ensured homogeneous dispersion of the hormone within the cement matrix. The components were mixed for approximately 30 seconds using a sterile spatula until a homogeneous paste was obtained. All mixing procedures were carried out in a temperature- and humidity-controlled laboratory to ensure

reproducibility across samples. Each cement batch was freshly prepared just prior to application, and all preparations were performed by the same investigator following a standardized protocol to maintain consistency. No visible phase separation or sedimentation was observed. Subjective assessment during application suggested that the addition of estradiol in the specified doses did not noticeably alter the cement's handling properties, including viscosity, malleability, and setting time.[7]

The cement was applied to the defect site and gently pressed into place. After placement, the area was washed, and the muscle tissue was approximated using absorbable sutures. Subcutaneous and dermal layers were then closed in standard fashion.

Sacrifice of experimental animals

After ketamine-xylazine anesthesia, anteroposterior radiographs of the right femur were taken for radiological evaluation. All rats were then sacrificed with high-dose anesthetic infusion. After killing, the right femur of all subjects was entered through the old incision scars. The IM formed after crossing the layers was cut and scraped with a scalpel and separated in 10% formalin for histopathologic study.

Histopathologic evaluation

Tissue samples obtained from all animals in the groups at the end of the 6th week were prepared using standard histology procedures. Sections of 3-5 μm thickness were cut and stained with Masson trichrome after deparaffinization in toluene. Prepared slides were imaged using an Olympus DP72 digital camera attached to an Olympus BX61 light microscope. The scoring of the specimens was performed following the histopathologic scoring system described by Huo et al.[13]

Immunohistochemical evaluation

Sections taken for immunohistochemical examination were evaluated for insulin-like growth factor-1 (IGF-1) and bone morphogenetic protein-4 (BMP-4) expression using the streptavidin-peroxidase method. Cells showing positive immunolabeling were scored according to the immune reactive scoring system (IRS) considering their density.[14]

Statistical analysis

The statistical significance of the scores obtained after histopathologic and immunohistochemical examinations was evaluated. Finally, the correlation between both evaluations was analyzed. Data were analyzed using IBM SPSS Statistics Standard Concurrent User V 26 (IBM Corp., Armonk, New York, USA) statistical package programs. Descriptive statistics were given as number of units (n), mean (X), standard deviation (SD), median (M), and interquartile range (IQR) values. The normal distribution of numerical variables was evaluated by the Shapiro–Wilk normality test. The Kruskal–Wallis test was used to compare the measurements in the study groups. Multiple comparisons were made with the Bonferroni–Dunn test for the measurements found to be significant in the Kruskal–Wallis Test. The $P < .05$ level was considered statistically significant.

Results

Histopathologic evaluation

Histopathologic examination of the tissue samples taken from all animals in the groups at the end of the 6th week revealed numerous cell groups containing euchromatic nuclei, rich in granular endoplasmic reticulum and ribosomes, which were thought to be clustered osteoblastic progenitor cells based on the morphologic characteristics of the cells.

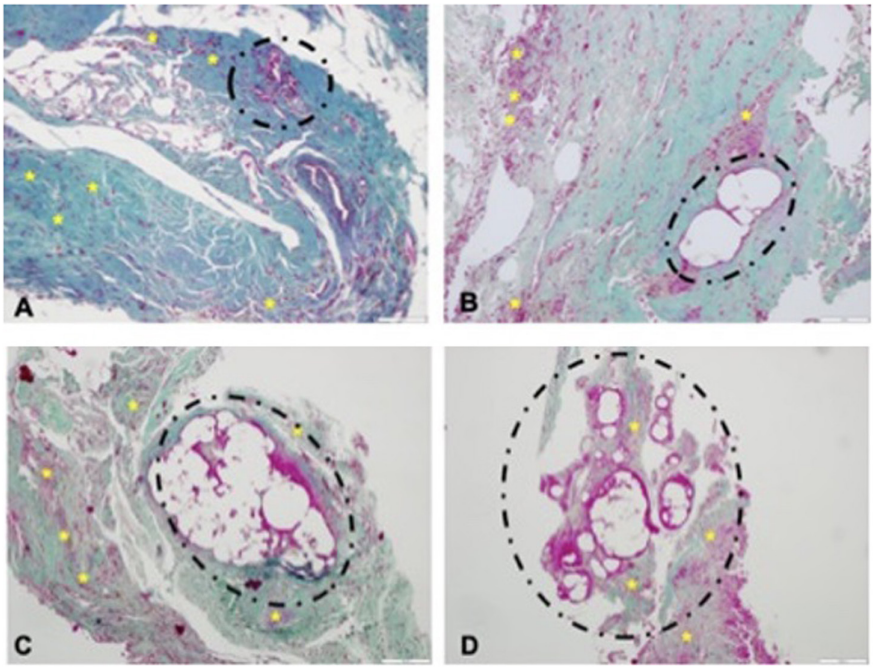

Figure 1. Microscopic images of histologic evaluation of samples from K, E1, E2, and E3 groups. A: In the control group containing only PMMA, areas of dense connective tissue (green areas), clusters of osteoprogenitor cells (*), and areas of ossification (black circle area with dashed lines) are also seen. B: The PMMA group containing 1 mg estrogen shows dense osteoprogenitor cells (*) with areas of increased ossification compared to the control group (black circle area with dashed lines). C: In the PMMA group containing 2 mg estrogen, prominent areas of ossification are seen adjacent to clusters of osteoprogenitor cells (*) (black circle area with dashed lines). D: In the 4 mg estrogen-containing PMMA group, the presence of prominent osteoprogenitor cells (*), as well as numerous large and small new bone formation centers (black circle area with dashed lines), is noteworthy. Masson's triple stain × 20.

In the control group containing only PMMA, areas containing dense connective tissue, osteoprogenitor cells, and ossification areas were observed. The samples belonging to the E1 group showed dense osteoprogenitor cells and increased ossification areas compared to the control group (Figure 1).

In the samples belonging to the E2 group, osteoprogenitor cells and prominent ossification areas adjacent to these cell clusters were detected. In the specimens belonging to the E3 group, numerous large and small bone formation centers with osteoprogenitor cells were observed (Figure 1).

Histopathologic scoring showed that bone differentiation increased as estrogen doses increased. (Table 1)

Table 1. Comparison of histology scores, BMP-4 IRS scores, and IGF-1 IRS scores by groups

	Groups				
	Control	E1	E2	E3	
	n=7	n=7	n=7	n=7	Test (*P*)
Histology					H=21.804
X ± SD	3.14 ± 0.69	5.86 ± 1.07	6.71 ± 1.25	8.86 ± 1.07	*P* < .001
M (IQR)	3 (1)	6 (2)	6 (2)	9 (2)	
BMP-4 IRS					H=14.426
X ± SS	1.43 ± 0.79	2.43 ± 0.53	2.86 ± 0.9	3.43 ± 0.53	*P*=.002
M (IQR)	1 (1)	2 (1)	3 (2)	3 (1)	
IGF-1 IRS					H=14.350
X ± SS	1.71 ± 0.76	2.57 ± 0.79	3 ± 0.82	3.71 ± 0.49	*P*=.002
M (IQR)	2 (1)	2 (1)	3 (2)	4 (1)	

Kruskal–Wallis test (H).

Immunohistochemical evaluation

Immuno immuno-reactive scoring system was used to evaluate BMP-4 and IGF-1 expression. This scoring is based on the following scores: no staining (0 points), mild staining (1 point), moderate staining (2 points), severe staining (3 points), and very severe staining (4 points). Samples from each rat were evaluated in a joint session by 2 experienced histologists, who were blinded to the group allocations. All samples were anonymized and coded prior to evaluation. The histologists scored the slides together and reached a consensus on each evaluation. Therefore, an interobserver agreement analysis (e.g., kappa or ICC) was not performed. The BMP-4 and IGF-1 expression were evaluated and scored according to the IRS system.[6,10,15] The scores were recorded in separate tables and each group was listed separately (Table 1).

The BMP-4 expression levels were evaluated in samples from all experimental groups. While BMP-4 (+) cells were diffusely distributed in the K group, dense BMP-4 (+) cells were commonly observed in the E1 group. In the E2 and E3 groups, where the estrogen dose was relatively higher, more BMP-4 (+) cells were detected (Figure 2).

In all samples in which IGF-1 expression was evaluated, an increase in the staining intensity and number of IGF-1 (+) osteoprogenitor cells was detected (Figure 3).

Statistical analysis of histological and immunohistochemical data

Table 1 shows the averages and comparisons of histologic scores, BMP-4, and IGF-1 IRS scoring of the subjects according to the study groups.

Histologic measurements showed a statistically significant difference in the study groups (H=21.804 *P* < .001). The BMP-4 IRS scores showed a statistically significant difference in the study groups (H=14.426 *P*=.002). Measurements of IGF-1 IRS scores showed statistically significant differences in the study groups (H=14.350 *P*=.002).

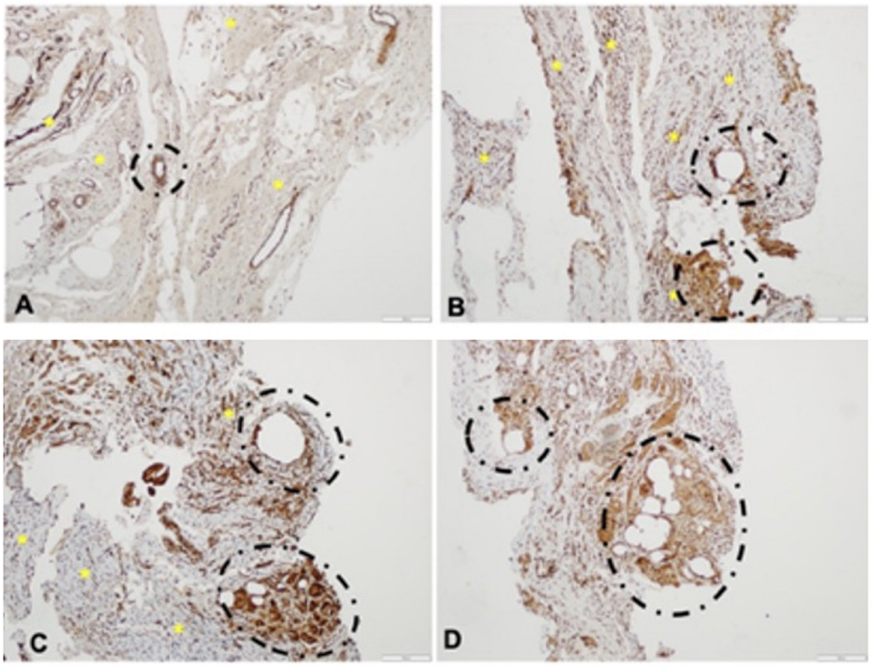

Figure 2. Microscopic image showing BMP-4 expression in K, E1, E2 and E3 groups. A: In the control group containing only PMMA; BMP 4 (+) cells are diffusely distributed in the connective tissue (*), and a small ossification center was also detected (black circle area with dashed lines). B: In the PMMA group containing 1 mg estrogen, dense BMP 4 (+) cells are commonly seen throughout the tissue (*), as well as the presence of small ossification centers (black circle area with dashed lines). C, D: In PMMA groups containing 2 mg estrogen and 4 mg estrogen, respectively, increased BMP 4 (+) cells (*) and an increased number of small ossification centers (black circle area with dashed lines). BMP 4 streptavidin- peroxidase × 10.

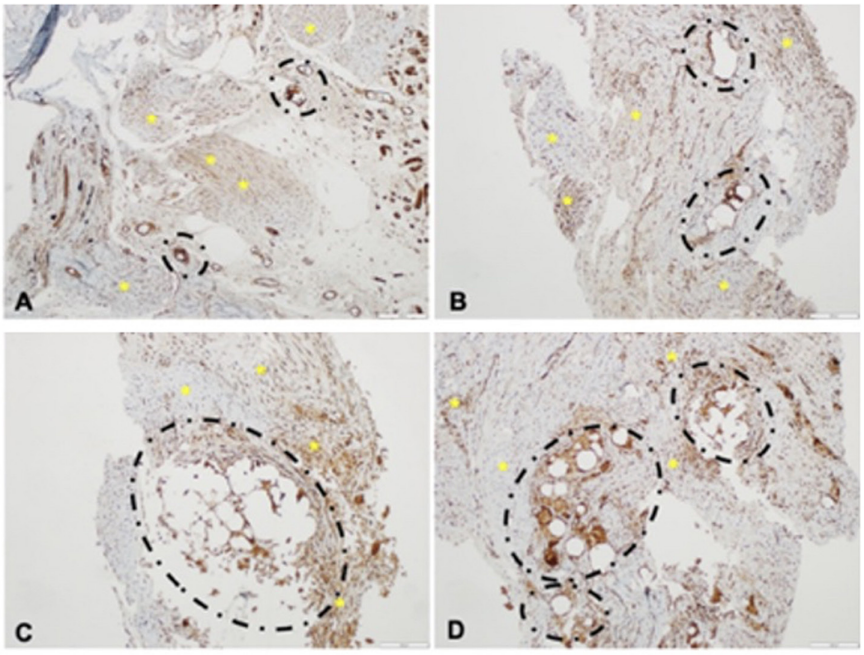

Figure 3. Microscopic image showing IGF-1 expression in K, E1, E2 and E3 groups. A: In the control group containing PMMA only; diffusely distributed IGF-1 (+) osteoprogenitor cells (*) and small areas of ossification can be seen (black circle area with dashed lines). B: In the 1 mg estrogen-containing PMMA group, there are more IGF-1 (+) cells (*) and prominent ossification islets (black circle area with dashed lines). C, D: In PMMA groups treated with increasing doses of estrogen including 2 mg estrogen and 4 mg estrogen respectively, intensely stained IGF-1 (+) progenitor cells (*) and areas of ossification with significantly increased numbers compared to the control group are obviously visible (black circle area with dashed lines). IGF-1 streptavidin-peroxidase × 10.

Table 2 shows the means and comparisons of the differences between the study groups for histologic scores. The E1 group was statistically significantly higher than the control group in histologic scores (P=.031). However, there was no statistically significant difference between the control group and E1 group in both BMP-4 IRS scoring (P=.087) and IGF-1 IRS scoring (P=.145). E2 group was significantly higher than the control group in histologic scoring (P=.005), BMP-4 IRS scoring (P=.012), and IGF-1 IRS scoring (P=.021). E3 group was significantly higher than the control group in histologic scoring (P < .001), BMP-4 IRS scoring (P < .001), and IGF-1 IRS scoring (P < .001). No significant differences were found between the E1 and E2 groups in any of the outcome measures in multiple comparisons (P > .05). In multiple comparisons, the E3 group achieved significantly higher scores than the E1 group on all outcome measures, including histological scoring (P=.014), BMP-4 IRS scoring (P=.048), and IGF-1 IRS scoring (P=.025). In multiple comparisons, group E3 achieved significantly higher histological scores than group E2 (P=.047). However, no statistically significant differences were observed between the E3 and E2 groups in terms of BMP-4 IRS (P=.243) and IGF-1 IRS scoring (P=.165).

Discussion

This study demonstrated that the addition of estradiol to the PMMA bone cement used in the first stage of the Masquelet technique significantly improved the quality of the resulting induced membrane. Both histological and immunohistochemical evaluations revealed a significant increase in osteogenic activity parallel to the increase in estrogen dose, suggesting a positive relationship between estrogen concentration and membrane quality. In the literature, estrogen has been shown to increase membrane quality, but there is no study on dose increase.[7]

Bone defects bring many problems such as difficulty in reconstruction, increased cost, prolonged hospitalization, problems that may be seen in the donor site and defect area, and the psychosocial status of the patient. In the study in which estrogen was added to the bone cement used for membrane induction in MT, it was observed in histopathologic and immunohistochemical evaluation parameters that new bone formation increased and this formation time was shortened.

Table 2. Multiple comparisons of histology scores, BMP-4 IRS scores, and IGF1 IRS scores by groups

	Groups					
	Control-E1	**Control-E2**	**Control-E3**	**E1-E2**	**E1-E3**	**E2-E3**
Histology						
X ± SE	−2.71 ± 0.56	−3.57 ± 0.56	−5.71 ± 0.56	−0.86 ± 0.56	−3.00 ± 0.56	−2.14 ± 0.56
Test (*P*)	***P*=.031**	***P* = .005**	***P* < .001**	*P* = .531	***P* = .014**	***P*=.047**
BMP4 IRS						
X ± SE	−1.00 ± 0.38	−1.43 ± 0.38	−2.00 ± 0.38	−0.43 ± 0.38	−1.00 ± 0.38	−0.57 ± 0.38
Test (*P*)	*P*=.087	***P* = .012**	***P* < .001**	*P* = .416	***P* = .048**	*P*=.243
IGF1 IRS						
X ± SE	−0.86 ± 0.39	−1.29 ± 0.39	−2.00 ± 0.39	−0.43 ± 0.39	−1.14 ± 0.39	−0.71 ± 0.39
Test (*P*)	*P*=.145	***P* = .021**	***P* < .001**	*P* = .397	***P* = .025**	*P*=.165

Bonferroni Dun Test, X ± SE: difference between means (mean difference ± standard error). Bold values indicate statistically significant differences after Bonferroni correction (p < 0.05).

Masquelet technique was described by Masquelet et al for the treatment of segmental critical-sized bone defects developing after trauma in adult patients using spongious bone grafts.[15]

Several studies on the clinical treatment of osteomyelitis using MT have been reported and satisfactory results have been observed.[16,17] When the induced membrane technique and conventional treatment methods were compared, it was shown to be superior in terms of hospitalization costs, treatment efficacy, number of operations, recovery time, and complications.[18,19] Masquelet and Begue reported that all 35 patients with bone defects achieved radiographic improvement after treatment with the induced membrane technique in their study.[5]

In a review conducted by Morelli et al in 2016, the union rate was shown to be 89.7% as a result of the Masquelet technique applied to 427 patients with bone defects ranging from 0.6 to 26 cm, and 7.7% of patients needed an additional union procedure to heal.[20]

Ilizarov segment shift technique is another bone reconstruction technique that is effective for defects over 20 cm in the treatment of bone defects. Masquelet technique has the advantage that the duration of treatment is independent of the length of the bone defect. The MT, which does not require prolonged use of external fixators, can be used in less compliant patients.[5] Avascular defective areas exposed to osteomyelitis or radiotherapy can be reconstructed using a vascularized fibula graft requiring microsurgery.[21,22] Masquelet technique does not require procedures that require microsurgery.

Nau et al investigated the effect of different antibiotics and cement on the membrane in an animal model and found that both the thickness and the ratio of elastic fibers varied significantly according to the antibiotic and cement used.[23] In a study using a rabbit model, PMMA was ectopically implanted into the subcutaneous tissue instead of bone defects, and it was shown that membranes with osteogenic and angiogenic properties were formed that secreted growth factors (VEGF, BMP-2, and TGFβ1) and increased osteoblastic differentiation.[16] Ziroğlu et al showed that the membrane formed by using antibiotic-supported bone cement in the first step of the MT improved membrane quality by increasing tissue levels of osteogenic factors such as TGF-β and VEGF.[7] Again, Ziroğlu et al compared the effects of fusidic acid, gentamicin, teicoplanin, and estrogen on the quality of the induced membrane and found that estrogen increased the quality of the induced membrane the most as a result of histologic evaluations.[7]

We decided to use rats in the study because of the increasing use of rats for the study of MT by creating critical-size bone defects and because nonunion models and fracture creation procedures in rats are well defined. Schmitz and Hollinger first mentioned the concept of critical size bone defect in 1986 and defined it as "the smallest size bone defect that will not heal during the life of an animal."[10] In their study, Heinrich et al examined the creation and characterization of the Masquelet technique in the critical size defect model in the rat femur, they created defects of 10 mm in size as the critical size.[24] Drosse et al showed that a 6 mm femoral defect in rats represented a critical size defect.[25] As mentioned in the section on the definition of critical-size bone defects, the defect interval determined by multiplying the diameter of the damaged bone diaphysis by 2.0 or 2.5 can also be defined as a critical-size bone defect.[26]

In the study by Masquelet et al, reconstruction with bone graft occurred approximately 6 weeks after the formation of a fibrous membrane induced by a foreign body-type inflammatory response around the cement placed in the bone resection site.[5,27] However, the stem cells present in the membrane after 2 weeks decreased after 4 and 6 weeks, while the amount of mature cells increased. This was followed by structural changes such as increased density and structuring of collagen fibers. At the same time, vascularization has been shown to improve significantly.[24,28] In light of this information, the killing date was determined to be approximately 6 weeks after the first operation.

Estrogen, which has a major role in female sex formation and development, is predominant in the female sex but also the male sex and has an anabolic effect on bone tissue as well as many other tissues in the body. Estrogen promotes mesenchymal stem cell differentiation by activating the BMP signaling pathway. As a result, osteoblast formation from preosteoblasts is increased.[29]

The BMP-2 and BMP-4 are in the same BMP subgroup due to the similarity of their amino acid sequences. The BMP-2, which is known to have an osteoinductive effect, is widely used in the treatment of bone fractures and non-union.[30,31] The BMP-4 has been detected together with BMP-2 in the newly formed osteoid matrix in the endochondral ossification area, especially in the callus tissue formed after fracture.[32] The presence of BMP-4, 6, 7, and 9 was observed in all IM specimens in a study conducted by Niikura et al in 2022 on 6 patients and based on immunohistochemical examination of the IM.[33] It has been shown that BMP-4-induced stem cells undergo osteogenic and chondrogenic differentiation in higher amounts than non-induced stem cells and thus increase osteoinductive activity.[34,35]

The IGF-1 can be synthesized in the liver, adipose tissue, heart, kidney, intestine, lung, pancreas, cartilage, and skeletal muscle and is mainly synthesized in the liver after birth. The IGF-1 is also released from the bone matrix and reduces the risk of fractures by promoting MSC differentiation into osteoblasts, increasing bone mass (BM), and maintaining bone mineral density. The IGF-1 stimulates the proliferation of mesenchymal stem cells and osteoprogenitors and also supports their differentiation into osteoblasts.[36,37]

In the study, the amount of expression of BMP-4 and IGF-1 in the IM immunohistochemically was evaluated. A significant increase in the IRS score of BMP-4 and IGF-1 expressed in the IM was observed with increasing estrogen dose.

Masquelet et al described the membrane formed around the bone cement as a 1-2 mm thick structure histologically resembling synovial tissue and providing support for bone healing. They also reported that it has a richly vascularized structure and may protect autologous bone grafts from resorption by inhibiting soft tissue invasion into the bone defect.[5]

Histological analysis is the gold standard in tissue examination for research or diagnostic purposes, both in terms of qualitative and quantitative measurement. It is used to analyze the stages of inflammation or healing and the presence and distribution of products formed in the surrounding tissue. Different staining methods can be used to identify structures ranging from cells and tissues to metal components.[38]

We quantitatively measured and analyzed the histological properties of the membrane (thickness and microvessel density) and the areas of new bone formation (cortical thickness). In the study in which the effect of different doses of estrogen on membrane formation was examined, histological scoring of the membranes was performed by

modifying the histological scoring system described by Huo et al.[11] It was observed that the dose increased estrogen significantly increased the histologic scoring compared to the control group. In addition, when the groups were compared with each other, it was shown that the histologic score of the E3 group increased significantly compared to the E1 and E2 groups.

The demonstration by Ziroğlu et al that estrogen-enriched cementum content was effective in the first step of MT led us to search for an answer to the question "Does the dose increase affect the membrane quality and formation time?"[7] In the statistical analysis of the obtained histopathologic and immunohistochemical evaluations and scoring, the data were significantly strong.

The results of the study showed that the quality of the membrane formed histologically and immunohistochemically increased. This gives hope that the membrane formation time of MT used in the treatment of critical bone defects can be realized at an earlier time with an increase in dose. However, objective and qualitative studies are still needed to shorten the treatment time and increase treatment success.

While the results are promising, certain limitations should be considered. Ethical constraints necessitated a controlled dose escalation to minimize the number of experimental groups, preventing a comprehensive evaluation of systemic effects. Additionally, although estrogen's osteogenic role is well-documented, its potential to induce a foreign body reaction remains a variable that was not specifically analyzed in the study. Another critical aspect is the mechanical integrity of the cement, as increased additive content may weaken its structural properties, an aspect that was beyond the scope of this investigation. Furthermore, given the novelty of the approach, a definitive reference point for the estrogen doses used was unavailable. Nonetheless, as one of the pioneering studies in this area, the findings provide a foundation for future research, guiding dose optimization and enhancing therapeutic efficacy. Finally, the osteogenic impact of estrogen that was assessed, did not measure its systemic effects or explore potential gender-based variations, which should be addressed in subsequent investigations. Despite these considerations, the findings contribute valuable insights into the regenerative potential of MT, underscoring the need for further targeted studies to optimize its clinical application in bone defect treatment.

Several limitations of this study stand out as important points to consider when interpreting the findings. First, the use of rats as an experimental model limits the direct generalizability of the findings to human biology. Only the first stage of the Masquelet technique was evaluated, and since grafting was not performed, the functionality of the resulting membrane could not be fully assessed. Although estrogen was administered locally, the possibility of its passage into the systemic circulation, albeit limited, cannot be ruled out. This failure to assess this possibility can be considered a limitation of the study. Finally, only histological and immunohistochemical evaluations were performed, and biomechanical analyses were not included. These limitations should be considered in the interpretation of the findings.

In conclusion, ongoing studies on the Masquelet technique indicate that the method still has room for improvement. Studies to determine the ideal cement type and connecting elements are important to increase the effectiveness of the method. The study demonstrated histopathological and immunohistochemical enhancement of the induced membrane in parallel with increasing estrogen dose, offering the potential to shorten the lengthy treatment period required for the Masquelet method. Although the findings are foundational, further preclinical studies and ultimately well-designed clinical trials are needed before this innovative approach can be applied to patient care.

Data Availability Statement: The data that support the findings of this study are available on request from the corresponding author.

Artificial Intelligence Usage Statement: The authors declared that no Artificial Intelligence Tool was used in the preparation of the manuscript.

Ethics Committee Approval: Ethical committee approval was received from the Ethics Committee of Bezmialem Vakıf University (Approval no: 2021/157, Date: 21.06.2021).

Informed Consent: N/A.

Peer-review: Externally peer-reviewed.

Author Contributions: Concept – G.T., B.T.; Design – M.U.Ç.; Supervision – M.G.B., N.Z.; Resources – F.Ö.; Materials – M.U.Ç., B.T.; Data Collection and/or Processing – M.P., F.Ö.; Analysis and/or Interpretation – G.T., B.T.; Literature Search – M.P., M.U.Ç.; Writing –M.U.Ç.; Critical Review – M.G.B., N.Z.

Declaration of Interests: Mustafa Gökhan Bilgili is a member of the Editorial Board of Acta Orthopaedica et Traumatologica Turcica. However, their involvement in the peer review process was solely as an author. Other authors have no conflict of interest to declare.

Funding: This study was supported by the Turkish Health Institutes Presidency (TUSEB) under the -program code 2022-ACİL-08 and project number 21303. We would like to thank them for their support of the project.

References

1. Lu Y, Lai CY, Lai PJ, et al. Induced membrane technique for the management of segmental femoral defects: A systematic review and meta-analysis of individual participant data. *Orthop Surg*. 2023;15(1):28-37. [CrossRef]
2. Xue N, Ding X, Huang R, et al. Bone tissue engineering in the treatment of bone defects. *Pharmaceuticals (Basel)*. 2022;15(7):879. [CrossRef]
3. Mauffrey C, Barlow BT, Smith W. Management of segmental bone defects. *J Am Acad Orthop Surg*. 2015;23(3):143-153. [CrossRef]
4. Mathieu L, Bilichtin E, Durand M, et al. Masquelet technique for open tibia fractures in a military setting. *Eur J Trauma Emerg Surg*. 2020;46(5):1099-1105. [CrossRef]
5. Masquelet AC, Begue T. The concept of induced membrane for reconstruction of long bone defects. *Orthop Clin North Am*. 2010;41(1):27-37; table of contents. [CrossRef]
6. Ziroglu N, Koluman A, Kaleci B, et al. The antibiotics supplemented bone cement improved the masquelet's induced membrane in a rat femur critical size defect model. *Injury*. 2023;54(2):329-338. [CrossRef]
7. Ziroglu N, Koluman A, Kaleci B, et al. Modified and alternative bone cements can improve the induced membrane: critical size bone defect model in rat femur. *Injury*. 2024;55(7):111627. [CrossRef]
8. Hadji P, Colli E, Regidor PA. Bone health in estrogen-free contraception. *Osteoporos Int*. 2019;30(12):2391-2400. [CrossRef]
9.)Kaluve AM, Le JT, Graham BM. Female rodents are not more variable than male rodents: A meta-analysis of preclinical studies of fear and anxiety. Neurosci Biobehav Rev. 2022 Dec;143:104962. doi:10.1016/j.neubiorev.2022.104962
10. Sun H, Godbout C, Hali K, et al. The induced membrane technique in animal models: a systematic review. *OTA Int*. 2022;5(1)(suppl):e176. [CrossRef]
11. Göksan SB, Şener N, Tözün İR, Göksan MA. Mechanical strenghth of antibiotic-loaded bone cement: A biomechanical study of Cemex bone cement with teicoplanin and tobramycin. Acta Ortho Traumatol Turc. 1997;31:245-249
12. Göğüş A, Akman S, Göksan SB, et al. Mechanical strength of antibiotic-impregnated bone cement on Day 0 and Day 15: a biomechanical study with Surgical Simplex P and teicoplanin. *Acta Orthop Traumatol Turc*. 2002;36(1):63-71.
13. Huo MH, Troiano NW, Pelker RR, et al. The influence of ibuprofen on fracture repair: biomechanical, biochemical, histologic, and histomorphometric parameters in rats. *J Orthop Res*. 1991;9(3):383-390. [CrossRef]
14. Kaya-Dagistanli F, Tanriverdi G, Altinok A, et al. The effects of alpha lipoic acid on liver cells damages and apoptosis induced by polyunsaturated fatty acids. *Food Chem Toxicol*. 2013;53:84-93. [CrossRef]
15. Masquelet AC, Fitoussi F, Begue T, et al. Reconstruction of the long bones by the induced membrane and spongy autograft. *Ann Chir Plast Esthet*. 2000;45(3):346-353.
16. Pelissier PH, Masquelet AC, Bareille R, et al. Induced membranes secrete growth factors including vascular and osteoinductive factors and could stimulate bone regeneration. *J Orthop Res*. 2004;22(1):73-79. [CrossRef]

17. Aho OM, Lehenkari P, Ristiniemi J, et al. The mechanism of action of induced membranes in bone repair. *J Bone Joint Surg Am*. 2013;95(7):597-604. [CrossRef]
18. Dzyuba GG, Reznik LB, Erofeev SA, et al. Efficiency of local cement reinforcing antibacterial implants in surgical treatment of long bones chronic osteomyelitis. *Khir Z NI Pirogova*. 2016;5(5):31-36. [CrossRef]
19. Marais LC, Ferreira N. Bone transport through an induced membrane in the management of tibial bone defects resulting from chronic osteomyelitis. *Strateg Trauma Limb Reconstr*. 2015;10(1):27-33. [CrossRef]
20. Morelli I, Drago L, George DA, et al. Masquelet technique: myth or reality? A systematic review and meta-analysis. *Injury*. 2016;47(suppl 6):S68-S76. [CrossRef]
21. Sales de Gauzy J, Fitoussi F, Jouve JL, et al. Traumatic diaphyseal bone defects in children. *Orthop Traumatol Surg Res*. 2012;98(2):220-226. [CrossRef]
22. Giannoudis PV, Faour O, Goff T, et al. Masquelet technique for the treatment of bone defects: tips-tricks and future directions. *Injury*. 2011;42(6):591-598. [CrossRef]
23. Nau C, Seebach C, Trumm A, et al. Alteration of Masquelet's induced membrane characteristics by different kinds of antibiotic enriched bone cement in a critical size defect model in the rat's femur. *Injury*. 2016;47(2):325-334. [CrossRef]
24. Henrich D, Seebach C, Nau C, et al. Establishment and characterization of the Masquelet induced membrane technique in a rat femur critical-sized defect model. *J Tissue Eng Regen Med*. 2016;10(10):E382-E396. [CrossRef]
25. Drosse I, Volkmer E, Seitz S, et al. Validation of a femoral critical size defect model for orthotopic evaluation of bone healing: A biomechanical, veterinary and trauma surgical perspective. *Tissue Eng Part C Methods*. 2008;14(1):79-88. [CrossRef]
26. Gugala Z, Lindsey RW, Gogolewski S. New approaches in the treatment of critical-size segmental defects in long bones. *Macromol Symp*. 2007;253(1):147-161. [CrossRef]
27. Alford AI, Nicolaou D, Hake M, et al. Masquelet's induced membrane technique: review of current concepts and future directions. *J Orthop Res*. 2021;39(4):707-718. [CrossRef]
28. Nau C, Simon S, Schaible A, et al. Influence of the induced membrane filled with syngeneic bone and regenerative cells on bone healing in a critical size defect model of the rat's femur. *Injury*. 2018;49(10):1721-1731. [CrossRef]
29. Cheng CH, Chen LR, Chen KH. Osteoporosis due to hormone imbalance: an overview of the effects of estrogen deficiency and glucocorticoid overuse on bone turnover. *Int J Mol Sci*. 2022;23(3):1376. [CrossRef]
30. Haubruck P, Tanner MC, Vlachopoulos W, et al. Comparison of the clinical effectiveness of Bone Morphogenic Protein (BMP) −Protei−roteiin (BMP) tein (BMP) effectiveness ononunions. *Orthop Traumatol Surg Res*. 2018;104(8):1241-1248. [CrossRef]
31. Major Extremity Trauma Research Consortium (METRC). A randomized controlled trial comparing rhBMP-2/Absorbable collagen sponge versus autograft for the treatment of tibia fractures with critical size defects. *J Orthop Trauma*. 2019;33(8):384-391. [CrossRef]
32. Kloen P, Di Paola M, Borens O, et al. BMP signaling components are expressed in human fracture callus. *Bone*. 2003;33(3):362-371. [CrossRef]
33. Niikura T, Oda T, Jimbo N, et al. Immunohistochemical analysis revealed the expression of bone morphogenetic proteins-4, 6, 7, and 9 in human induced membrane samples treated with the Masquelet technique. *J Orthop Surg Res*. 2022;17(1):29. [CrossRef]
34. Lee TJ, Jang J, Kang S, et al. Enhancement of osteogenic and chondrogenic differentiation of human embryonic stem cells by mesodermal lineage induction with BMP-4 and FGF2 treatment. *Biochem Biophys Res Commun*. 2013;430(2):793-797. [CrossRef]
35. Garg P, Mazur MM, Buck AC, et al. Prospective review of mesenchymal stem cells differentiation into osteoblasts. *Orthop Surg*. 2017;9(1):13-19. [CrossRef]
36. Locatelli V, Bianchi VE. Effect of GH/IGF-1 on bone metabolism and Osteoporsosis. *Int J Endocrinol*. 2014;2014:235060. [CrossRef]
37. Dixit M, Poudel SB, Yakar S. Effects of GH/IGF axis on bone and cartilage. *Mol Cell Endocrinol*. 2021;519:111052. [CrossRef]
38. Schaller B, Saulacic N, Imwinkelried T, et al. In vivo degradation of magnesium plate/screw osteosynthesis implant systems: soft and hard tissue response in a calvarial model in miniature pigs. *J Craniomaxillofac Surg*. 2016;44(3):309-317. [CrossRef]

Author Queries

JOB NUMBER: AOTT-2025-85-R1-(355)

JOURNAL: AOTT

Q1 If generative AI and/or LLM tools were used, the following statement should be included: “This study used [name of the tool/service] to [state the purpose, e.g., improve language, edit grammar, generate content, etc.] during the preparation of the manuscript.