Annals of Anatomy 258 (2025) 152374



Contents lists available at ScienceDirect

Annals of Anatomy

journal homepage: www.elsevier.com/locate/aanat



Geometric morphometric analysis of red fox (*Vulpes vulpes*) skulls using radiometric techniques at three and six months of development

Ozan Gündemir [a,*], İsa Özaydin [b], Ekin Emre Erkiliç [c], Olcay Öztürkler [d], Burak Büyükbaki [d], Alican Yilmaz [b], Vedat Onar [a], Uğur Aydin [b], Özgür Aksoy [b]

[a] Department of Anatomy, Faculty of Veterinary Medicine, Istanbul University-Cerrahpasa, Istanbul 34320, Türkiye
[b] Department of Surgery, Faculty of Veterinary Medicine, Kafkas University, Kars 36100, Türkiye
[c] Department of Internal Medicine, Faculty of Veterinary Medicine, Kafkas University, Kars 36100, Türkiye
[d] Department of Wildlife and Ecology, Faculty of Veterinary Medicine, Kafkas University, Kars 36100, Türkiye

ARTICLE INFO

Keywords:
Allometry
Carnivore
Cranium
Shape analysis
Veterinary anatomy
Wildlife

ABSTRACT

Background: Morphological growth naturally progresses with age; however, the rate of growth varies across different parts of an organism, with certain structures developing more rapidly than others. This study aimed to analyze and compare the skull development of red foxes (Vulpes vulpes) during two specific developmental stages: the 3rd and 6th months, which represent distinct growth phases in their early ontogeny.
Methods: In this study, we aimed to analyze and compare skull development in red foxes (*Vulpes vulpes*) during two specific post-natal time points: the 3rd and 6th months. Shape analysis was performed using radiographic images of nine red foxes at both the third and sixth months.
Results: Shape differences were observed in the skulls of red foxes (*Vulpes vulpes*) at these two ages. Our findings confirmed the hypothesis that skull shape changes over time, reflecting distinct morphological adaptations associated with age-related growth. In the measurements at the 3rd month, the neurocranial region exhibited a more distinct and developed structure compared to the facial bones. Toward the 6th month, the skull displayed a thinner and more elongated structure with the further development of the facial bones.
Conclusions: This difference indicates a period of rapid growth and development in the neurocranial area, suggesting that red foxes experience significant neurological and sensory development early in life. Future studies on skull shape variation across different developmental stages in red foxes can expand on these findings. Age-related morphological studies, such as this one, provide essential baseline data on the natural growth and development of wild species like red foxes. This knowledge is essential for identifying deviations from normal development, which could result from environmental stressors, habitat changes, or malnutrition.

1. Introduction

The Red Fox (Vulpes vulpes), the most widespread member of the *Canidae* family, is one of the most prevalent wild carnivores not only in Europe but also throughout various regions worldwide. Their ability to inhabit diverse geographic areas and adapt to different environments suggests a high level of ecological adaptability (Baker and Harris, 2004; Kobryn et al., 2023). Despite their adaptability, red foxes often favor areas near urban settlements, where they can more easily locate food resources (Kobryn et al., 2023). Their diet typically consists of human leftovers, domestic poultry, pet food, and small rodents, providing a reliable food supply in suburban and urban zones (Masters and Maher, 2022). The head morphology of red foxes, as with other mammals, reflects adaptations to their environment and diet. For a species like the red fox, which thrives across a broad geographic range and has a varied diet, the skull and jaw structure must accommodate diverse dietary needs and environmental demands. Therefore, morphological studies focused on red foxes are crucial for understanding their adaptability and ecological interactions.

The study of shape is fundamental to numerous biological research areas, providing key insights into structural and functional diversity among organisms (Klingenberg, 2022; Zelditch and Swiderski, 2023). Differences in morphological shapes can arise due to various biological factors, including developmental processes, genetic mutations, and

* Corresponding author.
E-mail address: ozan.gundemir@iuc.edu.tr (O. Gündemir).

https://doi.org/10.1016/j.aanat.2025.152374
Received 26 October 2024; Received in revised form 20 December 2024; Accepted 30 December 2024
Available online 3 January 2025
0940-9602/© 2025 Elsevier GmbH. All rights are reserved, including those for text and data mining, AI training, and similar technologies.

evolutionary adaptations, resulting in observable diversity among individuals (Boz et al., 2023; Viacava et al., 2023). Geometric morphometrics is considered one of the most sophisticated and efficient techniques for investigating structural morphology (Bookstein, 2023; Martin et al., 2023; Cardini, 2024; García-Medrano et al., 2020). This method not only allows for quantitative assessment but also offers a powerful visual representation of shape (Courtenay et al., 2024). In veterinary anatomy, geometric morphometrics has been widely applied to analyze the shapes of various anatomical structures, including the carcass, skull, scapula, and joints (Akçasiz et al., 2024; Gundemir et al., 2024; Guzel et al., 2024; Koçak et al., 2024).

Morphological growth naturally progresses with age; however, the rate of growth varies across different parts of an organism, with certain structures developing more rapidly than others. This variation is particularly pronounced in the skull, where size increases until puberty, but different regions grow at independent rates, reflecting functional and developmental adaptations. The aim of this study was to identify significant shape variations in the skull structure of red foxes (Vulpes vulpes) at two specific post-natal time points: the 3rd and 6th months. It is hypothesized that measurable shape differences occur between the 3rd and 6th months, as these are expected to be morphometrically distinct stages in skull development. By examining these periods morphologically using geometric morphometric and radiometric techniques, we aim to demonstrate growth-related shape changes in the same individuals. This approach is particularly valuable as the use of radiological methods enables the evaluation of data from the same individuals at different time points, minimizing individual variability and providing more accurate information about developmental changes.

2. Materials and methods

2.1. Animals and anaesthesia

The present study was conducted on nine red foxes of both sexes (5 males, 4 females), housed at the Kafkas University Wildlife Protection, Rescue, Rehabilitation, Research, and Application Center in Kars, Türkiye. Radiometric and morphometric analyses were performed twice when the animals were at 3 and 6 months old. Radiographic procedures were performed under anaesthesia induced by 6.2 mg/kg (IM) xylazine HCl (Beltazyn 2 %, Doğa İlaç®, Istanbul) and 17.1 mg/kg (IM) ketamine HCl (Keta-Control, 100 mg/mL, Doğa İlaç®, Istanbul) following a 12-h fasting period.

The selection of the 3rd and 6th months for this study is based on key developmental milestones observed in red foxes (*Vulpes vulpes*). Examination of ontogenetic variability in similar species has revealed that skull length undergoes rapid growth during the first six months of life, with the skull reaching its full length by the age of six months (Hartová-Nentvichová et al., 2010). To capture this progression, we chose the 6th month as a representative time point for fully developed skulls. Additionally, the 3rd month was selected as it represents the midpoint of this rapid growth phase, allowing us to examine developmental changes during an active growth period.

2.2. Radiographic imaging

The radiographs were captured using a high-resolution digital X-ray system (Fujifilm FCR Prima T2 [Dynamic X-RAY™, Ankara, Türkiye]), with exposure settings optimized for small mammal skulls. To perform geometric morphometrics analysis, radiographs were taken of each skull in two projections: dorsoventral (D/V) and lateral. For lateral images, animals were positioned on the X-ray table in lateral recumbency and images were taken after the skull had been positioned on the cassette with the mouth closed. Radiographs were taken of each skull in two projections: dorsoventral (D/V) and lateral. For the D/V view, animals were positioned on their ventral side with the skull symmetrically placed on the X-ray cassette. Special care was taken to ensure that the nasal planum and cervical vertebrae were aligned with the central axis of the cassette to minimize distortion and achieve accurate imaging.

Linear measurements were performed on the radiographic images using the Radiant DICOM Viewer (version 2024.1) software. Skull length and width were recorded in centimetres (cm) to ensure precise and consistent data collection. All measurements were conducted by the same individual to minimize inter-observer variability and enhance the reliability of the results.

2.3. Landmark placement

To facilitate landmark digitization, a TPS file was created for each set of images. The TPS files were generated using the tpsUtil software (version 1.74), creating two separate files: one for D/V images and one for lateral images. These files served as the primary input for landmark operations. After creating the TPS files, landmarks were digitized using TpsDig software (version 2.32). For the D/V images, 13 semi-landmarks were placed along the lateral border in a curve format to capture the shape of key structures, such as the posterior-most point of the skull, temporal contours, and the zygomatic arch (Fig. 1). For the lateral images, 10 semi-landmarks were positioned along the dorsal border of the skull to capture the shapes of the frontal peak, nasal bone, and occipital region of the skull (Fig. 1). To finalize the coordinates, the "tps curve to landmarks" option in tpsUtil (version 1.74) was used. This process ensured that the TPS files contained all necessary curve coordinates, with both landmark and semi-landmark points accurately prepared for subsequent morphometric analysis.

2.4. Geometric morphometrics and statistical analysis

MorphoJ software (version 1.07) was employed to conduct the statistical analyses. To prepare the data, landmark coordinates were first aligned using a Procrustes fit. This alignment process minimized non-shape variation due to differences in scale, rotation, and translation among the samples. Following this, a Generalized Procrustes Analysis (GPA) was performed to standardize the data, making it suitable for further statistical examination. Principal component analysis (PCA) was applied to uncover major patterns of shape variation within the data set. Principal components (PCs) were extracted from the PCA, with PC1 and PC2 accounting for the largest proportions of shape variance. Wireframe plots were created to visually depict positive and negative changes along these PCs, highlighting the curvature and structural modifications in skull shape across samples. To examine shape differences between the two groups (3-month-old and 6-month-old foxes), a discriminant function analysis (DFA) was conducted. A permutation test with 1000 iterations was applied to assess the statistical significance of the observed differences between the groups. Procrustes distance values were calculated for each comparison, providing a metric of shape difference between groups. The statistical significance of these differences was evaluated using p-values, with $p < 0.05$ considered statistically significant.

To assess the allometric effect, two linear measurements—skull length (akrokranion to prosthion) and skull width (zygion to zygion)—were taken in millimeters from the radiological images (Fig. 2) (Jashari et al., 2022). To determine the influence of these linear measurements on skull shape, a multivariate linear regression analysis was performed. In this analysis, PC1 values, representing the primary shape variable from the principal component analysis, were used as the dependent variable. Statistical analyses were performed using PAST statistical software (version 4.14).

3. Result

As a result of the study, linear measurements were obtained from 18 fox skulls. For 3-month-old foxes, the average skull length was 10.43 cm, while the average skull width measured 5.97 cm. In contrast, the skulls

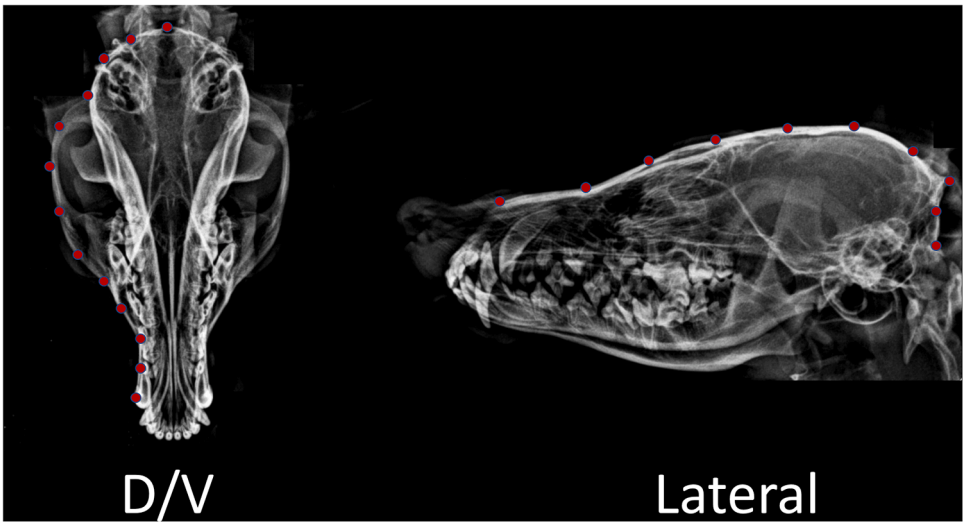

Fig. 1. Semilandmarks for D/V and Lateral view. In the dorsoventral (D/V) images (13 landmarks), landmarks were strategically placed along the lateral border of the skull as viewed from the dorsal perspective. This placement captured the contours and specific anatomical features along the skull's side edges in the dorsal view. In the lateral images (10 landmarks), landmarks were positioned along the upper (dorsal) border of the skull, defining the shape of the skull's upper contour when viewed from the side.



Fig. 2. Linear measurements. Skull width: The length between the widest points of the zygomatic arch (zygion to zygion); Skull length: From the most posterior point (akrokranion) of the skull to the most anterior point (prosthion) of the incisive bone.

of 6-month-old foxes had an average length of 12.96 cm and a width of 7.18 cm. The data on skull length and width across both age groups followed a normal distribution, and the measurements between the two age groups were found to be statistically significant ($p < 0.05$). As anticipated, the skulls of 6-month-old foxes were notably both longer and wider, reflecting the natural growth and developmental changes in skull morphology with age.

For geometric morphometrics, both dorsal (D/V) and lateral radiological images of the skull were utilized. In the dorsal view, 13 landmarks were placed along the lateral border of the skull. Principal Component Analysis (PCA) identified a total of 16 principal components (PCs). The first principal component (PC1), which explained the highest degree of variation, accounted for 58.84 % of the total variance observed (Fig. 3A). The second principal component (PC2) explained 17.76 %, while the third principal component (PC3) accounted for 7.19 % of the variation. For the lateral view, 10 landmarks were used along the dorsal border of the skull. In this analysis, PC1 again explained the majority of the variation, accounting for 56.02 % of the total variance (Fig. 3B). PC2 explained 15.13 %, and PC3 captured 12.36 % of the variance.

In the shape analysis of both the dorsal and lateral borders of the skull, PC1 was the most significant, explaining more than half of the total variation in both cases. Six-month-old foxes exhibited negative PC1 values for the lateral border, whereas the dorsal border showed positive PC1 values in the shape analysis. Conversely, three-month-old foxes demonstrated the opposite pattern, suggesting distinct age-related changes in skull morphology.

In the analysis of the skull's lateral border (as observed in the dorsal view), the primary shape variation identified was the skull becoming narrower in width and longer in overall structure. Specifically, at positive PC1 values, the posterior regions of the skull exhibited a more oval shape with a rounded appearance, which was predominantly observed in three-month-old foxes. This contrasts with the six-month-old foxes, where the skull shape tended to be more elongated and less oval, reflecting a developmental shift in cranial morphology. In PC2, a notable shape variation was observed in the zygomatic arch. At negative PC2 values, the zygomatic arch appeared more pronounced and laterally expanded. Overall, the six-month-old foxes tended to exhibit lower PC2

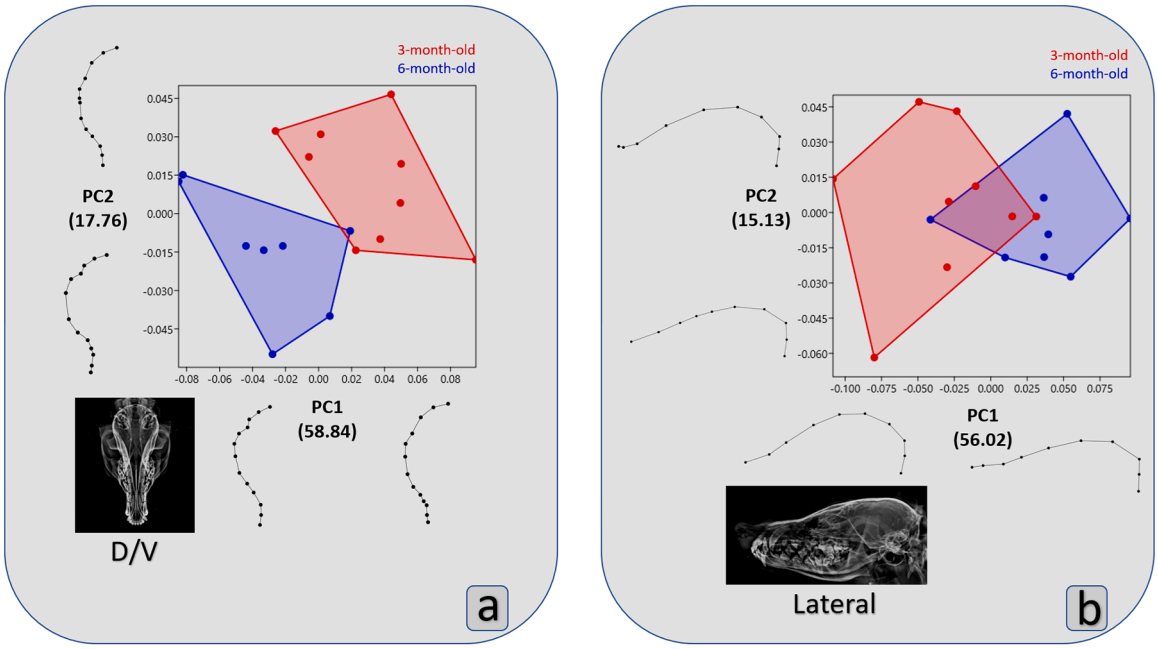

Fig. 3. Principal component analysis of skulls. Wire-frame warp plots of changes in orbit shape of fox skull for dorsal and lateral views. a: PCA results for D/V; b: PCA results for lateral view.

values.

For the dorsal border of skull (lateral view), notable shape changes were observed in the neurocranial region. As PC1 increased, the neurocranium exhibited a shorter yet broader configuration, with the frontal part of the skull becoming more oval, particularly at negative PC1 values. At positive PC1 values, the occipital part appeared flatter, while at negative PC1 values, it exhibited a more oval shape. In three-month-old foxes, the skull shape was more oval with a higher frontal part, demonstrating a unique cranial development compared to the older foxes. This analysis underscores the dynamic nature of skull morphology during early growth stages, with distinct structural adaptations occurring between 3 and 6 months of age. In PC2, a shape variation was observed in the nasal bone. At negative PC2 values, the nasal bone appeared straighter, whereas at positive PC2 values, it exhibited an upwardly curved structure. However, PC2 was not a distinguishing factor among the groups, as the variation observed in PC2 was primarily individual.

It was expected that the three-month-old and six-month-old foxes would differ in size due to their developmental stages. However, the study also conducted a shape analysis to explore not only size differences but also potential differences in skull shape. The shape analysis revealed individual variations in skull morphology, highlighting subtle differences between foxes within each age group. To further investigate whether these shape variations were distinct enough to classify the foxes into their respective age groups, a DFA was performed. The results, presented in Fig. 4, demonstrated that the two age groups were completely distinguishable based on their skull shapes. The DFA effectively separated the three-month-old and six-month-old foxes, indicating that their cranial morphology followed distinct trajectories as they matured. This separation suggests that age-related changes in skull shape are pronounced and can be used to reliably differentiate between younger and older foxes, beyond mere size differences.

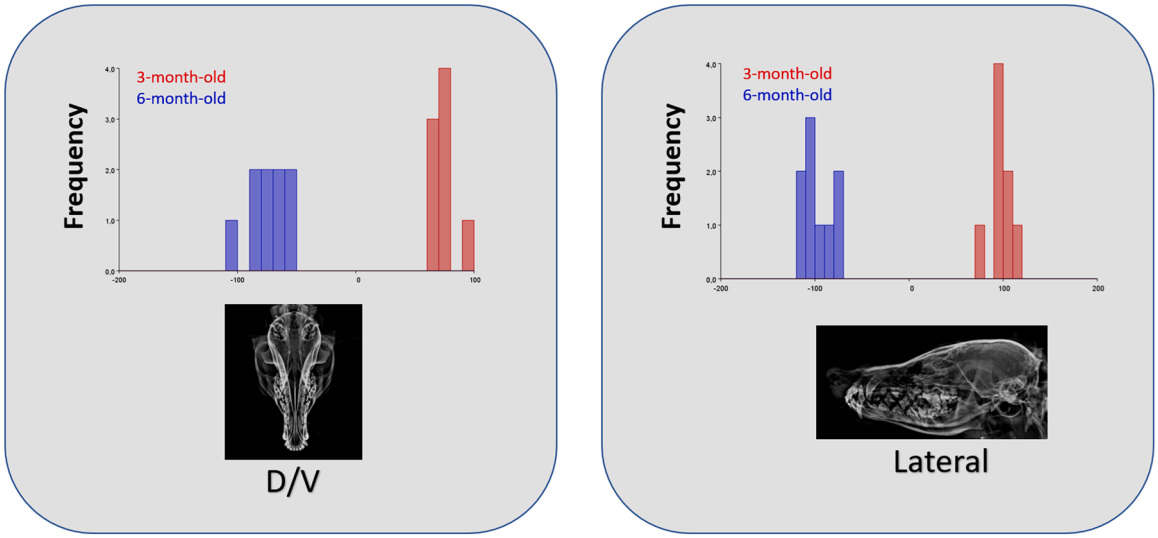

Fig. 4. Frequency Distribution on Discriminant Analysis Results.

To investigate the allometric effect, the influence of linear skull measurements—specifically skull length and skull width—on skull shape was examined. PC1, which accounted for the largest portion of variation in the shape analysis, was used as the primary shape variable. A multivariate linear regression analysis was performed to assess the relationship between PC1 values and the linear measurements of the skull (Fig. 5).

The results showed that all linear measurements had a statistically significant effect on skull shape in both the lateral and dorsal views ($p < 0.05$). Among these measurements, skull length exhibited the greatest allometric effect, with an R^2 value of 0.3446, indicating that approximately 34 % of the variation in skull shape could be explained by changes in skull length. The analysis yielded an F-statistic of 7.886, further confirming the strength of this relationship ($p < 0.05$).

4. Discussion and conclusion

The study identified clear and statistically significant shape differences in the skulls of red foxes (*Vulpes vulpes*) at two critical developmental stages (3rd and 6th months of age). By comparing these two time points, we were able to confirm our hypothesis that the skull shape would change over time, reflecting distinct morphological adaptations in response to age-related growth demands. The shape analysis revealed that these differences were most evident in both dorsoventral (D/V) and lateral views. In the D/V view, the neurocranial region, which houses and protects the brain, displayed increased height and distinctness compared to facial part in three-month-old red foxes. This difference indicates a period of rapid growth and development in the neurocranial area, potentially suggesting that red foxes experience significant neurological and sensory development early on. An allometric analysis, which investigates how changes in size impact shape, further confirmed that as the skull increased in size from three months old to six months old, this growth was not uniform across all skull regions. The linear measurements of skull length and width significantly influenced overall shape changes, showing that different skull parts grow at different rates.

The observation that the neurocranial region exhibits a more distinct and developed structure compared to the facial bones reflects the rapid development of the nervous system during early life stages. This pattern aligns with the prioritization of neurocranial growth to support critical survival functions such as sensory processing, spatial navigation, and defensive behaviors, particularly in wild environments. Such adaptations likely confer significant survival advantages in wild canids like red foxes (Vulpes vulpes), where sensory acuity and cognitive abilities are essential for successful foraging and effective interaction with their surroundings. By prioritizing neurocranial development, these species ensure that their sensory and cognitive systems are well-equipped to handle the challenges of their ecological niche. Research has established a strong link between neurocranial growth and brain development, suggesting that brain growth significantly influences the shape of the neurocranial region (Nie, 2005; Ross and Ravosa, 1993). Consequently, the neurocranium is one of the fastest-developing skeletal regions, outpacing the facial bones in growth rate. For instance, a study on mice investigating postnatal craniofacial skeletal growth found that during the initial three weeks, the most substantial development occurred in the posterior zygomatic width and interparietal width (Wei et al., 2017). As these regions rapidly expanded, this growth rate eventually slowed, while the width of the facial region continued to increase consistently with age. Another mouse study also highlighted that cranial width was primarily established early in development, with minimal changes after three weeks of age (Vora et al., 2016). However, it was noted that facial width continued to increase, though at a more gradual pace, even after overall skull growth had slowed. Our findings in red foxes align with these reference studies, supporting the pattern of early neurocranial growth. The red foxes demonstrated significant early development of the

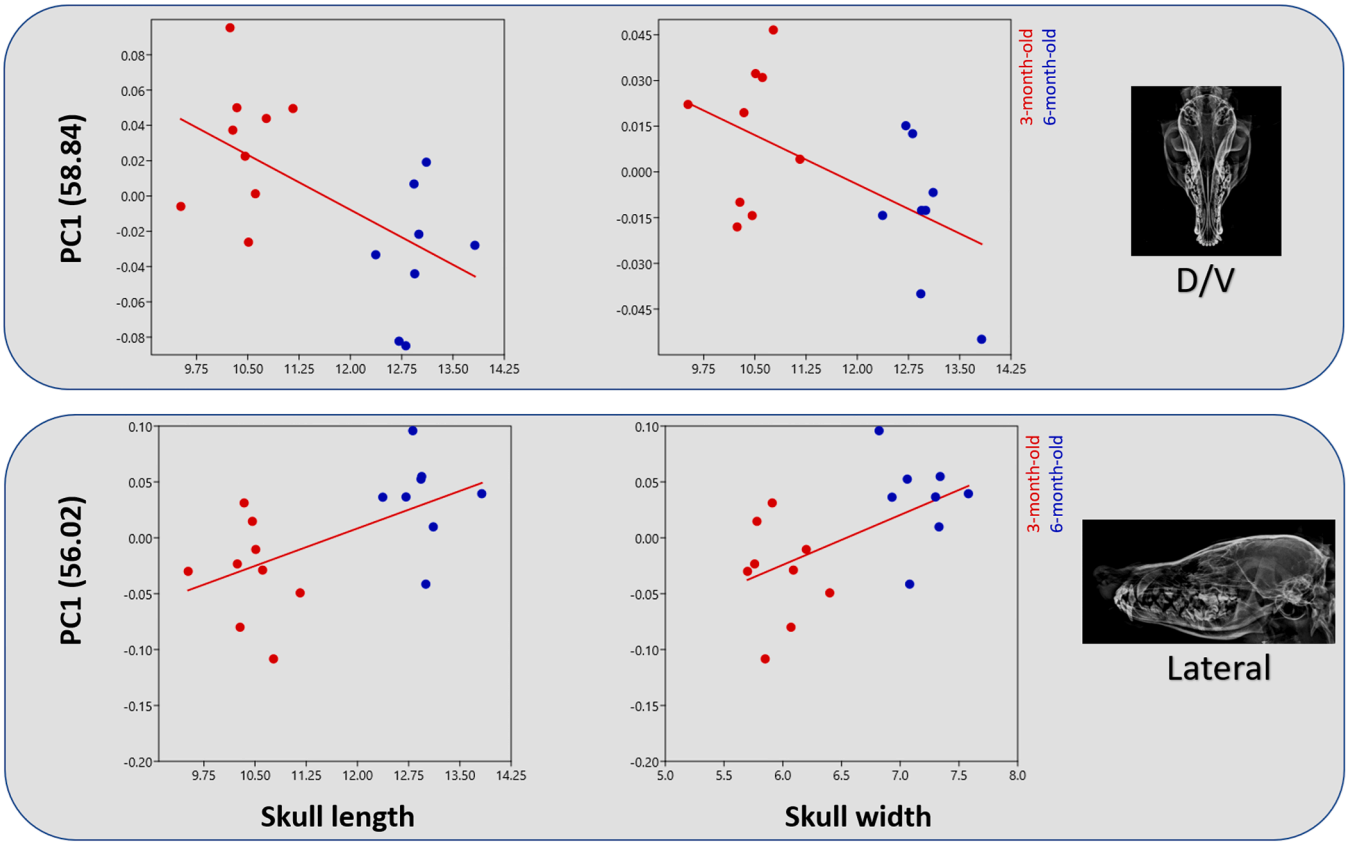

Fig. 5. Relationships of linear measurements to shape.

neurocranial region, which was observed to shape skull morphology prominently in early life stages. In the earlier three-month-old developmental stage, the skull's shape was more rounded, with a more developed neurocranial region compared to the facial region. This rounded, pronounced neurocranium is indicative of an early emphasis on developing the braincase, suggesting that brain growth and sensory organ development may be prioritized over facial and dental structures in younger red foxes. This pattern aligns with what we see in many mammals, where early growth focuses on areas that support neurological maturation and sensory processing, such as sight and smell, which are essential for foraging and predator awareness.

Animals often undergo shape changes as body size increases through ontogeny or phylogeny, highlighting the influence of size on shape (Klingenberg, 2016; Slater and Van Valkenburgh, 2009). For instance, studies on avian species have identified skull allometry, linking shape changes to ecological adaptations (Natale and Slater, 2022). Similarly, research in rodents has revealed that skull allometric properties can impact bite force, illustrating a functional relationship between morphology and feeding behaviors (Ginot et al., 2018). In canines, Selba et al., (2020) noted the role of facial allometry in dietary adaptation, showing how skull shape aligns with specific feeding habits in dogs. In this study on red foxes, skull size was found to significantly influence shape. Like previous findings in birds, these allometric traits may be linked to environmental variables. Alternatively, as seen in studies of dogs and rodents, skull morphology could correlate with bite mechanics and diet in red foxes. Further studies, with larger sample sizes and more detailed habitat data, could investigate how environmental factors shape these allometric effects in red fox populations.

Radiometric techniques provide a valuable, non-invasive tool for advancing veterinary anatomical studies, particularly in understanding skeletal and developmental changes (Akbas et al., 2023; Keneisenuo et al., 2022). The radiological method used in the study helped minimize individual variability, allowing for a more accurate evaluation of developmental changes. In animal studies, radiometric analysis has been successfully employed to assess bone shapes, which are essential for understanding health and developmental concerns without disrupting the natural growth process or behavior of the animals (Manuta et al., 2023; Mutlu et al., 2023, Senol et al., 2022; Ozkan et al., 2024). In studies of wild animals like red foxes, radiometric imaging is particularly advantageous; it enables researchers to capture detailed developmental data across life stages, facilitating comparisons that might otherwise require invasive or impractical techniques. As technology advances, the precision and accessibility of radiometric techniques in veterinary anatomy promise to unlock even more detailed data, from cellular-level changes in bone density to the impact of environmental factors on growth. This versatility makes radiometric studies an invaluable resource in both academic research and clinical applications, supporting animal welfare and advancing knowledge across diverse animal species. Additionally, imaging systems, 3D scanning, and artificial intelligence techniques, among many other technological tools, are making significant contributions to veterinary anatomy (Choudhary, 2021, Choudhary et al., 2023, Choudhary et al., 2024; Korkmazcan et al., 2025; Vickram et al., 2024).

This study investigated postnatal skull development in red foxes by applying traditional linear measurements and detailed shape analysis to two key developmental stages. The findings show that combining these methods to capture both size and shape variation in skull morphology provides more detailed morphological insights. This combined approach not only highlights specific growth patterns in the neurocranial and facial regions of the red fox but also offers valuable insights into age-related morphological adaptations. As these techniques are applied to a variety of species, findings from similar studies may shed light on the underlying causes of skeletal adaptations. Morphometric analyses, particularly in wild and free-ranging species, enhance our understanding of how skeletal structures respond to ecological pressures and developmental milestones. Comparative studies with other canid species could provide a broader reference framework by contextualizing individual growth patterns within broader adaptive trends. Additionally, addressing the environmental factors or genetic influences on skull development could further enrich future research in this field. Such studies can deepen our knowledge of species' life stages and habitat requirements, improving wildlife management and conservation strategies.

Funding

Not applicable.

Ethical Statement

This study was approved by the Kafkas University Animal Experiments Local Ethics Committee (Approval no: KAÜ-HADYEK/2024/142). The research permissions were obtained with the letter dated 08.08.2024 and numbered E-21264211–288.04–15350094 from the Republic of Türkiye, Ministry of Agriculture and Forestry, General Directorate of Nature Conservation and National Parks.

CRediT authorship contribution statement

Ozan Gündemir: Writing – original draft, Methodology, Conceptualization. **Alican Yilmaz:** Data curation, Conceptualization. **Vedat Onar:** Writing – review & editing, Conceptualization. **Uğur Aydin:** Writing – review & editing, Conceptualization. **Özgür Aksoy:** Writing – review & editing, Project administration. **İsa Özaydin:** Writing – review & editing, Supervision, Project administration, Conceptualization. **Ekin Emre Erkiliç:** Writing – review & editing, Data curation. **Olcay Öztürkler:** Visualization, Validation, Data curation. **Burak Büyükbaki:** Writing – review & editing, Methodology.

Declaration of Competing Interest

The authors declare that they have no known competing financial interests or personal relationships that could have appeared to influence the work reported in this paper.

References

Akbas, Z.S., Duro, S., Yalin, E.E., Gündemir, O., Özkan, E., Szara, T., 2023. Detection of sexual dimorphism of the foramen magnum in cats using computed tomography. Anat. Histol. Embryol. 52 (4), 595–602. https://doi.org/10.1111/ahe.12920.

Akçasiz, Z.N., Akbaş, Z.S., Özkan, E., Manuta, N., Saritaş, Ö., Szara, T., Spataru, M.C., Kaya, D.A., 2024. Geometric morphometric analysis of scapula at cats and dogs. Kafkas Univ. Vet. Fak. Derg. 30 (4), 481–487. https://doi.org/10.9775/kvfd.2024.31683.

Baker, P.J., Harris, S., 2004. Red foxes. The behavioural ecology of red foxes in urban Bristol. In: Macdonald, D.W., Sillero-Zubiri, C. (Eds.), Biology and Conservation of Wild Canids. Oxford University Press, Oxford, pp. 207–216.

Bookstein, F.L., 2023. Reworking geometric morphometrics into a methodology of transformation grids. Evol. Biol. 50 (3), 275–299. https://doi.org/10.1007/s11692-023-09607-2.

Boz, İ., Altundağ, Y., Szara, T., Hadziomerovic, N., Ince, N.G., Pazvant, G., Kahvecioglu, O., Ozkan, E., Manuta, N., Gundemir, O., 2023. Geometric morphometry in veterinary anatomy. Veterinaria 72 (1), 15–27. https://doi.org/10.51607/22331360.2023.72.1.15.

Cardini, A., 2024. A practical, step-by-step, guide to taxonomic comparisons using Procrustes geometric morphometrics and user-friendly software (part A): introduction and preliminary analyses. Eur. J. Taxon. 934 (1), 1–92. https://doi.org/10.5852/ejt.2024.934.2527.

Choudhary, O.P., 2021. Three-dimensional computed tomography reconstructions: a tool for veterinary anatomy education. Ann. Med. Surg. 11 (67), 102497. https://doi.org/10.1016/j.amsu.2021.102497.

Choudhary, O.P., Infant, S.S., Vickram, A.S., Chopra, H., Manuta, N., 2024. Exploring the potential and limitations of artificial intelligence in animal anatomy. Ann. Anat., 152366 https://doi.org/10.1016/j.aanat.2024.152366.

Choudhary, O.P., Saini, J., Challana, A., Choudhary, O., Saini, J., Challana, A., 2023. ChatGPT for veterinary anatomy education: an overview of the prospects and drawbacks. Int. J. Morphol. 41 (4), 1198–1202.

Courtenay, L.A., Aramendi, J., González-Aguilera, D., 2024. A graph-based mathematical model for more efficient dimensionality reduction of landmark data in geometric

morphometrics. Evol. Biol. 51, 310–329. https://doi.org/10.1007/s11692-024-09636-5.
García-Medrano, P., Maldonado-Garrido, E., Ashton, N., Ollé, A., 2020. Objectifying processes: the use of geometric morphometrics and multivariate analyses on Acheulean tools. J. Lithic Stud. 7 (1), 1–16. https://doi.org/10.2218/jls.4327.
Ginot, S., Herrel, A., Claude, J., Hautier, L., 2018. Skull size and biomechanics are good estimators of in vivo bite force in murid rodents. Anat. Rec. 301 (2), 256–266. https://doi.org/10.1002/ar.23711.
Gundemir, M., Yildiz, A., Büyükünal, S., Muratoğlu, K., Özkan, E., Demircioglu, A., Choudhary, O.P., Guzel, B., 2024. Evaluation of cold Carcasses of Kivircik and Romanov lambs by geometric morphometric method. Kafkas Univ. Vet. Fak. Derg. 30 (1), 87–94. https://doi.org/10.9775/kvfd.2023.30539.
Guzel, B.C., Manuta, N., Ünal, B., Ruzhanova-Gospodinova, I.S., Duro, S., Gündemir, O., Szara, T., 2024. Size and shape of the neurocranium of laying chicken breeds. Poult. Sci. 103 (9), 104008. https://doi.org/10.1016/j.psj.2024.104008.
Hartová-Nentvichová, M., Anděra, M., Hart, V., 2010. Cranial ontogenetic variability, sex ratio and age structure of the red fox. Cent. Eur. J. Biol. 5, 894–907. https://doi.org/10.2478/s11535-010-0093-2.
Jashari, T., Kahvecioğlu, O., Duro, S., Gündemir, O., 2022. Morphometric analysis for the sex determination of the skull of the Deltari Ilir dog (Canis lupus familiaris) of Kosovo. Anat. Histol. Embryol. 51 (4), 443–451. https://doi.org/10.1111/ahe.12807.
Keneisenuo, K., Choudhary, O.P., Kalita, P.C., Duro, S., Kalita, A., Doley, P.J., Priyanka, P., 2022. A comparative study on the morphology, radiography and computed tomography of the skull bones of barking deer (Muntiacus muntjak) and sambar deer (Rusa unicolor). Folia Morphol. 81 (1), 164–174.
Klingenberg, C.P., 2016. Size, shape, and form: concepts of allometry in geometric morphometrics. Development genes and evolution. Dev. Genes. Evol. 226 (3), 113–137. https://doi.org/10.1007/s00427-016-0539-2.
Klingenberg, C.P., 2022. Methods for studying allometry in geometric morphometrics: a comparison of performance. Evol. Ecol. 36 (4), 439–470. https://doi.org/10.1007/s10682-022-10170-z.
Kobryn, H.T., Swinhoe, E.J., Bateman, P.W., Adams, P.J., Shephard, J.M., Fleming, P.A., 2023. Foxes at your front door? Habitat selection and home range estimation of suburban red foxes (Vulpes vulpes). Urban Ecosyst. 26 (1), 1–17. https://doi.org/10.1007/s11252-022-01252-5.
Koçak, S., Özaydin, İ., Gündemir, O., 2024. Shape analysis of the carpal joint in healthy and septic arthritis in newborn calves. Anat. Histol. Embryol. 53 (4), e13080. https://doi.org/10.1111/ahe.13080.
Korkmazcan, A., Ünal, B., Bakıcı, C., Gündemir, O., 2025. Exploring skull shape variation and allometry across different chicken breeds. Ank. Univ. Vet. Fak. Derg. 72 (1), 1–7. https://doi.org/10.33988/auvfd.1454398.
Manuta, N., Gündemir, O., Yalin, E.E., Karabağli, M., Uçmak, Z.G., Dal, G.E., Gürbüz, İ., 2023. Pelvis shape analysis with geometric morphometry in crossbreed cats. Anat. Histol. Embryol. 52 (4), 611–618. https://doi.org/10.1111/ahe.12919.
Martin, B.E., O'Malley, B., Eshenroder, R.L., Kao, Y.C., Olds, C.M., O'Brien, T.P., Davis, C.L., 2023. Comparison of traditional and geometric morphometrics using Lake Huron ciscoes of the Coregonus artedi complex. Trans. Am. Fish. Soc. 152 (3), 296–309. https://doi.org/10.1002/tafs.10403.
Masters, H.M., Maher, C.R., 2022. Diet reveals potential for competition and coexistence among coyotes (Canis latrans), red foxes (Vulpes vulpes), and gray foxes (Urocyon cinereoargenteus). Can. J. Zool. 100 (2), 90–97. https://doi.org/10.1139/cjz-2021-0103.
Mutlu, Z., Karabağli, M., Altundağ, Y., Erdikmen, D.O., Kaya, D.A., Özkan, E., Günay, E., 2023. Radiogrametric analysis of the metapodial bones in english setters. Kafkas Univ. Vet. Fak. Derg. 29 (2), 117–123. https://doi.org/10.9775/kvfd.2022.28650.
Natale, R., Slater, G.J., 2022. The effects of foraging ecology and allometry on avian skull shape vary across levels of phylogeny. Am. Nat. 200 (4), E174–E188. https://doi.org/10.1086/720745.
Nie, X., 2005. Cranial base in craniofacial development: developmental features, influence on facial growth, anomaly, and molecular basis. Acta Odontol. Scand. 63 (3), 127–135. https://doi.org/10.1080/00016350510019847.
Ozkan, E., Unal, B., Altundag, Y., Mutlu, Z., Avanus, K., 2024. Allometry and atlas shape analysis between tekir and mix-breed cats. Kafkas Univ. Vet. Fak. Derg. 30 (1). https://doi.org/10.9775/kvfd.2023.30549.
Ross, C.F., Ravosa, M.J., 1993. Basicranial flexion, relative brain size, and facial kyphosis in nonhuman primates. Am. J. Phys. Anthropol. 91 (3), 305–324. https://doi.org/10.1002/ajpa.1330910306.
Selba, M.C., Oechtering, G.U., Heng, H.G., DeLeon, V.B., 2020. The impact of selection for facial reduction in dogs: geometric morphometric analysis of canine cranial shape. Anat. Rec. 303 (2), 330–346. https://doi.org/10.1002/ar.24184.
Senol, E., Gündemir, O., Duro, S., Szara, T., Demiraslan, Y., Karadağ, H., 2022. A pilot study: Can calcaneus radiographic image be used to determine sex and breed in cats? Vet. Med. Sci. 8 (5), 1855–1861. https://doi.org/10.1002/vms3.899.
Slater, G.J., Van Valkenburgh, B., 2009. Allometry and performance: the evolution of skull form and function in felids. J. Evol. Biol. 22 (11), 2278–2287. https://doi.org/10.1111/j.1420-9101.2009.01845.x.
Viacava, P., Blomberg, S.P., Weisbecker, V., 2023. The relative performance of geometric morphometrics and linear-based methods in the taxonomic resolution of a mammalian species complex. Ecol. Evol. 13 (3), e9698. https://doi.org/10.1002/ece3.9698.
Vickram, A.S., Infant, S.S., Chopra, H., 2024. AI-powered techniques in anatomical imaging: impacts on veterinary diagnostics and surgery. Ann. Anat. 258, 152355. https://doi.org/10.1016/j.aanat.2024.152355.
Vora, S.R., Camci, E.D., Cox, T.C., 2016. Postnatal ontogeny of the cranial base and craniofacial skeleton in male C57BL/6J mice: a reference standard for quantitative analysis. Front. Physiol. 12 (6), 417. https://doi.org/10.3389/fphys.2015.00417.
Wei, X., Thomas, N., Hatch, N.E., Hu, M., Liu, F., 2017. Postnatal craniofacial skeletal development of female C57BL/6NCrl mice. Front. Physiol. 8, 697. https://doi.org/10.3389/fphys.2017.00697.
Zelditch, M.L., Swiderski, D.L., 2023. The predictable complexity of evolutionary allometry. Evol. Biol. 50 (1), 56–77. https://doi.org/10.1007/s11692-022-09581-1.