OPEN

CASE REPORT
Reconstructive

Mandibular Metastases of Papillary Thyroid Carcinoma Treated by Hemimandibulectomy and Costochondral Rib Graft

Ugur Anil Bingol, MD*
Can Cinar, MD*
Oguz Cetinkale, MD†

Summary: Papillary thyroid carcinoma (PTC) is the most common and well-differentiated cancer of the thyroid. Unlike most cancers, spread to local lymph node does not worsen the survival rate of PTC, and complete resection of the metastases seems to be important and may have favorable effects on the prognosis. A 33-year-old woman was referred to our clinic with a mass involving the right angulus mandible. Incisional biopsy of the mass diagnosed follicular variant of papillary thyroid carcinoma. Right hemimandibulectomy was performed and reconstructed with costochondral rib graft. The patient survived for 5 years after the hemimandibulectomy. Metastases to the oral cavity indicate a grave prognosis, but PTC has relatively indolent biological behavior; long-term survival is usually possible even in patients with metastatic disease. *(Plast Reconstr Surg Glob Open 2015;3:e305; doi: 10.1097/GOX.0000000000000275; Published online 18 February 2015.)*

Carcinoma of the thyroid gland is a rare cancer but is the most common malignancy of the endocrine system.[1] Papillary thyroid carcinoma (PTC) is the most common and well-differentiated cancer of the thyroid (nearly 85%).[2,3] PTC is a curable disease, generally grows slowly, and the prognosis is very good. The mean survival rate after 10 years is higher than 90%.[4] Metastases are due to invasion of lymphatics and spread to the lymph nodes. Vascular involvement is very rare. The prognosis for differentiated carcinoma is better for patients younger than 40 years without extracapsular extension or vascular invasion.[2–5] PTC has some different characteristics and can behave very differently; unlike most cancers, spread to local lymph node does not worsen the survival rate,[6] and complete resection of the metastases seems to be important and may have favorable effects on the prognosis.[7] Distant metastases almost always indicate a grave prognosis for cancer patients, but PTC deserves special attention because PTC has relatively indolent biological behavior; long-term survival is usually possible even in patients with bone metastases. Only 4 cases of mandibular metastases of PTC have been previously reported in the English-language literature.[8–11] Here, we present a case of PTC with metastasis to the mandible.

*From the *Department of Plastic, Reconstructive and Aesthetic Surgery, Yeditepe Medical School, Yeditepe University, Istanbul, Turkey; and †Department of Plastic, Reconstructive and Aesthetic Surgery, Cerrahpasa Medical School, Istanbul University, Istanbul, Turkey.*
Received for publication November 25, 2014; accepted January 5, 2015.
Copyright © 2015 The Authors. Published by Wolters Kluwer Health, Inc. on behalf of The American Society of Plastic Surgeons. All rights reserved. This is an open-access article distributed under the terms of the Creative Commons Attribution-NonCommercial-NoDerivatives 3.0 License, where it is permissible to download and share the work provided it is properly cited. The work cannot be changed in any way or used commercially.
DOI: 10.1097/GOX.0000000000000275

CASE REPORT

A 33-year-old woman was referred to our clinic with a mass dimension 4×5 cm, involving the right angulus mandible. Physical examination showed that the mass was painless, firm, and fixed to mandible. A computed tomography scan showed a 6×5 × 3 cm soft-tissue mass with the right angulus mandible with bony destruction and extension to the lingual cortex.

She had a medical history of thyroid gland surgery when she was 20 years old because of PTC. Six years later, she had an operation again because of

Disclosure: *The authors have no financial interest to declare in relation to the content of this article. The Article Processing Charge was paid for by the authors.*

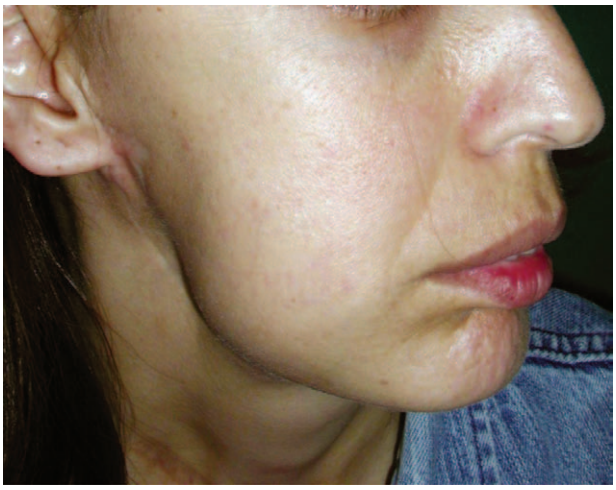

Fig. 1. Lateral view of the patient's face after surgery.

recurrence and also treated by radioactive iodine. When she was 30, she had 2 operations by orthopedic surgeons because of metastases to pelvic bones and humerus.

An incisional biopsy of the mass was performed and the diagnosis was follicular variant of papillary thyroid carcinoma (FVPTC). A right hemimandibulectomy was performed and reconstructed with costochondral rib graft(Fig. 1). The postoperative period was uneventful. She went to home 1 week after surgery. The patient was given a high-dose radioiodine therapy again. After surgery, there was no recurrence at the mandible. Five years after the hemimandibulectomy, when she was 37 years old, she died due to multisystem metastases, especially metastases to the central nervous system.

DISCUSSION

Carcinoma of the thyroid gland is a rare cancer but is the most common malignancy of the endocrine system.[1] Thyroid cancer usually occurs in people between the ages of 25 and 65, and most patients present before the age of 40. The age seems to be the single most important prognostic factor.[12] They tend to grow very slowly, especially in young patients. FVPTC is the most common subtype of PTC after conventional PTC (pure form).[13]

Metastatic tumors to the oral region are rare (approximately 1% of all malignant oral tumors), and they can affect oral soft tissues or jaw bones. Oral region is not a preferred site for metastases. They are hard to diagnose, and it is hard to distinguish them from inflammatory and reactive lesions of oral region. Usually, they are secondary spread from other metastatic lesions. The primary site differed between the genders: for women, it was the breasts followed by the adrenal, colorectum, female genital organs, and thyroid; for men, it was lung followed by the prostate, kidney, bone, and adrenal.[14–16] Metastases to jaw bones are more common than metastases to oral mucosa (ratio 2.5:1). Breast is the most common primary site for tumors that metastasizes to jaw bones, and lung is the most common source for cancers that metastasizes to the oral soft tissues.[15] Patients with metastases to jaw bones are younger than those with metastases to oral soft tissues. In the jaw bones, the molar area is the preferred area for metastatic lesions[15,16] (remnants of the red bone marrow most commonly found at posterior mandible).

Metastasis from PTC to mandible is a rare situation and should be kept in mind with the other differential diagnoses of tumors in the facial region. FVPTC is a totally different situation; patients had a high ratio of distant metastases, few lymph node metastases, and soft-tissue invasion.[17] The most common sites of distant metastases were bone and lung.[11]

Under normal conditions, metastases to the oral cavity indicate a grave prognosis, but metastatic thyroid tumors deserve special attention because despite the presence of distant metastases, PTC has relatively indolent biological behavior; long-term survival is usually possible even in patients with metastatic disease, with a reported 79.4% 5-year survival rate and 52.9% 10-year survival rate in patients with bone metastases.[18] In our case, the interval between cancer diagnosis and death was 17 years. Unlike other cancers, surgery for metastases of PTC may have favorable effects on the prognosis.[7] Some authors advocate surgery for the bone metastases from PTC to prevent or to treat complications of these metastases to decrease morbidity and to improve quality of life.[18]

The free fibula flap continues to remain the "gold standard" and best option for mandibular reconstruction. In our patient, the bone defect was 6 cm. The size of the defect was not a clear indication for free fibula flap; this size defect is in "gray zone" between nonvascularized bone grafts and free bone flaps. We prefer nonvascularized bone graft because the defect was 6 cm long and in a nonirradiated area. Also the patient and her family refused long time-consuming major surgery. We did not plan a "plates-only" reconstruction because of high complication rates and low success rates.

CONCLUSIONS

PTCs are slow-growing tumors; in most cases, patients with PTC have long survival rate even with distant metastases. The goal of surgical reconstruction of metastatic lesions of PTC should provide stable and durable construction that will allow functionality and will persist for long term. Reconstructive surgeons should give a chance to patients with meta-

static PTC for long-term, stable, and complex reconstructive surgery options and must avoid temporary, unstable reconstructive surgical options. Proper surgical treatment of these metastatic lesions may result in decrease in morbidity and improve prognosis and quality of life.

Ugur Anil Bingol, MD
Department of Plastic
Reconstructive and Aesthetic Surgery
Yeditepe Medical School
Yeditepe University
Devlet Yolu Ankara Cad No102-104
34752 Kozyatağı
Istanbul, Turkey
E-mail: ugur.bingol@yeditepe.edu.tr

REFERENCES

1. Hundahl SA, Fleming ID, Fremgen AM, et al. A National Cancer Data Base report on 53,856 cases of thyroid carcinoma treated in the U.S., 1985–1995. *Cancer* 1998;83:2638–2648.
2. Khan A, Nose V. In: Lloyd RV, ed. *Endocrine Pathology: Differential Diagnosis and Molecular Advances*. 2nd ed. New York: Springer; 2010:181–236.
3. Ito Y, Kihara M, Takamura Y, et al. Prognosis and prognostic factors of papillary thyroid carcinoma in patients under 20 years. *Endocr J*. 2012;59:539–545.
4. Malterling RR, Andersson RE, Falkmer S, et al. Differentiated thyroid cancer in a Swedish county—long-term results and quality of life. *Acta Oncol*. 2010;49:454–459.
5. Grant CS, Hay ID, Gough IR, et al. Local recurrence in papillary thyroid carcinoma: is extent of surgical resection important? *Surgery* 1988;104:954–962.
6. Guo K, Wang Z. Risk factors influencing the recurrence of papillary thyroid carcinoma: a systematic review and meta-analysis. *Int J Clin Exp Pathol*. 2014;7:5393–5403.
7. Niederle B, Roka R, Schemper M, et al. Surgical treatment of distant metastases in differentiated thyroid cancer: indication and results. *Surgery* 1986;100:1088–1097.
8. Erdag T, Bilgen C, Ceryan K. Metastatic thyroid carcinoma of the mandibule. *Rev Laryngol Otol Rhinol (Bord)*. 1999;120:31–34.
9. Itro A, Carotenuto A, Aquino S, et al. Metastases to the human mandible. *Minerva Stomatol*. 1999;48:543–552.
10. Colella G, Capone R, Cappabianca S. Mandibular metastasis from papillary thyroid carcinoma—a case report. *Tumori* 2003;89:452–454.
11. Liu L, Venkataraman G, Salhadar A. Follicular variant of papillary thyroid carcinoma with unusual late metastasis to the mandible and the scapula. *Pathol Int*. 2007;57:296–298.
12. Mazzaferri EL. Treating differentiated thyroid carcinoma: where do we draw the line? *Mayo Clin Proc*. 1991;66:105–111.
13. Ivanova R, Soares P, Castro P, et al. Diffuse (or multinodular) follicular variant of papillary thyroid carcinoma: a clinicopathologic and immunohistochemical analysis of ten cases of an aggressive form of differentiated thyroid carcinoma. *Virchows Arch*. 2002;440:418–424.
14. Hirshberg A, Leibovich P, Buchner A. Metastases to the oral mucosa: analysis of 157 cases. *J Oral Pathol Med*. 1993;22:385–390.
15. Hirshberg A, Buchner A. Metastatic tumours to the oral region. An overview. *Eur J Cancer B Oral Oncol*. 1995;31B:355–360.
16. Hirshberg A, Leibovich P, Buchner A. Metastatic tumors to the jawbones: analysis of 390 cases. *J Oral Pathol Med*. 1994;23:337–341.
17. Chang HY, Lin JD, Chou SC, et al. Clinical presentations and outcomes of surgical treatment of follicular variant of the papillary thyroid carcinomas. *Jpn J Clin Oncol*. 2006;36:688–693.
18. Wu K, Hou SM, Huang TS, et al. Thyroid carcinoma with bone metastases: a prognostic factor study. *Clin Med Oncol*. 2008;2:129–134.