Clin Exp Dermatol 2024; **00**:1–3
https://doi.org/10.1093/ced/llae244
Advance access publication date: 24 June 2024

CED
Clinical and Experimental Dermatology
Memorable Patient

Erythematous annular atrophic patchy lesions in the bilateral axillae

Tugba K Uzuncakmak,[1] Emre Bayındır,[1] Ayse M Onenerk[2] and Melike Melikoglu[3]

[1]Istanbul University – Cerrahpasa, Cerrahpasa Medical Faculty, Department of Dermatology, Fatih, Turkey
[2]Istanbul University – Cerrahpasa, Cerrahpasa Medical Faculty, Department of Pathology, Fatih, Turkey
[3]Istanbul University – Cerrahpasa, Cerrahpasa Medical Faculty, Department of Rheumatology, Fatih, Turkey
Correspondence: Tugba Kevser Uzuncakmak. Email: tugbakevser@gmail.com

Dermatomyositis (DM) is a common idiopathic inflammatory myopathy usually characterized by proximal muscle weakness, skin lesions and systemic manifestations. Both cellular and humoral immunity have important roles in the development of DM. Humoral immunity has important effects in the pathogenesis of DM through various mechanisms, particularly involving B cells and autoantibodies. B cells are important in the pathogenesis of DM, as evidenced by the relative efficacy of B-cell-directed treatments such as rituximab in the treatment of idiopathic inflammatory myopathies (IIMs). It is also known from biopsies that, in DM, muscle is infiltrated by $CD20^+$ B cells in a perivascular distribution, predominantly within the perimysium.

Furthermore, 60–70% of people with an IIM have myositis-specific (approximately 50%) or myositis-associated (approximately 20%) antibodies produced by plasma cells and, to a lesser extent, plasmablasts. These antibodies may play a direct role in disease pathology. For example, in DM, several autoantibodies such as anti-transcriptional intermediary factor 1 (TIF1)-γ and anti-melanoma differentiation-associated protein 5 (MDA-5) have been associated with specific clinical symptoms and outcomes. The presence of these autoantibodies is associated with different DM phenotypes, which may include severe skin rashes, increased risk of malignancy and interstitial lung disease, depending on the antibody involved.[1] Skin findings in DM are the most important manifestations of the disease. Accurate evaluation of the lesions is important for early diagnosis.[2]

A 43-year-old man was referred by Rheumatology for a 1-month history of pruritic red lesions in the bilateral axillae. The lesions were first considered to be candidal intertrigo and topical sertaconazole and naftifine were prescribed by the rheumatologist. The patient stated no difference after this topical antifungal treatment. Upon interrogation of the patient's medical history, it was learned that he had been diagnosed with DM 2 years previously and had tried various immunosuppressive agents, including mycophenolate mofetil, methotrexate, azathioprine, intravenous immunoglobulin and rituximab, at different times postdiagnosis.

Physical examination revealed erythematous annular atrophic patchy lesions in the bilateral axillae (Figure 1a). Wood lamp examination, which was performed to rule out erythrasma or tinea corporis, revealed no reflex in the lesions (Figure 1b). On dermatoscopic examination, branched linear vessels were seen on skin-coloured structureless areas in the axillary lesions. These findings were considered to be compatible with the dermatoscopic appearance of DM lesions (Figure 1c).

A 4-mm punch biopsy from an axillary lesion showed interphase changes with orthohyperkeratosis, mild basal vacuolar degeneration, dyskeratotic keratinocytes in the epidermis, and vascular proliferation, perivascular lymphocytes and histiocytes in the upper dermis (Figure 2a). Colloidal iron and alcian blue staining showed increased dermal mucin. These histopathological findings were consistent with DM (Figure 2b).

The common cutaneous symptoms of DM are pruritus and photosensitivity, symptoms that severely affect a patient's quality of life (QoL). In a study that evaluated the effect of DM on patients' QoL, it was found that DM caused a greater deterioration in QoL than atopic dermatitis or psoriasis.[3] Pruritus was prominent in our patient's axillary lesions.

Patients with DM are categorized according to muscle and skin involvement: (i) the classical form, which has simultaneous skin and muscle involvement; (ii) the amyopathic form, which has only skin involvement (no muscle involvement); (iii) the hypomyopathic form in which skin involvement is not accompanied by clinically significant muscle involvement but muscle involvement is detected subclinically (serological testing for muscle enzymes, electromyography, muscle

Accepted: 16 June 2024
© The Author(s) 2024. Published by Oxford University Press on behalf of British Association of Dermatologists. This is an Open Access article distributed under the terms of the Creative Commons Attribution-NonCommercial License (https://creativecommons.org/licenses/by-nc/4.0/), which permits non-commercial re-use, distribution, and reproduction in any medium, provided the original work is properly cited. For commercial re-use, please contact reprints@oup.com for reprints and translation rights for reprints. All other permissions can be obtained through our RightsLink service via the Permissions link on the article page on our site—for further information please contact journals.permissions@oup.com.

Downloaded from https://academic.oup.com/ced/advance-article/doi/10.1093/ced/llae244/7697988 by - user on 27 August 2024

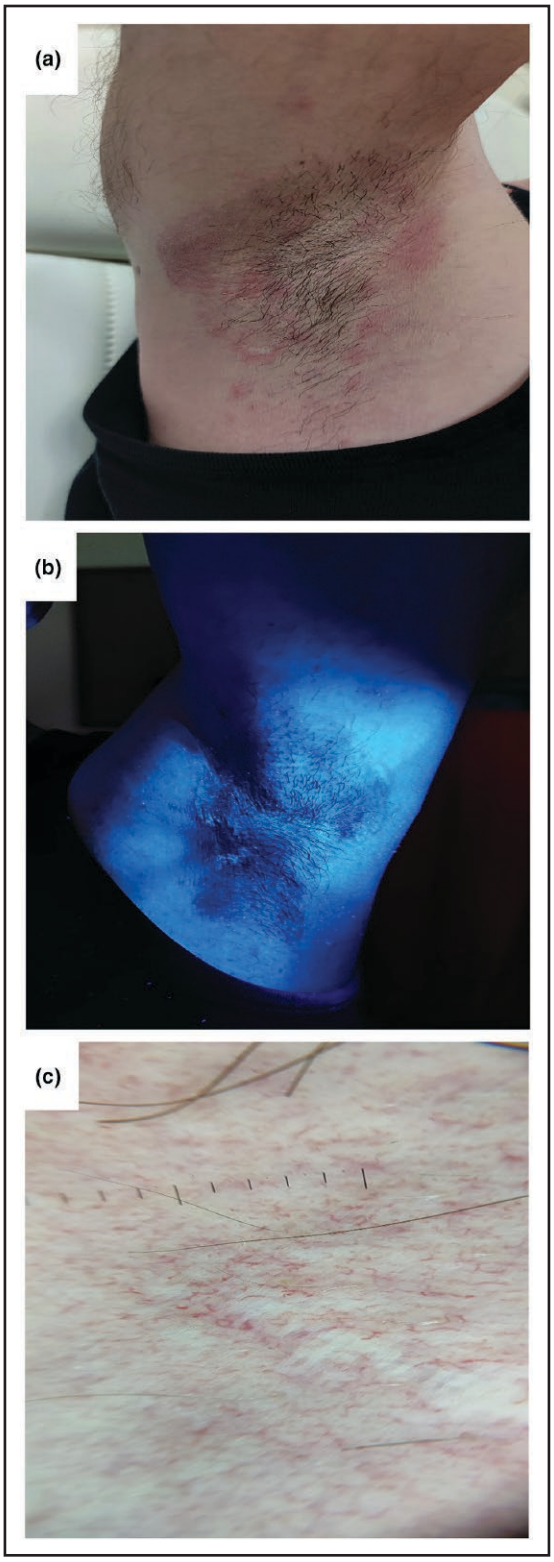

Figure 1 (a) Erythematous annular atrophic patchy lesions in the axillae; (b) no reflex in the lesion under a Wood lamp; (c) on dermatoscopy, branched linear vessels were seen in skin-coloured structureless areas in the axillary lesions.

biopsy or magnetic resonance imaging); (iv) the postmyopathic form in which muscle involvement regresses with immunosuppressive therapy, but only skin involvement persists; and (v) the paraneoplastic form, which accompanies malignancies.

The cutaneous manifestations of DM may vary. Traditionally, skin findings have been divided into pathognomonic (Gottron papules, Gottron sign and heliotrope rash), characteristic (nailfold changes, shawl sign, V sign and holster sign), compatible (poikiloderma and periorbital oedema), less common (vesiculobullous, necrotic or ulcerative lesions), rare (mechanic's hands, flagellate erythema) and nonspecific lesions (Raynaud phenomenon).[4]

Although a few case studies have reported tumoral calcinosis causing superficial ulcerations and acanthosis nigricans causing a hyperpigmented appearance in the axilla – especially in juvenile dermatomyositis[5] – axillary skin involvement is not usually an expected presentation in DM. Our patient's axillary lesions were initially considered by rheumatology to be candidal intertrigo. In fact, owing to the presence of erythematous and pruritic patches in the axillae in our patient (who was under immunosuppressive treatment for DM), candidal intertrigo was considered in the differential diagnosis.[6] However, failure of the lesions to regress with topical antifungal treatment led us away from this diagnosis.

Only a few cases of axillary skin involvement in DM have been reported. Our patient was diagnosed with dermatoscopically and histopathologically confirmed axillary DM, and is the first case, to our knowledge, to be reported in the literature.

We would like to remind clinicians that DM may involve different cutaneous sites and may also cause deterioration in the QoL of affected patients.

Funding sources

This research received no specific grant from any funding agency in the public, commercial or not-for-profit sectors.

Conflicts of interest

The authors declare no conflicts of interest.

Data availability

The data underlying this article will be shared on reasonable request to the corresponding author.

Ethics statement

Not applicable.

Patient consent

Written patient consent for publication was obtained.

Downloaded from https://academic.oup.com/ced/advance-article/doi/10.1093/ced/llae244/7697988 by - user on 27 August 2024

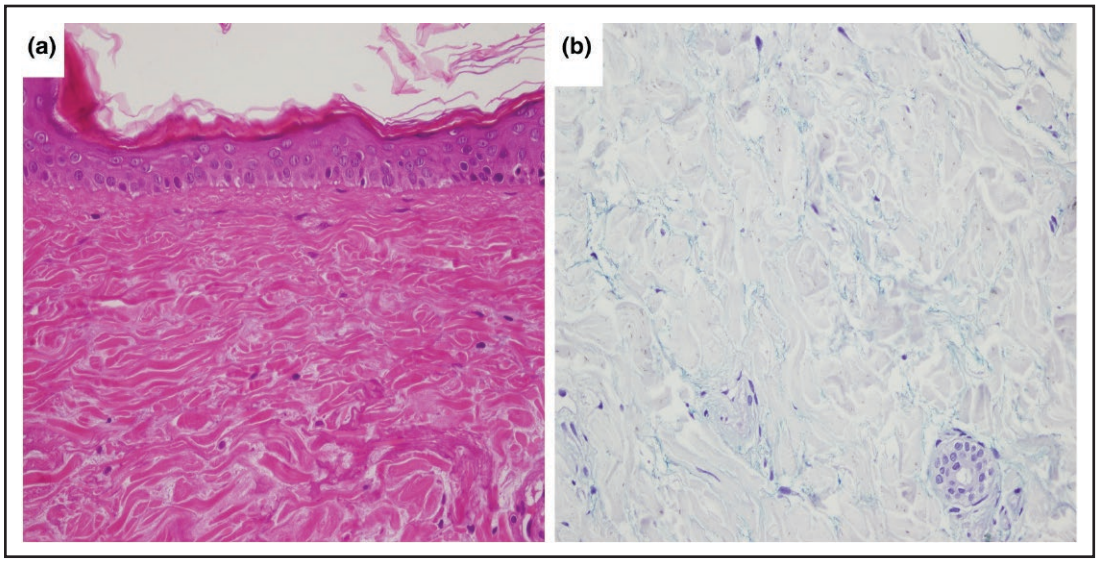

Figure 2 (a) Epidermal atrophy with loss of rete ridges with basal vacuolar degeneration (haematoxylin and eosin, magnification×200); (b) presence of slightly increased dermal mucin (alcian blue, magnification×200).

References

1 Kamperman RG, van der Kooi AJ, de Visser M *et al.* Pathophysiological mechanisms and treatment of dermatomyositis and immune mediated necrotizing myopathies: a focused review. *Int J Mol Sci* 2022; **23**:4301.
2 Muro Y, Sugiura K, Akiyama M. Cutaneous manifestations in dermatomyositis: key clinical and serological features – a comprehensive review. *Clin Rev Allergy Immunol* 2016; **51**:293–302.
3 Hundley JL, Carroll CL, Lang W *et al.* Cutaneous symptoms of dermatomyositis significantly impact patients' quality of life. *J Am Acad Dermatol* 2006; **54**:217–20.
4 DeWane ME, Waldman R, Lu J. Dermatomyositis: clinical features and pathogenesis. *J Am Acad Dermatol* 2020; **82**:267–81.
5 Dugan EM, Huber AM, Miller FW *et al.* Photoessay of the cutaneous manifestations of the idiopathic inflammatory myopathies. *Dermatol Online J* 2009; **15**:1.
6 Nobles T, Miller RA. Intertrigo. Available at https://www.ncbi.nlm.nih.gov/books/NBK531489 (last accessed 18 July 2024).

CPD questions

Learning objective

To gain knowledge of the characteristic clinical and cutaneous signs of dermatomyositis.

Question 1

Which of the following signs is pathognomonic for dermatomyositis?

(a) Flagellate erythema.
(b) Heliotrope rash.
(c) Mechanic's hands.
(d) Poikiloderma.
(e) Raynaud phenomenon.

Question 2

Which of the following is the most likely category of dermatomyositis in which skin involvement is not accompanied by clinically significant muscle involvement but subclinical muscle involvement findings are seen?

(a) Amyopathic dermatomyositis.
(b) Classic dermatomyositis.
(c) Hypomyopathic dermatomyositis.
(d) Paraneoplastic dermatomyositis.
(e) Postmyopathic dermatomyositis.

Downloaded from https://academic.oup.com/ced/advance-article/doi/10.1093/ced/llae244/7697988 by - user on 27 August 2024