Biologia
https://doi.org/10.1007/s11756-025-01881-z

ORIGINAL ARTICLE

Morphological and morphometric study of the head skeleton of the Balkan chamois (*Rupicapra rupicapra balcanica* Bolkay, 1925) in the West Balkan area

Sokol Duro[1] · Ozan Gündemir[2] · Nedžad Hadžiomerović[3] · Dražen Kotrošan[4] · Tomasz Szara[5]

Received: 4 June 2024 / Accepted: 28 January 2025
© Plant Science and Biodiversity Centre, Slovak Academy of Sciences (SAS), Institute of Zoology, Slovak Academy of Sciences (SAS), Institute of Molecular Biology, Slovak Academy of Sciences (SAS) 2025

Abstract

The Balkan chamois (*Rupicapra rupicapra balcanica* Bolkay, 1925), one of the subspecies of the Alpine chamois, is one important faunal representative of the Balkan region listed as Near Threatened by the International Union for Conservation of Nature (IUCN) because of habitat loss, hunting, and disturbance by human activities. The study aimed to document the morphological and morphometrical parameters of the skull and mandible of *R. r. balcanica*. The sexual dimorphism detection of the Balkan chamois skull was another study objective. In total, 47 and 18 linear morphometric parameters were assessed from the skull and mandible, respectively, in 21 Balkan chamois skulls. Additionally, five indices of the skull were calculated. Among the 47 linear parameters measured on the skull, only 16 were statistically significant, primarily on the caudal surface. The study shows that the Balkan chamois skull is characterized by its long, narrow shape with a sharp top, as indicated by the Skull index (40.35), while the orbits (left, right) and foramen magnum appear nearly circular, demonstrated by their respective indices (94.96; 96.16 and 96.28). The average skull length was 210.82 ± 8.15 mm in females and 210.5 ± 6.39 mm in males. This study provides for the first time elements of clinical anatomy, including the location of infraorbital foramina, inter supraorbital foramina distance, as well as the mental and mandibular foramina which can be used in the clinical veterinary practice, especially for the veterinarian working with wild fauna.

Keywords Balkan chamois · Clinical anatomy · Mandible · Orbit · Skull

Introduction

The Balkan chamois (*Rupicapra rupicapra balcanica* Bolkay, 1925) based on morphological, behavioral, and molecular evidence is one of the seven species of *Rupicapra rupicapra* which is found as a native species in the alpine terrain of the Balkan countries such as Albania, Bosnia and Herzegovina, Bulgaria, Croatia, northern Greece, Montenegro, North Macedonia, Serbia, and Slovenia. Its distribution is not continuous but rather patchy, as it is limited to specific parts of the mountain massifs and mountain chains within its range (Corlatti et al. 2022; Rezić et al. 2022).

The International Union for Conservation of Nature (IUCN) list the Balkan chamois as a species near threatened. The major threats to their population include habitat loss, hunting, and disturbance by human activities (Anderwald et al. 2020).

The chamois is in the goat-antelope subfamily and has typical head features that distinguish it from other species.

✉ Tomasz Szara
tomasz_szara@sggw.edu.pl

[1] Faculty of Veterinary Medicine, Agricultural University of Tirana, 1000 Tirana, Albania

[2] Department of Anatomy, Faculty of Veterinary Medicine, Istanbul University- Cerrahpaşa, Istanbul 34500, Türkiye

[3] Department of Basic Sciences of Veterinary Medicine, Veterinary Faculty, University of Sarajevo, Sarajevo, Bosnia and Herzegovina

[4] National Museum of Bosnia and Herzegovina, Zmaja Od Bosne 3, 71000 Sarajevo, Bosnia and Herzegovina

[5] Department of Morphological Sciences, Institute of Veterinary Medicine, Warsaw University of Life Sciences, 02-776 Warsaw, Poland

Published online: 03 March 2025

As part of the axial skeleton, the skull contains elements essential in taxonomy, comparative studies, veterinary medicine, zooarchaeology, and other fields.

Many studies are undertaken in the skulls of ruminants domestic or wild. Dalga et al. (2018), Gündemir et al. (2020), Jashari et al. (2021), and Karimi et al. (2011) have evaluated the morphometric parameters in sheep.

Goodarzi and Hoseini (2014), Choudhary et al. (2020), and Kataba et al. (2014) have evaluated the morphometric parameters in skull goats.

Monfared (2013a, b) and Mohamed et al. (2016) studied the clinical anatomy of the sheep skull, while, Olopade, and Onwuka (2009) studied the clinical anatomy of the goat's skull. Onuk et al. (2013) have described the anatomic and craniometric factors in differentiating roe deer from sheep and goats, or Zhu (2012) described craniometrical elements of the Tibetan gazelle skull.

Different studies have been conducted in the chamois species to measure the morphometric parameters of the skull or horns or to discover the sexual dimorphism in these species. Massei et al. 1993) and Markov et al. (2013) studied the morphometric measurements of the Balkanian chamois skull, García-González and Barandalla (2002) studied skull, horns, and mandibles parameters at Pirenean chamois, Fernández-López and García-González (1986) have studied the morphometric parameters of the skull and try to discover the sexual dimorphism of Pyrenean and Cantabrian chamois, Hrabě and Koubek (1984) and Chovanec et al. (2005), studied craniometrical characteristics of the tatrica chamois or Milošević-Zlatanović et al. (2022) studied the effect of sex and subspecies of *Rupicapra rupicapra* (*balcanica, carpatica, tatrica, and rupicapra*) in the cranial integration and modularity. Kobryńczuk et al. (2008a) developed discriminant functions allowing the determination of the sex of European bison based on their craniometric features.

The shape of the European bison skull has been studied during postnatal development. Krasińska et al. (2008) and Kobryńczuk et al. (2008b) compared different skull variants within this species. Szara et al. (2023) showed temporal trends in the shape of the European bison skull by comparing individuals from the last fifty years.

These studies are a strong base, but the information in these articles is insufficient for more detailed comparative studies because the parameters are limited. The mandible is not included except in the study of Fernández-López and García-González (1986), or used in clinical veterinary interventions such as cranial nerves bloc for the veterinarian which are involved in the studies and protection of the wild fauna.

The Balkan chamois also known as the wild goat is of great importance for the biodiversity of the Balkan region. Despite this significance, the complete data on the Balkan chamois skull morphometric parameters are lacking. Therefore, this study aims to document the linear morphometric parameters of the Balkan chamois skull.

Material and methods

The study was conducted over the period 2021 – 2022. Twenty-one skulls and nine mandibles of adult Balkan chamois were sourced from the bone collections of the veterinary faculties from Albania, Bosnia and Hercegovina, and Croatia.

In total, 47 and 18 linear morphometric parameters were assessed from the skull and the mandible, respectively. Additionally, five indices of the skull were calculated. Measurements were made based on the instructions of von den Driesch (1976), Goodarzi and Hoseini (2014), Choudhary et al. (2020) and Karimi et al. (2011). The linear measurements were derived using electronic calipers and thread fiber, and all measurements were taken in millimeters with a digital caliper (error 0.2 mm). The photographs of the samples were made with a Samsung photo camera NX210 20.3 MP.

Skull measurements (orientation points presented in Figs. 1, 2, 3, 4, 5 and 6):

1. Skull length (Sl)—Maximum length of the skull from the rostral tip of the incisive bones to the external occipital protuberance (Fig. 2)
2. Skull height (Sh)—From the level of the highest point of the frontal bone to the tip of the paracondylar process (Fig. 5)

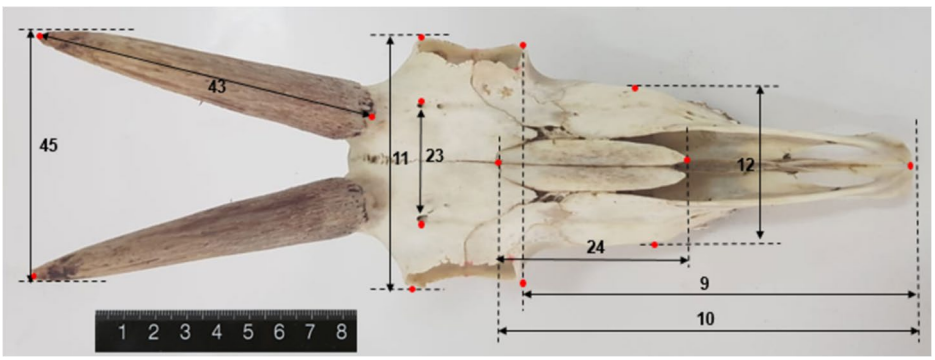

Fig. 1 Skull measurements of the Balkan chamois in the rostro-dorsal view. 9 Facial length (Fl); 10 viscerocranium length (Vcl); 11 facial width (Fw); 12 maxillary width (Mw); 23 supraorbital foramina distance (Sfd); 24 nasal bone length (Nl); 43 cornual process length (Cpl); 45 inter cornual procces tip (Icpt)



Fig. 2 Skull measurements of the Balkan chamois in the dorsal view. 1 Skull length (Sl); 6 cranial length (Cl); 7 parietal plane length in midline (Ppl); 8 maximum neuro cranium width (Mcw); 20 frontal bone length in middline (Fbl); 25 nasal bone width (Nw); 26 incisive bones width (Ibw); 27 inter entorbitale distance (Ied)

3. Basal length (Bl)—The distance from the rostral tip of the incisive bone to the intercondylar notch (Fig. 4)
4. Condylobasal length (Cbl)—The distance from the rostral tip of the incisive bone to the occipital condyle (Fig. 4)
5. Skull width (Sw)—Maximum breadth between two zygomatic arches (Fig. 4)
6. Cranial length (Cl)—The distance from the nuchal crest to the junction of the left and right nasofrontal sutures on the median plane (Fig. 2)
7. Parietal plane length in the midline (Ppl)—The distance from the interparietal bone to the parietofrontal suture in the midline line (Fig. 2)
8. Maximum neuro cranium width (Mcw)—The distance from the most lateral point of the cranial cavity on the left to the most lateral point of the cranial cavity on the right (Fig. 2)
9. Facial length (Fl)—The distance from the junction of the left and right nasofrontal sutures in the median plane to the rostral tip of the incisive bones (Fig. 1)
10. Viscerocranium length (Vcl) – The distance from the interorbital in the median plane to the rostral tip of the incisive bones (Fig. 1)
11. Facial width (Fw)—The distance between the caudal extents of the orbital margin (Ectorbital – Ectorbital) (Figs. 1, 4)
12. Maxillary width (Mw)—The distance between two facial tuberosity (Fig. 1)
13. Foramen magnum height (Fmh)—The distance between the midpoints of the dorsal and ventral rims of the foramen magnum (Fig. 5)
14. Foramen magnum width (Fmw)—Maximum width between two occipital condyles (Fig. 5)
15. Occipital squama height (Osh)—The distance from the caudoventral projection of the nuchal crest to the upper rim of the foramen magnum (Fig. 5)
16. Occipital condyle thickness (Oct)—Maximum width of single occipital condyle from the most lateral extent to the foramen magnum (Fig. 5)
17. Intercondylar width (Icw)—Width between the lateral borders of the occipital condyles (Fig. 5)
18. Interparacondylar width (Ipw)—The distance between the bases of the paracondylar processes (Fig. 5)
19. Paracondylar process length (Ppl)—Length from the tip of the paracondylar process to its junction with the squamous part of the occipital bone (Fig. 5)
20. Frontal bone length in the midline (Fbl)—Length of the interfrontal suture (Fig. 2)
21. Lacrimal bone length (Lbl)—The greatest length of the lacrimal bone (Fig. 3)
22. Zygomatic bone length (Zbl)—The greatest length of the zygomatic bone (Fig. 3)

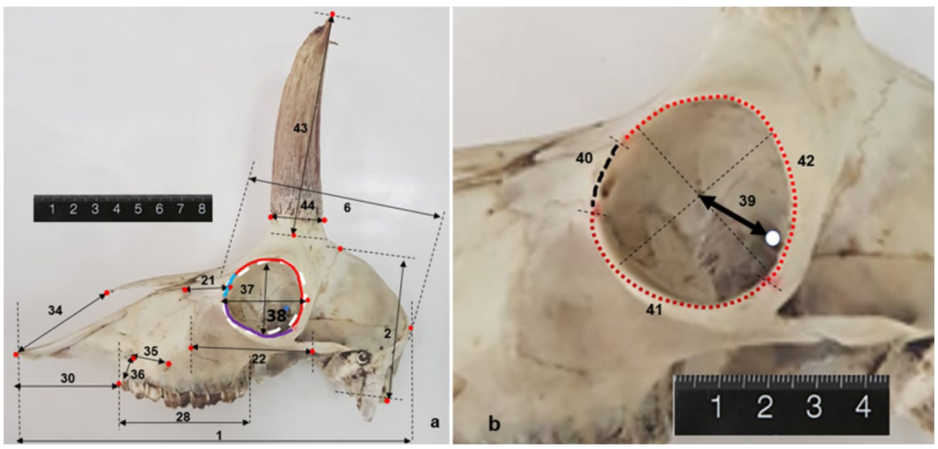

Fig. 3 Skull measurements of the Balkan chamois in the lateral view (**a**), measurements of the orbit (**b**). 1. Skull length (Sl); 2 skull height (Sh); 6 cranial length (Cl); 21 lacrimal bone length (Lbl); 22 zygomatic bone length (Zbl); 28 distance from Pm1 to M3 (Pm1M3); 30 distance from rostrum to PM1 (RPm1); 34 distance from rostrum to nasal (Rn); 35 infraorbital foramina to facial tuberosity (Ifft); 36 infraorbital foramina to alveolar margin (Ifam); 37 orbital length (Ol); 38 orbital height (Oh); 39 orbit depth (Od); 40 orbital margin of lacrimal bone (Oml); 41 orbital margin of zygomatic bone (Omz); 42 the orbital margin of the frontal bone (Omf); 43 cornual process length (Cpl); 44 cornual procces width (Cpw)

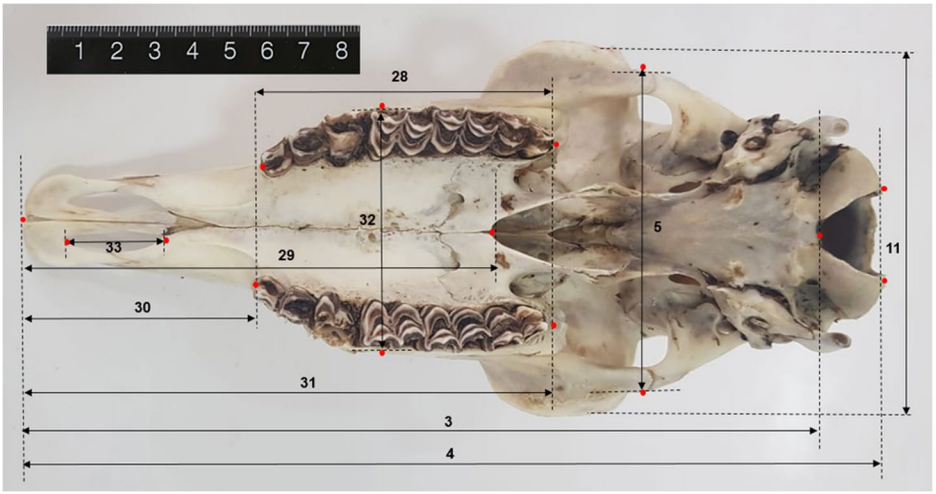

Fig. 4 Skull measurements of the Balkan chamois in the ventral view. 3 Basal length (Bl); 4 condylobasal length (Cbl); 5 skull width (Sw); 11 facial width (Fw); 28 distance from Pm1 to M3 (Pm1M3); 29 palatine length (Pl); 30 distance from rostrum to PM1 (RPm1); 31 dental length (Dl); 32 maximum palatine width (Mpw); 33 palatine fissure length (Pfl)

23. Supraorbital foramina distance (Sfd)—The distance between two supraorbital foramina (Fig. 1)
24. Nasal bone length (Nl)—The greatest length of nasal bone (Fig. 1)
25. Nasal bone width (Nw)—Maximum width between two nasal bones (Fig. 2)
26. Incisive bones width (Ibw)—Maximum width between two nasal processes of incisive bone (Fig. 2)
27. Inter entorbitale distance (Ied)—The least width between the cranial border (margin) of the orbits (Fig. 2)
28. Distance from Pm1 to M3 (Pm1M3)—The upper molar teeth row (Fig. 3)
29. Palatine length (Pl)—The distance from the tip of the rostrum to the Stafilon (Fig. 4)
30. Distance from the rostrum to PM1 (RPm1)—The distance between the rostral tip of the incisive bones to the first premolar tooth (Figs. 2, 4)

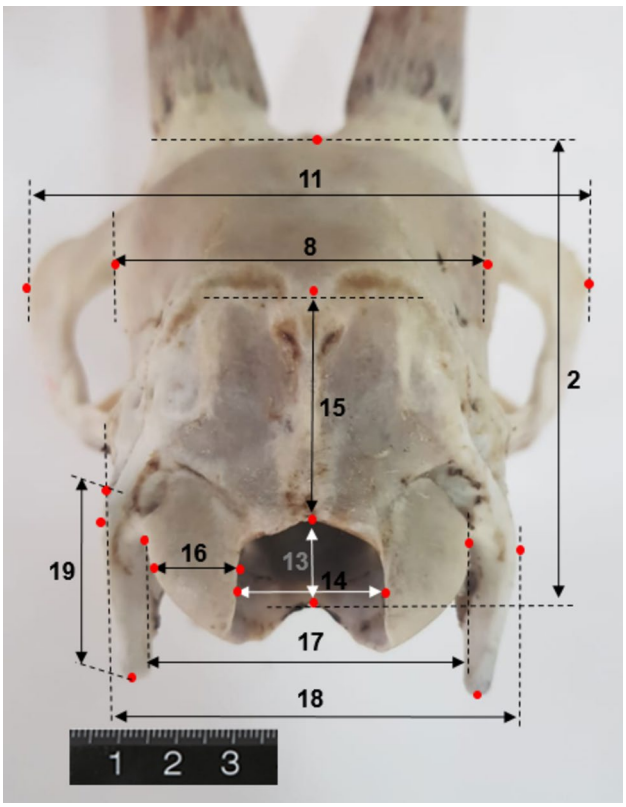

Fig. 5 Skull measurements of the Balkan chamois in the caudal view. 2 Skull height (Sh); 8 maximum neuro cranium width (Mcw); 11 facial width (Fw); 13 foramen magnum height (Fmh); 14 foramen magnum width (Fmw); 15 occipital squam height (Osh); 16 occipital condyle thickness (Oct); 17 intercondylar width (Icw); 18 interparacondylar width (Ipw); 19 paracondylar process length (Ppl)



Fig. 6 Horn measurements of the Balkan chamois in the lateral view. 46 Length of horn (Lh); 47 perimeter of the horn base (Phb)

31. Dental length (Dl)—The distance from the rostral tip of the incisive bones to the caudal border of the third molar (Fig. 4)
32. Maximum palatine width (Mpw)—The distance between the most outer points of the two maxillary alveolar processes (Fig. 4)
33. Palatine fissure length (Pfl) (Fig. 4)
34. Distance from the rostrum to nasal (Rn)—The distance from the rostral tip of the incisive bones to the tip of the septal process (Fig. 3)
35. Infraorbital foramina to facial tuberosity (Ifft)—The distance from the infraorbital foramina to facial tuberosity (Fig. 3)
36. Infraorbital foramina to alveolar margin (Ifam)—The distance from the infraorbital foramina to alveolar margin (Fig. 3a)
37. Orbital length (Ol) – Horizontal diameter (Fig. 3a)
38. Orbital height (Oh) – Vertical diameter (Fig. 3a)
39. Orbit depth (Od) – The distance from optic foramen to the central point of the orbit area (Fig. 3b)
40. Orbital margin of lacrimal bone (Oml) (Fig. 3b)
41. Orbital margin of zygomatic bone (Omz) (Fig. 3b)
42. Orbital margin of the frontal bone (Omf) (Fig. 3b)
43. Cornual process length (Cpl)—The distance from the base to the tip of the cornual process (Fig. 3a)
44. Cornual process width (Cpw)—The transverse width of the initial part of the cornual process (Fig. 3a)
45. Inter cornual process tip (Icpt)—Distance between the two tips of the cornual processes (Fig. 1)
46. Length of horn (Lh)—Length of the horn from the base to the tip (Fig. 6)
47. Perimeter of the horn base (Phb) – The circumference of the horn base (Fig. 6)

Mandible measurement (orientation points presented in Figs. 7 and 8):

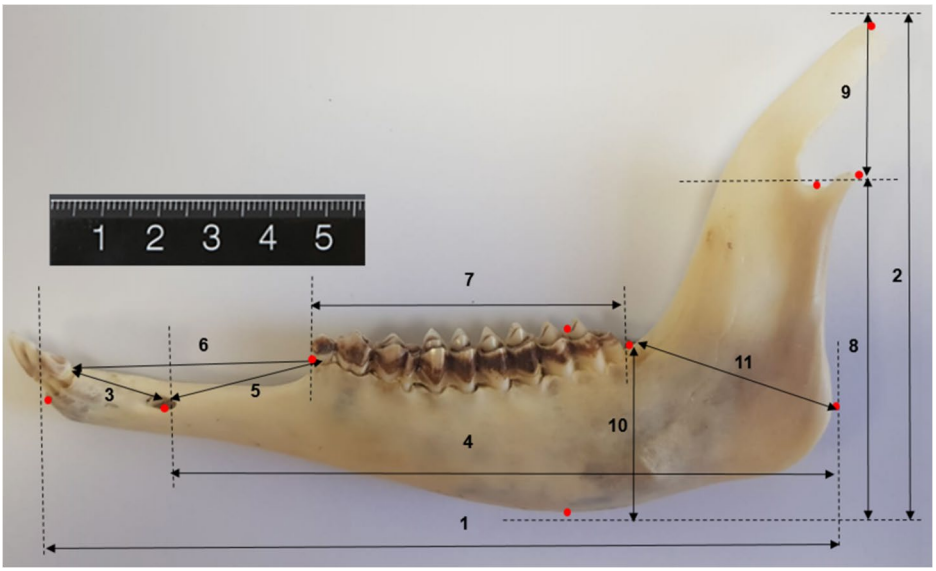

Fig. 7 Mandible measurements of the Balkan chamois in the lateral view. 1 Mandible length (Ml); 2 mandible height (Mh); 3 mental foramen to last incisive alveoli (Mfli); 4 mental foramen to mandible angle (Mfma); 5 mental foramen to Pm1 (MfPm1); 6 diastema (D); 7 molar row length Pm1—M3 (Pm1M3); 8 distance from base to condylar process (Bcp); 9 distance from mandible notch to coronoid process (Mncp); 10 distance from M3 to ventral margin (M3vm); 11 distance from M3 to mandible angle (M3ma)

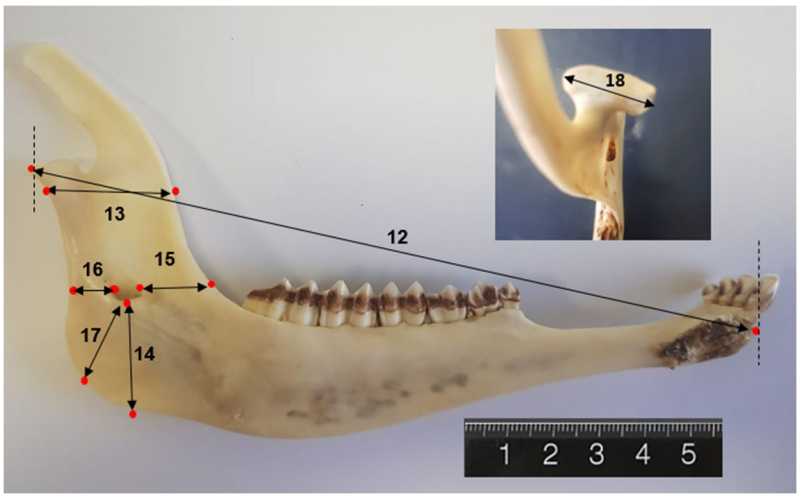

Fig. 8 Mandible measurements of the Balkan chamois in the medial view. 12 Distance from I1 to condylar process (I1cp); 13 ramus mandible width (Rmw); 14 distance from mandibular foramina to ventral margin (Mfvm); 15 distance from mandibular foramina to cranial margin (Mfcrm); 16 distance from mandibular foramina to caudal margin (Mfcam); 17 distance from mandibular foramina to mandible angle (Mfma); 18 articular surface length (Asl)

1. Mandible length (Ml)—From the level of the cranial extremity of the alveolar root of the incisor to the level of the caudal border of the mandible (Fig. 7)
2. Mandible height (Mh)—From the basal level of the mandible to the highest level of the coronoid process (Fig. 7)
3. Mental foramen to last incisive alveoli (Mfli)—The distance between mental foramen and the most lateral incisive alveoli (Fig. 7)
4. Mental foramen to mandible angle (Mfma)—The distance between mental foramen to the mandible angle (Fig. 7)
5. Mental foramen to Pm1 (MfPm1)—The distance between the mental foramen to the first premolar teeth (Fig. 7)
6. Diastema (D)—The distance between the first incisive tooth and the first premolar tooth (Fig. 7)
7. Molar row length Pm1—M3 (Pm1M3)—The length of the entire molar row from Pm1 to M3 (Fig. 7)
8. Distance from base to condylar process (Bcp)—The distance from the mandible base to the condylar process (Fig. 7)
9. Distance from mandible notch to coronoid process (Mncp)—The distance from the mandible notch to the coronoid process (Fig. 7)
10. Distance from M3 to ventral margin (M3vm)—The distance from the third molar tooth to the ventral margin of the corpus mandible (Fig. 7)
11. Distance from M3 to mandible angle (M3ma)—The distance from the third molar tooth to the mandible angle (Fig. 7)
12. Distance from I1 to condylar process (I1cp)—The distance from the level of the cranial extremity of the alveolar root of the first incisor to the caudal edge of the condylar process (Fig. 8)
13. Ramus mandible width (Rmw)—The distance from cranial to caudal border of the ramus mandible, just under the mandible notch (Fig. 8)
14. Distance from mandibular foramina to ventral margin (Mfvm)—The distance from mandibular foramen to ventral margin (Fig. 8)
15. Distance from mandibular foramina to cranial margin (Mfcrm)—The distance from mandibular foramen to cranial margin of mandibular branch (Fig. 8)
16. Distance from mandibular foramina to caudal margin (Mfcam)—The distance from mandibular foramen to caudal margin of mandibular branch (Fig. 8)
17. Distance from mandibular foramina to mandible angle (Mfma)—The distance from mandibular foramen to mandible angle (Fig. 8)
18. Articular surface length (Asl)—The length of the articular surface of the condylar process (Fig. 8)

Table 1 Skull measurements of the Balkan chamois

Morphometric parameters (mm)	Female					Male					Total					*P* value
	Mean	Stdev	Min	Max	CV	Mean	Stdev	Min	Max	CV	Mean	Stdev	Min	Max	CV	
Skull length (Sl)	210.51	6.39	195.70	217.78	3.04	211.13	9.91	195.00	226.00	3.87	210.82	8.15	195.35	221.89	4.69	0.86
Skull height (Sh)	65.81	2.06	61.96	69.31	3.14	66.69	6.12	60.95	82.00	6.18	66.25	4.09	61.46	75.66	9.18	0.66
Basal length (Bl)	180.63	5.79	166.27	191.00	3.20	180.68	6.40	170.00	190.00	3.37	180.65	6.09	168.14	190.50	3.54	0.98
Condylobasal length (Cbl)	191.45	4.50	178.21	195.78	2.35	193.52	5.85	183.84	201.00	2.69	192.48	5.18	181.03	198.39	3.02	0.37
Skull width (Sw)	85.19	3.08	81.72	92.30	3.61	84.87	3.42	80.06	90.69	3.82	85.03	3.25	80.89	91.50	4.03	0.82

Table 2 Cranial measurements of the Balkan chamois

Morphometric parameters (mm)	Female					Male					Total					*P* value
	Mean	Stdev	Min	Max	CV	Mean	Stdev	Min	Max	CV	Mean	Stdev	Min	Max	CV	
Cranial length (Cl)	102.92	8.72	85.85	112.72	8.47	105.42	4.27	98.63	114.47	6.23	104.17	6.49	92.24	113.60	4.05	0.42
Planum parietale length in the midline (Ppl)	30.00	3.18	25.55	35.31	10.59	30.88	2.45	26.17	34.10	9.24	30.44	2.81	25.86	34.71	7.94	0.49
Maximum neurocranium width (Mcw)	62.11	1.41	59.18	64.32	2.27	62.63	2.28	60.12	67.25	2.96	62.37	1.85	59.65	65.79	3.64	0.54
Foramen magnum height (Fmh)	18.29	0.93	16.48	19.59	5.10	18.14	0.43	17.23	18.71	3.74	18.21	0.68	16.86	19.15	2.36	0.64
Foramen magnum width (Fmw)	19.02	1.19	17.07	21.21	6.25	18.93	1.19	17.29	20.94	6.27	18.97	1.19	17.18	21.08	6.28	0.87
Occipital squam height (Osh)	24.55	2.49	20.74	29.08	10.13	24.77	1.04	23.48	27.38	7.15	24.66	1.76	22.11	28.23	4.19	0.80
Occipital condyle thickness (Oct)	11.67	0.84	10.25	13.11	7.17	11.97	1.31	9.50	14.16	9.09	11.82	1.07	9.88	13.64	10.97	0.53
Intercondylar width (Icw)	42.15	1.54	40.15	45.53	3.66	40.91	1.92	37.89	44.51	4.17	41.53	1.73	39.02	45.02	4.68	0.12
Interparacondylar width (Ipw)	51.15	2.27	47.29	54.55	4.45	49.19	4.31	42.11	56.06	6.56	50.17	3.29	44.70	55.31	8.76	0.20
Paracondylar process length (Parpl)	21.39	0.87	19.89	22.12	4.07	22.71	2.23	20.27	27.93	7.02	22.05	1.55	20.08	25.03	9.81	0.09
Frontal bone length in midline (Fbl)	67.94	6.17	51.43	73.96	9.09	71.41	6.36	63.01	82.84	9.00	69.68	6.27	57.22	78.40	8.91	0.22

Table 3 Facial measurements of the Balkan chamois

Morphometric parameters (mm)	Female					Male					Total					*P* value
	Mean	Stdev	Min	Max	CV	Mean	Stdev	Min	Max	CV	Mean	Stdev	Min	Max	CV	
Facial length (Fl)	109.32	5.23	101.56	119.75	4.14	109.79	3.84	101.60	118.71	3.50	109.55	4.54	101.58	119.23	4.79	0.82
Viscerocranium length (Vcl)	119.00	8.01	104.03	133.25	6.07	115.79	6.24	107.83	128.13	5.39	117.40	7.13	105.93	130.69	6.74	0.32
Facial width (Fw) Ect-Ect)	106.03	4.96	98.70	112.19	4.93	103.55	5.38	94.43	113.29	5.19	104.79	5.17	96.57	112.74	4.67	0.29
Maxillary width (Mw)	61.60	4.47	55.08	68.32	5.74	63.55	2.70	58.86	67.21	4.25	62.57	3.59	56.97	67.77	7.26	0.24
Lacrimal bone length (Lbl)	38.25	4.18	27.80	42.81	10.47	35.63	3.55	30.89	41.05	9.97	36.94	3.87	29.35	41.93	10.94	0.14
Zygomatic bone length (Zbl)	58.92	4.68	51.74	63.45	6.64	55.65	2.92	49.27	59.04	5.25	57.29	3.80	50.51	61.25	7.95	0.07
Supraorbital foramina distance (Sfd)	40.37	4.01	33.96	45.97	8.18	39.19	2.50	35.48	44.50	6.38	39.78	3.26	34.72	45.24	9.93	0.42
Nasal bone length (Nl)	63.28	4.93	52.96	70.32	6.71	62.48	3.51	57.90	71.25	5.62	62.88	4.22	55.43	70.79	7.78	0.67
Nasal bone width (Nw)	21.21	2.59	16.33	25.03	8.50	20.11	0.92	18.46	21.37	4.55	20.66	1.76	17.40	23.20	12.24	0.20
Incisive bones width (Ibw)	32.96	3.55	27.04	38.12	9.21	31.65	2.40	25.87	35.73	7.58	32.30	2.97	26.46	36.93	10.77	0.33
Inter Entorbitale distance (Ied)	103.93	4.27	97.70	108.29	4.53	101.82	5.06	93.43	111.29	4.97	102.88	4.66	95.57	109.79	4.11	0.32
Distance from rostrum to nasal (Rn)	54.07	3.32	48.08	57.26	4.94	53.38	1.99	48.42	56.79	3.72	53.72	2.65	48.25	57.03	6.14	0.57
Infraorbital foramina to facial tuberosity (Ifft)	18.24	1.76	15.42	21.38	8.77	18.30	1.45	15.80	20.87	7.90	18.27	1.60	15.61	21.13	9.64	0.94
Infraorbital foramina to alveolar processus (Ifap)	11.02	0.92	9.34	12.87	10.85	10.61	1.43	8.65	12.93	13.45	10.81	1.17	9.00	12.90	8.35	0.46

Table 4 Palatine measurements of the Balkan chamois

Morphometric parameters (mm)	Female					Male					Total					*P* value
	Mean	Stdev	Min	Max	CV	Mean	Stdev	Min	Max	CV	Mean	Stdev	Min	Max	CV	
Distance from Pm1 to M3 (Pm1M3)	58.90	3.15	52.71	62.70	5.35	59.96	5.17	51.36	68.27	7.00	59.43	4.16	52.04	65.49	8.62	0.57
Palatine length (Pl)	107.34	2.16	100.86	108.60	2.02	108.44	4.68	99.46	115.21	3.17	107.89	3.42	100.16	111.91	4.32	0.49
Distance from the rostrum to PM1 (RPm1)	57.50	1.11	54.19	58.28	1.93	58.14	2.29	54.30	63.18	2.94	57.82	1.70	54.25	60.73	3.93	0.42
Dental length (Dl)	116.57	4.05	105.77	120.83	3.47	117.66	6.36	105.49	125.00	4.44	117.12	5.20	105.63	122.92	5.40	0.64
Maximum palatine width (Mpw)	55.72	2.86	51.88	63.30	5.13	55.89	2.64	50.98	60.68	4.93	55.81	2.75	51.43	61.99	4.73	0.89
Palatine fissure length (Pfl)	23.10	0.69	22.86	25.19	3.01	22.67	1.27	20.17	24.72	4.29	22.88	0.98	21.52	24.96	5.60	0.34

Table 5 Orbital measurements of the Balkan chamois

Morphometric parameters (mm)	Female					Male					Total					*P* value
	Mean	Stdev	Min	Max	CV	Mean	Stdev	Min	Max	CV	Mean	Stdev	Min	Max	CV	
Orbital left length (Oll)	38.03	0.80	36.90	39.91	2.09	37.92	1.50	35.59	40.61	3.03	37.97	1.15	36.25	40.26	3.97	0.83
Orbital left height (Olh)	36.13	0.45	35.41	36.94	1.24	35.97	1.64	33.36	37.91	2.90	36.05	1.05	34.39	37.43	4.57	0.76
Lacrimal left margin (Llm)	14.36	1.04	12.12	15.91	7.27	14.16	1.31	11.19	16.30	8.24	14.26	1.18	11.66	16.11	9.23	0.71
Zygomatic left margin (Zlm)	48.19	4.10	42.00	56.02	8.51	45.86	4.22	39.00	52.11	8.85	47.02	4.16	40.50	54.07	9.21	0.22
Frontal left margin (Flm)	66.94	5.42	59.98	80.69	8.10	65.42	3.11	60.00	70.00	6.45	66.18	4.27	59.99	75.35	4.76	0.45
Orbital length R (Olr)	37.98	0.84	36.92	40.09	2.21	37.58	1.55	34.13	40.21	3.16	37.78	1.19	35.53	40.15	4.11	0.46
Orbital height R (Ohr)	36.34	0.65	35.56	37.42	1.80	36.30	1.81	32.66	38.93	3.39	36.32	1.23	34.11	38.18	4.99	0.94
Orbital depth: R (centre of orbit surface to optic foramen) (Odr)	44.20	0.00	44.20	44.20	0.00	44.33	2.07	41.08	48.89	2.34	44.26	1.04	42.64	46.55	4.68	0.84
Lacrimal right margin (Lrm)	14.05	1.94	8.71	15.58	13.81	14.62	1.57	11.62	16.98	12.24	14.34	1.75	10.17	16.28	10.72	0.47
Zygomatic right margin (Zrm)	47.65	3.83	43.00	56.00	8.04	45.29	4.35	39.00	53.27	8.80	46.47	4.09	41.00	54.64	9.60	0.20
Frontal right margin (Frm)	67.20	2.62	63.20	71.99	3.91	64.68	2.73	61.00	69.00	4.06	65.94	2.68	62.10	70.50	4.22	0.04
Orbital depth:L (centre of orbit surface to optic foramen) (Odl)	44.30	0.00	44.30	44.30	0.00	44.31	1.95	41.08	48.57	2.20	44.31	0.97	42.69	46.44	4.40	0.99

Table 6 Horn measurements of the Balkan chamois

Morphometric parameters (mm)	Female					Male					Total					*P* value
	Mean	Stdev	Min	Max	CV	Mean	Stdev	Min	Max	CV	Mean	Stdev	Min	Max	CV	
Cornual process length (Cpl)	88.57	12.94	52.53	98.77	14.61	98.08	9.84	78.47	110.00	12.20	93.33	11.39	65.50	104.39	10.03	0.08
Cornual process width (Cpw)	21.30	2.30	18.21	24.92	10.80	23.75	3.40	19.04	27.91	12.66	22.52	2.85	18.63	26.42	14.34	0.07
Inter cornual procces tip (Icpt)	58.47	3.59	49.33	65.14	6.14	59.05	12.20	38.38	75.39	13.44	58.76	7.90	43.86	70.27	20.67	0.88
Length of horn (Lh)	204.35	34.82	133.20	249.33	17.04	230.06	27.94	180.00	270.00	14.45	217.20	31.38	156.60	259.67	12.14	0.08
Perimeter of horn base (Phb)	75.63	5.88	67.33	85.10	7.77	85.88	6.79	80.30	100.00	7.84	80.76	6.33	73.82	92.55	7.91	0.00

The indices of cranium and orbit

1. Skull index (Si): Skull width (Sw) × 100/Skull length (Sl)
2. Cranial index (Ci): Maximum neurocranium width (Mcw) × 100/Cranial length (Cl)
3. Facial index (Fi): Facial width (Fw) × 100/Facial length (Fl)
4. Foramen magnum index (Fmi): Foramen magnum height (Fmh) × 100/Foramen magnum width (Fmw)
5. Orbital index (Oi): Orbital width (Ow) × 100/Orbital length (Ol)

Statistical analysis

Mean, standard deviations, minimum, maximum, and coefficient of variation of all linear measurements were calculated for male and female chamois goats.

An independent T-test was used to reveal statistical differences between the sexes. *P* values are given in the results tables. SPSS (version 22) software package was used for the statistical analysis.

Results

Morphometric results

The linear morphometric parameters of the skull and mandible of the Balkan chamois measured in this study are presented in Tables 1, 2, 3, 4, 5, 6 and 7, categorized according to the skull surfaces and structures. The skull indices are listed in Table 8.

A notable aspect of this study is the extensive coverage and detail on the linear parameters of the Balkan chamois skull and mandible.

Overall, the skull linear parameter values were larger in males than in females. Among all the linear parameters measured, only six parameters – skull width (Sw), foramen magnum height (Fmh) and foramen magnum width (Fmw), intercondylar width (Icw), facial length (Fl), maxillary width (Mw), infraorbital foramina to alveolar process (Ifap) and almost all linear orbital parameters were more significant in females.

Of the 47 linear parameters measured on the skull, only 16 were statistically significant. These parameters were predominantly distributed on the caudal surface of the skull, including Icw ($p = 0.12$), Ipw ($p = 0.20$), and Parpl ($p = 0.09$), with Fbl ($p = 0.22$) being the only parameter significant on the dorsal part of the skull.

Table 7 Mandible parameters on the male Balkan chamois

Morphometric parameters (mm)	Mean	Stdev	Min	Max	CV
Mandible length (Ml)	156.54	7.95	142.94	166.00	5.08
Mandible height (Mh)	95.10	6.47	81.18	102.00	6.81
Mental foramen to last incisive alvelol (Mfli)	17.49	3.63	12.44	23.66	20.74
Mental foramen to mandible angle (Mfma)	126.16	17.70	84.80	141.02	14.03
Mental foramen to Pm1 (MfPm1)	27.26	3.90	20.39	33.31	14.31
Diastema (D)	43.22	2.91	39.01	47.39	6.72
Molar row length Pm1—M3 (Pm1M3)	60.91	6.09	49.31	69.75	10.00
Distance from base to condylar process (Bcp)	65.82	5.51	57.72	71.00	8.37
Distance from mandible incisura to coronoid process (Micp)	32.77	3.39	25.73	37.75	10.34
Distance from M3 to ventral margin (M3vm)	28.95	0.99	27.02	30.58	3.41
Distance from M3 to mandible angle (M3ma)	43.94	4.38	39.59	53.14	9.98
Distance from I1 to condylar process (I1cp)	158.80	9.65	141.93	170.00	6.08
Ramus mandible width (Rmw)	25.38	0.87	24.00	26.71	3.42
Distance from mandibular foramina to ventral margin (Mfvm)	24.90	2.00	22.42	28.55	8.04
Distance from mandibular foramina to cranial margin (Mfcrm)	16.78	1.32	15.28	19.50	7.86
Distance from mandibular foramina to caudal margin (Mfcam)	13.34	1.54	11.29	15.62	11.53
Distance from mandibular foramina to mandible angle (Mfma)	22.93	2.08	20.59	26.64	9.08
Articular surface length (Asl)	18.13	1.72	15.66	21.14	9.48

On the facial part of the skull, statistically significant parameters included Fw ($p = 0.29$), Mw ($p = 0.24$), Lbl ($p = 0.14$), Zbl ($p = 0.07$), Nw ($p = 0.20$), Zlm, and Zrm ($p = 0.22$ and $p = 0.20$, respectively), with Frm ($p = 0.04$) being especially notable.

Noteworthy linear parameters included cornual process length ($p = 0.08$), Cpw ($p = 0.07$), and Lh ($p = 0.08$), with the most significant parameter being the perimeter of the horn base ($p = 0.00$). These findings suggest that sexual dimorphism is present in the Balkan chamois, although only in a few skull parameters.

The skull of Balkan chamois was narrow and elongated whereas the dorsal part of the skull was predominated by cornual processes, large and circular orbits, and very short nasal bones.

From all skull indices only the Facial Index (Fi) was significantly different ($p = 0.20$) between males and females.

Related mandible measurements are only in male Balkan chamois and are impossible to compare with females.

The morphometric linear parameter of the mandible is of great importance in veterinary clinical practice during regional anesthesia, block nerves, teeth extractions, etc.

Morphological results

The detailed observation of the Balkan chamois skulls reveals certain characteristics and differences compared to the domesticated goats (*Capra hircus*) as reported in studies on Mizoram goats by Choudhary et al. (2020), Gwembe Valley dwarf goats in Zambia by Kataba et al. (2014), and Kagani goats in the Jammu region by Sarma (2006). These features are presented in all surfaces of the skull and mandible of Balkan chamois.

Fronto-dorsal surface

The body of the incisive bone at the most rostral edge was larger, wider, and thicker than in domesticated goats concerning the size of the corresponding skull. The inter incisive fissure was short and narrow. The rostral nasal opening was wider than in domestic goats.

The nasal bone is one of the most differentiated structures which is shorter and thinner and the entire bone has almost the same width from the base to the septal process, contrary to in goats where its base was wider. The nasofrontal suture on both sides was "V" shaped. The dorsofrontal surface of the frontal bone is a bit concave compared to the domesticated goats where it is flat or a bit convex depending on the presence of the cornual processes. The most dorsal part of the skull is formed by the cornual processes, which are very strong and conical. They diverge at a very narrow angle between them, and their rostral surface creates a straight angle (90º) with the dorsofrontal surface of the frontal bone. In contrast to goats, the cornual processes are more

Table 8 Balkan chamois skull indices

Indices	Female					Male					Total					*P* value
	Mean	Stdev	Min	Max	CV	Mean	Stdev	Min	Max	CV	Mean	Stdev	Min	Max	CV	
Skull Index (Si)	40.48	1.36	37.52	42.53	3.35	40.22	1.18	37.87	41.67	3.15	40.35	1.27	37.70	42.10	2.94	0.64
Cranial Index (Ci)	60.69	4.49	56.70	70.95	7.39	59.44	2.03	55.48	62.53	5.43	60.07	3.26	56.09	66.74	3.42	0.43
Facial Index (Fi)	94.30	3.05	87.80	98.75	3.23	97.05	3.36	91.25	102.40	3.47	95.67	3.21	87.80	102.40	3.35	0.20
Foramen magnum Index (Fmi)	96.47	7.13	82.73	108.14	7.39	96.09	5.58	87.49	106.36	6.60	96.28	6.35	85.11	107.25	5.81	0.89
Orbit L Index (Oli)	95.03	1.86	89.80	96.99	1.96	94.89	3.49	89.78	100.14	2.82	94.96	2.68	89.79	98.56	3.68	0.91
Orbit R index (Ori)	95.72	2.47	91.72	99.76	2.58	96.60	3.20	88.87	100.15	2.95	96.16	2.84	90.29	99.95	3.32	0.48

diverged, curved, and caudally oriented, with a non-circular base. They diverge at a very narrow angle between them, and their rostral surface creates a straight angle (90º) with the dorsofrontal surface of the frontal bone unlike goats, which have the cornual processes more diverged, curved, and caudally oriented, with a non-circular base. The supraorbital foramina were usually single on either side and smaller than in goats. The last part of the interfrontal suture is almost straight without serrate compared to the goats the entire margin is serrated. The rostral margin of the parietofrontal suture at the attachment point with the interfrontal suture was concave, unlike goats where this margin is convex. The temporal line was not visible or was nonexistent in the chamois skull compared to that of goats. The rostral margin of the interparietal bone on the dorsal surface was almost straight in chamois, whereas in goats it tends to be more pointed or triangular.

Lateral surface

The nasal process of the incisive bone was completely straight dorsocaudally, whereas, in goats, there is a change in direction resembling an "S" or "Z" shape in its free dorsal margin. The nasoincisive notch was more visible in chamois compared to goats. The orbits were large and almost circular, and rostrally, on either side, there was a fossa on the dorsal surface of the lacrimal bone. The infraorbital foramen was smaller, almost with a single hole, and there was a fossa on the dorsal surface of the lacrimal bone. The opening of the external acoustic meatus was small and circular.

Ventral surface

The occipital notch was narrow and muscular tubercles were smaller compared to goats. The tympanic bulla was smaller and narrow and its caudal margin was attached to the rostral margin of the paracondylar process unlike in the domesticated goats. The perpendicular plate of the palatine bone forms the “V” shape in the median line. The premolars and molars had no differences in shape and numbers compared to the goats.

Caudal surface

The mastoid process was smaller and the paracondylar process was straighter. The external occipital protuberance was developed and more protruded compared to goats.

Mandible

The mandible of the Balkan chamois, unlike the skull, had fewer differences when contrasted with the goats' mandible. After detailed observations, it was discovered that the

coronoid process was straighter than that of goats, which was more curved caudally. The mental foramen was situated more rostrally, behind the last incisor (I_4).

Discussion

This detailed study of the skull and mandible of the Balkan chamois provided a database with morphometric data of different parameters, skull indices, and the most different shapes and sizes of the skull structures. The head skeleton, constituting a part of the axial skeleton, supports and protects vital organs such as the brain, eyes, and middle and inner ear, as well as the organs and structures of the oral and nasal cavities.

On the other hand, the skeleton of the head is of special interest in veterinary forensics, in taxonomy, in zooarchaeology, and in various comparative studies. The arrangement of the foramina through which the cranial nerves exit is especially significant. Accurate knowledge about anatomical measurements is fundamental for delivering anaesthetics during regional block procedures (Dalga and Aslan 2020).

Many studies in the field of osteometry have been carried out in the skulls of different domestic animals such as horses (Evans and McGreevy 2006; Komosa et al. 2006), donkeys (Zhu et al. 2014; Merkies et al. 2020), pigs (Choudhary et al. 2017), cattle (Monfared 2013a; Özkan et al. 2019), dromedary camels (Al Mohamad et al. 2023), one-humped camels (Yahaya et al. 2012), sheep (Özcan et al. 2010; Karimi et al. 2011; Dalga et al. 2018; Monfared 2013b; Gündemir et al. 2020; Jashari et al. 2021), goat (Goodarzi and Hoseini 2014; Sarma 2006), also in carnivores like a dog (Daskiran and Cedden 2006; Onar 1999; Onar et al. 2001) and cat (Saber et al. 2016; Dučić et al. 2024).

Similar studies have also been conducted in wild herbivores such as roe deer (Aragon et al. 1998; Avdić et al. 2013; Onuk et al. 2013), European bison (Kobryńczuk et al. 2008a, 2008b, Krasińska et al. 2008, Szara et al. 2023), antelope (Choudhary and Singh 2015), chital (Kumawat et al. 2014), gazelle (Zhu 2012), different subspecies of chamois (Chovanec et al. 2005; Massei et al. 1993; Markov et al. 2013) and in wild carnivores such as wolves and jackals (Milencovic et al. 2010; Younes and Fouad 2016; Rezić et al. 2017; Janssens et al. 2019; Srinivas and Jhala 2021; Okarma and Buchalczyk 1993; Hadžiomerović et al. 2022), fox (Magalhães et al. (2019), lion (Zuccarelli 2003; Saber and Gummow 2015), stone martens (Özen 2020) etc.

All these studies have aimed to highlight the morphometric parameters of the skull and mandible to create a database used in further taxonomic studies, and comparative anatomy, in the field of veterinary clinical practice and zooarchaeology.

The morphometric measurements of this study show that the Balkan chamois, as one of the subspecies of the alpine chamois, has an average skull length of 210.82 ± 8.15 mm in females and 210.51 ± 6.39 mm in males. These results are very similar to the data of the study on the Balkan chamois made by Markov et al. (2013) which concluded that Skull length was 213.90 ± 5.12 mm and 207.47 ± 5.61 mm in males and females, respectively. The study of Massei et al. (1993) in the Bulgarian chamois (Balkan chamois subspecies) describes the total length of the skull in males and females as 216.22 ± 3.66 mm and 211.5 ± 5.49 mm, respectively.

Chovanec et al. (2005) in their study on 18 skulls of Tatra chamois (*Rupicapra rupicapra tatrica*) describe the total skull respectively for males and females as 20.34–21.96 cm and 18.45–21.86 cm.

The study of Fernández-López and García-González (1986), has presented the total length of the skull in two subspecies of Pyrenean (*R. r. pyreneica*) and Cantabrian chamois (*R. r. parva*) in both male and female as: 199.0 ± 8.68 mm; 196.9 ± 5.88 mm and 198.7 ± 6.49 mm; 191.3 ± 4.98 mm, respectively. However, in the study of Garcia-Gonzalez and Barandalla (2002), again in the Pyrenean chamois, the total skull length was 198.5 ± 7.8 mm and 196.9 ± 5.9 mm in males and females respectively.

Based on this study the skull length of Balkan chamois is one of the largest skulls after the Caucasica chamois and the smallest is Abruzo chamois (*R. r. ornata*), (Massei et al. 1993).

Morphometric data on the different Chamois subspecies have been quite limited so far. The authors mentioned above do not address aspects of clinical anatomy.

In our study, elements of clinical anatomy are given for the first time, including the location of infraorbital foramina, dimensions of the foramen magnum, the size and depth of the eye orbits, inter supraorbital foramina distance, as well as the mental and mandibular foramina location and the length of the diastema.

The morphometric data of the skull and mandible of the Balkan chamois are presented in detail in this study (Tables 1, 2, 3, 4, 5, 6 and 7). It is observed that males measurements generally were larger than females, except for parameters related to the orbits and specific features such as Sw, Fmw, Fmh, Icw, Fl, Mw, Ifap which were larger in females. Statistically significant differences were observed in only a few measurements, particularly those related to the cornual processes and horns ($p = 0.08$ and $p = 0.00$, respectively) (Table 6). Thus, sexual dimorphism is not highly pronounced, a finding consistent with other similar studies, such as those by Garcia-Gonzalez and Barandalla (2002) and Miloševič-Zlatanović et al. (2022). However, the latter study notes that among the four subspecies examined, *R.r. balcanica* exhibits the greatest sexual dimorphism, with a correlation of 0.43.

The study shows that the skull of the Balkan chamois is long, narrow and sharp at the top, which is also demonstrated

by the Skull index (40.35), while the orbits (left, right) and foramen magnum appear almost completely circular and it is also shown by their respective index (94.96; 96.16 and 96.28).

Conclusion

In conclusion, this study brings a detailed database for the linear morphometric parameters of the skull and mandible of Balkan chamois, which will serve for comparative studies. The results demonstrate sexual dimorphism between males and females. Clinical parameters brought for the first time can be used in the clinical veterinary practice, especially for the veterinarian working with wild fauna.

Conflict of interest

The authors declared no potential conflicts of interest concerning the research, authorship, and/or publication of this article.

Acknowledgements We thank Martina Đuras from the Department of Anatomy, Histology and Embryology, Faculty of Veterinary Medicine, University of Zagreb for the opportunity and facilities she created for us in measuring the morphometric parameters in some of the Balkan chamois skulls found at the collection of the Faculty of Veterinary Medicine in Zagreb, Croatia

Data availability The data that support the findings of this study are available from the corresponding author upon reasonable request.

References

Al Mohamad Z, Hamed M, Abdellatif A, Eldoumani H, Elshafaey E, Abouelnasr K (2023) Topographical anatomy of the mandibular foramen in the dromedary camels (*Camelus dromedarius*): an extraoral approach for the inferior alveolar nerve blocks. Front Vet Sci 10:1303810. https://doi.org/10.3389/fvets.2023.1303810

Anderwald P, Ambarli H, Avramov S, Ciach M, Corlatti L, Farkas A, Jovanovic M, Papaioannou H, Peters W, Sarasa M, Šprem N, Weinberg P, Willisch C (2020) *Rupicapra rupicapra*. The IUCNRedList of Threatened Species, e. T39255A22149561 https://doi.org/10.2305/IUCN.UK.2020-3.RLTS.T39255A22149561.en

Aragon S, Braza F, San Jose C, Fandos P (1998) Variation in skull morphology of roe deer (*Capreolus capreolus*) in Western and Central Europe. J Mammal 79:131–140. https://doi.org/10.2307/1382847

Avdić R, Hadžiomerović N, Tandir F, Bejdić P, Ćutahija V (2013) Analysis of morphometric parameters of the roe deer mandible (*Capreolus capreolus*) and mandible of the sheep (*Ovis aries*). Veterinaria (Sarajevo) 62:1–9

Choudhary OP, Singh I (2015) Morphometrical studies on the skull of Indian blackbuck (*Antelope cervicapra*). Int J Morphol 33:868–876. https://doi.org/10.4067/S0717-95022015000300011

Choudhary OP, Kalita PC, Doley PJ, Kalita A (2017) Applied anatomy of the head region of the Indian wild pig (*Sus scrofa*) and its clinical value during regional anaesthesia. J Anim Res 7:339–344. https://doi.org/10.5958/2277-940X.2017.00049.3

Choudhary OP, Priyanka P, Kalita PC, Arya RS, Kalita A, Doley PJ (2020) A morphometrical study on the skull of goat (*Capra hircus*) in Mizoram. Int J Morphol 38(5):1473–1478. https://doi.org/10.4067/S0717-95022020000501473

Chovanec V, Chovancová B, Kropil R, Paule L (2005) Morfometrická Charakteristika Kraniolo−Gického Materiálu Kamzíka Vrchovského Tatranského (*Rupicapra Rupicapra Tatrica* Blahout 1971) Deponovaného V Múzeu Tanap−Uv Tatranskej Lomnici. Výskum a ochrana cicavcov na Slovensku VII, 39

Corlatti L, Iacolina L, Safner T, Apollonio M, Buzan E, Ferretti F et al (2022) Past, present and future of chamois science. Wildl Biol 4:e01025. https://doi.org/10.1002/wlb3.01025

Dalga S, Aslan K (2020) Topographic and morphometric study on mental foramen in Hemshin sheep for local anesthesia. MJAVL 10:93–97

Dalga S, Aslan K, Akbulut Y (2018) A morphometric study on the skull of the adult Hemshin sheep. Van Vet J 29:125–129

Daskiran I, Cedden F (2006) Some descriptive characteristics concerning craniometric measurement in Kangal dog. J Anim Vet Adv 5:194–196.

Dučić N, Kovačević S, Tandir F, Avdić R, Šaljić E, Vejzović A, Hadžiomerović N (2024) Craniometric analysis of a cat and clinical significance in performing dental nerve blocks. Adv Anim Vet Sci 12:233–238. https://doi.org/10.17582/journal.aavs/2024/12.2.233.238

Evans KE, McGreevy PD (2006) Conformation of the equine skull. A morphometric study. Anat Histol Embryol 35:221–227

Fernandez-Lopez J, Garcia-Gonzalez R (1986) Craniometrie comparée entre le chamois pyrénéen et le cantabrique. Mammalia 50:87–97

Garcia-Gonzalez R, Barandalla I (2002) Sexual dimorphism of Pyrenean chamois based on skull morphometry. Pirinious 157:25–37. https://doi.org/10.3989/pirineos.2002.v157.58

Goodarzi N, Hoseini TS (2014) Morphologic and osteometric analysis of the skull of Markhoz goat (Iranian angora). Vet Med Int 1:972682. https://doi.org/10.1155/2014/972682

Gündemir O, Duro S, Jashari T, Kahvecioğlu O, Demircioğlu İ, Mehmeti H (2020) A study on morphology and morphometric parameters on skull of the Bardhoka autochthonous sheep breed in Kosovo. Anat Histol Embryol 49:365–371. https://doi.org/10.1111/ahe.12538

Hadžiomerović N, Gündemir O, Kovačević S (2022) Mandible size and shape of the red fox (*Vulpes vulpes*) and golden jackal (*Canis aureus*). Adv Anim Vet Sci 10:364–368. https://doi.org/10.17582/journal.aavs/2022/10.2.364.368

Hrabě V, Koubek P (1984) Craniometrical characteristics of *Rupicapra rupicapra tatrica* (Mamm., Bovidae). Folia Zool 33:73–84

Janssens L, Perri A, Crombe P, Dongen SV, Lawler D (2019) An evaluation of classical morphologic and morphometric parameters reported to distinguish wolves and dogs. J Archeol Sci Rep 23:501–533. https://doi.org/10.1016/j.jasrep.2018.10.012

Jashari T, Duro S, Gündemir O, Szara T, Ilieski V, Mamuti D, Choudhary OP (2021) Morphology, morphometry and some aspects of clinical anatomy in the skull and mandible of Sharri sheep. Biologia 77:423–433. https://doi.org/10.1007/s11756-021-00955-y

Karimi I, Onar V, Pazvant G, Hadipour M, Mazaheri Y (2011) The cranial morphometric and morphologic characteristics of Mehraban sheep in Western Iran. Glob Vet 6:111–117

Kataba A, Mwaanga ES, Simukoko H, Parés CPM (2014) Clinical anatomy of the head region of Gwembe valley dwarf goat in Zambia. Int J Vet Sci 3:142–146. http://hdl.handle.net/10459.1/47773

Kobryńczuk F, Krasińska M, Szara T (2008a) Polarization of skull shapes in adult lowland European bison. *Bison bonasus bonasus*. Ann Zool Fennici 45:341–346. https://doi.org/10.5735/086.045.0416

Kobryńczuk F, Krasińska M, Szara T (2008b) Sexual dimorphism in skulls of the lowland European bison. *Bison bonasus bonasus*. Ann Zool Fennici 45:335–340. https://doi.org/10.5735/086.045.0415

Komosa M, Molinski K, Godynicki S (2006) The variability of cranial morphology in modern horses. Zool Sci 23:289–298. https://doi.org/10.2108/zsj.23.289

Krasińska M, Szuma E, Kobryńczuk F, Szara T (2008) Morphometric variation of the skull during postnatal development in the lowland European bison *Bison bonasus bonasus*. Acta Theriol 53:193–216. https://doi.org/10.1007/BF03193117

Kumawat R, Joshi S, Mathur R, Choudhary OP (2014) Gross anatomical studies on the cranial bones of skull in chital (*Axis axis*). Ind J Vet Anat 26:54–5. https://epubs.icar.org.in/index.php/IJVA/article/view/41382

Magalhães HIR, Romao FB, Paula YH, Luz MM, Barcelos JB, Silva Z et al (2019) Morphometry of the mandibular foramen applied to local anesthesia in hoary fox (*Lycalopex vetulus*). Pesq Vet Bras 39:278–285. https://doi.org/10.1590/1678-5150-PVB-5749

Markov G, Ninov N, Andreev R (2013) Craniological variation of the Balkan chamois, *Rupicapra rupicapra balcanica* from Bulgaria. Folia Zool 62:200–206. https://doi.org/10.25225/fozo.v62.i3.a5.2013

Massei G, Randi E, Markov G, Genov P (1993) Multivariate analysis of craniometrics characters in Bulgarian chamois. Hystrix It J Mamm 5:17–29. https://doi.org/10.4404/hystrix-5.1-2-4000

Merkies K, Paraschou G, McGreevy PD (2020) Morphometric Characteristics of the Skull in Horses and Donkeys - A Pilot Study. Animals 10:1002. https://doi.org/10.3390/ani10061002

Milencovic M, Spedic VJ, Blagojevic J, Tatovic S, Vujosevic M (2010) Skull variation in Dinaric-Balkan and Carpathian gray wolf populations revealed by geometric morphometric approaches. J Mammal 91:376–386. https://doi.org/10.1644/09-MAMM-A-265.1

Milošević-Zlatanović S, Vukov T, Chovancová G, Anderwald P, Corlatti L, Tomašević Kolarov N (2022) Cranial integration and modularity in chamois: The effects of subspecies and sex. J Mammal Evol 30:269–280. https://doi.org/10.1007/s10914-022-09644-2

Mohamed R, Driscoll M, Mootoo N (2016) Clinical anatomy of the skull of the Barbados Black Belly sheep in Trinidad. Int J Curr Res Med Sci 2:8–19 http://s-o-i.org/1.15/ijcrms-2016-2-8-2

Monfared AL (2013a) Gross Anatomical measurements of the head region of the iranian native cattle (*Bos taurus*) and their clinical value for regional anesthesia. Glob Vet 10:219–222. https://doi.org/10.5829/idosi.gv.2013.10.2.724

Monfared AL (2013b) Clinical anatomy of the skull of Iranian native sheep. Glob Vet 10:271–275. https://doi.org/10.5829/idosi.gv.2013.10.3.7253

Okarma H, Buchalczyk T (1993) Craniometrical characteristics of wolves *Canis lupus* from Poland. Acta Theriol 38:253–262. https://doi.org/10.4098/AT.arch.93-21

Olopade JO, Onwuka SK (2009) Morphometric analysis of the skull of the Sahel goat breed: basic and clinical anatomy. Ital J Anat Embryol 114:167–178

Onar V (1999) A morphometric study on the skull of the German shepherd dog (Alsatian). Anat Histol Embryol 28:253–256. https://doi.org/10.1046/j.1439-0264.1999.00202.x

Onar V, Ozcan S, Pazvant G (2001) Skull typology of adult male Kangal dogs. Anat Histol Embryol 30:41–48. https://doi.org/10.1046/j.1439-0264.2001.00292.x

Onuk B, Kabak M, Atalar K (2013) Anatomic and craniometric factors in differentiating roe deer (*Capreolus capreolus*) from sheep (*Ovis aries*) and goat (*Capra hircus*) skulls. Arch Biol Sci 65:133–141. https://doi.org/10.2298/ABS1301141M

Özcan S, Aksoy G, Kürtül I, Aslan K, Özüdogru Z (2010) A comparative morphometric study on the skull of the Tuj and Morkaraman sheep. Kafkas Universitesi Veteriner Fakultesi Dergisi 16:111–114. https://doi.org/10.9775/KVFD.2009.518

Özen AS (2020) Sexual dimorphism and variability in the skull of *Martes foina*. Anim Biol 70:373–383. https://doi.org/10.1163/15707563-bja10020

Özkan E, Siddiq AB, Kahvecioğlu KO, Öztürk M, Onar V (2019) Morphometric analysis of the skulls of domestic cattle (*Bos taurus* L.) and water buffalo (*Bubalus bubalis* L.) in Turkey. Turk J Vet Anim Sci 43:532–539. https://doi.org/10.3906/vet-1903-66

Rezić A, Iacolina L, Bužan E, Safner T, Bego F, Gačić D, Maletić V, Markov G, Milošević D, Papaioannou H, Šprem N (2022) The Balkan chamois, an archipelago or a peninsula? Insights from nuclear and mitochondrial DNA. Conserv Genet 23:527–539. https://doi.org/10.1007/s10592-022-01434-w

Rezić A, Bošković I, Lubinu P, Piria M, Florijančić T, Scandura M, Šprem N (2017) Dimorphism in the skull form of golden jackals (*Canis aureus* Linnaeus, 1758) in the Western Balkans: a geometric morphometric approach. Pak J Zool 532:989–997. https://doi.org/10.17582/journal.pjz/2017.49.3.989.997

Saber A, Gummow B (2015) Skull morphometry of the lion (*Panthera leo*), dog (*Canis lupus familiaris*) and cat (*Felis catus*). J Vet Anat 8:13–30. https://doi.org/10.21608/jva.2015.44849

Saber A, Cacec T, Gummow B, Johns K (2016) Morphometric studies on the skull of the Australian domestic cat (*F. catus*) and its clinical implications for regional anesthesia. J Vet Anat 9:1–24. https://doi.org/10.21608/jva.2016.37445

Sarma K (2006) Morphological and craniometrical studies on the skull of Kagani goat (*Capra hircus*) of Jammu Region. Int J Morphol 24:449–455. https://doi.org/10.4067/S0717-95022006000400025

Srinivas Y, Jhala Y (2021) Morphometric variation in wolves and golden jackal in India (Mammalia, Carnivora). Biodivers Data J 9:e67677. https://doi.org/10.3897/BDJ.9.e67677

Szara T, Klich D, Wójcik AM, Olech W (2023) Temporal trends in skull morphology of the European bison from the 1950s to the present day. Diversity 15(3):377. https://doi.org/10.3390/d15030377

von den Driesch A (1976) A guide to the measurements of animal bones from archaeological sites. Peabody Museum Bulletin 1. Cambridge Mass: Harvard University

Yahaya A, Olopade JO, Kwari HD, Wiam IM (2012) Investigation of the osteometry of the skull of the one humped camels. Part II: sex dimorphism and geographical variations in adults. Ital J Anat Embryol 117:34–44

Younes MI, Fouad FF (2016) Cranial allometry, sexual dimorphism and age structure in sample of the Egyptian wolf *canis anthus lupaster*. AlAzhar Bull Sci 27:1–8. https://doi.org/10.21608/absb.2016.24336

Zhu L (2012) Craniometrical studies on the skull of Tibetan gazelle (*Procapra picticaudata*). Int J Morphol 30:196–198. https://doi.org/10.4067/S0717-95022012000100035

Zhu L, Shi XD, Wang JJ, Chen JG (2014) A morphometric study on the skull of donkey (*Equus asinus*). Int J Morphol 32:1306–1310. https://doi.org/10.4067/S0717-95022014000400030

Zuccarelli MD (2003) Comparative morphometric analysis of captive vs. wild African lion (*Panthera leo*) skulls. Bios 75:131–138. https://doi.org/10.1893/0005-3155(2004)075%3c0131:CMAOCV%3e2.0.CO;2

Publisher's Note Springer Nature remains neutral with regard to jurisdictional claims in published maps and institutional affiliations.

Springer Nature or its licensor (e.g. a society or other partner) holds exclusive rights to this article under a publishing agreement with the author(s) or other rightsholder(s); author self-archiving of the accepted manuscript version of this article is solely governed by the terms of such publishing agreement and applicable law.