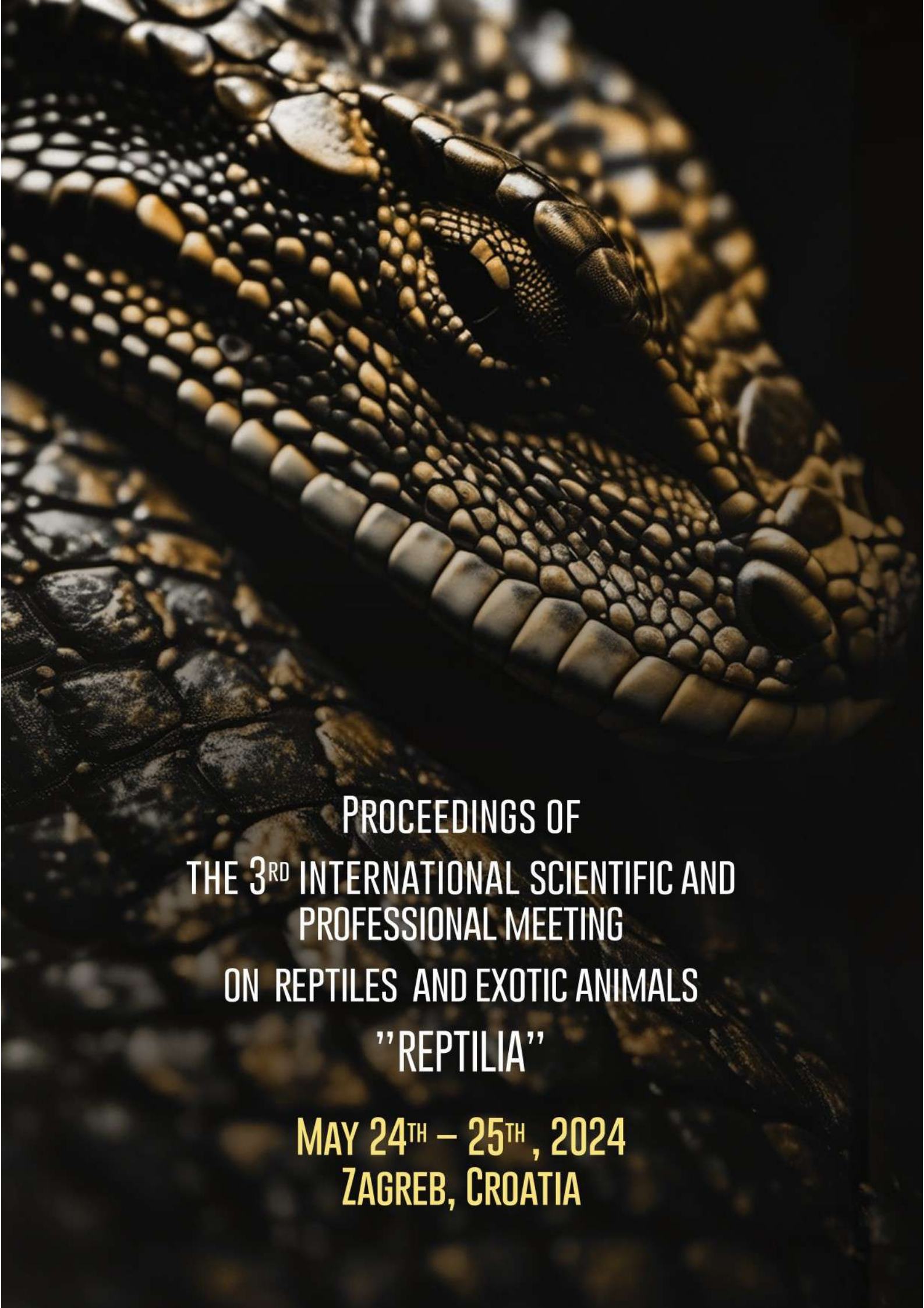

PROCEEDINGS OF THE 3RD INTERNATIONAL SCIENTIFIC AND PROFESSIONAL MEETING ON REPTILES AND EXOTIC ANIMALS "REPTILIA"

MAY 24TH – 25TH, 2024
ZAGREB, CROATIA

3RD INTERNATIONAL SCIENTIFIC AND PROFESSIONAL MEETING ON REPTILES AND EXOTIC ANIMALS "REPTILIA"

REPTILIA

Proceedings

Faculty of Veterinary Medicine, University of Zagreb

May 24th – 25th, 2024

Zagreb, Croatia

Proceedings
of

3RD INTERNATIONAL SCIENTIFIC AND PROFESSIONAL MEETING ON REPTILES AND EXOTIC ANIMALS "REPTILIA"

REPTILIA

Edited by

Srebrenka Nejedli

Coeditors

Mirela Pavić Vulinović, Ana Shek Vugrovečki and Ivona Žura Žaja

Publisher

Faculty of Veterinary Medicine University of Zagreb

Tehnical editors

Ivana Sabolek and Josip Miljković

Grafic design

Tea Novak

May 24th – 25th, 2024
Zagreb, Croatia

ISBN 978-953-8006-47-0

3RD INTERNATIONAL SCIENTIFIC AND PROFESSIONAL MEETING ON REPTILES AND EXOTIC ANIMALS "REPTILIA"

Faculty of Veterinary Medicine, University of Zagreb

May 24th – 25th, 2024

Zagreb, Croatia

ORGANIZER
Faculty of Veterinary Medicine, University of Zagreb

UNDER THE AUSPICES OF
Zoo Graden Zagreb

ORGANIZING COMMITEE
Srebrenka Nejedli, president

Ana Shek Vugrovečki, Ivona Žura Žaja, vice-presidents

Lucija Bastiančić, Maja Belić, Miloš Blagojević (RS), Hrvoje Capak, Eva Čermáková (CZ), Sokol Duro (AL), Siniša Faraguna, Gordana Gregurić Gračner, Miloš Halán (SK), Alen Hrastnik, Amina Hrković-Porobija (BA), Doroteja Huber, Gabrijela Jurkić Krsteska, Anđelko Gašpar, Jasna Kusanović, Denis Leiner, Duje Lisičić, Martina Lojkić, Maja Lukač, Josip Miljković, Ivana Jovandin (UE), Mirela Pavić Vulinović, Ivana Sabolek, Lana Pađen, Damir Skok, Ozren Smolec, Daniel Špoljarić

SCIENTIFIC COMMISCIENTIFIC COMMITEE
Martina Đuras, Valentina Kubale Dvojmoč (SI), Boris Habrun, Andrea Gudan Kurilj, Danijela Horvatek Tomić, Tugomir Karadjole, Zdenek Knotek (CZ), Dean Konjević, Nino Maćešić, Albert Marinculić, Damir Mihelić, Srebrenka Nejedli, Marina Pavlak, Maja Popović, Estella Prukner-Radovčić, Marko Samardžija, Elizabeth MS Schmidt (BR), Ivana Tlak Gajger, Ksenija Vlahović

All papers published in this Proceedings have been reviewed.

TABLE OF CONTENTS

INVITED LECTURES…… 1

Emergency cases in reptile practice…… 2

Amphibians and reptiles: marvels of physiology…… 6

Seeing Through Water: Anatomical and Histological Diversity in Fish Eyes with Histological Adaptations of Some Species..... 11

Branching pattern of the external carotid artery in the african green monkey (C*ercopithecus aethiops sabeus*)…….. 16

Clinical pathology of Brazilian reptiles…….. 22

The threat of *Tropilaelaps* spp. mites invasions for European beekeeping……. 26

Newly Emerging Infections in Pet Ferrets (*Mustela putorius furo*) – clinical presentations…… 31

ORAL PRESENTATIONS……. 32

The significance of the specificity of the digestive system and microbial fermentation in the digestion of herbivorous lizards…… 33

The influence of captivity on aggressivity of wild caught and laboratory raised Italian wall lizard, *Podarcis siculus*…….. 39

Fatty acid composition – what can we learn from…….. 45

Preferred body temperature of Italian lizards (*Podarcis siculus*) and common wall lizards (*Podarcis muralis*) under laboratory conditions…… 50

Machine learning in behavioural biology: using deep neural networks to assess aggression in lizards…… 54

Development, anatomical and histological organisation of central nervous system in snakes……. 59

Skin color of lizards, purpose of the change and how it changes in Panther Chameleon (*Furcifer pardalis*) and Green Anole (*Anola carolinensis*)…… 65

The characteristics of renal sexual segment in reptiles…….. 71

Comparison of histopathology and PCR examination results in arenavirus infection of snakes…… 75

Reference intervals for blood analysis in Snaked-necked freshwater turtles (*Hydromedusa tectifera*) in southern Brazil…… 80

Lung flukes of the genus *Haematoloechus* sp. in Asian Puddle Frogs (*Occidozyga lima*) from a veterinary point of view…….. 85

Clinical approach to the anemic ferret…… 91

Congenital anomalies of llamas and alpacas……. 94

Laboratory diagnosis of anemia in reptiles……. 98

Infertility in crested geckos (*Correlophus ciliatus*, Guichenot 1866.)..... 102

Blood fatty acid composition of different reptile species – a preliminary study……. 108

Body condition assessment in Indian star tortoises (*Geochelone elegans*)……. 114

Reptile enclosure design and optimal materials - what do we know?..... 120

Health inspection in Falcon Veterinary Practice: Insights from the United Arab Emirates 125

Blood analytes in urban and non-urban free-ranging Spectacled Caimans (*Caiman crocodilus* Linnaeus, 1758) in the central region of the Brazilian Amazon…… 130

Blood sample collection sites in South American tortoises (*Chelonoidis* spp.): a review... 136

Venomous snakes in captivity…… 140

POSTER PRESENTATIONS..... 141

Fish mycobacteriosis: bridging the gap between aquarium fish health and human health.. 142

Understanding the sting apparatus and venom composition of bees and hornets…… 143

Loggerhead Sea Turtles (*Caretta caretta)* as Hosts of Diverse Bacterial and Fungal Communities…….. 144

Ball python (*Python regius*) colour morphs - genetics and health……... 145

Comparative morphology and neurology of the Budgerigar (*Melopsittacus undulatus*), Cockatiel (*Nymphicus hollandicus*), Canary (*Serinus canaria)* and Zebra finch (*Taeniopygia guttata*)…… 146

The influence of environmental pollutants on the endocrine function of frogs……... 147

Is it possible to determine the sex of African lovebirds (*Agapornis* spp.) visually or by palpation?..... 148

Exploring protein electrophoresis as a diagnostic tool in reptilian medicine: A review….. 149

Histological study of the osteoderms in the skin of the common wall gecko (*Tarentola mauritanica*)…….. 150

Xanthoma recurrence in a Sulphur-crested cockatoo (*Cacatua galerita*) - a case report… 151

Breeding raccoons in captivity……... 152

Influence of gecko´s group size onto their vocalisation during feeding…… 153

Histological and anatomical characteristics of Budgerigars: adaptations for flight, communication, and survival……. 154

Temperature-dependent sex determination in reptiles…… 155

A Comparative Study of Marine Iguanas (*Amblyrhynchus cristatus*) and Green Iguanas (*Iguana iguana*): Habitat, Anatomy, Behavior, and Special Adaptations…….. 156

Presence of microplastics in amphibian tissue……... 157

Cavia porcellus with aberrant Kurloff cells: a case report…….. 158

Sexual dimorphism and geographic variation of the Caspian Whip Snake *Dolichophis caspius* (Gmelin, 1789) in Croatia…….. 159

The adaptation of the auditory apparatus structure of lizards and crocodiles to their habitat…….. 160

Cooperative Care: Enhancing Reptile Welfare in Veterinary Medicine……. 161

Neonatal care in bats……... 162

Characteristics of the adrenal gland in reptiles…… 163

Introduction of Dwarf Zebu Cattle (*Bos indicus*) into European Cattle Breeding……... 164

Effects of lithium heparin and dipotassium ethylenediaminetetraacetic acid on packed cell volume of blood samples of Indian star tortoise (*Geocheleone elegans*)……. 170

Abrasions and abscesses of the nasal region in captive snakes (a clinical case series)…… 171

Minimizing stress in the rehabilitation of wild birds…….. 172

The use of electrophoresis in snake venom research…….. 173

Monitoring the Microscopic Vascular Changes Induced by the Venom of the Medically Significant Snake Species *Bothrops jararaca*…… 174

Photobiomodulation as a supportive wound healing treatment in galah (*Eolophus roseicapilla*) – a case report…… 176

A rescue center specialized for reptiles - the « Refuge reptiles-reptilien »…….. 177

The blood squirting Texas horned lizard (*Phrynosoma cornutum*)…… 178

A case of corneal deposits and vision loss after feather colour change in the red-winged parrot (*Aprosmictus erythropterus*)…… 179

Microscopic identification of active phagocytes in the blood of the European pond turtles (*Emys orbicularis)*……..... 180

Preliminary research on sponge farming in the Adriatic Sea…….. 181

American foulbrood outbreaks in colonies of African honeybee subspecies (*Apis mellifera capensis, Apis mellifera scutellata*)……. 186

Does wireless communication technology have the same impact on insects and reptiles?. 187

New Caledonian Crested Gecko (*Correluphus ciliatus,* GUICHENOT, 1866) cholecystectomy…… 192

An overview of scorpion anatomy, behavior, reproduction, venom, and therapeutic potential……. 193

Branching pattern of the external carotid artery in the African greenmonkey (*Cercopithecus aethiops sabeus*)

Milos Blagojevic[1], Srebrenka Nejedli[2], Maciej Zdun[3], Ozan Gündemir[4], Iliana Ruzhanova-Gospodinova[5], Ivana Nesic[1], Milena Djordjevic[1], Nikola Cukic[1], Dejana Cupic-Miladinovic[1]

[1]Department of Anatomy, Faculty of Veterinary Medicine, University of Belgrade, Belgrade, Serbia
[2]Department of Anatomy, Histology and Embriology, Faculty of Veterinary Medicine, University of Zagreb, Zagreb, Croatia
[3]Department of Basic and Preclinical Sciences, Nicolaus Copernicus University in Torun, Torun, Poland
[4]Department of Anatomy, Faculty of Veterinary Medicine, Istanbul University-Cerrahpasa, Istanbul, Türkiye
[5]Department of Anatomy, Physiology and Animal Sciences, Faculty of Veterinary Medicine, University of Forestry, Sofia, Bulgaria

Abstract

The African green monkey cadavers, of both sexes, aged 3 to 4 years, weighed between 2.000 and 3.000 g were obtained from the Institute of Immunology and Virology "Torlak" from Belgrade. Visualization of the arteries of the head and neck was obtained by injecting a contrast mass, gelatin colored with red tempera, into the thoracic aorta. The right and left external carotid arteries represent the continuation of the corresponding common carotid arteries. After the arising of right and left *a. thyroidea*, *a. laryngea caudalis*, *truncus linguofacialis*, *a. pharyngea ascendens*, *a. occipitalis*, *a. auricularis caudalis* and *a. temporalis superficialis*, each the external carotid artery continues as maxillary artery. In the pterygopalatine fossa, the maxillary artery branches into the following six ones: *rami pterygoidei*, *a. buccalis*, *aa. temporales profundae*, which are usually two, caudal and rostral arteries, *a. alveolaris mandibularis*, *a. meningea media*, and *a. palatina descendens* with its branches: *a. sphenopalatina*, *a. palatina major* and *a. palatina minor*.

The results of this study are significant for comparative studies among different species of primates, humans and domestic mammals. The present study on morphology and distribution of the external carotid artery in the African green monkeys points to higher anatomical correlation between African green monkeys and humans than between the African green monkeys and domestic mammals.

Keywords: monkey, arteries, head, neck

Introduction

The African green monkeys, GA-monkeys, (*Cercopithecus aethiops sabeus*) belong to the family of Old World monkeys, including macaques and baboons monkeys (WILSON and REEDER, 2005). These monkeys, as non-human animals are interesting for anatomical studies of morphology and vascularization of their organs. A number of researchers have described the arterial vessels of the head and neck through the external and internal carotid arteries of primates (COCEANI and GLOOR, 1966; KUMAR et al., 2009) domestic mammals (GETTY et al., 1975; ASHWINI et al., 2008; CHADZYPANAGIOTIS and KUBASIC 2008; JACQMOT et al., 2011; KAPOOR et al., 2003) and humans (RANI et al., 2020; MACCHI et al., 2003; HAYASHI et al., 2005; AYSUN et al., 2004). A detailed knowledge of the external carotid

artery branching pattern in humans is of significance in head and neck surgery (HAYASHI et al., 2005). There are no publications to our knowledge on branching pattern of the external carotid artery in GA- monkeys. The aim of this study was to describe the origin and basic branching pattern of the GA-monkeys external carotid arteries.

Material and methods

The investigation was carried out on 7 fresh GA- monkey cadavers, of both sexes, aged 3 to 4 years, weighed between 2.000 and 3.000 g. These cadavers obtained from the Primate Laboratory (No. 123, 15.01.2008) of the Institute of Immunology and Virology "Torlak" from Belgrade, based on a letter from the Department of Anatomy, Faculty of Veterinary Medicine, Belgrade (No. 223, December 6, 2007) with the intention of making a collection of anatomical and histological samples of the organs and blood vessels of these monkeys. Visualization of the arteries of the head and neck was obtained by injecting a contrast mass, gelatin colored with red tempera, into the thoracic aorta. The arteries were photographed with a digital camera (OLYMPUS 7.1 MP Digital Camera Silver FE-230). An approval for this investigation was issued by the ethical committee No. 01-2/8, and was obtained on April 4, 2008.

Results

The external carotid artery (*a. carotis externa*) (Fig. 1 – 3A), right and left, arise from the corresponding common carotid artery (*a. carotis communis*) at the level of the C_1-C_2 or C_2-C_3 vertebra. Its branches are as follows:

The cranial thyroid artery (*a. thyroidea cranialis*) is the first branch of the external carotid artery. It supplies the thyroid gland (ramus thyroideus), the wall of the cranial part of the trachea (ramus trachealis) and the wall of the esophagus (ramus esophageus).

The cranial laryngeal artery (*a. laryngea cranialis*) (Fig. 1 - 4A and Fig. 2 – 10A) most frequently arises from the ventral surface of the external carotid artery.

The linguofacial trunk (*truncus linguofacialis*) (Fig. 1 – 11B and Fig. 2 – 11A, 19A) comes out from the external carotid artery, 1 mm to 2 mm from its beginning, passes rostrally through the intermandibular space and in the vicinity of the caudal edge of the mandibular ramus bifurcates into the lingual and the facial arteries.

The lingual artery (*a. lingualis*) (Fig. 1 – 6B, 10B) is a direct continuation of the common trunk. It passes deep to the hyoglossus muscle where it bifurcates into the sublingual (*a. sublingualis*) and deep lingual arteries (*a. profunda linguae*). The sublingual artery brings blood to the bottom of the oral cavity, while the deep lingual artery enters the tongue and supplies its body and the tip. The deep lingual artery also sends a glandular branch to the sublingual salivary gland.

The facial artery (*a. facialis*) (Fig. 1 – 7A, 11B and Fig. 2 – 16A) passes through the intermandibular space, adjacent to the medial side of the pterygoid muscle towards the mandibular notch (*incisura vasorum facialium*) and further extends dorsally, along the cranial border of the masseter muscle. The facial artery gives off five branches: a) the glandular branch (Fig. 1 – 8A, 12A) to the mandibular salivary gland; b) numerous small muscular to the masseter (Fig. 2 – 14A) and medial pterygoid muscles; c) the submental artery (Fig. 1 – 14B) which runs along the ventral border of the mandible and distributes to the anterior digastric and platysma muscles; d) the inferior labial artery (Fig. 1 – 13A and Fig. 2 – 17A) to the lower lip and e) the superior labial artery to the upper lip.

The ascending pharyngeal artery (*a. pharyngea ascendens*) (Fig. 2- 9B) is thin, long and lies external to the pharyngeal muscles, against the bulla. It sends branches to the cranial part of the roof and lateral wall of the pharynx.

The occipital artery (*a. occipitalis*) (Fig. 1– 15A and Fig. 2 – 12A) gives rise to branches to the muscles that are attached to the occipital bone, the dura mater of the brain and the auricle.

The caudal auricular artery (*a. auricularis caudalis*) (Fig. 1- 16A and Fig. 2 – 13B) arises from the external carotid artery deeply, under the parotid salivary gland as a separate branch. Its terminal branches bring arterial blood to the base of the auricle and the skin of the occipital region.

The superficial temporal artery (*a. temporalis superficialis*) (Fig. 2 – 15B) is the terminal branch of the external carotid artery. Its initial part is covered with the parotid salivary gland. The superficial temporal artery passes over the zygomatic arch rostral to the external auditory canal, between the temporomandibular joint and the base of the auricle. The transverse facial artery (*a. transversa faciei)* (Fig. 2 – 18B) arises from the beginning part of the superficial temporal artery. It runs horizontally over the lateral surface of the masseter muscle and dorsal to the facial nerve. It gives off branches to the masseter muscle and the skin of the cheek.

The maxillary artery (*a. maxillaris*) is the continuation of the external carotid artery. Along its course to the pterygopalatine fossa, the maxillary artery passes into the inner side of the mandibular ramus and lies between the mandibular ramus and the medial pterygoid muscle. In the pterygopalatine fossa, the maxillary artery gives off the following branches: a) *rami pterygoidei* to the pterygoid muscle; b) the buccal artery (*a. buccalis*) to the buccinator muscle. The major portion of the buccinator muscle is supplied by the branches of the facial artery; c) the deep temporal arteries (*aa. temporales profundae*) are usually two, the caudal and rostral arteries, which supply the temporal muscle; d) the mandibular alveolar artery (*a. alveolaris mandibularis*) which enters the mandibular canal through the *foramen mandibulae* where it gives off the branches (*rami dentales*) to the gingiva and teeth of the mandible; e) the middle meningeal artery (*a. meningea media*) enters the cranial cavity and branches into the dura mater; f) the descending palatine artery (*a. palatina descendens*) and its branches: 1) the sphenopalatine artery (*a. sphenopalatina*) passes through the sphenopalatine foramen into the nasal cavity and branches in the mucous membrane of the nasal cavity; 2) the greater palatine artery (*a. palatina major*) passes through the great palatine canal and branches into the hard palate and 3) the lesser palatine artery (*a. palatine minor*) which passes along the lateral side of the pterygoid process of the sphenoid bone and branches into the soft palate.

Discussion

The external carotid artery was one of the terminal branches of the common carotid artery, supplying blood to the face and neck in African green monkeys (GA-monkeys), macaque monkeys (KUMAR et al., 2009), humans (SANJEEV et al., 2010) and domestic mammals (GETTY et al., 1975). The common carotid arteries, the right and left, usually gave off the external carotid arteries at the level of the C_1-C_2 or C_2-C_3 vertebra in GA-monkeys, at the level of the C_3-C_4 vertebra in macaque monkeys (KUMAR et al., 2009), at the level of the C_3 vertebra in humans (RAO and SHETTY, 2011; RANI et al. 2020) and at the level of the atlas in dogs, pigs and horses (GETTY et al., 1975).

The cranial thyroid artery in rhesus macaque monkeys (CASTELLI and HUELKE, 1965) and other macaque monkeys (KUMAR et al., 2009) usually arose from the linguofacial trunk. In GA-monkey, similarly to humans (SANJEEV et al. 2010) it separated from the external carotid artery. However, in domestic mammals (GETTY et al., 1975) it separated from the common carotid artery.

The cranial laryngeal artery in rhesus macaque monkeys (CASTELLI and HUELKE, 1965) and humans (SANJEEV et al., 2010) was the branch of the superior thyroid artery while in the GA- monkeys and dogs (GETTY et al., 1975) it arose from the external carotid artery.
The linguofacial trunk in GA-monkeys, macaque monkeys (CASTELLI and HUELKE, 1965; KUMAR et al., 2009), horses and large ruminants (GETTY et al., 1975) was the common trunk of the lingual and facial arteries. In humans, the lingual and facial arteries arose from the external carotid as separate branches (SANJEEV et al., 2010).

In the present study the occipital and caudal auricular arteries arose as separated branches from the external carotid artery. This finding was also described by GETTY et al. (1975) in dogs and horses and SANJEEV et al. (2010) in humans. CASTELLI and HUELKE (1965) found that these arteries most frequently arose by a common trunk from the external carotid artery in the rhesus macaque monkeys.

The maxillary artery was the continuation of the external carotid artery in GA- monkeys, macaque monkeys (CASTELLI and Huelke, 1965; KUMAR et al., 2009), humans (SANJEEV et al., 2010) and domestic mammals (GETTY et al., 1975). The maxillary artery of the GA-monkeys had a similar branching pattern as that of macaque monkeys, humans and domestic mammals.

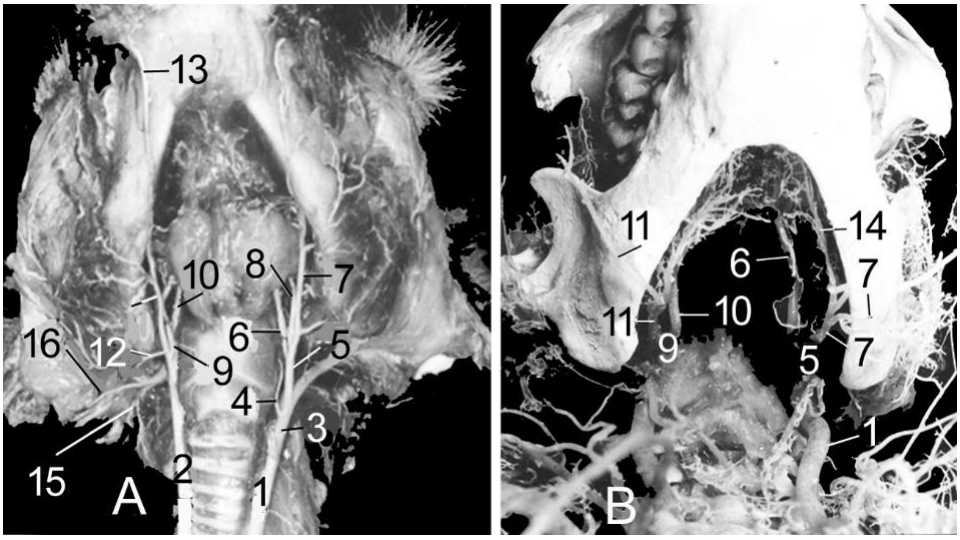

Figure 1. The arteries of the head of the African green monkey (*Cercopithecus aethiops sabeus*) A and B. Ventral view. 1 – a. carotis communis sinistra, 2 – a. carotis communis dextra, 3A – a. carotis externa sinistra, 4A – a. laryngea cranialis sinistra, 5 – truncus linguofacialis sinister, 6B – a. lingualis sinistra, 7A – a. facialis sinistra, 8A - ramus glandularis sinister of a. facialis sinistra, 9 – truncus linguofacialis dexter, 10B – a. lingualis dextra, 11B – a. facialis dextra, 12A – ramus glandularis dexter of a. facialis dextra, 13A – a. labialis inferior, 14B – a. submentalis sinistra, 15A – a. occipitalis, 16A– a. auricularis caudalis

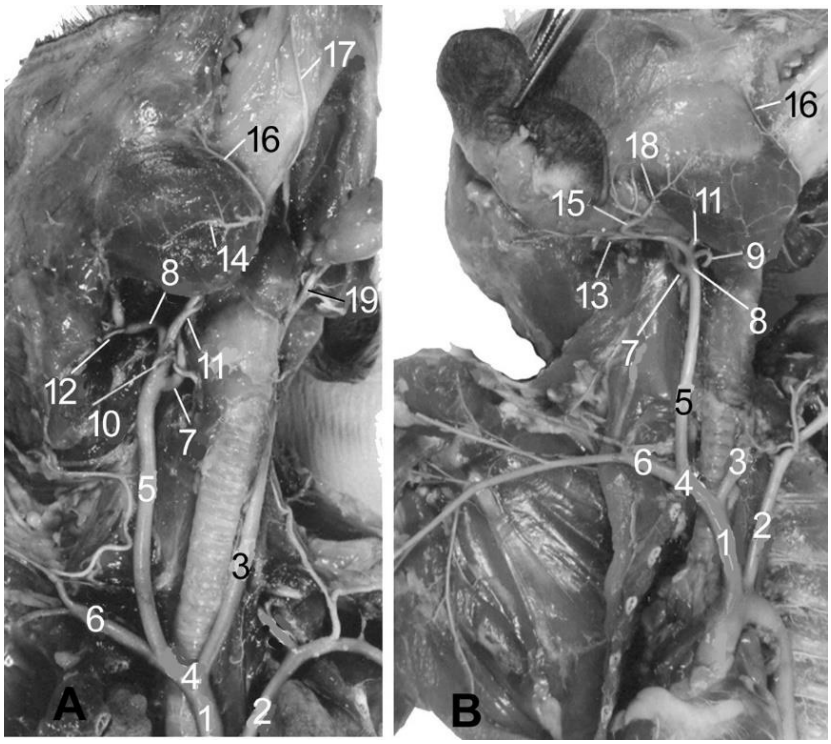

Figure 2. The arteries of the head of the African green monkey (*Cercopithecus aethiops sabeus*). 1 – truncus brachiocephalicus, 2 – a. subclavia sinistra, 3A – a. carotis communis sinistra, 4A – common trunk for a. carotis communis dextra et a. subclavia dextra, 5 - a. carotis communis dextra, 6 - a. subclavia dextra, 7 – a. carotis interna dextra, 8 – a. carotis externa dextra, 9B – a. pharyngea ascendens, 10A – a. laryngea cranialis dextra, 11A – truncus linguofacialis dexter, 12A – a. occipitalis, 13B – a. auricularis caudalis, 14A – ramus massetericus of a. facialis, 15B – a. temporalis superficialis, 16A – a. facialis dextra, 17 – a. labialis inferior, 18B – a. transversa faciei, 19A – truncus linguofacialis sinister

Conclusion

The present study on morphology and distribution of the external carotid arteries in the African green monkeys pointed to higher anatomical correlation between African green monkeys and humans than between the African green monkeys and domestic mammals.

References

ASHWINI, C., A. SHUBHA, R. K. JAYANTHI (2008): Comparative anatomy of the circle of Willis in man, cow, sheep, goat and pig. Neuroanatomy 7, 54-65.

AYSUN, U., K. M. ERBIL (2004): A morphological study of the posterior communicating artery. Folia Morphol. 63, 397–399.

CASTELLI, W. A., D. HUELKE (1965): The arterial system of the head and neck of the rhesus monkey with emphasis on the external carotid system. Am. J. Anat. 116, 149-170.

CHADZYPANAGIOTIS, D., D. A. KUBASIC (1968): Arteries supplying blood to the brain in the cat. Folia Morphol. 37, 477-487.

COCEANI, F., P. GLOOR (1966): The distribution of the internal carotid circulation in the brain of the macaque monkey (*Macaca mulatta*). J. Comp. Neurol. 128, 419-429.

GETTY R., S. SISSON, J. D. GROSSMAN (1975): The anatomy of the domestic animals, fifth edition, W. B. Saunders Company, Philadelphia, London, Toronto.

HAYASHI, N., E. HORI, Y. OHTANI, O. OHTANI, N. KUWAYAMA, S. ENDO (2005): Surgical anatomy of the cervical carotid artery for carotid endarterectomy. Neurol. Med. Chir. 45, 25-29.

JACQMOT, D. O., R. F. SNAPS, M. N. MAQUET, A. MP. HEINEN, E. A. GABRIEL (2011): Arterial Head Vascularization Cartographies of Normal Metencephalic Dogs Using Magnetic Resonance Angiography. Anat. Rec. 294, 1834–1841.

KAPOOR, K., V. K. KAK, B. SINGH (2003): Morphology and comparative anatomy of circulus arteriosus cerebri in mammals. Anat. Histol. Embriol. 32, 347-355.

KUMAR, N., J. J. LEE, J. S. PERLMUTTER, C. P. DERDEYN (2009) Cervical carotid and circle of Willis arterial anatomy of macaque monkeys: Comparative anatomy study. Anat. Rec. 292, 976-984.

MACCHI, C., R. M. LOVA, B. MINIATI, M. GULISANO, C. PRATESI, A. A. CONTI (2003): Relationship between the calibre of carotid arteries and the configuration of the circle of Willis in healthly older persons. J. Cardiovasc. Surg. 44, 231-236.

NOMINA ANATOMICA VETERINARIA (2017): Prepared by the International Committee on Veterinary Gross Anatomical Nomenclature (I.C.V.G.A.N.), sixth edition. Editorial Committee Hannover (Germany), Ghent (Belgium), Columbia, MO (U.S.A.), Rio de Janeiro (Brazil).

RAJEEV, M., D. I. MANSUR, B. P. POWAR (2020): Anatomical variations in the branches of external carotid artery in cadavers of Nepalese origin. J. Human Anat. 4, 1-6.

RANI, S., S. TABASSUM, V. VARSHA, G. S. JHA, S. K. KARN (2020): A study of branching pattern of external carotid artery in human cadavers. Int. J. Sci. Res. 9, 23-24.

RAO, T. R., P. SHETTY (2011): Unusual branching pattern of external carotid artery in a cadaver. Chang Gung Med. J. 34, 24–27.

SANJEEV, I. K, H. ANITA, M. ASHWINI, U. MAHESH, G. B. RAIRAM (2010): Branching pattern of external carotid artery in human cadavers. J. of Clinical and Diagnostic Res. 4, 128-133.

WILSON D. E., D. M. REEDER (2005): Mammal species of the world, 3rd edition, Johns Hopkins University Press, 181-184.