Cerrahpaşa Med J 2023; 47(3): 270-273

ORIGINAL ARTICLE

# Localized-Type Tenosynovial Giant Cell Tumors of the Upper Extremity: A 20-Year Retrospective Study with 139 Patients

Fatih Çınar[1], Mehmet Beşir Öner[2], Can Ege Yalcin[3], Ersin Yavuz[3], Ugur Celik[4], Nil Comunoglu[5], Semih Baghaki[6]

[1]Department of Plastic, Reconstructive and Aesthetic Surgery, Basaksehir Cam ve Sakura City Hospital, Istanbul, Turkey
[2]Private Practice, Istanbul, Turkey
[3]Department of Plastic, Reconstructive and Aesthetic Surgery, İstanbul University-Cerrahpaşa Cerrahpaşa Faculty of Medicine, Istanbul, Turkey
[4]Department of Plastic, Reconstructive and Aesthetic Surgery, Sultangazi Haseki Research and Training Hospital, Istanbul, Turkey
[5]Department of Pathology, İstanbul University-Cerrahpaşa Cerrahpaşa Faculty of Medicine, Istanbul, Turkey
[6]Department of Plastic, Reconstructive and Aesthetic Surgery, Koc University Faculty of Medicine, Istanbul, Turkey

***Cite this article as:*** Çınar F, Öner MB, Yalcin CE, et al. Localized-type tenosynovial giant cell tumors of the upper extremity: A 20-year retrospective study with 139 patients. *Cerrahpaşa Med J.* 2023;47(3):270-273.

## *Abstract*

**Objective:** Localized-type tenosynovial giant cell tumor is a rare, benign tumor that originates from synovial joints, tendon sheaths, and bursae. It has 2 forms: diffuse and localized. The localized form is most commonly found in hand and knee joints. The aim of this study is to present and evaluate the behavior of the tumor, its recurrence rates, its distribution by gender and localization, and the demographic features of affected individuals.

**Methods:** In this study, charts of patients operated on localized-type tenosynovial giant cell tumors located at the upper extremity between 2000 and 2020 were retrospectively evaluated.

**Results:** A total of 139 patients underwent surgery for a localized-type tenosynovial giant cell tumor of the upper extremity, with 99 of them being female and 40 being male. The average age of the patients was 45.9 years. Among these cases, 114 (82%) were localized in the fingers, 13 (9.8%) were in the palmar and dorsal regions, 6 (4.3%) were in the wrists, 4 (1.88%) were in the elbows, and 1 (0.7%) was in the shoulder. The first finger was the most frequently affected location, accounting for 24.5% of cases, and the tumor was more commonly seen on the right hand. This study provides information on the tumor's location, its correlation with relapse, and any comorbidities that may be present.

**Conclusion:** Localized-type tenosynovial giant cell tumors are rare neoplasms. This study concludes that overuse of the extremities and female sex may be risk factors for developing the tumor.

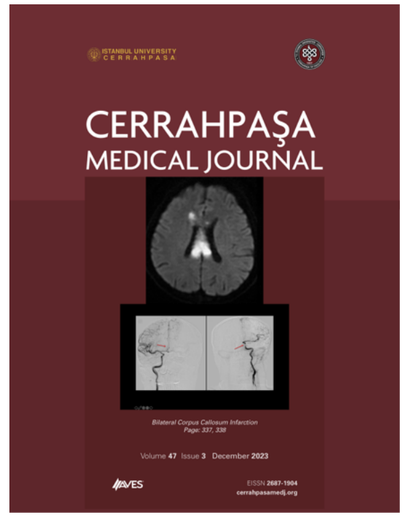


Volume 47, Issue 3, December 2023

Latest Issue

Archive

SHARE

POPULAR ARTICLES

The Effects of Two Different Concentrations of Levobupivacaine on Free Radicals in Blood, Brain, and Heart Tissues of Adult Rats
Y. Tunalı et al.

A 16-Year Analysis of Antifungal Susceptibilities of Invasive Candida