Sezgin and Ersoy
Egyptian Journal of Forensic Sciences (2023) 13:44
https://doi.org/10.1186/s41935-023-00364-z

Egyptian Journal of Forensic Sciences

ORIGINAL ARTICLE Open Access

Metric and morphological features of the ear in sex classification

Nurdan Sezgin[1*] and Gökhan Ersoy[2]

Abstract

Background The human face can reveal a great deal about a person's identity. Age, sex, and ethnicity differences can be recognized, classified, and analyzed using facial features, which give a scientific basis for personal identification and recognition. Sex, like age and ethnicity, has a significant influence on outer ear morphology. The shape and size of the auricle, which is one of the defining features of the face, are affected by age, sex, and ethnicity. Variations in the outer ear are known to be sufficient for identification in a forensic case and can help in determining whether the suspect is guilty or not. The aim of this research is to determine whether such metric and morphological features of the ear can be used to estimate sex and how dimorphic they are. After ear measurements with ImageJ 1.52a program, statistical data was recorded and analyzed in SPSS.

Results This study, which analyzed 350 people's facial images, provides significant information for forensic applications. Among the analyzed ear morphology data, the helix and ear lobe form showed sex differences. Except for the T-PCC distance, all measurements differed significantly between sexes.

Conclusions Model 1 has the greatest accuracy rate (88%) among the models created for sex estimation. Sex estimation can be performed as an effective method when the morphological and metric parameters of the ear are analyzed together.

Keywords Sex classification, Sexual dimorphism, Sex estimation, Ear morphology

Background

Facial features play a crucial role in helping us recognize, categorize, and study variations in factors like age, sex, and ethnicity. They offer a scientific foundation for identifying and acknowledging individuals (Alabi et al. 2019). Essentially, a person's face can reveal a wealth of information about who they are (Boutros et al. 2019).

Age, sex, and ethnicity are significant factors that affect the outer ear structure (Ugochukwu et al. 2017). Anthropometric studies have shown a significant sexual dimorphism in pinna measurements, which can be used to determine sex. Furthermore, it is well recognized that sex affects auricular morphometric data greatly (Alabi et al. 2019).

A full-frontal view of a person is difficult to obtain, especially from security camera footage. In these situations, images of a person's side profile and their ears can be quite valuable. Moreover, the ear is a useful biometric feature because it is not easily affected by variations in lighting conditions (Yaman et al. 2021). Images that are partly covered might only show a person's side face or ear. Despite having a wider rate of applications than face recognition, sex classification from a part of the face or the entire image is a discussed topic (Kaur et al. 2017; Terhörst et al. 2019).

One of the defining features of the face is the auricle. Age, sex, and ethnicity all have an impact on the size and shape of the auricle. As a result, some generalizations

*Correspondence:
Nurdan Sezgin
nurdansezgin@gmail.com
[1] Department of Forensic Sciences, Faculty of Engineering and Natural Sciences, Kütahya Health Sciences University, Merkez, Kütahya, Turkey
[2] Institute of Forensic Sciences and Legal Medicine, İstanbul University-Cerrahpaşa, Büyükçekmece, Istanbul, Turkey

Springer Open

© The Author(s) 2023. **Open Access** This article is licensed under a Creative Commons Attribution 4.0 International License, which permits use, sharing, adaptation, distribution and reproduction in any medium or format, as long as you give appropriate credit to the original author(s) and the source, provide a link to the Creative Commons licence, and indicate if changes were made. The images or other third party material in this article are included in the article's Creative Commons licence, unless indicated otherwise in a credit line to the material. If material is not included in the article's Creative Commons licence and your intended use is not permitted by statutory regulation or exceeds the permitted use, you will need to obtain permission directly from the copyright holder. To view a copy of this licence, visit http://creativecommons.org/licenses/by/4.0/.

are possible. For instance, ear size varies by ethnicity, ear size increases with age, and males' ears are larger than females' ear. Therefore, it is possible to come across ear morphology studies in the literature frequently. However, there is no current agreement on the terminology used to describe the auricle (Alexander et al. 2011).

It is noted that variations in the outer ear are sufficient for identification in forensic analysis and can help in the identification of a suspect as a criminal (Cameriere & DeAngelis 2011; Singh & Purkait 2009). From the camera images taken at the crime scene, these unique ear features and variations can help in identification (Hoogstate et al. 2001).

The aim of this research is to determine whether such metric and morphological features of ear can be used to estimate sex and how dimorphic they are.

Methods

A total of 350 participants, 155 females and 195 males, ages 18 to 92, whose informed consent was obtained and whose ear images were collected for one of the authors Sezgin's (2017) doctoral thesis titled "Digitally metric examining of age-related changes in human face," were used in this study (Sezgin 2017). These images were measured in mm using ImageJ 1.52a (Rasband W, NIH, USA). Measurements and morphological descriptions were recorded in SPSS (Statistical Package for the Social Sciences) (version 21.0 SPSS, Chicago, IL, USA). The Pearson chi-square test was used to analyze differences in the distribution of morphological groupings between sexes. The independent sample *t*-test was employed to determine the sex difference in the measured data. ROC curve analysis was utilized to define the cutoff points for sex estimation in ear measurements. Finally, utilizing ear measurements, binary logistic regression analyses were used to create a sex estimation model. Two different models were created for this aim using both physical variables (age, weight, and height) and only ear measurements.

Drawing on the study of Krishan et al. (2019), auricles were categorized according to four morphological features: Darwin's tubercle, helix forms, ear lobe forms, and ear lobe attachments. Frequency analysis was used to determine the presence of their subgroups. To define the cut-off points between the sexes, the true positivity (sensitivity) and false positivity (1-specificity) rates for each ear measurement were determined using receiver operating characteristic (ROC) curve analysis. The power of ear measurements to determine sex was evaluated using binary logistic regression analysis.

In the morphometric measurements of anthropometric points and the distances between them, the research "Sezgin & Ersoy (2020)" and "Zulkifli et al. (2014)" were used.

The following anthropometric points were performed for the study (Fig. 1):

- Otobasion superior (Obs)
- Otobasion inferior (Obi)
- Superaurale (Sa)
- Subaurale (Sba)
- Preaurale (Pra)
- Postaurale (Pa)
- Intertragic notch (Intno)
- Lobule anterior (LA)
- Lobule posterior (LP)
- Tragus (T)
- Posterior cavum concha (PC)
- Superior cavum concha (SCC)

The following distances were obtained using the anthropometric points mentioned above (Fig. 2):

- Obs-Obi
- Sa-Sba
- Pra-Pa
- Intno-Sba
- LA-LP
- T-PC
- Intno-SCC

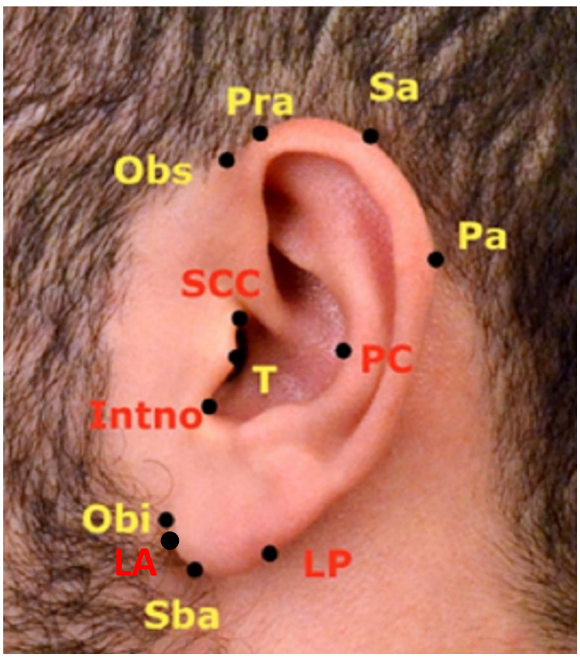

Fig. 1 Anthropometric points [Superaurale (Sa), Postaurale (Pa), Lobule anterior (LA), Lobule posterior (LP), Subaurale (Sba), Otobasion inferior (Obi), Intertragic notch (Intno), Tragus (T), Superior cavum concha (SCC), Otobasion superior (Obs), Preaurale (Pra), Posterior cavum concha (PC)]

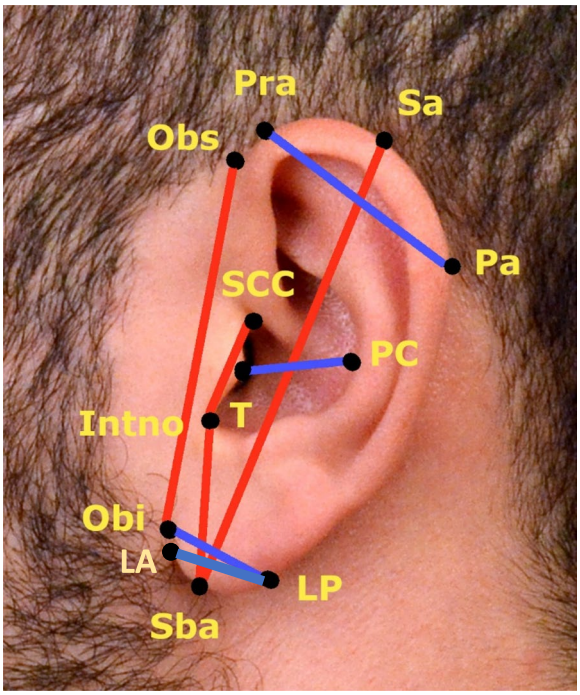

Fig. 2 Measurements (Obs-Obi, SCC-Intno, Intno-Sba, Sa-Sba, Pra-Pa, T-PC, LA-LP)

By comparing the 7 measurements and 4 morphological features—Darwin's tubercle (Fig. 3), helix form (Fig. 4), shape of the ear lobe (Fig. 5), and attachment of the ear lobe (Fig. 6)—sex classification was determined.

Results

The study involved 350 participants, including 195 males and 155 females. The participants' age rate is 43.87.

Table 1 shows the distribution of subcategories by sex in terms of morphological features. As a result, in terms of helix forms, the wide-covering scapha morphology is more prevalent in females while the concave marginal is more prevalent in males. Also, the arched lobe form is seen at a higher rate in males.

In terms of the participants' ages, there is no significant sex difference. Weight and height measurements differ substantially (Table 2). The average values of ear measurements by sex are shown in Table 2 when variables like weight, height, and age are excluded. All measurements, apart from the distance between the tragus and the posterior cavum concha, show a substantial difference between the sexes.

The measurements were submitted to ROC curve analysis, and the cut-off points were established. Again, without considering age, weight, or height factors, the cut-off points for the Otobasion superior-Otobasion inferior and Superaurale-Subaurale measurements resulted in the highest values of sensitivity and specificity (Table 3). The interpretation that values above the cut-off points for these measurements indicate being male is shown in Table 3 along with its true positivity (sensitivity) and false positivity (1-specificity) rates.

The ability of each measurable independent variable to predict sex was examined using Binary Logistic Regression. Without any variables (model 0), the rate of predicting sex was 55%; however, when ear measurements, age, weight, and height variables were added to the model, the rate of predicting sex increased to 88% (model 1). Thus, 132 of 155 females and 176 of 195 males fall within the parameters of the model.

At this point in the study, binary logistic regression was performed with only ear measurements included for individuals whose weight, height, and age could not

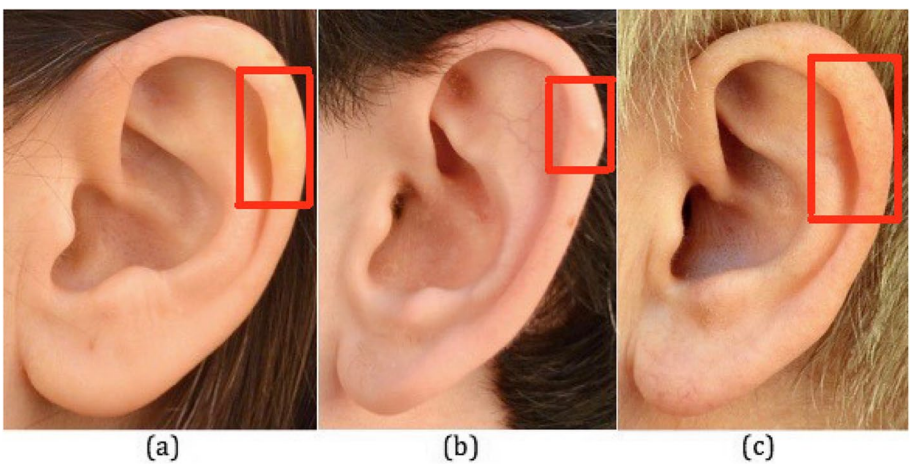

Fig. 3 Darwin's tubercle [nodosity (**a**), projection (**b**), enlargement (**c**)]

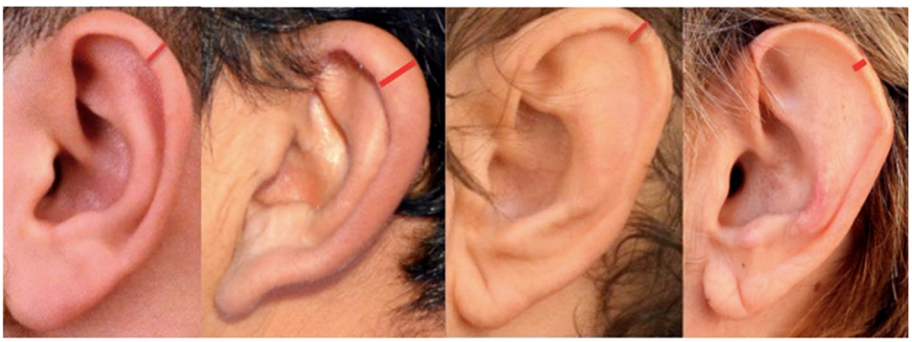

Fig. 4 Helix forms [normally rolled (**a**), wide covering scapha (**b**), concave marginal (**c**), flat (**d**)]

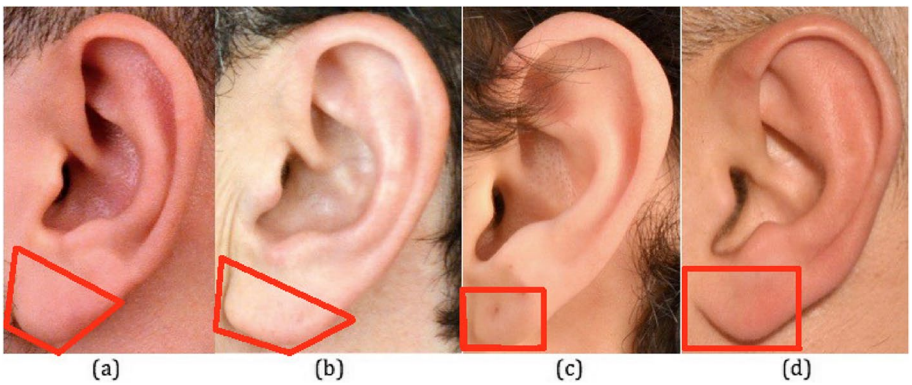

Fig. 5 Ear lobe forms [tongue (**a**), square (**b**), arched (**c**), triangular (**d**)]

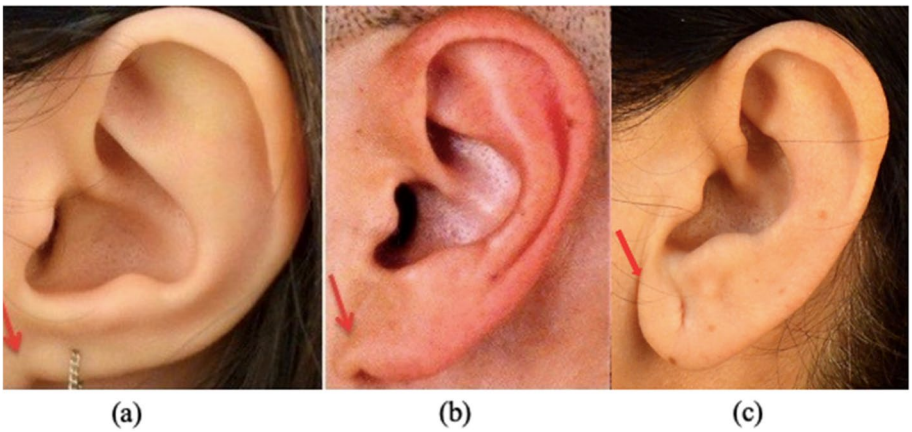

Fig. 6 Ear lobe attachments [attached (**a**), partially attached (**b**), free (**c**)]

be determined. The rate of estimating sex in the obtained model (model 2) was determined to be 68%. This model was able to contain 147 of 195 males and 91 of 155 females. Table 4 shows the test assumptions for both models. As a result, both models had better accuracy than model 0 (likelihood chi-square 0.005), and model 1 had higher pseudo-R2 (Cox and Snell and Nagelkerke) values than model 2. The Hosmer–Lemeshow tests showed all models to have acceptable model compatibility ($p > 0.05$).

Table 1 Distribution of subcategories by sex in terms of morphological features (*$p < 0.05$)

	Male	Female	Total	Chi-square (*p*)
Darwin's tubercle				
Absent	151	112	263	2.173 (0.537)
Enlargement	18	22	40	
Nodosity	16	13	29	
Projection	10	8	18	
Helix forms				
Normally rolled	144	116	260	14.868* (0.002)
Wide covering scapha	9	22	31	
Flat	7	2	9	
Concave marginal	35	15	50	
Ear lobe forms				
Tongue	102	94	196	10.243* (0.017)
Triangular	14	10	24	
Arched	51	20	71	
Square	28	31	59	
Ear lobe attachments				
Attached	21	18	39	1.018 (0.601)
Free	116	84	200	
Partially attached	58	53	111	
Total	195	155	350	

Table 2 Age, body size, and ear size averages differ between the sexes

	Female		Male		
	Mean	SD	Mean	SD	Sig
Age	43.90	18.61	43.84	16.26	.974
Weight (kg)	65.22	12.09	81.87	12.44	.000
Height (cm)	161.61	6.32	174.66	7.42	.000
(mm)					
Obs-Obi	65.93	8.00	71.20	7.72	0.000
Sa-Sba	86.10	9.05	92.06	8.87	0.000
Pra-Pa	46.29	5.45	48.92	5.28	0.000
Intno-Sba	28.06	4.66	29.67	5.39	0.003
LA-LP	20.71	4.52	22.05	5.00	0.010
T-PC	22.79	3.19	22.38	3.19	0.230
Intno-SCC	20.03	2.59	21.19	2.78	0.000

When model 1 is used with known age, weight, and height measurements, the significance values of body weight, height, Pra-Pa, and T-PC measurements are less than 0.05, and the wald values are more than 2. It can be observed that aging has no effect on ear morphology. Table 5 shows the relevant model values.

The significant values of the Obs-Obi, Sa-Sba, Intno-Sba, and T-PC measurements are less than 0.05 and the wald values are more than 2 in model 2; Table 6 shows the relevant model values.

Discussion

When fingerprint, face recognition, and other biometric data are unavailable, ear-related information can be used in identification research. Anthropometric data on outer ear measurements and morphology are presented in this study.

In a study on ear morphology, the ear shape was found to be round the most. The oval form in the auricle and the free form in the lobe attachment were the most prominently observed (Neupane et al. 2020). There was no significant relationship between the sexes in a study that examined the prevalence of lobe attachment (Edibamode et al. 2019). Osunwoke et al. (2018) stated in the ear morphology study that the ear shape is generally oval. There was no apparent difference in ear shape between males and females. As a result, it was determined that both sexes had similar ear morphology (Osunwoke et al. 2018). In Singh and Purkait's (2009) study, the ear shape was found to be the most common oval in both sexes, while the helix form was found to be normally rolled. Females were more likely to have a free ear lobe. Although Darwin's tubercle is more common in males, both sexes have the most nodosity type (Singh & Purkait 2009). According to Krishan (2019), ears are unique in terms of shape, size, and various morphological features. The oval shape was noticed frequently in both sexes in that study (Krishan et al. 2019). In a study, the normally rolled helix was found to be the most common type, with an incidence of 80% on the right side and 86% on the left. In the same study, the ear lobe shape was most commonly found to be square, and in the right ear attached lobe, and in the left ear partially attached lobe were common (Sowmya et al. 2023). In a different study, the helix form was found to be a high rate of normally rolled, 73.24% in male and 84.06% in female (Rani et al. 2020). In a study examining morphological variation in North East and North West Indian populations, 35% of the total were free and 65% attached ear lobes were noted in both populations, and oval ear shape was most common in both populations (Verma et al. 2016). There were little sex differences in the general shape of the ears. In both sexes, the helix form was commonly found to be normally rolled, and the ear lobe was arched. In ear lobe attachment, the most common type was attached in both sexes.

One of the physical characteristics of the ear known Darwin's tubercle is an important structure thought to have evolutionary significance (Loh & Cohen 2016). Darwin's tubercle was first classified by Bertillon (1893), who established the characteristics of nodosity, enlargement, projection, and tubercle (Bertillon 1893). Then, the

Table 3 Cut-off points obtained by comparing sex-specific ear measurements

Measurements	Area	Std. error[a]	Asymptotic Sig.[b]	Asymptotic 95% confidence interval		Cut-off points	Sensitivity	1-specificity
				Lower bound	Upper bound			
Obs-Obi	.694	.028	.000	.638	.750	67.880	.662	.361
Sa-Sba	.680	.029	.000	.624	.736	89.04	.646	.355
Pra-Pa	.638	.030	.000	.580	.696	47.060	.605	.400
Intno-Sba	.585	.030	−.007	.525	.644	28.325	.559	.445
LA-LP	.578	.031	.012	.518	.638	21.270	.554	.445
T-PC	.460	.031	.203		.521	22.815	.487	.529
Intno-SCC	.616	.030	.000	.557	.676	20.590	.574	.426

[a] Under the nonparametric assumption

[b] Null hypothesis: true area = 0.5

Table 4 Model performance values (degrees of freedom = 8)

	Model 1	Model 2
Omnibus test (chi-square/*p*)	288.005/0.000	70.098/0.000
Hosmer–Lemeshow (chi-square/*p*)	4.71/0.788	7.127/0.523
−2 Log likelihood	192.616	410.523
Cox and Snell *R* square	0.561	0.181
Nagelkerke *R* square	0.751	0.243

definition of Gürbüz's (2005) five categories—undeveloped, semi-developed, fully-developed, very significant, and multiple—was put out (Gürbüz et al. 2005). Singh and Purkait (2009), on the other hand, proposed a definition using the three categories of nodosity, enlargement, and projection (Singh & Purkait 2009). No consensus has yet been reached on these definitions.

Darwin's tubercle was found to be nodosity in both sexes (Krishan et al. 2019). Rubio et al. (2015) stated that Darwin's tubercle showed neither sexual dimorphism nor a relationship with the age of the individual (Rubio et al. 2015). In a study, Darwin's tubercle nodosity was found in 88.03% of males and 90.58% of females. Partially free ear lobes (53.52% in males and 46.38% in females) were found to be more common in only males than the attached one (38.03% in males and 47.83% in females) (Rani et al. 2020). When the ear morphology data in this study were analyzed, the helix and ear lobe form showed significance between sexes. In females, the helix form was found as the wide covering scapha, and in males, the concave marginal. Males had mostly arched lobes, while females had mostly square lobes. While Darwin's tubercle and lobe attachment were not statistically different, Darwin's tubercle was found to be the most absent in males,

Table 5 Model values formed by age, height and weight (*B*, measurement coefficient; *SE*, standard error; *df*, degrees of freedom; C.I.for EXP(B); *95% CI*, confidence interval)

		B	SE	Wald	df	Sig	Odds rate (B)	95% GA	
								Lower bound	Upper bound
Model 1	Age	.004	0.015	.061	1	.805	1.004	.975	1.03254
	Height (cm)	−.286	0.040	52.221	1	.000*	.751	.695	0.811953
	Weight (kg)	−.051	0.019	7.164	1	.007*	.950	.915	0.986339
	Obs-Obi	−.050	0.034	2.229	1	.135	.951	.890	1.015876
	Sa-Sba	−.047	0.052	.821	1	.365	.954	.861	1.056574
	Pra-Pa	−.148	0.053	7.779	1	.005*	.862	.777	0.95687
	Intno-Sba	−.046	0.070	.434	1	.510	.955	.832	1.095446
	LA-LP	.017	0.058	.083	1	.773	1.017	.907	1.140293
	T-PC	.187	0.075	6.150	1	.013*	1.205	1.040	1.396842
	Intno-SCC	.051	0.091	.310	1	.578	1.052	.880	1.257175
	Constant	61.715	7.373	70.062	1	.000			

* Values that are less than 0.05

Table 6 Model values that just include ear measurements (*B*, measurement coefficient; *SE*, standard error; *df*, degrees of freedom; C.I.for EXP(B); *95% CI*, confidence interval)

		B	SE	Wald	df	Sig	Odds rate (B)	95% GA	
								Lower bound	Upper bound
Model 2	Obs-Obi	−.060	.023	6.870	1	.009*	.942	.900	.985
	Sa-Sba	−.109	.034	10.426	1	.001*	.896	.839	.958
	Pra-Pa	−.058	.034	2.991	1	.084	.943	.883	1.008
	Intno-Sba	.166	.044	14.112	1	.000*	1.181	1.083	1.288
	LA-LP	−.031	.035	.798	1	.372	.970	.906	1.038
	T-PC	.173	.044	15.568	1	.000*	1.189	1.091	1.296
	Intno-SCC	.058	.058	1.016	1	.313	1.060	.946	1.188
	Constant	7.156	1.493	22.971	1	.000	1282.167		

* Values that are less than 0.05

enlargement in females, and lobe attachment was mostly free in males and partially attached in females.

In a study examining the effect of ear measurements on age and sex, a significant effect of sex was observed for all distances (right and left ear length and ear width) and areas on average (when males and females of the same age were examined, all measurements were greater in males) (Sfroza et al. 2009). In Ahmed and Omer's study (2015), these values were significantly higher in males than in females, except for lobe length (P0.001). Due to these results, the study emphasized the existence of sexual dimorphism (Ahmed & Omer 2015). Alexander et al. (2011) analyzed ear measurements by age, sex, and ethnicity and found that Indians had the longest ears, followed by Caucasians and Afro-Caribbeans. Although this relationship occurred in females, it was not significant, but it was substantial in males. Ear width varied with age and sex. The ears of Indian men were found to be larger than those of Caucasian and Afro-Caribbean men, while this association was not significant in women (Alexander et al. 2011). Fakorede et al. (2021), in their study, found that the sexual dimorphism estimation and sex classification accuracy of the measured variables were low (Fakorede et al. 2021).

In a study (2015) conducted on Sudanese, the maximum classification accuracy attained was 70% for the right ear and 68% for the left ear when using direct univariate discriminant analyses. Stepwise analyses, on the other hand, showed a reasonable accuracy of 71% for the right ear and 71.5% for the left ear, respectively; women were better assigned than males. According to the results of this investigation, using all sexual dimorphic variations gave an accuracy of 72% (Ahmed & Omer 2015).

Females' lobe length was shown to be significantly greater than males' in an ear measurement study (Edibamode et al. 2019). According to Brucker et al. (2003), while total ear height was found to be larger in males than females, lobe height and width were found to be almost the same (Brucker et al. 2003). A study showed the existence of sexual dimorphism in outer ear measurements (Shireen & Karadhelkar 2015). In a study conducted on Malaysians, males' total ear length and width were found to be greater than females', while females' ear lobe height was shown to be greater than males'. These variables were all greater in Indian men than in women (Kumar & Selvi 2016). In this study, all measurements except the T-PCC distance showed a significant difference between the sexes.

Ahmed and Omer (2015) developed breakpoints for all measures by using a series of direct univariate discriminant functions (functions 1–10) to determine which single measure was most accurate for sex estimation (Ahmed & Omer 2015). As a result, the study group's classification accuracy was determined to be between 60.5 and 70%. All measured independent variables in this study were subjected to Binary Logistic Regression analysis to determine their ability to estimate sex. Model 1 has an accuracy of 88% for sex estimation when all variables are included, and model 2 has an accuracy of 68% when only ear measurements are included. The difference in success rates between the two models shows that the models' success rate decreases when the individuals' body measurements are unknown. Although the estimation rate is low, model 2 is necessary in situations where only video and photographic images are analyzed, and the individuals' body measurements are unknown.

Conclusions

In conclusion, this study, which analyzed 350 people's facial images, provides significant information for forensic applications. Model 1 has the greatest accuracy rate (88%) among the models created for sex estimation. Sex estimation can be performed as an effective method when the morphological and metric parameters of the ear are analyzed together. The model accuracy rates are expected to improve in future research as the number of samples and variety increase.

Abbreviations

SPSS	Statistical Package for the Social Sciences
Obs	Otobasion superior
Obi	Otobasion inferior
Sa	Superaurale
Sba	Subaurale
Pra	Preaurale
Pa	Postaurale
Intno	Intertragic notch
LA	Lobule anterior
LP	Lobule posterior
T	Tragus
PC	Posterior cavum concha
SCC	Superior cavum concha

Acknowledgements
None.

Authors' contributions
NS: conception, design, sample collection, writing. GE: data analysis, writing, critical review.

Funding
This research did not receive any specific grant from funding agencies in the public, commercial, or not-for-profit sectors.

Declarations

Ethics approval and consent to participate
Istanbul University Cerrahpasa Medical Faculty Deanship Ethics Board of Clinical Research approved the study ethic protocol. This work has been carried out in accordance with the Helsinki Declaration.

Consent for publication
Applicable.

Competing interests
The authors declare that they have no competing interests.

Received: 15 May 2023 Accepted: 18 September 2023
Published online: 04 October 2023

References

Ahmed AA, Omer N (2015) Estimation of sex from the anthropometric ear measurements of a Sudanese population. Leg Med 17:313–319. https://doi.org/10.1016/j.legalmed.2015.03.002

Alabi AS, Adeola A, Kareem SB, Lewu SF, Olawepo A, Arogundade T et al (2019) Anthropometric analysis of auricular indices for sex and stature determination among Okun and Igala ethnic groups of Kogi State, Nigeria. J Environ Tox and Pub Health 4:6–14. https://doi.org/10.5281/zenodo.2561990

Alexander KS, Stott DJ, Sivakumar B, Kang N (2011) A morphometric study of the human ear. J Plast Reconstr Aesthet Surg 64:41–47. https://doi.org/10.1016/j.bjps.2010.04.005

Bertillon A (1893) Identification Anthropometric: Insturctions Signaletiques. Imprimiere administrative, Melun

Boutros F, Damer N, Terhörst P, Kirchbuchner F, Kuijper A (2019) Exploring the channels of multiple color spaces for age and gender estimation from face images. 22nd International Conference on Information Fusion. 2–5 July 2019 doi: https://doi.org/10.23919/FUSION43075.2019.9011383

Brucker MJ, Patel J, Sullivan PK (2003) A morphometric study of the external ear: age and sex related differences. Plas Recons Surg 112(2):647–652. https://doi.org/10.1097/01.PRS.0000070979.20679.1F

Cameriere R, DeAngelis D (2011) Ear identification: a pilot study. J for Sci 56(4):1010–1014. https://doi.org/10.1111/j.1556-4029.2011.01778.x

Edibamode EI, Mordi K, David LK, Eghoi AM (2019) Anthropometry of the external ear among adult Ijaws in Bayelsa State of Nigeria. Int J Med Medical Res 5(1):75–83. https://doi.org/10.11603/ijmmr.2413-6077.2019.1.9897

Fakorede ST, Adekoya KO, Fasakin TP, Odufisan JO, Oboh B (2021) Ear morpholojy and morphometry as potential forensic tools for identification of the Hausa, Igbo and Yoruba population of Nigeria. Bulletin of the National Research Centre 45(205):1–19. https://doi.org/10.1186/s42269-021-00665-0

Gürbüz H, Karaman F, Mesut R (2005) The variations of auricular tubercle in Turkish people. Acta Morphologica Et Anthropologica 10:150–156

Hoogstrate AJ, Van Den Heuvel H, Huyben E (2001) Ear identification based on surveillance camera images. Sci Justice 3(41):167–172. https://doi.org/10.1016/S1355-0306(01)71885-0

Kaur KD, Rai P, Khanna P (2017) Gender classification system for half face images using multi manifold discriminant analysis. 7th International Conference on Cloud Computing, Data Science & Engineering - Confluence. 12–13 January 2017 doi: https://doi.org/10.1109/CONFLUENCE.2017.7943221

Krishan K, Kanchan T, Thakur S (2019) A study of morphological variations of the human ear for its applications in personal identification. Egyp J for Sci 9(6):1–11. https://doi.org/10.1186/s41935-019-0111

Kumar BS, Selvi GP (2016) Morphometry of ear pinna in sex determination. Int J Anat Res 4(2):2480–2484. https://doi.org/10.16965/ijar.2016.244

Loh TY, Cohen PR (2016) Darwin's tubercle: Review of a unique congenital anomaly. Dermatology and Therapy 6(2):43–149. https://doi.org/10.1007/s13555-016-0109-6

Neupane B, Iyer K, Bhattarai C, Sigdel B (2020) External ear features: Role in tracing inheritance. Journal of College of Medical Sciences-Nepal 16(4):201–207. https://doi.org/10.3126/jcmsn.v16i4.33279

Osunwoke EA, Vidona WB, Atulegwu GC (2018) Anthropometric study on the anatomical variation of the external ear amongst Port Harcourt students. Nigeria Int J Anat Var 11(4):144–147

Rani D, Krishan K, Sahani R, Baryah N, Kanchan T (2020) Evaluation of morphological characteristics of the human ear in young adults. J Cranio Surg 31(6):1692–1698. https://doi.org/10.1097/SCS.0000000000006394

Rubio O, Galera V, Alonso M (2015) Anthropological study of ear tubercles in a Spanish sample. Homo 66(4):343–356. https://doi.org/10.1016/j.jchb.2015.02.005

Sezgin N (2017) Digitally metric examining of age related changes in human face, 2017 [PhD Thesis]. İstanbul University-Cerrahpaşa, İstanbul

Sezgin N, Ersoy G (2020) Age-related metric changes in ear size and position. The Bulletin of Legal Medicine 25(2):106–115. https://doi.org/10.17986/blm.1273

Sfroza C, Grandi G, Binelli M, Tommasi DG, Rosati R, Ferrario VF (2009) Age- and sex-related changes in the normal human ear. For Sci Int 187:110.e1–110.e7. https://doi.org/10.1016/j.forsciint.2009.02.019

Shireen S, Karadhelkar VP (2015) Anthropometric measurements of human external ear. J Evol Med Dent Sci 4(59):10333–10338. https://doi.org/10.14260/jemds/2015/1489

Singh P, Purkait R (2009) Observations of external ear-an Indian study. Homo 60(5):461–472. https://doi.org/10.1016/j.jchb.2009.08.002

Sowmya MV, Mehrotra D, Mohammad S, Singh RK, Tiwari AK, Katrolia R, Yogesh SS (2023) 3D assessment of ear morphology. J Oral Bio Cranio Res 13(5):622–629. https://doi.org/10.1016/j.jobcr.2023.08.001

Terhörst P, Huber M, Kolf JN, Damer N, Kirchbuchner F, Kuijper A (2019) Multi-algorithmic fusion for reliable age and gender estimation from face images. 22nd International Conference on Information Fusion. 2–5 July 2019 doi: https://doi.org/10.23919/FUSION43075.2019.9011294

Ugochukwu EG, Ifechukwude BJ, Raymond UA, Obun OC (2017) An anthropometric study of the normal auricle of Cross River State indigenes of Nigeria. Journal of the Anatomical Society of India 66(1):26–30. https://doi.org/10.1016/j.jasi.2017.04.002

Verma P, Sandhu HK, Verma KG, Goyal S, Sudan M, Ladgotra A (2016) Morphological variations and biometrics of ear: an aid to personal identification. J Clin Diagn Res 10(5):ZC138–ZC142. https://doi.org/10.7860/JCDR/2016/18265.7876

Yaman D, Eyiokur Fİ, Ekenel HK (2021) Multimodal soft biometrics: combining ear and face biometrics for age and gender classification. Multimedia Tools and Applications 22695–22713. https://doi.org/10.1007/s11042-021-10630-8

Zulkifli N, Yusof FZ, Rashid RA (2014) Anthropometric comparison of cross-sectional external ear between monozygotic twin. Ann of for Res Anal 1(2):1–6

Publisher's Note

Springer Nature remains neutral with regard to jurisdictional claims in published maps and institutional affiliations.

Submit your manuscript to a SpringerOpen journal and benefit from:

► Convenient online submission
► Rigorous peer review
► Open access: articles freely available online
► High visibility within the field
► Retaining the copyright to your article

Submit your next manuscript at ► springeropen.com