CASE REPORT OLGU SUNUMU

DOI: 10.5336/vetsci.2024-103834

True Hermaphroditism in a Young Dog

Genç Bir Köpekte Gerçek Hermafroditizm

Ruken YAŞAR[a], Bahar GEZER GÜNEŞ[a], Zeynep Günay UÇMAK[b], İsmail KIRŞAN[b], Funda YILDIRIM[c], Sinem Yaren GÜZELBAKAN[a], Hazal ÖZTÜRK GÜRGEN[c]

[a]İstanbul University-Cerrahpaşa, Institute of Graduate Education, Department of Obstetrics and Gynecology, Doctoral Program, İstanbul, Türkiye
[b]İstanbul University-Cerrahpaşa, Faculty of Veterinary Medicine, Department of Obstetrics and Gynecology, İstanbul, Türkiye
[c]İstanbul University-Cerrahpaşa, Faculty of Veterinary Medicine, Department of Pathology, İstanbul, Türkiye

ABSTRACT Intersexualism occurs in all mammalian species, and the pathogenesis of abnormal development of the gonads is still unclear. In this case report, the clinical and histopathological findings of a case of bilateral true hermaphroditism in a young dog are described. A 9-month-old Maltese X Shih Tzu hybrid dog was brought to our clinic with the complaint of a mass protruding from between the vulva lips. Blood was taken to determine the animal's general health status and steroid hormone levels. Serum estradiol was measured as <5 pg/mL, progesterone <0.2 ng/mL, testosterone <20 ng/dL. The C-reactive protein (CRP) level in the blood was found to be 1.4 mg/L. It was decided to perform hysterectomy and penis amputation for treatment purposes by obtaining written informed consent from the patient's owner. In conclusion, it was seen that cases of intersexuality in dogs can be detected by a detailed clinical and histopathological examination and treated with surgical intervention.

Keywords: Dog; hormones; intersexuality; true hermaphroditism; ovotestis

ÖZET İnterseksüalizm, tüm memeli türlerinde görülür ve gonadların anormal gelişiminin patogenezi hâlâ belirsizdir. Bu olgu sunumunda, genç bir köpekte bilateral gerçek hermafroditizm olgusunun klinik ve histopatolojik bulguları anlatılmaktadır. Dokuz aylık bir Malta X Shih Tzu melezi köpek, vulva dudaklarının arasından çıkıntı yapan bir kitle şikâyetiyle kliniğimize getirildi. Hayvanın genel sağlık durumunu ve steroid hormon seviyelerini belirlemek için kan alındı. Serum östradiol <5 pg/mL, progesteron <0,2 ng/mL, testosteron <20 ng/dL olarak ölçüldü. Kandaki C-reaktif protein (CRP) seviyesi 1,4 mg/L olarak bulundu. Tedavi amaçlı hasta sahibinden onam formu alınarak, histerektomi ve penis ampütasyonu yapılmasına karar verildi. Sonuç olarak köpeklerde interseksüalite olgularının detaylı klinik ve histopatolojik inceleme ile tespit edilebileceği ve cerrahi müdahale ile tedavi edilebileceği görülmüştür.

Anahtar Kelimeler: Köpek; hormonlar; interseksüalite; gerçek hermafroditizm; ovotestis

A "hermaphrodite" is an animal possessing sexual organs of both sexes. Male pseudohermaphrodites have testicular tissue and female genital organs, while female pseudohermaphrodites have male genital organs and ovarian tissue. True hermaphrodites contain gonadal tissues of both sexes.[1] Certain breeds show a predisposition to specific birth defects, suggesting a genetic basis.[2] In dog breeding, identifying breeds prone to genital system malformations is crucial.[3] Therefore, clinical, pathological, and cytogenetic evaluations are necessary to identify intersex cases in small animal practice. This case report discusses the clinical and histopathological findings of bilateral true hermaphroditism in a young dog.

TO CITE THIS ARTICLE:
Yaşar R, Gezer Güneş B, Uçmak ZG, Kırşan İ, Yıldırım F, Güzelbakan SY, et al. True hermaphroditism in a young dog. Turkiye Klinikleri J Vet Sci. 2026;17(1):74-8.

Correspondence: Ruken YAŞAR
İstanbul University-Cerrahpaşa, Institute of Graduate Education, Department of Obstetrics and Gynecology, Doctoral Program, İstanbul, Türkiye
E-mail: ruken_yashar_145@hotmail.com

Peer review under responsibility of Turkiye Klinikleri Journal of Veterinary Sciences.

Received: 01 Aug 2024 ***Received in revised form:*** 27 Dec 2024 ***Accepted:*** 27 Dec 2024 ***Available online:*** 21 Aug 2025

2146-8850 / Copyright © 2026 by Türkiye Klinikleri. This is an open access article under the CC BY-NC-ND license (http://creativecommons.org/licenses/by-nc-nd/4.0/).

CASE REPORT

A 9-month-old Maltese X Shih Tzu crossbreed dog weighing 5.9 kg was brought to İstanbul University-Cerrahpaşa, Faculty of Veterinary Medicine, Department of Obstetrics and Gynecology clinic with a complaint of a mass protruding from the vulva. Vaginal examination revealed a swollen, red-pink colored penis-like structure protruding from between the vulva lips (Figure 1). This penis-like protrusion was partially covered by the preputial fold. However, the testicles were not felt in the area between the inguinal ring and the underdeveloped scrotum.

A catheter was inserted through the orificium urethra externa to determine whether the urinary tract was functioning physiologically. Radio-opaque material was injected into the urethra and digital radiography (DR, Ekovia, Korea) was taken. In the ultrasonographic examination (Esaote MyLab One Vet, Esaote Pie Medical, Genova, Italy), testicle-like structures behind the kidneys and the uterus were visualized. Surgical intervention was decided as a treatment. Total blood count and biochemical parameters which were evaluated to avoid the anesthesia risks, were within reference ranges. The serum estradiol (E2), testosterone (Roche Cobas E601, China), and progesterone (P4) (Siemens Immulite 2000, Germany) were evaluated and serum steroid hormone results were presented in Table 1.

Infusion was started with Ringer's lactate at a rate of 7 mL/kg/hour (Mediflex, Koçak Farma, Türkiye). For premedication, atropine sulfate was used subcutaneously at a dose of 0.04 mg/kg (Atropine 0.2%, Vetaş, Türkiye). For induction, 6 mg/kg propofol was administered intravenously. The patient was intubated with a number 4 intubation tube. General anesthesia was provided with isoflurane (Isoflurane USP, Piramal Critical Care, USA) at a dose of 2.5% and oxygen at a dose of 0.5-1%. The vulvar lips were suspended from the dorsal part using absorbable surgical suture 2/0 (Monocryl, Medeks, Türkiye). Os clitoridis was excised and removed with the help of electrocautery (Zeus-400, 220V 50Hz, Korea). Vulvoplasty was applied to the excision area. During the operative procedure in the perivaginal area, absorbable suture material was used (Monocryl2/0, Medeks, Türkiye) (Figure 2).

TABLE 1: Serum steroid hormone results

Parameter	Conclusion	Unit	Reference
E2	<5.00	pg/mL	27-70: Proestrus 10-90: Estrus <25: Metestrus <40: Anestrus 10-40: Pregnant <15: Neuter
P4	<0.20	ng/mL	<1.0: Proestrus <30.0: Estrus 5.5-12.0: Anestrus
Testosterone	<20.0	ng/dL	0-15

E2: Estradiol; P4: Progesterone

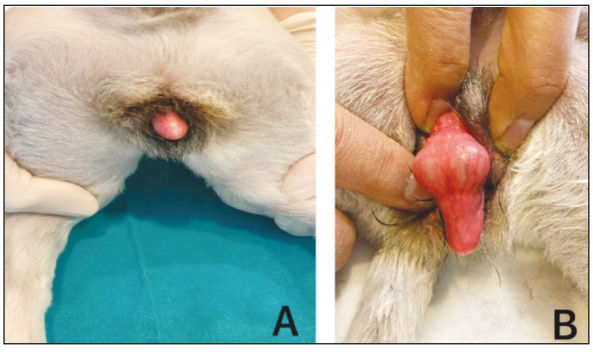

FIGURE 1: Images from vaginal examination; **A)** Enlarged vulva with an os clitoridis and a large penis-like "clitoris" with a urethral opening at its tip; **B)** Os clitoridis with retracted vulva lips resembling a penis

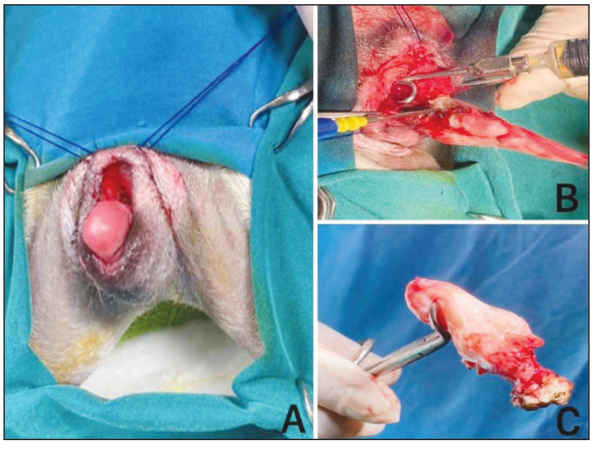

FIGURE 2: Images from surgical intervention; **A)** Vulva lips and os clitoridis; **B)** Os clitoridis excised with the assistance of electrocautery; **C)** Excision of the clitoris

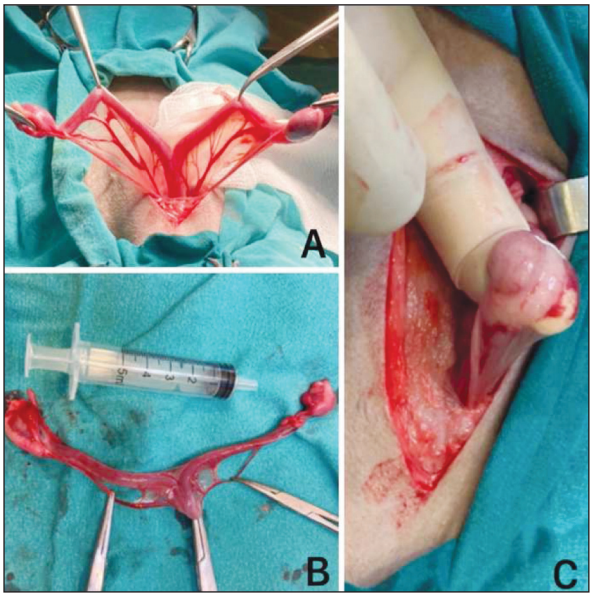

FIGURE 3: Images from laparotomy section; **A)** Cervix, cornu and corpus uteri suspended with hemostatic forceps; **B)** Dimensions of cervix, cornu and corpus uterus; **C)** A testis together with an epididymis on the cranial edge of the cornu uteri

For laparotomy, the dog was placed in the ventrodorsal position. The testicle-like structures located where the ovaries should be, the corpus and cornu uteri were removed (Figure 3). All sutures were made by using 2/0 absorbable suture material (Monocryl, Medeks, Türkiye).

After surgery, the antibiotic amoxicillin+ clavulanic acid (Synulox, HauptPharma, Italy) was administered sc at a dose of 8.75 mg/kg for 7 days. The meloxicam was given subcutaneously for 3 days at 0.2 mg/kg (Meloxicam, Bavet, Türkiye). All sutures were removed at postoperative 10th day and the dog's health condition was good (Figure 4).

The enlarged clitoris, uterus, and gonads were sent to the pathology department for histopathological evaluation. Tissue samples were fixed in 10% buffered formalin, processed, and embedded in paraffin. Sections 3-4 µm thick were prepared with a rotary microtome, stained with hematoxylin-eosin and evaluated microscopically. In macroscopic examination, testicles and epididymis were noted at the cranial edge of the cervix, corpus, and cornu uteri. Histopathological examination revealed an enlarged clitoris containing ossified tissue resembling an os penis. The penis-like structure was surrounded by squamous epithelium and composed of collagenous fibrous tissue (Figure 5A), along with extensive vascular and cavernous structures (Figure 5B). Bone tissue was identified in the medial part of the mass (Figure 5C) and showed hematopoiesis (Figure 5D). The cornu, corpus uteri, and testes were microscopically confirmed, with diffuse bleeding observed in the cornu uteri section

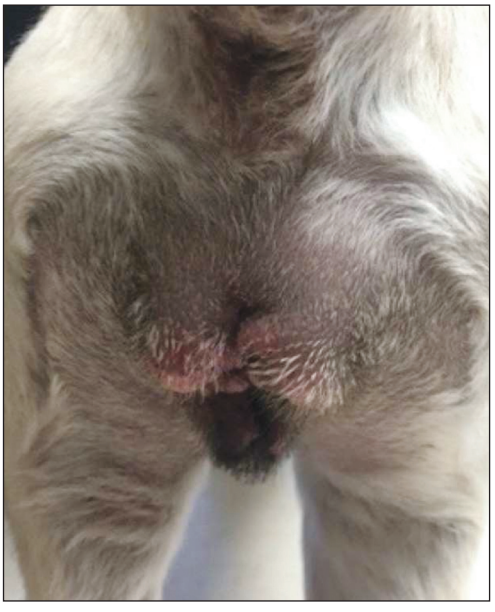

FIGURE 4: Final appearance of the vulva lips after the sutures are removed

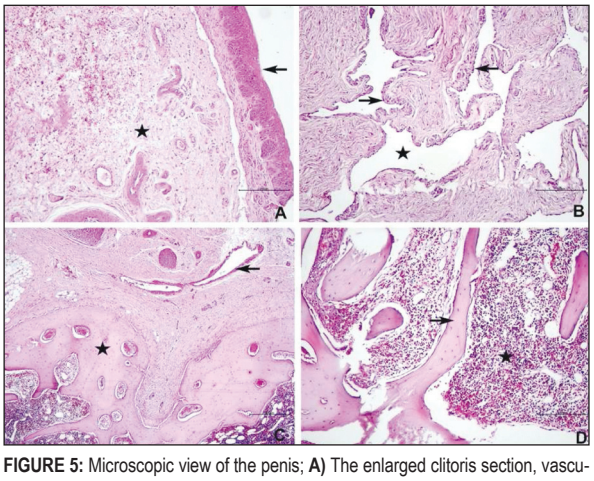

FIGURE 5: Microscopic view of the penis; **A)** The enlarged clitoris section, vascular and slightly edematous fibrous tissue (star) surrounding by squamous epithelium (arrow); **B)** Cavernous structures (star) lining by endothelium (arrow); **C)** Osseous tissue (star) detected in the middle of the enlarged clitoris, enlarged vascular structures (arrow); **D)** Bone marrow production, bone spicules (arrow) and hemopoietic cells (star); H&E staining, Figure A, B, and D: Bar=200 µm Figure C: Bar=400 µm H&E: Hematoxylin-eosin

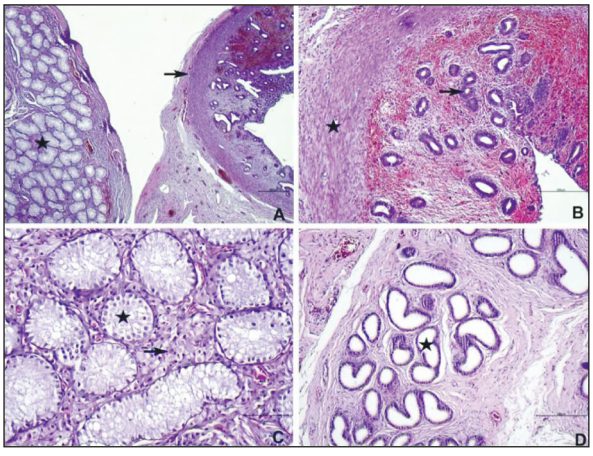

FIGURE 6: Microscopic view of the internal genital organs; **A)** Testes (star) and cornu uteri (arrow) tissue sections, H&E staining, Bar=300 µm; **B)** The uterine glands (arrow) in a hemorrhagic mucosa and the muscle layer (arrow), H&E staining, 200 µm; **C)** Inactive seminiferous tubules (star) and Leydig cells (arrow) among the tubules (star), H&E staining, 90 µm; **D)** Epididymal ducts (star), H&E staining, 200 µm
H&E: Hematoxylin-eosin

(Figure 6A, B). In the testicles and epididymis, abundant seminiferous tubules were present, characterized by weak lumen formation, prominent Sertoli cells, and the absence of spermatocytes in the area where the ovary should be. A few interstitial Leydig cells were also observed between the seminiferous tubules (Figure 6C, D).

Informed Consent: Written informed consent was obtained from the patient's owner for the publication of this case report and any accompanying clinical data and images for academic purposes.

DISCUSSION

To confirm a diagnosis, it is essential first to classify intersexuality and then to identify both the gonadal sex and the chromosomal sex of the individual in question.[4] The presence and expression of the Sex Determining Region Y (*SRY*) gene can be a crucial factor in leading to the formation of an ovotestis. Consequently, diagnosing the ovotestis may also be necessary, which can be accomplished through polymerase chain reaction (PCR) analysis of the gonadal tissue.[5] Unfortunately, within the parameters of this particular study, we faced limitations that prevented us from performing karyotyping and PCR analyses. The limited testing hampered our assessment of congenital diseases and the role of sex chromosome anomalies or specific gene disorders in the observed true hermaphroditism, despite the dog's female-like external genitalia and body structure. Notably, the clitoris was considerably larger than what is typically considered normal and exhibited a structure resembling that of a penis. Additionally, during the histopathological assessment that took place after an ovariohysterectomy, testicular tissue was discovered residing in the location where ovaries are generally expected to develop. The identification of uterine structures confirmed true hermaphroditism. The dog exhibited symptoms such as frequent vaginal licking, restlessness, and a reddened clitoris, indicating potential discomfort. In terms of hormone levels, healthy male dogs typically have reported testosterone levels ranging from 0.01 to 41.5 ng/mL, alongside E2 and P4 levels measured at 33.6 to 66.6 pg/mL and 0.02 to 0.5 ng/mL, respectively. On the other hand, in healthy female dogs, hormone level ranges have been documented as 0.01 to 0.3 ng/mL for testosterone, 31.5 to 69.0 pg/mL for E2, and 0.01 to 0.65 ng/mL for P4.[6] Notably, our search for existing literature concerning steroid levels in true hermaphroditic dogs yielded no relevant findings. However, Alam et al. did report cases of hyperestrogenism coupled with low testosterone levels in male pseudohermaphroditic dogs.[1] In this specific case we are discussing, the serum levels of testosterone, E2, and P4 were observed to be significantly lower than the established reference values, underscoring the hormonal discrepancies present in the condition. Therefore, it was concluded that the dog was not sexually active. Abnormal sex chromosomes, exposure to exogenous hormones or chemicals that cause virilism during pregnancy, genetic mutations occurring in the fetus, and severe traumas experienced during pregnancy contribute to the etiology of hermaphroditism, which is a congenital anomaly.[7] However, in most cases, the factor causing hermaphroditism could not be determined, and they were defined as cases of spontaneous hermaphroditism due to genetic disorder.[1,8,9] Since the anomaly was not noticed by dog owners before, the cause of hermaphroditism could not be determined exactly. True hermaphroditism in dogs might be overlooked by owners and can be discovered during routine

exams or surgeries. Breeding dogs should be closely checked for congenital issues like hermaphroditism that can lead to infertility. In conclusion, it was seen that cases of intersexuality in dogs can be detected by a detailed clinical and histopathological examination and treated with surgical intervention.

Source of Finance

During this study, no financial or spiritual support was received neither from any pharmaceutical company that has a direct connection with the research subject, nor from a company that provides or produces medical instruments and materials which may negatively affect the evaluation process of this study.

Conflict of Interest

No conflicts of interest between the authors and / or family members of the scientific and medical committee members or members of the potential conflicts of interest, counseling, expertise, working conditions, share holding and similar situations in any firm.

Authorship Contributions

Idea/Concept: *Ruken Yaşar, İsmail Kırşan;* ***Design:*** *Bahar Gezer Güneş, Zeynep Günay Uçmak;* ***Control/Supervision:*** *İsmail Kırşan, Zeynep Günay Uçmak;* ***Data Collection and/or Processing:*** *Ruken Yaşar, Sinem Yaren Güzelbakan;* ***Analysis and/or Interpretation:*** *Funda Yıldırım, Hazal Öztürk Gürgen;* ***Literature Review:*** *Ruken Yaşar, Bahar Gezer Güneş;* ***Writing the Article:*** *Ruken Yaşar,* ***Critical Review:*** *İsmail Kırşan, Zeynep Günay Uçmak;* ***References and Fundings:*** *Bahar Gezer Güneş, Ruken Yaşar;* ***Materials:*** *Hazal Öztürk Gürgen, Funda Yıldırım.*

REFERENCES

1. Alam MR, Cho YG, Cho SJ, Lee JI, Lee HB, Tae HJ, et al. Male pseudohermaphroditism in dogs: three case reports. Vet Med. 2007;52(2):74-8. [Link]
2. Basrur PK. Disrupted sex differentiation and feminization of man and domestic animals. Environ Res. 2006;100(1):18-38. [Crossref] [PubMed]
3. Frank LA, Rohrbach BW, Bailey EM, West JR, Oliver JW. Steroid hormone concentration profiles in healthy intact and neutered dogs before and after cosyntropin administration. Domest Anim Endocrinol. 2003;24(1):43-57. [Crossref] [PubMed]
4. Hare WC. Intersexuality in the dog. Can Vet J. 1976;17(1):7-15. [PubMed] [PMC]
5. Kobayashi K, Fujiwara T, Adachi T, Asahina M, Sasaki Y, Matsuda A, et al. Bilateral ovotestes in a female beagle dog. J Toxicol Pathol. 2007;20(2):111-5. [Link]
6. Kuiper H, Bunck C, Günzel-Apel AR, Drögemüller C, Hewicker-Trautwein M, Distl O. SRY-negative XX sex reversal in a Jack Russell Terrier: a case report. Vet J. 2005;169(1):116-7. [Crossref] [PubMed]
7. Pasello-Legrand F, Mowat V. Two cases of spontaneous pseudohermaphroditism in Cynomolgus monkeys (Macaca fascicularis). J Vet Med A Physiol Pathol Clin Med. 2004;51(7-8):344-7. [Crossref] [PubMed]
8. Silversides DW, Benoit JM, Collard F, Gilson C. Disorder of sex development (XX male, SRY negative) in a French bulldog. Can Vet J. 2011;52(6):670-2. [PubMed] [PMC]
9. Poth T, Breuer W, Walter B, Hecht W, Hermanns W. Disorders of sex development in the dog-Adoption of a new nomenclature and reclassification of reported cases. Anim Reprod Sci. 2010;121(3-4):197-207. [Crossref] [PubMed]