*Praca oryginalna* *Original paper*

# Radiographic evaluation of cardiac size in the white stork (*Ciconia ciconia*)

EBUDERDA GÜNAY[1], OZAN GÜNDEMIR[2], YUSUF ALTUNDAĞ[3], TUĞBA KURT[4], SOKOL DURO[5], BERNARD TUREK[6], TOMASZ SZARA[7]

[1]Department of Wild Animal Diseases and Ecology, Faculty of Veterinary Medicine, Istanbul University-Cerrahpasa, Istanbul, Turkey
[2]Department of Anatomy, Faculty of Veterinary Medicine, Istanbul University-Cerrahpasa, Istanbul, Turkey
[3]Department of Surgery, Faculty of Veterinary Medicine, Istanbul University-Cerrahpasa, Istanbul, Turkey
[4]Esenyurt Municipality, Modern Animal Shelter and Rehabilitation Center, Istanbul, Turkey
[5]Faculty of Veterinary Medicine, Agricultural University of Tirana, 1029 Tirana, Albania
[6]Department of Large Animal Diseases, Institute of Veterinary Medicine, Warsaw University of Life Sciences (SGGW), Warsaw, Poland
[7]Department of Morphological Sciences, Institute of Veterinary Medicine, Warsaw University of Life Sciences (SGGW), Warsaw, Poland

*Received 02.02.2022* *Accepted 12.03.2022*

Günay E., Gündemir O., Altundağ Y., Kurt T., Duro S., Turek B., Szara T.
**Radiographic evaluation of cardiac size in the white stork (*Ciconia ciconia*)**

Summary

**Physical examination of the cardiovascular system in birds is quite difficult compared to other animals. As in humans and mammalian animals, radiography is a reliable diagnostic tool to identify cardiovascular disorders in birds. However, cardiovascular radiography studies for birds are very limited and reference information is lacking. In this study the aim was to determine the reference values of cardiac radiographic measurements that can be used especially in the diagnosis of cardiomegaly in storks, which is a free-living bird species. For this purpose, 26 white storks without cardiovascular disorders were used in the study. Radiographs were taken in lateral and ventrodorsal projections. Five measurements: heart length (61.70 ± 6.69 mm), heart width (51.65 ± 4.84), carina length (139.80 ± 10.05), thoracic width (87.45 ± 6.58), and coracoid width (10.24 ± 1.20) were performed. The ratio of the heart width to thoracic width was 59.16%. The ratio of heart length to carina length was 44.28%. Heart width correlates significantly and positively with the thoracic width (R: 0.556, R2: 0.310, P: 0.003). The heart width can be estimated by using the thoracic width values with the regression-based formula in the results of this study. Clinically, it can be determined whether an individual case falls between the minimum or maximum reference values for heart width or length. The results presented in this study may provide clinicians with reference information regarding cardiomegaly.**

**Keywords: radiographic imaging, cardiac, heart, heart size, heart width**

The white stork (*Ciconia ciconia* Linnaeus, 1758), lives in aquatic and terrestrial ecosystems (23). Storks, migratory birds, nesting among other places in Central Europe and wintering in Central Africa up to South Africa. Considered a herald of spring, it often appears in literature and art as a symbol of Poland (7). The white storks are summer visitors and passage migrants in Turkey (9). During their migration between the African-European continents, they use Turkey as a gateway (10). Storks can live in open areas, large plains, forests, and reeds (11).

The bird's heart is proportionally larger than in mammals concerning body mass (13). The heart of winged vertebrates may also vary according to their physiological needs. The barnacle goose for example has an increased pre-migration heart size (21). The heart rate in birds is also variable. It may vary according to its activity or physiology (13). Although cardiovascular disease is known to be common in birds, free-living birds such as the stork are rarely diagnosed with heart failure (3). This is because the cardiac examination is more difficult in birds than in other animals. In addition, physical examination can be difficult to interpret (18). It has been reported that radiography is a reliable diagnostic tool to identify cardiomegaly in birds (8). For this purpose, researchers have focused on the reference ranges for the heart width, the measurement used in humans and domestic animals (dogs and cats) (4, 5, 19). In subsequent studies, these reference values were obtained for many bird species (6, 12, 15, 16, 20).

Physical examination of the cardiovascular system in poultry is rather limited and rarely performed in veterinary practice compared to that of dogs and cats. Research in this area, especially in free-living birds, is not as common as in domestic animals. This study aims to provide the reference values of cardiac radiographic measurements to be used in the diagnosis of cardiomegaly in storks.

## Material and methods

**Animals.** 26 white storks with bodyweight between 2.05-3.5 kg admitted to the Clinic in Wild Animal Diseases and Ecology Department Istanbul University-Cerrahpasa due to orthopedic problems during the migration were used in the study. Cases were collected from December 2018 to September 2021. The radiographs used in the study were taken during the routine clinical examination of these animals. No signs of cardiac problems were observed in the physical examination. The study was approved by the Ethics Committee of Istanbul University-Cerrahpaşa, Faculty of Veterinary Medicine (Decision number: 2021/52).

**Data.** Radiographic images in lateral and ventrodorsal projections were taken using an Ecoray (HF-525 Plus Vet) brand x-ray device. The wings were opened symmetrically and a ventrodorsal view was obtained. The measurements of selected parameters were taken using the Radiant DICOM Viewer (version 2020.2.2). 5 linear dimensions and 3 ratios were used (1). Parameters A and B were performed at the lateral (Fig. 1), and the remaining 3 on the ventrodorsal projection (Fig. 2).

**Statistical analysis.** Means and standard errors of 5 linear measurements and 3 indices were calculated. The relationships between heart width and other measurements were evaluated using linear regression. In each regression model, heart width was considered the dependent variable, and other anatomical measurements were an independent variable. SPSS software package (SPSS for Windows, version 21.0) was used for statistical analysis.

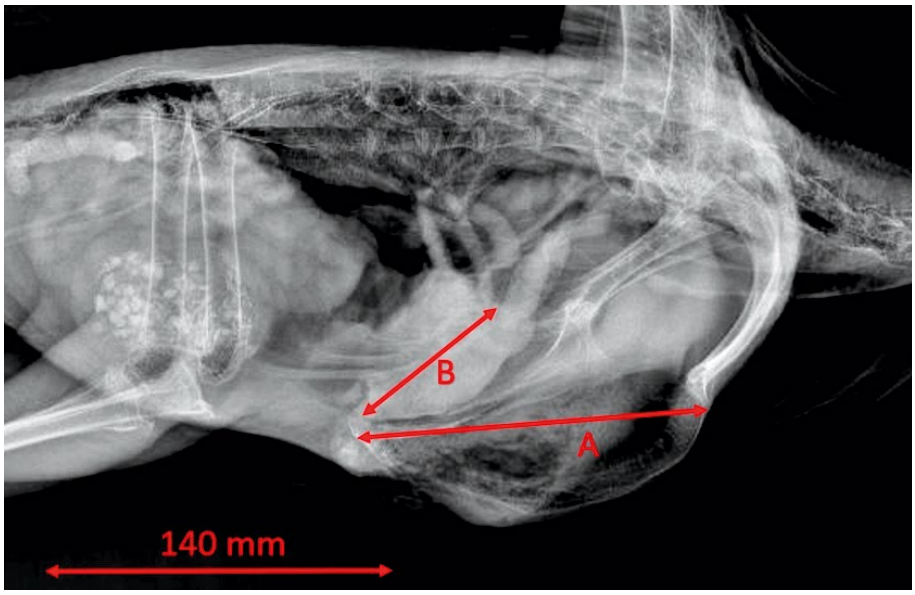


**Fig. 1. Lateral radiographic image of the white stork**
Explanations: A – carina length: distance between the most cranial point to the most caudal point of the carina; B – heart length: distance between the base and the apex of the heart

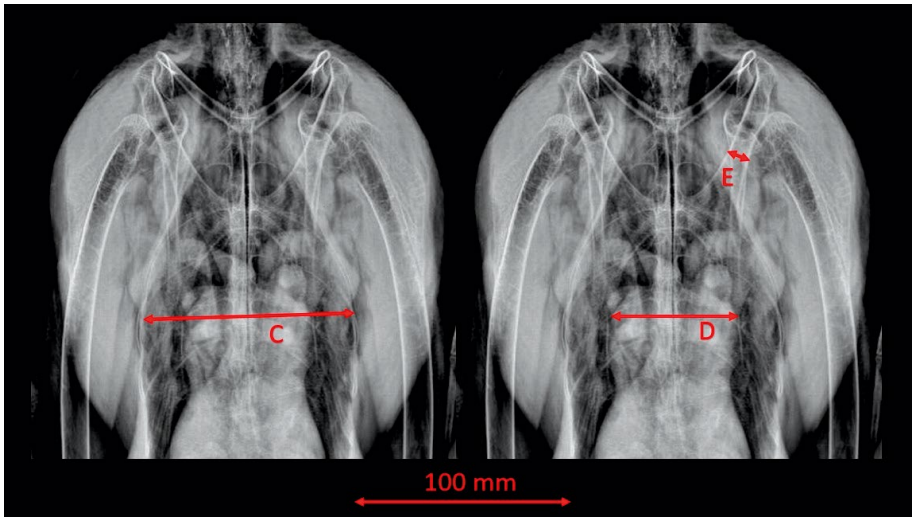


**Fig. 2. Ventrodorsal radiographic image of the white stork**
Explanations: C – thoracic width: width of the thorax at the same level that the width of the heart was measured; D – heart width: width of the heart at its widest point; E – coracoid width: width of the coracoid bone caudally to the articular surface with the humerus

**Tab. 1. Minimum and maximum values, means, and SDs for ratios of measurements in storks (n = 26)**

| Measurements | Minimum (mm) | Maximum (mm) | Mean (mm) | SD (mm) |
|---|---|---|---|---|
| Carina length | 117.90 | 160.20 | 139.80 | 10.05 |
| Heart length | 48.00 | 77.90 | 61.70 | 6.69 |
| Thoracic width | 77.30 | 97.70 | 87.45 | 6.58 |
| Heart width | 41.20 | 59.30 | 51.65 | 4.84 |
| Coracoid width | 8.80 | 13.40 | 10.24 | 1.20 |

## Results and discussion

Minimum and maximum values, means, and standard deviation for ratios of measurements in storks are given in Table 1. The index results used are given in Table 2. According to the study, the average heart length of storks was 51.65 ± 4.84 millimeters. Thoracic width was 87.45 ± 6.58 millimeters. The ratio of heart width to thoracic width was 59.16%. The ratio of heart

**Tab. 2. Minimum and maximum values, means, and SDs for index in storks (n = 26)**

| Ratio | Minimum (%) | Maximum (%) | Mean (%) | SD (%) |
|---|---|---|---|---|
| Heart length/carina length | 31.68 | 53.72 | 44.28 | 4.95 |
| Heart width/thoracic width | 49.21 | 68.80 | 59.16 | 4.91 |
| Heart width/coracoid width | 399.25 | 647.25 | 508.79 | 60.93 |

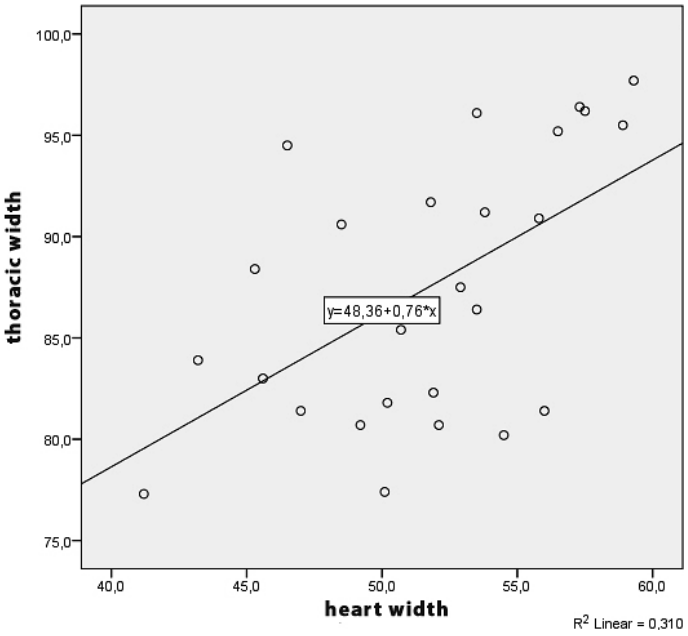


**Fig. 3. Scatterplot showing the relationship between heart width and thoracic width**

length to carina length was 44.28%. The heart width was approximately 5 times that of the coracoid width.

Heart width correlated significantly and positively with the thoracic width (R: 0.556, R2: 0.310, P: 0.003). The scatter plot showing the relationship between heart width and thoracic width is shown in Figure 3. According to the standardized regression coefficients, a one-unit increase in thoracic width results in a 55% increase in heart width.

As a result of this study, cardiac sizes of 26 healthy storks were obtained by lateral and ventrodorsal radiographic images. Heart width was found to be between 49.21% and 68.80% of thoracic width. Heart width was between 399.25% and 399.25% of the coracoid width. Heart length ranged from 31.68% to 53.72% of carina length. The linear regression indicates that only heart width correlates significantly with the thoracic width. There was no significant correlation with other anatomical measurements. The heart width can be estimated by using the thoracic width values with the regression-based formula in the dates of this study. Clinically, it can be determined whether an individual case falls between the minimum or maximum reference values of heart width or heart length. The results presented in this study may provide clinicians with reference information regarding cardiomegaly.

Cardiac size has been the object of numerous studies performed on various birds. Bartyzel et al. (2) examined the heart size of the wood pigeon, they proved that there are no differences between males and females. Straub (22) referred in his study that the width of the cardiac silhouette in parrots strongly correlates with the length of the sternum, the width of the coracoid, and the width of the thorax. Mirshahi (17) proved that there is an important correlation between the cardiac width and thoracic width and between cardiac width and coracoid width in kestrels. In our study of storks, statistically significant regression was found only between Heart width and Thoracic width.

Average cardiac size rates of different bird species are given in Table 3. According to the reference sources used in Table 3, the bird with the highest rate of heart width to the thoracic width was the peregrine falcon – 69% (16). In saker falcons and lanner falcons the value of this parameter was 68% (1). The bird with the lowest mean heart width relative according to the thoracic width was the bald eagle with 49% (14). In this study, the mean value of the above-mentioned index in storks was 59.16%. The bird with the highest rate of heart width to the coracoid width was the saker falcon 900% (1). This rate was on average 508.79% in storks. Migratory birds have been reported to have a larger heart than non-exercising birds (21). The ratio of the heart width to the thoracic width in non-migratory songbirds such as African gray parrots (56%), Senegal parrots (57%), and Amazon parrots (54%) was lower

**Tab. 3. Mean cardiac size ratios of different bird species**

| Species | Heart length/ carina length (%) | Heart width/ thoracic width (%) | Heart width/ coracoid width (%) |
|---|---|---|---|
| White stork | 44.28 | 59.16 | 508.79 |
| Saker falcons (Barbon et al., 1) | 56 | 68 | 900 |
| Lanner falcons (Barbon et al., 1) | 58 | 68 | 839 |
| Harris' hawks (Barbon et al., 1) | 56 | 58 | 706 |
| Peregrine falcons (Barbon et al., 1) | 57 | 69 | 861 |
| Kestrels (Mirshahi et al., 17) | – | 62 | 743 |
| African grey parrots (Straub et al., 22) | – | 56 | 593 |
| Senegal parrots (Straub et al., 22) | – | 57 | 624 |
| Amazon parrots (Straub et al., 22) | – | 54 | 599 |
| Budgerigars (Velayati et al., 24) | – | 62 | 734 |
| Wild galahs (Schnitzer et al., 20) | – | 50-65 | 570-743 |
| Gyr falcons (Caliendo et al., 6) | – | 60 | – |
| Bonelli's eagle (Lopes et al., 15) | – | 53 | 589 |
| Bald eagle (Locke et al., 14) | – | 49 | 670 |

than that of migratory storks (59.16%). However, budgerigars (62%), a non-migratory songbird, had a higher value than storks (24). Following these results, it would be more accurate to compare with more homogeneous samples to understand whether the percentage of heart width to thoracic width is related to a passerine, migratory, or predatory lifestyle. Similarly, falcons, a type of bird of prey, had the highest „heart width/thoracic width" ratio, while eagles, another type of bird of prey, had the lowest ratio (Tab. 3).

## References


1. *Barbon A. R., Smith S., Forbes N.*: Radiographic evaluation of cardiac size in four falconiform species. J. Avian. Med. Surg. 2010, 24 (3), 222-226.
2. *Bartyzel B., Kobryń H., Szara T., Podbielska I., Mysłek P.*: Heart size in wood pigeon Columba palumbus (Linnaeus, 1758). Veterinarija Ir Zootecnika 2003, 21, 43.
3. *Beaufrère H., Pariaut R., Rodriguez D., Tully T. N.*: Avian vascular imaging: a review. J. Avian Med. Surg. 2010, 24 (3), 174-184.
4. *Broek A. V. D., Darke P. G. G.*: Cardiac Measurements On Thoracic Radiographs of Cats. J. Small Anim. Pract. 1987, 28 (2), 125-135.
5. *Buchanan J. W.*: Vertebral scale system to measure heart size in radiographs. Vet. Clin. N. Am. Small Anim. Pract. 2000, 30 (2), 379-394.
6. *Caliendo V., Middelton R., Raghav R.*: Radiographic measurement of internal organs in gyr falcons (Falco rusticolus) and gyr peregrine hybrids (Falco rusticolus × Falco peregrinus). Exot. Pet Med. 2016, 25 (1), 13-17.
7. *Dolata P. T.*: The White Stork Ciconia ciconia protection in Poland by tradition, customs, law, and active efforts, [in:] Tryjanowski P., Sparks T. H. & Jerzak L. (eds.): The White Stork in Poland: studies in biology, ecology and conservation. Bogucki Wydawnictwo Naukowe, Poznań 2006.
8. *Fischer I., Christen C., Hatt J. M., Scharf G.*: Cardiomegaly in a whooper swan (Cygnus cygnus). Vet. Rec. 2005, 156 (6), 178-182.
9. *Göcek Ç., Çiftçi A., Siki M., Tryjanowski P.*: Breeding ecology of the white stork Ciconia ciconia in two localities of Turkey. Sandgrouse 2010, 32 (2), 156-162.
10. *Hall M. R., Gwinner E., Bloesch M.*: Annual cycles in moult, body mass, luteinizing hormone, prolactin, and gonadal steroids during the development of sexual maturity in the white stork (Ciconia ciconia). J. Zool. 1987, 211 (3), 467-486.
11. *Hancock J. A., Kushlan J. A., Kahl M. P.*: Storks, Ibises and Spoonbills of the World. Academic Press, London 1992.
12. *Hanley C. S., Murray H. G., Torrey S., Pokras M. A.*: Establishing cardiac measurement standards in three avian species. J. Avian Med. Surg. 1997, 11 (1), 15-19.
13. *King A. S., McLelland J.*: Cardiovascular system, [in:] Birds – their structure and function. 2nd edition, Baillie're Tindall East Sussex. 1984, p. 214-228.
14. *Locke S., Johnson D., Shimp J., Pridgen T. J.*: Radiographic Reference Intervals of the Cardiac Silhouette Width in the Bald Eagle (Haliaeetus leucocephalus). J. Avian Med. Surg. 2020, 34 (3), 260-267.
15. *Lopes F., Jesus S., Márquez I. L., Fernández V. M., Nunes T., Regalado L. S., González F. G.*: Radiographic reference values for the cardiac silhouette in Bonelli's eagle (Aquila fasciata). J. Avian Med. Surg. 2019, 33 (1), 53-58.
16. *Lumeij J. T., Shaik M. A., Ali M.*: Radiographic reference limits for cardiac width in peregrine falcons (Falco peregrinus). J. Am. Vet. Med. Assoc. 2011, 238 (11), 1459-1463.
17. *Mirshahi A., Shariatzadeh M., Razmyar J., Azizzadeh M.*: Evaluation of cardiac size in the common kestrel (Falco tinnunculus) based on radiographic measurements. J. Avian Med. Surg. 2016, 30 (4), 345-349.
18. *Pees M., Krautwald-Junghanns M. E.*: Cardiovascular physiology and diseases of pet birds. Vet. Clin. N. Am. Small Anim. Pract. 2009, 12 (1), 81-97.
19. *Sak D., Pazvant G.*: Estimation of vertebral heart size and cardiothoracic ratio in Persian cats. Anatomia, Histologia, Embryologia 2021, 50 (3), 543-549.
20. *Schnitzer P., Sawmy S., Crosta L.*: Radiographic measurements of the cardiac silhouette and comparison with other radiographic landmarks in wild Galahs (Eolophus roseicapilla). Animals. 2021, 11 (3), 587.
21. *Smith F. M., West N. H., Jones D. R.*: The cardiovascular system, [in:] Whittow G. C. (ed): Sturkie's avian physiology. 5th edition. Academic Press San Diego. 2000, p. 141-231.
22. *Straub J., Pees M., Krautwald-Junghanns M. E.*: Measurement of the cardiac silhouette in psittacines. J. Am. Vet. Med. Ass. 2002, 221 (1), 76-79.
23. *Sűel H.*: Türkiye'de leylek (Ciconia ciconia Linnaeus, 1758) dağılımının iklim değişikliğine göre kestirimi. Turk. J. 2019, 20 (3), 243-249.
24. *Velayati M., Mirshahi A., Razmyar J., Azizzadeh M.*: Radiographic reference limits for cardiac width of budgerigars (Melopsittacus undulatus). J. Zoo. Wild Med. 2015, 46 (1), 34-38.


**Corresponding author: Bernard Turek, DVM, PhD, Dr Sc, Department of Large Animal Diseases and Clinic, Nowoursynowska 100, 02-787 Warszawa, Poland; e-mail: bernardturek@gmail.com**