NÖRO PSİKİYATRİ ARŞİVİ
ARCHIVES OF NEUROPSYCHIATRY

RESEARCH ARTICLE

Arch Neuropsychiatry 2025
https://doi.org/10.29399/npa.28825

Biomarkers of Endothelial Dysfunction in Cerebral Small Vessel Disease

Uygur TANRIVERDİ[1], Çiğdem BAYRAM GÜREL[2], Gülsel AYAZ[3], Turgut ULUTİN[2], Serdar ARSLAN[4] Osman KIZILKILIÇ[4], Sedat GEZ[1], Ayşegül GÜNDÜZ[1], Birsen İNCE[1]

[1]Istanbul University-Cerrahpasa, Cerrahpasa Faculty of Medicine, Department of Neurology, Cerrahpasa, Istanbul, Türkiye
[2]Istanbul University-Cerrahpasa, Cerrahpasa Faculty of Medicine, Department of Medical Biology, Cerrahpasa, Istanbul, Türkiye
[3]Tekirdag Namık Kemal University, Faculty of Medicine, Department of Medical Biology, Tekirdag, Türkiye
[4]Istanbul University-Cerrahpasa, Cerrahpasa Faculty of Medicine, Department of Radiology, Istanbul, Türkiye

ABSTRACT

Introduction: Endothelial dysfunction (ED) plays a significant role in the development of cerebral small vessel disease (SVD). Analyzing biomarkers related to endothelial function, obtainable from peripheral blood, offers valuable insights for researchers. However, the link between biomarkers of ED and cerebral SVD remains controversial.

Our primary aim was to investigate the relationship between the biomarkers of ED by analyzing intercellular adhesion molecule-1 (ICAM-1), plasminogen activator inhibitor-1 (PAI-1), asymmetric dimethylarginine (ADMA), interleukin-6 (IL-6), C-reactive protein (CRP), and specific clinical findings of cerebral small vessel disease (SVD), such as the presence of minor stroke or cognitive impairment. We also performed a correlation analysis between ED biomarkers and neuroimaging markers of cerebral SVD.

Methods: Patients with cerebral SVD were grouped according to their symptoms. We compared the serum biomarkers of ED between patient groups. All biomarkers except CRP were studied using enzyme-linked immunosorbent assay. We also performed a correlation analysis between cerebral SVD biomarkers in neuroimaging and ED biomarkers.

Results: We included 68 patients in this study. Patients with minor stroke or cognitive deficits had lower levels of PAI-1 than asymptomatic patients, and this finding was more evident in patients with cognitive deficits. Enlarged perivascular spaces (EPVSs) in the basal ganglia score positively but slightly correlated with serum ADMA levels.

Conclusion: PAI-1 has a possible neuroprotective effect against the development of cognitive impairment in cerebral SVD. Biomarkers of ED differ according to the severity, and localization of the lesions. There was a specific relationship between ADMA and EPVSs in basal ganglia, –not EPVSs in the centrum semiovale– irrespective of vascular risk factors suggesting EPVSs in the centrum semiovale and basal ganglia may be the product of different pathological processes.

Keywords: ADMA; cerebral small vessel disease; CRP; endothelial dysfunction; ICAM-1; IL-6; PAI-1

Cite this article as: Tanrıverdi U, Bayram Gürel Ç, Ayaz G, Ulutin T, Arslan S, Kızılkılıç O et al. Biomarkers of Endothelial Dysfunction in Cerebral Small Vessel Disease. Arch Neuropsychiatry 2025, Feb 23. doi: 10.29399/npa.28825 [Epub ahead of print].

INTRODUCTION

Cerebral small vessel disease (SVD) is an important cause of ischemic and hemorrhagic stroke, vascular cognitive impairment and functional disability (1). Radiologically, it is typically characterized by including but not limited to white matter hyperintensities (WMH), lacunes, cerebral microbleeds, enlarged perivascular spaces (EPVSs) and atrophy (2). The pathogenesis of the disease is not well established, however impaired blood-brain barrier (BBB) and endothelial dysfunction (ED) seem to be the leading factors (1). Investigating ED has been advocated as crucial to enhancing our understanding of cerebral SVD (3).

Highlights

- **Decreased PAI-1 activity linked to cognitive impairment.**
- **Endothelial dysfunction varies in the centrum semiovale vs. basal ganglia.**
- **EPVSs in the basal ganglia associated with serum ADMA levels.**

Studying molecules directly linked to endothelial function and those influencing the endothelium itself can offer valuable insights to researchers (3). Unfortunately, the association between these biomarkers and cerebral SVD remains incomplete (3,4). First, the complexity of endothelial functions and interactions among biomarkers limit their utility. Another argument is that various radiological manifestations of cerebral SVD are partially or not related to the biomarkers of ED or systemic inflammation, and they could have different pathological background. This inconsistency –in addition to the above– could be attributed to the variable characteristics of the individuals included in the studies and the selection bias of the specific biomarkers included. It is still an ongoing debate whether ED is a cause or a result of cerebral

Correspondence Address: Uygur Tanrıverdi, Istanbul University – Cerrahpasa, Cerrahpasa Faculty of Medicine, Department of Neurology, Fatih, İstanbul, Türkiye • **E-mail:** uygur.tanriverdi@istanbul.edu.tr
Received: 16.05.2024, **Accepted:** 15.09.2024, **Available Online Date:** 23.02.2025
©Copyright 2024 by Turkish Association of Neuropsychiatry - Available online at www.noropskiyatriarsivi.com

SVD (4). Remarkably, only a handful of studies have simultaneously investigated biomarkers demonstrating the range of endothelial functions and systemic inflammation. This approach is critical in capturing the complete spectrum of endothelial functions and its implications in cerebral SVD (3,4). Furthermore, the inclusion criteria in many studies often overlooked the influence of large artery diseases or cardioembolic conditions on these biomarkers, presenting another layer of complexity.

Our study focuses on a set of biomarkers that are directly linked to key aspects of endothelial function which have emerged prominently in the literature over the last 30 years, making it easier to compare our findings with the literature (3–6). ICAM-1 is expressed by vascular endothelial cells and it mediates adhesion of platelets, leukocytes and is involved in BBB dysfunction. ICAM-1 was found to be elevated in cross-sectional studies conducted on cerebral SVD patients and was associated with the presence and/or severity of white matter hyperintensities and/or lacunes (7–11). In longitudinal studies, ICAM-1 was linked to the progression or presence of cerebral SVD (12–15). However, no relationship was found between ICAM-1 and EPVS (16). This lack of association between ICAM-1 and EPVS is noteworthy, given ICAM-1 has significant value in other radiological manifestations of cerebral SVD. On the other hand, despite the shared common mechanisms in both patients with cognitive impairment and stroke caused by cerebral SVD, ICAM-1 loses its utility in both cross-sectional and longitudinal studies when patients with cognitive impairment are included (17,18).

IL-6 and CRP are well-established markers of systemic inflammation and are not specific to the endothelium (5). The relationship between IL-6 and WMH is inconsistently reported in the literature. In population-based studies with healthy participants, IL-6 was found to be both unrelated (19–23) and related (24) to WMH. In a follow-up study, both IL-6 and CRP were associated with the progression of cerebral SVD (17). When considering EPVS, CRP was found to be related (21,25). However, some studies found that neither CRP nor IL-6 show an association with EPVS (8,16,21).

PAI-1 plays a significant role in the endogenous fibrinolytic activity of the endothelium. Elevated PAI-1 levels were associated with activated endothelial cells and increased thrombotic activity (26). Knotterus et al. found decreased PAI-1 activity was associated with extensive WMH (27). Another study failed to demonstrate any relationship between PAI-1 and cerebral SVD (28). In contrast, some studies found increased PAI-1 levels were associated with cerebral SVD (29,30).

Nitric oxide (NO), produced by endothelial cells, reduces vascular tone leading to vasodilation and inhibits platelet activation. It also regulates cell proliferation. Nitric oxide is produced from L-arginine by the enzyme nitric oxide synthase (NOS). Asymmetric dimethylarginine is a competitive endogenous inhibitor of NOS, and elevated levels in peripheral blood are associated with increased thrombotic activity, impaired endothelial function, and higher cardiovascular risk (31). In the context of cerebral SVD, ADMA is a promising biomarker (32).

In this study, we aim to explore the reasons why some patients exhibit symptoms while others remain asymptomatic, by analyzing endothelial dysfunction biomarkers. Specifically, we seek to determine whether the clinical features of the disease, such as cognitive impairment and stroke, correspond to distinct profiles based on these biomarkers. By doing so, we hope to shape potential treatment options that could offer promise for patients based on their clinical characteristics. Additionally, we aimed to demonstrate the correlation between the severity of radiological markers of small vessel disease and these biomarkers, allowing us to establish a specific relationship between the endothelium and a radiological marker within this complex pathophysiology. For this purpose, we chose i) intercellular adhesion molecule-1 (ICAM-1) to demonstrate vascular inflammation, ii) interleukin 6 (IL-6) and C-reactive protein (CRP) to demonstrate systemic inflammation, iii) plasminogen activator inhibitor-1 (PAI-1) to show hemostasis, and iv) asymmetric dimethylarginine (ADMA) to demonstrate regulation of vascular tone.

METHODS

This was a hospital-based, cross-sectional study. We included all eligible patients who were admitted to the outpatient clinics of our institution between April 2018 and June 2019 for a routine follow-up visit.

The inclusion criteria were being older than 40-years-old and having cerebral SVD in magnetic resonance imaging (MRI) based on STRIVE criteria (33). The exclusion criteria were as follows: a debilitating symptomatic ischemic stroke (NIHSS ≥5); acute or subacute stroke (<3 months); an MRI feature that suggested large artery involvement; a history of malignancy; atrial fibrillation (AF); evidence of large artery stenosis exceeding 50% in doppler ultrasound, computerized tomography angiography (CTA), or magnetic resonance angiography (MRA); cognitive impairment due to probable Alzheimer's disease; having other causes of SVD (genetic, inflammatory, toxic).

Patients were categorized into three distinct groups based on their clinical presentations. Initially, those with a history of minor ischemic stroke (NIHSS <5) or transient ischemic attack (TIA) were designated as the minor stroke group. Subsequently, among the remaining patients, those diagnosed with vascular cognitive impairment were classified as the cognitive group, following the 2011 AHA/ASA criteria (34). Cognitive and minor stroke groups constituted a symptomatic group. The rest of the patients who reported non-specific symptoms such as headache or tinnitus were identified as the asymptomatic group, indicating a silent clinical presentation.

Istanbul University Cerrahpaşa Faculty of Medicine local ethics committee approved the study protocol (reference number: 08/11/2017–419798), and a written informed consent was obtained from all participants.

The evaluation included a two-step procedure: laboratory investigation of ED biomarkers and detailed clinical and radiological assessment. The following biomarkers related to endothelial dysfunction, ICAM-1, ADMA, IL-6, and PAI-1, were assayed via enzyme-linked immunosorbent assay (ELISA). C-reactive protein was analyzed in the autoanalyzer of the faculty's central biochemistry laboratory (Immunoturbidimetric assay). Blood samples were taken from the cubital vein between 8–10 a. m. after a night-long fasting. All samples except CRP were evaluated twice. The time interval between blood collection and MRI imaging was less than six months. Blood samples collected in vacuum tubes were centrifuged within one hour, and the serum samples were aliquoted and stored at -80°C until analysis. To ensure the reliability of the results, hemolyzed blood samples were excluded from the study. Once all the samples were collected, the sera were brought to room temperature for the ELISA procedure, which was performed according to the manufacturer's instructions. The results were calculated based on the standard sera provided with the kit. ICAM-1 (Human ICAM-1 Platinum ELISA/ Affymetrix ebioscience Catalog No: BMS 201/96 test), ADMA (General Asymmetrical Dimethylarginine ELISA Kit / ABclonal Catalog No: RK00614/96 test), IL-6 (Human IL-6 ELISA Kit / Invitrogen Catolog No: BMS213–2/96 test) and PAI-1 (Human PAI-1 Platinum ELISA Affimetrix eBioscience Catalog No: BMS 2033/96 test).

We noted demographic features and vascular risk factors (hypertension, hyperlipidemia, obesity, smoking, diabetes mellitus coronary artery disease) and performed a detailed neurologic examination of each patient. A routine cardiovascular work-up, including electrocardiogram (ECG), 24-hour Holter monitoring, and transthoracic echocardiography, was performed to exclude cardioembolic causes in each case. A standardized mini-mental state test and routine laboratory tests, including complete blood count, glucose, kidney and liver function test, electrolytes, thyroid function test, lipid panel, HbA1 c, erythrocyte sedimentation rate, vitamin B12, glomerular filtration rate, anti-HIV, HBsAg, anti-HCV and VDRL were performed in all patients. Lastly, an estimated glomerular filtration rate was calculated for each patient using the modification of diet in renal disease (MDRD) formula.

Magnetic resonance scans were acquired using 1.5T The Siemens Magnetom Avanto (Erlangen, Germany) scanner and the 3T Philips Ingenia MR scanner (Philips, Best, the Netherlands) according to STRIVE criteria (33). The standard imaging protocol included sagittal TSE T2, coronal TSE T2 (repetition time (TR) 3,000 ms, echo time (TE) 80 ms, field-of-view (FOV) 185 mm × 230 mm, matrix size 400 × 320, slice thickness 5 mm), axial fluid attenuation inversion recovery (FLAIR) (TR 11,000 ms, TE 125 ms, inversion time 2.5 sec, FOV 185 mm × 230 mm, matrix size 370 × 260, slice thickness 5 mm), axial T1-weighted (TE=17 ms, TR=600 ms, matrix=188 × 320, NEX=1, FOV=230 mm, flip angle=90°) and, DWI sequences. Patients were excluded from the study if any sequence was missing. Two experienced neuroradiologists collaboratively evaluated all MRI data (S.A., O.K.) according to STRIVE criteria: The WMHs were graded on a scale of 0 to 3 for both periventricular and deep white matter using the Fazekas scale. The EPVSs were counted and graded on a 5-point scale (0=no, 1= <10, 2=11–20, 3=21–40, and 4= >40) both for the centrum semiovale (EPVSs-CS) and the basal ganglia (EPVSs-BG). Lacunes were counted and separated into three groups (none, single and multiple). Cerebral atrophy was evaluated with global cortical atrophy scale (35).

Statistical Analysis

Continuous variables were indicated as median, minimum-maximum, or mean, and standard deviation as applicable. Categorical variables were shown as n (%). The Shapiro-Wilk test was performed for normality. As all the data were nonhomogeneous, we used the χ^2 test for categorical variables and Mann-Whitney U test for continuous variables. Bonferroni correction was applied if multiple comparison tests were encountered. A univariate analysis was used to evaluate the relationship between radiological markers (scores of WMHs-pv, WMHs-deep, EPVSs-CS, EPVSs-BG, lacunes, and atrophy) and biomarkers of ED (serum levels of ADMA, PAI-1, IL-6, CRP, ICAM-1). We also performed a logistic regression analysis by adjusting for vascular risk factors, other radiological features and glomerular filtration rate for the statistically significant variables in the abovementioned analysis.

Statistical significance was set at a p-value ≤0.05. All calculations were made using IBM Statistical Package for Social Sciences (SPSS) program version 20 (International Business Machines Corp., New Orchard Road, Armonk, NY, USA)

RESULTS

We recruited 97 patients in the study period. However, we had to exclude 17 patients due to comorbid conditions: malignancy (n=3), hepatitis C infection (n=3), AF (n=8), and rheumatoid arthritis (n=1). Additionally, two patients were excluded: one had an acute stroke, and one had large artery disease. We excluded seven more patients from the analysis due to missing data: hemolysis of the serum samples (n=2) and insufficient MRI data (n=5). Five more patients diagnosed with cerebral autosomal dominant arteriopathy with subcortical infarcts and leukoencephalopathy (CADASIL) during the study were also excluded from the analysis. Eventually, we analyzed the clinical, serum samples, and neuroimaging of 68 patients (Figure 1).

There were 43 symptomatic patients, and 15 of them had a history of minor stroke or TIA. The other 25 patients comprised the asymptomatic group. The median age of all patients was 70, and 36 (52%.9) patients were men. Obesity was more common in the symptomatic group (p<0.005). The other demographic characteristics and risk factors were not different. Table 1 shows the clinical and radiological features of these groups.

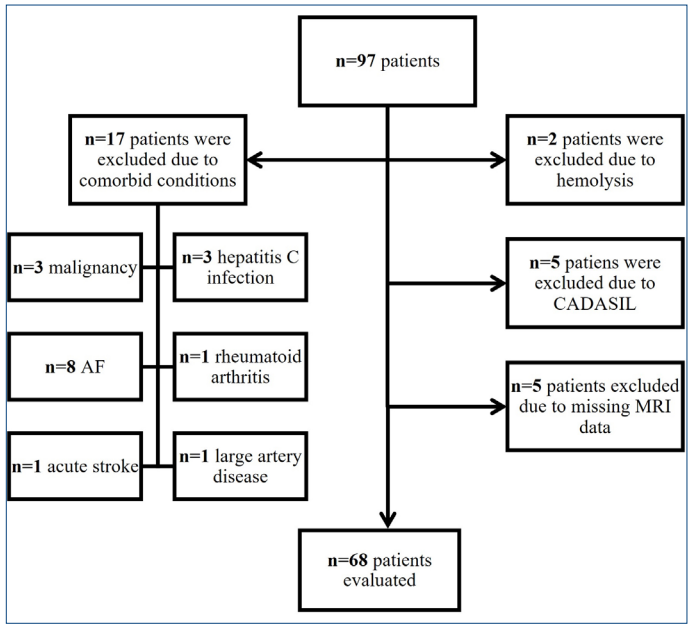

Figure 1. Flow chart of the study population.

Table 1. Clinical characteristics of whole patient group and subgroups

	All patients n=68	Symptomatic n=43	Asymptomatic n=25	p
Age (y) median (min-max)	70 (43–90)	71 (43–90)	68 (52–81)	0.263*
Sex (M) n (%)	36 (52.9)	21 (48.8)	15 (60.0)	0.374**
HT n (%)	52 (76.5)	36 (83.7)	16 (64.0)	0.065**
DM n (%)	25 (36.8)	18 (41.9)	7 (28.0)	0.253**
HL n (%)	22 (32.4)	16 (37.2)	6 (24.0)	0.262**
CAD n (%)	13 (19.1)	7 (16.3)	6 (24.0)	0.435**
Smoking n (%)	29 (42.6)	20 (46.5)	9 (36.0)	0.398**
Obesity n (%)	25 (36.8)	20 (46.5)	5 (20.0)	**0.029****

*Mann-Whitney U test; **Chi-square test; [†a] p<0.05; CAD: coronary artery disease; DM: diabetes mellitus; HL: hyperlipaemia; HT: hypertension; M: male; Y: year.

Table 2. Levels of serum biomarkers of endothelial dysfunction

	All patients n=68	Symptomatic (n=43)	Asymptomatic (n=25)	p*
ICAM-1 (ng/mL)	304.47 (196.12–569.42)	304.24 (196.12–569.42)	304.7 (210.51–544.14)	0.533
PAI-1 (ng/mL)	87.9 (29.4–172)	85.9 (53–167)	99.5 (29.4–172)	0.028**
ADMA (ng/mL)	518.87 (121.56–671.06)	506 (121.56–671.06)	566.02 (128.74–662.48)	0.258
IL-6 (pg/mL)	0.881 (0.008–4.606)	0.946 (0.008–4.606)	0.608 (0.008 – 4.148)	0.215
CRP (mg/L)	2.09 (0.17–22.47)	2.08 (0.17–22.47)	2.24 (0.2–7.82)	0.834

*Mann-Whitney U test; **p<0.05; ADMA: asymmetric dimethylarginine; CRP: C-reactive protein; ICAM-1:Intercellular adhesion molecule-1; IL-6:Interleukin 6; PAI-1: Plasminogen activator inhibitor-1.

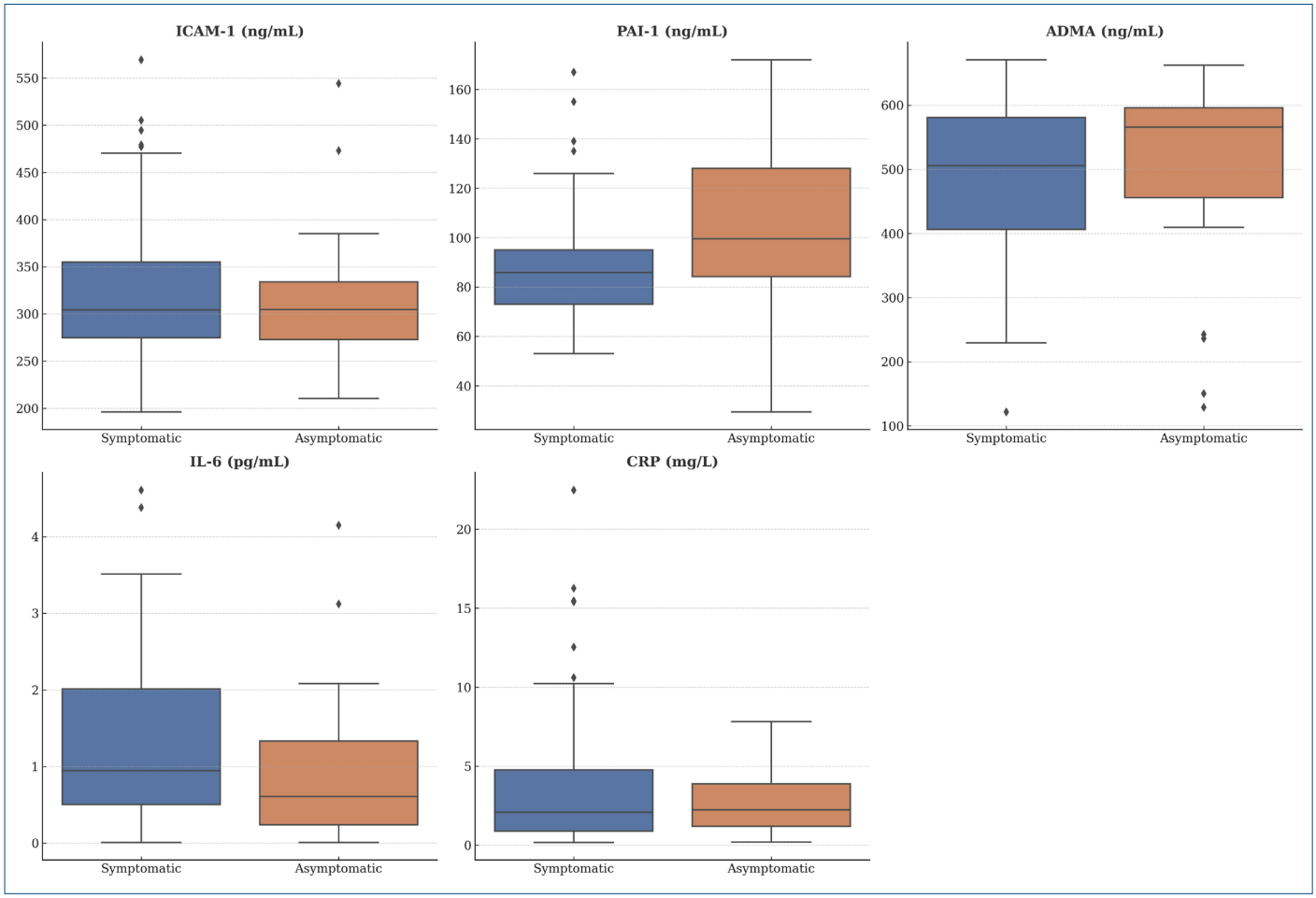

Figure 2. Biomarkers and clinical groups (ADMA: asymmetric dimethylarginine; CRP: C-reactive protein; ICAM-1: intercellular adhesion molecule-1; IL-6: interleukin 6; PAI-1: plasminogen activator inhibitor-1).

Among the markers utilized in our study, only PAI-1 exhibited statistical significance (Table 2, Figure 2). PAI-1 levels of symptomatic patients were significantly lower compared to the asymptomatic group (Table 2). When the patients with cognitive deficit and patients with minor stroke were compared with the asymptomatic group, it was observed that the patients with cognitive deficit had lower PAI-1 levels (Table 3, Figure 3). Patients with minor stroke also exhibited lower median PAI-1 levels, but this tendency was not statistically significant.

The EPVSs-BG scores graded according to a 5-point scoring system were found to be positively but slightly correlated with serum ADMA levels (Table 4). A multivariable logistic regression analysis was performed to evaluate the relationship between serum ADMA levels and EPVS-BG while controlling for potential confounders. Vascular risk factors such as age, sex, hypertension, diabetes mellitus, hyperlipidemia, coronary artery disease, smoking, obesity, antiplatelet medications, and glomerular filtration rate were included in the model to control for their potential confounding effects. The significant relationship between ADMA and severe EPVS-BG (EPVS-BG score >2) remained after adjusting for these potential confounders (Nagelkerke R^2=0.343, Odds ratio=1.007, 95% CI: [1.001–1.013]).

Table 3. Levels of serum biomarkers of endothelial dysfunction according to subgroups of patients

	Minor stroke n=15	Cognitive (n=28)	Asymptomatic (n=25)	Minor stroke versus Cognitive p*	Cognitive versus Asymptomatic p*	Minor stroke versus Asymptomatic p*
ICAM-1 (ng/mL)	304.24 (196.1–569.4)	305.06 (200.0–505.2)	304.7 (210.5–544.1)	0.848	0.581	0.615
PAI-1 (ng/mL)	85.9 (59.9 – 167)	85.6 (53.0–126.0)	99.5 (29.4–172.0)	0.499	0.015	0.314
ADMA (ng/mL)	448.13 (121.6–671.1)	512.43 (310.9–645.3)	566.02 (128.7–662.5)	0.346	0.581	0.105
IL-6 (pg/mL)	1.03 (0.01–4.38)	0.924 (0.1 – 4.6)	0.608 (0.01 – 4.1)	0.557	0.397	0.162
CRP (mg/L)	2.01 (0.3–15.5)	2.1 (0.2–22.5)	2.24 (0.2–7.8)	0.702	0.810	0.933

*Mann-Whitney U test with Bonferroni correction, alpha value set to 0.017; ADMA: asymmetric dimethylarginine; CRP: C-reactive protein; ICAM-1:Intercellular adhesion molecule-1; IL-6:Interleukin 6; PAI-1: Plasminogen activator inhibitor-1.

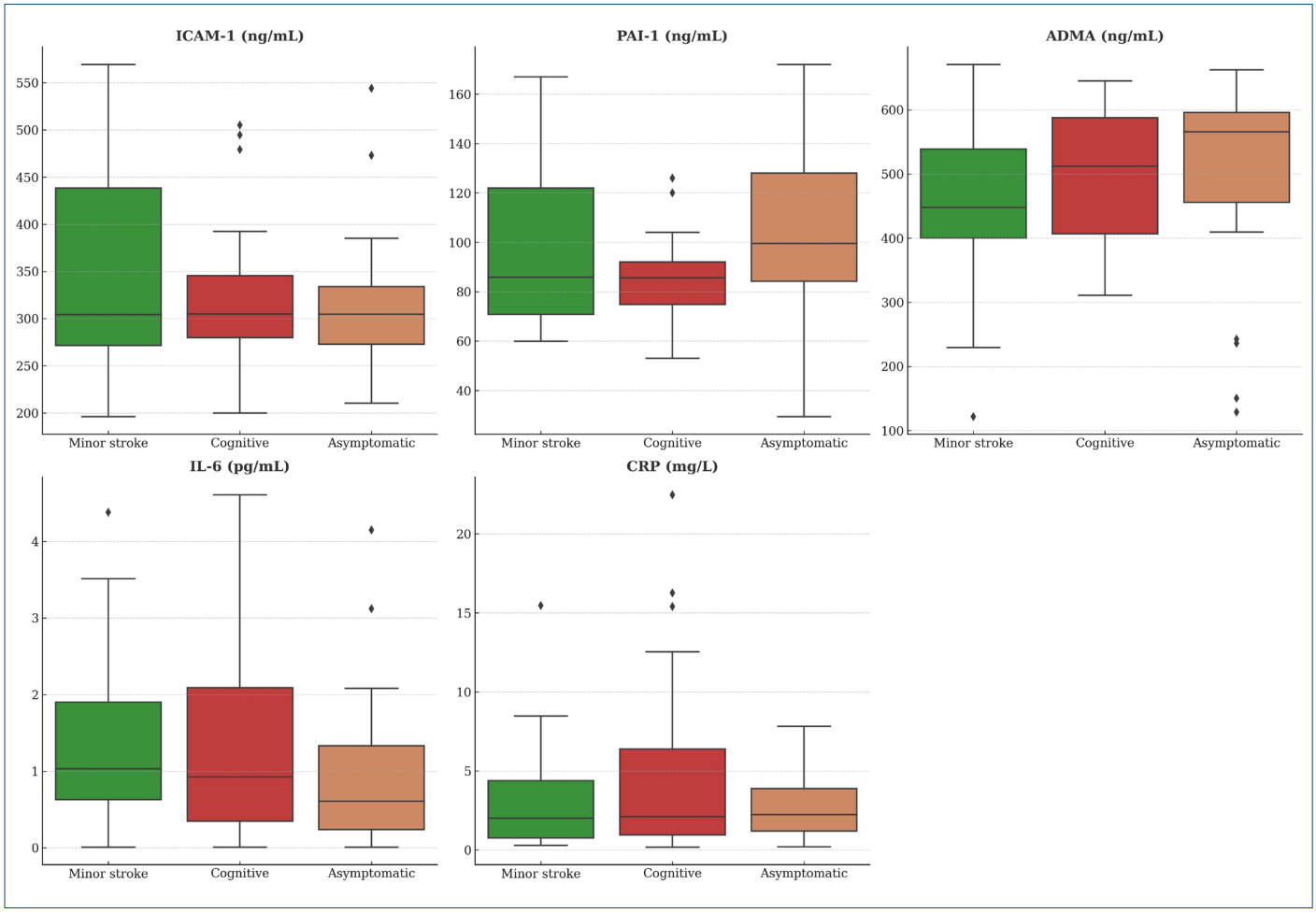

Figure 3. Biomarkers and clinical subgroups (ADMA: asymmetric dimethylarginine; CRP: C-reactive protein; ICAM-1: intercellular adhesion molecule-1; IL-6: interleukin 6; PAI-1: plasminogen activator inhibitor-1).

DISCUSSION

The major findings in this study are i. patients with minor stroke or cognitive deficit had lower levels of PAI-1 than asymptomatic patients, and this finding was more evident in patients with cognitive deficit, ii. EPVSs-BG scores weakly but positively correlated with serum ADMA levels.

Several studies found ICAM-1 was associated with cerebral SVD (7–10,12,22), whereas others did not (16,17,36). The studies questioning the relationship between EPVSs and ICAM-1 were limited, and no correlation was found in these studies (8,16,37). Several studies found PAI-1 was associated with cerebral SVD (27,30), whereas others did not

Table 4. Biomarkers of ED and MRI features

	WMHs-pv	WMHs-deep	EPVSs-CS	EPVSs-BG	Lacunes	Atrophy
ICAM-1	r=0.096 p=0.434	r=0.148 p=0.227	r=-0.016 p=0.899	r=-0.108 p=0.379	r=-0.073 p=0.555	r=-0.099 p=0.42
PAI-1	r=-0.012 p=0.924	r=0.029 p=0.815	r=0.186 p=0.13	r=-0.03 p=0.809	r=-0.058 p=0.64	r=-0.184 p=0.132
ADMA	r=0.06 p=0.627	r=0.07 p=0.57	r=0.224 p=0.067	**r=0.317 p=0.008**	r=0.077 p=0.533	r=-0.06 p=0.627
IL-6	r=-0.092 p=0.456	r=0.056 p=0.652	r=0.055 p=0.653	r=0.043 p=0.727	r=0.045 p=0.716	r=0.151 p=0.22
CRP	r=-0.013 p=0.914	r=0.079 p=0.521	r=0.078 p=0.529	r=0.034 p=0.784	r=-0.097 p=0.431	r=-0.234 p=0.054

ADMA: asymmetric dimethylarginine; CRP: C-reactive protein; EPVSs-CS: enlarged perivascular spaces in the centrum semiovale; EPVSs-BG: enlarged perivascular spaces in the basal ganglia; ICAM-1: intercellular adhesion molecule-1; IL-6: interleukin 6; PAI-1: plasminogen activator inhibitor-1; WMHs-deep: deep white matter hyperintensity; WMHs-pv: periventricular white matter hyperintensities

(28,38,39). On the contrary, all studies that used ADMA as a biomarker found increased serum levels of ADMA in cerebral SVD (32,40–45). Interestingly, none of these studies chose EPVSs as a radiological feature of cerebral SVD. Asymmetric dimethylarginine sustained its utility in young asymptomatic patients (32), in CADASIL (44), in non-stroke population-based cohorts (40,41), in non-stroke hospital-based cohorts (43), in acute stroke patients (45), and in chronic symptomatic patients (42). We propose that the consistency exhibited by ADMA, in contrast to other biomarkers, suggests its active involvement in all stages of cerebral SVD, regardless of clinical findings.

The only serum ED biomarker related to the clinical findings of cerebral SVD in our study was PAI-1. Patients with minor stroke or cognitive deficits had lower levels of PAI-1 than asymptomatic patients, and this finding was even more evident in patients with cognitive impairment. Glial cells, especially astrocytes, express PAI-1 in the central nervous system and PAI-1 inhibits the neurotoxicity and neuronal cell death caused by tissue plasminogen activator (t-PA) activity (46). An animal experiment also demonstrated a model of depression in PAI-1 gene-silenced mice (47). In addition, low levels of PAI-1 were associated with decreased cognitive functions in an Asian study on cognitive functions (48). In the Sydney Memory and Aging Study, subjects with preserved cognitive functions showed increased PAI-1 levels compared to cognitively impaired subjects (49). In the Maastricht stroke study, patients with severe WMHs had increased t-PA and decreased PAI-1 levels. The authors suggested that tissue damage and BBB damage induced by t-PA could not be supported by the protective efficacy of PAI-1 (27). Intracranial injection of PAI-1 has been shown to reduce infarct volume in an experimental model of stroke in mice (50,51). In contrast, another recent study from Moscow found that t-PA levels were associated with WMHs and EPVSs, while PAI-1 levels were not associated with cerebral SVD (28). However, all patients in the Maastricht stroke study had a lacunar stroke, but only half of the patients in the Moscow study had a lacunar stroke. In our research, we found a similar relationship in the cognitive domain. The lack of association between radiological features of SVD and PAI-1 in our study could be attributed to the similarity between our study and the Moscow study since 41% of our patients had lacunes.

Asymmetric dimethylarginine is recognized as a mediator of oxidative stress and a biomarker of ED due NOS inhibition. Moreover, increased ADMA levels can stimulate endothelial cells for platelet and leukocyte adhesion (31). It has been shown that ICAM-1 levels increase when ADMA is added to cell culture in-vitro (52). In an animal experiment, it was observed that angiotensin-converting enzyme expression and superoxide production increased with ADMA injection in endothelial NOS gene-silenced mice, and more vascular effects were observed compared to the control group (53). This relationship suggests that ADMA plays a longer-term role in ED by acting on intracellular pathways and gene expressions, apart from its acute effects. Therefore, ADMA may be associated with oxidative stress, impaired BBB permeability, and indirectly increased inflammation. We know the relationship between ADMA and EPVSs in sporadic cerebral SVD has yet to be searched. In our study, there was a weak positive correlation between EPVSs-BG scores –not EPVSs-CS scores– and serum ADMA levels irrespective of vascular risk factors. This finding suggests that EPVSs in the centrum semiovale and basal ganglia may be the product of different pathological processes. Similarly, in a recent follow-up study, impaired endothelial reactivity was found to correlate with EPVSs-BG but not with EPVSs-CS (54).

We acknowledge certain limitations of our study. While there are studies in the literature with smaller sample sizes than ours, our relatively small sample size may limit the statistical power to detect smaller effects, particularly in subgroup analyses. Thus, larger studies are needed to confirm our findings. We did not have a healthy non-SVD group. However, this cross-sectional study aimed to compare clinical findings of SVD, not patients with SVD and healthy subjects. Another limitation was that we do not have micro bleeding data in the neuroimaging findings. Although this may have prevented us from considering the radiological features of SVD as a whole, it did not compromise the integrity of the available data. Another possible limitation was that we excluded patients with Alzheimer's disease using only radiological biomarkers, not cerebrospinal fluid biomarkers. This situation may have shadowed the results by causing mixed dementia patients to be included in the patient group despite detailed neurological evaluation.

As a result, PAI-1 has a possible neuroprotective effect against the development of cognitive impairment in cerebral SVD. Biomarkers of ED differ according to the severity, and localization of the lesions. There was a specific relationship between serum levels of ADMA and EPVSs in basal ganglia, not EPVSs in the centrum semiovale– irrespective of vascular risk factors suggesting EPVSs in the centrum semiovale and basal ganglia may be the product of different pathophysiological processes.

Ethics Committee Approval: Istanbul University Cerrahpaşa Faculty of Medicine local ethics committee approved the study protocol (reference number: 08/11/2017–419798).

Informed Consent: Written informed consent was obtained from all participants.

Peer-review: Externally peer-reviewed.

Author Contributions: Concept- Bİ, UT, ÇBG, OK; Design- Bİ, UT, ÇBG, OK,SA; Supervision- UT, ÇBG, GA,TU, SA, OK, SG,AG,Bİ; Resource- UT, ÇBG, GA,TU, SA, OK, SG,AG,Bİ; Materials- UT, ÇBG, GA,TU, SA, OK, SG,AG,Bİ; Data Collection and/or Processing- UT, ÇBG, GA,TU, SA, OK, SG,AG,Bİ; Analysis and/or Interpretation- UT, AG, Bİ, SA; Literature Search- UT, Bİ; Writing- UT, ÇBG, GA,TU, SA, OK, SG,AG,Bİ; Critical Reviews- Bİ, AG, UT, ÇBG, TU OK.

Conflict of Interest: The authors declared that there is no conflict of interest.

Financial Disclosure: This study was supported by the Turkish Neurological Society.

REFERENCES

1. Wardlaw JM, Smith C, Dichgans M. Mechanisms of sporadic cerebral small vessel disease: insights from neuroimaging. The Lancet Neurology. 2013;12(5):483–497. [Crossref]
2. Duering M, Biessels GJ, Brodtmann A, Chen C, Cordonnier C, de Leeuw F-E, et al. Neuroimaging standards for research into small vessel disease-advances since 2013. Lancet Neurol. 2023;22(7):602–618. [Crossref]
3. Poggesi A, Pasi M, Pescini F, Pantoni L, Inzitari D. Circulating biologic markers of endothelial dysfunction in cerebral small vessel disease: a review. J Cereb Blood Flow Metab. 2016;36(1):72–94. [Crossref]
4. Low A, Mak E, Rowe JB, Markus HS, O'Brien JT. Inflammation and cerebral small vessel disease: a systematic review. Ageing Res Rev. 2019;53:100916. [Crossref]
5. Jaime Garcia D, Chagnot A, Wardlaw JM, Montagne A. A scoping review on biomarkers of endothelial dysfunction in small vessel disease: molecular insights from human studies. Int J Mol Sci. 2023;24(17):13114. [Crossref]
6. Wiseman S, Marlborough F, Doubal F, Webb DJ, Wardlaw J. Blood markers of coagulation, fibrinolysis, endothelial dysfunction and inflammation in lacunar stroke versus non-lacunar stroke and non-stroke: systematic review and meta-analysis. Cerebrovasc Dis. 2014;37(1):64–75. [Crossref]
7. Hassan A, Hunt BJ, O'Sullivan M, Parmar K, Bamford JM, Briley D, et al. Markers of endothelial dysfunction in lacunar infarction and ischaemic leukoaraiosis. Brain. 2003;126(Pt 2):424-432. [Crossref]
8. Rouhl RPW, Damoiseaux JGMC, Lodder J, Theunissen ROMFIH, Knottnerus ILH, Staals J, et al. Vascular inflammation in cerebral small vessel disease. Neurobiol Aging. 2012;33(8):1800–1806. [Crossref]
9. Arba F, Giannini A, Piccardi B, Biagini S, Palumbo V, Giusti B, et al. Small vessel disease and biomarkers of endothelial dysfunction after ischaemic stroke. Eur Stroke J. 2019;4(2):119–126. [Crossref]
10. Han JH, Wong KS, Wang YY, Fu JH, Ding D, Hong Z. Plasma level of sICAM-1 is associated with the extent of white matter lesion among asymptomatic elderly subjects. Clin Neurol Neurosurg. 2009;111(10):847–851. [Crossref]
11. Sarchielli P, Nardi K, Chiasserini D, Eusebi P, Tantucci M, Di Piero V, et al. Immunological profile of silent brain infarction and lacunar stroke. PLoS One. 2013;8(7):e68428. [Crossref]
12. Markus Hugh S., Hunt Beverley, Palmer Kiran, Enzinger Christian, Schmidt Helena, Schmidt Reinhold. Markers of endothelial and hemostatic activation and progression of cerebral white matter hyperintensities. Stroke. 2005;36(7):1410–1414. [Crossref]
13. Kawamura T, Umemura T, Kanai A, Nagashima M, Nakamura N, Uno T, et al. Soluble adhesion molecules and C-reactive protein in the progression of silent cerebral infarction in patients with type 2 diabetes mellitus. Metabolism. 2006;55(4):461–466. [Crossref]
14. Umemura T, Kawamura T, Umegaki H, Mashita S, Kanai A, Sakakibara T, et al. Endothelial and inflammatory markers in relation to progression of ischaemic cerebral small-vessel disease and cognitive impairment: a 6-year longitudinal study in patients with type 2 diabetes mellitus. J Neurol Neurosurg Psychiatry. 2011;82(11):1186–1194. [Crossref]
15. Chen Y, Yu H, Zhu J, Zhang H, Zhao Y, Dong Y, et al. Low carotid endothelial shear stress associated with cerebral small vessel disease in an older population: a subgroup analysis of a population-based prospective cohort study. Atherosclerosis. 2019;288:42–50. [Crossref]
16. Wang X, Chappell FM, Valdes Hernandez M, Lowe G, Rumley A, Shuler K, et al. Endothelial function, inflammation, thrombosis, and basal ganglia perivascular spaces in patients with stroke. J Stroke Cerebrovasc Dis. 2016;25(12):2925–2931. [Crossref]
17. Staszewski J, Piusiska-Macoch R, Brodacki B, Skrobowska E, Stpie A. IL-6, PF-4, sCD40 L, and homocysteine are associated with the radiological progression of cerebral small-vessel disease: a 2-year follow-up study. Clin Interv Aging. 2018;13:1135–1141. [Crossref]
18. Huang C-W, Tsai M-H, Chen N-C, Chen W-H, Lu Y-T, Lui C-C, et al. Clinical significance of circulating vascular cell adhesion molecule-1 to white matter disintegrity in Alzheimer's dementia. Thromb Haemost. 2015;114(12):1230–1240. [Crossref]
19. Jefferson AL, Massaro JM, Wolf PA, Seshadri S, Au R, Vasan RS, et al. Inflammatory biomarkers are associated with total brain volume: the Framingham Heart Study. Neurology. 2007;68(13):1032–1038. [Crossref]
20. Baune BT, Ponath G, Rothermundt M, Roesler A, Berger K. Association between cytokines and cerebral MRI changes in the aging brain. J Geriatr Psychiatry Neurol. 2009;22(1):23–34. [Crossref]
21. Aribisala BS, Wiseman S, Morris Z, Valdés-Hernández MC, Royle NA, Maniega SM, et al. Circulating inflammatory markers are associated with magnetic resonance imaging-visible perivascular spaces but not directly with white matter hyperintensities. Stroke. 2014;45(2):605–607. [Crossref]
22. Shoamanesh A, Preis SR, Beiser AS, Vasan RS, Benjamin EJ, Kase CS, et al. Inflammatory biomarkers, cerebral microbleeds, and small vessel disease. Neurology. 2015;84(8):825–832. [Crossref]
23. Satizabal CL, Zhu YC, Mazoyer B, Dufouil C, Tzourio C. Circulating IL-6 and CRP are associated with MRI findings in the elderly: the 3C-Dijon Study. Neurology. 2012;78(10):720–727. [Crossref]
24. Fornage M, Chiang YA, O'Meara ES, Psaty BM, Reiner AP, Siscovick DS, et al. Biomarkers of inflammation and MRI-defined small vessel disease of the brain: the cardiovascular health study. Stroke. 2008;39(7):1952–1959. [Crossref]
25. Hilal S, Ikram MA, Verbeek MM, Franco OH, Stoops E, Vanderstichele H, et al. C-reactive protein, plasma amyloid-β levels, and their interaction with magnetic resonance imaging markers. Stroke. 2018;49(11):2692–2698. [Crossref]
26. Wang M, Hao H, Leeper NJ, Zhu L; Early Career Committee. Thrombotic regulation from the endothelial cell perspectives. Arterioscler Thromb Vasc Biol. 2018;38(6):e90–e95. [Crossref]
27. Knottnerus ILH, Govers-Riemslag JWP, Hamulyak K, Rouhl RPW, Staals J, Spronk HMH, et al. Endothelial activation in lacunar stroke subtypes. Stroke. 2010;41(8):1617–1622. [Crossref]
28. Dobrynina LA, Shabalina AA, Zabitova MR, Kremneva EI, Gadzhieva ZS, Krotenkova MV, et al. Tissue plasminogen activator and MRI signs of cerebral small vessel disease. Brain Sci. 2019;9(10). [Crossref]
29. Kario K, Matsuo T, Kobayashi H, Hoshide S, Shimada K. Hyperinsulinemia and hemostatic abnormalities are associated with silent lacunar cerebral infarcts in elderly hypertensive subjects. J Am Coll Cardiol. 2001;37(3):871–877. [Crossref]
30. Nagai M, Hoshide S, Kario K. Association of prothrombotic status with markers of cerebral small vessel disease in elderly hypertensive patients. Am J Hypertens. 2012;25(10):1088–1094. [Crossref]
31. Winkler MS, Bahls M, Böger RH, Ittermann T, Dörr M, Friedrich N, et al. Association of asymmetric and symmetric dimethylarginine with inflammation in the population-based study of health in pomerania. Biomolecules. 2023;13(11):1612. [Crossref]
32. Janes F, Cifù A, Pessa ME, Domenis R, Gigli GL, Sanvilli N, et al. ADMA as a possible marker of endothelial damage. A study in young asymptomatic patients with cerebral small vessel disease. Sci Rep. 2019;9(1):14207. [Crossref]
33. Wardlaw JM, Smith EE, Biessels GJ, Cordonnier C, Fazekas F, Frayne R, et al. Neuroimaging standards for research into small vessel disease and its contribution to ageing and neurodegeneration. Lancet Neurol. 2013;12(8):822–838. [Crossref]
34. Gorelick PB, Scuteri A, Black SE, Decarli C, Greenberg SM, Iadecola C, et al. Vascular contributions to cognitive impairment and dementia: a statement for healthcare professionals from the american heart association/american stroke association. Stroke. 2011;42(9):2672–2713. [Crossref]
35. Pasquier F, Leys D, Weerts JG, Mounier-Vehier F, Barkhof F, Scheltens P. Inter- and intraobserver reproducibility of cerebral atrophy assessment on MRI scans with hemispheric infarcts. Eur Neurol. 1996;36(5):268–272. [Crossref]
36. Leeuw F-E de, Kleine M de, Frijns CJM, Fijnheer R, Gijn JV, Kappelle LJ. Endothelial cell activation is associated with cerebral white matter lesions in patients with cerebrovascular disease. Ann N Y Acad Sci. 2002;977(1):306–314. [Crossref]
37. Zhang D-D, Cao Y, Mu J-Y, Liu Y-M, Gao F, Han F, et al. Inflammatory biomarkers and cerebral small vessel disease: a community-based cohort study. Stroke Vasc Neurol. 2022;7(4):302–309. [Crossref]

38. Gottesman RF, Cummiskey C, Chambless L, Wu KK, Aleksic N, Folsom AR, et al. Hemostatic factors and subclinical brain infarction in a community-based sample: the ARIC study. Cerebrovasc Dis. 2009;28(6):589–594. [Crossref]
39. Kim Y, Kim Y-K, Kim NK, Kim S-H, Kim O-J, Oh S-H. Circulating matrix metalloproteinase-9 level is associated with cerebral white matter hyperintensities in non-stroke individuals. Eur Neurol. 2014;72(3-4):234–240. [Crossref]
40. Notsu Y, Nabika T, Bokura H, Suyama Y, Kobayashi S, Yamaguchi S, et al. Evaluation of asymmetric dimethylarginine and homocysteine in microangiopathy-related cerebral damage. Am J Hypertens. 2009;22(3):257–262. [Crossref]
41. Pikula A, Böger RH, Beiser AS, Maas R, DeCarli C, Schwedhelm E, et al. Association of plasma ADMA levels with MRI markers of vascular brain injury: Framingham offspring study. Stroke. 2009;40(9):2959–2964. [Crossref]
42. Khan U, Hassan A, Vallance P, Markus HS. Asymmetric dimethylarginine in cerebral small vessel disease. Stroke. 2007;38(2):411–413. [Crossref]
43. Gao Q, Fan Y, Mu L-Y, Ma L, Song Z-Q, Zhang Y-N. S100B and ADMA in cerebral small vessel disease and cognitive dysfunction. J Neurol Sci. 2015;354(1-2):27–32. [Crossref]
44. Rufa A, Blardi P, De Lalla A, Cevenini G, De Stefano N, Zicari E, et al. Plasma levels of asymmetric dimethylarginine in cerebral autosomal dominant arteriopathy with subcortical infarct and leukoencephalopathy. Cerebrovasc Dis. 2008;26(6):636–640. [Crossref]
45. Chung J-W, Oh MJ, Cho YH, Moon GJ, Kim G-M, Chung C-S, et al. Distinct roles of endothelial dysfunction and inflammation in intracranial atherosclerotic stroke. Eur Neurol. 2017;77(3-4):211–219. [Crossref]
46. Tjärnlund-Wolf A, Brogren H, Lo EH, Wang X. Plasminogen activator inhibitor-1 and thrombotic cerebrovascular diseases. Stroke. 2012;43(10):2833–2839. [Crossref]
47. Party H, Dujarrier C, Hébert M, Lenoir S, Martinez de Lizarrondo S, Delépée R, et al. Plasminogen activator inhibitor-1(PAI-1) deficiency predisposes to depression and resistance to treatments. Acta Neuropathol Commun. 2019;7(1):153. [Crossref]
48. Shen X-N, Lu Y, Tan CTY, Liu L-Y, Yu J-T, Feng L, et al. Identification of inflammatory and vascular markers associated with mild cognitive impairment. Aging (Albany NY). 2019;11(8):2403–2419. [Crossref]
49. Trollor JN, Smith E, Baune BT, Kochan NA, Campbell L, Samaras K, et al. Systemic inflammation is associated with MCI and its subtypes: the Sydney memory and aging study. Dement Geriatr Cogn Disord. 2010;30(6):569–578. [Crossref]
50. Yang D, Nemkul N, Shereen A, Jone A, Dunn RS, Lawrence DA, et al. Therapeutic administration of plasminogen activator inhibitor-1 prevents hypoxic-ischemic brain injury in newborns. J Neurosci. 2009;29(27):8669–8674. [Crossref]
51. Nagai N, Suzuki Y, Van Hoef B, Lijnen HR, Collen D. Effects of plasminogen activator inhibitor-1 on ischemic brain injury in permanent and thrombotic middle cerebral artery occlusion models in mice. J Thromb Haemost. 2005;3(7):1379–1384. [Crossref]
52. Wei-Kang G, Dong-Liang Z, Xin-Xin W, Wei K, Qi-Dong Z, Yu Z, et al. Actin cytoskeleton modulates ADMA-induced NF-kappaB nuclear translocation and ICAM-1 expression in endothelial cells. Med Sci Monit. 2011;17(9): BR242-BR247. [Crossref]
53. Suda O, Tsutsui M, Morishita T, Tasaki H, Ueno S, Nakata S, et al. Asymmetric dimethylarginine produces vascular lesions in endothelial nitric oxide synthase-deficient mice: involvement of renin-angiotensin system and oxidative stress. Arterioscler Thromb Vasc Biol. 2004;24(9):1682–1688. [Crossref]
54. Libecap TJ, Bauer CE, Zachariou V, Pappas CA, Raslau FD, Liu P, et al. Association of baseline cerebrovascular reactivity and longitudinal development of enlarged perivascular spaces in the basal ganglia. Stroke. 2023;54(11):2785–2793. [Crossref]